

**Development and evaluation of two mouse models
for endometriosis focused on the involvement of the
immune system in endometriosis establishment**

Dissertation

zur Erlangung des akademischen Grades des
Doktors der Naturwissenschaften (Dr. rer. nat.)

eingereicht im Fachbereich Biologie, Chemie, Pharmazie
der Freien Universität Berlin

vorgelegt von
Diplom-Humanbiologin
Nicola Maria Nowak
aus Siegen

Juli 2008

Meinen Eltern

Gutachter / Referees

1. Gutachter: Prof. Dr. Ursula-Friederike Habenicht

2. Gutachter: Prof. Dr. Carsten Niemitz

Disputation am: 05.11.2008

Table of content

1	INTRODUCTION	7
1.1	Endometriosis overview	7
1.1.1	Definition and aetiology	7
1.1.2	Current therapies	12
1.2	Animal models for endometriosis	14
1.2.1	Primate models.....	14
1.2.2	Rodent models	15
1.2.2.1	Heterologous mouse models	15
1.2.2.2	Syngeneic and autologous mouse models.....	16
1.3	Endometriosis and inflammation.....	17
1.3.1	Immunological alterations in endometriosis patients.....	17
1.3.2	New anti-inflammatory therapeutic approaches	19
1.4	Endometriosis and angiogenesis	22
1.4.1	Angiogenic factors in endometriosis.....	22
1.4.2	New anti-angiogenic therapies	23
1.5	Aim of the thesis.....	25
2	MATERIAL AND METHODS	26
2.1	<i>In vitro</i>-techniques	26
2.1.1	Peritoneal lavage and peritoneal cell counting.....	26
2.1.2	Blood collection	26
2.1.3	Fluorescence-activated cell sorting (FACS)	27
2.1.4	Serum E ₂ level analysis with radio immune assay	27
2.1.5	<i>In vitro</i> macrophage stimulation and cytokine measurement.....	28
2.2	<i>In vivo</i>-techniques	28
2.2.1	Mice	28
2.2.2	Development of the transplantation model.....	29
2.2.3	Development of the injection model	30
2.2.4	Peritonitis model and endometriosis induction	31
2.2.5	Immune suppression model and endometriosis induction	32
2.3	Histological and immunohistochemical examinations	32
2.4	Statistical analyses	34
2.4.1	Statistical analysis of <i>in vitro</i> data	34
2.4.2	Statistics in the transplantation model.....	34
2.4.3	Statistics in injection model	35

3	RESULTS.....	36
3.1	Transplantation model.....	36
3.1.1	Evaluation and histological characteristics.....	36
3.1.2	Treatment with the anti-estrogen ZK703.....	39
3.1.3	Inflammatory parameters in the peritoneal cavity of mice with induced endometriosis.....	41
3.1.4	Summary transplantation model.....	44
3.2	Injection model	45
3.2.1	Evaluation and histological characteristics.....	45
3.2.2	Lesion establishment, morphology and inflammatory parameters at different time points after endometriosis induction.....	47
3.2.2.1	Morphology and histology of lesions	48
3.2.2.2	Analysis of peritoneal cell counts and cell composition.....	52
3.2.2.3	Measurement of cytokines in the peritoneal fluid	54
3.2.2.4	Summary of the time course experiment.....	54
3.3	Induction of endometriosis in inflamed peritoneal cavity.....	55
3.3.1	Evaluation of thioglycolate-induced acute peritoneal inflammation	55
3.3.2	Induction of endometriosis in an inflamed peritoneal cavity.....	57
3.3.3	Peritoneal inflammation decreased endometriosis	61
3.4	Induction of endometriosis in immune suppressed mice.....	62
3.4.1	Immune suppression model	62
3.4.2	Induction of endometriosis in immune suppressed mice	65
3.4.3	Immune suppression does not alter endometriosis establishment	65
3.5	Summary injection model.....	66
4	DISCUSSION	67
4.1	Mouse models of endometriosis	67
4.1.1	Transplantation model.....	67
4.1.2	Injection model	70
4.2	New insights into endometriosis development from time course experiments of lesion establishment	72
4.3	Impact of the immune system on endometriotic lesion establishment.....	76
4.4	Peritoneal inflammation in patients: Cause or consequence of endometriosis?	82
5	CONCLUSION AND OUTLOOK.....	85
6	SUMMARY / ZUSAMMENFASSUNG.....	86
7	REFERENCES.....	89

8	APPENDIX	98
8.1	List of publications.....	98
8.2	Abbreviations.....	99
8.3	Acknowledgements.....	100

1 Introduction

1.1 Endometriosis overview

1.1.1 Definition and aetiology

Endometriosis is a common benign gynaecological disorder and affects around 10 - 22 % of all women in reproductive age (1991). The disease is characterised by the presence of endometrial tissue fragments outside the uterine cavity, which grow in an estrogen-dependent manner. These so called endometriotic lesions are frequently found in the pelvis minor, especially on fixed organs like the ovaries, on parietal peritoneum, in the pouch of Douglas, on fallopian tubes and rectovaginal septum (Figure 1) (Osteen *et al.*, 2005). The morphology of lesions is categorised as “red (red, red-pink and clear lesions), white (white, yellow-brown) and black (black and blue lesions)” (ASRM, 1997). Examples for this division are depicted in Figure 2. Red lesions are highly vascularised and are assumed to bleed; white lesions are supposed to be scar tissue and include fibrotic material; black lesions often contain clotted blood. The lesion size ranges from pinhead up to large, egg-shaped cystic formations. Furthermore, adhesions are concomitant phenomena, often impairing several organs and making it impossible to distinguish the affected organs in detail.

In addition to the categorisation of lesion appearance, an internationally accepted classification of endometriosis definition was published by The American Society for Reproductive Medicine (ASRM) in a revised version 11 years ago. They suggested that four different stages of endometriosis should be distinguished: (I) minimal, (II) mild, (III) moderate and (IV) severe endometriosis. The determination is based on a weighted point system, in which the following parameters are investigated: superficial or deep endometriosis, severity of adhesions (filmy or dense), obliteration of the pouch of Douglas and enclosure of the ovaries (ASRM, 1997). The detection of the phenomenon called “kissing ovaries”, in which ovaries are very closely glued together, e.g. is a special indicator of severe endometriosis (stage IV) (Ghezzi *et al.*, 2005).

A common symptom is cyclical or non-cyclical pelvic pain with varying severity (light to severe). In women with chronic pelvic pain, endometriosis is diagnosed in 40 - 70 % of cases (Sinaii *et al.*, 2008). Irregular bleeding (dysmenorrhoea), problems during defaecation (dyschezia) and during sexual intercourse (dyspareunia) also belong to the manifestations of endometriosis. Besides pain, sub- and infertility are symptoms strongly associated with endometriosis (D'Hooghe *et al.*, 2003; Mahutte and Arici, 2002; Matalliotakis *et al.*, 2007, 2008). Twenty-one of 100 infertile patients were diagnosed with endometriosis in a study from 1982 (Strathy *et al.*, 1982). Recent data from the Practice Committee of the American Society

for Reproductive Medicine demonstrate that actually 30 - 50 % of all infertile women suffer from endometriosis (ASRM, 2004).

Due to this hardly tangible symptom profile, diagnosis is difficult and laparoscopic examination is required for a clear diagnosis. This surgical intervention is the gold standard for precise disease detection. Unfortunately, the disease is highly underdiagnosed and time to diagnosis often exceeds 6 to 8 years, which may partly be due to the unspecific symptoms and partly be attributed to risks associated with performing laparoscopy, such as adhesions, accidental puncture of the bowel or blood vessels and peritoneal inflammation, as it has been demonstrated in baboons (D'Hooghe *et al.*, 1999). A non-invasive diagnostic method is urgently needed to decrease time to diagnosis, being a current challenge in endometriosis research field.

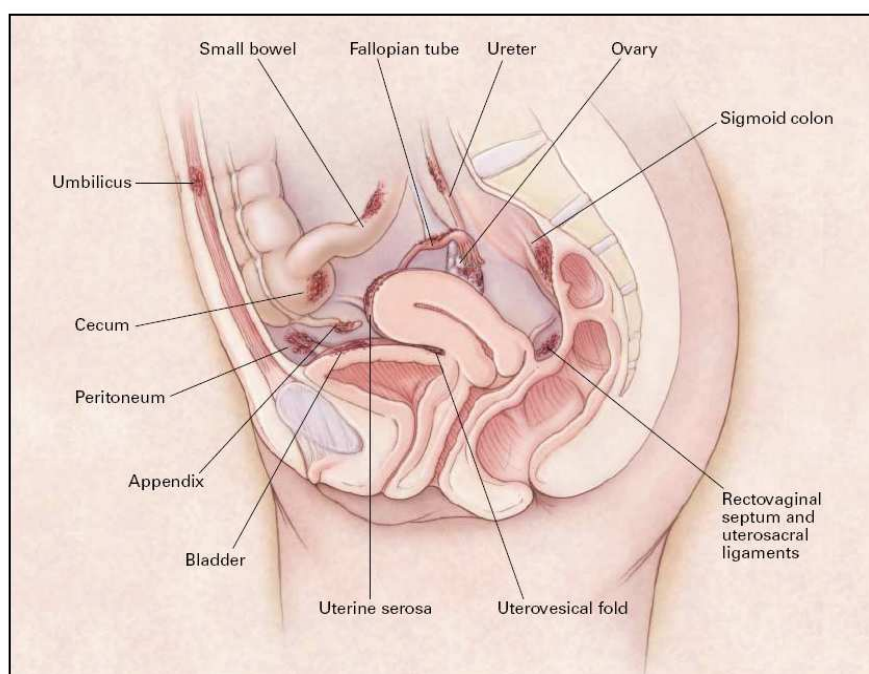


Figure 1: **Common locations of endometriotic lesions** (indicated as dark red patches) within the peritoneal cavity, e.g. on the ovary, bladder, uterine serosa, rectovaginal septum, pouch of Douglas (Olive and Pritts, 2001)

Epidemiological data revealed that several conditions are associated with increased risk for endometriosis, e.g. early menarche, shorter cycle length (24 instead of 28 days) and heavy menstrual bleeding as well as lower body weight and alcohol use (Matalliotakis *et al.*, 2007).

The aetiology of endometriosis is not yet fully understood. According to the widely accepted theory by John Sampson, lesion development is caused by retrograde menstruation (Sampson, 1927), which is a rather common phenomenon occurring in 90 % of all menstruating women (Halme *et al.*, 1984). Several points support this thesis, for example the fact that the sites of adhesion correspond to the side where tubal reflux occurs (Jenkins *et al.*,

1986), e.g. women with an occluded right fallopian tube have more lesions in the left abdominal side. Moreover, Klemmt *et al.* (2007) have demonstrated that endometrial cells express integrins and metalloproteinases on their surface, which are factors necessary for invasion, and further studies could show that pro-angiogenic factors are produced by endometrium and endometrial cells (Becker and D'Amato, 2007; Laschke and Menger, 2007), thus enabling the retrogradely transported tissue fragments to adhere to and invade into the peritoneum and to build up their own blood supply.

An additional fact supporting the reflux-theory is the similarity of endometriotic lesions with the primordial uterus. The inner layer of the uterus, composed of functional and basal endometrium, subendometrial musculature and stratum subvasculare (archimyometrium) is defined as archimetra and underlies cyclic activities due to hormonal changes from the ovary. Hence, Leyendecker *et al.* defined endometriotic lesions as “miniarchimetras”, postulating its development from shed endometrium, more precisely from the basalis cell layer (Leyendecker and Kunz, 2005). This finding was further supported by the fact that in 80 % of endometriosis patients fragments of basalis could be detected in menstrual blood (Leyendecker *et al.*, 2002).

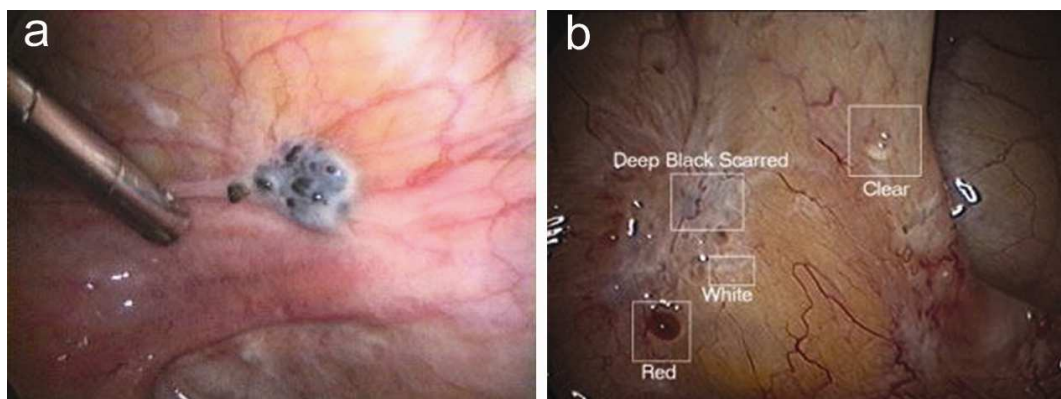


Figure 2: Laparoscopic overview of the different lesion types. (a) Laparoscopic view of implants of endometriosis with both black and white appearances, overlying the bladder. **(b)** Photograph demonstrating the varied appearances of endometrial implants, showing white, black and deep scarred implants. Most of these implants are on the left pelvic sidewall, located caudal of the ovary. (www.womenssurgerygroup.com)

Despite retrograde menstruation occurs in 90 % of all menstruating women with patent tubes (Halme *et al.*, 1984), only around 10 % of them develop endometriosis symptoms. Thus, peritoneal reflux is a necessary but insufficient condition leading to endometriosis. Hence, two additional theories have been proposed to explain the occurrence of endometrial tissue on ectopic sites: (1) development by coelomic metaplasia (the coelom being one of the two layers developed after the splitting of the embryonic mesoderm, and subsequently forming the pericardial, peritoneal and pleural cavities) or (2) development from Müllerian remnants.

The coelomic metaplasia theory suggests that germinal epithelium from the ovary (Matsuura *et al.*, 1999; Meyer, 1903) or the mesothelial layer of the peritoneal wall transforms into endometrium (Suginami, 1991; Vinatier *et al.*, 2001). This relation may be plausible since endometriosis occurs also in the absence of menstruation, for instance in males, such as one case of a cystic endometriosis in the epididymis in a 27-year-old male and a paratesticular endometriosis in a 82-year-old male treated with estrogens for prostatic adenocarcinoma, respectively (Giannarini *et al.*, 2006; Young and Scully, 1986). Furthermore, lesions were detected at extrapelvic locations such as vertebrae, the meninges or pancreas, but these cases are very rare (Bergqvist, 1992).

The theory regarding Müllerian remnants has recently been carefully examined and determined to be highly correlated but not causally associated with endometriosis. Sampson (1925) published a list of five classifications of heterotopic endometrial tissue. There are 4 variations automatically implying different subtypes of endometriosis (direct endometriosis, implantation endometriosis, transplantation endometriosis and metastatic endometriosis). The 5th, namely “developmentally misplaced endometrial tissue”, is now defined as Müllerianosis (Batt *et al.*, 2007), which results in similar histological qualities (endometrial glands and stroma), but differs in pathogenesis. Moreover, invasion seems to be the *sine qua non* for endometriosis (Koninckx *et al.*, 1999b). Müllerianosis on the other hand is not invasive and thus has to be distinguished from endometriosis (Batt *et al.*, 2007).

The processes of endometriosis establishment follow a series of escalating events. After retrograde menstruation, viable endometrial cells are flushed into the peritoneal cavity. This marks the beginning of endometrial-peritoneal adhesion. Subsequent processes of implantation and invasion are supported by increasing angiogenesis to supply the endometriotic fragments with oxygen and nutrients. During this process, inflammatory cells are recruited, which are assumed to further enhance the adhesion by secreting pro-angiogenic cytokines while failing to clear the endometriotic fragments. The final stage includes growth and maintenance of lesions. A detailed overview of the processes and involved factors is given in Figure 4.

According to the reflux theory by Sampson, endometriosis develops from shed cells of the uterine lining that retrogradely travel up the fallopian tubes into the peritoneal cavity. Hence it seems reasonable that the lesions also underlie the regulatory hormonal influences affecting the endometrium and the reproductive tract. This hypothesis is supported by the fact that the endometriotic implants are supposed to bleed on ectopic sites, underlined by the detection of “chocolate” or “black” lesions. This was mimicked in an endometriosis xenograft mouse model, where subcutaneously transplanted endometrial fragments bled after progesterone withdrawal (Greenberg and Slayden, 2004). Endometrial alterations are tightly regulated by

the hypothalamus-pituitary-axis. The neurosecretory cells of the hypothalamus secrete stimulatory and inhibitory hormones that affect hormone release of the pituitary gland. One of these hormones leads to the release of gonadotropins (e.g. follicle-stimulating hormone, FSH; luteinising hormone, LH; prolactin) from the anterior lobe of the pituitary and is therefore named gonadotropin-releasing hormone (GnRH). The gonadotropins then stimulate the reproductive tract, the ovaries and the uterus in a cyclic, feed-back controlled manner. The usual menstrual cycle amounts to 28 days and starts with menstruation followed by the proliferative, ovulatory and the secretory phases ending again in menstruation. The lesions are supposed to follow this reproductive cycle as well. Furthermore, endometriosis occurs mainly in women of reproductive age and regresses after menopause or under treatment with estrogen-suppressive substances such as danazol or gonadotropin-releasing hormone (GnRH) agonists. Thus, endometriosis seems to grow and regress in an estrogen-dependent manner (Kitawaki *et al.*, 2002).

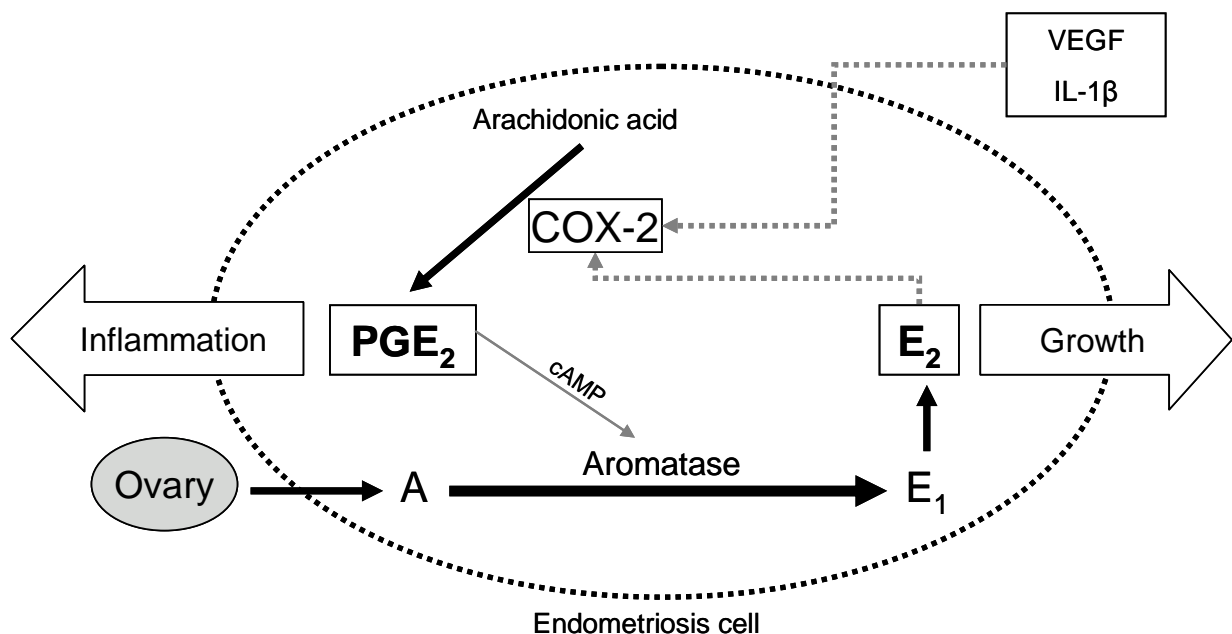


Figure 3: Hypothesised connections between aromatase activation, estrogen production, cell growth and inflammation in an endometriosis cell. Androstenedione (A), inter alia from the ovary, is converted by the enzyme aromatase to estrone (E₁). Estrone is further reduced to estradiol (E₂), which in turn stimulates cell growth and induces the enzyme cyclo-oxygenase-2 (COX-2). COX-2 converts arachidonic acid to prostaglandine E₂ (PGE₂), thus stimulating inflammation. Finally, PGE₂ activates aromatase via cyclic adenosine monophosphate (cAMP) and a positive feedback-loop is created. Vascular endothelial growth factor (VEGF) and IL-1β from the peritoneal environment also contribute by inducing COX-2 (Attar and Bulun, 2006).

The hypothesis that endometriotic lesion growth is estrogen-dependent was supported by publications revealing the presence of estrogen receptor (ER) and aromatase enzyme in endometriotic lesions (Jänne *et al.*, 1981; Matsuzaki *et al.*, 2001; Noble *et al.*, 1996). Aromatase converts androgens to estrogens and thus increases the level of 17β-estradiol (E₂) in the lesion and its environment. Estrogen, as indicated in Figure 3, leads to cell growth

and COX-2-activation, resulting in prostaglandine E₂ (PGE₂) production, increased inflammation and further activation of aromatase – a vicious circle is created (Attar and Bulun, 2006; Bulun *et al.*, 1999).

1.1.2 Current therapies

As mentioned above, endometriosis is an estrogen-dependent disease with pain as a major symptom. Current therapeutic management of this condition attempts to relieve symptoms through surgical and/or medical treatment. Surgery via laparoscopy or laparotomy removes lesions via excision; however, this procedure is far from ideal due to implied risks associated with all surgical interventions. Furthermore, Abbott *et al.* (2004) could demonstrate that 20 % of patients which underwent laparoscopic surgery did not report an improvement of pain.

Medical treatment aims to relieve pain in the first line with improvement of fertility as a second objective. It strives for suppression and atrophy rather than for removal of lesions. Due to hormonal sensitivity of endometriotic tissue, disease symptoms usually decrease in periods without menstruation and low E₂ levels, which include menopause, amenorrhea or pregnancy. This information was used to create medial therapeutic approaches, which aim to interfere with sex hormone metabolism.

The first drug approved for endometriosis by the FDA was danazol. This agent has androgenic agonist effects, inhibits enzymes in the steroidogenic pathway and increases free testosterone concentrations by displacement of testosterone from sex hormone-binding globulin (SHG). Treatment results in anovulation with hypoestrogenism and hyperandrogenism, thus relieving pain symptoms (Olive and Pritts, 2001). However, numerous adverse effects and poor tolerability due to its androgenic and anabolic properties are reported. Weight gain, acne, hirsutism, decreased breast size, hot flushes and muscle cramps frequently occur in women under danazol treatment.

Other commonly used therapeutics are agents like GnRH analogues, which successfully repress the hypothalamic-pituitary-ovary axis. They bind to GnRH receptors and result in stimulation of gonadotropin release. After this initial increase in gonadotropin secretion (a flare'), cessation follows due to the effect that GnRH analogues have a remarkably longer half life than natural GnRHs. Therefore the pituitary is exposed to continuous GnRH stimulation resulting in downregulation of its function and reduction of LH and FSH secretion. Consequently, secretion of ovarian steroids like E₂ is blocked, resulting in postmenopausal E₂ levels and pain relief is achieved in most cases. Side effects of this treatment are triggered by the hypoestrogenic status and range from dizziness, vaginal dryness, loss of libido to increased risk of thrombosis and osteoporosis (Griesinger *et al.*, 2005). As a remedy, "add back" hormone replacements can be given to alleviate the consequences of low E₂ in the

body (Garai *et al.*, 2006), especially when GnRH analogues are used as long-term treatment longer than 6 months (Child and Tan, 2001).

“Off-label use” (drug use beyond indications and not reimbursed by the health insurance) of combined oral contraceptives (COCs) is another frequently applied therapy to ease patients’ symptoms, leading to a pregnancy-pretending hormonal state with decreased gonadotropin levels, ovulation inhibition and reduced menstrual flow (Rice, 2002). For women with chronic pelvic pain where endometriosis is diagnosed, COCs are widely utilised as initial therapy, often together with analgesic non-steroidal anti-inflammatory drugs (NSAIDs). This approach is accompanied by fewer side effects, but like other anti-hormonal treatments, eliminates the possibility for pregnancy in affected women desiring children.

New agents to treat endometriosis are under investigation, which either target the hormonal metabolism or try to modulate the immune system or to influence angiogenic processes. One example for new anti-hormonal compounds are anti-estrogens like Selective Estrogen Receptor Modulators (SERMs), which are designed to act as antagonists on the endometrium and on lesions but as agonists on bone, e.g. to avoid osteoporosis. Raloxifene (Eli Lilly) was thought to be such a candidate. However, a recent study investigated the impact of raloxifene on chronic pelvic pain in a 6-month treatment period after surgery and revealed that raloxifene-treated patients reported pain significantly sooner than the placebo group (Stratton *et al.*, 2008). Thus, the study had to be terminated. It was hypothesised that raloxifene somehow induced a positive feedback loop, leading to increased estrogen levels and lesion growth; the latter resulting in increasing pain. Nonetheless SERMs are a promising approach due to their independent action on different target tissues and will be further investigated.

Another approach involving E_2 metabolism focuses on aromatase inhibitors. These substances aim to decrease local estrogen synthesis and thus inhibit lesion growth (see Figure 3). At present, anastrozole and letrozole, which showed reduction of pelvic pain scores in small pilot studies (Ailawadi *et al.*, 2004; Takayama *et al.*, 1998), are in clinical phase II (Mihalyi *et al.*, 2006), but require confirmation in larger, randomized clinical trials to evaluate their safety and side effect profiles.

Therapies influencing the immune system are yet another approach. Cyclo-oxygenase-2 (COX-2) is a strategic target as E_2 induces COX-2 activity, leading to elevated prostaglandin E_2 (PGE_2) production and thus mediating inflammation and pain. PGE_2 in turn is a potent stimulator of aromatase in endometriotic cells, resulting in elevated E_2 levels and cell growth (Figure 3). Therefore, inhibition of COX-2 would both decrease endometriotic cell growth *and* reduce inflammation besides the analgesic effect (Ebert *et al.*, 2005). Several selective COX-2 inhibitors have already been tested *in vivo*. While treatment with nimesulide did not

show any effect in a xenograft nude mouse model (Hull *et al.*, 2005), celecoxib decreased lesion establishment in a preventive approach in an autologous mouse model. However, this compound had no effect when delivered in a therapeutic setting (treatment started 15 or 30 days after endometriosis induction) (Efsthathiou *et al.*, 2005). In humans, daily treatment with 25 mg rofecoxib (Merck) showed a positive effect on dysmenorrhea, dyspareunia and chronic pelvic pain in a small study (28 patients, double-blind, placebo-controlled). Additionally, no significant side effects were detected (Cobellis *et al.*, 2004). Theoretically, use of selective COX-2 inhibitors could be of great benefit for the treatment of endometriosis, targeting local estrogen production and inflammation. At the moment, agents like rofecoxib are already used due to their analgetic effects. However, increased risks of cardiovascular side effects are associated with long-term use of COX-2 inhibitors (Hochman and Shah, 2006; Moore *et al.*, 2007). Thus, additional studies in non-human primates are needed to further evaluate the safety of these drugs.

Due to the fact that the establishment of a new blood supply is essential for the survival of lesions, additional non-hormonal approaches include anti-angiogenic agents (for further information see 1.4). Endostatin (a proteolytic fragment of collagen XVIII) as well as an antagonist against the pro-angiogenic growth factor VEGF-A have been successfully tested in autologous (Becker *et al.*, 2005) and xenograft mouse endometriosis models, respectively (Hull *et al.*, 2003). When conducting experiments with anti-angiogenic approaches, teratogenic effects of the compound always have to be considered. No such effects could be demonstrated when mating mice treated with endostatin compared to untreated animals (Becker *et al.*, 2005). However, studies in a validated non-human primate model are necessary prior to conducting clinical trials.

1.2 Animal models for endometriosis

Endometriosis is a disease that mainly affects humans and only some non-human primates. Disease pathophysiology cannot be studied in women because all patients already demonstrate established endometriosis. Moreover, disease progression can only be confirmed by repeated laparoscopic examinations, raising ethical concerns. Thus, endometriosis research must rely on animal models.

1.2.1 Primate models

The only species developing spontaneous endometriosis are several non-human primates. Although this disease has been detected in 11 different monkey species (Story and Kennedy, 2004), most experiments are conducted with Rhesus macaques and baboons. In these animals, the lesions establish at similar sites and demonstrate comparable histological characteristics to the human condition. While spontaneous endometriosis develops slowly

and with low frequency in the wild, its frequency increases in direct relation with time in captivity. As an additional model, artificial induction of endometriosis has been established with various methods like repositioning of the cervix in the first experiments (Scott and Te-Linde, 1950), suturing of endometrium fragments at ectopic sites in the peritoneal cavity (Fazleabas *et al.*, 2002) or injection of endometrium (D'Hooghe *et al.*, 1995b). Both the spontaneous and artificial models have been used extensively in various experiments. The primates developing spontaneous endometriosis offer an ideal situation to examine the influence of ectopic implants on eutopic endometrium and the differences between the tissues. Additionally, by comparing parameters in spontaneous versus induced endometriosis, cause and effect of disease development can be studied (Grummer, 2006). Although the non-human primates are the most appropriate model to investigate endometriosis, the infrequent rate and the long periods to disease manifestation in captured primates and ethical considerations concerning primate experiments in general as well as high costs make this model impractical for systematic evaluation in endometriosis research. For these reasons, small laboratory animal models, mainly performed in mice and rats, have been developed over the last decades.

1.2.2 Rodent models

Unlike non-human primates, rodents do not menstruate and, therefore, do not spontaneously develop endometriosis. However, disease can be induced in rabbits, hamsters, rats or mice using autologous techniques as detailed below (1.2.2.2). The first autologous endometriosis rodent model was performed in rabbit. In this approach, endometrium fragments from one uterus horn were transplanted on the peritoneum (Schenken and Asch, 1980) and 14 days later could be histologically confirmed as endometriosis-like lesions. Vernon and Wilson applied this technique on rats, suturing uterine squares on the peritoneum (1985) with the same result. In hamsters, two autologous transplantation models were established, one with uterus biopsies on peritoneum (Steinleitner *et al.*, 1991), the other with endometrial fragments placed on the striated skin muscle in a dorsal skin-fold chamber (Laschke *et al.*, 2006b). Another, frequently used animal model for endometriosis research is the mouse model, whether as heterologous, autologous or syngeneic approach.

1.2.2.1 Heterologous mouse models

Heterologous mouse models all include transplantation or injection of non-mouse material in immunodeficient mice. Human endometrium from women with or without endometriosis or fragments from endometriotic lesions are utilized in these models, whether intraperitoneally or subcutaneously (Grummer *et al.*, 2001; Nisolle *et al.*, 2000; Zamah *et al.*, 1984).

Mice with a defective immune system lack a graft-versus-host reaction and thus allow for successful establishment of tissue fragments. First approaches have been conducted with athymic “nude” mice (Han:NMRI nu/nu) (Zamah *et al.*, 1984). Later on, severe combined immunodeficient mice (SCID) and non-obese diabetic (NOD)-SCID mice were employed, which display a congenital deficiency in T- and B-lymphocyte function. Compared to “nude” mice experiments, the “take-rate” (the number of fragments established from the number of transplanted ones) was higher in SCID mice and the developed lesions showed a better preserved morphology and expression of steroid receptors (Aoki *et al.*, 1994; Grummer *et al.*, 2001). However, these mouse strains maintain detectable natural killer (NK) cell activity. Hence, an immunodeficient strain additionally deficient in NK-cell activity [RAG-2 γ (c)-knockout] was used for heterologous transplantation, resulting in visible lesions only when the transplanted endometriotic biopsies contained gland-like structures (Greenberg and Slayden, 2004).

Taken together, the heterologous models are advantageous compared to primate models due to high availability and low costs. The fact that human endometrial or endometriotic tissue is utilized in these models is valuable for evaluating the aetiology of the disease and for therapeutic testing of pharmacological approaches (Gruemmer, 2006). Despite these advantages, investigating the impact of the immune system on lesion establishment is not possible in these models. For this purpose, autologous models in non-immunosuppressed mice are helpful.

1.2.2.2 Syngeneic and autologous mouse models

Adapted from the first rat model (Golan *et al.*, 1984; Vernon and Wilson, 1985), the first autologous mouse model was described in 1995 by Cummings and Metcalf (1995). In this model, one uterus horn is excised and cut into small fragments which are then sutured in the same animal on defined places in the peritoneal cavity. The advantage of this model is the high take rate due to fixed lesions and the easy recovery. Alternatively, endometrium alone can be used to establish endometriosis by injection into the peritoneal cavity (Somigliana *et al.*, 1999). Unfortunately, the detection of lesions in this approach is low due to difficult discovery of the lesions. An approach to overcome this problem was presented by Hirata *et al.* (2005) in a syngeneic model. They used EGFP-transgenic mice as endometrium donors, removed the endometrium and injected the fragments into a sibling recipient mouse. Consequently the fluorescent EGFP in developed lesions could be easily detected.

Limitations of these models are the obvious lack of menstruation and subsequent spontaneous endometriosis. Additionally, the use of entire uterus including myometrium in the suture model does not exactly mimic the situation of human endometriotic lesions. Nevertheless, various studies have been carried out using autologous mouse models. The

opportunity to examine large groups of genetically similar animals as well as long-term studies, low costs and a well-characterised murine genome and immune system are important advantages of these models (Gruemmer, 2006). Other benefits are the possibility of investigating environmental influences like dioxin on the establishment of lesions (Cummings *et al.*, 1996) or of impacts on fertility (Cummings and Metcalf, 1996). These models are highly suitable for examining immunomodulatory drugs or anti-inflammatory compounds and have thus been selected for the experiments performed herein.

1.3 Endometriosis and inflammation

Inflammatory and angiogenic processes seem to lie closely together in many diseases and often the same factors (like TNF- α ; 1.4.1) are regulated in both incidents. In endometriosis, a similar situation occurs, as is depicted schematically in Figure 4.

In the next paragraph, inflammation and angiogenesis in endometriosis and potential therapies referring to these issues are divided into 2 sections to give a general survey of each particular process. Nevertheless, it often cannot be thoroughly distinguished between successful anti-inflammatory and anti-angiogenic therapy; most likely both processes are involved in endometriosis. Thus, mentioning of angiogenic factors in the inflammatory section and vice versa is inevitable and underlines the complexity of this disease.

1.3.1 Immunological alterations in endometriosis patients

In recent years, the potential role of the immune system in endometriosis pathophysiology has increasingly gained new attention. Immunological alterations in patients have been noticed for decades, but were regarded as secondary side effects and have not been further evaluated as potential cause of the disease or possible target for therapeutical approaches. Hypothesised influences include increased inflammatory activity in the peritoneal fluid as well as impaired immune recognition, also described as defective 'immunosurveillance' (Christodoulakos *et al.*, 2007), and hindered clearance of ectopic cells (Kyama *et al.*, 2003). Consequently, intense research efforts have focused on elucidating differences between healthy versus endometriosis-afflicted women. Peritoneal fluid examination of endometriosis patients contains significantly increased amounts of cytokines like interleukin (IL) 6, IL-8 and the monocyte chemotactic protein-1 (MCP-1) compared to healthy samples (Kalu *et al.*, 2007; Pizzo *et al.*, 2002). MCP-1 is a chemo-attractant that recruits macrophages into the peritoneal cavity which are able to secrete further pro-inflammatory cytokines such as Regulated upon Activation, Normal T cell Expressed and Secreted (RANTES) (Lebovic *et al.*, 2004) and angiogenic IL-8. Moreover, peritoneal macrophages (PM) are increased in the peritoneal fluid of patients. Additionally, these macrophages produce higher levels of IL-1 β , IL-6, IL-8, IL-10 and tumour necrosis factor α (TNF- α) under basal and stimulated conditions *in vitro*

compared to peritoneal macrophages of healthy women (Montagna *et al.*, 2007; Rana *et al.*, 1996). Peritoneal macrophages from women with endometriosis also stimulate eutopic and ectopic endometrial cell proliferation *in vitro* (Braun *et al.*, 2002; Loh *et al.*, 1999) and macrophage-conditioned medium acts as a growth factor on murine endometrial stromal cells (Olive *et al.*, 1991). Macrophage secretory products, IL-8 and TNF- α , are known to enhance proliferation and adhesion of endometrial cells (Arici *et al.*, 1998; Garcia-Velasco and Arici, 1999; Harada *et al.*, 1999). Profiles of other immune cells are altered as well: natural killer cell cytotoxicity (Vinatier *et al.*, 1996; Wilson *et al.*, 1994) and T-cell cytotoxicity is decreased (Harada *et al.*, 2001) in peritoneal cells from endometriosis patients.

Furthermore, adhesion processes play an important role in endometriosis establishment. Without attachment to the peritoneal wall or the mesothelial lining of the peritoneal cavity, the regurgitated fragments would not survive. It has been suggested that inflammatory parameters contribute to these adhesive incidents. Cytokines like TNF- α , IL-6 and IL-8 produced by endometrial cells are most likely involved by stimulating the adhesion of endometrial stromal cells to extracellular matrix components (Witz *et al.*, 2001a). Matrix metalloproteinases (MMPs) are hypothesised to be involved as well. These enzymes are tissue-remodelling proteases, associated with destructive and invasive diseases when aberrantly expressed (Sternlicht and Werb, 2001). MMP-1, MMP-3 and MMP-7 for instance are elevated in eutopic and ectopic endometrium from women with endometriosis (Bruner-Tran *et al.*, 2002; Hudelist *et al.*, 2005). Bruner *et al.* (1997) already evaluated the connection between MMP expression and endometriosis in a xenograft mouse model and discovered that suppression of enzyme activity with tissue inhibitor of matrix metalloproteinases (TIMP-1) prevented the establishment of lesions. Pro-inflammatory cytokines like TNF- α have been shown to increase the expression of MMP-3, thus the inflammatory environment in the peritoneal cavity might contribute to the invasive nature of endometrial fragments (Sillem *et al.*, 2001).

The capacity of endometriotic cells to avoid elimination by the immune system can reflect either or both inherent resistance and/or impaired capacity of the immune cells to mediate endometriotic cell lysis. The latter was investigated by Somigliana *et al.* (1996), who examined the concentrations of soluble intracellular adhesion molecule-1 (sICAM-1) in endometrial cell culture supernatants. Their study demonstrated that endometrial stromal cells constitutively shed this molecule from their surface. Furthermore, they first incubated isolated NK cells with the supernatant and consequently cocultured endometrial stromal cells with the incubated NK cells to measure cytotoxicity. This experiment resulted in a significant correlation between the concentration of sICAM-1 in the supernatant and the percentage of inhibited, NK cell mediated, cell lysis. Thus, they hypothesised that an increased sICAM-1

secretion decreases NK cytotoxicity and may allow endometrial fragments to elude immunosurveillance.

Taken together, these findings indicate a strong involvement of the immune system in the pathogenesis of endometriosis. Several therapeutic approaches aiming to modulate the immune system have been conducted in animal experiments and are presented below.

1.3.2 New anti-inflammatory therapeutic approaches

In order to further explore the role of the immune system in endometriosis towards new possible therapies in this field, various animal experiments based on different inflammatory processes have been conducted. COX-inhibitors and nonsteroidal anti-inflammatory drugs (NSAIDs) are already prescribed in the clinic as first-line treatment to manage endometriosis-caused pain. The effect of NSAIDs was examined in an autologous murine model, which resulted in decreased lesion burden in NSAID-treated mice (e.g. celecoxib, indomethacin, ibuprofen), but showed no effect for aspirin (Efsthathiou *et al.*, 2005). In contrast to these findings, Hull *et al.* demonstrated that the selective COX-2 inhibitor nimesulide did not reduce lesion size or number in a “nude” mouse model (Hull *et al.*, 2005). Further contradictory results were reported by Ozawa *et al.* (2006), who investigated the effect of a selective COX-2 inhibitor (NS398) on lesion development in a SCID-xenograft model and discovered a significant decrease in lesion size. Thus, further studies are necessary to evaluate the usability and safety of COX-2 inhibition and NSAID effects on endometriosis. Tumour necrosis factor- α (TNF- α) is another key factor in inflammatory processes concerning endometriosis (1.3.1). When neutralised by the recombinant human TNFRSF1a (r-hTBP1, the soluble form of TNF receptor type 1), lesion development diminished in rats (D'Antonio *et al.*, 2000) and in a prospective, randomized, placebo- and drug controlled study in baboons (D'Hooghe *et al.*, 2006). TNFRSF1a-treated baboons showed a lower peritoneal lesion surface area and volume. In addition, the histological confirmation of excised lesions to be endometriotic lesions was lower compared to controls. Studies like these are evidence for an effective immunomodulatory treatment of endometriosis. Due to the fact that TNF- α is also involved in angiogenic processes, which will be explained later on (1.4.1), it cannot be thoroughly distinguished between successful anti-inflammatory and anti-angiogenic therapy, presumably both processes are involved.

Lebovic *et al.* (2007) treated baboons exhibiting intraperitoneally induced endometriosis with Peroxisome Proliferator-Activated Receptor- γ (PPAR- γ) ligand (rosiglitazone) and compared this group with GnRH-antagonist or placebo-treated primates. PPAR- γ ligands inhibit TNF- α , IL-6 and IL-1 β expression in monocytes (Jiang *et al.*, 1998), demonstrate potent inhibition of cell growth (Houston *et al.*, 2003) and display anti-angiogenic effects mediated by decreased VEGF-production (Panigrahy *et al.*, 2002), the latter being another

example for the proximity of inflammatory and angiogenic processes. Treatment with rosiglitazone resulted in statistically significantly lower surface area of endometriotic lesions compared to placebo group. Furthermore, a change from red lesions to white implants was observed in rosiglitazone-treated baboons, indicating a possible conversion of active lesions to inactive ones (Lebovic *et al.*, 2007). However, a clinical phase II study to examine the effect of rosiglitazone on endometriosis (Clinical trials.gov identifier: NCT00115661), conducted by Lebovic and the National Institute of Child Health and Human Development (NICHD), has been suspended due to the recent meta-analysis about cardio-vascular adverse effects (Lebovic, 2005).

Another immunomodulatory drug is pentoxifylline (PTX; a xanthine derivative), which is a known inhibitor of TNF- α (Schandene *et al.*, 1992). Administration of PTX to rats after endometriosis induction resulted in a decrease of lesions (Nothnick *et al.*, 1994). However, a prospective clinical study revealed no effect of this immunomodulatory drug on recurrence of endometriosis in humans (Alborzi *et al.*, 2007). In contrast to this finding, a clinical study performed by Kamencic and Thiel (2008) to examine the effect of PTX on recurrence of endometriosis after conservative surgery resulted in a significantly better visual analogue pain scale (VAS) score in patients treated for 2 or 3 months, compared to the status before surgery and treatment. Due to this contradictory outcomes, further investigations are needed to clarify the effects of PTX on endometriosis in humans.

In summary, all these findings suggest that the immune system in the peritoneal environment of women with endometriosis is altered and highly activated. Still the question of origin remains: are these changes in immunological and inflammatory mediators a cause or consequence of endometriosis? Perhaps an exaggerated immune response to retrogradely transported endometrial cells provides a convenient environment for endometriosis establishment or an already existing peritoneal inflammation leads to adherence and growth of ectopic endometrial fragments. Many anti-inflammatory or immunomodulatory approaches have been investigated in animals and humans, but the results are contradictory, prompting further investigation, clinically and via animal experiments. The present work investigates the influence of the immune system on endometriosis establishment and explores these processes with the help of autologous and syngeneic mouse models.

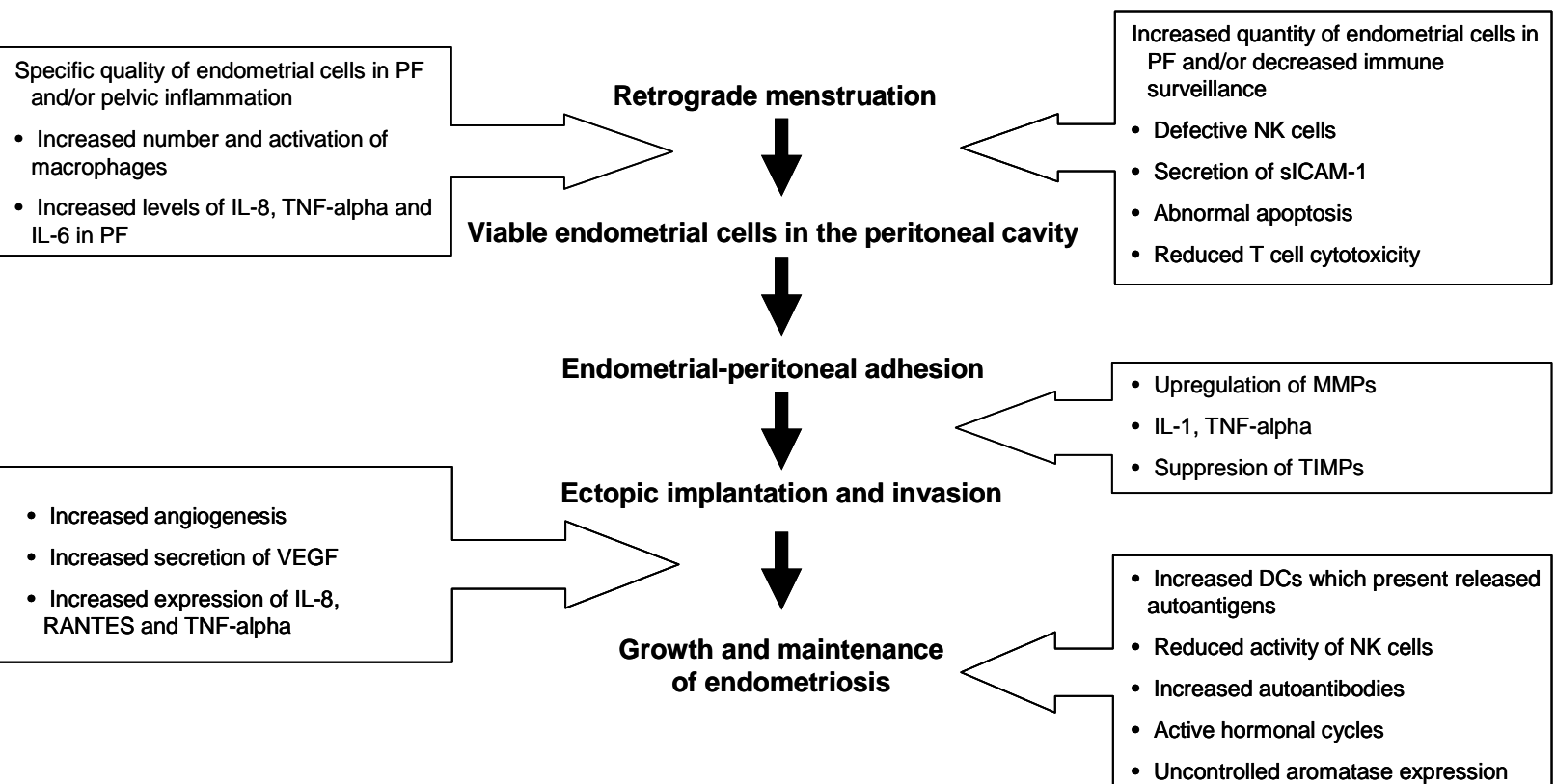


Figure 4: A simplified overview of the processes leading to endometriosis establishment and the role of immune system and angiogenesis in the development and maintenance of endometriosis. PF = peritoneal fluid, NK cells = natural killer cells, sICAM = soluble intracellular adhesion molecule, MMPs = matrix metalloproteinases, TIMPs = tissue inhibitors of metalloproteinases, DC = dendritic cells, VEGF = vascular endothelial growth factor (Kyama *et al.*, 2003)

1.4 Endometriosis and angiogenesis

As mentioned previously, in endometriosis both inflammatory and angiogenic processes are involved. The latter will be described in more detail in the following section, presenting angiogenic factors and anti-angiogenic therapeutic approaches in endometriosis.

1.4.1 Angiogenic factors in endometriosis

The process of building new blood vessels from pre-existing ones is called angiogenesis. Other processes concerning new blood vessels are vasculogenesis, the spontaneous development out of precursor cells (angioblasts), and intussusception, the vessel formation by splitting off of existing ones. Neovascularisation in turn describes the formation of functional microvascular networks with red blood cell perfusion (Rucker *et al.*, 2006).

Angiogenesis starts from a mature blood vessel, which becomes destabilised due to the dissolution of pericytes and smooth muscle cells, the so called mural cells (Fujimoto *et al.*, 2004), and degradation of extracellular matrix stimulated by pro-angiogenic factors like vascular endothelial growth factor (VEGF-A) (Figure 5). Consequently, endothelial cells are able to migrate and build capillary buds and sprouts in the surrounding interstitium. The newly developed blood vessels increase via proliferation of endothelial cells. Finally, attachment of the mural cells to the vessel wall and the production of extracellular matrix compounds enhances stabilisation (Laschke and Menger, 2007).

Recent studies suggested that angiogenesis plays a pivotal role in the pathogenesis of endometriosis (Taylor *et al.*, 2002) and represents a crucial step during endometriosis establishment. The lesions require blood to deliver oxygen and essential nutrients for growth. Indeed, various pro- and anti-angiogenic molecules have been identified in women with endometriosis (Laschke and Menger, 2007), often displaying an imbalance compared to healthy subjects.

Examples for interaction of angiogenesis and inflammatory factors and processes are frequently detected in endometriosis. Cytokines like IL-1 β for example are secreted by activated macrophages in endometriosis patients and increased expression of pro-angiogenic VEGF-A and IL-6 is observed *in vitro* (Lebovic *et al.*, 2000). Additionally, stimulation of endometrial stromal cells with IL-1 β results in an upregulation of IL-8 gene expression, a pro-angiogenic cytokine (Rossi *et al.*, 2005). IL-8 in turn excites angiogenesis (Strieter *et al.*, 1992) and, together with TNF- α , leads to an increased release of VEGF-A by neutrophils after *in vitro* stimulation with PF from endometriosis patients (Na *et al.*, 2006). Another recent study could demonstrate that TNF- α leads to a secretion of VEGF-A from infiltrating neutrophils and macrophages in an endometriosis mouse model (Lin *et al.*, 2006). VEGF-A itself is one of the

most important and extensively investigated pro-angiogenic factors. Its production is stimulated by various cytokines, hormones like estrogen and progesterone, prostaglandin E2 and hypoxic conditions (Cullinan-Bove and Koos, 1993; Lebovic *et al.*, 2000; Lin *et al.*, 2006). With regard to endometriosis, VEGF-A is believed to be the main stimulus for angiogenesis and increased vascular permeability (Taylor *et al.*, 2002). It has also been shown to be elevated in peritoneal fluid and lesions of endometriosis patients (Donnez *et al.*, 1998).

Sex hormones, especially E₂, also play an important role in endometriotic angiogenesis. This hormone is involved in several different pathways resulting in a direct increase of VEGF expression (Hyder *et al.*, 2000), eg. by upregulation of aromatase in endometriotic lesions, resulting in stimulation of COX-2, increased levels of prostaglandin E2 (PGE2), enhanced VEGF-expression (Pai *et al.*, 2001) and finally increased COX-2 expression (Tamura *et al.*, 2002) (Figure 3).

1.4.2 New anti-angiogenic therapies

Anti-angiogenic agents display different mode of action. They can affect pro-angiogenic cytokines and inhibit their interaction with their receptor (e.g. VEGF-A inhibitors) or have a direct inhibitory impact on endothelial cells (Tabruyn and Griffioen, 2007).

Agents affecting pro-angiogenic cytokines include a soluble form of truncated VEGF receptor (sFlt-1) or an affinity-purified antibody against VEGF. These two agents significantly inhibited endometriotic lesion growth in a mouse model (Hull *et al.*, 2003; Nap *et al.*, 2004).

The endogenous anti-angiogenic protein endostatin for example acts directly on endothelial cells, inter alia by downregulating the gene expression of angiogenic factors (Tabruyn and Griffioen, 2007). However, the specific effects are still unknown. Treatment of induced endometriosis in mice with endostatin resulted in growth inhibition of newly formed lesions but did not affect established implants (Becker *et al.*, 2005). Additionally, no impact on fertility or teratogenic effects could be demonstrated.

Another potent angiogenesis inhibitor is the synthetic antibiotic TNP-470 (fumagillin analogue), which acts through inhibition of VEGF-induced VEGF receptor 2 (VEGFR2) phosphorylation (Satchi-Fainaro *et al.*, 2005). Applied in an animal model, TNP-470 reduced the number of established lesions by more than 50 % in non-pregnant mice (Nap *et al.*, 2004). However, severe effects on embryonic growth were detected in pregnant mice (Klauber *et al.*, 1997). Hence, a non-toxic derivative of TNP-470 named caplostatin was developed and utilised successfully in a syngeneic, non-invasive mouse model resulting in inhibition of lesion growth (Becker *et al.*, 2006).

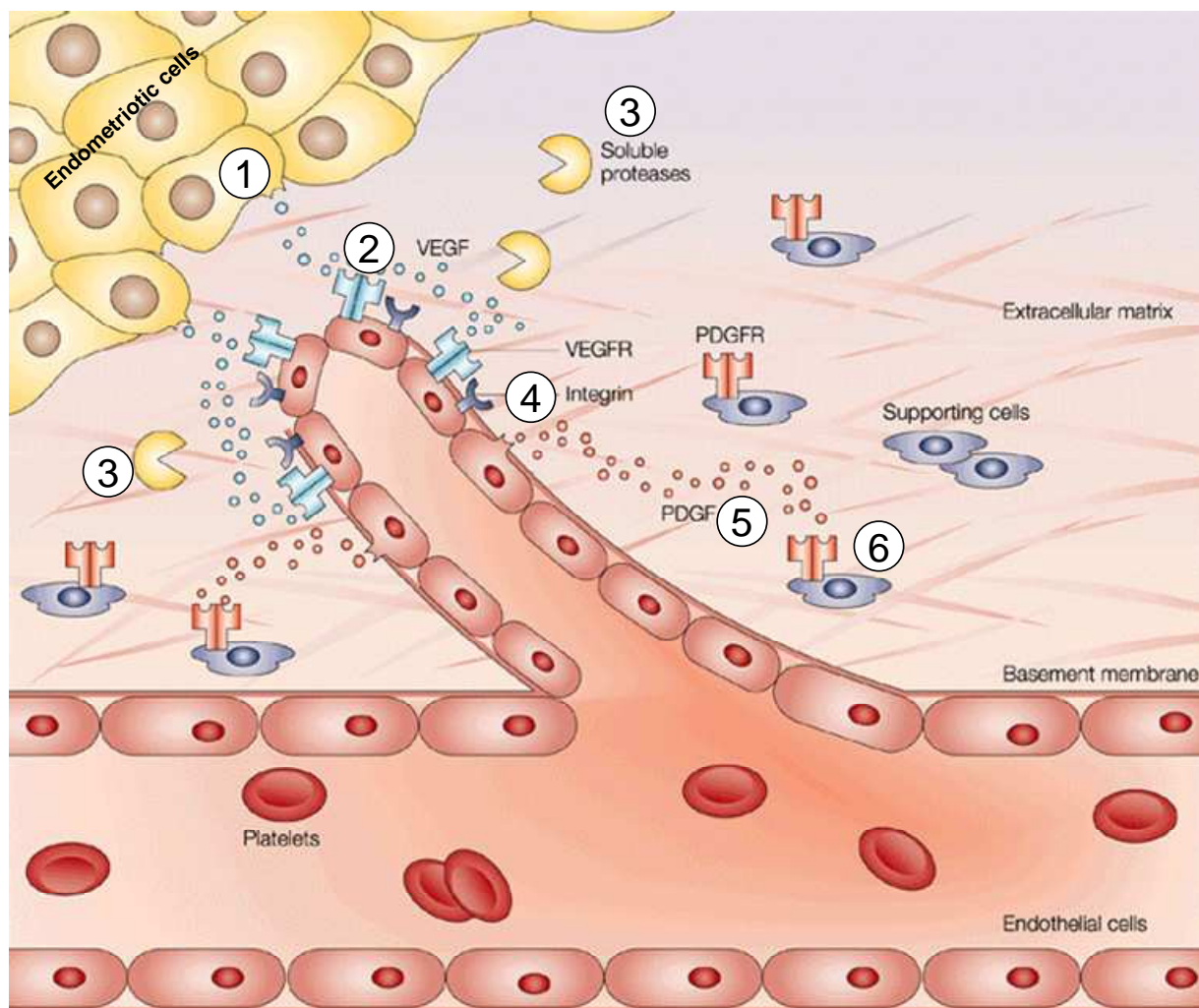


Figure 5: **Hypothetical depiction of angiogenesis processes in endometriosis.** (1) Endometrial cells are proposed to release pro-angiogenic factors, such as vascular endothelial growth factor (VEGF), which diffuse into nearby tissues and (2) bind to receptors on the endothelial cells of pre-existing blood vessels, leading to their activation. Such interactions between endothelial cells and endometrial cells lead to the secretion and activation of various proteolytic enzymes, (3) such as matrix metalloproteinases (MMPs), which degrade the basement membrane of vessels and the extracellular matrix. Degradation allows activated endothelial cells to migrate towards the endometrial cells. (4) Integrin molecules help to pull the sprouting new blood vessel forward. The endothelial cells deposit a new basement membrane and secrete growth factors, (5) such as platelet-derived growth factor (PDGF), which attract (6) supporting cells to stabilise the new vessel. PDGFR = PDGF receptor; VEGFR = VEGF receptor (modified after Cristofanilli *et al.*, 2002)

Additionally, anti-inflammatory agents could also interfere with angiogenesis, as inflammatory and angiogenic processes often interact. COX-2 induction results in the production of PGE2 and estradiol, which in turn increase VEGF expression (Figure 3). Selective inhibition of this key enzyme COX-2 is likely to result in inhibition of angiogenesis. Several animal experiments have already shown that selective COX-2 inhibition decreases lesion establishment (1.3). However, the effects may have also been caused by the anti-inflammatory properties of these agents.

Taken together, promising approaches concerning anti-angiogenic compounds as potential therapeutics for endometriosis have been conducted. Nevertheless, further investigation is

needed to gain a deeper understanding of the angiogenic processes in lesion establishment. Furthermore, it is important to bear in mind that anti-angiogenic therapies may not only interfere with lesion vascularisation, but could also disrupt necessary physiological angiogenesis in female reproductive organs, essential for normal cycling, fertility and pregnancy (Reynolds *et al.*, 1992). Therefore, it has to be carefully considered when to treat patients with anti-angiogenic compounds.

1.5 Aim of the thesis

One aim of this thesis was the establishment and evaluation of two different mouse models for endometriosis to investigate their suitability as animal models for this disease and for testing of therapeutic approaches. One model was developed by transplanting autologous uterus biopsies in the peritoneal cavity. This model had the benefit of easy lesion detection and access due to fixed transplants. In the second model endometriosis was induced by injecting endometrial fragments, thereby mimicking retrograde menstruation. In both models, histological and immunohistochemical examinations were performed to investigate the analogy of mouse endometriotic lesions to human lesions.

Furthermore, a goal was to gain a deeper knowledge about lesion development processes and to discover tissue reorganisation and angiogenesis in a time course experiment in the injection model.

The main aim was to investigate the involvement of the immune system in general and especially in endometriosis establishment. Therefore, peritoneal lavages in both models were performed, followed by evaluation of peritoneal cell types and cytokine measurement to evaluate inflammatory processes after endometriosis induction, either after establishment of lesions (for the transplantation model) or at various time points (for the injection model).

In line with investigation of the immune system it was evaluated if a pre-existing inflammation has any impact on endometriosis establishment. This question is of long-standing clinical interest and has not been approached in a mouse model before. Therefore, a peritonitis model was established and endometriosis was induced in the pre-inflamed peritoneal cavity.

Moreover, the effect of systemic immune suppression on lesion establishment was analysed. A model for immune suppression was established and evaluated and, consequently, endometriosis was induced in immunosuppressed mice.

2 Material and Methods

2.1 *In vitro*-techniques

2.1.1 Peritoneal lavage and peritoneal cell counting

To gain peritoneal cells and fluid, a peritoneal lavage was performed. Therefore, the mice were sacrificed by inhalation of CO₂. The fur above the umbilicus was wetted with 70 % ethanol (Merck, Darmstadt, Germany; diluted in distilled water), held with tweezers and a short, 5 mm horizontal cut was made. The fur above and below the cut was gripped and pulled apart to expose the peritoneum. This has to be carefully done to avoid vents in the peritoneum. A 5-mL syringe (B. Braun, Melsungen, Germany) was filled with 5 mL ice-cold sterile phosphate-buffered saline (PBS; PAA, Pasching, Austria) which was slowly injected into the peritoneum with a 26-gauge needle (B. Braun). Then a disinfected, wetted needle cap was used to thoroughly massage the liquid-filled belly for at least 1 min. To gain the peritoneal fluid, a 20-gauge needle was inserted into the peritoneal cavity, 4 mL of the liquid were carefully extracted and filled in cold 15 mL falcon tubes (BD, San Diego, USA) on ice.

The falcon tubes were centrifuged for 5 min at 4 °C with 1000 rpm (multifuge 3 S-R, Thermo Fischer Scientific, Rochester, USA). The supernatant, named peritoneal fluid (PF) in the following, was decanted into a new tube and frozen at -80 °C. The remaining cell pellet was resuspended in 1 mL cold PBS and transferred into a new 1.5 mL tube. Then 50 µL were taken out for cell counting. Finally, the cells were centrifuged again under same conditions as already mentioned, the supernatant was discarded, the cell pellet resuspended in 100 µL freezing medium [10 % dimethyl sulfoxide in foetal calf serum (FCS), both Gibco-Invitrogen, Karlsruhe, Germany] and frozen at -80 °C in an isopropanol cell freezing tank (Nalgene/Thermo Fischer Scientific).

Cells were counted with a CASY cell counter (CASY, Schaefer System GmbH, Reutlingen, Germany). To exclude false positive results due to contaminating erythrocytes, only cells larger than 5 µm in diameter were measured.

2.1.2 Blood collection

Mice were narcotised with ether, the neck gently compressed and the eye made to bulge. Then a glass capillary pipette was used to collect blood from the retrobulbar venous plexus. For FACS analysis, the blood was transferred to a 2 mL tube filled with 10 µL liquimin (Hoffmann-La Roche, Basel, Switzerland) to avoid coagulation and stored at 4 °C until further use.. For serum hormone level analysis, blood was allowed to coagulate in the 2 mL tubes for 2 h at room temperature. Then the tubes were centrifuged for 10 min with 1000 rpm at room

temperature and the serum was collected and frozen at -20 °C. Finally, the mice were sacrificed by cervical dislocation.

2.1.3 Fluorescence-activated cell sorting (FACS)

For fluorescence-activated cell sorting (FACS), antibodies labelled with the following fluorochromes were used: Fluorescein-5 isothiocyanate (FITC, emission peak at 530 nm), phycoerythrin (PE, 570 nm), allophycocyanin (APC, 680 nm).

Peritoneal cells were thawed on ice, washed twice with PBS, resuspended in FACS-blocking buffer [1 % bovine serum albumin (BSA, Sigma-Aldrich GmbH, Seelze, Germany) in PBS containing anti-CD16/CD32 antibody, Pharmingen/BD Bioscience, Erembodegem, Belgium] and incubated for 15 min at 4 °C. Subsequently, cells were labelled with the following anti-mouse antibodies: anti-CD11b-FITC, anti-F4/80-PE, anti-GR1-APC and anti-NK1.1-PE (all BD Bioscience) for 20 min at 4 °C.

The whole blood was diluted 1:5 with PBS and incubated for 30 min at 4 °C with the following anti-mouse antibodies: anti-MHC-II-PE, anti-CD4-APC and anti-CD23-FITC (all BD Bioscience). Then 1 mL FACS™ lysis solution (BD Bioscience) was added in each tube and they were incubated for another 10 min at 4 °C. After that, the tubes were centrifuged for 5 min with 400 g at room temperature (multifuge 3 S-R). The supernatant was discharged, the cell pellet resuspended in 200 µL FACS-buffer (1 % BSA in PBS) and finally the cell suspension measured with FACScalibur (BD Bioscience).

In general, dilution of antibody was chosen according to the manufacturer's protocol and appropriate isotype antibodies were used as negative control in all cases. To exclude dead cells, aggregates and debris, cells were gated using the forward-sideward scatter plot. The data were acquired and analysed using the software CellQuest Pro (BD Bioscience).

2.1.4 Serum E₂ level analysis with radio immune assay

Serum E₂ levels were analysed during treatment with estradiol-valerate, a synthetic valerate ester of estradiol (EV, ZK5104, Bayer Schering Pharma AG) in the transplantation model (2.2.2) to investigate if continuous E₂ levels are present. Therefore, EV (100 µg/kg body weight, in ethanol/arachis oil 1:10) was injected subcutaneously as a depot on day 0 and day 7. At 7 different time points after EV injection serum samples from 5 mice were analysed (24 h; 3, 5, 7, 8, 10 and 14 days). Serum from mice in estrus cycle stage without any hormonal treatment was investigated to define the physiological levels. E₂ levels were measured with radio immune assay (RIA) using ¹²⁵I estradiol (DSL-4400, Texas, USA) according to the manufacturer's protocol. Analysis was performed using a gamma-counter

(1470 Wizard, PerkinElmer, Massachusetts, USA) and the software MULTICALC (PerkinElmer).

2.1.5 *In vitro* macrophage stimulation and cytokine measurement

Peritoneal cells (5×10^5 cells in 100 μ L per well) were cultured in a 96-well-plate (Corning, Corning, USA) using RPMI 1640 medium (including 10 % FCS and 1 % penicillin/streptavidin; all PAA) for 12 h at 37 °C in an incubator. Subsequently, plates were washed with PBS and adhered macrophages were stimulated with 0.1 to 1000 ng/mL LPS (Sigma-Aldrich) for 20 h at 37 °C in an incubator. Following incubation, supernatants were collected and TNF- α levels were measured by enzyme-linked immunosorbent assay (ELISA).

ELISA of TNF- α (in cell culture supernatant and PF) and IL-6 (only in PF) was performed using maxisorp plates (Nunc, Wiesbaden, Germany) and ELISA sets (ready-set-go! reagent, eBioscience, San Diego, USA) according to the manufacturer's protocol. A standard curve was established using serial dilutions of purified TNF- α and IL-6, starting at a concentration of 1000 g/mL and 500 pg/mL, respectively. The ELISA was sensitive down to 8 pg/mL for TNF- α and 4 pg/mL for IL-6. Each sample was measured twice.

Cytokines in the PF were measured with multiplex assay or with ELISA. Therefore, PF was thawed and transferred to Vivaspins 6 columns (Sartorius, Goettingen, Germany) to concentrate the liquid. After 60 minutes of centrifugation at 4 °C with 4000 g, 500 μ L were left, yielding a 8 x concentration.

To analyse the PF from the transplantation model (2.2.2), a multiplex assay was used (mouse cytokine/chemokine LINCOplex kit mcyto-70K, Linco Research, St. Charles, USA) in a 96 well plate format according to the manufacturer's protocol. In this so called "sandwich" approach, fluorochrome-labelled beads bearing antibodies are incubated with samples and controls and consequently form a bead-antibody-sample complex. The latter is then recognized by a biotinylated detection antibody and a fluorescing streptavidine-phycoerythrin-complex. The fluorescence is finally detected with a BioPlex system (Bio-Rad Laboratories, Hercules, USA). Twenty-two different murine cytokines and chemokines were simultaneously measured. Each PF sample was measured 3 times.

2.2 *In vivo*-techniques

2.2.1 Mice

All procedures involving animals were performed in accordance with institutional, state and federal guidelines. Mice were fed on mouse diet and water ad libitum and kept on a light/dark cycle of 12/12h under controlled conditions.

The transplantation model was performed with 8 to 10 weeks old female NMRI mice (Charles River, Berlin, Germany). For the injection model, transgenic mice [C57BL/6-Tg(ACTB-EGFP)1Osb/J] ubiquitously expressing enhanced green fluorescent protein (EGFP) were obtained from Jackson Laboratories (Bar Harbor, USA) and were bred at the Bayer Schering Pharma AG on-site animal care facility. In the experiment 3.3, female, heterozygous, 6 to 8 months old mice were used as endometrium donors and 8 to 12 weeks old wild type C57BL/6 mice (Charles River, Berlin, Germany) as recipient mice. Additionally, 8 to 10 weeks old EGFP-transgenic matching sibling mice as recipients were applied in the experiments 3.2 and 3.4.

2.2.2 Development of the transplantation model

For the endometriosis model, vaginal smears were performed with wet cotton swabs to evaluate the cycle stage. Only mice in estrus were taken into account. Then the mice were anaesthetised via intraperitoneal injection with 1+1 ketamine hydrochloride (Ketavet, Pfizer, Karlsruhe, Germany) and xylazine hydrochloride (Rompun, Bayer, Leverkusen, Germany), further diluted 1:10 in sterile distilled water. The fur was disinfected with 70 % ethanol and skin as well as peritoneum were opened longitudinally to perform the first laparotomy. The right uterus horn was exposed, ligated with absorbable suture thread (5.0, vicryl rapid, Ethicon, Norderstedt, Germany) shortly after the cervix and excised. In a petri dish filled with sterile 37 °C warm Dulbecco's modified eagle medium (DMEM w/o phenol red, Gibco-Invitrogen, Karlsruhe, Germany) the horn was longitudinally opened and six uterus biopsies were taken with a steel biopsy punch (2 mm in diameter, FST, Heidelberg, Germany). The biopsies were then sutured with black suture thread (6.0, surgical silk, Ethicon) onto the peritoneum, one on left and right side each, and 2 on the guts' mesenteries. During the entire procedure the opened peritoneal cavity was wetted with sterile sodium chloride solution to avoid desiccation. After placement of the uterus biopsies, the peritoneum and the skin were closed with absorbable suture thread. The mice were allowed to recover on a warm plate and constantly surveyed after awakening. Fourteen days later a second laparotomy was performed, the mice were anaesthetised again, the peritoneal cavity was reopened and the developed endometriotic lesions documented and measured with a calliper. After closing the peritoneal cavity and recovery, one group of mice were treated daily with the test compound selective estrogen receptor destabiliser (SERD) ZK703 (Bayer Schering Pharma AG, Berlin, Germany), the other with vehicle only. Autopsy was performed 14 days after the second laparotomy. Mice were sacrificed, the lesions measured a second time and excised. The residual right uterus horn was excised as well and all tissue samples were fixed in 4 % PBS-diluted formalin (Merck).

Treatment with EV and SERD (ZK703) was performed via subcutaneous injection in the back or thigh skin (the latter for SERD only). Estradiol-valerate was applied weekly to one group right after the first laparotomy to create a subcutaneous depot. ZK703 was injected daily (1 mg/kg) after the second laparotomy diluted in the same vehicle as estradiol-valerate. The groups were defined as: Group 1 (no E₂ – vehicle), Group 2 (no E₂ – ZK703), Group 3 (EV – vehicle) and Group 4 (EV – ZK703).

2.2.3 Development of the injection model

Induction of endometriosis

Induction of endometriosis was performed according to a method reported by Hirata *et al.* (2005) with slight modifications. In contrast to their work, no E₂ supplementation was given. It has already been shown that estrogens have an influence on the immune system (Straub, 2007). To avoid any impact of estrogens, intact cycling donor mice were used and recipient mice were not supplemented with E₂ as well. Eight to ten weeks old EGFP-transgenic mice in estrus state were used as endometrium donor. The breed female sibling mice in same age were used as recipients. The EGFP-mice were anaesthetised with CO₂ and killed by cervical dislocation. The uterus horns were removed and stored in 37 °C warm DMEM w/o phenol red. Endometrium was peeled off with tweezers and chopped into 400 x 400 µm wide pieces using a tissue chopper (McIlwain tissue chopper, Agar Scientific, Essex, UK). The endometrium fragments of two uteri were pooled and every recipient mouse received 40 mg tissue in 400 µL warm DMEM. The suspended tissue was injected into the peritoneal cavity through the abdominal wall with a 20-gauge needle on the midline just below the umbilicus. During this procedure, recipient mice were anaesthetised with dimethyl ether. Depending on the approach, mice were sacrificed via cervical dislocation after ether anaesthesia 24 h, 72 h or 10 days following injection of endometrium fragments.

Fluorescence imaging of EGFP-expressing tissues

After the appropriate time following endometrial fragment injection, mice were euthanised with an overdose of dimethyl ether. Autopsy was performed by a longitudinal midline incision. A stereo-microscope (Stemi SV6, Carl Zeiss AG, Göttingen, Germany) with a fluorescence device and a camera (AxioCam HRm, Zeiss) was used to illuminate the peritoneal cavity. EGFP-expressing lesions and non-attached tissue fragments were photographed, removed and snap-frozen in optimal cutting temperature (OCT) compound Tissue-Tek (Sakura Finetek, Zoeterwoude, Netherlands) in liquid nitrogen or fixed in 4 % paraformaldehyde (PFA, Riedel de Haen AG, Seelze, Germany) in PBS for 24 h.

An overview over both models and the applied techniques is given in Table 1.

Table 1: Overview over the two mouse models and the applied techniques and time lines

	Transplantation model	Injection model
Mouse strain	NMRI	C57BL/6-Tg(ACTB-EGFP)10sb/J
Approach	Autologous	Syngeneic
Technique	Transplantation	Injection
Tissue	Uterine biopsies	EGFP-expressing endometrial fragments
Treatment	SERD ZK703, 1 mg/kg bodyweight, daily for 14 days	None
Time until autopsy	14 days without treatment 28 days with treatment	24 h, 72 h, 10 days
Histology, Immunohistochemistry	HE, ER- α , CD31, smooth muscle actin, cytokeratins 8, 18	HE, ER- α , CD31, smooth muscle actin, cytokeratins 8+18, KI67, Elastica-Weigert-Van Gieson
Peritoneal lavage	After 14 days	After 24 h, 72 h, 10 days

2.2.4 Peritonitis model and endometriosis induction

Induction of peritonitis

A non-septic non-chronic peritoneal inflammation was induced by injecting thioglycolate medium (TM) as described before (Argyris, 1967). Briefly, peritoneal exudate cells (PEC) were elicited by injecting 1 mL of 3 % sterile, 14 days at 4°C aged TM (Brewer modified; BD, Sparks, USA) into the peritoneal cavity. Three days later, mice were sacrificed and PEC were harvested by peritoneal lavage (2.1.1).

Induction of endometriosis in inflamed peritoneal cavity

First, peritonitis was induced as described above in wild type C57BL/6 mice. The control animals were not treated with TM. Three days later, TM-treated and control mice were injected each with 40 mg of EGFP-expressing endometrium fragments under anaesthesia as described above. Ten days after injection, mice were sacrificed and the peritoneal cavity was examined under fluorescent light (2.2.3). Lesions were excised, photographed and measured using the software Axiovision. Non-attached debris was taken out and counted. Finally, lesions and debris were snap frozen or fixed in 4 % PFA for further analysis.

2.2.5 Immune suppression model and endometriosis induction

Immune suppression

Immune suppression was conducted by daily injection of 1 mg/kg body weight prednisolone (ZK5932, Bayer Schering Pharma AG). Therefore, prednisolone was diluted in a solution consisting of 0.085 % myrj 53 (ICI, Essen, Germany) in 0.9 % sodium chloride (B. Braun, Melsungen, Germany), a microcrystal suspension was prepared using glass beads (2 mm in diameter, Worf Glaskugeln GmbH, Mainz, Germany) in an ultrasonic water bath (Bandelin Sonorex, Schalltec GmbH, Mörfelden, Germany) and administered by gavage (canula: 1.0 x 30 mm, R. Helwig GmbH, Berlin, Germany) in a volume of 0.1 mL. Furthermore, daily body weight was measured. After 7 days, the mice were anaesthetised with ether and blood collected as mentioned elsewhere (2.1.2). Subsequently the mice were sacrificed via cervical dislocation and a peritoneal lavage was performed (2.1.1). Finally, thymus and spleen were excised and weighed.

Induction of endometriosis in immune suppressed mice

Mice were treated with prednisolone or vehicle for 7 days. On day 8, endometriosis was induced by injection of EGFP-expressing endometrium as described previously (2.2.3). The treatment with prednisolone or vehicle was continued for another 10 days. Then the mice were sacrificed, developed lesions were detected under the fluorescence microscope, photographed, measured and fixed in 4 % PFA for further histological analysis.

2.3 Histological and immunohistochemical examinations

Frozen tissues were cut at 10 µm on a cryostat (CM3050S, Leica, Solms, Germany). Formalin or PFA-fixed lesions were embedded in paraffin and cut at 5 µm thickness on a rotation microtome (RM2135, Leica). Sections were mounted on SuperFrost Ultra Plus glass slides (Menzel GmbH, Braunschweig, Germany). For gross examination sections were stained with haematoxyline-eosin. Therefore, slides were dehydrated 2 x 10 min in xylol (C₈H₁₀, Merck), 2 min in 100 %, 96 %, 80 %, 70 % and 60 % ethanol (Merck; diluted with distilled water), rinsed with distilled water and stained for 30 sec in haematoxyline (Merck). Afterwards the slides were washed for 10 min in tap water and stained for 2 min in eosin solution (Chroma, Muenster, Germany). Consequently the slides were hydrated again for 15 sec in several ethanol baths with increasing concentrations (60 %, 70 %, 80 %, 96 %, 100 %) followed by 2 x 10 min incubation in xylol. Finally they were covered with permanent mounting medium (Histomount, Thermo Shandon, Frankfurt, Germany) and cover glasses.

Weigert-Elastica-van Gieson staining was performed using resorcin-fuchsin red (Merck), iron haematoxyline (Merck) and picric acid (Fluka Biochemika, Buchs, Switzerland) combined with thiazine red (Chroma) leading to black-brown coloured nuclei, black coloured elastic fibres, magenta coloured collagenic connective tissue and yellow coloured muscle tissue. Therefore, the slides were dehydrated as already described, stained 20 min in resorcin-fuchsin red, rinsed with tap water (1 min) as well as distilled water (1 min) and stained further for 2 min in iron haematoxyline. Afterwards they were washed for 10 min in tap water and stained for 4 min with thiazine red. Finally the slides were hydrated by incubation in increasing alcohol solutions and xylol and covered with mounting medium as mentioned before.

Immunohistochemical examinations were carried out using either the DAKO EnVision protocol for rabbit antibodies (DAKOCytomation, Carpinteria, USA), a mouse-to-mouse detection kit protocol for mouse monoclonal antibodies (Chemicon-Millipore, Temecula, USA) or the ABC streptavidin-biotin method. First the sections were dehydrated as described previously. Then they were washed in PBS for 5 min and heat-induced epitope retrieval in the microwave was performed with target retrieval solution (pH 6, DAKO) for approximately 2 min at 600 watt until the solution cooks followed by another 20 min at 80 watt. The slides were cooled down in the solution for 30 min and rinsed several times with distilled water. After that, they were incubated with 3 % H₂O₂ solution for 10 min followed by 20 min protein block (serum free, DAKO). If the ABC method was used, a avidin-biotin blocking (Vector, Peterborough, England) was applied right before the protein block according to the manufacturer's protocol.

Binding of primary antibody was carried out overnight at 4 °C using the following antibodies: monoclonal rat anti-mouse Ki67 (dilution 1:50; DAKO), monoclonal mouse anti-mouse cyto-keratins multi Ab-1 (1:100; clone C11, Dianova, Hamburg, Germany), polyclonal rabbit anti-mouse estrogen receptor α (1: 200; clone MC-20, Santa Cruz Biotechnology, Santa Cruz, USA), polyclonal rabbit anti-mouse smooth muscle actin (1:100; Spring Bioscience, Fremont, USA) and polyclonal rabbit anti-mouse CD31 (1:200, Santa Cruz). Negative controls were only incubated with antibody diluent (DAKO). Secondary antibodies coupled with horseradish peroxidase (HRP) derived from EnVision kit (for rabbit primary antibodies, DAKO), from mouse-to-mouse kit (for mouse primary antibodies) or a polyclonal rabbit anti-rat antibody was used (biotinylated, for rat primary antibodies; DAKO). If the biotinylated secondary antibody was applied, the slides were subsequently incubated with HRP-coupled streptavidin (DAKO).

To visualise antibody binding, 3 different peroxidase substrates were used: DAB (brown; from mouse-to-mouse detection kit, Chemicon-Millipore), NovaRed (red; Vector) or Vector® SG (blue-grey; Vector). Counterstaining was performed with haematoxyline (Merck). The results

were analysed and documented with the microscope AxioPlan 2 and the AxioCam camera (Zeiss) using the software AxioVision Rel. 4.5.

Double-staining with anti-smooth muscle actin and anti-CD31 antibodies was performed mostly as described previously. First, slides were incubated with anti-CD31 antibody over night at 4 °C. Then the slides were washed 2 x 5 min in PBS and HRP-coupled secondary antibody was applied for 1 hour (EnVision kit for rabbit primary antibodies, DAKO). Consequently, slides were washed again and HRP-substrate Vector® SG was administered to yield a blue-grey signal for CD31-containing cells. Afterwards, the slides were incubated for 20 min with protein block and the second primary antibody against smooth-muscle actin was applied for 1 hour at room temperature. Again HRP-coupled secondary antibody was administered and HRP substrate NovaRed used to finally gain a double staining with endothelial vessel cells in blue-grey and smooth muscle cells in red.

2.4 Statistical analyses

2.4.1 Statistical analysis of *in vitro* data

The peritoneal cell counts and the FACS data (2.1.1, 2.1.3) as well as the results of cytokine measurement (2.1.5) were presented as mean \pm standard deviation (SD). The SD was calculated because it quantifies scatter due to biological variation.

For statistical analysis, all data sets were first tested on normality. If that was the case, an unpaired Student's t-test was performed with two-sided P value. A standard t-test assumes that the two groups have equal variances. It investigates the likelihood that the difference between the means of the two groups could have been caused by chance. Thus, the most important results are the 95 % confidence interval for that difference and the P value.

For non-Gaussian distributed data, the non-parametric two-sided Wilcoxon rank sum test (also called Mann-Whitney *U* or Mann-Whitney-Wilcoxon test) was applied to compare the two unpaired groups.

Both tests were applied using SigmaStat 3.0 (Systat, San Jose, USA).

2.4.2 Statistics in the transplantation model

In the transplantation model the effect of the anti-estrogen SERD ZK703 on lesion growth (estrogen-dependency) was tested. Additionally, the impact of estradiol-valerate (EV) supplementation on lesion size (estrogen-responsiveness) was investigated. The groups were defined as: Group 1 (no E₂ - vehicle), Group 2 (no E₂ - ZK703), Group 3 (EV - vehicle) and Group 4 (EV - ZK703). Each lesion was measured twice, one time 14 days following endometriosis induction (laparotomy) and the second time after ZK703 or vehicle treatment

(autopsy). Lesion size was defined as diameter 1 x diameter 2 and the sum of lesion size per mouse was used for the analysis. To evaluate the effects of ZK703 and E₂ supplementation, the median percent change was calculated using the median values of the sum of lesion size:

$$100 \cdot \frac{\text{autopsy value} - \text{laparatomy value}}{\text{laparatomy value}}$$

The median percent change was compared between Groups 1 and 2 (both without EV) and Groups 3 and 4 (both with EV) by means of exact two-sided Wilcoxon Rank-Sum tests. No adjustment for multiple testing was performed, as the comparisons were considered separately.

2.4.3 Statistics in injection model

The lesions were measured and the cross-sectional areas (CSA) for every lesion was calculated according to the formula for an ovoid: diameter 1 x diameter 2 x $\pi/4$ (Becker *et al.*, 2005; Efsthathiou *et al.*, 2005). The mean of all CSAs per mouse was taken for further analysis and only animals with lesions were included. For the statistical comparison of CSA between control and compound-treated animals, log-transformed values were used. A general mixed linear model was fitted, using the treatment group as fixed effects and animal as random experimental unit. To model the covariance structure between the measurements of each animal, a compound symmetry structure was assumed. Different covariance structures were used between the treatment groups. The Kenward-Rogers approach was applied for the calculation of the denominator degrees of freedom for the *F*-tests in a two-sided test.

Additionally, the sum of lesion CSA per mouse was used as a measure for the overall burden of the animal. To compare the overall burden, an exact two-sided Wilcoxon rank-sum test was used on the sum CSA per animal. Animals without lesions were included with value zero.

All analyses of CSAs in transplantation and injection model were performed using PROC MIXED in SAS®, Version 9.1.3 (Heidelberg, Germany). Probability $p < 0.05$ was considered as statistically significant.

3 Results

3.1 Transplantation model

Examining endometriosis evokes the need of an animal model. As previously mentioned (see 1.2.1), the most adequate model is the menstruating non-human primate. However, ethical concerns and high costs limit the use of this animal as a model for this disease (1.2.1). Hence, a mouse model was established using immunocompetent cycling NMRI mice without any estrogen (E_2) supplementation on the one hand and with weekly estradiol-valerate (EV) depot injections of 100 mg/kg body weight to investigate estrogen responsiveness. An autologous transplantation model with sutured uterus biopsies was applied in order to facilitate the recovery of the lesions. Immunocompetent mice were used to avoid graft-versus-host reactions.

3.1.1 Evaluation and histological characteristics

For the autologous transplantation model, two uterus biopsies were sutured on the peritoneum and two on the intestine mesenteries. All mice developed at least two lesions and the overall take rate was 85 %, i.e. 85 % of all sewed biopsies adhered to peritoneum or mesenterium. Figure 6 shows the morphological appearance of a peritoneal lesion (Figure 6a) and a mesenterial lesion (Figure 6b).

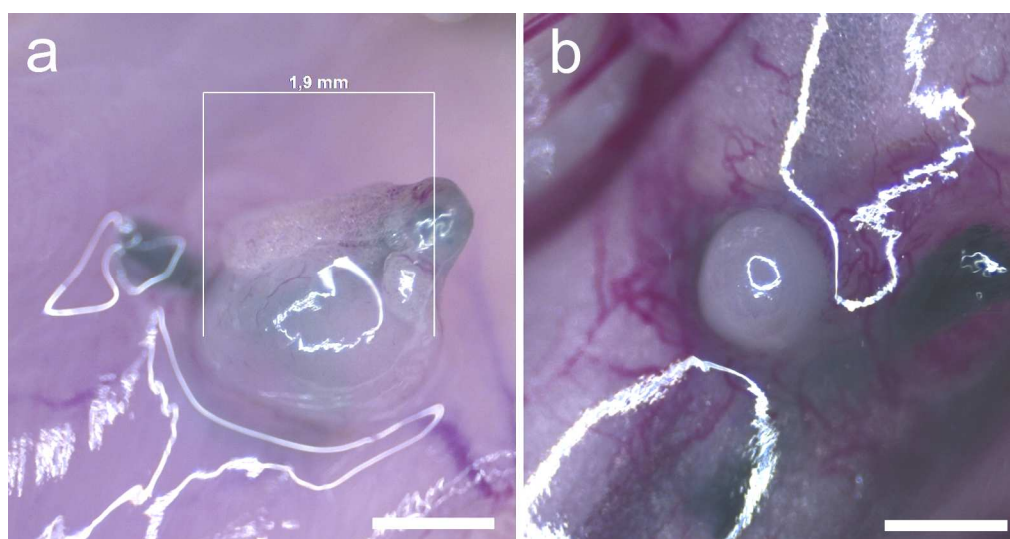


Figure 6: Picture of lesions developed after autologous transplantation of uterus biopsies. (a) A peritoneal lesion is measured digitally. The black suture thread is clearly distinguishable from the surrounding peritoneal tissue. **(b)** The mesenterial lesion has the typical cyst-like shape. The black thread lies within the mesenteries on the right side of the lesion. The rich blood supply surrounding the white lesion can be easily detected. Scale bar = 1 mm

The permanent black suture thread, clearly visible on the pictures, was used as a means to detect the transplanted uterus biopsies. The lesions often had a cyst-like appearance and displayed a smooth, white to transparent homogenous surface. For further evaluation of the

model, the lesions were excised and examined histologically and immunohistochemically to detect typical histological criteria of endometriosis lesions like the presence of glandular epithelium, stromal structures and vascularisation.

Figure 7a exemplarily shows a haematoxyline-eosin (HE) staining of a mesenterial lesion. The cyst-like formation has a wide lumen, filled with unspecifically stained liquid, and is attached to parts of the guts. Additionally, estrogen receptor α (ER- α) is present in the lesions as it has also been shown in lesions from human patients (Jänne *et al.*, 1981; Matsuzaki *et al.*, 2001), illustrated by brown nuclei in Figure 7b. Some non-positive nuclei are indicated by arrows.

Vascularisation of the lesions and supporting vessels are displayed on Figure 7c and d. Anti-smooth muscle actin (SMA) staining gives evidence for pericytes around mature vessels (see arrows) and additionally confirms the presence of muscle fibres in the marginal areas of the lesion and in the stromal structure, indicated with the letter m (Figure 7c). These muscular structures presumably derive from myometrium due to the transplantation of uterus biopsies. Anti-CD31 staining (Figure 7d) demonstrates the presence of endothelial cells around a small lumen embedded in stroma as another confirmation of blood vessels.

Gland-like structures within the lesion are lined with glandular epithelium, where cells positive for cytokeratins 8 and 18 display a brown staining in the cytoplasm (Figure 7e). A negative control, incubated with antibody diluent instead of antibody solution, is shown in the upper right corner to demonstrate the specificity of the staining.

Taken together, immunohistochemical evaluations of formalin-fixed, paraffin-embedded lesions confirmed characteristics of endometriotic lesions. Glandular epithelium could be detected, which is a hallmark for endometriosis. Another criteria of endometriosis is the presence of ER- α , which could be demonstrated in the lesions as well. Additionally, several blood vessels were disclosed in the lesions, indicated by CD31 for endothelial cells and by smooth muscle actin for pericytes and vessel musculature. Like in human lesions, the mouse implants have a rich blood supply to assure oxygen and nutrients maintenance. Thus, the mouse lesions of this model are comparable to human lesions

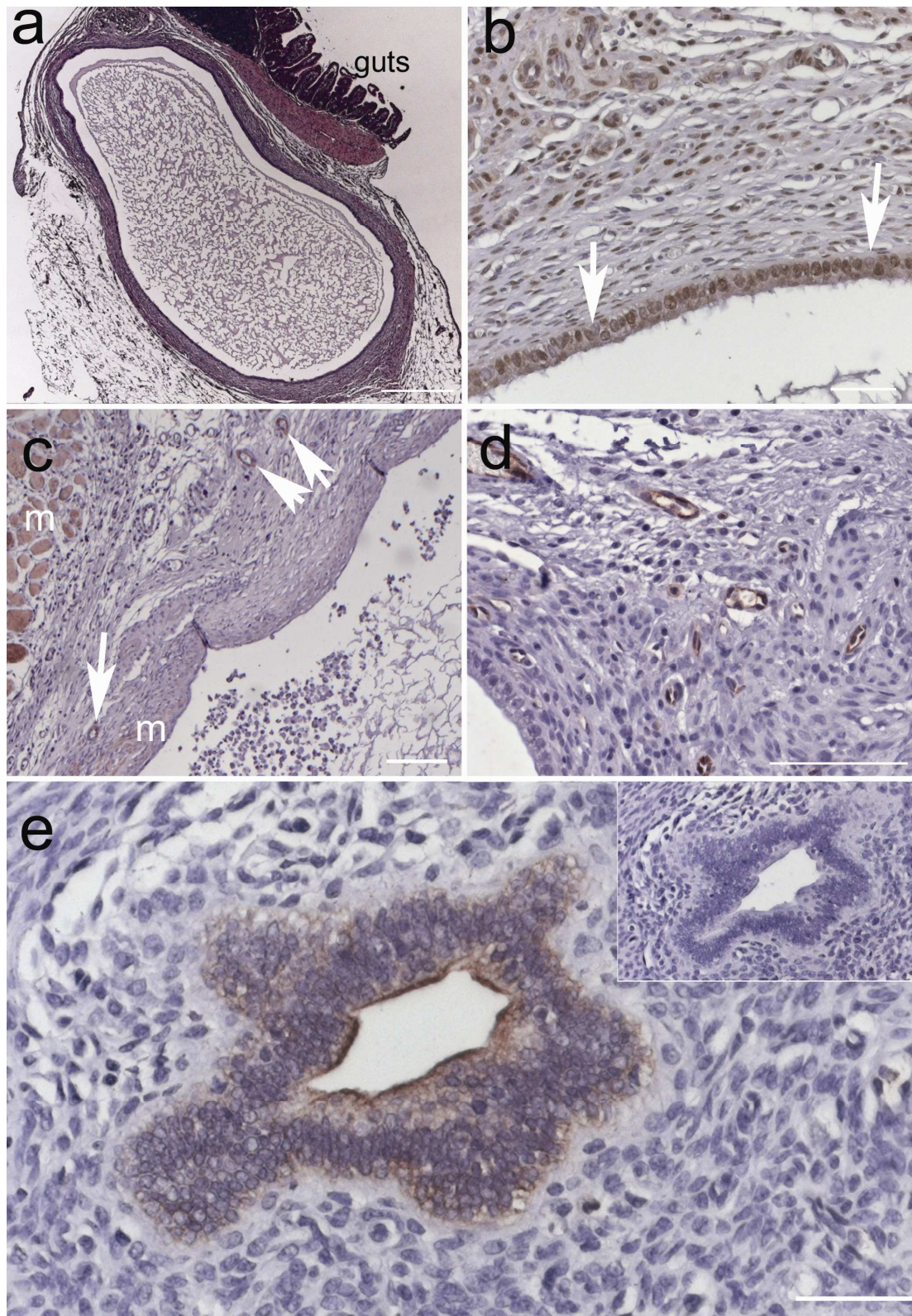


Figure 7: Histological examination of lesions attached to mesenterium and peritoneum. (a) Cystic mesenterial lesion attached to guts, HE staining. **(b)** Anti-ER- α staining: some negative nuclei are exemplarily indicated by the arrows. **(c)** Smooth muscle actin staining: vessels are indicated by arrows, red stained muscle fibres (e.g. myometrium remnants) by letter m. **(d)** Anti-CD31 staining displays endothelial cells in red. In the lower left corner the glandular epithelium of a cystic lumen can be seen. **(e)** Anti-Cytokeratins 8 and 18 illustrated by brown staining demonstrate the presence of glandular epithelium. The picture includes a negative control (incubated with antibody diluent only) in the upper right corner. Scale bars: a = 500 μ m, b + d = 100 μ m, c + e = 50 μ m

3.1.2 Treatment with the anti-estrogen ZK703

Endometriosis is a strongly estrogen-dependent disease (see 1.1). Besides surgical treatment, current therapeutic approaches aim at lowering estrogen levels in the women's metabolism, which lead to less pain symptoms and ameliorate the patients' quality of life. Thus, validation of the model concerning estrogen dependency was performed using an anti-estrogenic approach, i.e. the selective estrogen receptor destabiliser (SERD) ZK703. SERDs are pure estrogen antagonists that cause efficient destabilisation of the estrogen receptor protein. Moreover, mice were supplemented with E_2 to investigate the responsiveness of the lesions towards this hormone.

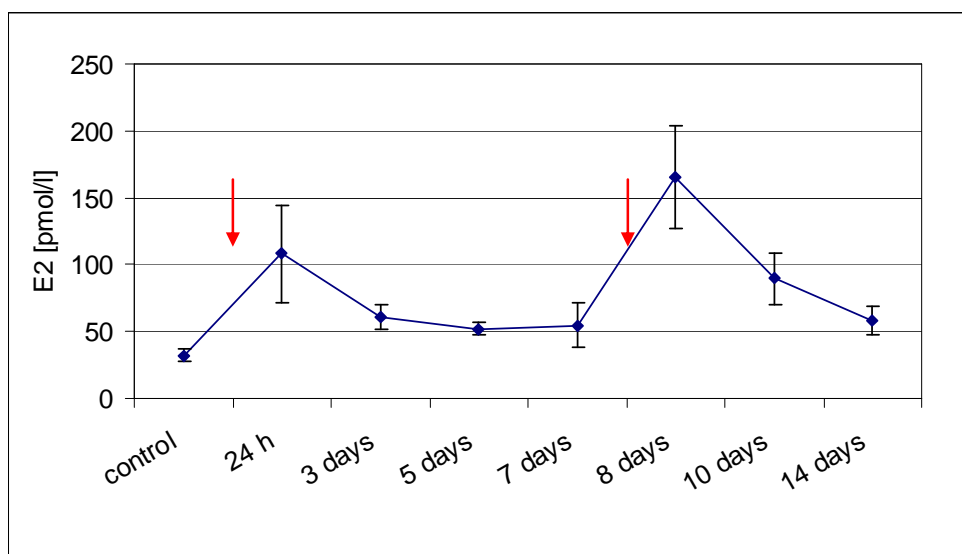


Figure 8: **Serum E_2 levels after estradiol-valerat (EV) injection.** EV injections were applied on day 0 and day 7, indicated by the red arrows. The serum E_2 increases after hormone injection and decreases over time. After the second hormone injection, the amount of E_2 seems to accumulate but decreases to almost physiological levels 7 days later. Control mice did not receive any treatment.

First, serum E_2 levels after E_2 supplementation were analysed. Therefore, blood was taken at different time points after estradio-valerate injection in a preliminary experiment (2.1.3). Control animals were all in estrus cycle stage and did not receive any hormone. The measurement by RIA resulted in a physiological level of 36 pmol/L in controls and in an increase of E_2 levels shortly after injection (24 h, Figure 8) followed by return to almost base line levels after 5 days. The second injection on day 7 resulted in highly increased levels (> 150 pmol/L), which then decreased to base line after another 7 days (14 days, Figure 8). Thus, EV depot injection leads to almost constant E_2 levels after a short initial increase. Endometriosis was induced by suturing uterus biopsies on peritoneum and mesenterium as previously described (see 3.1.1). After induction of endometriosis, EV injection was applied weekly until autopsy while control mice receiving only vehicle treatment. The mice were allowed to recover for 2 weeks, then laparotomy and measurement of lesions was performed.

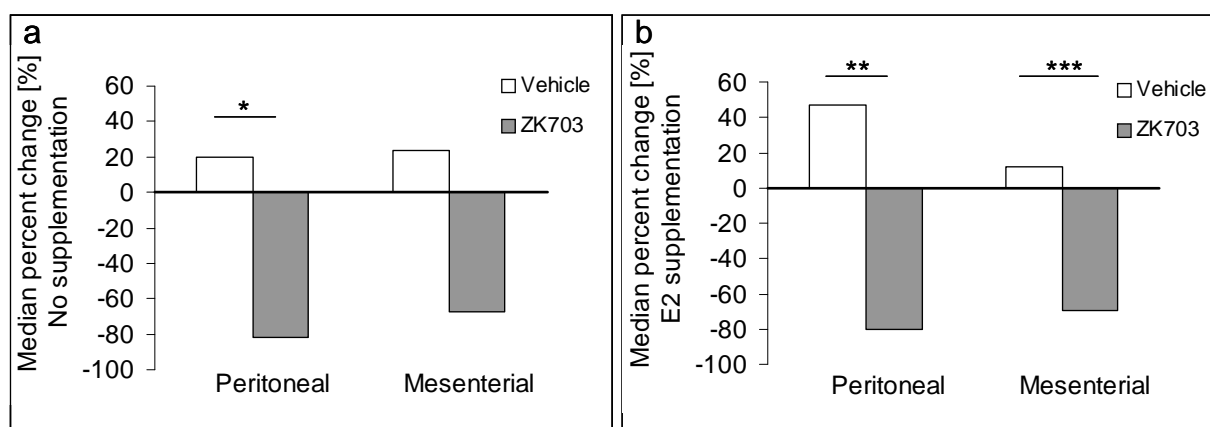


Figure 9: **Treatment with SERD ZK703 significantly decreased lesion surface. (a)** Peritoneal lesion surface was significantly decreased in ZK703-treated mice without hormonal treatment. For mesenteric lesion size, the difference was not significant. **(b)** After treatment with ZK703, size of peritoneal and mesenteric lesions in mice supplemented with weekly subcutaneous EV injection was significantly decreased. Statistical analysis was performed with exact two-sided Wilcoxon Rank sum test.

Daily subcutaneous treatment with ZK703 or vehicle was conducted after laparotomy for another 2 weeks. Finally, mice were sacrificed, the lesions excised and measured for a second time to allow a comparison between lesion size before and after treatment.

Table 2: Descriptive statistics of the measured lesion size at laparotomy and at autopsy after treatment with vehicle (C) or ZK703 (ZK) in the group without E₂. The table demonstrates the mean surface value (Mean), the standard deviation (SD), the minimum (Min), median and maximum (Max) lesion surface.

Peritoneal Lesions							
Assessment	Group	N	Mean	SD	Min	Median	Max
Laparotomy (mm ²)	C	8	4.99	2.55	2.5	4.15	10.3
	ZK	7	2.76	1.20	1.4	2.7	5
Autopsy (mm ²)	C	8	5.55	5.54	0	3.7	17
	ZK	7	0.91	1.12	0	0.8	3.2
Difference (mm ²)	C	8	0.56	3.73	-5.7	0.4	6.7
	ZK	7	-1.84	1.20	-4.1	-1.8	-0.1
Percent Change (%)	C	8	4.44	61.44	-100	19.9	65
	ZK	7	-71.11	33.78	-100	-82	-3
Mesenteric Lesions							
Assessment	Group	N	Mean	SD	Min	Median	Max
Laparotomy (mm ²)	C	8	4.94	3.39	0.6	4.6	10.3
	ZK	8	4.39	2.09	2.1	3.9	8.3
Autopsy (mm ²)	C	8	5.68	4.13	0	4.4	12.2
	ZK	8	1.36	1.41	0	1.15	3.7
Difference (mm ²)	C	8	0.74	2.65	-2.8	0.7	3.9
	ZK	8	-3.03	3.14	-8.3	-2.6	1.6
Percent Change (%)	C	8	64.19	189.55	-100	23.75	516.7
	ZK	8	-53.93	59.40	-100	-67.7	76.2

Peritoneal and mesenterial lesion sizes were calculated independently. For the group without E₂-supplementation, each particular setting (laparotomy and autopsy) together with the number of animals and the difference of lesion size between laparotomy and autopsy is listed in Table 2.

The median percent changes between laparotomy and autopsy are displayed in Table 3 and are also presented as a graph in Figure 9 to outline the differences in lesion size between laparotomy and autopsy after ZK703- or vehicle-treatment and the results for the EV-treated mice, respectively.

For all but one animal (n = 7) that were treated with ZK703, lesions decreased in size. Interestingly, an increase of 76 % in mesenterial lesion size was observed in one animal from ZK703-group in non-EV-treated animals (from 2.1 mm² at laparotomy to 3.7 mm² at autopsy). In the control groups, the median percent change increased, indicating a growth of lesions

Table 3: Comparison of median percent change in mice without hormonal supplementation and with E₂-supplementation. Statistical analysis was performed using exact two-sided Wilcoxon rank sum test

	No hormonal supplementation			E ₂ supplemented		
	control	ZK703	P-Value	Control	ZK703	P-Value
Peritoneal lesions	19 %	-82 %	* 0.0284	46 %	-80 %	** 0.0080
Mesenterial lesions	23 %	-67 %	0.0687	12 %	-69 %	*** 0.0006

Taken together, these results indicate that the treatment with the anti-estrogen ZK703 resulted in a decrease of lesion surface area when applied to the autologous mouse model. In mice without E₂, peritoneal lesion size was significantly diminished compared to non-treated controls and mesenterial lesion size was reduced as well. In mice with E₂-supplementation, peritoneal and mesenterial lesions size decreases significantly after ZK703-treatment. Estrogen-responsiveness of the peritoneal lesions could be demonstrated by the increase of lesion size in the vehicle group in EV-treated mice compared to non-supplemented mice. Thus, this endometriosis model is responsive for anti-hormonal therapy approaches and suitable for further anti-hormonal therapeutic research.

3.1.3 Inflammatory parameters in the peritoneal cavity of mice with induced endometriosis

Frequently, inflammatory parameters like pro-inflammatory cytokine levels are altered in the peritoneal fluid of endometriosis patients (1.3.1). Until now, this has not been demonstrated

for the autologous mouse model. To gain novel insights into the prevailing inflammatory situation, peritoneal fluid content was analysed for its cell number and cytokine content 14 days following endometriosis induction. Endometriosis was induced in seven mice ($n = 7$). As control, healthy mice without any treatment were used ($n = 5$). An additional group of sham-operated mice ($n = 6$), which received only the suture thread on peritoneal and mesenteric locations, was also investigated to exclude inflammatory effects due to surgical procedures.

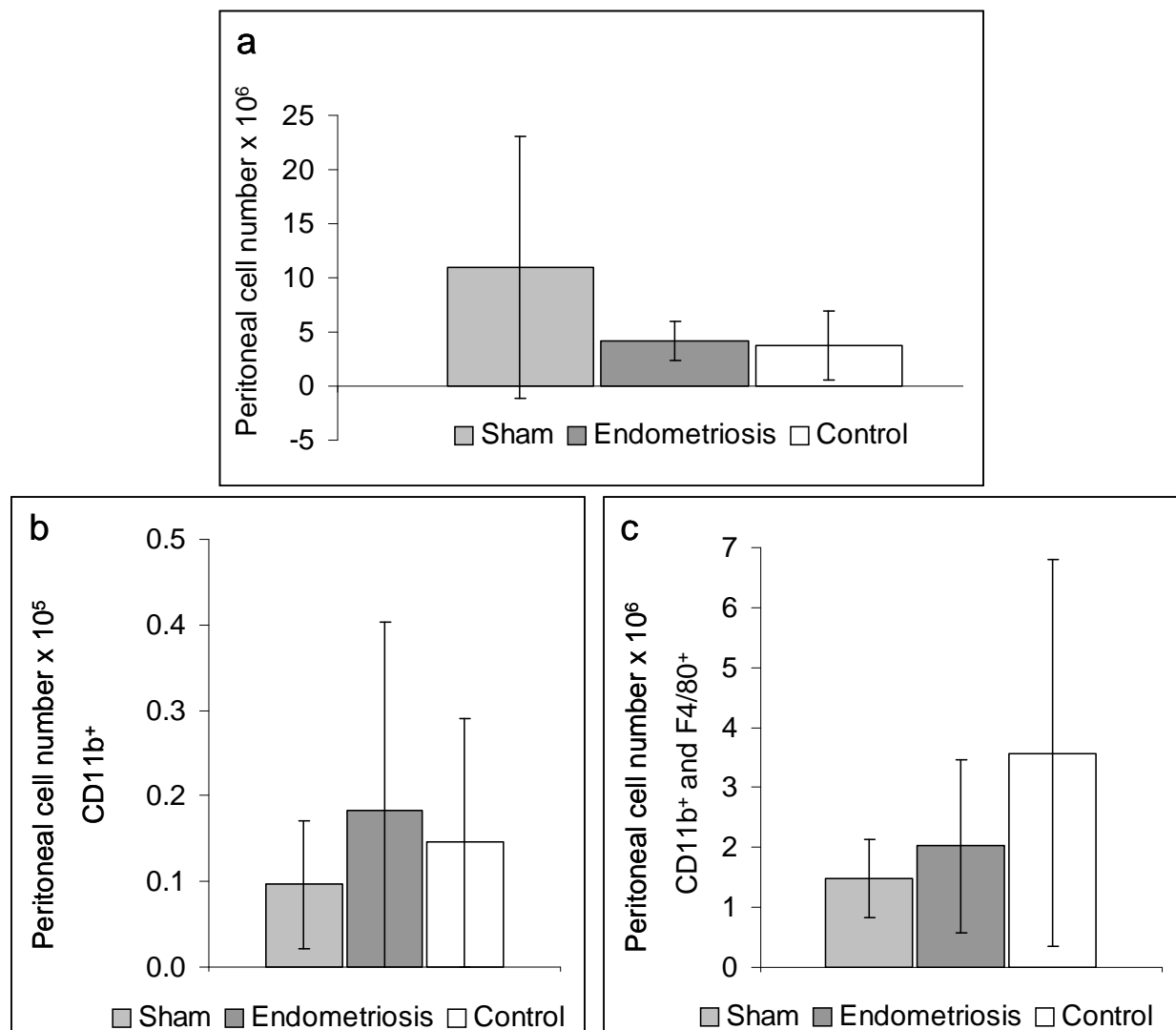


Figure 10: **Peritoneal cell counts and characterisation of cell type.** (a) Total cell number in PF after peritoneal lavage. Explanation for the high SD is given in the text. (b) FACS analysis of CD11b⁺ peritoneal cells: granulocytes, NK cells, microglia, dendritic cells and macrophages. (c) Amount of all cells double-positive for CD11b and F4/80 (macrophages and eosinophils). All amounts of positive cells are expressed as mean \pm standard deviation and are related to the total cell number. Statistical analysis did not show any significant differences.

Total peritoneal cell number

A high cell number in the peritoneal fluid (PF) usually indicates inflammatory processes. Thus, peritoneal cells were counted with a cell counter to investigate a potential inflammation in the peritoneal cavity. As a result, no significant difference in the total cell number between

the three groups could be detected (Figure 10a, Table 4). Unfortunately, the sham-operated group contained three peritoneal fluid samples contaminated with blood due to problems during lavage. The erythrocytes contained in the samples were also counted, together with all peritoneal cells. This might be an explanation for the high standard deviation seen in Figure 10a in the sham-operated group. Fluorescence Activated Cell Sorting of peritoneal cells

Following determination of the peritoneal cell number, FACS analysis was performed to assess the cell types present in the PF. The peritoneal cells of the three different experimental groups were labelled with antibodies against CD11b (expressed on granulocytes, NK cells, microglia, dendritic cells and macrophages) and F4/80 respectively, a surface marker specific for macrophages and eosinophiles.

Cell sorting and counting revealed no significant differences between the sham-operated, the endometriosis and the control group. CD11b⁺ and F4/80⁻ cells were increased in the endometriosis group compared to sham-operated and control animals (Figure 10b). However, this difference was not significant. The differences in macrophage- and eosinophile numbers were not significant as well (Figure 10c). The data are summarised in Table 4. High standard deviations are present in all samples, due to the small sample size and the naturally occurring variability in peritoneal cell composition.

Table 4: Overview of total cell number in peritoneal fluid and of FACS results for peritoneal cells. CD11b is expressed on granulocytes, NK cells, microglia, dendritic cells and macrophages and F4/80 on macrophages and eosinophile granulocytes. The data is displayed as mean \pm standard deviation.

	Total cell number $\times 10^6$	CD11b ⁺ / F4/80 ⁻	CD11b ⁺ / F4/80 ⁺ $\times 10^6$
Sham-operated, n = 6	10.97 \pm 12.13	9 596 \pm 7 486	1.49 \pm 0.66
Endometriosis, n = 7	4.14 \pm 1.82	18 380 \pm 21 994	2.02 \pm 1.44
Control, n = 5	3.76 \pm 3.18	14 544 \pm 14 587	3.57 \pm 3.23

Cytokine measurement in peritoneal fluid with a multiplex assay

Other parameters for inflammation or activation of the immune system besides the presence of inflammatory cells are the levels of pro-inflammatory cytokines in the peritoneal fluid. Hence, the concentrations of several pro-inflammatory cytokines were measured in a multiplex assay (Bio-Plex) investigating the peritoneal lavage fluid of sham-operated mice (n = 4), animals with endometriosis (n = 4) and controls (n = 3). Each sample was measured three times. The low sample size was due to limitations in the assay format.

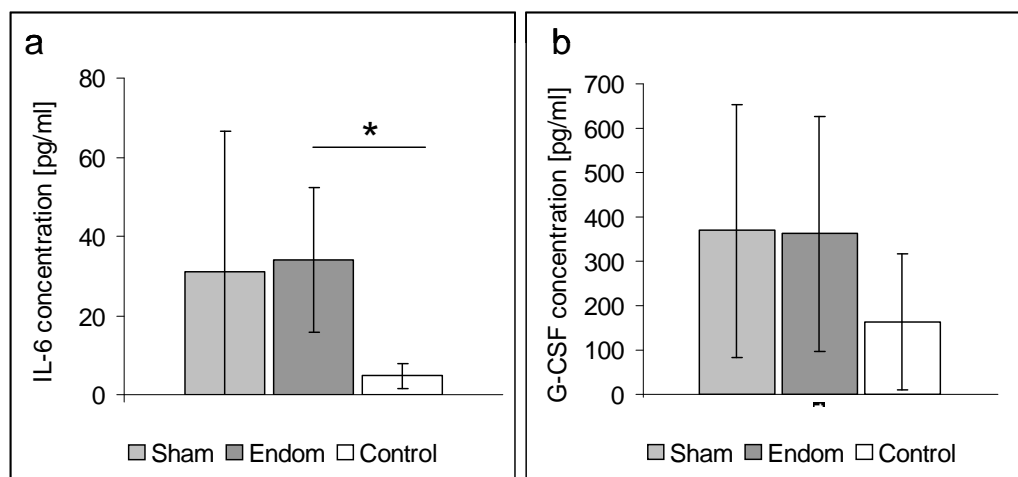


Figure 11: **Analysis of cytokine levels in the peritoneal fluid (PF), gained 14 days following endometriosis induction or sham-surgery, using a multiplex technique.** (a) A significant difference in IL-6 concentration could be detected between the endometriosis and the control group. t-test: * $p = 0.044$, 95 % confidence interval: 1.25 to 57.51. (b) The levels of G-CSF in PF of sham-operated mice, endometriosis mice and controls were not significantly different. All samples were measured in triplicates.

Figure 11 demonstrates the mean levels of IL-6 and granulocyte-colony stimulating factor (G-CSF). All other cytokine levels were below detection range. A significant difference of IL-6 levels could only be discovered when comparing endometriosis mice to controls (data see Table 5).

In summary, levels of IL-6 in PF of endometriosis mice were significantly elevated when compared to controls. However, the concentration of IL-6 in sham-operated animals was not significantly different from the endometriosis samples. No further significant differences in inflammatory parameters could be detected in the PF 14 days after endometriosis induction, regardless of total peritoneal cell amount, cell profiles or cytokine levels of PF. The standard deviations are high and the sample number was low, consequently the data has to be interpreted cautiously.

Table 5: Summary of the cytokine levels of IL-6 and G-CSF in peritoneal lavage fluid. Statistical analysis was performed using t-Test.

	IL-6 [pg/mL]	G-CSF [pg/mL]	p-value
Sham-operated, n = 4	30.99 ± 35.63	362.24 ± 284.94	* 0.044
Endometriosis, n = 4	34.16 ± 18.31	369.38 ± 265.72	
Control, n = 3	4.78 ± 3.21	163.20 ± 154.56	

3.1.4 Summary transplantation model

After suture of uterus biopsies onto mouse peritoneum and guts' mesenterium, endometriotic lesions developed with a take rate of 85 %. These lesions displayed endometriotic

characteristics as assessed by histological and immunohistochemical examination. Furthermore, they were sensible for anti-hormonal approaches confirmed by lesion size decrease after treatment with an anti-estrogen (SERD ZK703). Investigation of inflammatory parameters 14 days after induction did not show any differences. Taken together, the autologous transplantation of uterus biopsies is a valid mouse model for endometriosis and can be used to investigate anti-hormonal therapy approaches.

3.2 Injection model

The applicability of the mouse as an animal model for endometriosis has been shown in the previous chapter of this work. However, the transplantation model has the disadvantage of using entire uterus instead of endometrium alone, due to technical restraints. Moreover, the transplants are sutured on specific locations close to vessels, which presumably enhances the adherence due to a good supply with oxygen and nutrients. Thus, a second mouse model for endometriosis was developed by injecting endometrial fragments derived from transgenic, enhanced green fluorescent protein (EGFP)-expressing mice into the peritoneal cavity of recipient sibling mice. This method is supposed to mimic retrograde menstruation and the fragments are allowed to establish freely in the peritoneal cavity. Furthermore, the fluorescing tissue allows detection of every established lesion under UV light, especially of small implants hidden behind organs, which are otherwise not visible.

3.2.1 Evaluation and histological characteristics

EGFP-expressing endometrium fragments were injected into the peritoneal cavity of C57BL/6 mice. On average, 95 % of the animals developed 2 to 3 endometriosis-like lesions.

Macroscopically, lesions consisted of white to light yellow ellipsoid nodules that were 0.5 mm to 4 mm in diameter. They formed on structures covered with peritoneal epithelium like the omentum, on parietal peritoneum and pancreatic peritoneum. Lesions could also be detected behind the bifurcation of the uterus as well as embedded in the fatty tissue around the uterine horns (Figure 12a+b). As exemplified, all lesions emitted green light under fluorescence light (Figure 12b+d).

Typical histological characteristics of endometriotic lesions could be demonstrated by immunohistochemistry. To confirmed the presence of glandular epithelium, one of the hallmarks of endometriosis, a staining was performed against specific glandular cytokeratins (CK8, CK18), which shows the glandular epithelium lining the cyst lumen (Figure 13a).

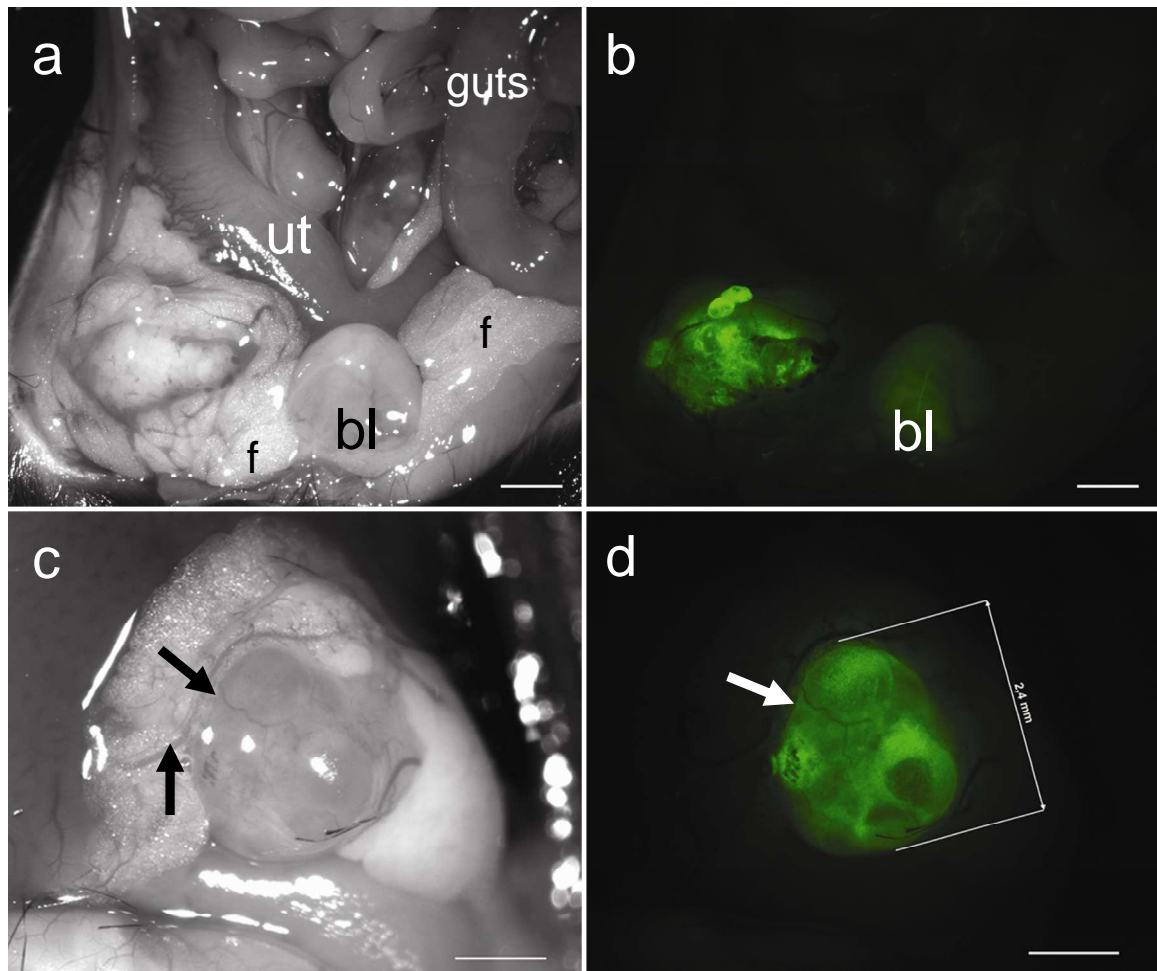


Figure 12: Macroscopic appearance of two EGFP-expressing lesions embedded in fatty tissue 10 days after injection of endometrial fragments. (a) Lesion under impinging light embedded in fatty tissue (f) around the uterus (ut). The bladder (bl) lies caudal from the uterus bifurcation. **(b)** Lesion from (a) examined under fluorescent light. The bladder (bl) shows autofluorescence. **(c)** Lesion under impinging light revealing supporting blood vessels, indicated by arrows. **(d)** Lesion from (c), measured digitally (2.4 mm). A blood vessel is indicated by the arrow. Scale bar: a+b = 2 mm, c+d = 1 mm

Additionally, staining for the proliferation marker Ki67 revealed cell proliferation within the epithelium and surrounding stromal cells, as illustrated by red nuclei (Figure 13b). Proliferating cells could be seen in the content of the cystic lumen as well, presumably indicating proliferating immune cells. ER- α positive cells, displayed by brown nuclei, were detected in the lesion epithelium as well as in stromal structures (Figure 13c) as an important criteria for endometriosis-like lesions. Finally, Weigert-Elastica-van Gieson (W-E-vG) staining was applied to further characterise the lesion tissue. Collagenic connective tissue could be detected which appeared magenta after the trichrome staining (Figure 13d).

In summary, the injection of EGFP-expressing endometrium leads to the development of endometriotic lesions on different adhesion sites. The lesions can be easily detected under UV-light and display typical characteristics of endometriosis confirmed by histological and immunohistochemical analyses. Thus, the injection model is a valuable method to investigate the adherence of endometrial fragments and the development of endometriotic lesions.

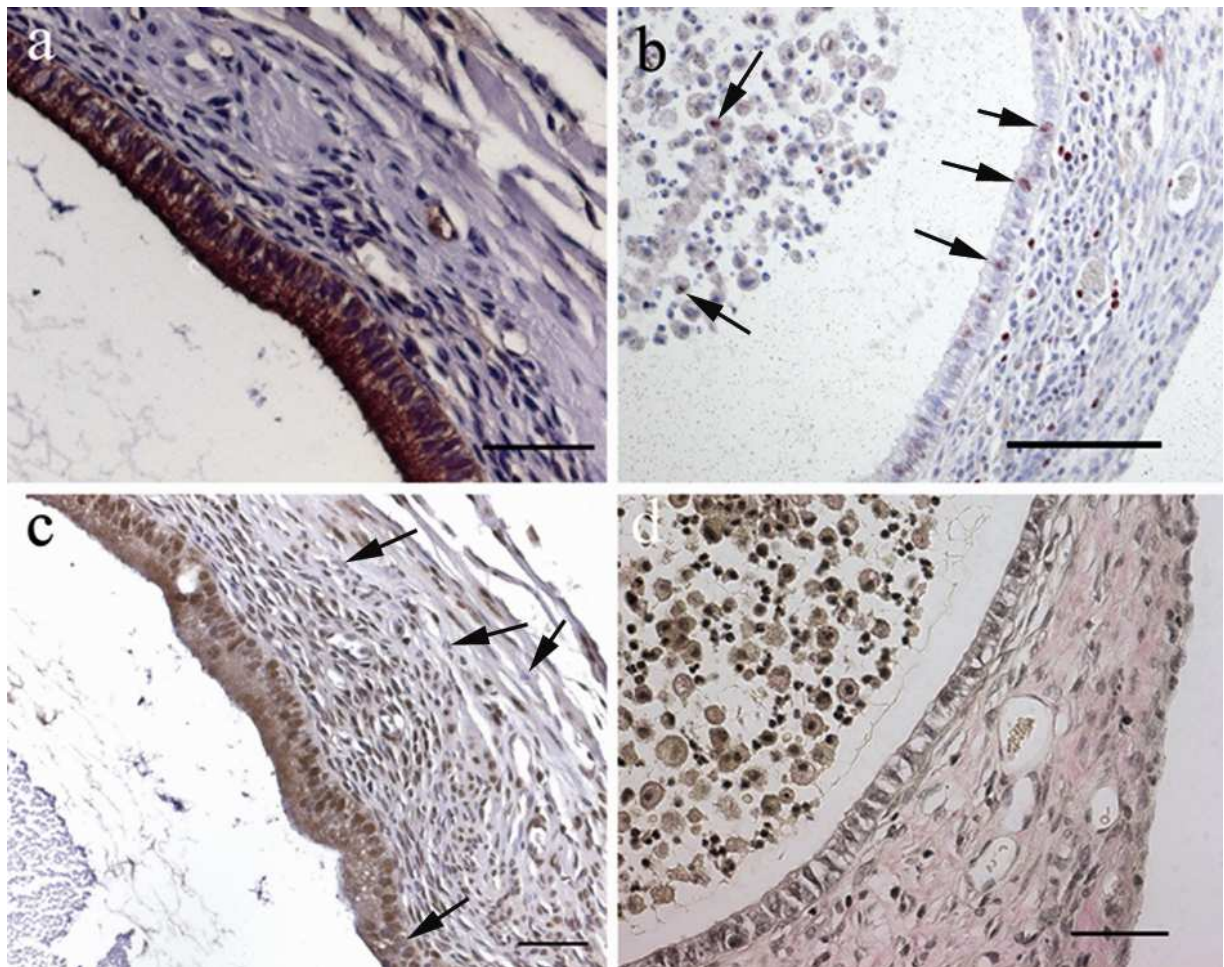


Figure 13: **Histological and immunohistochemical examination of EGFP-expressing endometriotic lesions.** (a) Anti-cytokeratin staining demonstrates glandular epithelial cells in brown around the cystic lumen. (b) Proliferating cells positive for Ki67 in lesion epithelium, stroma and in lesion lumen content are indicated by red stained nuclei (black arrows). (c) ER- α positive nuclei in epithelium and stroma are stained brown. Some ER- α negative nuclei are exemplarily indicated by the arrows. (d) Weigert-Elastica-van Gieson staining of an endometriotic lesion reveals collagenic connective tissue in magenta. Nuclei are stained black. Scale bar: a, c, d = 50 μ m, b = 100 μ m.

3.2.2 Lesion establishment, morphology and inflammatory parameters at different time points after endometriosis induction

Endometriosis is associated with inflammatory events in the peritoneal cavity. So far, it remains elusive whether this inflammation is cause or consequence of lesion establishment. To evaluate if inflammatory events occur after endometriosis induction in the injection model, a time course experiment was conducted. The previous experiments with the transplantation model had shown that 14 days after endometriosis induction no inflammatory parameters could be detected (see 3.1.3). Hence, two early (24 hours, 72 hours) and one late time point (10 days) were chosen to cover a broader range of events. Endometriosis was induced by injection of EGFP-expressing endometrium as previously described (3.2.1). Control animals were injected with medium. After 24 hours (24 h), 72 hours (72 h) and 10 days the mice were sacrificed. Lesion morphology and histology were evaluated to examine adherence behaviour and to study possibly occurring reorganisation processes. Moreover, PF and peritoneal cells

were harvested to investigate inflammatory parameters. Cells were counted and analysed by FACS to evaluate the amount and the cell type of immune cells. The PF was examined to detect differences in cytokine levels. Each group contained five mice and the experiment was repeated once.

3.2.2.1 Morphology and histology of lesions

Twenty-four hours: After 24 h, 6 out of 10 mice already had attached lesions. These lesions were not invasively fixed on organs or peritoneum as in the transplantation model. They were tightly bound to fatty tissue but could be torn off. Handling with tweezers was difficult because the lesions had a spongy, soft consistency. They displayed a patchy surface and were composed out of several smaller pieces as can be seen on Figure 14a. Histological examination showed no cystic lumen in any of the lesions.

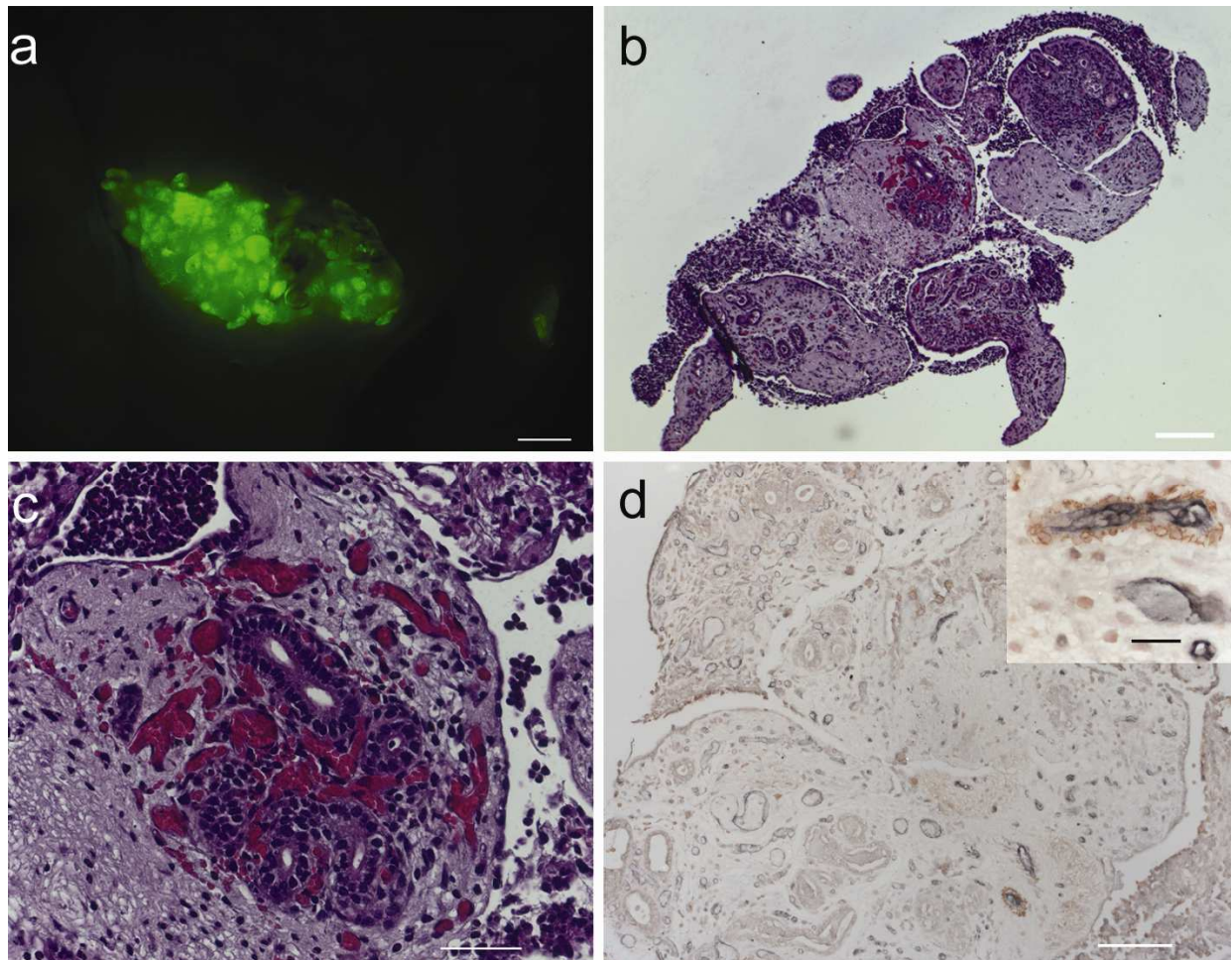


Figure 14: **Morphology and histology of a lesion 24 h after endometriosis induction.** (a) Lesion under fluorescent light revealing the conglomerate of small fragments. (b) HE staining of the section demonstrates the patchy tissue structure. (c) Magnification (200x) of the lesion in (b), revealing the areas with small gland-like structures and surrounding vessels. (d) Double staining of vessels. CD31 is displayed in grey-blue and indicates vessel endothelium; smooth muscle actin is stained red, indicating pericytes. The picture in the upper right corner shows a magnification of a vessel consisting of endothelial cells and pericytes. Scale bars: a = 1 mm, b = 100 μ m, c = 50 μ m, d = 100 μ m / 20 μ m

As illustrated in Figure 14b, the lesions seemed to be a conglomerate of several small tissue fragments. Higher magnification revealed some areas with small gland-like structures surrounded by vessels in every lesion (Figure 14c). The double-staining against CD31 for endothelial cells and smooth muscle actin (SMA) for pericytes revealed many immature vessels without surrounding pericytes, being exclusively positive for CD31, and only a few double-positive mature vessels.

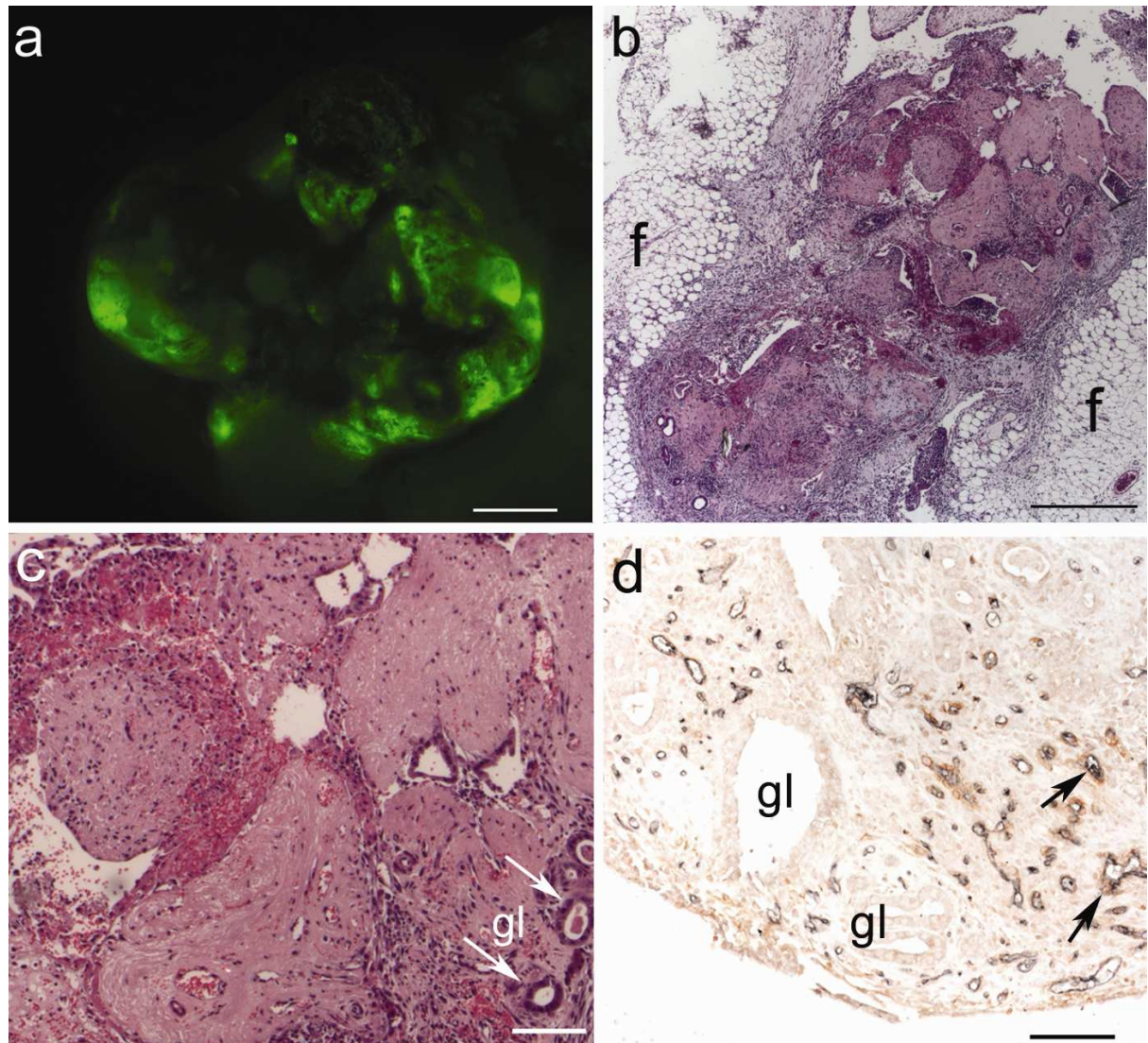


Figure 15: Morphology and histology of a lesion 72 hours after induction. (a) Lesion under fluorescent light. The dark shadows on the surface indicate blood accumulation. (b) Lesion after HE-staining embedded in fatty tissue (f). The heterogeneous structure and the large blood-filled areas can be easily distinguished. (c) Magnification of (b), revealing extensive erythrocyte-filled zones and some small gland-like structures (gl) indicated by arrows. (d) Double-staining against CD31 in vessel endothelium (grey-blue) and smooth muscle actin, e.g. in pericytes (red). Two double-positive vessels are pointed out by the arrows. Gland-like structures (gl) can be distinguished from the surrounding stroma. Scale bars: a = 1 mm, b = 500 μ m, c+d = 100 μ m.

Seventy-two hours: Counting of lesions after 72 h revealed that 9 out of 10 mice already had at least one attached lesion. Fifty percent of the lesions revealed dark shadows on the surface and were hardly detectable even under fluorescent light (Figure 15a). The texture

was solid and all of them had to be excised for further examination. HE-staining revealed a patchy structure similar to that of 24 h-lesions (Figure 15b). There were no large cystic lumina and still several small glandular formations (Figure 15c). Interestingly, 50 % of all examined lesions contained large hemorrhagic areas, in contrast to 24 h-lesions. The double-staining against vessel markers revealed more mature vessels, double-positive for CD31 and SMA, compared to the sections after 24 h.

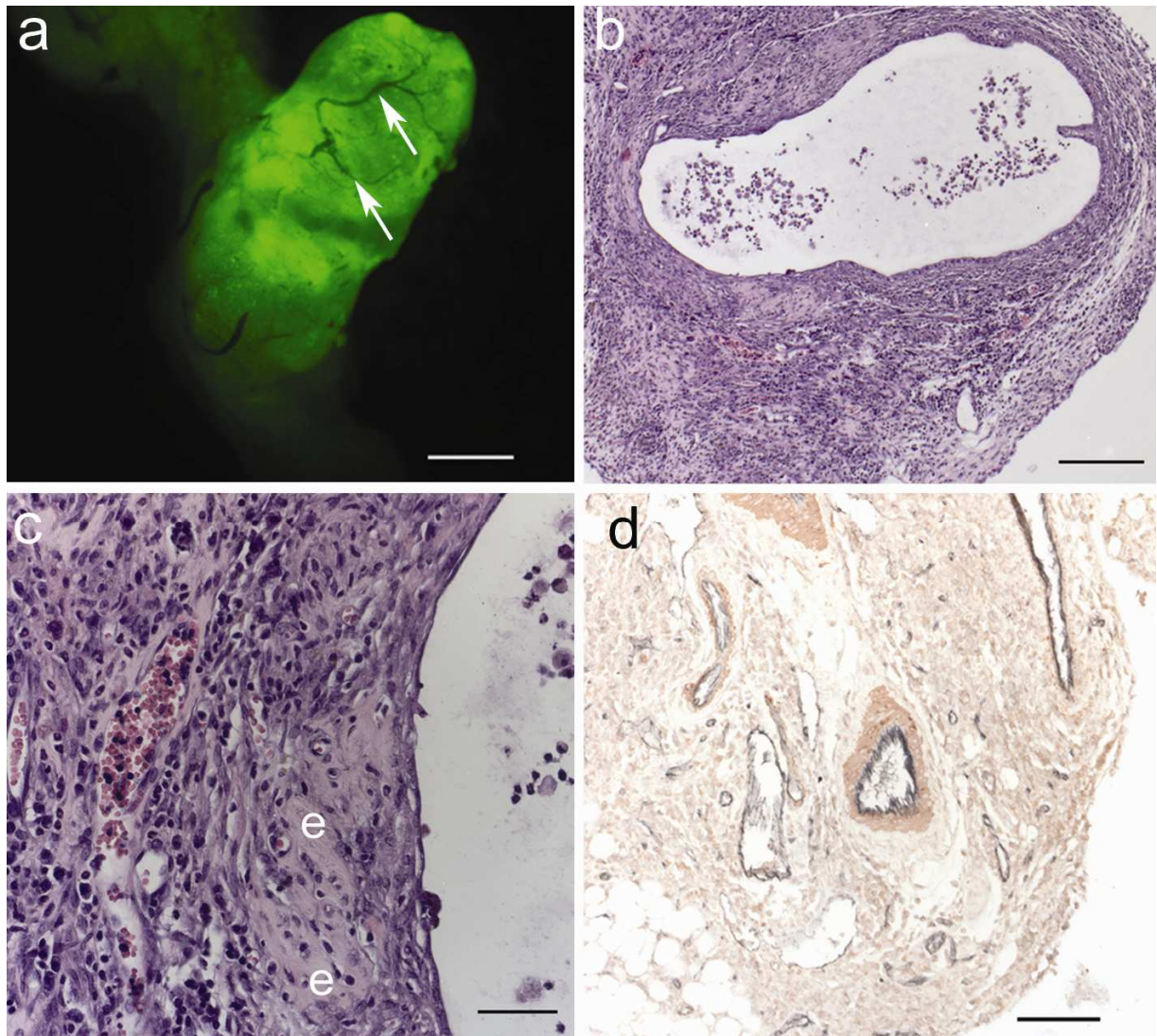


Figure 16: **Morphology and histology of lesions excised 10 days after endometriosis induction.** (a) Lesion under fluorescent light. Vessels are indicated by arrows. (b) HE-staining of a cystic lesion. The wide lumen contains immune cells. (c) Magnification of a part from (b), demonstrating the stromal structure of the lesion, erythrocyte-filled vessels and eosinophile patches (e). (d) Double-staining against CD31 in vessel endothelium (grey-blue) and smooth muscle actin (SMA), e.g. in pericytes (red). Large mature vessels positive for CD31 and SMA are easily detectable. Scale bars: a = 1 mm, b = 500 μ m, c = 50 μ m, d = 100 μ m.

Ten days: Ten days after injection of EGFP-expressing endometrium, 90 % of mice had attached lesions which had to be excised with scissors for further preparation. The outer lesion surface was smooth and highly vascularised. The entire structure appeared compact and solid (Figure 16a). Four out of nine lesions displayed a large cystic lumen as

demonstrated in Figure 16b. The others consisted of dense, non-cystic tissue. HE-staining revealed a heterogenic structure with stromal cells, vessels and eosinophile patches (collagenic connective tissue). No tissue fragment patches could be distinguished, thus the fragments seemed to have grown together compared to the 24 h/72 h sections (Figure 14b, Figure 15b). Additionally, no hemorrhagic areas and no small gland-like structures could be detected any more. Taken together, the morphology and histological appearance of lesions changed over time. The patchy structure of early time point lesions, indicating a conglomerate of several endometrium fragments, was lost after 10 days and a rather homogeneous structure was observed in the histological sections. Furthermore, the number of small glands detectable after 24 h and 72 h decreased and large, liquid-filled cysts were present later on. Moreover, the first attached lesions could be detected after 24 h, demonstrating early onset of adherence processes.

Angiogenic processes

The histological examination of the lesions after the three time points revealed that angiogenic processes might change over time. Fifty percent of lesions excised after 72 h displayed large hemorrhagic areas which was not the case in either 24 h- or 10 day-sections.

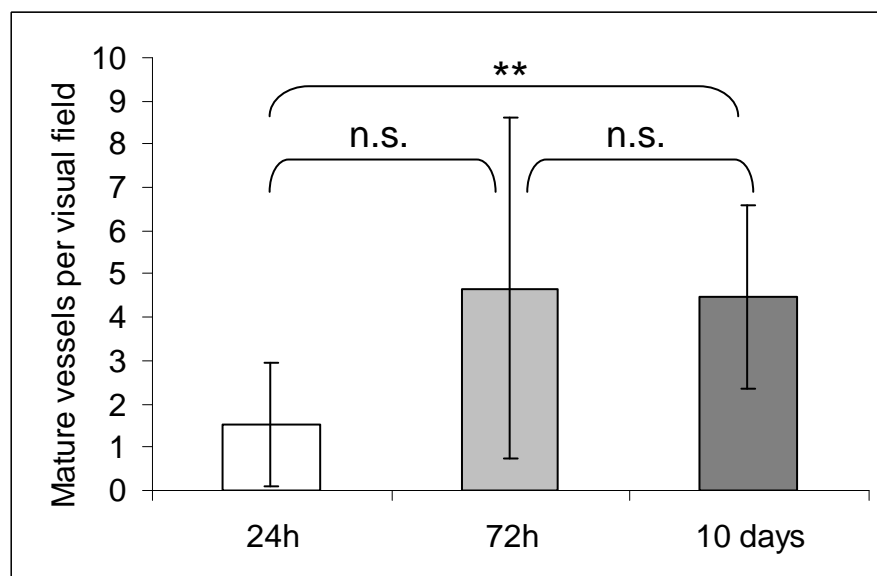


Figure 17: **Analysis of mature vessels.** Structures double-positive for CD31 and SMA around a lumen were counted in every section in 5 different visual fields. The difference between the mean mature vessel number after 24 h and 10 days was significant ($p = 0.004$, 95 % confidence interval: -4.81 to -1.09). Data are expressed as mean \pm SD. Statistical analysis was performed using t-test. n.s. = not significant

Therefore, a immunohistochemical staining against the endothelial marker CD31 and the pericytes marker smooth muscle actin (SMA) was performed. CD31 appeared in grey-blue and SMA in red (see Figure 14d, Figure 15d, Figure 16d). Double-staining of both markers around a luminal structure revealed mature blood vessels, which were counted in five

different visual fields in each section. From each time point (lesion number: 24 h, $n = 4$; 72 h, $n = 6$; 10 days, $n = 5$) two sections per lesion were evaluated.

The comparison of mature vessel number resulted in a significant difference between 24 h and 10 days (1.5 ± 1.44 vs. 4.5 ± 2.1 ; $p = 0.004$). The differences between 24 h and 72 h (4.7 ± 3.9) as well as between 72 h and 10 days were not conclusive, respectively. Thus, there were less mature vessels at an early time point apparently increasing over time.

3.2.2.2 Analysis of peritoneal cell counts and cell composition

Peritoneal inflammation is usually accompanied by an increase of immune cells in the peritoneal cavity. To evaluate whether endometriosis induction leads to an inflammatory situation in the peritoneal cavity, peritoneal cells were harvested via peritoneal lavage 24 h, 72 h and 10 days after endometriosis induction. In control mice, no endometriosis was induced and 400 μ L medium was injected instead.

Counting of peritoneal cells showed significant differences between medium-treated mice and endometriosis animals. After 24 h, the mean total cell number was significantly increased in endometriosis mice with $p < 0.001$ (Figure 18, Table 6). After 72 h the difference decreased, but was still statistically significant ($p = 0.005$; Figure 18, Table 6). Finally, counting peritoneal cells 10 days after endometriosis induction revealed a small, but significant increase ($p = 0.014$; Table 6). The experiment was repeated once, confirming the results.

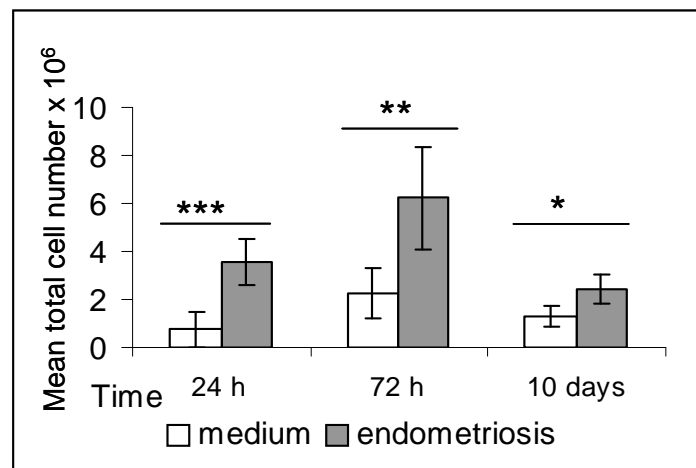


Figure 18: **Analysis of the total cell number in PF** ($n = 5$). A significant increase of cell amounts could be detected for every time point. Data expressed as mean \pm SD. t-test: * $p = 0.014$, ** $p = 0.005$, *** $p < 0.001$

In summary, the total cell amount of peritoneal cells increased after endometriosis induction with highest values after 72 h and slowly decreased over time. Thus, injection of endometriosis resulted in an early, intense inflammatory reaction, which was still detectable after 10 days.

Further characterisation of peritoneal cells was performed using FACS analysis and an antibody against CD11b to reveal differences in the immune cell population. Cells positive for CD11b are innate immune cells like granulocytes, NK cells, dendritic cells, microglia and macrophages. Comparing the amount of CD11b⁺ cells in the peritoneal fluid (PF) of medium-treated animals with endometriosis mice revealed significant differences. After 24 h, the endometriosis group contained significantly more CD11b⁺ cells in the PF than controls ($p < 0.001$; Table 6). After 72 h and 10 days, the differences were still significant with more CD11b⁺ cells in the endometriosis group ($p = 0.04$; Figure 19; Table 6).

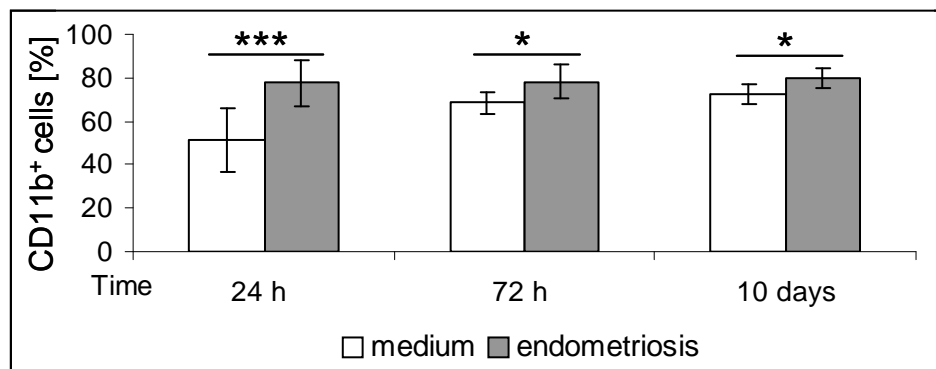


Figure 19: **FACS analysis of CD11b⁺ peritoneal cells.** Comparison of all CD11b⁺ cells (myeloid-derived cells) expressed as percent of total cells \pm SD ($n = 10$). t-test: *** $p < 0.001$, * $p = 0.04$

In summary, myeloid-derived CD11b⁺ cells were elevated after endometriosis induction. Their population most strongly increased immediately after injection of endometrial tissue and declined over time.

Table 6: Overview of mean total cells in the peritoneal fluid and FACS data for CD11b⁺ cells. Data are expressed as mean or percent of total cells \pm standard deviation, respectively. Statistical analysis was performed with t-test.

Time	Group	Total cells $\times 10^6$ ($n = 5$)	<i>p</i> -value 95 % confidence	Percentage of CD11b ⁺ cells ($n = 10$)	<i>p</i> -value 95 % confidence
24 h	Control	0.74 ± 0.76	$p < 0.001$	$51.54 \% \pm 14.81$	$p < 0.001$
	Endometriosis	6.57 ± 0.99	-4.11 to -1.55	$77.57 \% \pm 10.31$	-38.28 to -13.79
72 h	Control	2.27 ± 1.02	$p = 0.005$	$68.48 \% \pm 5.23$	$p = 0.04$
	Endometriosis	6.25 ± 2.13	-6.41 to -1.55	$78.27 \% \pm 7.97$	-16.13 to -3.46
10 days	Control	1.31 ± 0.45	$p = 0.014$	$72.63 \% \pm 4.48$	$p = 0.04$
	Endometriosis	2.343 ± 0.62	-1.93 to -0.31	$79.69 \% \pm 4.67$	-11.51 to -2.63

3.2.2.3 Measurement of cytokines in the peritoneal fluid

Peritoneal inflammation is accompanied by elevated levels of pro-inflammatory cytokines. In the previous paragraph, it has been demonstrated that the mean peritoneal cell number and innate immune cell levels are significantly increased in endometriosis animals, indicating a peritoneal inflammation. Thus, cytokine levels in the peritoneal lavage fluid were examined to further approve the hypothesis of peritoneal inflammation after endometriosis induction.

TNF- α and IL-6 were chosen since these cytokines are elevated in the PF of endometriosis patients (Kalu *et al.*, 2007). PF of endometriosis animals showed a tendency towards higher amounts of TNF- α after 24 h. The TNF- α levels 72 h and 10 days after induction showed no significant differences as well (Figure 20a). Regarding the levels of IL-6, a tendency of an elevation after 24 h and a significantly increased concentration after 72 h could be detected (Figure 20b). No difference in IL-6 levels could be demonstrated 10 days after induction of endometriosis.

In summary, detection of TNF- α revealed an increase after 24 h, although this was not significant. Same was found after investigating the 24 h-levels of IL-6. Interestingly, IL-6 is significantly elevated 72 h after endometriosis induction. Thus, the results suggest that endometriosis induction provoked an elevation of pro-inflammatory cytokines shortly after injection of endometrial fragments. This increase diminished, but was still detectable after 10 days.

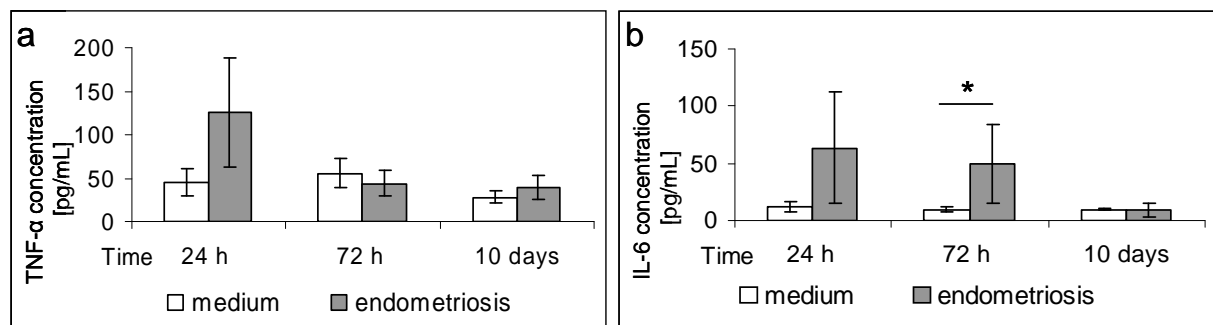


Figure 20: **Analysis of cytokine levels in PF by ELISA** ($n = 5$, samples measured in triplicate). **(a)** TNF- α levels showed a light increase after 24 h in endometriosis animals, which was not significant. **(b)** IL-6 levels were elevated after 24 h and significantly increased after 72 h in endometriosis mice. Data expressed as mean \pm SD. t-test: * $p = 0.032$

3.2.2.4 Summary of the time course experiment

Evaluation of lesion morphology revealed that adhesion processes occurred very early. Histological examination illustrated that these early lesions consisted of several fragments in a conglomerate as well as small areas of glands similar to these in human eutopic endometrium. After 72 h, strong angiogenic processes seemed to emerge in the lesions, indicated by large areas filled with erythrocytes and elevated numbers of mature vessels.

Investigating the lesions 10 days after induction, the small gland-like structures disappeared and large cysts were formed in nearly 50 % of lesions. The overall histological structure lost the patchy pattern and no more large blood-filled areas could be detected.

The investigation of inflammatory parameters revealed a correlation between all examined factors. First, all inflammatory parameters in peritoneal cavity were elevated in mice with endometriosis compared to controls with the strongest response occurring after 24 h. Second, there were still increased amounts of peritoneal cells and myeloid-derived cells after 72 h, but the levels were lower compared to 24 h. Third, evaluation after 10 days still revealed an increased peritoneal cell amount and elevated levels of myeloid-derived cells, but these were again lower than the values at 24 h and 72 h. Thus, the inflammatory parameters indicated an acute inflammation after 24 h, which decreased slowly after 72 h. However, after 10 days some inflammatory parameters were still elevated, revealing a light persisting chronic inflammation.

3.3 Induction of endometriosis in inflamed peritoneal cavity

The involvement of the immune system in endometriosis still remains clandestine. Using the injection model, the question was addressed whether a pre-existing inflammation, as hypothesised for instance by D'Hooghe (1992; D'Hooghe *et al.*, 1996a), influences lesion establishment. Therefore, a model for a peritoneal inflammation (peritonitis) was established and characterised towards inflammatory parameters (3.3.1). Ultimately, this peritonitis model was combined with the endometriosis injection mouse model (3.3.2).

3.3.1 Evaluation of thioglycolate-induced acute peritoneal inflammation

A well known method to induce a non-chronic inflammatory response in the murine peritoneal cavity is the intraperitoneal injection of thioglycolate medium (TM) (Li *et al.*, 1997). This method was also used in the following experiment to evoke an acute peritonitis. Peritoneal exudate cells (PEC) were harvested by peritoneal lavage with PBS 3 days after TM-injection. The cells were counted and further analysed with FACS technique. Furthermore, harvested macrophages from TM- and non-treated controls were stimulated with lipopolysaccharide (LPS) in an *in vitro* assay to evaluate differences in their cytokine secretion potential. Cytokines were also investigated in the peritoneal lavage fluid.

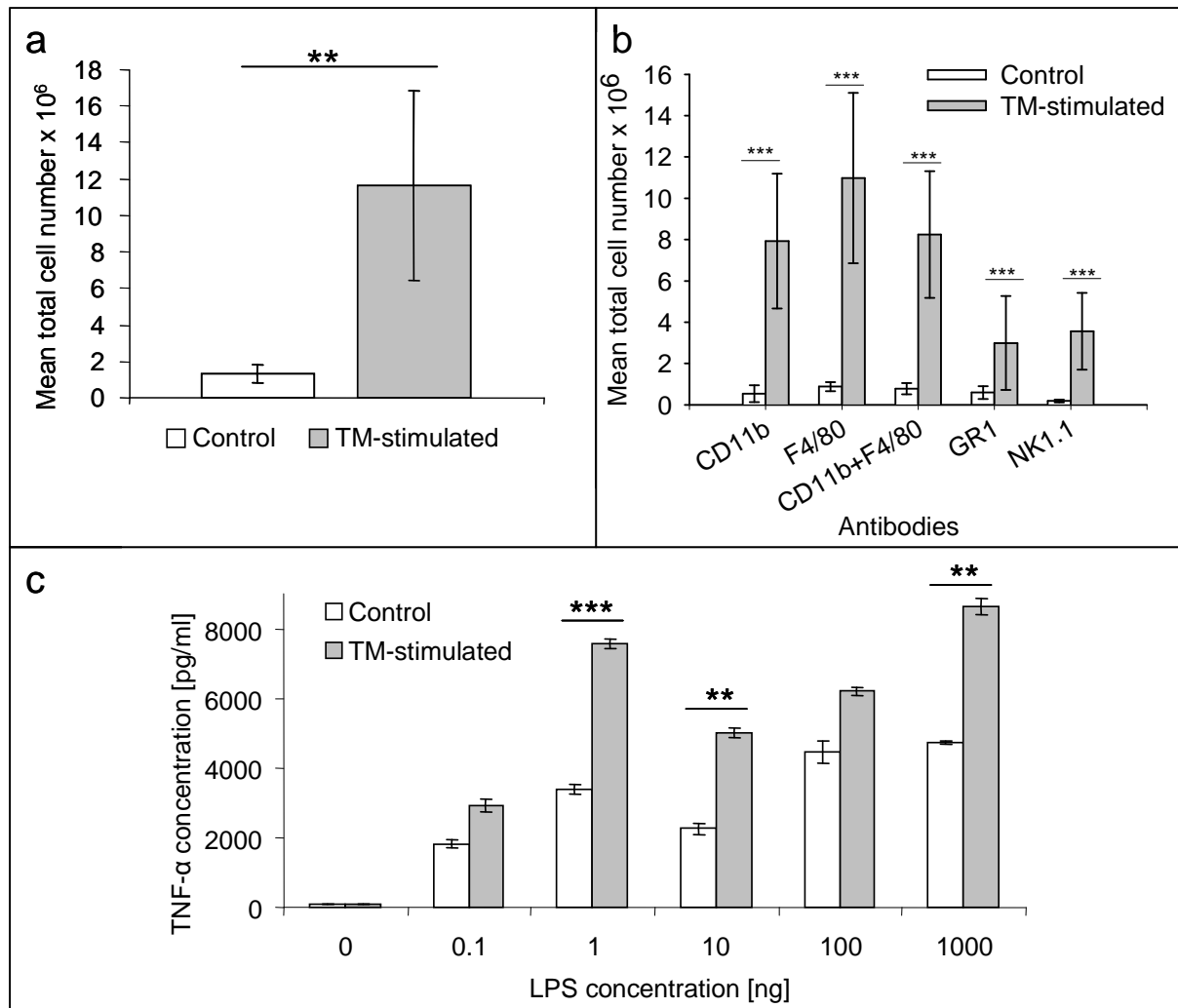


Figure 21: Evaluation of the peritonitis model. (a) Total cell amount after peritoneal lavage in control mice ($n = 12$) and TM-treated mice ($n = 12$) three days after TM-injection ($**p < 0.01$). (b) After analysing the peritoneal exudate cells (PEC) by FACS, higher total amounts of innate immune cells like neutrophils, macrophages, granulocytes and natural killer cells were detected in TM-treated mice ($***p < 0.001$). (c) A concentration-dependent increase of TNF- α was detected after LPS stimulation in the supernatant of pooled peritoneal macrophages from TM-stimulated mice ($n = 6$) and resident macrophages from control mice ($n = 6$). Significant differences were detected at a LPS concentration of 1 ng ($***p < 0.001$), concentration of 10 ng ($**p = 0.005$) and concentration of 1000 ng ($**p = 0.001$). Statistical analysis was performed using Wilcoxon rank sum test in (a) and (b) and t-test in (c). All results are expressed as mean \pm SD.

In response to TM treatment, a significant increase in peritoneal cell counts could be detected. Highest cell numbers were found on day 3 showing a 9-fold increase within the PF of TM-treated mice compared to PBS-treated controls ($**p < 0.01$; Figure 21a).

FACS analysis of PEC revealed an increase in various innate immune cells in the TM-treated mice compared to controls. Numbers of macrophages ($F4/80^+$ and $CD11b^+$) were significantly elevated in the treatment group ($8.3 \pm 3.1 \times 10^6$ vs. $0.8 \pm 0.3 \times 10^6$; $p < 0.001$; Figure 21b), representing around 70 % of the total cell number, thus demonstrating that macrophages are the predominant cell type in the inflamed peritoneal cavity. In addition, populations of

granulocytes (GR1⁺) and natural killer cells (NK1.1⁺) were significantly increased (Figure 21b).

Peritoneal macrophages of TM-stimulated and control mice were isolated from the PF, cultured *in vitro* and stimulated with increasing concentrations of LPS to examine their cytokine secretion. After investigation with ELISA, TNF- α level were significantly increased in the TM-group compared to controls after 20h LPS stimulation with concentrations of 1, 10 and 1000 nanogram (Figure 21c). Peritoneal lavage fluid was also collected and investigated, but the examined cytokines were below detection limit.

In summary, these findings demonstrate that i.p. injection of TM into mice leads to an acute non-septic peritonitis with increased levels of innate immune cells. Furthermore, the elevated TNF- α levels in the cell culture supernatant after LPS stimulation suggest a higher activity of macrophages after TM-treatment, which thus resemble macrophages from endometriosis patients.

Table 7: Data from peritoneal cell counts, FACS analysis and macrophage stimulation assay, comparing controls with TM-stimulated animals. Data are expressed mean \pm SD. Statistical analysis was performed with Wilcoxon rank sum test for non-Gaussian data (cell counts and FACS data) and t-test for normally distributed data (TNF- α concentration). n.s. = not significant

		Control	TM-stimulated	P value
Peritoneal cells $\times 10^6$		1.3 \pm 0.5	11.6 \pm 5.3	p < 0.01
FACS data $\times 10^6$	CD11b ⁺ + F4/80 ⁺	0.8 \pm 0.3	8.3 \pm 3.1	p < 0.001
	GR1 ⁺	0.6 \pm 0.3	2.9 \pm 2.3	p < 0.001
	NK1.1 ⁺	0.2 \pm 0.1	3.6 \pm 1.9	p < 0.001
TNF- α concentration [pg/mL]	LPS 0.0 [ng]	26.3 \pm 6.3	19.2 \pm 5.3	n.s.
	LPS 0.1 [ng]	453.8 \pm 110.4	732.8 \pm 198.7	n.s.
	LPS 1.0 [ng]	842.9 \pm 133.5	1894.2 \pm 146.7	p < 0.001
	LPS 10 [ng]	567.5 \pm 159.8	1256.2 \pm 144.5	p = 0.005
	LPS 100 [ng]	1109.8 \pm 333.2	1549.8 \pm 119.1	n.s.
	LPS 1000 [ng]	1182.3 \pm 37.9	2157.9 \pm 213.9	p = 0.001

3.3.2 Induction of endometriosis in an inflamed peritoneal cavity

The question if a peritoneal inflammation has an impact on lesion establishment was addressed by inducing endometriosis in an inflamed peritoneal cavity. First, the acute peritonitis was evoked by injection of thioglycolate medium. Following the induction of peritonitis, EGFP-expressing endometrial tissue fragments were injected into the peritoneal

cavity of TM-treated mice (see 3.2). Lesions formed under these conditions were examined, measured after autopsy and compared to lesions from endometriosis control mice, which did not receive a TM injection. Histological investigation was performed after lesions were embedded in paraffin.

On gross examination, fewer mice with lesions were found in the TM-treated group (Table 8). Five out of twenty mice (25 %) developed no endometriosis compared to 1 out of 20 (5 %) in the control group. Moreover, the mean lesion number per mouse was different. Mice with TM-treatment had fewer lesions per mouse compared to controls (Table 8).

Moreover, lesion size from TM-treated mice was compared to controls. Therefore, the cross-sectional area (CSA) was calculated using the formula for an ellipsoid [$\text{length} \times \text{width} \times (\pi/4)$] and the mean CSA per mouse was taken for analysis. The evaluation resulted in smaller CSA values in TM-treated animals (Table 8; Figure 22a). The cross-sectional areas in the TM-treated group tended to be around 48 % of those in the control group, with a 95 % confidence limit of [20.3 %, 114 %] ($p = 0.0943$). In this analysis, only mice with lesions were taken into account.

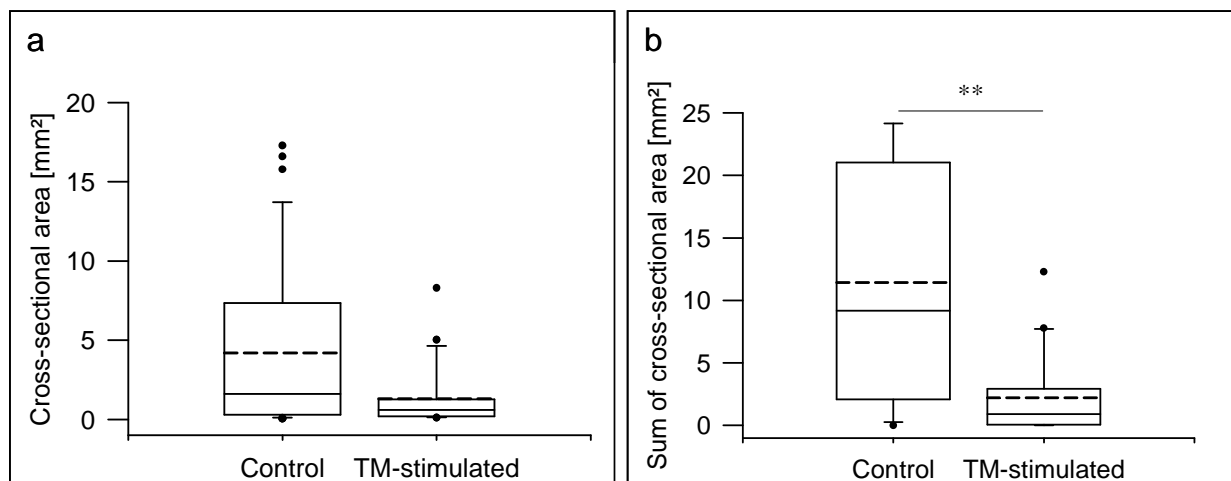


Figure 22: **Comparison of lesion size between control animals and TM-stimulated animals.** **(a)** Comparison of cross-sectional area (CSA) of lesions between control endometriosis animals and TM-treated endometriosis animals ($p = 0.0943$). **(b)** Box plot of the sum CSA per animal. The solid line in the boxes indicates the median, the dashed line the mean. Box margins are 25th and 75th percentiles, black dots indicate outliers and end of whiskers indicate 5 / 95th percentile, respectively. Statistical analysis was performed with exact two-sided Wilcoxon Rank sum test (** $p = 0.0013$).

Another examined parameter was the sum of lesion CSAs per mouse, used as a measure for the overall disease burden of the animal. Statistical analysis showed that TM-treated mice had a significantly reduced overall disease burden. The box plot (Figure 22b) of the sum CSA per mouse demonstrates the statistically significant difference between the two groups. The median overall burden in the TM-treated group was 0.92 mm², which was significantly lower than the overall burden of 8.8 mm² in the control group (Table 8; $p = 0.0013$).

Table 8: Comparison of different parameters analysed for lesion establishment and appearance in control mice and TM-stimulated mice (n = 20). Statistical analysis: Wilcoxon rank sum test. n.s. = not significant

Parameter	Control	TM-group	P value
Mice with no lesions	1 (5 %)	5 (25 %)	n.s.
Mice with debris	8 (40 %)	18 (90 %)	n.s.
Mean lesion number per mouse	2.4 ± 1.4	1.7 ± 1.4	n.s.
Lesion number range	0 - 6	0 - 4	n.s.
Mean cross-sectional area/mouse	4.9 ± 4.5	1.4 ± 1.6	n.s.
Median of CSA [mm²]	1.6 ± 5.9	0.6 ± 1.9	n.s.
Geometric mean of CSA [mm²]	1.3 ± 6.3	0.6 ± 3.5	n.s.
Sum CSA of all lesions [mm²]	217.4	44.2	n.s.
Median of sum CSA/mouse [mm²]	8.8 ± 9.9	0.9 ± 3.3	0.0013

The histological examination of lesions was carried out by morphological identification following haematoxyline-eosin staining and immunohistochemistry. In both groups, the lesions displayed endometriotic criteria like glandular epithelium and stromal cells. They had either a compact content (Figure 23a) or a cyst-like appearance (Figure 23b). The supporting blood vessels embedded in fatty tissue can be seen on Figure 23a. Furthermore, HE staining revealed several eosinophile patches within the lesion which could be identified as collagenic connective tissue by W-E-vG staining (Figure 23d). Moreover, mineralisation of tissue was discovered in TM-treated mice and controls in both lesion types (cystic and compact) indicating necrosis (illustrated with “m” in Figure 23a).

Immunohistochemical examination with SMA antibodies displayed only a low number of positive cells in the lesions from both groups. However, strong signals could be detected in surrounding vessels (Figure 23c). This indicates that there are no muscle fibers (e.g. myometrium from impure uterus preparation) and only a few pericytes in the lesions. Additionally, this staining illustrated the rich blood supply from the surrounding tissue.

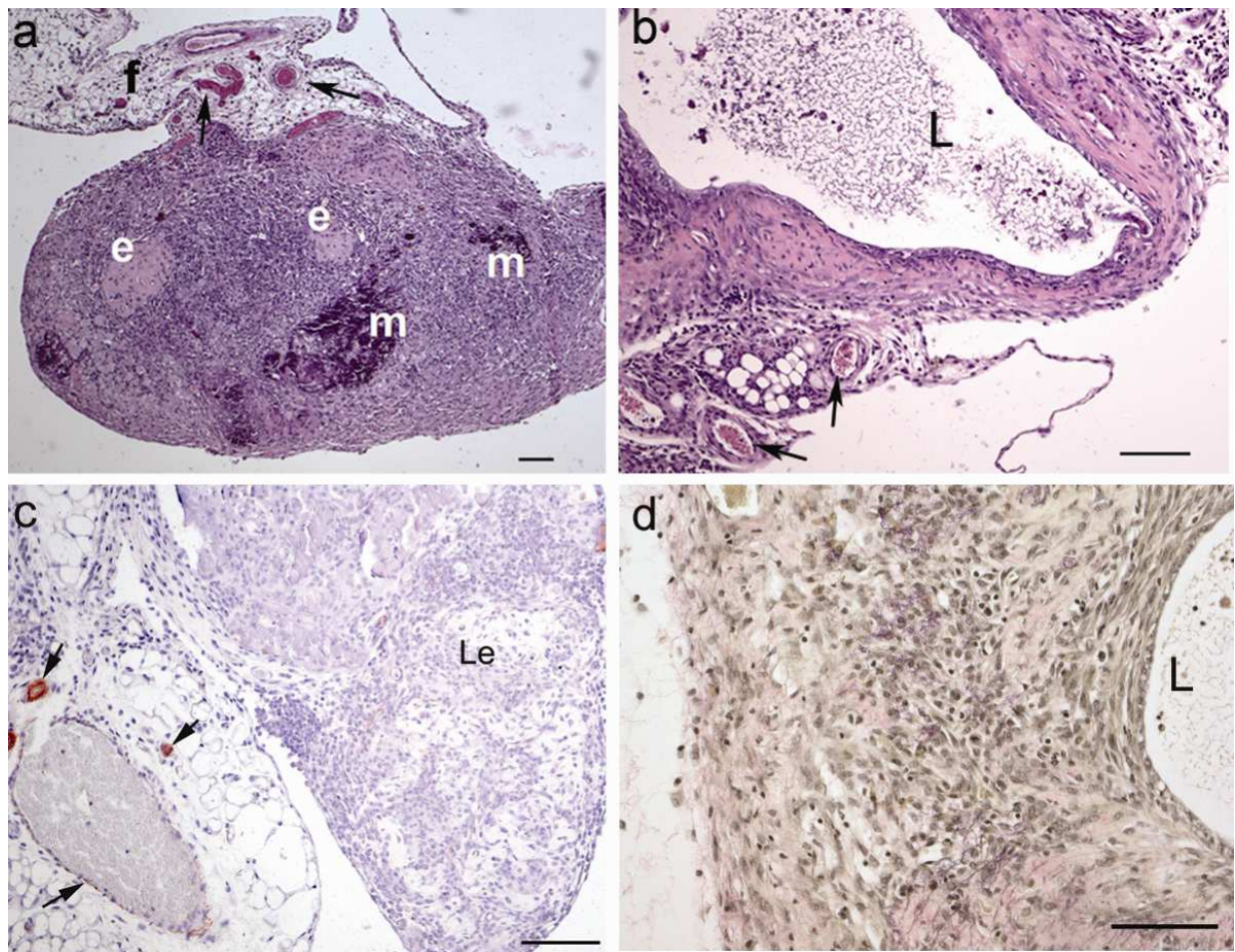


Figure 23: **Histological and immunohistochemical examination of lesions.** (a) Haematoxyline-eosin stained lesion from a TM-treated mouse with compact content, showing supporting vessels (indicated by arrows) embedded in fatty tissue (f), several sites of mineralisation (m) and eosinophile patches (e). (b) Lesion from a control mouse with cystic lumen (L) surrounded by stromal cells and supporting vessels. (c) Immunohistochemical anti-smooth muscle actin staining reveals vessels in the supporting fatty tissue surrounding the lesion (Le), indicated by the arrows. No further actin staining could be detected. (d) The Weigert-Elastica-van Gieson staining of a cystic lesion demonstrates collagenic connective tissue in magenta and cell nuclei in black around the cystic lumen (L). Scale bars: 100 µm

Another difference between TM-treated mice and controls besides the lesion number was the incidence of non-attached debris. Ninety percent of TM-treated mice and 40 % of control mice displayed intraperitoneally non-attached fragments. Figure 24a demonstrates the high amount of loose fragments taken out of a TM-treated mouse, on average 12 to 15 pieces. Peritoneal cavities of control mice contained only around one to three piece. Histological examination of debris sections revealed a heterogenic, diffuse structure (Figure 24b). No glandular epithelium could be detected and a cystic lumen could only be seen in one single piece of a control mouse (Figure 24c, upper right corner). Eosinophile patches occurred in different places which could be further characterised as collagenic connective tissue as shown by W-E-vG staining (Figure 24c). Additionally, in the debris sections no CD31⁺ cells could be detected (Figure 24d).

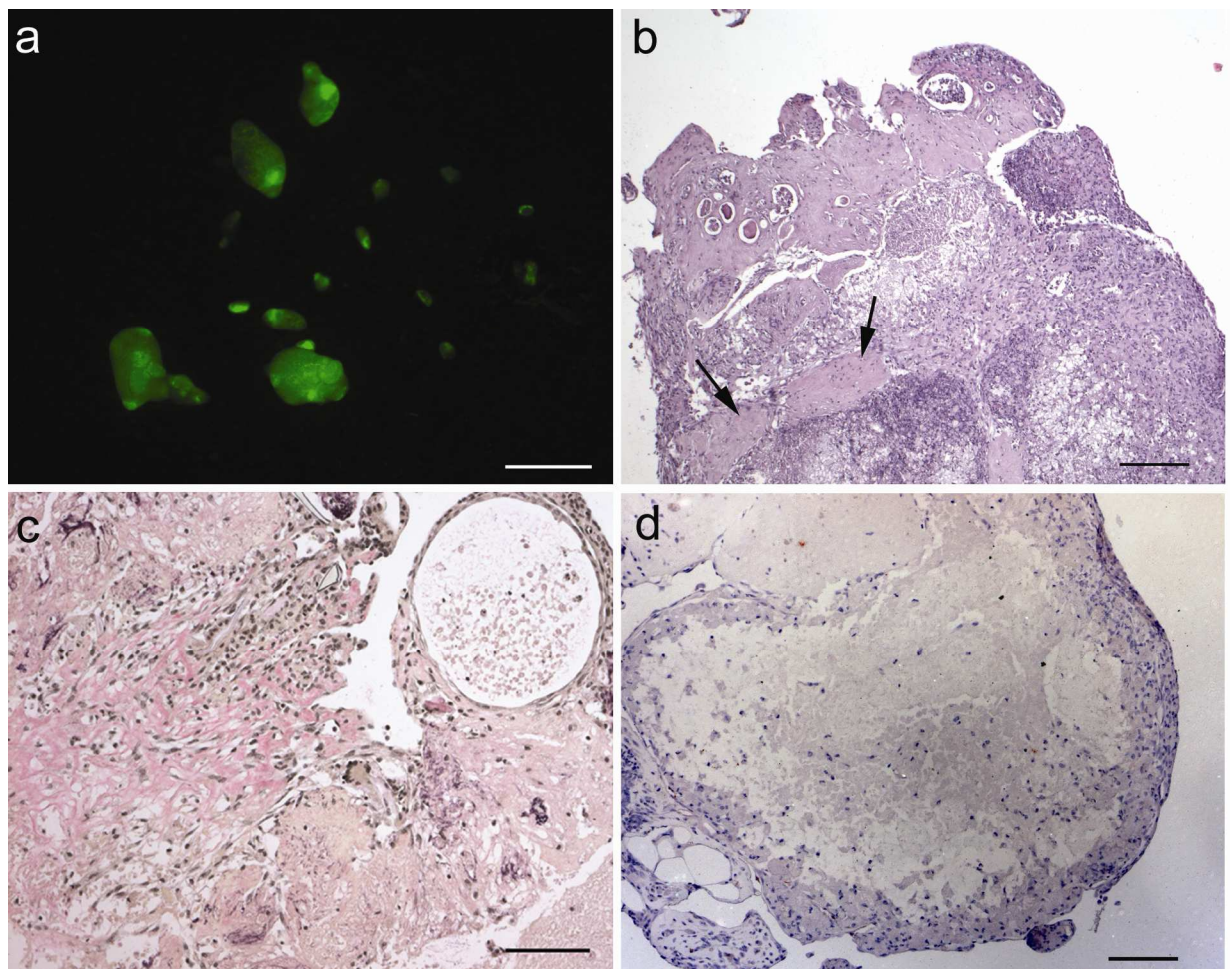


Figure 24: **Investigation of non-attached debris of a TM-treated mouse removed after autopsy.** (a) Picture taken under fluorescent light demonstrating the amount of debris in the peritoneal cavity of a TM-treated mouse. (b) In the haematoxyline-eosin staining of a paraffin-embedded debris section eosinophile patches are indicated by arrows. (c) Weigert-Elastica-van Gieson staining of a debris section. Collagenic connective tissue is stained magenta and nuclei black. (d) After anti-CD31 staining no vessels could be detected in debris. Scale bar: a = 2 mm, b = 200 μ m, c+d = 100 μ m.

3.3.3 Peritoneal inflammation decreased endometriosis

The induction of endometriosis in an inflamed peritoneal cavity resulted in fewer lesions per mouse and a smaller lesion size as well as significantly lower disease burden compared to non-treated controls. Furthermore, more mice with debris in the peritoneal cavity were detected in the TM group with a higher amount of debris per mouse. Histologically and immunohistochemically, no difference could be detected in lesions from TM-treated mice versus controls. Histological examination of debris showed a heterogeneous, patchy structure without SMA⁺ or CD31⁺ cells, indicating the absence of vessels and blood supply. Thus, a pre-existing peritoneal inflammation does not increase endometriosis establishment in this mouse model.

3.4 Induction of endometriosis in immune suppressed mice

The previous experiments have shown that a pre-existing immune stimulation like a peritoneal inflammation had no increasing effect on endometriosis establishment, it rather diminished the adherence. To further elucidate the role of the immune system in endometriosis, the impact of a *suppressed* immune system was investigated on implantation of endometrial fragments in the injection mouse model.

3.4.1 Immune suppression model

Investigation of the impact of a suppressed immune system on endometriosis establishment was performed in prednisolone-treated mice. Application of this glucocorticoid (GC) suppresses the immune system systemically and affects the innate and the adaptive immune system alike.

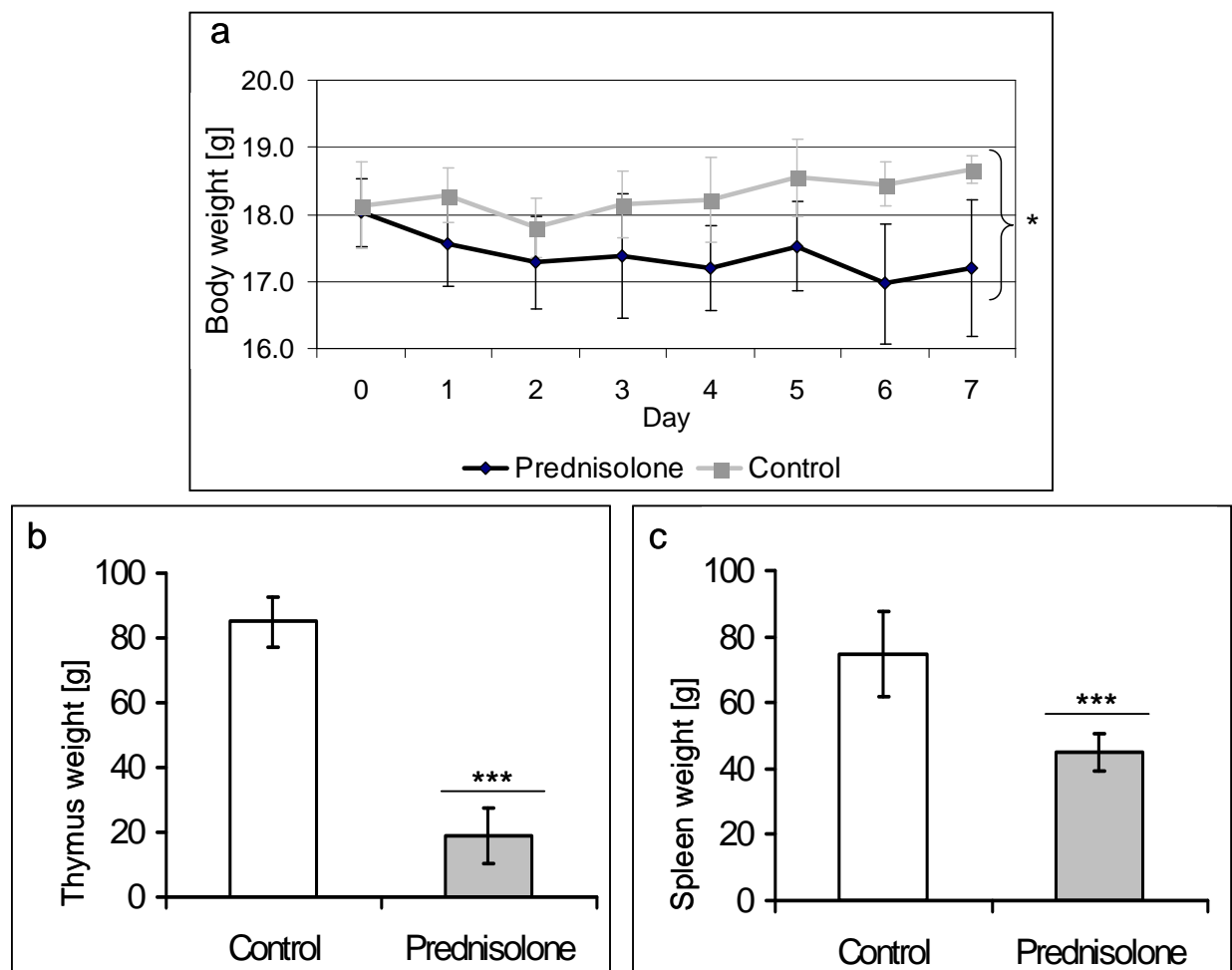


Figure 25: **Weight and organ weight measurements of prednisolone-treated animals and controls** (n = 6). **(a)** Body weight of prednisolone-treated animals significantly decreased after 7 days. t-test: *p = 0.021. **(b)** Thymus and spleen weights significantly decreased after 7 days treatment with prednisolone. t-test: ***p < 0.001

To validate the immune suppressive effects, a preliminary experiment was conducted where mice ($n = 6$) received a daily oral injection of 10 mg/kg body weight prednisolone for 7 days.

Body and organ weight

Daily investigation of body weight demonstrated a significant decrease in prednisolone-treated mice compared to vehicle-treated controls (Figure 25a). Additionally, thymus and spleen weights were examined after autopsy, revealing a significant decline as well (Figure 25b+c). The mean thymus weight was 84.9 ± 7.7 g for controls and 18.9 ± 8.4 g for prednisolone-treated mice. Mean spleen weights values added up to 74.7 ± 12.9 g in controls and 44.8 ± 5.7 g in treated mice. These findings displayed the expected effect of the treatment.

Analysis of whole blood and peritoneal cells

Besides the impact on body weight and lymphatic organs, glucocorticoid treatment has additional effects on blood cells. Adhesion of neutrophils to blood vessels is strongly decreased and consequently high numbers of neutrophils can be found in peripheral blood. Moreover, lymphocytes and monocytes undergo apoptosis and the expression of Major Histocompatibility Complex II (MHC-II) on these cells is decreased. To evaluate the effects of prednisolone treatment on blood cells, FACS analysis was performed with different surface markers to detect MHC-II molecules (MHC-II⁺), B cells (CD23⁺) and monocytes (CD4⁺).

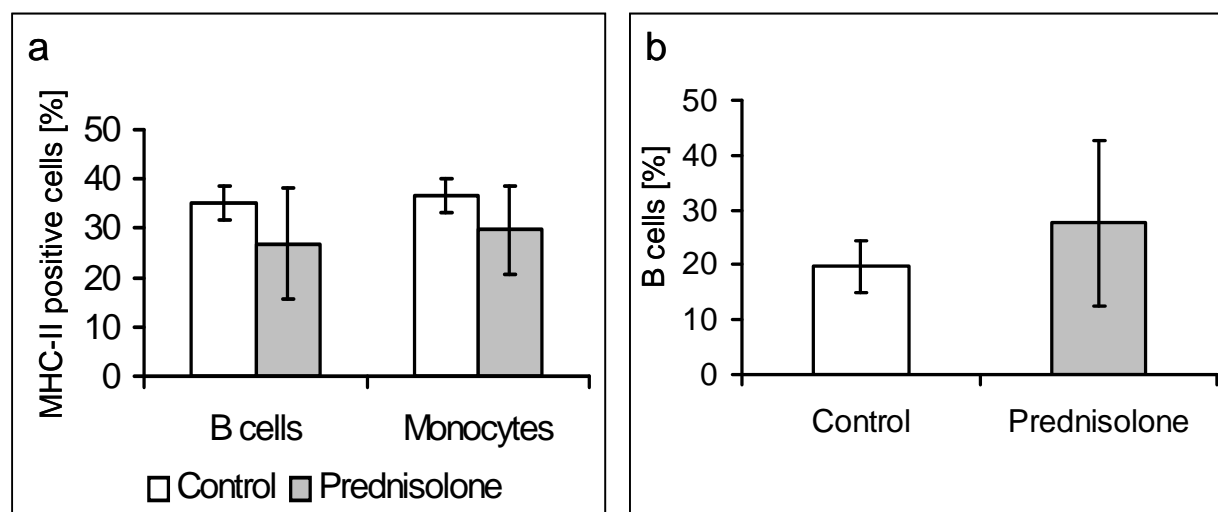


Figure 26: **FACS analysis of blood derived from control animals and animals treated with prednisolone for 7 days** ($n = 6$). **(a)** Percentage of B cells and monocytes expressing MHC-II on their surface was decreased in prednisolone-treated mice. Taking controls as 100 percent, MHC-II⁺ B cells add up to 76.8 % and MHC-II⁺ monocytes to 81.3 % of controls. **(b)** Percentage of B cells compared to total cell number did not show a conclusive difference.

The analysis of blood samples showed a tendency towards decreased levels of MHC-II on B cells and monocytes in blood of prednisolone-treated mice (Figure 26a). Calculating the

amount of MHCII⁺ B cells in controls as 100 %, B cells of prednisolone-treated animals were 76.8 % and monocytes 81.3 % of controls. No significant decrease of B lymphocyte numbers (Figure 26b) could be detected. Due to limited sample numbers, neutrophile levels could not be examined. Thus, the effect of prednisolone on blood cells was hardly detectable in this experiment.

In the present model, the induction of endometriosis is performed via injection in the peritoneal cavity. Hence, the effect of prednisolone on peritoneal cells was evaluated as well. After peritoneal lavage, the peritoneal cells were counted and prepared for analysis with FACS technique. Counting of total cell amount revealed no significant difference between prednisolone-treated animals and controls (Figure 27a; t-test: $p = 0.053$).

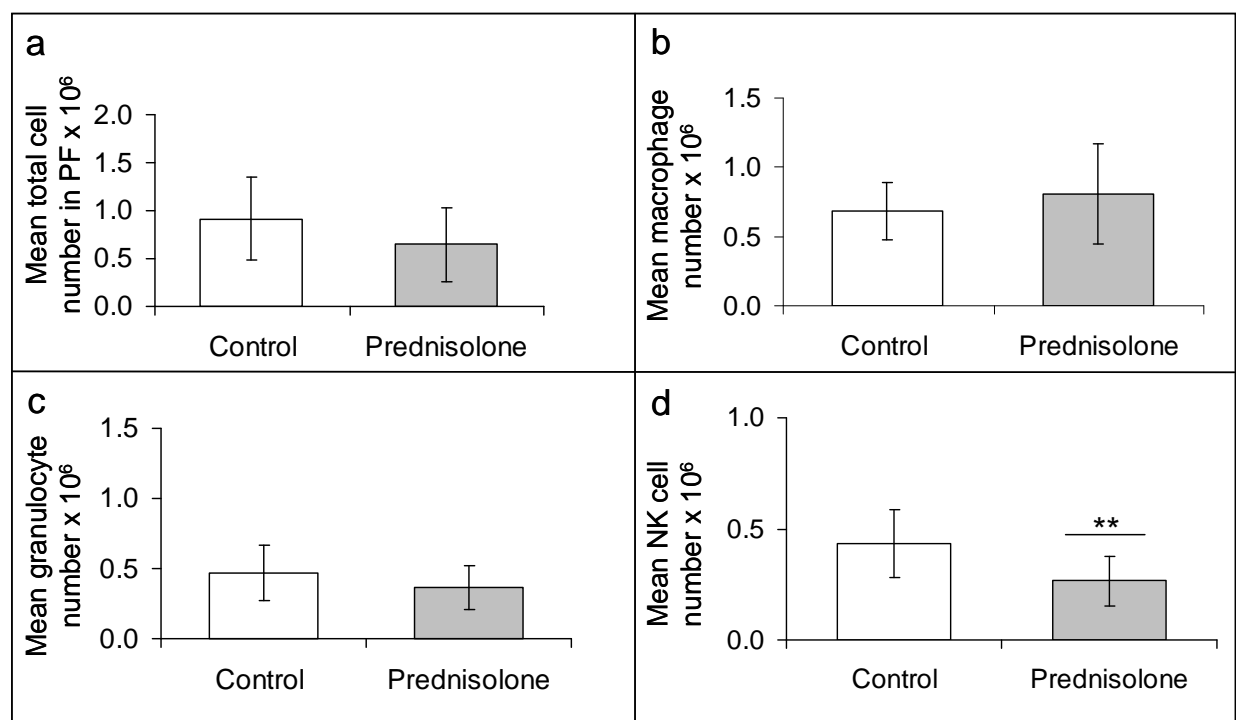


Figure 27: **Analysis of PF from prednisolone-treated mice and controls** ($n = 12$). **(a)** Total peritoneal cell number revealed no significant difference. t-test: $p = 0.053$. **(b)** The amount of macrophages (F4/80⁺) and **(c)** the amount of granulocytes (CD11b⁺) in PF was not significantly different between controls and prednisolone-treated mice. **(d)** In prednisolone-treated animals a significantly lower amount of NK cells (NK1.1⁺) could be detected in PF. All data are expressed as mean \pm SD. t-test: ** $p = 0.006$

Investigating the harvested peritoneal cells with FACS technique demonstrated no significant differences in macrophage levels (Figure 27b) and in granulocyte amounts (Figure 27c). Interestingly, the number of NK cells was significantly decreased in prednisolone-treated mice (Figure 27d). Controls had a mean total number of $0.43 \times 10^6 \pm 0.15 \times 10^6$ compared to $0.27 \times 10^6 \pm 0.11 \times 10^6$ in prednisolone-treated mice.

In summary, treatment with 10 mg/kg body weight prednisolone resulted in a systemic immune suppression with significantly decreased body weight, thymus and spleen weight.

Additionally, a tendency of decreased MHC-II expression on B cells and monocytes could be detected as well as increased B lymphocyte levels in whole blood analysis, although these data were not statistically significant. Examining the peritoneal cells revealed significantly decreased numbers of NK cells while other peritoneal cell populations like granulocytes were not affected.

3.4.2 Induction of endometriosis in immune suppressed mice

The impact of a suppressed immune system on endometriosis establishment was investigated after induction of endometriosis in prednisolone-treated mice. The recipient mice underwent prednisolone or vehicle treatment for 7 days and received EGFP-expressing endometrium on day 8.

The glucocorticoid-treatment continued for another 10 days. Autopsy including measurement of lesions was performed on day 18. All results are summarised in Table 9. The take rate in each group was 87.5 % (14 of 16 mice had lesions).

Comparison of lesion surface area (CSA; Figure 28a) and of sum CSA (Figure 28b) did not demonstrate any significant differences. Moreover, statistical analysis of the lesion number per mouse revealed no significant differences as well (t-test; $p = 0.282$).

Table 9: Summary of parameters evaluated 10 days following endometriosis induction in immune suppressed mice ($n = 16$). Statistical analysis was performed with t-test. n.s. = not significant

Parameter	Control	Prednisolone	P-Value
Mice with lesions	14	14	n.s.
Total lesion number	42	29	n.s.
Mean lesion number per mouse	3.0 ± 2.0	2.1 ± 1.3	n.s.
Lesion number range	0 - 8	0 - 5	n.s.
Mean cross-sectional area/mouse	2.4 ± 1.6	3.5 ± 1.5	n.s.
Median of CSA [mm²]	2.10	3.23	n.s.
Sum CSA of all lesions [mm²]	96.6	87.8	n.s.
Median of sum CSA [mm²]	4.9	6.0	n.s.

3.4.3 Immune suppression does not alter endometriosis establishment

Investigating the impact of a systemically suppressed immune system on endometriosis establishment showed no significant differences compared to non-treated animals. The take rate was 87.5 % in both groups with 3.0 ± 2.0 lesions per mouse in controls and 2.07 ± 1.33 lesions in treated mice (Table 9). Additionally, no significant difference in mean CSA and mean sum of CSA per mouse could be detected (Figure 28).

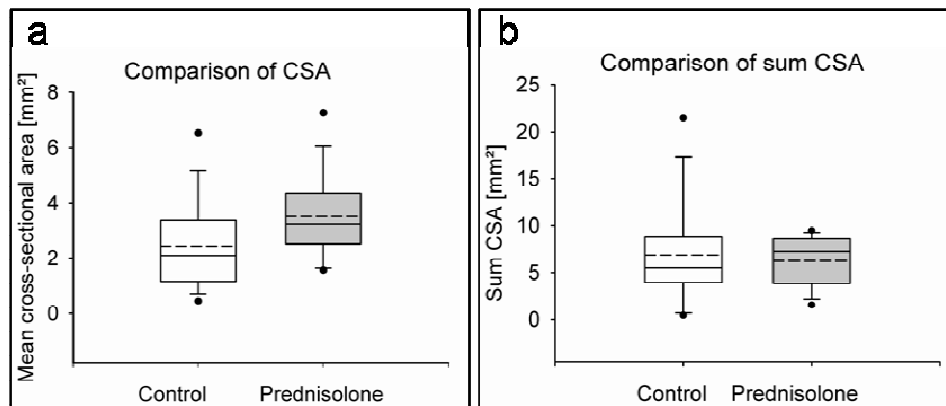


Figure 28: **Comparison of CSA and sum CSA between controls and prednisolone-treated mice.** (a) No difference in mean CSA could be detected. (b) Comparison of sum CSA per animal did not show significant differences. The solid line indicates the median and the dashed line the mean value. Box margins are 25th and 75th percentiles, black dots indicate outliers and end of whiskers indicate 5th/95th percentile, respectively. Statistical analysis was performed using exact two-sided Wilcoxon rank sum test.

3.5 Summary injection model

Intraperitoneal injection of EGFP-expressing endometrium fragments in mice resulted in establishment of endometriosis-like lesions with typical histological characteristics. These structures reorganise over time and changed from spongy conglomerates with small glands and a patchy structure (24 h and 72 h after induction) to solid, cyst-like lesions with well-established vascularisation. Additionally, the induction of endometriosis caused an acute inflammation confirmed by higher amounts of peritoneal cells, especially granulocytes and higher inflammatory cytokine levels compared to controls. Even after 10 days, slightly increased inflammatory parameters could be detected.

Finally, this mouse model was used to investigate the impact of the immune system on endometriosis establishment. On the one hand, a pre-existing peritoneal inflammation resulted in fewer lesions per mouse and a significantly lower disease burden as well as more non-attached debris in treated mice. On the other hand, a systemic immune suppression with the GC prednisolone did not cause any differences in lesion establishment in treated mice compared to controls.

4 Discussion

Endometriosis is a multifactorial disease characterised by a complex pathophysiology. Involvement of the immune system is known to have an impact, but exact details still remain enigmatic, therefore requiring intensive investigations to gain deeper insights into the pathophysiology of endometriosis. Controlled investigations in humans are limited by ethical concerns, making it difficult to justify repeated laparoscopies. Furthermore, most patients seek clinical counsel post-onset of endometriosis, eliminating the possibility to examine pre-existing endometriosis-promoting conditions. Thus, investigating the pathophysiology of endometriosis and consequently developing new therapeutic approaches evoke the need of an animal model system. The only animals known to spontaneously develop endometriosis are non-human primates (D'Hooghe *et al.*, 1991; MacKenzie and Casey, 1975), which makes them the best animal modeling for this disease. However, the long duration of endometriosis occurrence and the rare incidence rate decrease this model's susceptibility to systematic evaluation. Artificial induction of endometriosis in primates represents an alternative model to spontaneous endometriosis, but ethical concerns and high costs often limit the use of this approach. Alternatively, rodent models for endometriosis are used in this work to gain a better understanding of the pathophysiological conditions leading to the establishment and maintenance of endometriosis.

4.1 Mouse models of endometriosis

The first rodent model of endometriosis was performed in the rabbit. Endometrial fragments from one uterus horn were transplanted on the peritoneum in an autologous fashion (Schenken and Asch, 1980). Vernon and Wilson adapted this model to rats, suturing uterine squares on the peritoneum (1985). Referring to this method, Cummings and Metcalf published the first transplantation model in mice (1995). They sutured uterus biopsies from one horn onto the mesentery vessels of the small intestine. Further approaches have been made to optimise the model, for instance biopsies sutured additionally on the peritoneum in order to mimic peritoneal lesions, like it has been demonstrated by Becker *et al.* (2005).

4.1.1 Transplantation model

The mouse transplantation model according to Becker *et al.* (2005) was used in the present study with light modifications to evaluate its applicability as a model for endometriosis and drug discovery. As endometrium alone could not be used due to its soft consistency impairing suturing, uterine biopsies were sutured onto the right and left sides of the peritoneum as well

as two fragments onto the mesenteries. One group of mice was supplemented with weekly estradiol-valerate injections to examine the responsiveness of lesions towards E₂.

After 14 days, cyst-like endometrial lesions developed. These ectopic fragments demonstrated histological characteristics of the human lesions, such as glandular epithelium and stroma around a cystic lumen (Figure 7e). The presence of glandular epithelium is one hallmark of endometriosis and a diagnostic criteria for this disease in human patients. Furthermore, the presence of ER- α was demonstrated (Figure 7b). This finding is another important criteria for endometriosis since estrogen responsiveness of the lesions and estrogen-dependent lesion growth rely on the presence of the estrogen receptor (Jänne *et al.*, 1981; Matsuzaki *et al.*, 2001). Evaluation of the transplantation model showed enhanced lesion growth in mice supplemented with E₂ (Figure 9b) compared to animals without supplementation, demonstrating estrogen responsiveness as it has also been previously reported (Cummings and Metcalf, 1995; Lin *et al.*, 2006). High vascularisation was also revealed by immunohistochemistry which correlates well with data shown by Cummings and Metcalf (1995), supplying necessary nutrients for growth (Figure 7d). Thus, histology of the lesions obtained from the transplantation model reveal similarity to human lesions, reinforcing the suitability of this model.

In addition to the histological hallmarks for endometriosis, treatment with the SERD ZK703 demonstrated the estrogen-dependency of the model. This compound was initially found to be an effective anti-estrogen in breast cancer research (Hoffmann *et al.*, 2004). Anti-estrogens like SERD ZK703 destabilise and downregulate the ER and lead directly to the complete disruption of ER-mediated growth stimulation in ER-bearing tissues. After treatment with ZK703, endometriotic lesion size was significantly diminished (3.1.2). Decreased lesion size also occurs in women treated with GnRH analogues (Erickson and Ory, 1989). These compounds interrupt the hypothalamus-pituitary axis by preventing the secretion of gonadotropins like FSH and LH and consequently the secretion of estrogen, thus acting indirectly on the human cycle. Unfortunately, combined use of ZK703 together with E₂ supplementation is ineffective in mice. Since the experiments with the transplantation model in this study were performed using mice with or without E₂ supplementation (3.1.2), a SERD was used instead of GnRH analogues to validate the model.

Interestingly, after treatment with the SERD ZK703, one mesenterial lesion increased in size (page 39 ff). This could be explained by the rare occurrence of a suture granuloma, which can be misleadingly interpreted as an endometriotic lesion. These granulomas develop after incomplete dissolving of the suture thread and consist of fibrotic, sometimes inflamed connective tissue. Their outward appearance resembles endometrial lesions. Granuloma cells

could be identified by histological examination but not every lesion was excised and embedded in paraffin, so that the existence of a granuloma could not be verified.

In order to synchronise the animals' E₂ levels, several authors used ovariectomised mice and supplemented them with E₂ pellets (Becker *et al.*, 2008; Cummings and Metcalf, 1995; Harris *et al.*, 2005; Lin *et al.*, 2006; Somigliana *et al.*, 1999). Conversely, in-house results demonstrated that the insertion of E₂ pellets initially leads to a very high serum concentration of E₂ that slowly decreases over time rather than maintaining a constant level, whereas estradiol-valerate injections display a short increase in E₂ levels but return to base line levels after 3 days (Figure 8). In the present study, E₂-supplemented and non-supplemented mice were used. Analysis of endometriotic lesion size without E₂ revealed that lesions actually do grow without hormonal substitution (Figure 9a). Moreover, E₂ is known to influence the immune system (Straub, 2007) in addition to its effect on the endometrium. Therefore, E₂ supplementation was refrained from further experiments. Instead, endometriosis was induced in mice in estrus cycle stage to synchronise the animals for the starting point of the experiment. Additionally, the endometrium of uterus in estrus is well established, thus facilitating the extraction of uterus biopsies.

In addition to previously mentioned histological criteria of endometriosis, inflammatory parameters were also examined in the transplantation model. Peritoneal lavages were performed in mice 14 days following experiment onset. After this time period the lesions were well established and no visible wound healing processes were detected (Figure 6). Neither counting of the peritoneal cells nor analysis of immune cell profiles by FACS revealed any significant differences among the three groups. Interestingly, analysis of cytokines in the peritoneal lavage fluid with a multiplex assay demonstrated that animals with induced endometriosis had significantly elevated levels of IL-6 compared to controls (Figure 11). IL-6 belongs to the acute-phase cytokines (Ramadori and Christ, 1999) and is also elevated in endometriosis patients (Kalu *et al.*, 2007). However, it is difficult to conclude from these findings that IL-6 is an inflammatory response stimulated by endometriosis in the mouse, since no significant difference between endometriosis mice and sham-operated animals was observed. Moreover, the cytokine levels in the lavage fluid were below the level of detection, further rendering the interpretation of the results inconclusive.

As no differences were detected in the number of peritoneal or innate immune cells, there seems to be no inflammation present in the peritoneal cavity after 14 days of lesion growth. In addition, the lesions (Figure 6) displayed a smooth surface and a hard, tense consistency with no evidence of inflammation such as redness, purulence or swelling. Interestingly, inflammatory events could be shown inside the lesions and in the cystic lesion content by the presence of macrophages and neutrophils 14 days following endometriosis induction (data

not shown). Presumably the inflammatory events only occur inside the lesion but not within the peritoneal cavity.

To obtain more conclusive results, increased animal numbers should be examined, including earlier time points. Moreover, cytokine levels should be determined in concentrated PF by a more sensitive method, e.g. ELISA, to ensure protein detection.

4.1.2 Injection model

In addition to transplanting uterus tissue onto peritoneum or mesenteries, other autologous methods have been performed; these include transplantation of endometrium beneath the renal capsule of a rat (Katsuki *et al.*, 1998) or intraperitoneal injection of endometrial fragments in mice (Somigliana *et al.*, 1999). In the present work, a slightly modified method was used by injecting EGFP-expressing endometrium into intact cycling wild type mice according to an experiment detailed by Hirata *et al.* (2005). EGFP-expressing endometrial fragments were used to facilitate the detection of lesions that are not otherwise tracable under impinging light. Immunohistochemical investigations showed that two of the histological hallmarks of endometriosis, namely glandular epithelium and ER- α , are present in the lesions (Figure 13a, c), emphasising the suitability of this approach as a murine model for endometriosis. Compared to the transplantation model, in which uterus biopsies are sutured within the peritoneal cavity, the tissue fragments in the injection model adhere spontaneously onto specific locations like the omentum and peritoneum. These observations correspond to previous results reported by Hirata *et al.* (2005). Another frequent site of lesion adherence in the present model is the fatty tissue around the uterus and pancreas, presumably due to estrogen production in fatty tissue (Brodie, 1979). The predisposition of lesions on fatty tissues is a phenomenon also described by other investigations of endometriosis establishment in murine models (Hirata *et al.*, 2005; Somigliana *et al.*, 1999). Adipose tissues produce estrogens that may facilitate lesion growth. In addition, pro-angiogenic factors derived from these tissues might have an impact as well. The cytokine leptin for example is secreted by adipocytes and has strong pro-angiogenic effects (Sierra-Honigsmann *et al.*, 1998). Furthermore leptin absence or ablation has been demonstrated to disrupt the establishment of endometriosis-like lesions in a mouse model (Styer *et al.*, 2008). Thus, the role of fatty tissue as a favoured attachment site is an interesting finding and seems to be important beyond E₂ production in this model. In patients, high concentrations of leptin have been found in the PF (Matarese *et al.*, 2000). However, fatty tissues are not preferential attachment sites for endometriotic lesions in humans.

The measurement of lesion surface area in the injection endometriosis model revealed that despite the injected tissue fragment size of 400 x 400 μ m, lesions with a size of up to 4 mm in

diameter could be detected. This might be due to adherence of injected pieces to each other and subsequent growth of the conglomerate (Figure 14a). Immunohistochemical stainings for the proliferation marker Ki67 demonstrated that epithelial as well as stromal cells of lesions continued to proliferate, thus confirming lesion growth (Figure 13b). Another immunohistochemical finding was the very low amount of α -smooth muscle actin in lesions, demonstrating that there were only a few pericytes present in the tissue sections (Figure 23c). Pericytes usually surround endothelial cells and, together with the basal membrane, build up the mature microvessel. In contrast, immature microvessels consist only of endothelial cells. Endometriosis is strongly associated with neovascularisation (Becker and D'Amato, 2007; Groothuis *et al.*, 2005; Laschke and Menger, 2007) and immature vessel formation (Hull *et al.*, 2003). Thus, the lesions developed after injection of EGFP-expressing endometrium mimic the neovascularisation characterized in human endometriotic lesions.

Advantages and disadvantages of both mouse models

The transplantation and the injection model are both suitable for endometriosis research as demonstrated in the present study (3.1.4, 3.2.1). However, utilization of each model must be carefully based on the desired outcome as each model presents its unique advantages and disadvantages.

The transplantation approach is a robust model with a high take rate, defined number of lesions as well as easy recovery and measurement of lesions. It enables to investigate therapeutic approaches as control laparotomies can be performed and comparison of lesion sizes before and after therapy is possible. The high take rate and the defined number of lesions are important for its application in both basic and pharmacological research. Moreover, lesions can be easily excised and examined histologically. Estrogen dependency has been demonstrated by successful treatment with ZK703, demonstrating the applicability of this model for anti-hormonal therapeutic approaches.

However, uterine fragments are used and myometrial structures were always found in the lesions in contrast to the histological appearance of human lesions, where myometrial structures do not frequently appear. Furthermore, the lesions are sutured into the peritoneal cavity, thereby damaging the tissue and possibly influencing lesion growth due to inflammatory and wound healing processes. Technical problems arise from the thread still present in the lesions, resulting in difficulties when preparing samples on the microtome.

In contrast to the transplantation model, the injection model is suitable to examine adherence processes. Endometrium, instead of entire uterus, is injected to mimic retrograde menstruation. Furthermore, the developed lesions histologically resemble human endometriotic lesions and there is no wound healing in the recipient mouse after

endometriosis induction. Moreover, the EGFP-expressing endometrium enables detection of small and hidden lesions or non-attached debris under fluorescent light.

A disadvantage of the injection model is the varying lesion number from 0 - 8 per mouse. Furthermore, the lesions can be tiny, rendering them impossible to perform histological examinations and leading to an increased risk of detachment during peritoneal lavages. The size of the injected endometrial tissue fragment must be small enough to fit through the canula, thus limiting the evaluation of adherence capacity of different fragment sizes. In addition, autopsy under fluorescent light is a time-consuming process compared to laparoscopy in the transplantation model.

In summary, lesion histology of both models resembles the human condition, thereby demonstrating the applicability of both approaches for endometriosis research. Furthermore, the transplantation model is a useful tool for therapeutic approaches, especially for compounds targeting hormonal processes or affecting lesion growth. The injection model is in turn suitable to examine lesion establishment and adherence processes.

4.2 New insights into endometriosis development from time course experiments of lesion establishment

Further evaluation of adherence and angiogenesis processes was performed in a time course experiment using the injection model. Endometriosis was induced by injection of EGFP-expressing endometrial fragments as previously described (2.2.3). Twenty-four hours, 72 h and 10 days later the mice were sacrificed for evaluation. A peritoneal lavage was performed to examine peritoneal cells and fluid and the endometrial fragments were evaluated for disposition. The results from this time course experiment further underlined the applicability of the injection model for experiments evaluating the establishment of endometriotic lesions. Formation of adhered lesions had already started after 24 h and increased over time. Moreover, the developed lesions demonstrated morphological, histological and angiogenic similarities to human endometriotic lesions (Figure 14, Figure 15, Figure 16).

Adherence and reorganisation processes

Investigating the localisation of the endometrial fragments 24 h following endometriosis induction revealed that in 6 out of 10 mice lesions were already established at this early time point (3.2.2.1). These results correspond to the findings of Witz *et al.*, who cocultured human menstrual endometrium with human peritoneal explants for 1 h and discovered a rapid adherence between the two tissues (Witz *et al.*, 2001b). In addition, the evaluation of lesions after 24 h, 72 h and 10 days demonstrated that the presence of small, gland-like structures

diminishes and large, cyst-like structures appear over time (3.2.2.4), indicating that the lesions undergo a reorganisation process. These findings are in accordance with results from Nisolle *et al.* who demonstrated that human endometrium, transplanted into nude mice, adhered in the peritoneal cavity within 1 day and reorganised into gland-like and stromal structures 5 days following induction (Nisolle *et al.*, 2000). However, in the present study the small gland-like structures disappeared over time and large, dilated cysts appeared in nearly 50 % of cases after 10 days. This difference to the work of Nisolle *et al.* is most likely due to the origin and composition of the tissue material. The human endometrial biopsies, taken from the menstrual phase, displayed degenerative stroma, some fragments of glandular epithelium and ruptured, collapsed glands (Nisolle *et al.*, 2000). In the present work, murine endometrial fragments from uterus in estrus were injected, mainly to facilitate the separation of endometrium and myometrium; and furthermore, murine endometrium in estrus demonstrates peak vascularisation and maximum epithelial cell development. Additionally, the connective tissue is oedematously relaxed with consequently protruding capillaries and glands (Nitschke and Fabian, 1970). Thus, the endometrial tissue samples used in the two endometriosis mouse models differ in glandular structure and vascularisation, presumably leading to differences in reorganisation processes.

Angiogenesis and hypoxia in endometriotic lesions

In the present work, double-staining against CD31 and SMA showed that the number of mature vessels (double-positive for CD31 and SMA) is greater after 10 days than after 24 h following endometriosis induction, indicating more mature vessels at the 10 days time point (Figure 17).

Interestingly, the angiogenic processes occurring in the murine endometriotic lesions correlate well with recent data from humans, where the “age” or activity of lesions is associated with the complexion. Concerning angiogenesis, red lesions are supposed to be early lesions that have recently developed and are active whereas white lesions represent scar tissue and are inactive (Donnez *et al.*, 2003). The correlation between early red lesions and higher angiogenesis is supported by Fujishita *et al.* (1999), where they demonstrated that the index for proliferating cell nuclear antigen (PCNA) and endoglin (CD105, a pro-angiogenic component of transforming growth factor β) is higher in red lesions compared to black or white lesions, indicating varying degrees of angiogenic activities in different lesion types. Increased amounts of VEGF were also detected in red lesions compared to black lesions and eutopic endometrium (Donnez *et al.*, 1998), providing further evidence for higher angiogenic activity in early lesions, which correlates well with the present work. Endometriosis is generally associated with immature vessels and neovascularisation (Becker and D'Amato,

2007; Groothuis *et al.*, 2005; Laschke and Menger, 2007), thus the angiogenic processes in the murine endometriotic lesions reflect the situation in human lesions.

However, the present model does not distinguish between vessels derived from EGFP-expressing graft endometrium and host-derived vessels. This topic was addressed by deposition of human menstrual endometrium in the peritoneal cavity of nude mice (Eggermont *et al.*, 2005). Experimentators used immunohistochemical staining with antibodies specific for murine or human epitopes to identify the origin of the vessels. Evaluation of the number of human and murine vessels in the lesions after immunohistochemical staining demonstrated significant decrease and increase, respectively (Eggermont *et al.*, 2005). Thus, existing vessels from the graft diminished and new vessels from the host took over the blood supply, indicating that endometriotic lesions are able to induce angiogenesis in the host. Furthermore, the experiment reveals that angiogenic reconstruction processes occur rather at early time points.

Angiogenic processes were also detected at early time points in the present study in accordance with the study of Eggermont *et al.* (2005). Lesions excised 72 h following induction of endometriosis revealed large hemorrhagic areas filled with erythrocytes and rudimentary vessel structures (3.2.2.1). Assuming angiogenesis occurs, new vessels will develop from pre-existing host-derived vessels. VEGF will be secreted by endometriotic cells, attract ambient vessels and induce angiogenesis (Figure 5). New immature vessel fragments initially consist only of endothelial cells. Subsequent stabilisation occurs via attachment of pericytes and blood flow through the lumen. If these fragile immature vessels assemble within the developing lesions, the unstabilised vessel walls may rupture due to movement of the animal. Since there is already a pseudo-capsule around the lesion, the blood is enclosed and accumulates, which might explain the hemorrhagic areas detected in the lesions after 72 h (Figure 15).

Furthermore, the hypoxic state of the injected endometrial fragments shortly after injection might also contribute to angiogenesis. In the present study, the lesions existing after 24 h all exceeded 150 μm in diameter; oxygen and nutrients are able to diffuse up to a distance of 150 μm through tissue (Brahimi-Horn *et al.*, 2007). Thus, the inner layers are likely to become hypoxic, which would consequently lead to the secretion of VEGF. This hypothesis is supported by a study of Becker *et al.* in a transplantation mouse model (2008). The authors suggest that endometriotic lesions acquire new blood vessels through hypoxia-induced upregulation of VEGF. The presence of hypoxyprobe-1 (which forms insoluble protein conglomerates under hypoxic conditions) in early lesions as well as the upregulation of hypoxia-inducible factor-1 α (HIF-1 α) confirmed the occurrence of hypoxia in their study. Moreover, the therapeutic approach with the anti-angiogenic agent 2-methoxyestradiol

inhibited HIF-1 α and decreased lesion size (Becker *et al.*, 2008). Thus, hypoxia plays a role in the pathophysiology of endometriosis and might be another elicitor for the angiogenic processes occurring in the murine lesions.

Induction of endometriosis provokes peritoneal inflammation

Elevated numbers of peritoneal cells and innate immune cells along with higher concentrations of the pro-inflammatory cytokines TNF- α and IL-6 were detected in mice with induced endometriosis compared to controls without endometriosis, indicating an inflammatory reaction (3.2.2.2, 3.2.2.3). Highest levels were detected 24 h following induction which declined over time, but were still elevated after 10 days (Figure 18, Figure 19, Figure 20). Thus, injection of endometrium and establishment of endometriosis-like lesions induce a peritoneal inflammation. These results are in line with findings from D'Hooghe *et al.* (2001), who investigated the effect of endometriosis induction on peritoneal inflammatory parameters in baboons, the best available animal model. They demonstrated that 3 months following induction of endometriosis a subclinical peritoneal inflammation was present, which was indicated by increased leukocyte concentration and elevated subsets of cells positive for TNF- α , CD3 and intracellular cell adhesion molecule-1 (ICAM-1) (D'Hooghe *et al.*, 2001). Thus, the similar effect of intraperitoneal injection of endometrium on inflammatory parameters observed in both baboons and in the present mouse model underlines the suitability of the injection approach.

Reasons for the detected peritoneal inflammation may be attributed to specific properties of endometrial cells. They are known to secrete pro-inflammatory cytokines like TNF- α , IL-6 and IL-8 *in vitro* (Witz *et al.*, 2001a), which in turn can further enhance inflammation. TNF- α for example is known to initiate the cascade of pro-inflammatory cytokines and other factors associated with inflammation (Hunt *et al.*, 1992). IL-6 is a regulator of inflammation and immunity, for instance promoting T-cell activation and B-cell differentiation (Siristatidis *et al.*, 2006). The polypeptide IL-8 facilitates macrophage recruitment into the peritoneal cavity, which in turn secrete additional pro-inflammatory cytokines. Thus, the results of the present work suggest that specific properties of ectopic endometrial cells might contribute to an inflammatory environment. To further investigate the possibility of a chronic inflammation, further time points such as 2 or 4 weeks should be examined in future experiments.

Moreover, the observed inflammatory response might be induced by cell contents released after preparation of the endometrial fragments. This is comparable to the situation of retrograde menstruation in women, where tissue fragments and cell debris together with blood are transported in the peritoneal cavity. In the mouse model, intracellular proteins and parts of the cell membrane are injected together with endometrial fragments in the peritoneal

cavity and could lead to the inflammatory response. At a later time point, the fragments conglomerate and become surrounded by a defined capsule-like covering. Hence, no further cell content is released and the inflammation subsides. Intracellular EGFP as potential antigen and inducer of inflammation is rather unlikely since responses involving the adaptive immune system require repeated contact with the antigen.

Furthermore, it is conceivable that the detected peritoneal inflammation occurred due to injection of “mislocated” material, not endometrium in particular. Injection of another syngeneic EGFP-expressing material such as intestinal mucosa, that is syngeneic and anatomically similar to endometrium, could be a suitable control approach to investigate this hypothesis. However, it remains elusive whether intestinal tissue will adhere to the peritoneal cavity. A study performed by Somigliana *et al.* (1999) in a syngeneic mouse model demonstrated that significantly fewer lesions developed after injection of small bowel mucosa. Furthermore, the lesions did not display histological characteristics of bowel mucosa, but consisted of fibrotic material.

The experiment showed that induction of endometrium induced a strong inflammatory response shortly after injection of endometrial fragments. In nearly all patients, elevation of inflammatory parameters like peritoneal immune cells and cytokines in the PF is also detected. However, it is unlikely that this inflammatory environment results from a recently developed endometriosis. There must be additional processes provoking and maintaining the detected inflammation. As reported for the baboon, leukocyte concentration in the PF is significantly increased during menstruation, in comparison to nonmenstrual phases, indicating inflammatory processes in the peritoneal cavity (D'Hooghe *et al.*, 1996b). The hypothesis is that the inflammation is reactivated every time the baboons or the women menstruate by regurgitation of new endometrial fragments in the peritoneal cavity or by bleeding of lesions during menstruation. However, this hypothesis cannot be experimentally assessed due to ethical restrictions.

4.3 Impact of the immune system on endometriotic lesion establishment

The role of the immune system in endometriosis establishment is an important question throughout the research community as outlined above, yet to be fully understood. The present work aimed to investigate contributing details of the immune system alterations on the establishment of endometriotic lesions.

Peritoneal inflammation decreases lesion establishment in the injection mouse model

A question of long-standing clinical interest is the assumption that pre-existing peritoneal inflammation might induce or at least favour the establishment of endometriosis. Clinical studies are not able to investigate hypotheses of this kind and little is known in actual disease. Moreover, it is ethically difficult to address this issue adequately in women because it is not feasible to perform repeated laparoscopies. Therefore, this question was pursued by combining a murine peritonitis model with an endometriosis model.

Peritoneal inflammation was induced by intraperitoneal injection of thioglycolate medium (TM), a method that has been routinely used for several decades by now (Argyris, 1967). Induction of peritonitis can also be achieved by injection of other agents, such as casein, bacillus Calmette-Guérin vaccine or methylated bovine serum albumine (mBSA) (Cook *et al.*, 2003; Hrabak *et al.*, 2006), each leading to different effects on peritoneal cells. Comparison between mBSA and TM revealed that TM injection recruited more immune cells into the peritoneal cavity than mBSA treatment (Cook *et al.*, 2003). Additionally, macrophages were larger, more vacuolated and displayed different surface marker distribution compared to resident and mBSA-elicited macrophages (Cook *et al.*, 2003). Furthermore, the TM-excited macrophages resemble activated macrophages in many respects (Den Otter *et al.*, 1982). Isolated TM-elicited macrophages revealed increased TNF- α and IL-12 secretion, a characteristic also described in endometriosis patients (Rana *et al.*, 1996; Wu *et al.*, 1999). Therefore, TM injection was chosen as a model for an acute pre-inflamed peritoneal cavity with features resembling the inflammatory situation described in patients. In-house data demonstrated that TM-induced inflammation peaked after 3 days, which was selected as the time point.

Analysis of the number and size of lesions established in the peritoneal cavity revealed a significantly lower overall disease burden as well as fewer lesions per mouse and more non-attached debris in the TM-treated mice compared to controls. Thus, the pre-existing peritoneal inflammation does not enhance endometriosis, but actually seems to reduce lesion establishment.

A higher clearance of tissue fragments due to an increased phagocytosis rate might explain the situation detected in TM-treated mice. The preparation of endometrium leads to tissue disruption and damaged cells, which are injected together with endometrial tissue fragments into the peritoneal cavity. This process attracts macrophages and initiates phagocytosis. Thus, a 10-fold increase of phagocytosing cells after TM injection (Figure 21) might lead to a faster clearance of the tissue than would occur with an unstimulated immune system.

Additionally, macrophages can execute diverse functional activities including oxidative burst, matrix dissolution and tissue remodelling (Janeway *et al.*, 2005). Lin *et al.* also showed that macrophages and neutrophils infiltrate ectopic endometrial tissue and the peritoneal cavity (Lin *et al.*, 2006). Their local secretion of cytokines and chemokines may also influence the development of lesions. Hence, elevated numbers of macrophages could lead to increased cell destruction via radicals released by respiratory burst and finally to a pronounced tissue degradation, impairing the adherence capabilities of the endometrium fragments. Macrophage degradation of surface proteins impedes further adherence with other fragments and with peritoneal surfaces and consequently decreases lesion formation and may increase debris found in TM-treated mice. An *in vitro* comparison of TM-elicited and resident macrophages would further increase the understanding of activated macrophages and their role in endometriosis. Activated macrophages are presumably different in their migration pattern or pro-inflammatory cytokine secretion. Furthermore, immunohistochemical stainings of distinct cell adhesion proteins like integrins or cadherins on the lesion surface might show a difference between lesions or debris derived from TM-treated mice or controls.

Currently, anti-inflammatory approaches are a frequently discussed potential therapeutic treatment. However, this *in vivo* study demonstrates that a broad, unspecific, pre-existing peritoneal inflammation decreases the establishment of endometriosis-like lesions. It is the first study investigating the impact of a pre-inflamed peritoneal environment on the establishment of endometriotic lesions in the EGFP mouse model. The results are in line with a previous study where a pro-inflammatory compound successfully decreased endometriosis establishment (Somigliana *et al.*, 1999). The pro-inflammatory cytokine IL-12, which favours the generation of the T-helper cell 1 (Th1) response, was injected intraperitoneally in mice (2 days prior endometriosis induction until 2 days after). Their study demonstrated that treatment with this cytokine effectively reduces ectopic implantation of endometrial fragments in an endometriosis mouse model. Furthermore, the authors suggest “that IL-12 may enhance the growth and augment the cytolytic activity of both NK/LAK (lymphokine-activated killer) and T cells” and thus leads to reduced endometriosis establishment. In contrast to TM, which elicits a broad inflammation, IL-12 activates a specific pathway of immune response (Brunda, 1994).

Another interesting pro-inflammatory approach to treat endometriosis was conducted in rats (Itil *et al.*, 2006). In contrast to the non-septic peritoneal inflammation induced by TM, a bacterial vaccine with *Bacillus Calmette-Guérin* (BCG) was subcutaneously administered and endometriosis was induced by autologous transplantation of uterine fragments two weeks later. Eight weeks following laparotomy, a significantly lower lesion number was detected in the vaccinated group. Thus, a systemic challenge of the immune system and stimulation of the cellular immune response by a bacterial vaccine may also exert an inhibitory effect on

lesion establishment (Ittil *et al.*, 2006). The manner in which vaccination with BCG affects and modulates the immune system and thereby reduces lesion establishment, remains to be clarified.

By contrast, disease burden can also be reduced after treatment with anti-inflammatory NSAIDs (Efsthathiou *et al.*, 2005). However, according to the authors, properties other than anti-inflammatory activity of NSAIDs could be responsible for decreased lesion size. They suggest that the COX-2-inhibitor Celecoxib for example might be associated with induction of apoptosis in the endometriotic explants, but no further experiment was conducted to validate this hypothesis. Additionally, lesion reduction may be attributed to the anti-angiogenic effects of Celecoxib (Efsthathiou *et al.*, 2005). This controversial situation, where pro- and anti-inflammatory approaches both result in decrease of lesion size, might be due to the fact that TM-induced inflammation, IL-12 and Celecoxib all act through different mechanisms and pathways. These data suggest that not only one pathway but several are involved in the development of the disease and underline the importance of the immune system in this disease.

However, the induced peritoneal inflammation in this study represents only certain aspects of inflammatory events observed in endometriosis. A primary defect like abnormal macrophage function in endometriosis patients is a frequently discussed issue and may also be an important factor for lesion establishment. Additionally, a lower phagocytosis rate caused by lesion-derived proteins affecting peritoneal macrophages is postulated for endometriosis patients (Sharpe-Timms *et al.*, 2002).

Taken together, the initiation of an inflammatory response in the peritoneal cavity followed by endometriosis induction is a valuable approach to investigate the role of the immune system in this disease. The study demonstrates that a pre-existing inflammation did not increase, but decreased disease burden in the mouse model and thus might rather not be a prerequisite for the development of endometriosis. In humans, there is increasing evidence that other factors like primary macrophage defects rather than inflammation are responsible for the establishment of endometriosis (Vinatier *et al.*, 1996). Thus, further experiments, e.g. investigation of the role of peritoneal macrophages, characteristics of their migration or congenital gene profile alterations, are necessary for understanding the coherence between immunologic alterations and endometriosis establishment. Additionally, it still remains an open question whether solely anti-inflammatory approaches without any additional characteristics or a combination of anti-inflammatory and anti-angiogenetic drugs are the most potent treatment for endometriosis.

Immune suppression has no effect on lesion size and overall disease burden

The present work demonstrates that pre-existing peritoneal inflammation influences the establishment of endometriosis. Consequently, it was investigated whether the inverse situation, induction of endometriosis in pre-immunosuppressed mice, might also have an impact on lesion establishment.

To suppress the immune system, cycling mice were treated with the glucocorticoid (GC) prednisolone to evaluate the immunosuppressive effect on the organism (Baxter and Harris, 1975). This approach resulted in significant thymus and spleen atrophy and loss of body weight (3.4.1). Additionally, as reported previously (Celada *et al.*, 1993; Dennis and Mond, 1986), the percentage of MHC-II-expressing monocytes in blood from prednisolone-treated mice was decreased (Figure 26). Peritoneal lavages were performed in prednisolone- and vehicle-treated mice to analyse peritoneal immune cells by FACS analysis, which had not been reported before. A significantly lower level of NK cells in prednisolone-treated mice (Figure 27) was detected. These results are in line with recent data, illustrating that methylprednisolone impairs NK cell proliferation and survival *in vitro* (Chiossone *et al.*, 2007). Since FACS analysis of other peritoneal innate immune cells did not show any differences and cell counts did not differ from controls, prednisolone might not have an impact on cell proliferation, viability or migration of murine peritoneal macrophages or granulocytes in this experiment.

Endometriosis was induced in immunosuppressed mice by injection of EGFP-expressing endometrial fragments (1.2.2.1). After induction, mice were continuously treated with prednisolone or vehicle for another 10 days, then the experiment was terminated. No significant differences could be detected in take rate, lesion size and overall disease burden (3.4.3) in prednisolone-treated mice compared to controls. Thus, immune suppression with prednisolone seems to have no effect on lesion establishment in endometriosis.

Other immunosuppressive agents like sirolimus (Rapamycin; macrocyclic lactone from the bacterium *Streptomyces hygroscopicus*) could have also been used instead of GCs. Sirolimus successfully reduced lesion growth in the dorsal-skinfold-chamber endometriosis model. However, it is assumed to act through its anti-angiogenic and anti-proliferative properties, not through anti-inflammatory effects (Laschke *et al.*, 2006a). Moreover, a local immune suppression, e. g. depletion of distinct immune cell populations with antibodies, might be preferable to examine the effect of certain immune cells on lesion establishment in the peritoneal cavity. Other approaches involving immunodeficient mice are heterologous endometriosis models (1.2.2.1). These animals received human endometrial tissue to investigate fragment growth under different treatments. However, the aim of these studies

was to demonstrate an effective adherence of human tissue, not to investigate the impact of a deficient murine immune system. Apparently, the lack of distinct immune cells does not interfere with lesion establishment.

GCs are frequently used to enable transplantation and to facilitate the adherence of grafts in humans and animals (Wennberg *et al.*, 2001). Hence, it was assumed that immune suppression would increase lesion establishment. Since this was not the case in the present study, GCs may possibly have no effect on adherence of grafts in syngeneic organ transplantation models. Long-term GC therapy, as it is the case in transplantation medicine, leads to suppression of Th1-mediated cellular immunity and a shift towards Th2-mediated response (Elenkov *et al.*, 1999). Interestingly, treatment with IL-12, which provokes a shift towards Th1 immune response, resulted in reduced lesion establishment in a mouse injection model (Somigliana *et al.*, 1999). Since GC treatment did not demonstrate any effect on endometriosis establishment, the shift towards Th2 response does not seem to be a major factor influencing the pathophysiology of endometriosis. Further characteristics of GC treatment include decreased transcription of pro-inflammatory parameters such as cytokines (e.g. IL-1, IL-6, TNF- α), chemokines (e.g. IL-8, RANTES, MIP-1 α , MCP-1) and COX-2 (Barnes, 2001). However, the influence of GCs on the immune system in this *in vivo* model did not measurably affect endometriosis establishment.

Another aspect underlining a potential ineffectiveness of prednisolone-treatment in this study can be identified when examining the role of macrophages. GC treatment leads to a decrease in phagocytic capacity, chemotactic ability and accumulation of peritoneal macrophages *in vitro* (Nagaoka *et al.*, 1988). If macrophage activity might indeed be impaired by prednisolone, the lesion take rate should have been higher in prednisolone-treated mice, because the macrophages would no longer interfere with lesion establishment by phagocytosis and oxidative burst. Such was not the case, thus the effect of prednisolone on macrophages in this experiment seemed to be too low or did not exist at all. However, Nagaoka *et al.* (1988) performed their experiments with peritoneal macrophages derived from concanavalin A-induced peritonitis, thus were working with a different setting of cells. Nevertheless, the results indicate a potential ineffectiveness of prednisolone-treatment in this mouse model.

The fact that an altered immune system can indeed influence endometriosis establishment has been already demonstrated in the present thesis (3.3.1). TM injection induced an acute peritonitis with significantly increased levels of macrophages, granulocytes and NK cells (Figure 21). Subsequent induction of endometriosis in the inflamed peritoneal cavity resulted in decreased endometriosis establishment (3.3.3). Prednisolone treatment in turn only resulted in decreased NK cell numbers (Figure 27) and did not influence other peritoneal immune cell populations. Altered NK cell function is assumed to be involved in the

pathophysiology of endometriosis and decreased activity and cytotoxicity of NK cells was detected in PF of human patients (Ho *et al.*, 1995; Oosterlynck *et al.*, 1991; Oosterlynck *et al.*, 1992). However, the detected NK cell decrease after prednisolone-treatment might not be enough to interfere with endometriosis establishment.

After induction of endometriosis, treatment with prednisolone was continued, thus could not only be regarded as immunosuppressive agent, but also as medication for endometriosis. GCs are frequently applied as therapeutics in inflammatory, allergic or autoimmune diseases like asthma and rheumatoid arthritis. In the present mouse model, no difference in lesion size or take rate could be demonstrated in prednisolone-treated mice compared to controls after 10 days of treatment. Thus, GC-induced systemic immune suppression seems to have no therapeutic effect on endometriosis. This observation is underlined by another experiment in a primate endometriosis model, where treatment with methylprednisolone actually resulted in an increase of endometriosis in baboons. Primates with spontaneous endometriosis had a higher number and increased size of lesions following 3 months of daily GC injection, whereas baboons with induced endometriosis showed no difference (D'Hooghe *et al.*, 1995a). Besides, GCs have a broad spectrum of side effects including skin atrophy, central obesity, proteolysis, anovulation and osteoporosis (Janeway *et al.*, 2005). Thus, based on the present data and the above discussed studies, GCs are not recommended for endometriosis therapy.

In summary, GCs seemed to be the best characterised compounds for immune suppression which had not yet been used in endometriosis mouse models; therefore they were chosen to systemically suppress the immune response of recipient mice in the endometriosis injection model. However, immune suppression with prednisolone did not show any effect on endometriosis establishment. Various reasons may account for the lack of GC therapy effectiveness, some of which include the short administration time of 7 days before endometriosis induction or an inefficient dosage. Alternatively, the immune cells affected by prednisolone-treatment may not be involved in endometriosis establishment.

4.4 Peritoneal inflammation in patients: Cause or consequence of endometriosis?

The altered immune system observed in the peritoneal cavity of endometriosis patients still lacks a detailed explanation and raises an interesting question: Is endometriosis a cause or consequence of this modified immunological environment?

On the one hand, endometriosis may be the consequence of the altered immune system. A congenital or acquired defect in the immune “disposal” system might lead to or at least favour lesion establishment (Dmowski *et al.*, 1994). There is evidence that in healthy women

misplaced endometrial cells are eliminated from the ectopic locations and do not implant (Dmowski *et al.*, 1994; Koninckx *et al.*, 1999a; Lebovic *et al.*, 2001). Thus a defect in the immune system might be a plausible cause for endometriosis establishment. According to this theory, endometriosis is the consequence of an altered function of the immune system. Findings of Haney *et al.* (1991) support this hypothesis by stating that endometrial fragments do not induce peritoneal inflammation. They examined the correlation between the extent of endometriosis (according to the ARSM classification and separate scores like ovarian implants and peritoneal adhesions) and PF volume and numbers of intraperitoneal inflammatory cells. They did not find a significant relationship and concluded, that menstrual tissue fragments are probably not a major factor leading to peritoneal inflammation (Haney *et al.*, 1991). In another experiment conducted in baboons, D'Hooghe *et al.* (1996b) investigated inflammatory parameters such as white blood cell concentration and percentage of macrophages and CD8⁺ lymphocytes in PF. They demonstrated that these parameters were only significantly elevated in baboons with spontaneous endometriosis, not in animals with induced disease, suggesting that alterations of white blood cell populations in PF may lead to the development of endometriosis.

Alternatively, endometriosis may be the consequence of a pre-existing peritoneal inflammation and lesion formation being favoured in the setting of an inflammatory environment. However, the results of the present work disagree with this theory as a pre-existing peritoneal inflammation did not increase lesion establishment in a mouse model of endometriosis and the immunological factors altered by this TM-induced peritonitis did not influence adherence, respectively (3.3.3).

On the other hand, endometriosis might cause immunological alterations in patients. D'Hooghe *et al.* (2001) demonstrated in baboons that during the menstrual phase the intra-peritoneal leukocyte concentration as well as the proportion of peritoneal cells positive for TNF- α and ICAM-1 were significantly increased compared to nonmenstrual phases. In another experiment the same outcome was detected after injecting autologous endometrial fragments in the peritoneal cavity of baboons. Thus, the authors concluded that a subclinical inflammation occurs during menstruation and after endometrium injection (D'Hooghe *et al.*, 2001), suggesting that endometriosis might be the cause of peritoneal inflammation. Furthermore, a study conducted in mice demonstrated that 4 h to 72 h after i.p. injection of mouse endometrial epithelial and stromal cells the number of peritoneal macrophages and production of MCP-1, IL-1 α and IL-6 increased (Cao *et al.*, 2004). The results of the present study also confirm these findings. Injection of EGFP-expressing endometrium fragments resulted in a peritoneal inflammation, indicated by significantly increased numbers of peritoneal immune cells and elevated levels of pro-inflammatory cytokines in the peritoneal

fluid (3.2.2). This inflammatory situation was detected as early as 24 h following endometriosis induction and persisted also 10 days later.

Taken together, there is evidence that peritoneal inflammation may be a consequence of rather than a cause for endometriosis in the presented mouse model, keeping in mind that species-specific effects may play a role as well. Future therapeutic strategies to ameliorate the inflammatory reaction associated with endometriosis should target potentially pathologically-acting inflammatory proteins and molecules, but should not ignore their likely physiological actions on normal eutopic endometrial function.

5 Conclusion and Outlook

In the present thesis, two mouse models for endometriosis were successfully established and evaluated and advantages and disadvantages of each model were determined. The transplantation model and the injection model are both suitable for endometriosis research and for testing of new therapeutic approaches. The transplantation model seems to be more useful for anti-hormonal therapies whereas the injection model shows greater advantages when testing establishment of lesions.

Furthermore, tissue reorganisation and angiogenic processes in developing lesions were shown over time in the injection model, underlining the suitability of the model due to the high analogy to human lesions. Additionally it was demonstrated that the injection of endometrium induced a peritoneal inflammation, still persisting after 10 days.

Finally, a deeper knowledge about the involvement of the immune system in endometriosis establishment was gained. A pre-existing peritoneal inflammation decreases endometriosis, thereby additionally answering the question if endometriosis is cause or consequence of the altered inflammatory environment. Moreover, a suppressed immune system due to prednisolone treatment did not show any influence on lesion establishment.

For future research it should be considered that the inflammatory peritoneal environment in the patient might not be an acute inflammation, but a chronic situation. Therefore, investigation of the impact of a chronic peritoneal inflammation would be an important contribution to the field of endometriosis research.

Moreover, the systemic immune suppression approach via prednisolone might not be sufficient to exclude any influence of a deficient immune system. Further experiments have to be conducted with special focus on distinct cell populations, whether depletion via antibodies or experiments with knock-out mice, to examine the role of single factors in endometriosis establishment. In addition, the approaches could be used conversely to increase single factors, cell populations or proteins to provide a deeper insight into establishment processes in endometriosis.

6 Summary / Zusammenfassung

Endometriosis is a common gynaecological disease, affecting around 10 % of women in reproductive age. It is characterised by the presence of endometrial tissue fragments outside the uterine cavity, the so called endometriotic lesions, which grow in an estrogen-dependent manner. The major symptoms like severe chronic pain, dysmenorrhea and decreased fertility have a deep impact on the quality of the women's lives. Current therapies result in pain release and amelioration of life conditions, but the recurrence rate is very high. Thus, there is an urgent need for new, more effective therapeutics.

Due to ethical concerns, drug discovery cannot be conducted in humans. Non-human primates like the baboon, which menstruate and develop endometriosis spontaneously, are the best model system. However, high costs, long time periods until endometriosis occurs and ethical considerations limit the use of these animals. Mouse models are an alternative to examine endometriosis establishment and subsequently to test new therapeutical approaches, albeit their reproductive cycle is different.

In the present work, two different endometriosis mouse models were established and evaluated to demonstrate their usability for endometriosis research and drug discovery. The first endometriosis model was an autologous transplantation model where uterus biopsies were sutured onto peritoneum and intestine mesenteries. Histological analysis revealed that the developed lesions resembled human endometriotic lesions. Additionally, the lesions demonstrated estrogen dependency by decreased lesion size after treatment with an anti-estrogen. Thus, the transplantation model is suitable for investigating anti-hormonal therapeutic approaches.

The second endometriosis mouse model presented in this study was induced by intraperitoneal injection of enhanced green fluorescent protein-expressing endometrium fragments (EGFP). The developed lesions could be easily detected using a fluorescence microscope and revealed histological similarities with human lesions, thus making this model applicable for endometriosis research. Furthermore, a time course experiment demonstrated that the lesions underlay tissue reorganisation and angiogenic processes were visible which varied over time.

In the pathophysiology of endometriosis, one important aspect is the role of the immune system, even though its exact impact still remains enigmatic. In the present study, both models were investigated particularly with regard to inflammatory events in the peritoneal cavity. No differences could be demonstrated for the transplantation model compared to

sham-operated and untreated controls. However, in the injection model increased inflammatory parameters could be detected 24 h, 72 h and even 10 days after endometriosis induction. Thus, the induction of endometriosis provoked a peritoneal inflammation in the injection model.

Furthermore, the injection model was used to examine the impact of an altered immune system on endometriosis establishment. Endometriosis was induced on the one hand in a pre-inflamed peritoneal cavity and on the other hand in immunosuppressed animals. Induction of endometriosis in a pre-inflamed peritoneal cavity resulted in fewer lesions and significantly lower disease burden per mouse. Thus, a pre-existing peritoneal inflammation might not be a factor favouring the development of endometriosis. By contrast, a suppressed immune system had no significant impact on lesion number and size. In summary, the injection model can be used to investigate establishment of lesions and potentially attachment-interfering agents.

Zusammenfassung

Endometriose ist eine häufig auftretende gynäkologische Erkrankung. Von ihr betroffen sind etwa 10 % aller Frauen im reproduktiven Alter. Die Krankheit wird charakterisiert durch das Vorhandensein von endometrialen Gewebsfragmenten außerhalb der Uterushöhle, den sogenannten endometriotischen Läsionen, welche östrogenabhängig wachsen. Die Hauptsymptome wie starker chronischer Schmerz, unregelmäßige Blutungen und herabgesetzte Fruchtbarkeit haben einen großen Einfluss auf die Lebensqualität der erkrankten Frauen. Die aktuell angewendeten Therapien reduzieren die Schmerzsymptomatik und verbessern die Lebensbedingungen, aber die Rückkehr der Erkrankung nach Absetzen der Medikamente ist hoch. Daher werden neue, effektivere Therapeutika dringend benötigt.

Aufgrund ethischer Richtlinien wird die Erforschung neuer Medikamente nicht am Menschen durchgeführt. Das beste Modellsystem für Endometriose sind momentan Altweltaffen wie z. B. der Pavian, welche menstruieren und spontan Endometriose entwickeln können. Allerdings limitieren hohe Kosten, lange Zeiträume bis zur Entwicklung der Endometriose und ethische Berücksichtigungen die Verwendung dieser Tiere. Obwohl sich der Reproduktionszyklus der Maus von dem des Menschen unterscheidet, sind Mausmodelle eine mögliche Alternative, um die Etablierung der Endometriose zu untersuchen und darauf folgend neue therapeutische Ansätze zu testen,

In der vorliegenden Arbeit wurden zwei verschiedene Mausmodelle für Endometriose etabliert und evaluiert, um ihre Verwendbarkeit für Endometrioseforschung und die Entwicklung neuer

Medikamente zu zeigen. Als erstes wurde ein autologes Transplantationsmodell verwendet, bei welchem Uterusbiopsien auf Peritoneum und Darmmesenterien aufgenäht wurden. Die histologische Analyse ergab, dass die entstandenen murinen Läsionen humanen Läsionen ähneln. Zusätzlich zeigten die Läsionen Östrogenabhängigkeit, da ihre Größe nach Behandlung mit einem Anti-Östrogen abnahm. Folglich scheint das murine Endometriose-Transplantationsmodell geeignet, um anti-hormonelle Therapieansätze zu testen.

Das zweite in dieser Arbeit präsentierte Mausmodell wurde durch intraperitoneale Injektion von „Enhanced green fluorescent protein“ (EGFP)-exprimierenden endometrialen Fragmenten induziert. Die entstandenen Läsionen konnten unter einer Fluoreszenzlupe gut entdeckt und quantifiziert werden und zeigten ebenfalls histologische Ähnlichkeit mit humanen Läsionen. Somit ist das Injektionsmodell für Endometrioseforschung verwendbar. Darüber hinaus zeigte ein Zeitverlauf-Experiment, dass die Läsionen Gewebsreorganisation unterliegen und Angiogeneseprozesse sichtbar sind, welche sich im Verlauf der Zeit verändern.

Eine bedeutende Rolle in der Pathophysiologie der Endometriose spielt das Immunsystem. Allerdings ist sein genauer Einfluss bisher nicht komplett entschlüsselt worden. In der vorliegenden Arbeit wurden beide Modelle besonders unter dem Aspekt der Inflammation in der Peritonealhöhle untersucht. Im Vergleich zu Kontrollen ohne Operation und scheinoperierten Tieren wurden in den Tieren mit transplanteder Endometriose keine Unterschiede in inflammatorischen Parametern gefunden. Im Injektionsmodell dagegen wurden erhöhte inflammatorische Marker 24 Stunden, 72 Stunden und 10 Tage nach Endometriose-Induktion detektiert. Folglich führt die Induktion von Endometriose durch Injektion von endometrialen Fragmenten zu einer peritonealen Entzündung.

Weiterhin wurde das Injektionsmodell verwendet, um den Einfluss eines veränderten Immunsystems auf die Etablierung der Endometriose zu untersuchen. Endometriose wurde zum Einen in einer entzündeten Peritonealhöhle und zum Anderen in immunsupprimierten Tieren induziert. Herbeiführen der Endometriose in einer entzündeten Peritonealhöhle resultierte in geringeren Läsionszahlen und einer signifikant geringeren Krankheitsbelastung pro Tier. Daher scheint eine bereits bestehende peritoneale Inflammation kein krankheitsfördernder Faktor der Endometriose zu sein. Konträr zu diesen Ergebnissen hatte das suppressierte Immunsystem keinen signifikanten Einfluss auf Läsionsanzahl und -größe. Zusammenfassend ist festzustellen, dass das Injektionsmodell für die Untersuchung von Läsionsetablierung und möglichen adhäsionsvermindernden therapeutischen Agenzien sehr geeignet ist.

7 References

- Abbott J, Hawe J, Hunter D, Holmes M, Finn P, Garry R (2004) Laparoscopic excision of endometriosis: a randomized, placebo-controlled trial. *Fertil Steril* 82: 878-884
- Ailawadi RK, Jobanputra S, Kataria M, Gurates B, Bulun SE (2004) Treatment of endometriosis and chronic pelvic pain with letrozole and norethindrone acetate: a pilot study. *Fertil Steril* 81: 290-296
- Alborzi S, Ghotbi S, Parsanezhad ME, Dehbashi S, Alborzi S, Alborzi M (2007) Pentoxifylline therapy after laparoscopic surgery for different stages of endometriosis: a prospective, double-blind, randomized, placebo-controlled study. *J Minim Invasive Gynecol* 14: 54-58
- Aoki D, Katsuki Y, Shimizu A, Kakinuma C, Nozawa S (1994) Successful heterotransplantation of human endometrium in SCID mice. *Obstet Gynecol* 83: 220-228
- Argyris BF (1967) Role of macrophages in antibody production. Immune response to sheep red blood cells. *J Immunol* 99: 744-750
- Arici A, Seli E, Zeyneloglu HB, Senturk LM, Oral E, Olive DL (1998) Interleukin-8 induces proliferation of endometrial stromal cells: a potential autocrine growth factor. *J Clin Endocrinol Metab* 83: 1201-1205
- ASRM (1997) Revised American Society for Reproductive Medicine classification of endometriosis: 1996. *Fertil Steril* 67: 817-821
- ASRM (2004) Endometriosis and infertility. *Fertil Steril* 82 Suppl 1: S40-45
- Attar E, Bulun SE (2006) Aromatase and other steroidogenic genes in endometriosis: translational aspects. *Hum Reprod Update* 12: 49-56
- Barnes PJ (2001) Molecular mechanisms of corticosteroids in allergic diseases. *Allergy* 56: 928-936
- Batt RE, Smith RA, Buck Louis GM, Martin DC, Chapron C, Koninckx PR, Yeh J (2007) Mullerianosis. *Histol Histopathol* 22: 1161-1166
- Baxter JD, Harris AW (1975) Mechanism of glucocorticoid action: general features, with reference to steroid-mediated immunosuppression. *Transplant Proc* 7: 55-65
- Becker CM, D'Amato RJ (2007) Angiogenesis and antiangiogenic therapy in endometriosis. *Microvasc Res* 74: 121-130
- Becker CM, Rohwer N, Funakoshi T, Cramer T, Bernhardt W, Birsner A, Folkman J, D'Amato RJ (2008) 2-methoxyestradiol inhibits hypoxia-inducible factor-1 α and suppresses growth of lesions in a mouse model of endometriosis. *Am J Pathol* 172: 534-544
- Becker CM, Sampson DA, Rupnick MA, Rohan RM, Efstathiou JA, Short SM, Taylor GA, Folkman J, D'Amato RJ (2005) Endostatin inhibits the growth of endometriotic lesions but does not affect fertility. *Fertil Steril* 84 Suppl 2: 1144-1155
- Becker CM, Wright RD, Satchi-Fainaro R, Funakoshi T, Folkman J, Kung AL, D'Amato RJ (2006) A novel noninvasive model of endometriosis for monitoring the efficacy of antiangiogenic therapy. *Am J Pathol* 168: 2074-2084
- Bergqvist A (1992) Extragenital endometriosis. A review. *Eur J Surg* 158: 7-12
- Brahimi-Horn MC, Chiche J, Pouyssegur J (2007) Hypoxia and cancer. *J Mol Med* 85: 1301-1307
- Braun DP, Ding J, Dmowski WP (2002) Peritoneal fluid-mediated enhancement of eutopic and ectopic endometrial cell proliferation is dependent on tumor necrosis factor- α in women with endometriosis. *Fertil Steril* 78: 727-732
- Brodie AM (1979) Recent advances in studies on estrogen biosynthesis. *J Endocrinol Invest* 2: 445-460
- Brunda MJ (1994) Interleukin-12. *J Leukoc Biol* 55: 280-288
- Bruner-Tran KL, Eisenberg E, Yeaman GR, Anderson TA, McBean J, Osteen KG (2002) Steroid and cytokine regulation of matrix metalloproteinase expression in endometriosis and the establishment of experimental endometriosis in nude mice. *J Clin Endocrinol Metab* 87: 4782-4791

7 References

- Bruner KL, Matrisian LM, Rodgers WH, Gorstein F, Osteen KG (1997) Suppression of matrix metalloproteinases inhibits establishment of ectopic lesions by human endometrium in nude mice. *J Clin Invest* 99: 2851-2857
- Bulun SE, Zeitoun K, Takayama K, Noble L, Michael D, Simpson E, Johns A, Putman M, Sasano H (1999) Estrogen production in endometriosis and use of aromatase inhibitors to treat endometriosis. *Endocr Relat Cancer* 6: 293-301
- Cao X, Yang D, Song M, Murphy A, Parthasarathy S (2004) The presence of endometrial cells in the peritoneal cavity enhances monocyte recruitment and induces inflammatory cytokines in mice: implications for endometriosis. *Fertil Steril* 82 Suppl 3: 999-1007
- Celada A, McKercher S, Maki RA (1993) Repression of major histocompatibility complex IA expression by glucocorticoids: the glucocorticoid receptor inhibits the DNA binding of the X box DNA binding protein. *J Exp Med* 177: 691-698
- Child TJ, Tan SL (2001) Endometriosis: aetiology, pathogenesis and treatment. *Drugs* 61: 1735-1750
- Chiossone L, Vitale C, Cottalasso F, Moretti S, Azzarone B, Moretta L, Mingari MC (2007) Molecular analysis of the methylprednisolone-mediated inhibition of NK-cell function: evidence for different susceptibility of IL-2- versus IL-15-activated NK cells. *Blood* 109: 3767-3775
- Christodoulakos G, Augoulea A, Lambrinoudaki I, Sioulas V, Creatsas G (2007) Pathogenesis of endometriosis: The role of defective 'immunosurveillance'. *Eur J Contracept Reprod Health Care* 12: 194 - 202
- Cobellis L, Razzi S, De Simone S, Sartini A, Fava A, Danero S, Gioffre W, Mazzini M, Petraglia F (2004) The treatment with a COX-2 specific inhibitor is effective in the management of pain related to endometriosis. *Eur J Obstet Gynecol Reprod Biol* 116: 100-102
- Cook AD, Braine EL, Hamilton JA (2003) The phenotype of inflammatory macrophages is stimulus dependent: implications for the nature of the inflammatory response. *J Immunol* 171: 4816-4823
- Cullinan-Bove K, Koos RD (1993) Vascular endothelial growth factor/vascular permeability factor expression in the rat uterus: rapid stimulation by estrogen correlates with estrogen-induced increases in uterine capillary permeability and growth. *Endocrinology* 133: 829-837
- Cummings AM, Metcalf JL (1995) Induction of endometriosis in mice: a new model sensitive to estrogen. *Reprod Toxicol* 9: 233-238
- Cummings AM, Metcalf JL (1996) Effect of surgically induced endometriosis on pregnancy and effect of pregnancy and lactation on endometriosis in mice. *Proc Soc Exp Biol Med* 212: 332-337
- Cummings AM, Metcalf JL, Birnbaum L (1996) Promotion of endometriosis by 2,3,7,8-tetrachlorodibenzo-p-dioxin in rats and mice: time-dose dependence and species comparison. *Toxicol Appl Pharmacol* 138: 131-139
- D'Antonio M, Martelli F, Peano S, Papoian R, Borrelli F (2000) Ability of recombinant human TNF binding protein-1 (r-hTBP-1) to inhibit the development of experimentally-induced endometriosis in rats. *J Reprod Immunol* 48: 81-98
- D'Hooghe TM, Bambra CS, Cornillie FJ, Isahakia M, Koninckx PR (1991) Prevalence and laparoscopic appearance of spontaneous endometriosis in the baboon (*Papio anubis*, *Papio cynocephalus*). *Biol Reprod* 45: 411-416
- D'Hooghe TM, Bambra CS, Isahakia M, Koninckx PR (1992) Evolution of spontaneous endometriosis in the baboon (*Papio anubis*, *Papio cynocephalus*) over a 12-month period. *Fertil Steril* 58: 409-412
- D'Hooghe TM, Bambra CS, Raeymaekers BM, De Jonge I, Hill JA, Koninckx PR (1995a) The effects of immunosuppression on development and progression of endometriosis in baboons (*Papio anubis*). *Fertil Steril* 64: 172-178
- D'Hooghe TM, Bambra CS, Raeymaekers BM, De Jonge I, Lauweryns JM, Koninckx PR (1995b) Intrapelvic injection of menstrual endometrium causes endometriosis in baboons (*Papio cynocephalus* and *Papio anubis*). *Am J Obstet Gynecol* 173: 125-134
- D'Hooghe TM, Bambra CS, Raeymaekers BM, Hill JA (1999) Pelvic inflammation induced by diagnostic laparoscopy in baboons. *Fertil Steril* 72: 1134-1141

7 References

- D'Hooghe TM, Bambra CS, Raeymaekers BM, Koninckx PR (1996a) Serial laparoscopies over 30 months show that endometriosis in captive baboons (*Papio anubis*, *Papio cynocephalus*) is a progressive disease. *Fertil Steril* 65: 645-649
- D'Hooghe TM, Bambra CS, Xiao L, Peixe K, Hill JA (2001) Effect of menstruation and intrapelvic injection of endometrium on inflammatory parameters of peritoneal fluid in the baboon (*Papio anubis* and *Papio cynocephalus*). *Am J Obstet Gynecol* 184: 917-925
- D'Hooghe TM, Debrock S, Hill JA, Meuleman C (2003) Endometriosis and subfertility: is the relationship resolved? *Semin Reprod Med* 21: 243-254
- D'Hooghe TM, Hill JA, Oosterlynck DJ, Koninckx PR, Bambra CS (1996b) Effect of endometriosis on white blood cell subpopulations in peripheral blood and peritoneal fluid of baboons. *Hum Reprod* 11: 1736-1740
- D'Hooghe TM, Nugent NP, Cuneo S, Chai DC, Deer F, Debrock S, Kyama CM, Mihalyi A, Mwenda JM (2006) Recombinant human TNFRSF1A (r-hTBP1) inhibits the development of endometriosis in baboons: a prospective, randomized, placebo- and drug-controlled study. *Biol Reprod* 74: 131-136
- Den Otter W, De Groot JW, Van Basten CD, Rademakers LH, De Weger RA, Pels E (1982) Brewer thioglycollate medium induces different exudates in guinea pigs and mice. *Exp Mol Pathol* 36: 403-413
- Dennis GJ, Mond JJ (1986) Corticosteroid-induced suppression of murine B cell immune response antigens. *J Immunol* 136: 1600-1604
- Dmowski WP, Gebel HM, Braun DP (1994) The role of cell-mediated immunity in pathogenesis of endometriosis. *Acta Obstet Gynecol Scand Suppl* 159: 7-14
- Donnez J, Smoes P, Gillerot S, Casanas-Roux F, Nisolle M (1998) Vascular endothelial growth factor (VEGF) in endometriosis. *Hum Reprod* 13: 1686-1690
- Donnez J, Squifflet J, Casanas-Roux F, Pirard C, Jadoul P, Van Langendonck A (2003) Typical and subtle atypical presentations of endometriosis. *Obstet Gynecol Clin North Am* 30: 83-93, viii
- Ebert AD, Bartley J, David M (2005) Aromatase inhibitors and cyclooxygenase-2 (COX-2) inhibitors in endometriosis: new questions--old answers? *Eur J Obstet Gynecol Reprod Biol* 122: 144-150
- Efstathiou JA, Sampson DA, Levine Z, Rohan RM, Zurakowski D, Folkman J, D'Amato RJ, Rupnick MA (2005) Nonsteroidal antiinflammatory drugs differentially suppress endometriosis in a murine model. *Fertil Steril* 83: 171-181
- Eggermont J, Donnez J, Casanas-Roux F, Scholtes H, Van Langendonck A (2005) Time course of pelvic endometriotic lesion revascularization in a nude mouse model. *Fertil Steril* 84: 492-499
- Elenkov IJ, Webster EL, Torpy DJ, Chrousos GP (1999) Stress, corticotropin-releasing hormone, glucocorticoids, and the immune/inflammatory response: acute and chronic effects. *Ann N Y Acad Sci* 876: 1-11; discussion 11-13
- Erickson LD, Ory SJ (1989) GnRH analogues in the treatment of endometriosis. *Obstet Gynecol Clin North Am* 16: 123-145
- Fazleabas AT, Brudney A, Gurates B, Chai D, Bulun S (2002) A modified baboon model for endometriosis. *Ann N Y Acad Sci* 955: 308-317; discussion 340-302, 396-406
- Fujimoto A, Onodera H, Mori A, Isobe N, Yasuda S, Oe H, Yonenaga Y, Tachibana T, Imamura M (2004) Vascular endothelial growth factor reduces mural cell coverage of endothelial cells and induces sprouting rather than luminal division in an HT1080 tumour angiogenesis model. *Int J Exp Pathol* 85: 355-364
- Fujishita A, Hasuo A, Khan KN, Masuzaki H, Nakashima H, Ishimaru T (1999) Immunohistochemical study of angiogenic factors in endometrium and endometriosis. *Gynecol Obstet Invest* 48 Suppl 1: 36-44
- Garai J, Molnar V, Varga T, Koppan M, Torok A, Bodis J (2006) Endometriosis: harmful survival of an ectopic tissue. *Front Biosci* 11: 595-619
- Garcia-Velasco JA, Arici A (1999) Interleukin-8 stimulates the adhesion of endometrial stromal cells to fibronectin. *Fertil Steril* 72: 336-340
- Ghezzi F, Raio L, Cromi A, Duwe DG, Beretta P, Buttarelli M, Mueller MD (2005) "Kissing ovaries": A sonographic sign of moderate to severe endometriosis. *Fertil Steril* 83: 143-147

7 References

- Giannarini G, Scott CA, Moro U, Grossetti B, Pomara G, Selli C (2006) Cystic endometriosis of the epididymis. *Urology* 68: 203.e201-203.e203
- Golan A, Winston RM, Dargenio R (1984) Experimental endometriosis: a microsurgical animal model in rats. *Isr J Med Sci* 20: 1094-1096
- Greenberg LH, Slayden OD (2004) Human endometriotic xenografts in immunodeficient RAG-2/gamma(c)KO mice. *Am J Obstet Gynecol* 190: 1788-1795; discussion 1795-1786
- Griesinger G, Felberbaum R, Diedrich K (2005) GnRH-antagonists in reproductive medicine. *Arch Gynecol Obstet* 273: 71-78
- Groothuis PG, Nap AW, Winterhager E, Grummer R (2005) Vascular development in endometriosis. *Angiogenesis* 8: 147-156
- Gruemmer R (2006) Animal models in endometriosis research. *Hum Reprod Update* 12: 641-649
- Grummer R, Schwarzer F, Bainczyk K, Hess-Stumpp H, Regidor PA, Schindler AE, Winterhager E (2001) Peritoneal endometriosis: validation of an in-vivo model. *Hum Reprod* 16: 1736-1743
- Halme J, Hammond MG, Hulka JF, Raj SG, Talbert LM (1984) Retrograde menstruation in healthy women and in patients with endometriosis. *Obstet Gynecol* 64: 151-154
- Haney AF, Jenkins S, Weinberg JB (1991) The stimulus responsible for the peritoneal fluid inflammation observed in infertile women with endometriosis. *Fertil Steril* 56: 408-413
- Harada T, Enatsu A, Mitsunari M, Nagano Y, Ito M, Tsudo T, Taniguchi F, Iwabe T, Tanikawa M, Terakawa N (1999) Role of cytokines in progression of endometriosis. *Gynecol Obstet Invest* 47 Suppl 1: 34-39; discussion 39-40
- Harada T, Iwabe T, Terakawa N (2001) Role of cytokines in endometriosis. *Fertil Steril* 76: 1-10
- Harris HA, Bruner-Tran KL, Zhang X, Osteen KG, Lyttle CR (2005) A selective estrogen receptor-beta agonist causes lesion regression in an experimentally induced model of endometriosis. *Hum Reprod* 20: 936-941
- Hirata T, Osuga Y, Yoshino O, Hirota Y, Harada M, Takemura Y, Morimoto C, Koga K, Yano T, Tsutsumi O, Taketani Y (2005) Development of an experimental model of endometriosis using mice that ubiquitously express green fluorescent protein. *Hum Reprod* 20: 2092-2096
- Ho HN, Chao KH, Chen HF, Wu MY, Yang YS, Lee TY (1995) Peritoneal natural killer cytotoxicity and CD25+ CD3+ lymphocyte subpopulation are decreased in women with stage III-IV endometriosis. *Hum Reprod* 10: 2671-2675
- Hochman JS, Shah NR (2006) What price pain relief? *Circulation* 113: 2868-2870
- Hoffmann J, Bohlmann R, Heinrich N, Hofmeister H, Kroll J, Kunzer H, Lichtner RB, Nishino Y, Parczyk K, Sauer G, Gieschen H, Ulbrich HF, Schneider MR (2004) Characterization of new estrogen receptor destabilizing compounds: effects on estrogen-sensitive and tamoxifen-resistant breast cancer. *J Natl Cancer Inst* 96: 210-218
- Houston KD, Copland JA, Broaddus RR, Gottardis MM, Fischer SM, Walker CL (2003) Inhibition of proliferation and estrogen receptor signaling by peroxisome proliferator-activated receptor gamma ligands in uterine leiomyoma. *Cancer Res* 63: 1221-1227
- Hrabak A, Bajor T, Csuka I (2006) The effect of various inflammatory agents on the alternative metabolic pathways of arginine in mouse and rat macrophages. *Inflamm Res* 55: 23-31
- Hudelist G, Lass H, Keckstein J, Walter I, Wieser F, Wenzl R, Mueller R, Czerwenka K, Kubista E, Singer CF (2005) Interleukin 1alpha and tissue-lytic matrix metalloproteinase-1 are elevated in ectopic endometrium of patients with endometriosis. *Hum Reprod* 20: 1695-1701
- Hull ML, Charnock-Jones DS, Chan CL, Bruner-Tran KL, Osteen KG, Tom BD, Fan TP, Smith SK (2003) Antiangiogenic agents are effective inhibitors of endometriosis. *J Clin Endocrinol Metab* 88: 2889-2899
- Hull ML, Prentice A, Wang DY, Butt RP, Phillips SC, Smith SK, Charnock-Jones DS (2005) Nimesulide, a COX-2 inhibitor, does not reduce lesion size or number in a nude mouse model of endometriosis. *Hum Reprod* 20: 350-358
- Hunt JS, Chen HL, Hu XL, Tabibzadeh S (1992) Tumor necrosis factor-alpha messenger ribonucleic acid and protein in human endometrium. *Biol Reprod* 47: 141-147

7 References

- Hyder SM, Nawaz Z, Chiappetta C, Stancel GM (2000) Identification of functional estrogen response elements in the gene coding for the potent angiogenic factor vascular endothelial growth factor. *Cancer Res* 60: 3183-3190
- Itil IM, Cirpan T, Akercan F, Gamaa A, Kazandi M, Kazandi AC, Yildiz PS, Askar N (2006) Effect of BCG vaccine on peritoneal endometriotic implants in a rat model of endometriosis. *Aust N Z J Obstet Gynaecol* 46: 38-41
- Janeway C, Travers P, Walport M, Shlomchik M (2005) *Immunobiology*. 6th edn. Garland Science Publishing. New York, USA
- Jänne O, Kauppila A, Kokko E, Lanto T, Rönnerberg L, Vihko R (1981) Estrogen and progestin receptors in endometriosis lesions: comparison with endometrial tissue. *Am J Obstet Gynaecol* 141: 562-566
- Jenkins S, Olive DL, Haney AF (1986) Endometriosis: pathogenetic implications of the anatomic distribution. *Obstet Gynecol* 67: 335-338
- Jiang C, Ting AT, Seed B (1998) PPAR-gamma agonists inhibit production of monocyte inflammatory cytokines. *Nature* 391: 82-86
- Kalu E, Sumar N, Giannopoulos T, Patel P, Croucher C, Sherriff E, Bansal A (2007) Cytokine profiles in serum and peritoneal fluid from infertile women with and without endometriosis. *J Obstet Gynaecol Res* 33: 490-495
- Kamencic H, Thiel JA (2008) Pentoxifylline after conservative surgery for endometriosis: a randomized, controlled trial. *J Minim Invasive Gynecol* 15: 62-66
- Katsuki Y, Takano Y, Futamura Y, Shibutani Y, Aoki D, Udagawa Y, Nozawa S (1998) Effects of dienogest, a synthetic steroid, on experimental endometriosis in rats. *Eur J Endocrinol* 138: 216-226
- Kitawaki J, Kado N, Ishihara H, Koshiba H, Kitaoka Y, Honjo H (2002) Endometriosis: the pathophysiology as an estrogen-dependent disease. *J Steroid Biochem Mol Biol* 83: 149-155
- Klauber N, Rohan RM, Flynn E, D'Amato RJ (1997) Critical components of the female reproductive pathway are suppressed by the angiogenesis inhibitor AGM-1470. *Nat Med* 3: 443-446
- Klemmt PAB, Carver JG, Koninckx P, McVeigh EJ, Mardon HJ (2007) Endometrial cells from women with endometriosis have increased adhesion and proliferative capacity in response to extracellular matrix components: towards a mechanistic model for endometriosis progression. *Hum. Reprod.* 22: 3139-3147
- Koninckx PR, Barlow D, Kennedy S (1999a) Implantation versus infiltration: the Sampson versus the endometriotic disease theory. *Gynecol Obstet Invest* 47 Suppl 1: 3-9; discussion 9-10
- Koninckx PR, Kennedy SH, Barlow DH (1999b) Pathogenesis of endometriosis: the role of peritoneal fluid. *Gynecol Obstet Invest* 47 Suppl 1: 23-33
- Kyama CM, Debrock S, Mwenda JM, D'Hooghe TM (2003) Potential involvement of the immune system in the development of endometriosis. *Reprod Biol Endocrinol* 1: 123
- Laschke MW, Elitzsch A, Scheuer C, Holstein JH, Vollmar B, Menger MD (2006a) Rapamycin induces regression of endometriotic lesions by inhibiting neovascularization and cell proliferation. *Br J Pharmacol* 149: 137-144
- Laschke MW, Elitzsch A, Vollmar B, Vajkoczy P, Menger MD (2006b) Combined inhibition of vascular endothelial growth factor (VEGF), fibroblast growth factor and platelet-derived growth factor, but not inhibition of VEGF alone, effectively suppresses angiogenesis and vessel maturation in endometriotic lesions. *Hum Reprod* 21: 262-268
- Laschke MW, Menger MD (2007) In vitro and in vivo approaches to study angiogenesis in the pathophysiology and therapy of endometriosis. *Hum Reprod Update* 13: 331-342
- Lebovic DI (2005) <http://clinicaltrials.gov/show/NCT00115661>.
- Lebovic DI, Bentzien F, Chao VA, Garrett EN, Meng YG, Taylor RN (2000) Induction of an angiogenic phenotype in endometriotic stromal cell cultures by interleukin-1beta. *Mol Hum Reprod* 6: 269-275
- Lebovic DI, Chao VA, Taylor RN (2004) Peritoneal macrophages induce RANTES (regulated on activation, normal T cell expressed and secreted) chemokine gene transcription in endometrial stromal cells. *J Clin Endocrinol Metab* 89: 1397-1401

7 References

- Lebovic DI, Mueller MD, Taylor RN (2001) Immunobiology of endometriosis. *Fertil Steril* 75: 1-10
- Lebovic DI, Mwenda JM, Chai DC, Mueller MD, Santi A, Fisseha S, D'Hooghe T (2007) PPAR-gamma receptor ligand induces regression of endometrial explants in baboons: a prospective, randomized, placebo- and drug-controlled study. *Fertil Steril* 88: 1108-1119
- Leyendecker G, Herbertz M, Kunz G, Mall G (2002) Endometriosis results from the dislocation of basal endometrium. *Hum. Reprod.* 17: 2725-2736
- Leyendecker G, Kunz G (2005) Endometriosis and adenomyosis. *Zentralbl Gynakol* 127: 288-294
- Li YM, Baviello G, Vlassara H, Mitsuhashi T (1997) Glycation products in aged thioglycollate medium enhance the elicitation of peritoneal macrophages. *J Immunol Methods* 201: 183-188
- Lin YJ, Lai MD, Lei HY, Wing LY (2006) Neutrophils and macrophages promote angiogenesis in the early stage of endometriosis in a mouse model. *Endocrinology* 147: 1278-1286
- Loh FH, Bongso A, Fong CY, Koh DR, Lee SH, Zhao HQ (1999) Effects of peritoneal macrophages from women with endometriosis on endometrial cellular proliferation in an in vitro coculture model. *Fertil Steril* 72: 533-538
- MacKenzie WF, Casey HW (1975) Animal model of human disease. Endometriosis. Animal model: endometriosis in rhesus monkeys. *Am J Pathol* 80: 341-344
- Mahutte NG, Arici A (2002) New advances in the understanding of endometriosis related infertility. *J Reprod Immunol* 55: 73-83
- Matalliotakis IM, Cakmak H, Fragouli YG, Goumenou AG, Mahutte NG, Arici A (2007) Epidemiological characteristics in women with and without endometriosis in the Yale series. *Arch Gynecol Obstet*
- Matalliotakis IM, Cakmak H, Fragouli YG, Goumenou AG, Mahutte NG, Arici A (2008) Epidemiological characteristics in women with and without endometriosis in the Yale series. *Arch Gynecol Obstet* 277: 389-393. Epub 2007 Oct 2009.
- Matarese G, Alviggi C, Sanna V, Howard JK, Lord GM, Carravetta C, Fontana S, Lechler RI, Bloom SR, De Placido G (2000) Increased leptin levels in serum and peritoneal fluid of patients with pelvic endometriosis. *J Clin Endocrinol Metab* 85: 2483-2487
- Matsuura K, Ohtake H, Katabuchi H, Okamura H (1999) Coelomic metaplasia theory of endometriosis: evidence from in vivo studies and an in vitro experimental model. *Gynecol Obstet Invest* 47 Suppl 1: 18-20; discussion 20-12
- Matsuzaki S, Murakami T, Uehara S, Canis M, Sasano H, Okamura K (2001) Expression of estrogen receptor alpha and beta in peritoneal and ovarian endometriosis. *Fertil Steril* 75: 1198-1205
- Meyer R (1903) Über eine adenomatöse Wucherung der Serosa in einer Bauchnarbe. *Z Geburtshilfe Gynakol* 49: 32-41
- Mihalyi A, Simsa P, Mutinda KC, Meuleman C, Mwenda JM, D'Hooghe TM (2006) Emerging drugs in endometriosis. *Expert Opin Emerg Drugs* 11: 503-524
- Moen MH, Muus KM (1991) Endometriosis in pregnant and non-pregnant women at tubal sterilization. *Hum Reprod* 6: 699-702
- Montagna P, Capellino S, Villaggio B, Remorgida V, Ragni N, Cutolo M, Ferrero S (2007) Peritoneal fluid macrophages in endometriosis: correlation between the expression of estrogen receptors and inflammation. *Fertil Steril*: In press, Epub ahead of print, 4 June 2007
- Moore RA, Derry S, McQuay HJ (2007) Cyclo-oxygenase-2 selective inhibitors and nonsteroidal anti-inflammatory drugs: balancing gastrointestinal and cardiovascular risk. *BMC Musculoskelet Disord* 8: 73
- Na YJ, Yang SH, Baek DW, Lee DH, Kim KH, Choi YM, Oh ST, Hong YS, Kwak JY, Lee KS (2006) Effects of peritoneal fluid from endometriosis patients on the release of vascular endothelial growth factor by neutrophils and monocytes. *Hum Reprod* 21: 1846-1855
- Nagaoka I, Kaneko H, Yamashita T (1988) Inhibition of the accumulation of macrophages and the generation of macrophage chemotactic activity by dexamethasone in concanavalin A-induced peritonitis of mice. *Agents Actions* 25: 156-163
- Nap AW, Griffioen AW, Dunselman GA, Bouma-Ter Steege JC, Thijssen VL, Evers JL, Groothuis PG (2004) Antiangiogenesis therapy for endometriosis. *J Clin Endocrinol Metab* 89: 1089-1095

7 References

- Nisolle M, Casanas-Roux F, Donnez J (2000) Early-stage endometriosis: adhesion and growth of human menstrual endometrium in nude mice. *Fertil Steril* 74: 306-312
- Nitschke T, Fabian G (1970) [Measurements of the endometrium of the mouse during estrus]. *Zentralbl Veterinarmed A* 17: 216-229
- Noble LS, Simpson ER, Johns A, Bulun SE (1996) Aromatase expression in endometriosis. *J Clin Endocrinol Metab* 81: 174-179
- Nothnick WB, Curry TE, Vernon MW (1994) Immunomodulation of rat endometriotic implant growth and protein production. *Am J Reprod Immunol* 31: 151-162
- Olive DL, Montoya I, Riehl RM, Schenken RS (1991) Macrophage-conditioned media enhance endometrial stromal cell proliferation in vitro. *Am J Obstet Gynecol* 164: 953-958
- Olive DL, Pritts EA (2001) Treatment of endometriosis. *N Engl J Med* 345: 266-275
- Oosterlynck DJ, Cornillie FJ, Waer M, Vandeputte M, Koninckx PR (1991) Women with endometriosis show a defect in natural killer activity resulting in a decreased cytotoxicity to autologous endometrium. *Fertil Steril* 56: 45-51
- Oosterlynck DJ, Meuleman C, Waer M, Vandeputte M, Koninckx PR (1992) The natural killer activity of peritoneal fluid lymphocytes is decreased in women with endometriosis. *Fertil Steril* 58: 290-295
- Osteen KG, Bruner-Tran KL, Eisenberg E (2005) Endometrial biology and the etiology of endometriosis. *Fertil Steril* 84: 33-34; discussion 38-39
- Pai R, Szabo IL, Soreghan BA, Atay S, Kawanaka H, Tarnawski AS (2001) PGE(2) stimulates VEGF expression in endothelial cells via ERK2/JNK1 signaling pathways. *Biochem Biophys Res Commun* 286: 923-928
- Panigrahy D, Singer S, Shen LQ, Butterfield CE, Freedman DA, Chen EJ, Moses MA, Kilroy S, Duensing S, Fletcher C, Fletcher JA, Hlatky L, Hahnfeldt P, Folkman J, Kaipainen A (2002) PPARgamma ligands inhibit primary tumor growth and metastasis by inhibiting angiogenesis. *J Clin Invest* 110: 923-932
- Pizzo A, Salmeri FM, Ardita FV, Sofo V, Tripepi M, Marsico S (2002) Behaviour of cytokine levels in serum and peritoneal fluid of women with endometriosis. *Gynecol Obstet Invest* 54: 82-87
- Ramadori G, Christ B (1999) Cytokines and the hepatic acute-phase response. *Semin Liver Dis* 19: 141-155
- Rana N, Braun DP, House R, Gebel H, Rotman C, Dmowski WP (1996) Basal and stimulated secretion of cytokines by peritoneal macrophages in women with endometriosis. *Fertil Steril* 65: 925-930
- Reynolds LP, Killilea SD, Redmer DA (1992) Angiogenesis in the female reproductive system. *FASEB J* 6: 886-892
- Rice VM (2002) Conventional medical therapies for endometriosis. *Ann N Y Acad Sci* 955: 343-352; discussion 389-393, 396-406
- Rossi M, Sharkey AM, Vigano P, Fiore G, Furlong R, Florio P, Ambrosini G, Smith SK, Petraglia F (2005) Identification of genes regulated by interleukin-1beta in human endometrial stromal cells. *Reproduction* 130: 721-729
- Rucker M, Laschke MW, Junker D, Carvalho C, Schramm A, Mulhaupt R, Gellrich NC, Menger MD (2006) Angiogenic and inflammatory response to biodegradable scaffolds in dorsal skinfold chambers of mice. *Biomaterials* 27: 5027-5038
- Sampson JA (1925) Heterotopic or misplaced endometrial tissue. *Am J Obstet Gynaecol* 10: 649-664
- Sampson JA (1927) Peritoneal endometriosis due to menstrual dissemination of endometrial tissue into the peritoneal cavity. *Am J Obstet Gynecol* 14: 422-429
- Satchi-Fainaro R, Mamluk R, Wang L, Short SM, Nagy JA, Feng D, Dvorak AM, Dvorak HF, Puder M, Mukhopadhyay D, Folkman J (2005) Inhibition of vessel permeability by TNP-470 and its polymer conjugate, caplostatin. *Cancer Cell* 7: 251-261
- Schandene L, Vandenbussche P, Crusiaux A, Alegre ML, Abramowicz D, Dupont E, Content J, Goldman M (1992) Differential effects of pentoxifylline on the production of tumour necrosis factor-alpha (TNF-alpha) and interleukin-6 (IL-6) by monocytes and T cells. *Immunology* 76: 30-34

7 References

- Schenken RS, Asch RH (1980) Surgical induction of endometriosis in the rabbit: effects on fertility and concentrations of peritoneal fluid prostaglandins. *Fertil Steril* 34: 581-587
- Scott R, Te-Linde R (1950) Experimental endometriosis. *Am J Obstet Gynecol.* 60: 1147-1173
- Sharpe-Timms KL, Zimmer RL, Ricke EA, Piva M, Horowitz GM (2002) Endometriotic haptoglobin binds to peritoneal macrophages and alters their function in women with endometriosis. *Fertil Steril* 78: 810-819
- Sierra-Honigmann MR, Nath AK, Murakami C, Garcia-Cardena G, Papapetropoulos A, Sessa WC, Madge LA, Schechner JS, Schwabb MB, Polverini PJ, Flores-Riveros JR (1998) Biological action of leptin as an angiogenic factor. *Science* 281: 1683-1686
- Sillem M, Prifti S, Koch A, Neher M, Jauckus J, Runnebaum B (2001) Regulation of matrix metalloproteinases and their inhibitors in uterine endometrial cells of patients with and without endometriosis. *Eur J Obstet Gynecol Reprod Biol* 95: 167-174
- Sinaii N, Plumb K, Cotton L, Lambert A, Kennedy S, Zondervan K, Stratton P (2008) Differences in characteristics among 1,000 women with endometriosis based on extent of disease. *Fertil Steril* 89: 538-545
- Siristatidis C, Nissotakis C, Chrelias C, Iacovidou H, Salamalekis E (2006) Immunological factors and their role in the genesis and development of endometriosis. *J Obstet Gynaecol Res* 32: 162-170
- Somigliana E, Vigand P, Gaffuri B, Guarneri D, Busacca M, Vignali M (1996) Human endometrial stromal cells as a source of soluble intercellular adhesion molecule (ICAM)-I molecules. *Hum. Reprod.* 11: 1190-1194
- Somigliana E, Vigano P, Rossi G, Carinelli S, Vignali M, Panina-Bordignon P (1999) Endometrial ability to implant in ectopic sites can be prevented by interleukin-12 in a murine model of endometriosis. *Hum Reprod* 14: 2944-2950
- Steinleitner A, Lambert H, Suarez M, Serpa N, Roy S (1991) Immunomodulation in the treatment of endometriosis-associated subfertility: use of pentoxifylline to reverse the inhibition of fertilization by surgically induced endometriosis in a rodent model. *Fertil Steril* 56: 975-979
- Sternlicht MD, Werb Z (2001) How matrix metalloproteinases regulate cell behavior. *Annu Rev Cell Dev Biol* 17: 463-516
- Story L, Kennedy S (2004) Animal studies in endometriosis: a review. *Ilar J* 45: 132-138
- Strathy JH, Molgaard CA, Coulam CB, Melton LJ, 3rd (1982) Endometriosis and infertility: a laparoscopic study of endometriosis among fertile and infertile women. *Fertil Steril* 38: 667-672
- Stratton P, Sinaii N, Segars J, Koziol D, Wesley R, Zimmer C, Winkel C, Nieman LK (2008) Return of chronic pelvic pain from endometriosis after raloxifene treatment: a randomized controlled trial. *Obstet Gynecol* 111: 88-96
- Straub RH (2007) The Complex Role of Estrogens in Inflammation. *Endocr Rev* 28: 521-574
- Strieter RM, Kunkel SL, Elner VM, Martonyi CL, Koch AE, Polverini PJ, Elner SG (1992) Interleukin-8. A corneal factor that induces neovascularization. *Am J Pathol* 141: 1279-1284
- Styer AK, Sullivan BT, Puder M, Arsenault D, Petrozza JC, Serikawa T, Chang S, Hasan T, Gonzalez RR, Rueda BR (2008) Ablation of leptin signaling disrupts the establishment, development, and maintenance of endometriosis-like lesions in a murine model. *Endocrinology* 149: 506-514
- Suginami H (1991) A reappraisal of the coelomic metaplasia theory by reviewing endometriosis occurring in unusual sites and instances. *Am J Obstet Gynecol* 165: 214-218
- Tabruyn SP, Griffioen AW (2007) Molecular pathways of angiogenesis inhibition. *Biochem Biophys Res Commun* 355: 1-5
- Takayama K, Zeitoun K, Gunby RT, Sasano H, Carr BR, Bulun SE (1998) Treatment of severe postmenopausal endometriosis with an aromatase inhibitor. *Fertil Steril* 69: 709-713
- Tamura M, Sebastian S, Gurates B, Yang S, Fang Z, Bulun SE (2002) Vascular endothelial growth factor up-regulates cyclooxygenase-2 expression in human endothelial cells. *J Clin Endocrinol Metab* 87: 3504-3507
- Taylor RN, Lebovic DI, Mueller MD (2002) Angiogenic factors in endometriosis. *Ann N Y Acad Sci* 955: 89-100; discussion 118, 396-406

7 References

- Vernon MW, Wilson EA (1985) Studies on the surgical induction of endometriosis in the rat. *Fertil Steril* 44: 684-694
- Vinatier D, Dufour P, Oosterlynck D (1996) Immunological aspects of endometriosis. *Hum Reprod Update* 2: 371-384
- Vinatier D, Orazi G, Cosson M, Dufour P (2001) Theories of endometriosis. *Eur J Obstet Gynecol Reprod Biol* 96: 21-34
- Wennberg L, Czech KA, Larsson LC, Mirza B, Bennet W, Song Z, Widner H (2001) Effects of immunosuppressive treatment on host responses against intracerebral porcine neural tissue xenografts in rats. *Transplantation* 71: 1797-1806
- Wilson TJ, Hertzog PJ, Angus D, Munnery L, Wood EC, Kola I (1994) Decreased natural killer cell activity in endometriosis patients: relationship to disease pathogenesis. *Fertil Steril* 62: 1086-1088
- Witz CA, Montoya-Rodriguez IA, Cho S, Centonze VE, Bonewald LF, Schenken RS (2001a) Composition of the extracellular matrix of the peritoneum. *J Soc Gynecol Investig* 8: 299-304
- Witz CA, Thomas MR, Montoya-Rodriguez IA, Nair AS, Centonze VE, Schenken RS (2001b) Short-term culture of peritoneum explants confirms attachment of endometrium to intact peritoneal mesothelium. *Fertil Steril* 75: 385-390
- Wu MY, Ho HN, Chen SU, Chao KH, Chen CD, Yang YS (1999) Increase in the production of interleukin-6, interleukin-10, and interleukin-12 by lipopolysaccharide-stimulated peritoneal macrophages from women with endometriosis. *Am J Reprod Immunol* 41: 106-111
- Young RH, Scully RE (1986) Testicular and paratesticular tumors and tumor-like lesions of ovarian common epithelial and mullerian types. A report of four cases and review of the literature. *Am J Clin Pathol* 86: 146-152
- Zamah NM, Dodson MG, Stephens LC, Buttram VC, Jr., Besch PK, Kaufman RH (1984) Transplantation of normal and ectopic human endometrial tissue into athymic nude mice. *Am J Obstet Gynecol* 149: 591-597

8 Appendix

8.1 List of publications

This work has been performed from July 2005 until June 2008 in the laboratories of Bayer Schering Pharma AG Berlin, GDD-TRG Women's Healthcare, Gynecological Therapy 1.

Parts of this thesis were already published or presented:

Publication:

Nowak NM, Fischer OM, Gust TC, Fuhrmann U, Habenicht U-F, Schmidt A

Intraperitoneal inflammation decreases endometriosis in a mouse model

Human Reproduction, accepted April 2008, in press

Poster:

Nowak NM, Fischer OM, Fuhrmann U, Moeller C, Schmidt A

Influence of immune suppression on lesion establishment in an endometriosis mouse model

World Conference on Endometriosis, March 2008, Melbourne, Australia

Nowak NM, Weidmann R, Folgnand K, Fischer OM, Schmidt A

Endometriosis mouse model: Examining the involvement of the immune system

Summer School on Endocrinology, August 2007, Bregenz, Austria

Nowak NM, Weidmann R, Folgnand K, Fischer OM, Schmidt A

Endometriosis mouse model: Examining the involvement of the immune system

4th Int. Conference on the Female Reproductive Tract, June 2007, Frauenchiemsee, Germany

Nowak NM, Weidmann R, Schmidt A

Two different mouse models for endometriosis

51. Symposium of the German Society for Endocrinology, March 2007, Salzburg, Austria

Nowak NM, Weidmann R, Schmidt A

Two different mouse models for endometriosis

Summer School on Endocrinology, July 2006, Bregenz, Austria

8.2 Abbreviations

A	Androstenedione
APC	Allophycocyanin
CD	Cluster of differentiation
COX	Cyclo-oxygenase
Cs A	Cyclosporin A
CXCL	C-X-C motif ligand
E ₁	Estrone
E ₂	Estradiol/Estroge
EGFP	Enhanced green fluorescent protein
ELISA	Enzyme-linked immunosorbent assay
ER	Estrogen receptor
FACS	Fluorescence-activated cell sorting
FCS	Foetal calf serum
FITC	Fluorescein
GC	Glucocorticoid
GnRH	Gonadotropin releasing hormone
HE	Haematoxyline-eosine
HIF-1 α	Hypoxia-inducible factor-1
HRP	Horseradish peroxidase
i.p.	intraperitoneal
IL	Interleukine
LH	Lutenising hormone
LPS	Lipopolysaccharide
MCP-1	Monocyte chemoattractant protein
MHC	Major histocompatibility class
NK	Natural killer
PBS	Phosphate-buffered saline
PE	Phycoerythrin
PEC	Peritoneal exudate cells
PF	Peritoneal fluid
PG	Prostaglandine
RANTES	Regulated upon Activation, Normal T-cell Expressed, and Secreted
SERD	Selective estrogen receptor destabilizer
TM	Thioglycolate medium
TNF- α	Tumour necrosis factor-alpha
VEGF	Vascular endothelial growth factor

8.3 Acknowledgements

I am especially grateful that Drs. Anja Schmidt and Oliver Fischer supervised my thesis. Without them, progress would have been very slow! They were always there for my questions, open for discussion and supported me with scientific knowledge and very helpful advises. Thank you!

My further acknowledgements go to Prof. Dr. Ursula-Friederike Habenicht, who supervised my thesis as my first referee and provided very helpful criticism on my publication manuscript and thesis.

Moreover I would like to thank Prof. Dr. Carsten Niemitz for his willingness to coach me in his function as university professor from FU Berlin and for kindly being the head of my PhD thesis examination board as well as for his very valuable comments on my publication manuscript and thesis.

Thanks go also to my colleague Ronald Weidmann for teaching me how to conduct animal experiments, assisting me with my endometriosis models and always cheering me up, to Geert Bodewitz and Manuela Steinbach, who taught me everything they knew about immunohistochemistry, to Gabi Borowicz, who performed the RIA with my serum samples and to Kerstin Folgnand, who did the first ELISA experiments and *in vitro* macrophage assays with my samples and instructed me how to perform these techniques.

A big “Thank you!” goes to Dr. Tatjana Gust for assisting me with FACS analysis and all other immunological questions. Furthermore, she and Parham Mirshahpanah did a great job in correcting my thesis.

Moreover, my acknowledgements go to all my TRH Women’s Healthcare colleagues, who all contributed to my work; to Dr. Ulrike Fuhrmann who made it possible that I could do my PhD thesis in her group and to Dr. Katja Prella, who did a great job in communicating with LAGetSi on behalf of my animal experiment application. Furthermore I like to thank Dr. Karl-Heinz Thierauch for discussing angiogenesis with me, Dr. Wolf Döcke and Christine Stock for their important information about glucocorticoids and immune system, Nicole Kahmann for assisting with a tricky immunohistochemical staining and Gabi Betzholz and Martina Heinrich for attentively caring for my mice and my breed.

I thank all my colleagues and especially the PhD students from BSP for being such a pleasant company and for letting me have such a funny and informative time!

Finally I would like to thank my parents and KB for their loving support!