

Aus der Klinik für Mund -Kiefer - und Gesichtschirurgie
der Medizinischen Fakultät Charité– Universitätsmedizin Berlin

DISSERTATION

**Long-term results after open reduction of the
subcondylar fracture via- modified Risdon approach**

zur Erlangung des akademischen Grades
Doctor medicinae dentariae (Dr. med. dent.)

vorgelegt der Medizinischen Fakultät
Charite– Universitätsmedizin Berlin

von

Mohamed Saaed Zeno
aus Hama-Syrien

Datum der Promotion: 11.12.2015

Table of contents

Abstract	V
Zusammenfassung	VII
1. Introduction	1
1.1 History	1
1.2 Anatomical review of the temporomandibular joint	2
1.2.1 The mandibular condyle	3
1.2.2 The disc and its attachments	3
1.2.3 Capsule	4
1.2.4 Vessels and nerves of the TMJ	5
1.3 Functional anatomy	5
1.4 Incidence, etiology of condylar fractures	6
1.5 Biomechanics of condylar fracture:	7
1.6 Classification of condylar fractures	8
1.7 Diagnosis of condylar fractures	12
1.7.1 Clinical diagnosis	12
1.7.2 Radiological diagnosis	14
1.8 TREATMENT OF MANDIBULAR CONDYLE FRACTURES	16
1.8.1 Conservative treatment of condylar fractures	17
1.8.2 Open reduction of the fractured mandibular Condyle	19
1.8.3 Indications for open reduction of condyle fractures	20
1.8.4 Surgical approaches to the fractured Mandibular Condyle	22
1.8.5 Methods of internal fixation Osteosynthesis	26
1.9 late sequel and prognosis after condylar fracture	28
2. Aim of the study	29
3. Materials and Method	30
3.1. Patients and the distribution	30
3.2. Type of participants	30
3.3. Time of Follow-up	30
3.4 Methodology of Follow-up	30
3.4.1 Anamnesis and subjective assessment of treatment outcome	31
3.5 Clinical examination	32

3.5.1 Evaluation of occlusal status	32
3.5.2 Helkimo TMJ dysfunction index.....	33
3.5.3 Assessment of facial nerve function	37
3.5.4 Assessment of the scar.....	38
3.5.5 Radiographic assessment.....	39
3.6 Statistical Analysis	43
4. Results	44
4.1 Demographic Results.....	44
4.1.1 Fracture distribution according to Spiessl & Schroll.....	46
4.2 Intervention Date.....	47
4.3 Scoring of occlusive support	48
4.4 Analysis of surgical intervention data	48
4.4.1 Surgical approach and osteosynthesis.....	49
4.5 Results of functional findings.....	50
4.5.1 Interincisal Opening	50
4.5.2 Relationship between the Fracture type and postoperative MMO	50
4.5.3 Pro and laterotrusion.....	51
4.5.4 TMJ and masticatory muscle Pain	52
4.5.5 TMJ Clicking	52
4.5.6 Assessment of the scar.....	53
4.5.7 Assessment of facial nerve function	55
4.5.8 Occlusal Disturbances	56
4.6 Evaluation of calculated indexes	56
4.6.1 Assessment of clinical dysfunction index according Helkimo	56
4.6.2 Classification according to Hochban (Hochban W. et al. 1996)	57
4.7 Radiographic findings.....	57
4.7.1 Pre-operative assessment:	57
4.7.2 Assessment of postoperative anatomical reduction According to Hochban ...	58
4.7.3 Shortening in ramus height	59
4.7.4 Complications of Osteosynthesis	59
5. Discussion	61
5.1 Intervention Date.....	63
5.2 Scoring of occlusive support	64

5.3 Analysis of surgical intervention data	64
5.4 Osteosynthesis	67
5.5 Results of functional findings.....	68
5.5.1 Interincisal Opening	68
5.5.2 Pro- and laterotrusion	69
5.5.3 TMJ and masticatory muscle Pain	70
5.5.4 TMJ Clicking	72
5.5.5 Assessment of the scar.....	72
5.5.6 Assessment of facial nerve function.....	73
4.5.7 Occlusal disturbances.....	74
5.6 Evaluation of calculated indexes	75
5.6.1 Assessment of clinical dysfunction index according Helkimo	75
5.6.2 Classification according to Hochban (Hochban W. et al. 1996)	76
5.7 Radiographic findings.....	77
5.7.1 Pre- operative assessment:	77
5.7.2 Shortening in ramus height	79
5.7.3 Complications of Osteosynthesis	79
6. Appendix.....	X
7. Reference.....	XX
8. Eidesstattliche Versicherung	XLI
9. Curriculum vitae (Lebenslauf).....	XLII

Abstract

Although the mandibular condyle is one of the most commonly fractured facial bones, the debate about the approach to the mandibular condyle continues.

The major criticisms of surgical technique are due to possible risks of facial nerve damage and visible facial scars.

The specific objective of this study was to control, at least 6-months after surgery via-modified Risdon approach, the treatment concept of condylar fracture at the Division of Oral and Maxillofacial-Surgery of the University Hospital Charite–Berlin.

From June 2008 to January 2011, a total of 45 adult patients with 49 surgically treated condylar neck fracture were radiologically and clinically retrospectively reviewed in this study. The postoperative assessment was based on DVT. We found that the DVT is suitable for assessment of postoperative results after open reduction of condylar fracture, and it may therefore be recommended that this imaging technique should be considered as a choice for examination of bone changes of the TMJ.

The evaluation of radiographic findings according to Hochban, Ellers et al. (1996) indicated that an accurate anatomical reduction was possible in 23/49 (46.9%), and good results were achieved in 49% (24/49) of the cases.

In the follow-up of 45 patients, the clinical findings were good. With respect to the mobility of the mandible, the mean amounts of maximal active interincisal opening, lateral movement to the fractured side, lateral movement to the contralateral side and protrusive movement were 45.5 mm, 10.54, 10.57, and ≥ 7 mm in 87%, respectively, and were considered to be good averages.

The clinical findings were surveyed for evaluation of the individual structures of the stomatognathic system and summarized in a standardized dysfunction index according to Helkimo. In our group, the Helkimo index showed that 75.6% of patient population (34/45) had a low score D0 (symptom-free). A strong relationship between the functional and radiological parameters was established in this study, so that in 23 cases of correct anatomical reduction of the condylar process, minimal functional impairment existed only in 1 case.

Assessment of the function of the facial nerve, the 19 slight temporary weakness of the facial nerve lasted for 5 months in 3 patients, for 3 months in 9 patients, for 2 months in 3 patients, and for 1 month in 2 patients. After 6 months the permanent impairment of

the facial nerve was observed only in 2 cases (4%) with slight degree of weakness. The resultant scar was less noticeable, and it was felt as disturbing by the patients only in 6.1 % of the cases (3/49).

To conclude, that despite each extra-oral access to the TMJ is associated with its specific complications. open reduction via the modified Risdon approach is an effective and reliable technique offering good exposure of the fracture region and good functional radiological results with low morbidity and good patient satisfaction.

Zusammenfassung

Obwohl die Frakturen der Kiefergelenkfortsätze eine der häufigsten Frakturen im Gesichtsbereich sind, bleibt Ihre Behandlung weiterhin umstritten. In diesem Zusammenhang muss auf mögliche Risiken und Komplikationen der extraoralen chirurgischen Therapie von Kiefergelenkfortsatzfrakturen hingewiesen werden.

Ziel der vorliegenden Untersuchung war, mindestens 6 Monate postoperativ über den modifizierten Risdon Zugang, die Behandlungskonzepte von Kollumfrakturen in der Abteilung für Mund- Kiefer- und Gesichtschirurgie des Universitätsklinikums der Charite Berlin zu evaluieren .

Von Juni 2008 bis Januar 2011 wurden insgesamt 45 erwachsene Patienten, mit 49 chirurgischen behandelten Kollumfrakturen bei dieser retrospektiven Studie klinisch und radiologisch überprüft. Die postoperative Verlaufskontrolle wurde mittels DVT durchgeführt. Nach Auswertung der postoperativen DVT- Aufnahmen nach chirurgischen Reposition der Kollumfrakturen kammen wir zu dem Ergebnis, dass diese spezielle Technik bei der Beurteilung der Knochenveränderungen am TMJ im Betracht gezogen werden sollte .

Die Auswertung des Röntgenbefundes (Hochban, Ellers et al. 1996) zeigte, dass die genaue anatomische Rekonstruktion in 23/49 (46.9%) möglich war und damit gute Ergebnisse erreicht wurden (49%, 24/49) . Die Durchschnittswerte der postoperativen Mobilität des Unterkiefers wurden in 87% der Patientin als gut berücksichtigt sein . Die Werte waren wie folgt : die mittlere Höhe der maximal aktiven Interinzisal Öffnung (45.5 mm), Lateralebewegung an den gebrochenen Seiten (10.54), seitliche Bewegung an der kontralateralen Seite (10.57), Protrusionsbewegung ≥ 7 mm in.

Für die Beurteilung der einzelnen Strukturen des stomatognathen Systems wurden die klinischen Befunde begutachtet und in einem standardisierten Dysfunktion Index nach Helkimo zusammengefasst. In unserer Gruppe hatte 75.6 % der Patienten (34/45) eine geringe Punktzahl D0 (symptomfrei). Ein enge Zusammenhang zwischen funktionellen und radiologischen Parametern können in dieser Studie nachgewiesen werden, sodass in 23 Fällen eine korrekte anatomische Reposition der Frakturen bestand, wobei minimale funktionelle Beeinträchtigungen in 1 Fall. Bei der Beurteilung der Funktion der

Gesichtsnerven, wurde in 19 von 49 Fälle eine leichte vorübergehende Schwäche des Gesichtsnervs mit einer Dauer von 5 Monaten bei drei Patienten. Nach 6 Monaten wurde die permanente Störung der Gesichtsnerven nur in 2 Fällen (4%) mit leichten Schwäche Grad gesehen. Die resultierenden Narben waren wenig auffällig und wurden als störend nur in 6.1 % der Fälle von den Patienten (3 /49) empfunden.

Der extraorale Zugang zum Kiefergelenk ist mit spezifischen Komplikationen verbunden. Die offene Reposition durch den modifizierten Risdon Zugang ist eine wirksame und zuverlässige Technik. Er bietet eine gute Darstellung des Frakturbereiche, gute funktionelle und radiologische Ergebnisse mit niedriger Morbidität und guter Patientenzufriedenheit.

1. Introduction

1.1 History

Due to its exposed anatomic position, the mandible is often involved in head and face trauma (Sawazaki, Lima Junior et al. 2010). The lower jaw is broken in 65 to 70% of all maxillofacial fractures, and it alone is injured in 50% (Becker R, 1973). Ellis et al. found that mandibular fractures outnumber midfacial fractures by a ratio of 2:1 (Ellis, Moos et al. 1985). A change in frequency of condylar fractures over time can be observed. Whereas before World War I condylar fractures were rare events comprising less than 10% of all mandibular fractures (Reichenbach E, 1938), their incidence rose in the following years (Hayward 1947). During the last 25 years, condylar fractures comprised between 17.5% and 52% of all mandibular fractures. Due to its particular anatomic location, the treatment of fractures of the jaw joint occupies a special position and is a particularly serious task for the oral and maxilla -facial surgeon.

In 1927, without naming concrete figures, Wassmund characterized the condylar fracture as “a frequent event” (Wassmund M. 1927). The first recommendations for medical treatment of temporo-mandibular joint fractures (conservative treatment with immobilization using a chin cap and a leather cuff), which are found in the literature, date back to 1500 BC in the Edwin Smith’s papyrus (*Westendorf, 1966*). Then, in 1805, Desault developed a description of the diagnosis and conservative therapy of condylar fractures (Desault P.J, 1805). Perthes, in 1924, performed the first surgical treatment by means of plate osteosynthesis (Perthes G. 1924). A Few years later, Wassmund advocated a surgical approach to the treatment of condyle fractures by means of wires for fixation of the condylar segments (Wassmund M. 1927). However, antibiotics for treatment of postoperative complications such as infection and necrosis of the condyle were not available at that time. Not surprisingly, closed treatment concepts prevailed into the 1940s (Reichenbach E. 1938). A further milestone in the development of surgery was the first clinical application of penicillin by Fleming (Fleming A. 1950). At the same time, there had been many efforts to improve the stability of osteosynthesis. Stephenson and Graham pioneered the use of Kirschner wires for small fragment fixation in fractures of mandibular condyle (Graham and Cadenat. 1952). Thoma and Herfert attempted to improve small fragment stabilization using a combination of wire and extraoral pin fixation (Thoma, 1954) (Hertfert, 1956).

Then the principle of functionally stable osteosynthesis was developed by the Swiss AO working group (Luhr HG, et al. 1968, Spiessl B.1969, and Becker R . et al. 1973). The principle of functionally stable osteosynthesis made it possible for the first time to meet the two main requirements of joint fracture treatment: exact repositioning of the fragments and mobilization of the joint for restoration of function (Pfeifer G. 1995). As further progress was made in medical technology, surgical treatment of condyle fractures saw a significant increase. Pfeifer reported a rise in the surgically treated cases in the Hamburg clinic from 8% to 35% over the years 1964 to 1972 (G. Pfeifer 1995). But open reduction of condylar fractures has always been very challenging because of the complexities involved in achieving stable osteosynthesis and safe access to the temporomandibular joint. For this reason and because of the possible adverse effects such as visible scars and temporary or permanent facial nerve damage, the controversy discussion of this treatment has continued to the present time.

1.2 Anatomical review of the temporomandibular joint

In order to appreciate the complexity of the TMJ, it is important to understand the anatomy of this articulation and how the anatomy is altered by traumatic injuries. The TMJs are ginglymoid, diarthrodial, freely movable and one of the synovial articulations of the bicondylar type. The term "diarthrodial" is used because the joint has two articulating bone components, the mandibular condyle inferiorly, and the articular eminence and glenoid-fossa of the temporal bone superiorly (Fonsica, Raymond J.2000). The temporal surface combines the mandibular fossa and the articular tubercle, the roof of the fossa is thin and separates the brain from the joint cavity, therefore during surgical manipulation at the fossa, care should be taken to avoid perforating the roof of the fossa. The muscles of mastication (MOM) associated with the TMJ include the temporalis, masseter, lateral pterygoid, and medial pterygoid. Muscle attachments of the temporalis, deep masseter, and superior belly of the lateral pterygoid have been observed within portions of the articular disk anteriorly, while the inferior belly of lateral pterygoid inserts onto the medial aspect of the condylar neck. Owing to this unopposed

muscle pull, fractures of the subcondylar fractures often exhibit anterosuperior rotation. Low subcondylar fractures may have variable muscle pull from the medial pterygoid muscle and the masseter depending upon fracture configuration (Blasberg B, Greenberg MS,2003). Accessory MOM includes the digastric, mylohyoid, geniohyoid, buccinators, stylomandibular, and stylohyoid. Cervical muscles commonly associated with the temporomandibular disorders (TMD) are the sternocleidomastoid, splenius capitis and trapezius (Blasberg B, Greenberg MS, 2003).

1.2.1 The mandibular condyle

The condyle resides in the articular fossa, its axis is perpendicular to the mandibular ramus, to which it is connected by a thin collum, forming an angle of 25° with the frontal plane. The condyle has two poles, a lateral and a medial one, to which the disc is fixed by strong fraenula. Anatomically, the adult condyle is composed of dense cortical bone and variable amount of cancellous bone depending upon the age of the patient. The condyle measures approximately 8.5 mm in sagittal diameter and 21 mm in transverse diameter, on average. The collum that supports it measures 22 mm in sagittal and only 5 mm in transverse diameter at its neck. This configuration results in a preponderance of subcondylar fractures in adults rather than fractures of the condylar head (Jean-luc Kahn. 2009).

1.2.2 The disc and its attachments

The disk (Fig. 1) is an oval plate of fibrocartilage that is attached circumferentially to the capsule and interposed between the temporal and mandibular surfaces, interlocking with the condyle during movement by powerful lateral and medial fraenula. The posterior ridge is prolonged by the “bilaminar zone”.

The **bilaminar zone** is a vascular, innervated tissue that plays an important role in allowing the condyle to move forward. The anterior ridge, closely connected to the superior bundle of the lateral pterygoid muscle, separates the temporomandibular articulation into two compartments:

- the upper disco-temporal compartment, seat of translation.
- the lower disco-mandibular compartment, seat of rotation (Richard S. Snell, 2007).

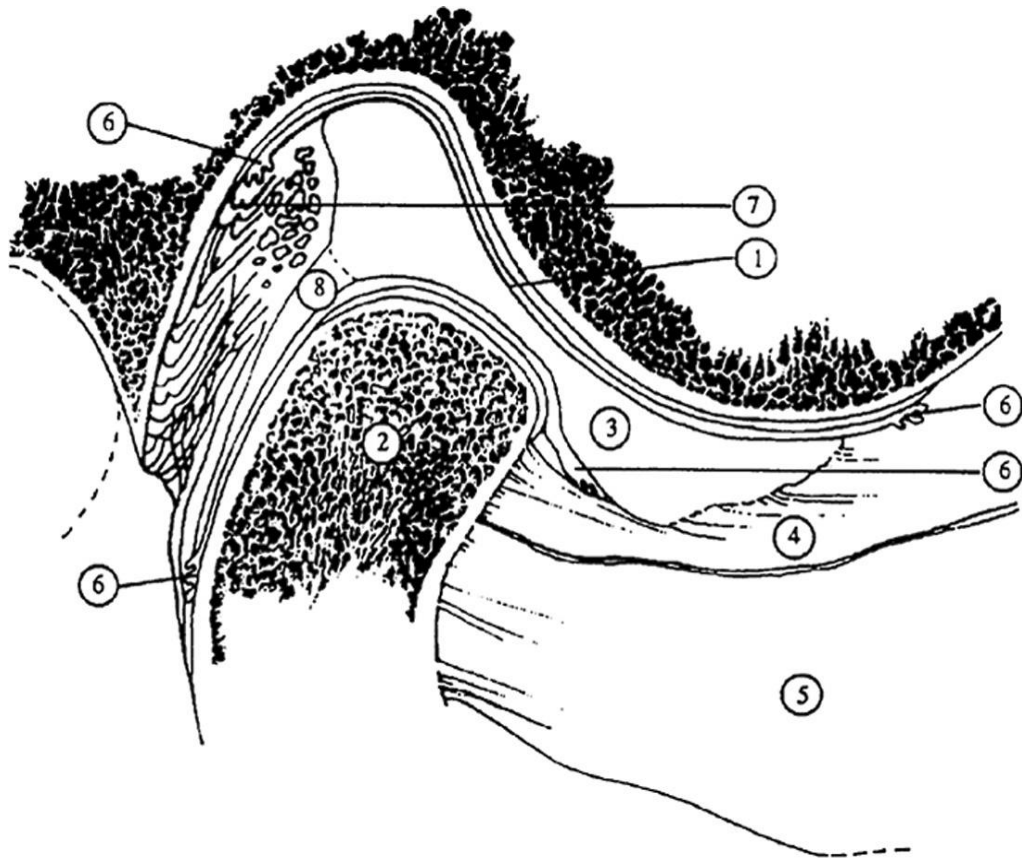


FIG. 1- **Lateral view of cross-section through the TMJ.** 1, Posterior slope of the eminencia; 2, condyle; 3, disk; 4, superior lateral pterygoid muscle; 5, inferior lateral pterygoid muscle; 6, synovial tissue; 7, retrodiscal tissue including posterior attachment of disk to temporal bone; 8, posterior ligamentous attachment of disk to the condyle. (From Peter E. Dawson: *Functional Occlusion From TMJ to Smile Design*, 2007, Mosby; p. 34.)

1.2.3 Capsule

The joint capsule is a fibroelastic, highly vascular, and highly innervated dense connective tissue. The capsule is well defined outwardly and inwardly where it is attached to the lateral and medial borders of articular surfaces. The lateral aspect of the capsule attaches to the zygomatic tubercle, the lateral rim of glenoid fossa, and the postglenoid tubercle. The spine of sphenoid, the sphenomandibular ligament, and the middle meningeal artery are closely related to the middle surface. The surgeon has to be aware of these relationships and should avoid interfering with the medial capsule. The disc is

attached to the lateral and medial sides of the capsule, thus the disc and its muscle attachments form with the capsule what is called the “disc – capsule-muscle – complex“. Inferiorly, the capsule attaches to the periosteum of the neck of the condyle. Lateral retraction of the capsule should allow access to the upper joint space. Incising and reflecting the capsule usually lead to the cutting of the nerve fibers, which may result in a period of postoperative analgesia and relief from pain (Fonsica, Raymond J. 2000).

1.2.4 Vessels and nerves of the TMJ

- The arteries are branches of superficial temporal artery, the maxillary artery and the facial artery.
- The satellite veins pass into the external jugular vein.
- The nerves arise from the mandibular nerve V3 CN (Jean-luc Kahn. 2009).

Summing up, the TMJ has much in common with other synovial joints, but it also has its own unique features. These unique features include: (1) the condylar cartilage is considered a growth center that insignificantly contributes to the overall growth of the mandible but is important for condylar response to trauma, and it disappears by about age 25; (2) the TMJ functions bilaterally and can be influenced by dental occlusion; and (3) the TMJ has an intact disc that is movable during all joint movements and functions as a shock absorber (Fonsica, Raymond J. 2000).

1.3 Functional anatomy

Any mandibular movement necessarily involves two temporomandibular articulations. The mandible moves through “elevation-lowering”, “propulsion - retropulsion” and “laterotrusion”. Each movement acts on the inferior compartment (for rotation) and the superior compartment (for translation).

Lowering-elevation:

The opening of the mouth starts with a rotation of the condyle below the disc and then continues with anterior translation of the disc-condyle complex beneath the temporal surface. At maximum opening of the mouth, the advancement of the condyle is 12 mm. The lowering is accomplished by the three suprahyoid muscles: anterior belly of the digastric muscle, geniohyoid and mylohyoid muscles. The disc itself is pulled forward by the lateral pterygoid muscle. The closer is accomplished by the elevator muscles: masseter, temporal and medial pterygoid muscles. The disc returns backwards due to

the elastic properties of posterior fraenum (Bumann und Lotzmann 2000 S. 46, Theusner et al. 1993 S. 209).

Propulsion-retropulsion :

propulsion along the occlusal plane is due to the simultaneous contraction of the two lateral pterygoid muscles and principally takes place through the translation in the upper compartment. Retropulsion is the inverse movement to return of the initial position due to the contraction of the posterior fibers of the temporal muscle.

Laterotrusion:

When the chin moves to one side, the homolateral condyle pivots, without advancing, around the axis of the column. The contralateral condyle, which is capped by the disc, undergoes anterior translation due to the contraction of the lateral pterygoid muscle (Jean -luc Kahn. 2009).

1.4 Incidence, etiology of condylar fractures

The percentage of condylar fractures in all mandibular fractures ranges between 17.5 % and 52 % (Miloro 2003), (Villarreal, Monje et al. 2004). Most studies proved that fractures of the mandibular condylar process are the most common fractures in the mandibular and maxillofacial region (Ellis and Throckmorton 2000). In patients of preschool age, condylar process fractures account for up to 75% of mandibular fractures, fractures of the condylar head are in this age group most frequent with up to 60%. The frequency of condylar process fractures decrease with age and falls at the close of the permanent dentition to about 50% (Thoren, Iizuka et al. 1998). The maximum frequency of condylar fracture can be observed in the third and fourth decade of life (Marker, Nielsen et al. 2000). In the literature is listed for adults a distribution of 62% of low fractures to 24% high and 14% of capitellum fractures (Hans Henning-Horch (Hrsg), 2007. book). Regarding the gender distribution of condylar fractures, almost all epidemiological studies showed a higher frequency of fractures in adult males than in females in different geographic regions, for example 8 to 1 in Singapore (Wong 2000), and a ratio of 11 to 1 in the United Arab Emirates (Al Ahmed, Jaber et al. 2004). But Zachariades, in a literature review of 466 condylar fractures, reported no significant difference between men and women and that about two-thirds of all condylar fractures in men and women were unilateral and one third were bilateral.

Additionally, up to 10% of all condylar fractures were undisplaced, 65 to 75% were displaced, and deviation occurred in 10 to 15% (Zachariades, Mezitis et al. 2006).

Very often various factors such as violence, falls, sports injury and all traffic accidents (which include car, motor-cycle and bicycle accidents), play a role in the etiology of fractures of the mandibular condyle. The significant differences in the etiology result from different social and economic conditions, moreover gender and age distribution, increases in population size, population density, traffic intensity, and mobility have to be considered (Ellis, Moos et al. 1985). Although severe fractures occur more frequently after falls and traffic accidents, individual violence remains the most frequent cause in developing countries, with high alcohol consumption being another major factor. Assault was the cause of 48% of condyle fractures in the study by Kolk A. (2002), 57% by 563 condyle fractures in France (Rocton, Chaine et al. 2007), and 53.7 % of 665 fractures in USA (Simsek, Simsek et al. 2007), whereas traffic accidents tend to be the most common cause in developed areas such as the UAE with 75% of 150 condyle fractures (Al Ahmed, Jaber et al. 2004), and Pakistan with 35.8% (Abbas, Ali et al. 2003).

1.5 Biomechanics of condylar fracture:

In spite of the fact that the temporomandibular joint is well protected in the glenoid fossa, and that the condylar process is relatively well protected by the zygomatic arch against direct injury, TMJ injuries are relatively common. In terms of strength, the condylar neck constitutes the weakest region of the entire mandible and is therefore the most susceptible to fracture as a result of indirect forces, where the forces of impact are transmitted along the mandible from distant sites such as the angle, body or symphysis to the condylar neck (Dimitroulis 1997). The central force in the middle of chin (e.g. bicycle accident) can cause a bilateral condylar fracture. In this case, the fracture is called bending-fracture, which is caused by the clash of condyle against the posterior rim of the glenoid fossa. If the force is applied to the lateral aspect of the mandible at the level of canine and premolar region, not only there be a fracture of the mandible on the side of the force, but tension will develop along the contra lateral condylar neck leading to fracture in this area (Peterson LJ 1992, book). But if the force applied is not exhausted in the resulting fracture, a dislocation fracture will occur, in this case, the potential remaining force leads to a rupture of the periosteum at the fracture site, and thus a shift of the fragments is an expecting result because of the muscle tension at the fracture site (Austermann K.H. et al. 1980).

Studies show that, when impacted third molars are present, this area represented a region of inherent weakness and the incidence of condylar fractures decreases, whereas the incidence of mandibular angle fractures increases (Thangavelu, Yognandha. et al. 2010). In any case, the fracture type (localization, the height of the fracture, the direction of the fracture, the degree of displacement, dislocation, single or double,....) depends on many factors. Mueller and Guenther summarized the following parameters for fracture type and its extent (Müller W. 1973, Günthe H. et al. 1966).

The Parameters:

- 1- Amount of the force applied.
- 2- Direction of the force applied.
- 3- Point of application the force.
- 4- Elasticity of the bone.
- 5- Resistance of the muscle and the ligaments of the capsule.
- 6- Position of the mandible at the moment of force application.

1.6 Classification of condylar fractures

There have been many attempts to create classification systems for fractures of the mandibular condyle, therefore we can find many different classifications in the literature, making it difficult to compare treatment results (Mokros S. 1997). The following criteria should be taken into account for a good classification system (Hans Henning- Horch (Hrsg), 2007, Book):

- The anatomical position of the fracture and especially the height of fracture and its relationship to insertion field of the lateral pterygoid muscle.
- The displacement, which in US/UK nomenclature means that there is some degree of contact between the fractured and dislocated bony segments while the condylar head remains within the articular fossa. The term "dislocation" is used in mainland Europe as a synonym (Veras, Kriwalsky et al. 2007).
- The dislocation, which in US/UK nomenclature means that the condylar head rests completely outside the boundaries of the articular fossa. The term "luxation" is used in mainland Europe as a synonym (Veras, Kriwalsky et al. 2007). According to the meaning of "dislocation", fractures of the neck of the condyle tend to be displaced medially or anteromedially in response to the action of the lateral pterygoid muscle. But the fragment can also displace anteriorly or posteriorly and rarely laterally (Schneider

M. 2005). An internationally accepted classification should consider the anatomical aspects, but should also be clinically useful for treatment decisions. A usable classification system should consider all possibilities of injuries in the condyle region, added to this should be simple enough for ease of use, and must be responsive to the contemporary treatment options available to the surgeon (Abdel-Galil and Loukota 2010).

In 1927, Wassmund made a distinction between the fractures of the condylar head, and fractures of the condylar neck. According to MacLennan 1952, condylar fractures are divided into groups according to anatomic location, the position of condylar head in the glenoid fossa, and the relation between the fractured segments (Mac 1952):

- Low condylar neck fracture: from base of sigmoid notch downwards and backwards.
- High condylar neck fracture: above level of sigmoid notch, and usually associated with dislocation.
- Subcondylar fracture: posterior oblique fracture of the mandibular ramus.
- Complete luxation: avulsion of condylar process.

MacLennan also defined four categories based on axial bending criteria as follows: no deviation, a deviation at fracture level, a displacement without luxation out of the fossa, and dislocation of the condyle. The MacLennan classification regards a simple angulation of the condylar process to the major mandibular fragment with bone contact between fragments as (deviation), no contact between fragments and without dislodgement out of the fossa as (displacement), and complete luxation of the condyle out of the articular fossa (dislocation) as the most important of the surgical issues, however this is helpful in managing surgical therapy (Haug and Brandt 2007). In 1955, Rowe and Killey classified the condylar fractures with regard to the relationship of the (TMJ) capsule to the injury:

- Intracapsular fractures
 - Extracapsular fractures
 - Fractures associated with lesions of the capsule, ligaments, disc or surrounding bones of the TMJ.
- In the Rowe and Killey system, an intracapsular fracture is defined as a fracture that involves the articular surface or that occurs above and through the condylar neck. They considered extracapsular fractures as those that “run from the lowest point of the sigmoid notch downwards and backward (Rowe, Killey 1955). But for practical purposes, the anatomical level of the fractures is divided into three sites (Figs. 2): the condylar head (intracapsular), the condylar neck (extracapsular) and the subcondylar region (Silvennoinen, Lizuka et al. 1992) (Newman 1998).

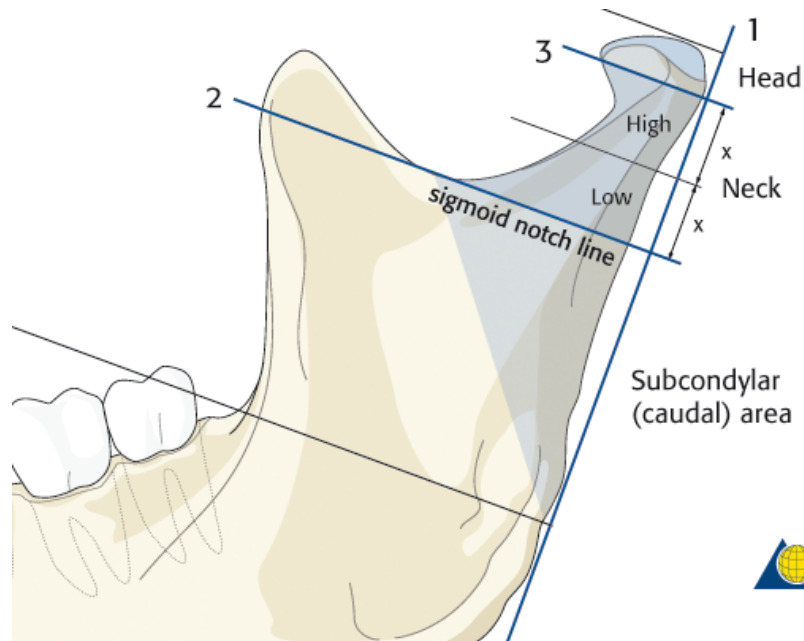


FIG . 2- from AO Foundation

In the German-speaking part of the world, one of the most commonly and frequently used classifications was developed by Spiessel and Schroll (Figs. 3), they distinguish between fractures of the condylar base and neck, and based on the fracture position and the relationship between the fracture fragment and glenoid fossa (Spiessl, B and Schroll, 1972):

- Class I, condylar neck fracture, but there is virtually no deviation/displacement of the fragments.
- Class II, low condylar neck fracture with deviation/displacement. Frequently there is still contact between the bone fragments.
- Class III, high condylar neck fracture with anterior, posterior, medial, or lateral deviation/displacement. As a rule, there is no contact between the fragments.
- Class IV, low condylar neck fracture with dislocation.
- Class V, high condylar neck fracture with dislocation.
- Class VI, intracapsular/ diacapitular fracture. These occur mostly in children younger than 6 years.

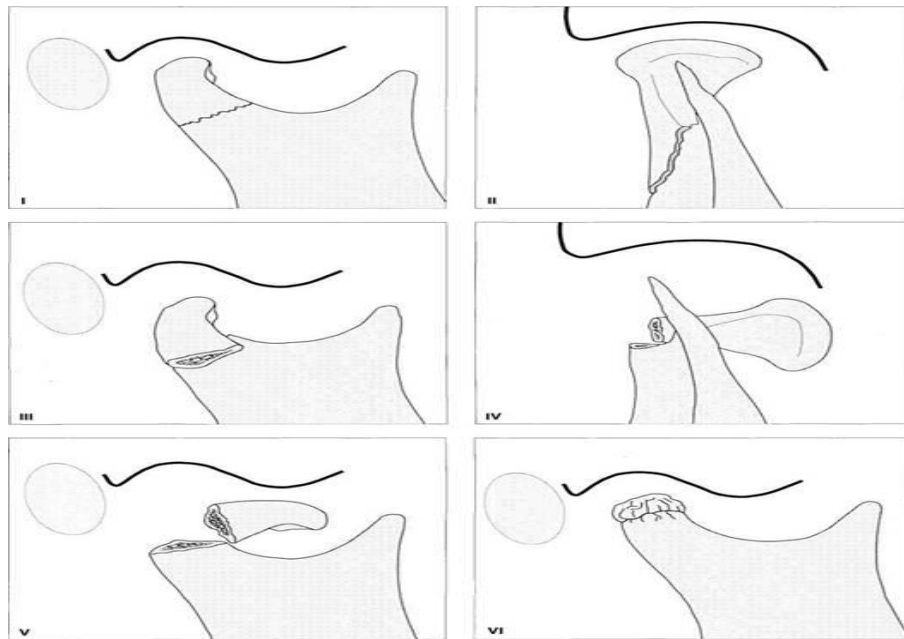


FIG . 3- Classification of condylar neck fractures according to Speissl and Schroll

The Speissl& Schroll classification is the one most commonly used in many publications and in clinical practice. This system has also been adopted in our study, because it allows comparability with other studies. But there are deficiencies in this classification, because it lacks a measured angle of dislocation (anteroposterior with or without mediolateral) and the measured physical overlap, which can also provide useful information to the surgeon. However the subjective descriptions of “high” and “low” fractures should be clarified as follows (Loukota, Eckelt et al. 2005):

- High condylar neck fracture: The fracture line starts somewhere above line A and extends more than 50% above the line A in the lateral view (Figs. 4). Line A is the perpendicular line through sigmoid notch to the ramus tangent.
- Low condylar neck fracture (subcondylar fracture): The fracture line runs behind the mandibular foramen and, in more than half, below line A, refers to the area between the mandibular sigmoid notch and mandibular posterior aspect.

The subclassification proposed by Loukota et al. is recommended and adopted by Strasbourg Osteosynthesis Research Group and AO Foundation. It allows for better

communication between radiologists and surgeons, is also found to be simple to use and can help predict treatment need and outcome (Cenzi, Burlini et al. 2009).

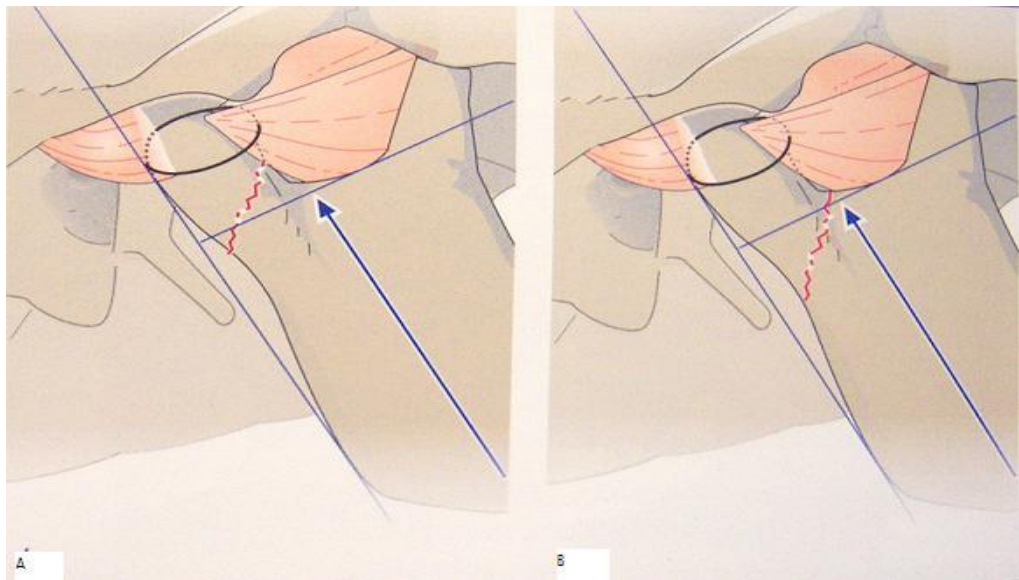


FIG . 4- Subclassification of fractures of the condylar process of the mandible according to Loukota et al “**Book of Fractures of the Mandibular Condyle, page 38** ”

1. 7 Diagnosis of condylar Fractures

1.7.1 clinical diagnosis

The diagnosis of a fracture of the mandibular condyle should be made based on clinical and radiographic examinations. Because the condylar process is protected by the zygomatic arch and the jaw closing muscle, access to the condylar process is limited in clinical examination (Becker R. and Austerman K.H, 1990), therefore, a careful history of the mechanism of injury should always lead the way of the clinical examination of a patient with a suspected fracture or injury of the mandibular condyle. Falls, blows to the contralateral face or ipsilateral preauricular area, or direct impact to the mandibular symphysis should alert the clinician to the possibility of condylar/subcondylar injury. The clinical signs of fracture of the condylar process are directly dependent on the level of the fracture and the degree of dislocation of the fragments. A significant factor is the relative position of the fracture gap and the insertion of the lateral pterygoid muscle (Eckelt 2000). By inspecting patients with a fracture of the mandibular condyle, one or more of the following suggestive clinical signs and symptoms could usually be noticed:

- Swelling over the TMJ region preauricular (Jacobs et al. 1977)
- Possible bleeding from the ear (Rees and Weinberg 1983).

- A laceration or contusion of the chin should raise suspicion (Norholt, Krishnan et al. 1993), (Defabianis 2003).
- There may be obvious facial asymmetry due to soft tissue edema or secondary to shortening of the mandibular ramus caused by overlap of the proximal and distal fracture segments (Mac 1952). The facial asymmetry will occur later if ramus height is not restored (Ellis and Throckmorton 2000).
- Varying degree of limited mandibular movement in response to muscle spasm, edema, and joint bleeding (MacLennan 1969).

The clinical diagnosis is completed also by a physical examination, whereby the examiner can also arrive at one or more of the following findings:

- Pain and tenderness to palpation over the affected TMJ, attempted manipulation of the jaw by the examiner or patient may also cause significant pain (Eckelt 2000).
- Abnormal patterns of condyle movement by the palpation of the TMJ in the external ear canal (Becker und Austermann 1990).
- Malocclusion is often a reliable indicator of the underlying injury. The dental occlusion can give orientation about the fracture location. With a unilateral condylar process fracture and subsequent reduction of height in the ramus, the clinician will see an ipsilateral premature occlusion and contralateral open bite. The dental midline will shift toward the the side of fracture. A contralateral posterior open bite is due to a canting of the mandible. Bilateral condylar fractures may result in a marked anterior open bite and retrognathia (Eckelt 2000; Defabianis 2003).
- Checking the maximum mouth opening, and the difficulty of mouth opening or mouth closure (Mac 1952; Eckelt 2000).
- Deviation of the mandibular midline may be seen both at rest and with attempted movement of the mandible.

Secondary to foreshortening of the ipsilateral ramus, the mandible may deviate to the affected side at rest. Bilateral condylar fractures may result in little midline deviation because both condyles are involved (Hoopes, Wolfort et al. 1970; Defabianis 2003). Finally, we have to say that four elements determine articular function following condylar fracture: the fracture site, fragments displacement, disc integrity, and occlusal guidance (Zachariades, Meztis et al. 2006).

1.7.2 Radiological diagnosis

The clinical findings must be supported by the radiological examination in order to obtain accurate diagnosis for a given condition as the first step for establishing proper care of the patient (Luyk and Ferguson 1991). But the radiological reading is sometimes difficult in view of the superposition of many adjacent structures (Zachariades, Mezitis et al. 2006). Fractures extending into the capsule and sagittal fractures may be missed (Bos, Ward Booth et al. 1999). Therefore, injuries to the condylar fracture should be viewed in at least two planes of space, preferably orientated at 90 degrees to each other (Clementschtsch F. 1960), and if only one view is used, fractures can easily be missed. A panoramic radiograph and the posterioranterior mandibular view G/15° with mouth opening (according to Clementschtsch) are adequate in screening studies, very diagnostic, and relatively inexpensive radiographs to survey the condyle (Fonseca. 2000).

Panoramic radiographs have many advantages, including broad image, low radiation dose and ability to be taken on patients unable to open their mouths. The disadvantage is the image's lack of anatomic details (Ziccardi and Ochs 1995). With this radiography, fractures at the mandibular neck (upper subcondyle) and base of the condylar process (lower subcondyle) can be clearly recognized. Panoramic views also show shortening of the posterior mandibular height, and demonstrate the relative displacement of the upper fragment relative to its articular fossa (Lee, Mueller et al. 1998).

But unfortunately, Panorex radiographs cannot indicate the exact angle and direction of displacement, and unable to demonstrate the fracture override position, however the Clementschtsch view often provides this information (Lee, Mueller et al. 1998). This view is particularly helpful for evaluating displacement of the condyle, and for determining the mediolateral position of the condyle segment.

The typical radiographic findings when a condylar fracture is present are the following: a shortened ramus length; the presence of fracture line or, in the case of overlapped segments, the presence of a radiopaque double density, and evidence of premature contact on the side of the fracture, if the radiograph is taken with the patient in occlusion (Raustia, Pyhtinen et al. 1990). Conventional X-ray is no longer the standard in radiological imaging for cranio-facial trauma detection, and computed tomography (CT) is regarded as the gold standard for the radiographic evaluation of fractures of the mandibular condyle process (Roth FS et al . 2005). For midface fractures, CT images are obligatory to differentiate fracture types and to differentiate the extent of the fracture

(Book „*Craniofacial Trauma*“ N. Hardt, J. Kuttnerberger. 2010). If more accurate information of the condylar fracture is required, CT scans /computed tomography/ in axial and coronal planes supply a sufficient means of diagnosing the fracture details (Chacon, Dawson et al. 2003).

CT is very useful and recommended for showing displacement, override, condyle head dislocation, and the angle of condylar fractures (Schimming, Eckelt et al. 1999; Kellman 2003). The advantages of CT include that it provides images of fine-cut slices (1-2 mm thick), solving the problem of the overriding of structures, occurring on plane radiographs (Booth PW, Schendel S, Hausemen J-E, 2006, Book). Following this, CT is indicated if no fracture is seen on the conventional images and if fracture symptoms persist, moreover coronal CT scans permit adequate analyses of fracture lines and fracture types, making for to more effective treatment (Schimming, Eckelt et al. 1999).

Three-dimensional CT reconstruction has been playing an increasingly important role of diagnostic imaging in the head and neck (Fuhrmann, Wehrbein et al. 1993).

3D CT reconstructions greatly facilitate the surgeon's understanding of the patient's morphology, simplify the overall visual option and assist surgical management planning (Levy, Edwards et al. 1992; Zinreich 1992). Continuous efforts to develop the diagnostic methods in oral and maxillofacial surgery in recent years have led to an increasing need for three-dimensional digital imaging (Arai, Tammsalo et al. 1999). Digital volume tomography (DVT) is a new imaging technique used in the maxillofacial area. The patient's head is placed between an X-ray generator and an X-ray detector which rotate around the patient's head. The initial data is presented for primary reconstruction. After this initial reconstruction, further secondary reconstructions, such as sagittal, coronal and para-axial cuts and 3D-reconstructions can be generated (Ziegler, Woertche et al. 2002). DVT is a new technique which offers 3D images with a quality similar to that of CT with high geometric accuracy in all spatial planes, lower radiation dose, less metallic artifacts, and lower cost compared with CT (A. Dini, N.Sakkas.2006). Choudhary have found significantly increase in the detection of fracture lines and visualization by the use of DVT in the midface and mandibular condyle region compared with conventional radiographs, and thus thanks to its lower radiation dose than CT, DVT has been recommended for general use in dentomaxillofacial for 3D imaging instead of conventional radiography (Choudhary, Motwani et al. 2011). Also especially for operative reduction and rigid internal fixation of condylar process fractures, and

because operative access is limited, precise postoperative control is essential (Ellis, McFadden et al. 2000; Meyer, Zink et al. 2008). The postoperative imaging data must be examined, the focus being on the possible and degree of secondary displacement, accuracy of fracture reduction, resorption or erosion of the condylar head, control the process of bony ossification, and on checking for morphological changes of the osteosynthesis material (Lee, Lee et al. 2010; Singh, Bhagol et al. 2010). For the reasons mentioned above, and in view of the fact that postoperative conventional radiographs such as orthopantomographs depict factors which increase the risk of osteosynthesis failure (Seemann, Undt et al. 2011), and according to DVT advantages, we have adopted the DVT as a radiological control after surgery (Figs. 5).

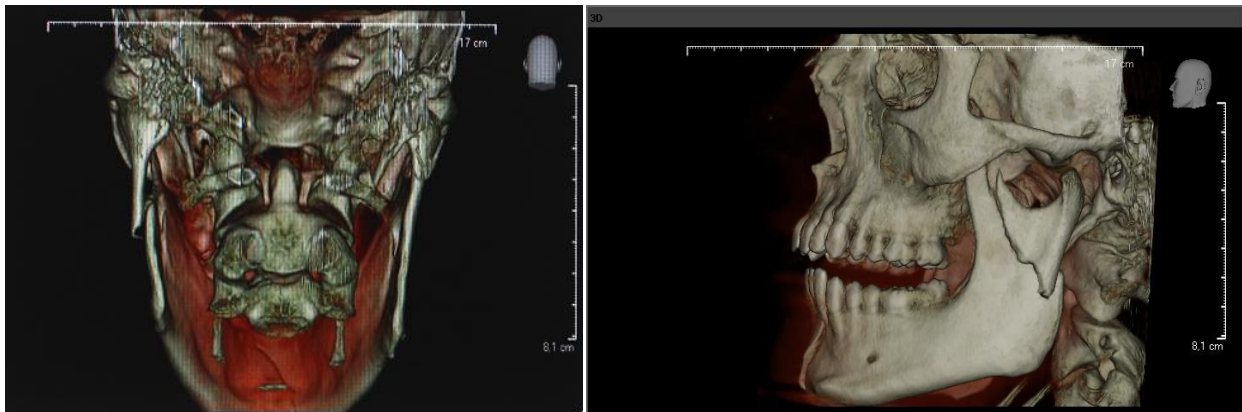


FIG . 5 - Low dislocated subcondylar fracture 3D DVT – view (From Charité University of Medicine in Berlin, Germany)

1.8 Treatment of mandibular condyle fractures

suitable management of the fractured mandibular condyle is among the most controversial issues in maxillofacial trauma (Cascone, Spallaccia et al. 2008), creating a wide variety of opinions and proposed treatment modalities. Ideally, treatment of condylar fractures must realize three main aims: consolidation of the bony fragments (Walker 1994), anatomic correction of the segments (a consensus. (1998), and restoration of joint function which typically involves pain-free movement (Walker 1994), mouth opening beyond 40 mm (Girthofer and Goz 2002) and the restoration of the preoperative occlusion and facial symmetry (Rasse M, 2000). Of these three goals, the

restoration of joint function is the most important (Fonseca. 2000), (Park, Jang et al. 2010). In the literature, we can in principle distinguish between three main therapeutic approaches to the condylar process fractures of adults: 1) a period of maxillomandibular fixation (MMF) followed by functional therapy; 2) functional therapy without a period of MMF; and, 3) open reduction with or without internal fixation (Ellis and Throckmorton 2005). The therapeutic choice must be selected based on very important physical and imaging evidence and requirements such as: level of the fracture, loss of ramal length, uni- or bilateral fractures, occlusal state including completeness of the dentition, the dental malocclusion and mandibular dysfunction, degree and direction of displacement or dislocation, presence of concomitant maxillofacial fractures, complexity of surgical approach, risk of hypertrophic and/ or keloid scarring, the clinical experience of the surgeon, patient's age, general state, and willingness to be operated, and possibility of providing physical therapy (Ellis, Throckmorton et al. 2000; Villarreal, Monje et al. 2004). The level of condylar fracture has a major effect on the selection of a method of treatment and is one of the most important factors, the degree of the displacement is the second most important variable for selecting method of therapy (Hayward and Scott 1993; Yamaoka, Furusawa et al. 1994; Villarreal, Monje et al. 2004). The advocates of surgical treatment are convinced that this make it possible to achieve the correct restoration of the condylar process, and to re-establish the optimal function of the jaw. The proponents of conservative treatment believe that the selective exercises lead to functional adaptation of the bony structures and the surrounding soft tissues (Umstadt, Ellers et al. 2000).

1.8.1 Conservative Treatment of condylar fractures

Conservative therapy generally focuses on the bloodless nonsurgical repositioning of the fracture fragments, with intermaxillary or extraoral splintings helping to reduce and fixate of the fracture (Spiessl und Schroll 1972; Becker und Austermann 1990). some surgeons believe that conservative therapy should be considered as the first choice for the management of condylar fractures (Smets, Van Damme et al. 2003; Villarreal, Monje et al. 2004) because as long as there is contact between the fracture fragments, union will occur with a satisfactory functional outcome (Villarreal, Monje et al. 2004), although there is no exact anatomical repositioning (Joos and Kleinheinz 1998). An anatomical accurate reduction of the fracture fragments is not possible, because they

are only surgically accessible (Oezmen, Mischkowski et al. 1998); instead, it relies on the functional remodeling capacity in the TMJ area (Dahlstrom, Kahnberg et al. 1989). Also as arguments for a conservative approach, the proponents of conservative management claim that the risk of resorption and deviation of the condylar segments through the surgical method is increased as a result of unsatisfactory reduction of the condylar fragment and rigid fixation in a non-physiological position, due to increased functional load (Iizuka, Lindqvist et al. 1991). Thus, an opportunity results of conservative therapy related to: a growing patient up to adolescence, slight dislocation of the fractured fragment, and an intact occlusion (Yasuoka and Oka 1991). The conservative therapy is indicated in almost all condylar fractures in children (Gundlach, Schwipper et al. 1991), in highly and slightly dislocated or undislocated condylar neck fractures (Valiati, Ibrahim et al. 2008), and if patient's medical history contraindicates for open therapy of fractures (Zachariades, Mezitis et al. 2006). conservative management of condylar fractures ranges from observation and prescription of a soft diet to variable periods of immobilization followed by intense physiotherapy (Moss. 1998).

In the pure conservative management of the condylar process, efforts should be achieved to optimal adjustment of occlusion, followed by splints and intermaxillary fixation (IMF) with arch bars, eyelet wires, or splints to achieve initial fibrous union of the fracture segments (Banks 1998). Immobilization re-establishes or maintains normal occlusion and relieves posttraumatic pain (Ikemura 1985). Nevertheless, if the patient is able to maintain a normal occlusion with a minimal amount of discomfort, no immobilization is required and active physiotherapy with close follow-up will be enough (Zachariades, Mezitis et al. 2006). The length of the period of IMF varies widely depending on the type of fracture, the degree of condylar dislocation (Cascone, Sassano et al. 1999), and the age of the patient (Walker 1994). The duration of IMF ranges from about two weeks (Kleinheinz, Anastassov et al. 1999; Eckelt, Schneider et al. 2006) to three (Feifel, Albert-Deumlich et al. 1992) or four weeks (Hirschfelder, Mussig et al. 1987). However, in adults, some surgeons recommend 6 weeks of IMF in the case of very low fractures depending on the fact that, in general, the lower the fracture, the longer the period of IMF recommended (Lachard, Guilbert et al. 1981). Moreover, early mobilization of the jaw and functional adaptation is essential to prevent complications such as muscular atrophy, joint hypomobility, and ankylosis TMJ (Killey. 1974). The importance of functional rehabilitation after condylar fracture treatment is equally necessary for both conservative and operative strategy.

Ellis suggested that it is better to describe closed therapy of condylar fractures as a technique of functional adaptation (Ellis and Throckmorton 2005). In recent years, various surgeons have been increasingly reporting that functional adaptation allows adequate stimulation of condyle growth (De Riu, Gamba et al. 2001), remodeling of a new TMJ (Rasse 2000), and preventing scar formation and their resulting contractures of the masticatory muscles. There are several basic means of functional adaptation management including physiotherapy and extra- or intraoral appliances. physiotherapy can comprise many exercises, which include mouth opening motions in front of a mirror (Choi 1997), closing the mouth in maximum occlusion (Hovinga, Boering et al. 1999), protrusive exercises (Donoff and Roser 1973), chewing on a chewing gum (Crivello 2002), mastication on the non-fractured side (Sahm 1988), etc . Exercise can be active (Neff, Kolk et al. 2002) or passive (Bottini, Gnoni et al. 2006) with the help of tongue blades (Palmieri, Ellis et al. 1999). The standard duration of physiotherapy up to twelve weeks has been recommended by some authors (Umstadt, Ellers et al. 2000).

Additionally, appliances used in the management of condylar fractures such as posterior bite blocks (Villarreal, Monje et al. 2004), guiding elastic traction, and splints (Basdra, Stellzig et al. 1998), may support the positioning of the mandible in relation to the maxilla (Proffit, Vig et al. 1980).

Finally, nonsurgical management may take longer (Defabianis 2003) and can be accompanied with more complications than surgical reduction, thereby increasing the work on physicians and stress on patients (Schendel, Wiesinger et al. 1991). It demands close observation of the patient (Crivello 2002), and a high level of patient cooperation (Walker 1994). Also malocclusion, limited movement, chronic pain and discomfort, asymmetry are occasionally associated with nonsurgical management regardless of the type of fracture (Brandt and Haug 2003).

1.8.2 Open Reduction of the Fractured Mandibular Condyle

Operative surgery means principally the exact anatomical reduction of the distal fragment and at the same time retention and internal fixation of the fracture by means of functionally stable osteosynthesis. conventional logic suggest that a reduction under direct vision should help to get maximal accuracy, however, previously most surgeons

were compelled to use nonsurgical methods, because of the tradition and experience of physicians and their belief in the difficulty of the anatomical location and risks posed by the surgical technique (Lee, Lee et al. 2010). The debate between the supporters of open or closed reduction is still continuing and the issue has not been resolved, not a consensus reached. While the advocates of nonsurgical management rely on the remodeling ability of the TMJ and targeted exercise therapy to reach the pre-traumatic situation. the proponents of surgery list the main arguments for surgical approach, which include re-establishing the exact anatomical reduction to achieve the favorable conditions required for optimal restoration of function (Rasse 2000), to allow primary healing of unreducible or unstable fractures, to avoid IMF (Valiati, Ibrahim et al. 2008), with a good possibility of quick restoration of functional activity, maintenance of face symmetry, and less long-term TMJ malfunction (Choi, Huh et al. 2003). However it seems difficult to evaluate an operation as successful in terms of the reconstruction of the preoperative situation, because there are no comparable data on a patient's condition before the accident, therefore the following are some of the criteria suggested for assessing the success of outcomes (Bos, Ward Booth et al. 1999):

- Restoration of the pre-injury occlusion
- normal mouth opening (about 40 mm)
- pain-free joint, or no worse than pre-injury
- absolutely minimal morbidity of surgery, e.g. no damage to the branches of the facial nerve, well-hidden scars, no aesthetic complications.

The development of plate and screw devices and improvement of minimally invasive surgical techniques in the treatment of TMJ fractures have made it possible markedly to improve the results of open reduction versus closed treatment and for surgeons to become more comfortable with open approaches (Eckelt, Schneider et al. 2006). For these reasons, there has been a rise in recent years in the number of surgically operated condylar fractures (Landes and Lipphardt 2005). Because the operative therapy is not universally adaptable, the choice of treatment must be made individually (Eckelt, Schneider et al. 2006).

1.8.3 Indications for open reduction of condyle fractures

Reports of indications and contraindications for open reduction abound in the literature, but regretfully, indications for the therapy of condylar fracture have remained

contradictory among different investigators (Brandt and Haug 2003), because they were based on the materials and surgical technique available at each point in time, and to date, no agreement or general consensus exists on the indications for using the surgical technique for the condylar process in adults (Biglioli and Colletti 2008). However, as the complexity of the fracture increases, the tendency to treat surgically in general rises, taking into account the different individual definitions of fracture complexity from surgeons to other (Hochban, Ellers et al. 1996). The consensus conference in 1997 of IAOM- FS recommended that the correct selection of management should consider primarily the extent of displacement or condyle dislocation (1998; Bos, Ward Booth et al. 1999). However, a review of recently published studies demonstrated a tendency to operate a displaced and dislocated fractures (Eckelt 2000; Jing, Sun et al. 2001; Haug and Brandt 2007). The question as to the degree of displacement and angle of dislocation of the proximal fragment at which open reduction becomes appropriate than the nonsurgical method remains controversial. Kleinheinz reported that closed treatment in adults with 37 degrees of dislocation or more, or with shortening of the ascending mandibular ramus of more than 4 mm is unable to support a tilted fragment to an upright position (Kleinheinz, Anastassov et al. 1999). Admittedly, the indications remain controversial. Hans Henning– Horch summarized the indications as absolute and relative (Hans Henning- Horch (Hrsg), 2007, book). **Absolute** indications for the use of an open technique in subcondylar fractures are as follows:

- high grade of dislocation (loss of condyle–discus–fossa-relation).
- significant displacement ($> 30^\circ$ and/or vertical – loss > 4 mm (Joos and Kleinheinz 1998) or 5 - 6 mm (Eckelt 2000).
- considerable diastasis of the fracture plane and intervening of soft tissue, which lead to non-union or pseudarthrosis.
- inability to achieve adequate occlusion by conservative therapy (Joos and Kleinheinz 1998).

Relative indications of surgical treatment of subcondylar fracture in adults:

- when associated with comminuted mid-face fracture, so that the vertical support by mandibular joint is not ensured (Eckelt 2000; Neff, Kolk et al. 2005).
- medical indications prohibiting intermaxillary fixation (Joos and Kleinheinz 1998).
- bilateral fractures in edentulous jaw (Joos and Kleinheinz 1998).
- displaced condyle with edentulous or partially edentulous mandible with posterior bite collapse (Valiati, Ibrahim et al. 2008).

- multiple fractures in the mandible (Horch und Herzog, 1992).

However the authors themselves state that the "relative indications are arguable and patients may be treated differently by each surgeon"

At the University Hospital Charite Berlin, surgical treatment is generally performed when a condylar fracture causes anatomical and functional problems as follows:

- displaced and /or dislocated fractures of the extracapsular condyle region classified as types II to V according to Spiessl and Schroll, so that we adopt Schneider's results according to which fractures with a deviation of more than 10°, or a shortening of the ascending ramus of more than 2 mm should be treated with open reduction and fixation, regardless of the level of the fracture (Schneider, Erasmus et al. 2008),
- insufficient contact of the fragments
- when dental malocclusion causes functional problems,
- loss of chin projection, and asymmetry at rest and/or in function (Martin and Lee 2003),
- no severe comminution,
- enough room is available for plate and screw fixation (Sawazaki, Lima Junior et al. 2010) and
- in adults no medical contraindications for surgery (Valiati, Ibrahim et al. 2008).

1.8.4 Surgical approaches to the fractured Mandibular Condyle

Over the years, many approaches to the TMJ have been developed, including intraoral, preauricular, submandibular, retroauricular, and retromandibular approaches. Each has its own advantages, disadvantages, and complications (Giroto, Mancini et al. 2011). However, although several attempts have been made to reach a common position, (1998; Bos, Ward Booth et al. 1999), no consensus exists on the surgical techniques for condylar fracture treatment. Different surgeons prefer different approaches according to their experience with the technique and their personal beliefs (Biglioli and Colletti 2008). Moreover, many factors, such as the anatomical level of condylar fracture, degree of dislocation, presence of other fractures, the type of osteosynthesis to be applied (Schneider, Lauer et al. 2007), and last but not least cosmetic consideration influence the choice of a surgical method (Klatt, Pohlenz et al. 2010). Ideally, the selected approach should consider the following criteria (Eckelt 2000):

- it should allow a maximum view of the fracture region.
- it should facilitate and enable a secure repositioning of the fragments.
- it should avoid permanent damage to the branches of the facial nerve, to major vessels (e.g., internal maxillary artery, retromandibular vein), and to the parotid gland.

- it should maximize the use of natural skin creases for cosmetic wound closure and, if possible leave no visible scar.

Retro-mandibular approach :

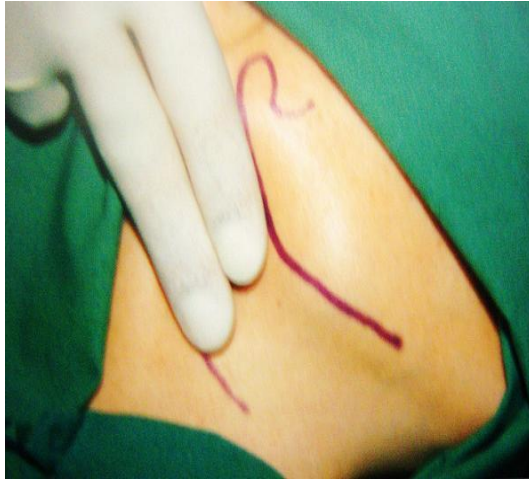Retromandibular access was first described in 1967 for vertical subcondylar osteotomy and it later became prevalent in surgical treatment of TMJ dysfunction and low condyle fractures. Hinds et al considered it the best approaching for subcondylar fractures (Hinds and Girotti 1967). This incision is best placed in a skin fold with 4 to 5 cm length, the line begins 1cm below the lobe of ear and 1cm posterior to ramus of mandible. Parotid gland is retracted anteriorly and masseter muscle are separated to reach fracture gap. Girotto et al reported that this incision is a safe approach, and it takes little time to perform the operation. Moreover, the distance to the fracture site is short, and compared to the submandibular approach, it allows a closer view of the mandibular ramus and condylar process (Girotto, Mancini et al. 2011). But the retromandibular approach can be associated with some risk of damage to the facial nerve fibers and gland tissue, which is reported in approximately 19.3-30% of the cases (Ellis, McFadden et al. 2000; Manisali, Amin et al. 2003). The facial nerve injury is a result of a retraction of the parotid gland from its posterior or inferior lobe to expose the fracture site and consequently facial nerve compression can be caused by the retractor during surgery (Tang, Gao et al. 2009).

Submandibular approach:

This approach (fig.6a) is the best suitable and most appropriate method of dealing with fractures of the condylar neck and of the base of the condyle (Schneider, Lauer et al. 2007). It was first described by Perthes (1924). The incision is 4 to 5 cm long in the skin crease line two finger-breadth about 3 cm below the mandibular angle (Eckelt 2000). The initial incision is made sharply through the skin and subcutaneous tissue down to the platysma. About 1 cm below the mandibular border dissection is continued in layers, going carefully through the platysma and the deep cervical fascia, testing for the marginal rami of the facial nerve, which could also be identified using a nerve stimulator. If the nerve is detected, it can usually be retracted superiorly. The pterygomasseteric sling is divided at the inferior border of the mandible, and the periosteum is incised to expose the fracture site. The submandibular approaches allow for good fracture treatment, but present some risk of damaging the mandibular branch of the facial nerve

(Kallela, Soderholm et al. 1995), so that the rate of facial nerve damage using this approach can reach up to 37% according to (Manisali, Amin et al. 2003), another major distinct disadvantage is the distance between the incision and the condylar neck (Eckelt 2000), that requires greater pressure from the retractor on the soft tissue to facilitate the application of the osteosynthesis. **Risdon** have modified the submandibular incision, so that the classic Risdon incision is more posterior and vertical near the angle of the mandible compared with the traditional submandibular incision. Dingmann and Grabb have studied the course of the marginal mandibular branch of the facial nerve (Dingman and Grabb 1962). In 81% of the cases the nerve passed above the inferior border of the mandible proximal to where the facial artery crossed the inferior border of the mandible. In 19% of the cases the nerve passed a maximum of 1 cm below the inferior margin of the mandible. For the same reason, that the marginal branch runs as much as 1 cm below the inferior border of the mandible, Kruger (1990) recommended making this incision at least 1.5 cm below the inferior border of the mandible in a skin crease below this area.

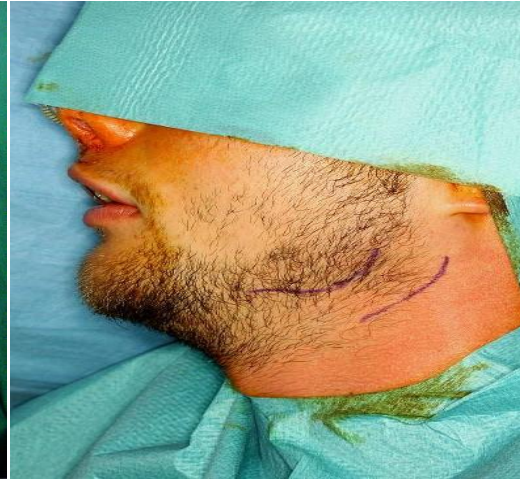We systematically use in the Charite Berlin Hospital an open approach derived from the classical Risdon approach and retromandibular access for better nerve and gland protection (fig.6b). It is a combination of two classic approaches to access all low subcondylar fractures and most high subcondylar ones. A curvilinear incision approximately 3 to 5 cm is placed 1.5-2 cm below the edge of the angular region and curved superiorly in best cosmetic conformity parallel to the mandibular ramus and extended similarly to retromandibular access to approximately 2 cm below the lobe of the ear. Our approach requires little time to reach the fracture gap and allows direct access to the condylar neck region by reducing the size of the upper flap and also offers a better view of the fracture compared to the intraoral and submandibular approaches. Additionally, our approach, in comparison to the retromandibular access, has the advantage of not dissecting through the parotid gland, and thus the occurrence of salivary fistula and facial nerve damage, especially through plane-by-plane dissection, can be considerably minimized.



(FIG.6a) submandibular approach

3 cm below the edge of mandible

(Book by Johannes Kleinheinz, Christophe Meyer, Fractures of the Mandibular condyle; Guintessence, 2009)



(FIG.6b) Risdon approach

skin incision 1.5 cm below the edge of the mandible angle

(From Charité University Hospital)

Intraoral approach :

It was described by Sear (1972) for removal of hyperplastic condyles (Sear 1972). It is a minimally invasive approach, which should be considered as an advantage in maxillofacial surgery. An intraoral approach is possible 3 to 3.5 cm in length, through a vestibular incision similar to that used for intraoral vertical ramus osteotomies. It is indicated only for very minimally displaced low fractures, when the fracture line is running through the sigmoid notch or deeper (Bos, Ward Booth et al. 1999).

Extraoral approaches have the risk of facial nerve damage and can produce visible scarring, which is why some surgeons prefer the transoral access to avoid such possible complications (Jacobovicz, Lee et al. 1998; Kellman and Cienfuegos 2009). However, an intraoral access can be technically complex, especially in the case of fractures at higher levels or with medial dislocation of the proximal fragment. Even with the aid of an endoscopic guidance, the technique requires special instruments, intensive training in endoscopic techniques, and long duration of the operation, which can take up to 143±63 minutes (Lee, Mueller et al. 1998; Klatt, Pohlenz et al. 2010; Park, Jang et al. 2010). Moreover, some investigators have reported that the intraoral access is associated with a greater degree of complications compared with extraoral approaches (Jensen, Jensen et al. 2006; Schneider, Lauer et al. 2007). These complications include

condylar head resorption, permanent postoperative occlusal distribution, TMJ dysfunction, and secondary displacement and shortening in the fractured site (Biglioli and Colletti 2009).

These possible complications may be often attributed to the difficulty in intraoperative control of the correct position of the fragments because of the relatively poor and limited visibility, take of surgical skill in this technique, and difficulty in application of double plates as a result of limited space .

1.8.5 Methods of internal fixation Osteosynthesis

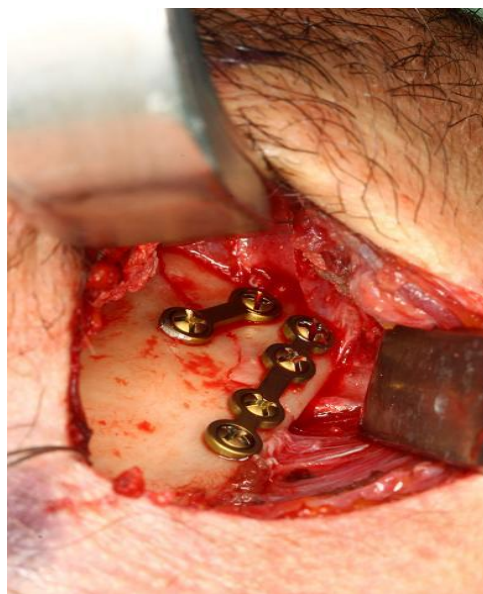up to the present day, there is no consensus on optimal plating systems for condylar process fracture (Tominaga, Habu et al. 2006). The proper choice is dependent probably on the individual experience of the surgeon with any given system (Bos, Ward Booth et al. 1999), the fracture localization and the selected surgical approach (Schneider, Lauer et al. 2007). As a general rule, the smallest amount of hardware that will achieve functional stability should be used. In spite of availability of different forms and types of rigid fixation devices for condylar fractures (i.e., plate and screw, lag screw, lag screw combined with plate), the miniplates and Lag screws play a significant role here.

Miniplates Osteosynthesis :

The miniplate osteosynthesis system was developed and modified by Champy and his coworkers (Champy, Lodde et al. 1977) (Champy, Lodde et al. 1976). Based on the theory of neutralization of tension forces that physiologically occurs in “ideal lines of osteosynthesis” (Michelet, Deymes et al. 1973), the original goal in this kind of osteosynthesis is to get stable anatomical reduction of mandibular fractures without the need for interfragmentary compression or maxillomandibular fixation so that the absolute rigid fixation is not a prerequisite for the healing of the fracture. Champy recommended that a single noncompression miniplate with monocortical screw be placed over the tensile side of the mandible. Usually a four- to six- hole 2- mm single adaptation miniplate with at least two screws on each fracture segment should be applied vertically along the lateral posterior border of the ramus, utilizing its thick cortical bone and flat surface (Haug and Assael 2001; Hyde, Manisali et al. 2002).

Various investigators confirmed that there is evidence of a high rate of complications associated with the single plate technique (up to 35%), including, plate deformation,

plate fractures, screws loosening and structural instability (Sugiura, Yamamoto et al. 2001; Rallis, Mourouzis et al. 2003; Seemann, Schicho et al. 2007). On the other hand, many studies suggest a new concept, which involves the application of two condylar process plates in combination instead of one miniplate to ensure greater primary stability, also to protect the first plate from mechanical overloading, and thus to avoid secondary displacement and implant complications compared with the use of a single plate (Rallis, Mourouzis et al. 2003; Schmelzeisen, Cienfuegos-Monroy et al. 2009; Parascandolo, Spinzia et al. 2010). This new concept is based on the fact that there are tensile and pressure forces, which are exerted on the mandibular condyle region during mastication (Meyer, Kahn et al. 2002), and consequently one miniplate in some conditions will not provide adequate strength to resist the physiological tension occurring in this area during mastication (Meyer, Serhir et al. 2006). The first plate is positioned in the posterior-lateral border of the ramus as usual, respecting the vertical lines of compression in this region, while the second plate with at least one screw on each side of the fracture is obliquely placed over the tension strain lines occurring under the mandibular notch (Figs. 7) (Parascandolo, Spinzia et al. 2010) . Rallis et al reported the cost of additional plate and longer operation time as disadvantage of the two plating concept (Rallis, Mourouzis et al. 2003).



(FIG.7) position of two plates used to stabilize a left subcondylar fracture (the posterior plate is on the posterior ramus edge **(From Charité University medicine)**).

Lag screw osteosynthesis:

Axial anchor lag screws are an alternative to plate fixation of condylar fractures. It is a type of osteosynthesis in which absolute interfragmental functional compression is produced by screws that transfix the fracture gap with the possibility for easy removal of the element without re-exposure of the TMJ area. This method was modified by Eckelt and Graber 1981, which includes a set of lag screws of different diameters and lengths (Eckelt and Gerber 1981). A lag screw is characterized by the presence of threads only at the terminal end so they can engage the proximal condylar fragment and provide interfragmentary pressure upon tightening, while the head sets against the near cortex. Advantages of lag screw fixation include stability, rapid application, and ease of hardware removal. The disadvantage lies in the limited scope, because this system cannot be used with very narrow or short mandibular ramus, if the mandibular bone is heavily damaged (Welk and Sumnig 1999).

1.9 late sequel and prognosis after condylar fracture

The prognosis of condylar treatment is dependent on the following criteria (Ellis, Palmieri et al. 1999; Neff, Kolk et al. 1999; Zachariades, Mezitis et al. 2006; Schneider, Lauer et al. 2007):

- Manner and severity of the TMJ trauma.
- Concomitant injury in the maxillofacial region
- severity of associated soft tissue injury.
- Starting point of therapy.
- Type and duration of post-operative care .
- Occlusal and functional conditions present prior to the accident.
- patient age.

Despite all therapeutic efforts for treatment of condylar fracture and whether they are treated surgically or nonsurgically, a variety of short- and long-term complications can be seen with treatment of these fractures (Ellis 1998). These risks include pain, edema, bleeding, infection, healing failure, nonunion, malocclusion and malunion. malunion is defined as a healed bone that is not in exact proper anatomical alignment, which can result from poor reduction of the fragments or it can occur with late-treated or untreated fractures. This malposition leads to a shortening in the mandibular ramus. In the case of bilateral condylar fracture there is in particulate, a risk of an open bite.

The most common late risks are the functional disorder of TMJ, including joint sounds, stiffness of the jaws, difficulty in opening, decreased lateral excursive ability (Widmark, Bagenholm et al. 1996). Additional problems vary with the approach used and the techniques employed to fix the condylar fragments.

2. Aim of the study

The aim of this study is to quantify the patient benefit and to analyse retrospectively the functional and radiographical results 6 months after open reduction of the subcondylar fracture using the modified Risdon approach which includes: evaluation of the adequacy of repositioning the fractured condylar process, determination whether the internal fixation by miniplate osteosynthesis provided satisfactory stability over the first 6 months, the viability of the modified Risdon approach in reducing condylar process fracture, and its morbidity owing to the risk of facial nerve damage, the cosmetic outcome, use and duration of IMF, dysfunction of TMJ, and the number of complications.

3. Materials and Method

The study protocol was approved by the Ethics Committee of the Charité University Medicine in Berlin, Germany.

3.1. Patients and the distribution

A total of fifty-four treated patients with condylar neck fractures (12 females and 33 males) between 2008 and 2011 participated in this retrospective study. The patients were operated at the Department of Oral and Maxillofacial Surgery, Charité University of Medicine in Berlin, Germany. Of the 45 patients, 4 presented with bilateral condylar fractures for a total of 49 fractures.

3.2. Type of participants

The main inclusion criteria for this study included:

- Age of patients older than 18 years
- Unilateral or bilateral fracture of the condylar neck of the mandible
- no previous history of TMJ dysfunction.

While patients with the following criteria were excluded :

- patients with intracapsular fractures
- severe pretraumatic skeletal dysgnathia of the jaws
- patients with mental deficiency.

Patients who match the inclusion criteria were invited 6 months after surgery in writing for a follow-up (patient letter, see Appendix). If the patient failed to meet the appointment, a new invitation was sent. If the patient did not respond 2 weeks after sending the second letter, patients were contacted by phone in order to find out if, they are willing to participate in the study. We could only follow-up 47% of the registered patients (45/95) in our investigation, 53% failed to appear due to a change of address or could not be reached by phone or because of patient's refusal to undergo checkup.

3.3. Time of Follow-up

Follow-up examinations were performed a minimum of 6 months after surgical treatment, because it was believed that most fracture should have healed, and most of facial nerve weakness resolved by that time (Ellis 1998).

3.4 Methodology of Follow-up

The follow-up comprises making a general clinical anamnesis and clinical investigation of functional parameters according to the Research Diagnostic Criteria for Temporomandibular Dysfunction (RDC/TMD) (Schmitter, Ohlmann et al. 2005; John,

Hirsch et al. 2006). This protocol was selected for this study because of its proven scientific reliability in discovering TMD or late complications, such as pain or clicking of the (TMJ). The subjective assessment of complaints was documented by means of a questionnaire, which included an anamnesis, a measurement form, and a clinical examination (RDC/TMD). Also in the preparation of the follow-up, postoperative x-rays were measured and assessed, and the results were recorded in a database.

3.4.1 Anamnesis and subjective assessment of treatment outcome

The data collection was carried out using a standard questionnaire of the Charité University of Medicine Berlin according to the following terms of reference and summarized in the tables:

- In the first part , the personal data of the patients were recorded, including age at time of surgery, gender, etc.
- In the second part, the special general medical anamnesis, which may affect the results, was recorded. The anamnesis is important in the evaluation of the physiological status of the patient as e.g. smoker [yes/no], dental status, cause of the fracture, etc.
- In the pre-operative section, the fracture classification and all fracture related-findings such as, fracture localization [high or low], fracture displacement with the measured physical overlap, existence of a dislocation with the direction and the measured angle of anteroposterior and/or mediolateral tilt of the condylar fragment in the panoramic mandibule and open mouth Towne's radiograph preoperatively, the facial concomitant fracture, etc. were documented.
- In the operative section, information was collected about, age of fracture at time of surgery, duration of surgery, whether the operation is performed by a surgeon inexperienced in the access, about the antibiotics, the system used for internal fixation, plate size (e.g. four holes), and the use and duration of IMF [yes/no], etc.
- The "post-operative" part provides information on the duration of hospitalization, possible complications such as infection, bleeding, osteosynthesis removal [yes/no], etc.

Then each registered patient was handed their individual questionnaire. The questionnaire contains 14 questions in which several response options were offered to the patient in order to allow differentiation of the intensity to the perceived impairment. The patients were asked about levels of pain or discomfort associated with maximum

mouth opening, pain during chewing, satisfaction with residual scar, and changes in tactile sensitivity in certain areas of the face. then the severity of pain or discomfort levels were recorded through use of 3-point Likert –type scales in a score of I to III as follows (see Table 1):

No complaints	Slight complaints	Severe complaints
I	II	III

Table 1: Subjective assessment options of complaints

The patient is requested to indicate whether the problem was already noticeable before the injury, or whether it was related to the fracture or its treatment. This enabled us to make a comparison with the pre-operative situation. the patient was also asked if there was any limitation in mouth opening, impairment of mastication, joint cracking or muscle pain while chewing, pre-contact in occlusion, the need to modify or renew the dental denture, change in facial expression, and most importantly the patient’s satisfaction with the therapy outcomes. This anamnestic dysfunction test was answered by the patient with "yes" or "no". The information thus obtained allowed the patients to be classified based on dysfunction anamnesis indexes.

3.5 clinical examination

The assessment of treatment outcomes after mandibular condylar fractures requires particular clinical findings, which summarize the function of the TMJ and the mandible and allow the comparison. The clinical examination of all patients was performed by the same physician in order to avoid an interindividual difference of the reading of the findings.

3.5.1 Evaluation of occlusal status

First, regarding the examination of occlusal status, the assessment of occlusive support in the molar region was given particular consideration. The first panoramic radiographs after surgery were used to assess the occluding of posterior teeth on both the fractured and nonfractured sides, so that the classification is considered as insufficient support

zone when the dental posterior region (molars and premolars) guarantees no supporting role to the vertical bite relation. We used the Eichner classification (questionnaire, see Appendix), which considers and concentrates on the antagonistic contact between the molars and premolars, while the anterior teeth remain in the occlusive supportive view unconsidered.

The occlusion was assessed as carefully as possible by the same investigator. Malocclusion was considered only if the patient complained of occlusal deficiencies postoperatively. However, no attempt was made to quantify any malocclusion.

3.5.2 Helkimo TMJ dysfunction index

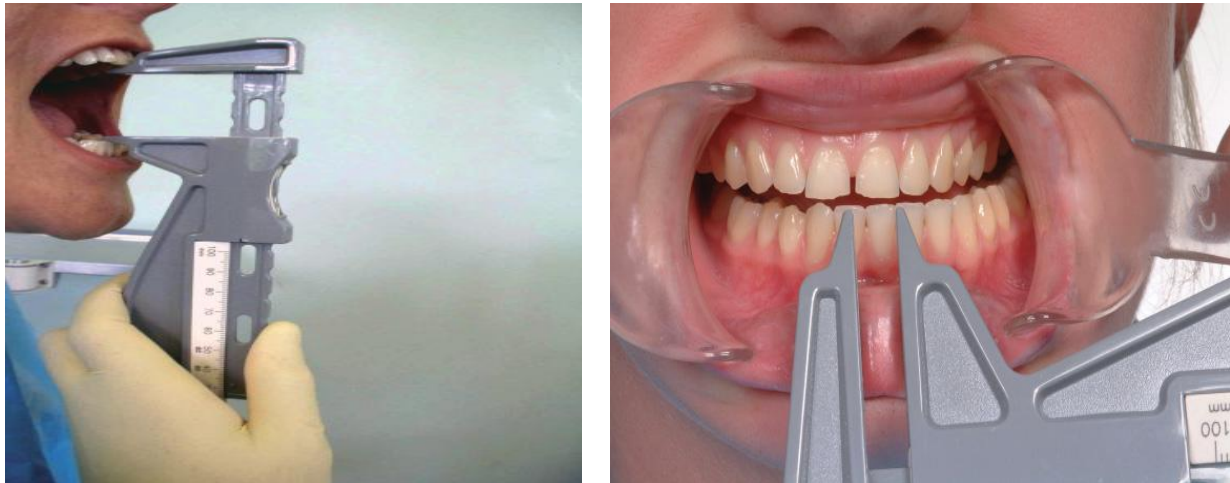The investigation of TMJ function is based on the Helkimo dysfunction index. The Helkimo dysfunction scoring protocol consists of 3 indexes to evaluate and measure anamnestic, clinical dysfunction, occlusion and articulation defect. It is an accepted system to determine the functional results after surgery of mandible and TMJ disorders (Widmark, Bagenholm et al. 1996; Ellis, Simon et al. 2000).

The clinical symptoms in this index are summarized in a points system for a total evaluation for five subgroups (Jaw mobility, TMJ function, palpation of masticatory muscles, palpation of the TMJ, pain by moving the mandible), so that according to Helkimo (Helkimo 1974) the most frequent signs of TMD include reduced movement of the mandible, reduced TMJ function, pain when moving the mandible, muscle pain and pain in the TMJ. TMD was defined as the presence of one of the five signs cited. There are four grades of clinical dysfunction: no signs, light, medium, and severe dysfunction. Scores were determined in compliance with a three-level scale of acuteness, the following score was assigned: 0 points for absence of symptoms, 1 point for mild pain, 5 points for an acute symptom.

3.5.2.1 Range of mandibular motion:

During the assessment of the range of motion, the patient is requested to fully open the mouth, and then patient's maximum opening from incisal edge to incisal edge at the midline should be measured with a millimeter rule. Maximum lateral excursive movements should also be measured, and any accompanying pain should be noted, so

that a point is made on the mandibular incisors that matches the maxillary midline, and then the difference between the midline and the mandibular point is measured after maximum laterotrusion (Figs. 8), measurement of protrusion must also be performed. For this measurement, it is recommended to measure the distance between labial surface of the maxillary incisors at maxillary midline when in centric occlusion and again at maximum voluntary protrusion (see Table 2).



(FIG. 8) Method of measuring maximum active opening and maximum lateral movement (From Robin J.M. Gray and M. Ziad Al-Ani: Temporomandibular Disorders: A problem-based approach, 1st Edition 2011, Blackwell, P. 30.)

	Points
Maximal active opening of mouth	
≥ 40 mm	0
30-39 mm	1
< 30 mm	5
Maximal laterotrusion to the right	
≥ 7 mm	0
4-6 mm	1
0-3 mm	5
Maximal laterotrusion to the left	
≥ 7 mm	0
4-6 mm	1

0-3 mm	5
Maximal protrusion	
≥ 7 mm	0
4-6 mm	1
0-3 mm	5

Table 2: score of Range of mandibular motion

The mandibular mobility was assessed using the following Code:

0 points= Mobility index **0** = normal mandibular mobility

1-4 points= Mobility index **1** = slightly impaired mobility

5-20 points= Mobility index **5** = severely impaired mobility

3.5.2.2 TMJ Function impairment: (see table 3)

A	Smooth movement without TM-joint sounds and deviation on opening or closing movements ≤ 2 mm	0
B	TM-joint sounds in one or both joints and/or deviation ≥ 2mm on opening or closing movements	1
C	Locking and/or luxation of the TM-joint	5

Table 3 : Score of TMJ Function impairment

3.5.2.3 Muscle pain during palpation:

muscle palpation is a very important step in the diagnosis of TMD and myofascial pain syndromes (Conti, Oltramari et al. 2007). The palpation is performed using appropriate finger pressure, and the patient is asked, “Does it hurt or is it just pressure?”. The response is positive if palpation produces a clear reaction from the patient, i.e., palpebral response, or if the patient states that the palpation “hurts“, indicating that the site is more tender than the surrounding structures or the contralateral structure (Table 4).

The following bilateral areas were subjected to routine palpatory examination: *m. masseter profundus*, *m. masseter superficialis*, *m. temporalis-pars anterior*, *medialis*, *posterior*, and insertion at the coronoid process, *m. pterygoideus lateralis*, *m. pterygoideus medialis*).

A	No tenderness to palpation	0
B	Tenderness to palpation in 1-3 palpation sites	1
C	Tenderness to palpation in 4 or more palpation sites	5

Table 4: Score of Muscle pain during palpation

3.5.2.4 *TMJ pain during palpation:*

Tenderness to palpation is considered as one of the most important signs in the detection of intracapsular pathologies (Conti, Oltramari et al. 2007). Palpation of the lateral aspects of the TMJ is accomplished with the mouth in half-open position. Palpation of the posterior TMJ capsule is performed anterior to the tragus with maximum opening of the mouth (Dworkin and LeResche 1992) (See table 5).

A	No tenderness to palpation	0
B	Tenderness to palpation laterally	1
C	Tenderness to palpation posteriorly	5

Table 5: Score of Muscle pain during palpation

3.5.2.5 *pain during mandibular movement :*

The patient was asked if he/she felt pain during any mandibular movements and also the source of the Pain was localized (joint or muscle pain). (see table. 6)

A	No pain on movement	0
B	Pain in one movement	1
C	Pain in 2 or more movements	5

Table 6: Score of pain during mandibular movement

The assessment of the five above- named individual scores is proposed in the following grades (table. 7):

Points	Dysfunction group	Clinical dysfunction index
0	0	D0 (no clinical symptoms)
1 - 4	1	D I (mild dysfunction)

5 - 9	2	DII (moderate dysfunction)
10 - 13	3	DIII (acute, serious dysfunction)
15 - 17	4	
20 - 25	5	

Table 7. Clinical dysfunction index, Di, based on evaluation of five different symptoms

In addition to the Helkimo index, to provide an isolated view of mandibular motion, the clinical functional parameter (mouth opening, laterotrusion, and deviation) according to Hochban was used, which is divided into 4 grades (Hochban, Ellers et al. 1996) (see table 8):

Grade 0	Maximum straight mouth opening > 40 mm, free laterotrusion > 7 mm
Grade 1	Maximum mouth opening ≤ 40 mm with deviation, limited laterotrusion 5-7 mm
Grade 2	Maximum mouth opening ≤ 35 mm, limited laterotrusion 2–5 mm
Grade 3	Maximum mouth opening < 30 mm, limited laterotrusion 0–2 mm

Table 8 classification according to Hochban

3.5.3 Assessment of facial nerve function

For checking the state of facial nerve, the patient was asked to whistle and pucker the lips, also to wrinkle the forehead, and to close the eyes. Facial nerve injury was deemed to have occurred by lack of symmetry in the movements performed, also if the patient was unable to draw the lower lip and corner of the mouth downward, unable to whistle, or unable to completely close the eyelids or to wrinkle the brow. Additionally we documented the duration of facial nerve weakness, and if it resolved by the 6-month period. Also we assessed the grade of motor nerve function according to Hause

Brackmann Facial Nerve Grading System as following : Grade (I) - no deficit; (II)mild weakness; (III)- moderate weakness; (IV)- severe weakness; (V)- absence of function (table.9).

Grade	Definition
I (no deficit)	Normal symmetrical function in all areas
II (mild weakness)	Slight weakness noticeable only on close inspection mouth. Slight asymmetry of smile with maximal effort.
III (moderate weakness)	Obvious weakness, but not disfiguring asymmetrical mouth movement with maximal effort
IV (severe weakness)	Obvious disfiguring weakness and only barely perceptible motion. At rest : asymmetry. Mouth : slight movement
V (absence of function)	No movement

Table 9: House Brackmann Facial Nerve Grading System

3.5.4 Assessment of the scar

Post-operative scarring was objectively evaluated. We registered first the scar length. Additionally, standard lateral color photographs of the patient were performed (Figs.9). The photographic documentation was taken at the same magnification and with same photographic apparatus. The scale of any assessed scar was scored as in the table 10:

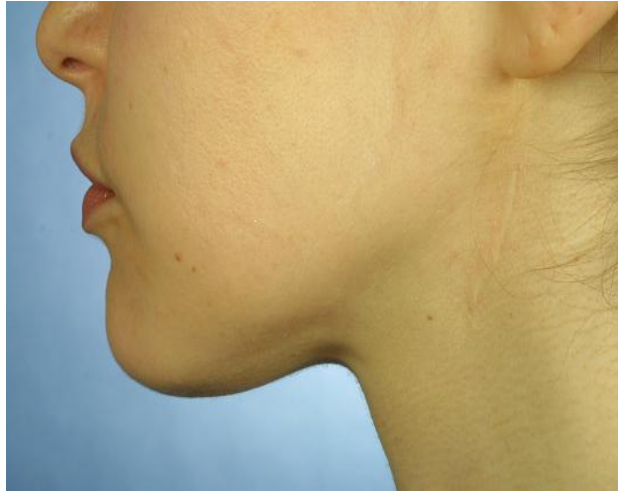1	2	3	4
No noticeable scar	Visible but thin and linear	Wide scar > 2mm in diameter	Hypertrophic scar > 1mm in elevation or keloid

Table 10: The scale of the assessed scar

Also the color of the scar was scored as follows (table. 11):

1	2	3	4	5
No noticeable color	Visible but normal skin color	Red scar	hyperpigmented	Hypopigmented

Table 11: The scale of scar color



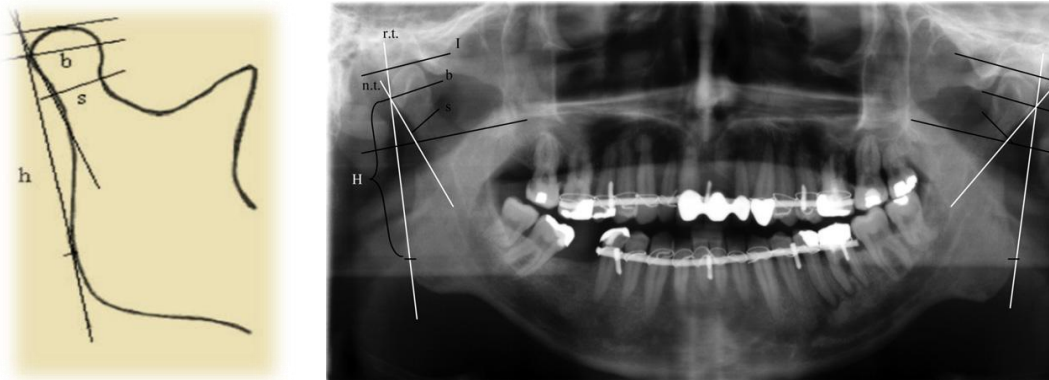
(FIG. 9) After 6 months, Postoperative lateral color photograph of the scarring

3.5.5 Radiographic assessment

The pretreatment panoramic and Clementschitsch radiographs were used to classify the fracture according to (Spiessel and Schroll), to determine the level of the fracture as high or low according to Loukota et al, and to quantify the displacement of the fractured condylar processes in the coronal and sagittal planes. In the panoramic radiograph, the displacement of the upper fragment in the anterior -posterior direction was investigated, and the reduction of the ramus height was measured by the difference in length between the fractured and non-fractured side. The radiographic magnification factor was not taken into account in the measurements, because this examination involves comparative measurements. Furthermore, the degree of coronal displacement in the mediolateral direction was measured in the pretreatment Clementschitsch radiograph.

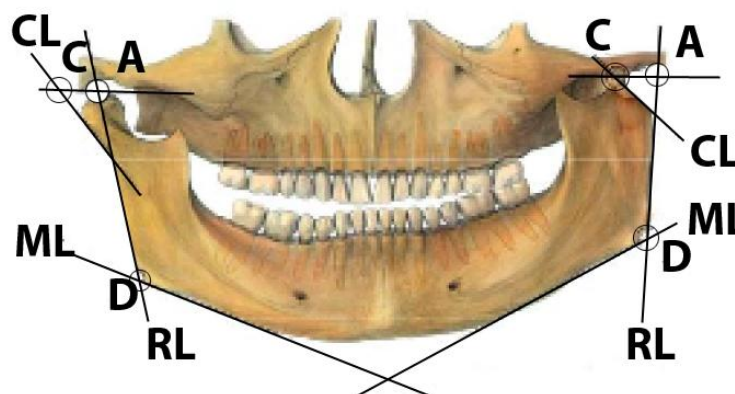
(Figure. 10) showing the method of measuring of ramus height. Mandibular ramus height was examined based on the condylar morphology scale method (CMS) for observation of condylar remodeling or resorption (Borstlap, Stoelinga et al. 2004).

The ramus height is calculated as a distance on the ramus tangent (RL) between the broadest part of condylar head (b) and most inferior contact of line (RL) to the angle of the mandible. The difference between the nonfractured and the fractured sides was used as a measure of difference in ramus length. In cases of bilateral fracture, the amount of overlay was measured to assess the amount of shortening.



(FIG. 10) Tracing of OPGs for analysis of ramus height from (Veras et al. Outcomes of Condylar Fracture Treatment by Intraoral Access. J Oral Maxillofac Surg, 2007).

Sagittal displacement in the panoramic image was measured as the angle between a line drawn along the posterior surface of the condylar process fragment and the ramus tangent (RL) (figs. 11).



(FIG. 11) Method of measuring sagittal displacement of condylar fracture; (CL) condylar tangent, (CD) Ramus Tangent (From Härle et al, Atlas of Craniomaxillofacial Osteosynthesis, 1999, Thieme)

Coronal displacement in the pretreatment Clementschitsch's image was measured as the angle between a line drawn between the medial and lateral poles of the condyle and a line through the middle or lateral surface of the mandibular ramus (Figs. 12). The difference between the angle on the non-fractured and the fractured sides was used as a measure of coronal displacement (Palmieri, Ellis et al. 1999).

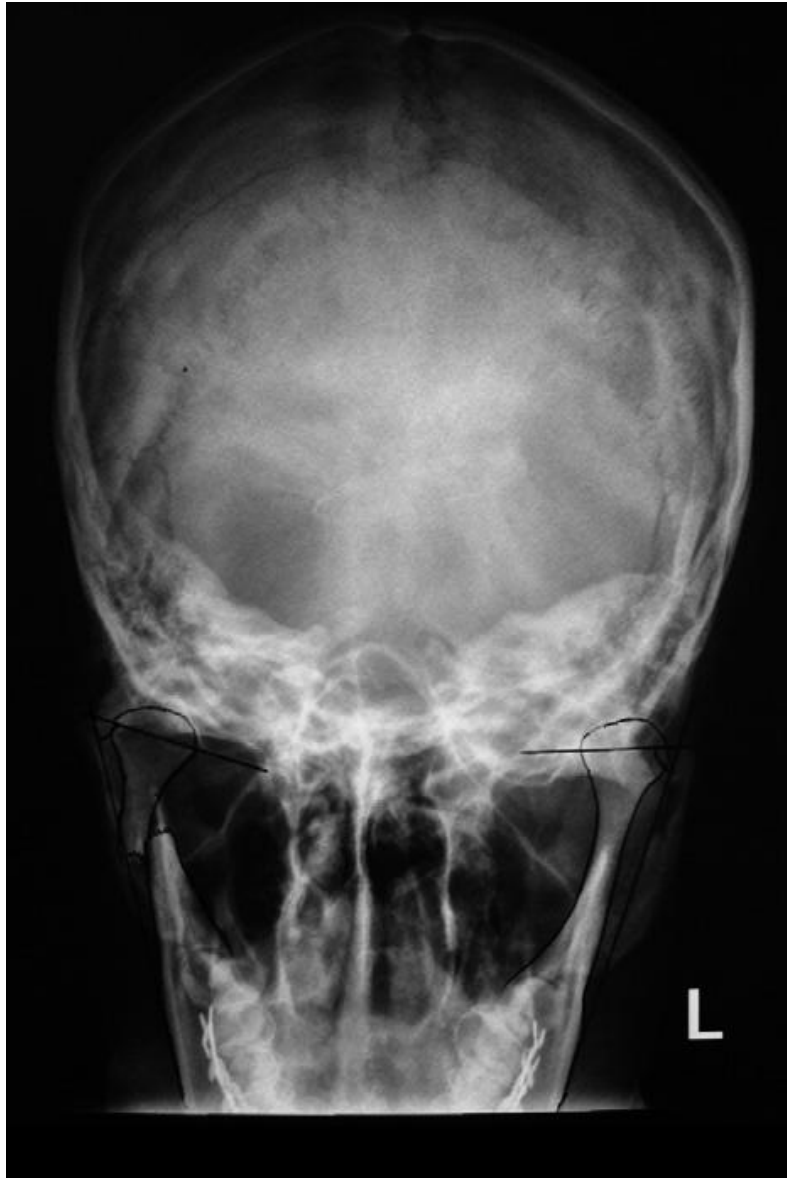

FIG. 12 Illustration showing the method of measuring the degree of displacement of the fracture in Towne's radiograph (Singh et al. Outcomes of Treatment of Mandibular Subcondylar Fractures. J Oral Maxillofac Surg, 2010)

Postoperative radiological examinations were carried out at the same intervals with the aid of DVT (Iluma DVT apparatus from Imtec- a 3M company, 120kV tube voltage, 3.8 mA current). Evaluation criteria are as follows (see figs. 13):

- bony consolidation, so that we consider the case as a good bony healing if the fracture is continuously bridged with homogenous density of the callus (Radiologische

Diagnostik der Knochen und Gelenke von Klaus Bohndorf, Herwig Imhof, Wolfgang Fischer, book, 2006).

- occurrence of mechanical abnormalities of the osteosynthesis material (plate fracture, plate bending, screw loosening, screws).
- accuracy of anatomical reduction.

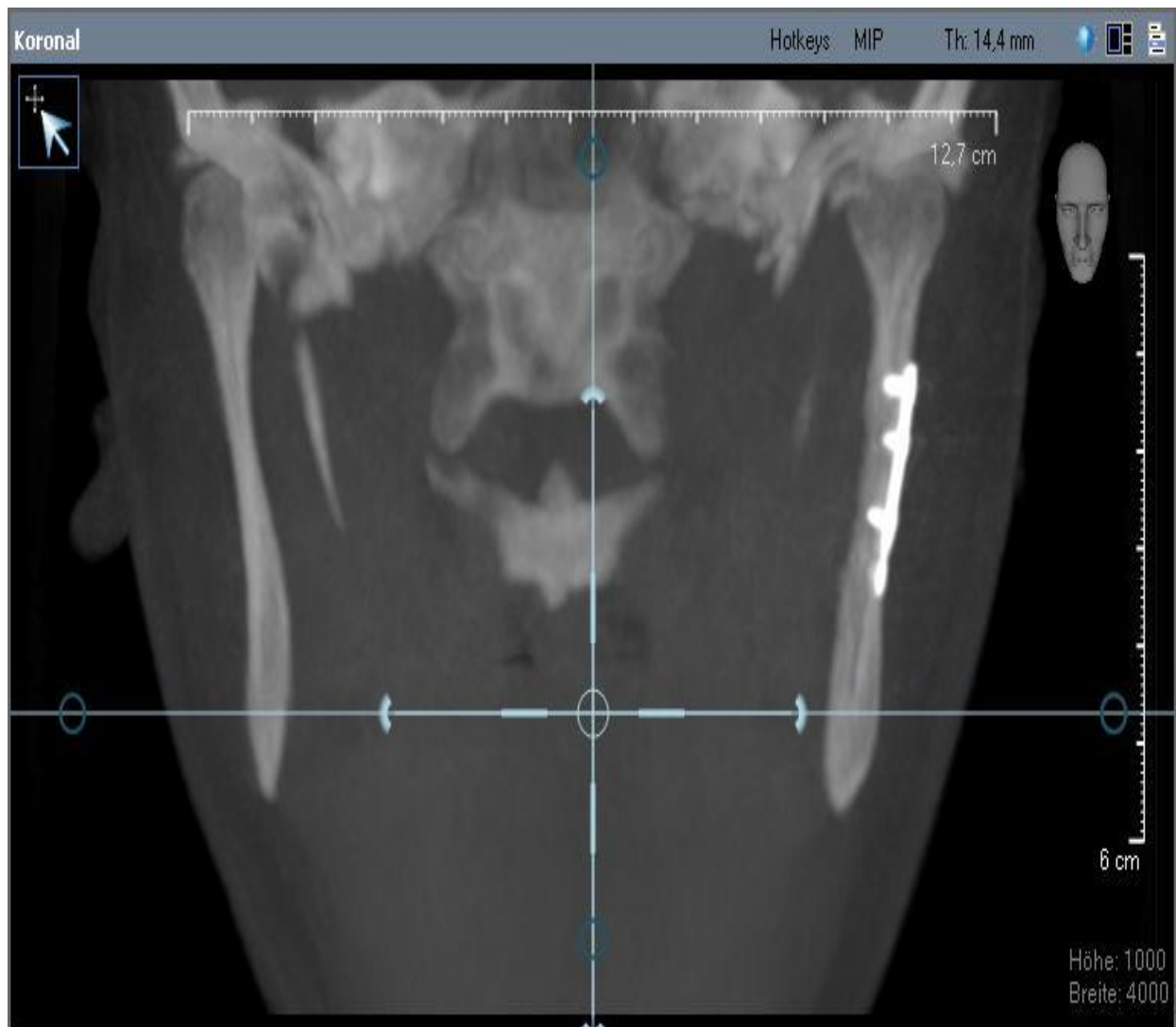


FIG. 13 Post-operative 3D DVT: anatomical restoration-coronal view (From Charité University Hospital, Berlin)

According to Hochban the postoperative anatomical reduction can be classified into correct, good, satisfactory and poor results (Hochban, Ellers et al. 1996). Only cases of exact anatomical restoration of articular process without loss of ramus height were scored as a correct reduction result, (see table. 12).

A	Correct open reduction	(anatomically correct)
B	Good result of open reduction	(shortening less than 2 mm, anterior/ posterior $\leq 3^\circ$, lateral medial $\leq 5^\circ$)
C	Satisfactory result of open reduction	(shortening less than 5 mm, anterior/ posterior $\leq 5^\circ$, lateral/medial $\leq 10^\circ$)
D	Poor result of open reduction	(values above those mentioned)

Table 12– Evaluation of results of open reduction by comparing pre- and postoperative radiographs 6 months postoperatively (classification according to Hochban)

To identify the accuracy of tracing and digitizing the images used in this study, the radiographs were traced and digitized by the same investigator two different times with a minimum interval of two weeks.

3.6 STATISTICAL ANALYSIS

relationships between the different variables and the statistical measurements were obtained using statistical software SPSS 16.0 for Windows software (Statistical Package for the Social Sciences).

4 . Results

4.1 Demographic Results

the male to female ratio of the total of patients material was about 2.7:1. As shown in the figure 14, it means in numbers, that of 45 patients, 33 men (73.3%) and 12 (26.7%) women have participated in this study. The t test revealed a significant difference in the presence of condylar fractures between men and women ($P < .05$).

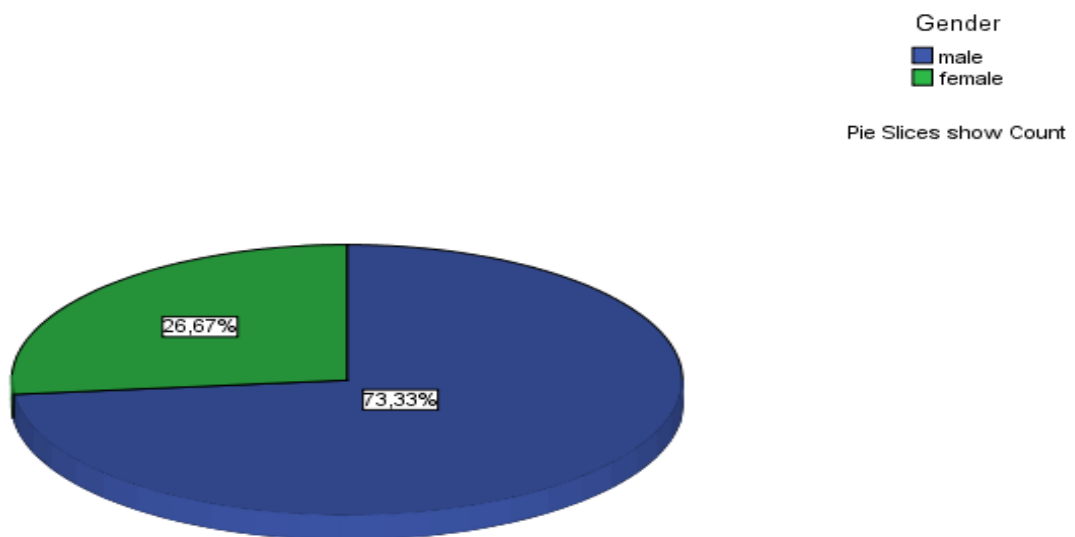


FIG . 14 Gender distribution for the group

In the present study, of the 45 patients, 4 patients presented with bilateral condylar fractures for a total of 49 fractures. Mean age at the time of the surgery was 37 years (minimum 16, maximum 75, SD 14). The peak incidence in terms of age emerges in the group 20 to 30 years in men and 30 to 40 years in women.

The time between operation and follow-up ranged from at least 6 to 20 months (mean 13 months). 47% of the fractures (23/49) occurred in the left condyle, while 53% of the fractures (26/49) were in the right condyle.

In 40% of the patients (20/45), there was only a fracture of the condylar process without accompanying fractures. the contralateral parasymphyseal fracture of the mandible was associated with the condylar fracture in 24% of the patients (11/45), and in 5 patients (10%) the parasymphyseal fracture of the mandible on the ipsilateral side. In the remaining 6% of patients (3/45), additional multiple fractures of the midface were diagnosed. statistically, Mandibular symphyseal and parasymphyseal fractures were significantly associated with fractures of the mandibular condyle ($P < .05$). The types and percentages of additional fractures accompanying the condylar fractures are shown in fig 15.

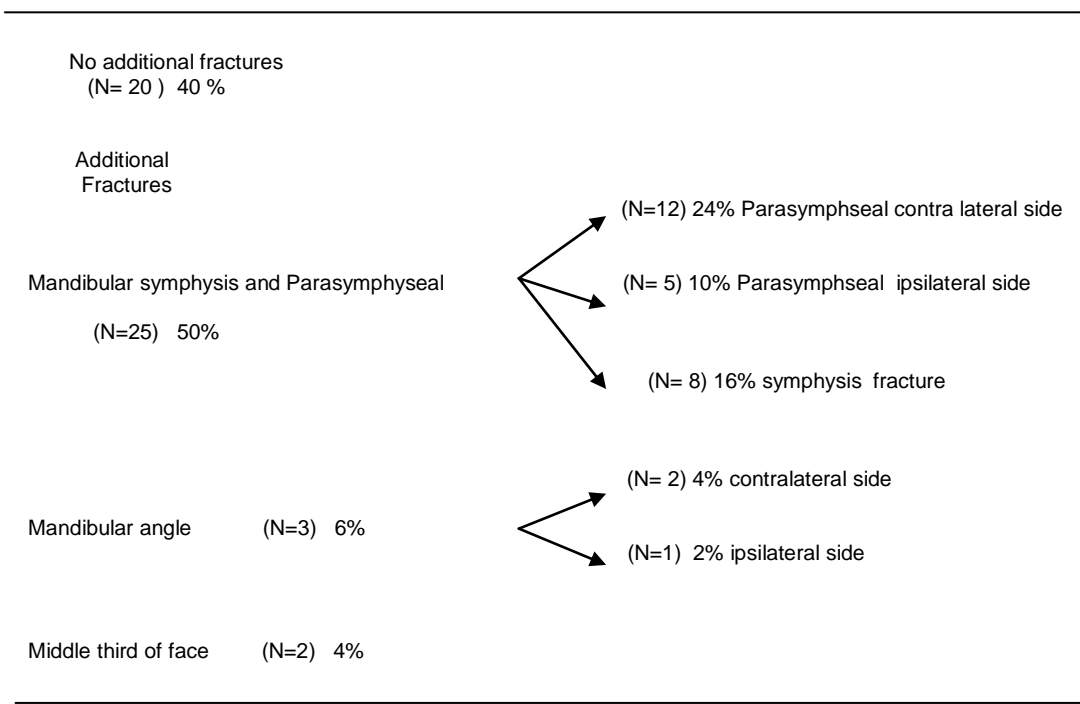


FIG. 15 – types and percentages of additional fractures accompanying condylar fractures

As the most frequent **causes** of the condylar fractures in the study group were falls and violence with 33.3% for each factor (15 patients). traffic accidents (car, motorcycle, bicycle, i.e.) were second in frequency in 24.4% of cases (11/45). In the case of traffic accidents, the most common cause of condylar fractures was bicycle accidents (6 patients, 12%) followed by car accidents (4 patients) and motorcycle (1 patient). Third in frequency were Sports accidents with 9% of all cases (4 patients). The Kruskal-Wallis test showed statistically no significant association between patient age and the cause of

the condylar fractures ($P > .05$), but particularly for interpersonal violence, 13 of 15 patients were in the age group 18-30 years.

The distribution of fracture etiologies is given in figure 16.

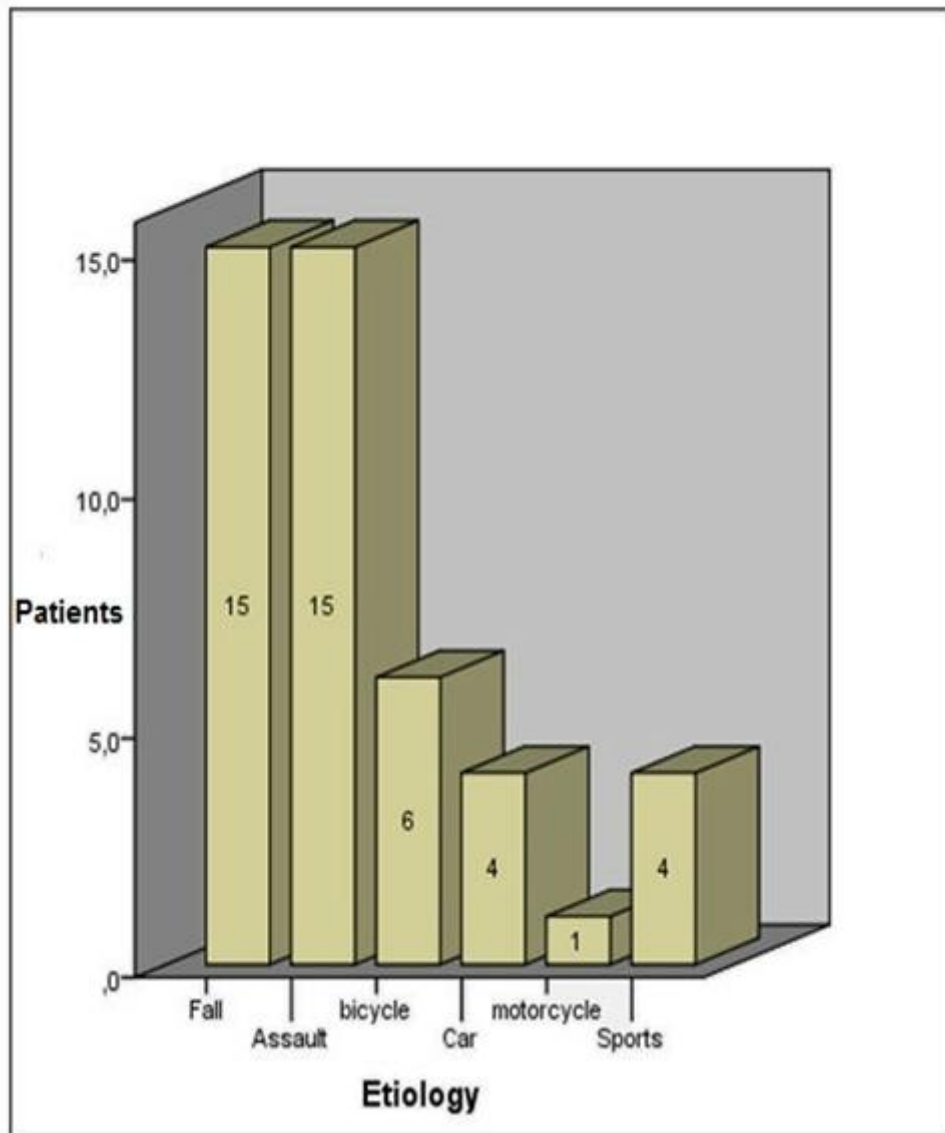


Fig. 16 The distribution of causes of fractures

4.1.1 Fracture distribution according to Spiessl & Schroll

The condylar fractures in this study were divided into 4.1% (2/49) as type I (without significant displacement), type II (low condylar neck fracture with deviation/displacement) in 57.1% of cases (28/49), type III (high condylar neck fracture with deviation/displacement) in 28.6% of cases (14/49), type IV (low condylar neck fracture with dislocation) in 6.1% of patients (3/49), and type V (high condylar neck fracture with dislocation) in 4.1% of patients (2/49). The most common fractures were types II and III.

The increased incidence of fracture types (II/III) is derived from the correlation with the causes, so that 44% (19/43) of fractures types (II/ III) were caused by fall or bike accidents (see table 13).

		Etiology		
Classification		Fall	bicycle	Total
	Type I without significant displacement	2	0	2
	Type II low condylar neck fracture with deviation/ displacement	8	3	11
	Type III high condylar neck fracture with deviation/ displacement	5	3	8
	Type IV low condylar neck fracture with dislocation	0	0	0
	Total	15	6	21

Table 13– Classification * Etiology (Crosstabulation)

4. 2 Time lapse before intervention

The fracture was treated in 48 cases (98%) within the first 6 days after the accident. However the interval between injury and operation ranged from 0 to 8 days, the median being first day after accident, so that 48% (24/49) of the fractures were managed on the first day after trauma (figs. 17)

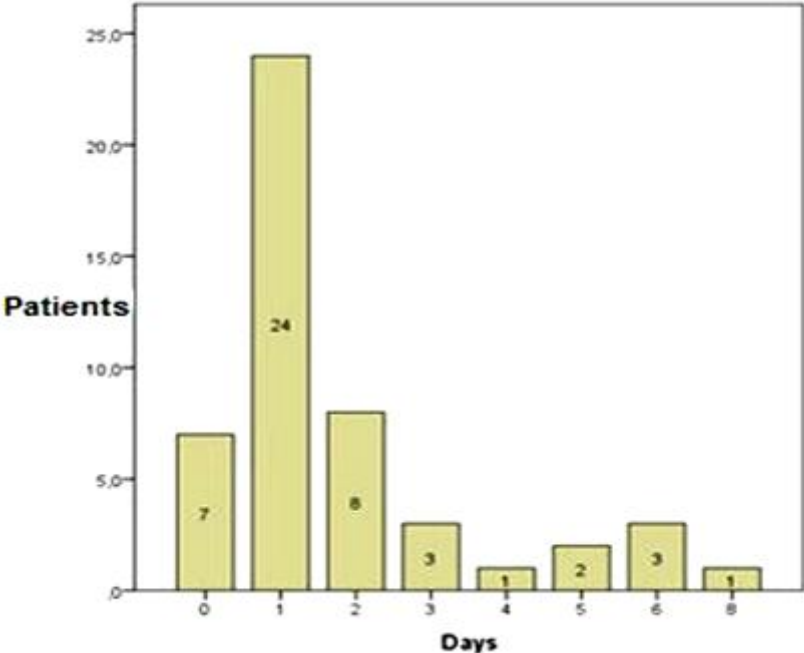


FIG 17. Elapsed time between injury and operation

4.3 Scoring of occlusive support

Most patients (42/45) (93.3%) had scores of (A) according to Eichner on the panoramic radiographs, which means that at least one tooth is in contact between the maxilla and mandible in the bilateral premolar and molar areas. In our study, all observed cases of dislocated fractures type (IV, V) according Spissel have been accompanied with sufficient occlusive support. Statistically, we could not confirm an association between the sufficient occlusive support and absence of dislocation of condylar head from the glenoid fossa ($P > .05$).

4.4 Analysis of surgical intervention data

The operating time for the treatment of one condylar fracture ranged from 30 to 85 minutes, with a mean duration of 50 minutes. The average operating time dropped to 43.5 (min 30 to max 65) minutes with increased experience, while the average operating time by surgeons inexperienced in the technique was 62 minutes (45 to 85). 63% of the fractures (31/49) were operated by expert surgeon in this technique. Regarding the length of stay in hospital, our results indicated that the postoperative hospitalization time was 2 to 7 days, with a mean duration of 4 days. Patients with no other injuries than the condylar fracture stayed in hospital for 2 to 5 days (mean 3 days). The longer hospitalization times were due to other reasons, e.g. complications or concomitant body injuries such as brain and limb injuries. The surgical drain (Redon-drainage) was applied in 98% (48/49) of the fractures. With respect to antibiotics, all the patients were given antibiotics. Clindamycin 600 mg (lincosamide antibiotic) was administered in 78% of the patients (35/45), and Unacid (Beta-lactam antibiotic with Sulbactam) was given in 22% of the cases (10/45). The duration of administration of the antibiotics ranged from 4 to 10 days, with a mean duration of 7 days. No significant difference between the two antibiotics was found with regard to the infection rate.

Wound healing deficit or postsurgical infection developed in 2 cases, that necessitated a revision for drainage on fourth day. The wound then healed without further complications, but left behind an unaesthetic scar. Large hematoma was not observed in any of the patients. Also, there were no cases of osteomyelitis. In 3 fractures (6%) malposition of the fragment was detected in the postoperative radiographic follow-up and consequently, had to be operated. After the re-operation an acceptable healing of fracture were observed.

Postoperative IMF screws (synthesis) with wire was performed in 10 patients (22%). In these 10 patients, the period of IMF was on average 6 days (minimum 2 days, maximum 14 days). There were many multiple trauma patients or patients with complicated three-fold fractures in this group of patients. In these complex fractures, the average of IMF duration was significantly increased.

4.4.1 surgical approach and osteosynthesis

All patients were operated on through modified submandibular access. Regarding the osteosynthesis, the Modus miniplates 2.0 (Medartis) were inserted in 98% of the fractures (48/49) (predominant use of 4-hole miniplates in 96% of the cases (46/49). Placement of two miniplates was used in 37% of the fractures (18/49). Only in one case was the fracture stabilized by means of a Eckelt lag screw. All metallic plates used in our study group are summarized in Table 14. The hardware removal after healing of fracture was performed in 24.5% of the cases (12/49). the reason for the removal of the plates in (7/12) 58.4% of the cases was that the symptom-free patients requested this. The required time for the performance of the surgical operation with double plating was 46 min in this study. We didn't find a significant difference in the mean time of operation between the use of one and two plates.

methods of osteosynthesis	Frequency	Percent %
Two 4-hole miniplates	18	37
One 4-hole miniplate with long bar	14	28.5
One 4-hole miniplate with short bar	13	26.5
One 4-hole miniplate without Bar	2	4.0
Eckelt lag screw	1	2.0
one X-shaped 6-hole miniplate	1	2.0
Total	49	100

Table. 14- methods of osteosynthesis used

4.5 Results of functional findings

4.5.1 Interincisal Opening

The mean maximal active interincisal opening for our group was 45.5 mm (range 30 to 60 with SD 5.7 mm). Mouth opening reached normal values (over 40 mm) in 40 of the patients (89%) in the follow up, While a slight impairment of mouth opening between 30 and 39 mm was seen in the rest of the patients (5/45) with average age of 20 to 45 years (table 15). Four of these five patients (mean of age 33) found the impairment unacceptable. 4.4% of the patients (2/45) indicated a slight discomfort by (MMO).

Mouth Opening (mm)	Patients number
≥ 40	40 (89%)
30-39	5 (11%)
< 30	0 (0%)

Table 15- Maximal mouth opening (n = 45 patients)

In individual consideration of the maximal mouth opening (MMO) in the patients with postoperative IMF, statistically, we observed no correlation between the shortened use of IMF and reduced MMO ($P > .05$).

4.5.2 Relationship between the Fracture type and postoperative MMO

In the classification according to Spiessl & Schroll, no significant correlation could be observed between fracture type and MMO. On average, a sufficient postoperative MMO was noted for each type of fracture (see Figure 18).

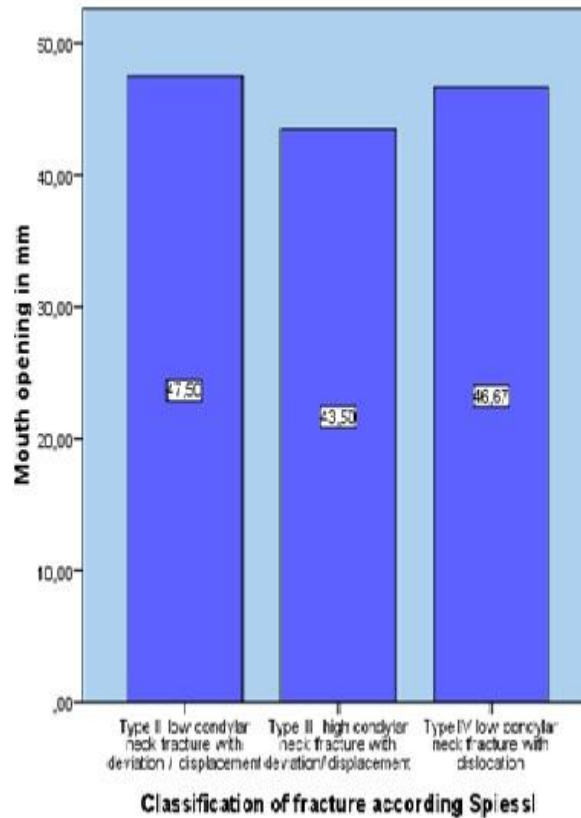


FIG - 18 Relationship between the fracture type and postoperative MMO

4.5.3 Pro and laterotrusion

Protrusion was ≥ 7 mm in 87% of the patients (39/45), while a limited protrusion motion between 4-6 mm was seen only in 13% (6/45). No patient indicated a discomfort when performing a protrusive movement (table 16).

The lateral movement as measured at the incisors, was 10.54 mm (mean) to the fractured side (SD= 2.357; maximum 15, minimum 6). For comparison, the mean of laterotrusion to the opposite sides of the mandible was 10.57 mm (SD= 2.371; maximum 15, minimum 6). The results of the lateral movement showed no significant differences between the contralateral and fractured sides, so that symmetry of the lateral movements (difference less than 2 mm between the both sides) was observed in 41 of the patients (91.1%).

A tendency to diminished lateral movements < 7 mm towards the unfractured side was noticed only in 2 cases .

Maximal protrusion (mm)	Patients number
≥ 7	39 (87%)
4-6	6 (13%)
0-3	0 (0%)

Table 16- Maximal protrusive movement (n = 45 patients)

4.5.4 TMJ and masticatory muscle Pain

In the follow-up, the graded pain scale showed 6% (3/49) cases with score II (slight pain in TMJ). In all the cases of TMJ discomfort was associated with fracture type III (high condylar neck fracture with deviation/displacement). Three patients complained of pain in function on the fractured side, two of whom had tenderness on palpation, and no patients had spontaneous pain. Slight pain on palpation of one or more masticatory muscles on the side of the fracture was found in 3 patients, also muscle pain in function was documented only in one patient.

4.5.5 TMJ Clicking

Joint clicks were auscultated at the fractured joint during the opening and closing movements of the mandible in 10% of cases (5/49). Also Joint clicks at the opposite side was present in 8% of cases (4/49). Bilateral joint sounds were found in 12% of patients (6/49). In the cases of TMJ clicking, just 2 patients felt the sound phenomena as uncomfortable. (4/5) cases of TMJ clicks at fractured side were associated with fracture type III (high condylar neck fracture with deviation/ displacement). As shown in the drawing, no difference was noted between the fractured and non-fractured sides (figure 19).

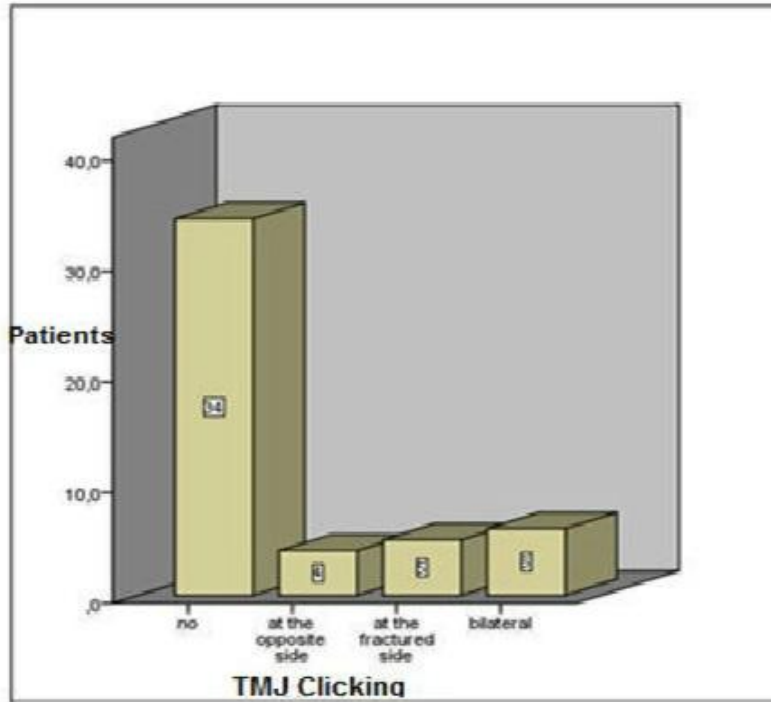


FIG- 19 TMJ Sound at the opening and closing movements

4.5.6 Assessment of the scar

Patients’ opinion on cosmetic outcome was assessed at the follow-up appointment. The results were evaluated as good by 40 cases (81.6), fair by 6 cases, and in 6.1% of the cases (3/49) the patients found the scar to be disturbing (figure 20). The scar length was on average 36.3 mm long (minimum 20, maximum 55; SD = 6.54).

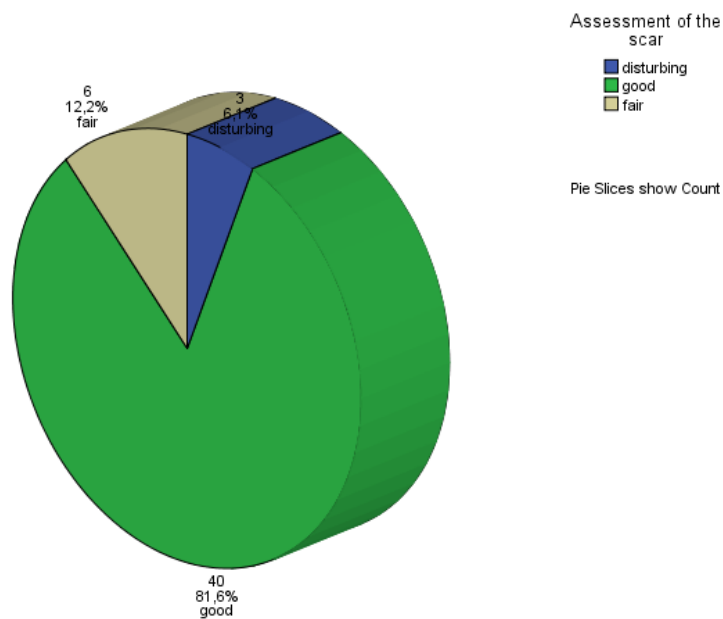


FIG- 20 Patients’ opinion on cosmetic outcome

The outcomes of assessed scar according to the observer are summarized in Table 17 :

	1	2	3	4
Scarring evaluation	No noticeable scar	Visible but thin and linear	Wide scar > 2mm in diameter	Hypertrophic scar > 1mm in elevation or keloid
Patients number	36 (73.5 %)	7 (14.3 %)	4 (8.2 %)	2 (4.1%)

Table 17- Observer Scar assessment

Also the results of color assessment of the scar according to the observer was documented as shown in the following figure 21:

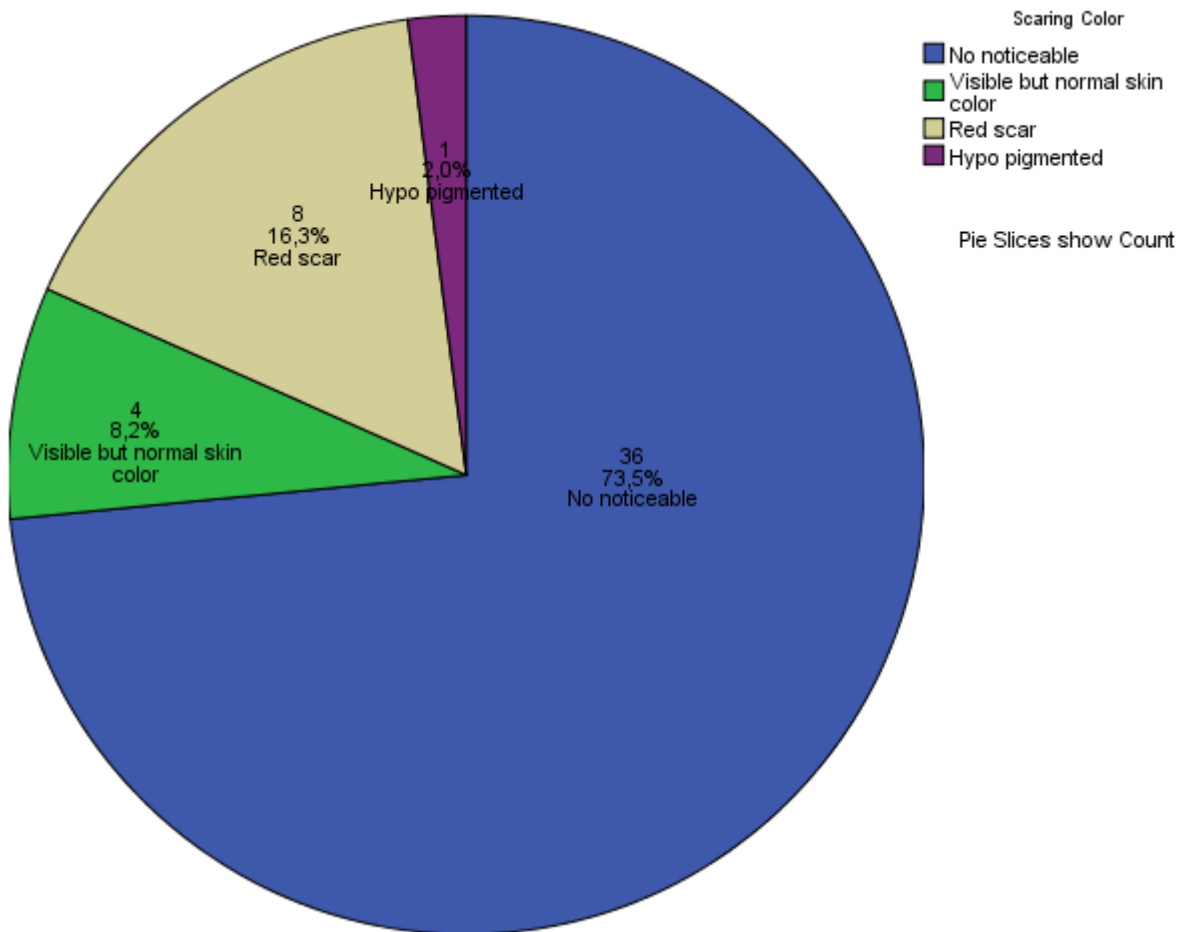


FIG-21- Scarring color evaluation

4.5.7 Assessment of facial nerve function

19 of 49 of our surgical access (38.8%) showed postoperative transient weakness of marginal mandibular branch of the facial nerve. 13 of these 19 cases (68.4%) showed temporary slight weakness grade II according to Hause Brackmann Facial Nerve Grading System, while grade (III) as moderate weakness was documented in 4 cases (21%), and grad (IV) as severe weakness in 2 cases (10.6%). However no case of grad V (absence of function) was observed in our sample; according to Schneider and experientially, we showed that such a postoperative impairment of the function of the rami marginal of facial nerve could be observed only during active mouth puckering or by the downward movement of affected corner of the mouth (Schneider, Lauer et al. 2007). Temporary weakness of facial nerve lasted for 5 months in 3 patients, for 3 months in 9 patients, 2 months in 3 patients, and 1 month in 2 patients (figure 22).

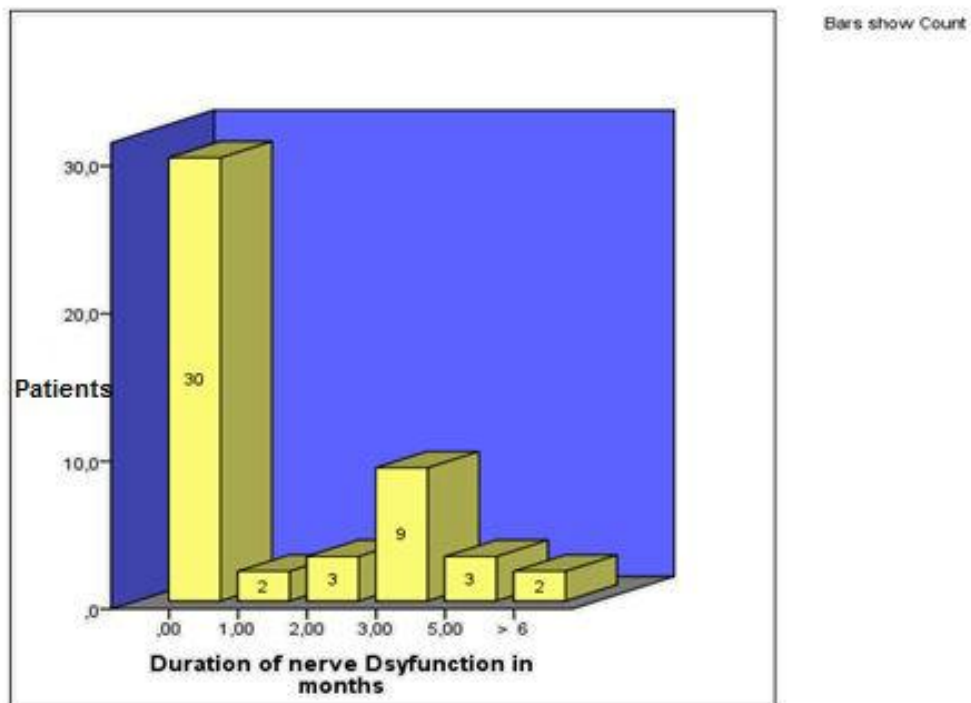


FIG- 22 Duration of nerve Dysfunction in months

After 6 months permanent disturbance of the facial nerve was seen only in 2 cases (4%) with slight weakness grad. The two permanent dysfunction cases were noted when the operation was performed by an un-experienced surgeon, so that the impairment of the facial nerve is largely avoided by nerve protecting preparation.

However we didn't observe statistically significant differences between experienced and un-experienced surgeons with regard to occurrence of temporary weakness of facial nerve (Table 18).

		Temporary weakness of facial nerve		
		yes	No	Total
Surgeon	experienced	12(38.7%)	19	31
	inexperienced	7(39.9%)	11	18
	Total	19	30	49

Table 18- Surgeon * Temporary weakness of facial nerve (Crosstabulation)

4.5.8 Occlusal Defects

Return to the anamnestic reconstruction of pre-traumatic occlusal status, 5 of 45 (11%) patients reported minor occlusal defects after 6 months. Of these 5 cases with permanent malocclusion, 3 patients had multipletrauma with multiple additional midface or mandibular fractures, and 1 patient had unoperated condylar head fracture on the opposite side.

4.6 Evaluation of calculated indexes

4.6.1 Assessment of clinical dysfunction index according Helkimo

An evaluation using the Helkimo index revealed no to moderate dysfunction. No severe dysfunction was found in any of the patients. The Helkimo Index presented 34 of patients (75.6%) who were classified as D0 (Free of symptoms), 10 patients (22.2%) as D I (mild dysfunction), and one patient as DII (moderate dysfunction) (Table 19).

Of the ten patients with mild clinical dysfunction, 5 patients had a score of 2 points and 4 patients had 1 points (range DI = 1-4 points).

We did not confirm any statistical correlation between the index score and fracture classification (P= 0.069), but there was a significant correlation between the Helkimo-index and the reposition results, so that 22 out of 23 patients with correct anatomical

reduction showed score D0, while 11 out of 22 patients with inexact anatomical reduction showed DI or DII $p < 0.05$.

	Helkimo index of dysfunction	Total number
Patients		
D 0	Free of symptoms	34 (75.6 %)
D I	Signs of slight dysfunction	10 (22.2%)
D II	Signs of moderate dysfunction	1 (2.2%)
D III	Severe dysfunction	0

Table 19 – Helkimo index of dysfunction in condylar fracture patients

4.6.2 classification according to Hochban (Hochban W. et al. 1996)

The pure functional parameters (mouth opening, lateral deviation by mouth opening, and laterotrusion) are only used to evaluate the dysfunction index according to Hochban which was divided into 4 degrees (Hochban, Ellers et al. 1996). The advantage of this classification is the possibility of a more accurate differentiation of the mandibular motion.

84.6% of the patients (38/45) were classified as grade 0 (no dysfunction). Grade I (slight Impairment) was seen in 11% of cases (5/45). 2 patients showed moderate dysfunction (grade II), and no patient showed severe dysfunction (grade III) (see table 20).

Dysfunction index according Hochban	Patients
Grade 0 - no dysfunction	(38) 84,6 %
Grade I - slight dysfunction	(5) 11 %
Grade II - moderate dysfunction	(2) 4.4 %

Table 20 – Dysfunction index according Hochban

4.7 Radiographic findings

4.7.1 pre-operative assessment:

On average, the preoperative shortening of the fractured condylar process was 3.89 mm (minimum 0, maximum 10; SD= 2.9). Preoperative displacement of the fractured fragment presented in 91.8% (45 fractures). In the patients mentioned; 8% (4 patients)

showed dislocation of the condylar head out of the glenoid fossa in addition to the displacement. Medial-lateral tilting of fractured condyle in the coronal plane occurred in 43 cases (87.8%) in the medial direction, and in 2 cases (4.1%) in the lateral direction. An examination of the anterior- posterior displacement in sagittal plane also showed that the upper fragment was displaced in 25 cases (51%) towards anterior, in 18 cases (36.7%) in the posterior direction . With regard to the grad of tilting as explained under 3.5.5, the average pre-operative degree of angulation (angulation to medial or lateral) was 32.36° (range, 0° to 80°; SD =21.17).

4.7.2 assessment of postoperative anatomical reduction according to Hochban

As noted under 3.5.5, the results of reposition and fixation based on the pre- and postoperative radiographs were classified according to Hochban. table 21 shows the repositioning results.

Repositioning results		Of patients number
A	Correct open reduction (anatomically correct reduction)	23(46.9%)
B	Good result of open reduction (shortening less than 2 mm, anterior/ posterior ≤ 3°, lateral medial ≤ 5°)	24 (49%)
C	Satisfactory result of open reduction (shortening less than 5 mm, anterior/ posterior ≤ 5°, lateral/ medial ≤ 10 °)	2 (4.1%)
D	Poor result of open reduction (values above those mentioned)	

Table 21- Repositioning results according to Hochban

In this series, of 18 patients receiving the treatment from an operator inexperienced in this technique, radiographs confirmed that the fracture fragments had healed in the correct position in 4 cases (22.2%), while a good reduction was achieved in (12/18) of the cases. On the other hand, correct open reduction was possible in 61.2% of cases (19/31), which had been treated by an experienced surgeon, indicating that the experience of the surgeon is another major variable in the open reduction of condylar fractures (table 22).

		Repositioning results according to Hochban			
		correct Reduction	good result	Satisfactory result	Total
Surgeon	experienced	19	12	0	31
	inexperienced	4	12	2	18
	Total	23	24	2	49

Table- 22 Surgeon * Repositioning results according to Hochban (Crosstabulation)

The relationship between the clinical and radiological findings was debated in many writings. In our study, in 23 cases of radiological correct anatomical open reduction of the condylar process, minimal functional impairment existed only in 1 case, while 50% of the patients with radiologically inexact anatomical reduction showed functional defects. This indicates a strong relationship between the radiological analysis and functional outcome.

4.7.3 Shortening in ramus height

The average postoperative shortening of the ascending ramus height compared with non-fractured side was less than 1 mm (range, 0 to 3 mm; SD, 0.82). The reduction of the mandibular ramus length between 1-3 mm was calculated in 32.6% of cases (16/49). (12/16) of these patients had concomitant fractures of the mandible or maxilla, and the rest were operated by an inexperienced surgeon.

4.7.4 complications of osteosynthesis

The occurrence of mechanical abnormalities of the osteosynthesis material were summarized. The evaluation was based on DVT radiograph 6 months after the surgery. Osteosynthesis was assessed to check for complications such as: plate fracture, plate bending, plate or screw loosening. In 2 patients, a screw loosening was observed. In these cases, hardware removal was performed. Bending and fractures of the plates

were not observed. However, when 2 miniplates were used, no plate fracture, bending, or screw loosening was observed(see table 23).

Complications	1 miniplate (n = 30)	2 miniplates (n = 18)
plate fracture	0	0
plate bending	0	0
plate or screw loosening	2	0

Table- 23 Complications of Osteosynthesis

5. Discussion

The management of mandibular condylar fracture has generated wide debate about maxillofacial trauma. Proponents of nonsurgical therapy often advocate it for reduced immediate morbidity, easier implementation, prevention of typical surgical complications, less hazard of ankylosis and vascular necrosis, claiming that the result is comparable to that of the open approach (Haug and Assael 2001; Landes, Day et al. 2008).

In contrast, after the development of plate and screw fixation devices the open reposition using internal fixation becomes more and more popular in the literature. Enthusiasts of the open approach to the condylar process report also favorable treatment outcomes in terms of either adequate anatomical repositioning of the fracture, posterior ramus height restoration, less risk of facial asymmetry, occlusal stability, early mobilization of the jaw on rapid functional rehabilitation (Ellis and Throckmorton 2000). However, at the present time, there is no consensus in the world literature with regard to the clinical outcomes of patients treated using a closed (nonsurgical) or open (surgical) approach and whether and when open reduction or closed treatment should be selected (Brandt and Haug 2003; Stiesch-Scholz, Schmidt et al. 2005).

The present study was undertaken to review and ensure the quality of condylar treatment in Department of Oral and Maxillofacial- Surgery of the University Hospital Charite – Berlin.

This study, aimed to observe the ability to anatomically reduce and rigidly stabilize the fracture fragments via the open approach, to quantify outcomes, to assess the state and satisfaction of patient 6 months after surgery, and to discuss the morbidity associated with the modified Risdon surgical approach.

45 patients with mandibular condylar fractures were examined in a retrospective study between 2008 and 2011.

Gender distribution in our study shows a clear predominance of males, with a ratio of male (73.3%) to female (26.7%) of 2.7:1; this is consistent with the literature of central European countries (Jeckel et al. 1983/Germany), (Bormann, Wild et al. 2009), but greater than that reported by Marker, Nielsen et al. (2000) (2:1).

The mean age of our examined patients at the time of surgery, as already mentioned in Chapter 4, was 37 years with a wide range from 16 to 75 years. consistent with our findings, Bormann, Wild et al. (2009); Zix, Schaller et al. (2011) found similar mean age.

In the literature, several main causes appear among the etiologic factors associated with mandibular condylar fractures. Boole, Holtel et al. (2001) reported that the frequency of etiology of fracture depends most probably on the geographical situation of the country, socio-economic factors, population growth, traffic intensity, and mobility. Interpersonal violence was the most common cause in 57% of 563 condylar fractures in France, followed by road accident 12% (Rocton, Chaine et al. 2007). According to Simsek, in the USA (Simsek, Simsek et al. 2007) mandibular fractures were a consequence of assault also in 53.7% of 665 fractures, followed by motor vehicle accidents (MVA) as the second cause in 28.1% .

In our sample, the leading trauma causes were falls and fights with 33.3% for each factor (15 patients). Second in frequency, with 24.4% of all cases, were road traffic accidents (11 patients), which could be subdivided into three main categories: bicycle accidents (6 patients), MVA (4 patients) and motorcycle (1 patient). Sports accounted for 9% of all cases and was third in frequency (4 patients). The frequent incidence of fall-related fractures appears higher in large cities such as in our city Berlin (Ellis, Moos et al. 1985). with respect to high frequency of aggression-related fractures, this may be related to the high rate of young patients between (18-30) years in (87 %) (13/15) of cases, moreover a total of 80% of these patients (12/15) were under the influence of alcohol at the time of the accident .

condylar fractures occurred in 4 patients 8.8% on both sides, while the rest was located on one side (41 patients). Consistent with Lautenbach (1964), a predominant localization of the fractured side (right or left) could not be ascertained.

The evaluation of the concomitant fractures shows 40% of isolated condylar neck fractures, 56% with additional mandibular fractures and 4% with other associated facial fractures. It appears therefore, according to (Zachariades, Mezitis et al. 2006) that in the majority of cases, condylar fractures may be the result of the exertion of force which is not fully absorbed in the area of its primary application, i.e. the mental region. Kniggendorf, E. (1979) and Villarreal, Monje et al. (2004) described similar fracture

distributions. Sawazaki, Lima Junior et al. (2010) reported also that subcondylar fracture is a consequence of tensile failure via distributed indirect impact, which leads to extreme bending of the mandibular neck as one of the weakest points in the mandible. This mechanism provides an answer to the correlation between symphyseal fractures and condylar fractures.

Relating to the frequency of distribution of fractures according to Spiessl and Schroll, Type II (low condylar neck fracture with deviation/displacement) were most often represented with 57.1% of cases (28/49), followed by type III (displaced high condylar fractures) with 28.6% (14/49). Consistent opinion prevails in the literature that low condylar neck fractures with displacement or dislocation (class II/III) are most frequently represented in patient groups (Landes and Lipphardt 2005; Stiesch-Scholz, Schmidt et al. 2005; Landes and Lipphardt 2006).

The noticeably frequent occurrence of types (II/III) in the our patient population can be explained by the correlation with etiology of the fracture, so that a fall on one side of the face (bike accident, fall) in most cases, causes fracture of mandible through direct application of force and contralateral subcondylar fracture by indirect force. This theory occupies an important place in our study group, because 19 fractures of types (II/III) were caused by fall or bike accident.

5.1 The lapse before Intervention

The time of definitive surgical operation was between the day of trauma and the day when traumatic swelling and general condition permitted, but not later than after 8 days in one case. **(the median being at first day after accident)**. In preparation for the surgical intervention, more time between the accident and surgery is required in cases of associated injuries or instability of vital signs. Haertel et al. (1994) performed the surgery an average of 2.5 days after the accident, whereby about 60% are treated on the first day, while Landes and Lipphardt (2006) classified the operation as urgent and scheduled it on the fifth day at the latest.

Traditional teaching has it that an early start of surgical treatment leads to better and effective results. Recent studies have shown no increase in complications with a delay of repair beyond 24 hours (Webb, Makhijani et al. 2009; Barker, Oo et al. 2011). Biller et al showed no increase in infections in repairs delayed over 72 hours, but there was an

increased incidence of technical complications (Biller, Pletcher et al. 2005). Like the previous data, this dependence cannot be confirmed in the present study.

5.2 Scoring of occlusive support

In our sample, we documented the sufficient support of premolar and molar occlusion (class A) according to Eichner in 93.3% of the patients (42 /45). This percentage has clear correlation with the age of patients, whereas the young patients, who represent a large part in our sample, should be approximately fully toothed for the most part.

In our group, we have classified fractures as dislocated fractures type (IV,V) according to Spissel only in 5 cases; in these cases, the patients had a score of (A) with complete and sufficient occlusive support, therefore, we found that occlusive support apparently plays no part in the dislocation of the condyle from the glenoid fossa after the trauma.

The importance of occlusive support grading according to Eichner. (1955), is to evaluate the difficulty and reliability of IMF, and to ensure long-term results, so that the occlusive support of the posterior region is a significant factor for success of treatment (Assael, 2003).

With insufficient posterior occlusal contact, plate fractures, screw loosening, or secondary angulation of the reduced fragment can occur, which may lead to a serious impairment of the clinical-functional, radiological and instrumental results. In the literature, there are barely studies, which discuss the relationship between occlusal support and long-term results of the therapy. For example, Schmid. (1973) and Mueller (1969) reported the role of insufficient posterior occlusal contact in the development of post-traumatic pain. This observation was not supported by the present study.

5.3 Analysis of surgical intervention data

The mean length of the surgical procedure from incision to skin closure was approximately 50 min (minimum 30, maximum 85). Increased operating time is usually attributed to difficult fracture repair as a result to medial override fractures, medial subluxation of the condylar head, or lack of occlusal contact and consequently the difficulty to apply temporary maxillomandibular fixation. We noticed, in agreement with Choi, Yi et al. (2001), a difference in the mean operating time between experienced and learner surgeons, so that the approach becomes a routine method of fracture treatment. Our results were similar to data reported by Vogt, Roser et al. (2005) with 55 minutes,

also by Trost, Trouilloud et al. (2009) with 45 min. Endoscope-assisted fixation of mandibular condylar processes was associated partly with significantly higher operating time, with Lee et al. reporting an average surgical time of 143 ± 63 min (Lee, Mueller et al. 1998).

The mean postoperative hospitalization time in our sample was 4 days, similar to that published by Martini, Takahashi et al. (2006). However patients with complications or concomitant body injuries had a longer mean hospitalization time of 6 days. A comparison with literature shows fundamental differences. treatment guidelines in the United States and Australia provide only for short inpatient treatment times, while according to European guidelines, surgically treated patients are normally discharged from inpatient treatment to outpatient treatment after satisfactory healing.

The surgical drain was applied routinely in 98% (48/49) of the cases. Redon-drainage was mainly introduced to avoid hematoma formation, and it was left in situ for 2-3 days. In one case, the hospital staff had forgotten to insert a drain and consequently post-operative infection had developed. We learned from personal experience that the drainage after extra-oral open reduction of condylar fracture must be done to discharge serous leakage in order to prevent the development of infection.

The efficacy of prophylactic antibiotics in decreasing the incidence of postoperative infections is controversial. The use of perioperative and postoperative antibiotics in the treatment of mandible fractures, especially in the dentate portion is well established to reduce the risk of infection (Zallen and Curry 1975). By contrast, Miles, Potter et al. (2006), proved that continuous postoperative administration an antibiotic did not further improve the infection rate.

Because of unachievable safe sterilization of the operating area due to the need of IMF through the contaminated intraoral field during surgical intervention and on the basis of our clinical experience, the use of intraoperative "single-shot" and postoperative antibiotics was listed in all cases. All patients received antibiotic prophylaxis (intravenously) until discharged, and then oral antibiotics were continued for 3 to 5 subsequent postoperative days, so that the mean duration of antibiotic coverage was 7 days. Postsurgical routine antibiotics is beneficial in our group, because we believe that the usage of the surgical drain lead to an accumulation of drain body fluid which in itself

becomes a focus of infection. The selection of the antibiotic was not mandated by the study protocol.

Two patients developed a wound healing defect or postoperative wound infection, that resolved after a wound irrigation and drainage on the fourth day. However, these infections did not interfere with fracture healing. Kent reported that the hazard of infection after open management is small but always greater than with closed therapy (Kent et al. 1990). But in our study and in that reported by Meyer, Zink et al. (2008), we have found that the open reduction is associated with a rare risk of postoperative infection. Our low rate of infection attributed to our use of an aseptic management protocol, surgical drain and antibiotics. The risk of infection increases in the case of poly-traumatized patients, the combined use of tobacco and alcohol, immunocompromise, delayed surgery, lack of antibiotic coverage, and extended hospitalization (Assael 2003).

Large hematoma was not seen in any of the patients and no case of osteomyelitis was observed. The efficacy of surgical reduction and sufficient stability of fractured fragments by the rigid fixation may play an important part in preventing of bone infection.

A secondary malposition of the condylar fragment was detected between the 14th postoperative day and the 6th month in 3 of the fractures (6%). In patient 1, primary surgery was performed by surgeons inexperienced in the technique, so that the plate was not exactly in the correct position. In 2 patients, inadequate reduction of the additional parasymphyseal fracture or closed treatment of one side of bilateral condylar fracture may have caused unstable osteosynthesis and condylar displacement due to faulty occlusion. The 3 patients needed retreatment or corrective surgery, and a revision was performed using same approach and definitive osteosynthesis with miniplates.

After the re-op, an acceptable healing of the fracture was noted. Our rate of malreduction is consistent with the literature (Biglioli and Colletti 2008). Biglioli reported that trying to shorten the skin incision may restrict vision and make it difficult to reduce the fracture.

rigid intermaxillary fixation (IMF) using IMF screws (Medartis) was performed intraoperatively to obtain the preoperative dental occlusion. After fracture fixation and checking the occlusal relationship of the teeth and the jaw motion, the (IMF) was not

required in most of the cases in order to start the physiotherapy as early as possible. Also, a normal diet directly after surgery should be avoided till fractures are consolidated. From the first day after the operation, patients started speaking and it is recommended, in agreement with Derfoufi, Delaval et al. (2011), to put the patient on a liquid diet for 15 day after surgery followed by a soft diet over the next 15 days.

The patients received postoperative IMF with wire for 6 days on average (minimum 2 days, maximum 14 days) in few cases (10 patients, 22%) of incomplete reduction, such as a closed treatment of one side of bilateral condylar fracture and surgical therapy of the other side, early diastasis, malocclusion, or panfacial fractures with comminution. In these complex fractures, the average IMF duration was significantly longer. The fracture of one or both mandibular condyles in combination with other mandibular fractures can cause malocclusion due to variances in mandibular width by reduction or fixation faults. We believe that the application of a short period of IMF in these fractures may ensure that the patients maintain their preoperative occlusal state in cases of minor postoperative malocclusions, and that may also promote osseous union.

5.4 Osteosynthesis

In our sample, the placement of single straight four-hole miniplate (2.0, Medartis) on the posterior border of the condylar neck surface were used in 59% of cases (29/ 49), and placement of two miniplates was used in 37% of fractures (18/49). None of the plates fractured or bent, and 2 plates of one plate group had loosened screws.

To raise the stability of plates, sufficient distance between the screws and the fracture line should be kept. For this reasons, miniplates with bars should be selected wherever possible, taking the anatomical conditions into account (Meyer, Zink et al. 2008). Accordingly, 13 fractures in our group were treated using 4-hole miniplates with short bars, and 14 fractures using 4-hole miniplates with long bars. Undet et al reported that single miniplates can be sufficient if the fragments are adapted suitably (Undt, Kermer et al. 1999). On the other hand, functional forces are actually greater than the rigidity of one miniplate, and therefore to increase the stability of plates, the use of double plating, when circumstances permit, has been demonstrated and supported by much data,

(Tominaga, Habu et al. 2006; Pilling, Eckelt et al. 2010). Our findings are in accord with these findings, taking in account, fracture morphology, and that the accommodation of two plates requires a sufficient amount of bone in fracture region, especially in the proximal fragment.

The average of time for performance the surgical operation with double plating was 46 min in this study. We didn't find a significant difference in the mean of operating time between the use of one or two plates.

In 12 cases (24.5%), plates and screws had been removed at the request of symptom-free patients (58.4%, 7 of 12), and a part of the plates (16.6%, 2 of 12) were also removed because the patients complained of discomfort without infection or swelling at the area of plate, or parallel to the surgical keloidal scar or scar correction in (25%, 3 of 12).

Champy recommends the routine removal of all miniplates after 3 months (Persson, Hellem et al. 1986). Also previous retrospective studies indicated a need for the removal of plates in the maxillofacial region in 12–17% of traumatic cases (Brown, Trotter et al. 1989; Velich, Nemeth et al. 2002) .

5. 5 Results of functional findings

5.5.1 Interincisal Opening

The mean amount of maximal active interincisal opening was 45.5 mm (range 30 to 60 with SD= 5.7 mm). This value was acceptable in comparison to a standard collective (Landes and Sader 2007).

consistent with the results of other studies (Landes, Day et al. 2008), the MMO was sufficient for all types of fracture according to Spiessl & Schroll, indicating that there is no significant correlation between fracture type and MMO.

Chen et al reported that many factors can affect mouth opening, which involve the period of postsurgical IMF, severity of displacement before management, surgery of the fracture side, and patient cooperation during rehabilitation (Chen, Feng et al. 2011).

In our sample, 9 patients (22.5%) of 40 patients with no limited mouth mobility underwent postoperative IMF with a mean duration of 6 days, while in the 5 cases of limited mouth movement only one patient with 35 mm MMO underwent IMF for 14 days.

Therefore, we were unable to show any relation, between IMF and reduced MMO after 6 months. This aspect correlates with the findings of Marker, Nielsen et al. (2000). severe displacement before treatment often leads to a luxation of the mandibular head out of the glenoid fossa, which is associated with joint damage and functional loss of the lateral pterygoid muscle. In the present study, a limitation in MMO of less than 40 mm correlated with severely displaced condylar fractures in 3/5 cases. Therefore the reduced mouth mobility in this study may be attributed to severe displacement of fractured fragment before treatment and to postoperative scarring occurred during healing of the surgical site (Palmieri, Ellis et al. 1999; Yang, Chen et al. 2002). In the follow-up, 40 patients (89%) had recovered normal mouth opening up to 40 mm, reduced movement capacity of maximum interincisal opening between 30–39 mm was noted in 11% of the patients, and no patient showed an impairment range of less than 30mm. incisal maximum distances of 40 mm or more were considered normal, whereas an impairment range of 30–39mm was regarded to be slightly, and less than 30mm severely impaired (Mohl et al. 1988). But Dijkstra et al reported that most patients with MMO > 35 mm can chew and speak without difficulty (Dijkstra, Huisman et al. 2006). Our findings are in accord with these findings, so that difficulty chewing was reported only in 2 patients with MMO< 35 mm.

5.5.2 Pro- and laterotrusion

The significance of pro and laterotrusion movements in evaluating the functional ability of TMJ is more meaningful than opening movements, because these measurements provide the best measures of translational motions of the condyle and could be affected to a greater degree through the damage of TMJ (Buschang, Throckmorton et al. 2001). In our group, the normal range of lateral protrusive movement was 10.54 mm to the fractured side and 10.57 mm to contralateral side, without differences between the contralateral and homolateral side.

Consistent with the results of another study (Trost, Trouilloud et al. 2009) with symmetrical mandibular movement in 84.4% of the patients at 6 months, the present study also showed symmetrical motion in 88.9% and asymmetrical movements (more than 2 mm difference in lateral movements between the two sides) in 5 patients (11.1%). The reason for asymmetrical movements cannot be definitively clarified,

contra-lateral un-operated head fractures (2 patients), lack of patient cooperation during rehabilitation (1 patient), and/or poor initial repositioning of fractures (2 patients) might be responsible for this. In the literature, the limitations of movement of the condyle are related to adhesions in the articular cavity, postoperative scarring in the capsular ligament system and disc dislocation (Hlawitschka, Loukota et al.2005). According to Van Damme et al, pro- and laterotrusion movements are rated as follows: normal >6 mm, slightly disturbed 6–4mm, severely disturbed < 4mm (Smets, Van Damme et al. 2003). Our study showed a little reduction in lateral movements of less than 7 mm in 2 cases (4%), and slight restricted anterior movements of less than 7 mm (4-6 mm) in 13% (6 patients). In these patients, the slight loss of protrusion and lateral pathways was not causing any complaint. Our values were in part in line with the literature (Reinhart et al. 1996) with 2.9% of limited pro and laterotrusion movements, but not in line with the outcomes observed by MacArthur, Donald et al. (1993), who reported the restriction in anteroposterior or lateral movements in more than 43% of cases. However, a retrospective analysis of non-surgical treatment of condylar fractures in adults confirmed the limitation in 14 out of 49 patients (29%) (Smets, Van Damme et al. 2003). The previous results highlighted the benefits of open reduction over closed treatments in re-establishing the functional task of the lateral pterygoid muscle in translational movements of the condyle (Hlawitschka, Loukota et al. 2005)

5.5.3 TMJ and masticatory muscle Pain

The prevalence of pain in the temporomandibular region in normal population ranges from 2%–15% (Gorgu, Deren et al. 2002).

In a review of the literature, a distinction can be made between different forms of pain (pain during physical activity, pressure pain and spontaneous pain or persistent pain), accordingly, the possibility of comparing the pain after surgical reduction of condyle with other studies is limited, because different types of pain were described.

In the present study, 3-point Likert-type scale in a score of I to III was used to measure the intensity of pain or discomfort levels. At the follow-up, 3 cases (6%) of slight joint pain on mastication at the fractured side were seen, and in one case slight pain was noted in the non-affected joint, which was accompanied with tenderness on lateral palpation. The cause of pain in this patient was inefficiency in the posterior occlusal

support, and in addition to this, the TMJ overloading because unilateral chewing and thus increased activity of mastication on the un-fractured side.

The authors found different distribution of tenderness to palpation after surgical reduction of fracture, for example 4% by Stiesch-Scholz, Schmidt et al. (2005) and about 10% of the cases by Hochban, Ellers et al. (1996), while in our group we noticed TMJ tenderness to palpation just in 4% (2/49) of the fractures.

No case of spontaneous pain or persistent pain was observe. Altogether pain in all forms occurred in 6% of cases, and all cases of TMJ discomfort accompanied fracture type III (high condylar neck fracture with deviation/displacement). We agree in our findings with Yang et al, who after surgical treatment of condylar and subcondylar fractures reported TMJ pain in 1 out 22 patients (4.55%) of cases in subcondylar subgroups, and 7.14% in condylar subgroups, indicating that the closer the fracture level is to the TMJ, the greater the probability of TMJ symptoms (Yang, Chen et al. 2002). Moreover, based on our patient population, it could be demonstrated, that whenever the time between operation and follow up is longer, the appearance of pain can decrease considerably.

In addition to TMJ pain, the diagnosis of masticatory muscle pain during function should be also included in the follow up, due to the fact that any increase in the muscular compensation indicates a function Impairment. Out of 45.3 patients 6.6% had slight pain on palpation located in masticatory muscles on the side of the fracture, and of these just one patient experienced discomfort in the masseter muscle in the affected side during chewing. In this case, the pain can be attributed to the scarring in the traumatized masseter muscle as a result of excess short surgical approach. No muscle pain occurred bilaterally. the low percentages of free-muscular pain are to be seen as a good outcome. Our findings are not in accord with Yang's findings, who found that impaired masticatory function and pain located to masticatory muscles are seen significantly more frequently in patients treated surgically (Yang, Chen et al. 2002). Talwar et al. also reported imbalances and dysregulation in masticatory muscle after condylar fractures. However, his collective is not strictly comparable to the present collective, since it is an investigation on bilateral fractures (Talwar, Ellis et al. 1998). Hochban et al. also reported muscle pain in 30.0% of conservatively treated patients, and 10.0% after surgical treatment (Hochban, Ellers et al. 1996).

5.5.4 TMJ Clicking

The occurrence of TMJ sounds should be considered also as a parameter for assessment of joint function. 10% (5/49) of our cases reported postoperative clicking or crepitation at opening and closing movements daily or sporadically from the TMJ on the operated side, also Joint clicks at the opposite side were diagnosed in 8% of cases (4/49), but neither TMJ dysfunction nor resorption of the condyle developed. The low percentage of TMJ clicks in this study is partially attributed to the good anatomic repositioning of the condyle and careful handling of condyle components. The percentage of TMJ clicking observed by us is not too different from the rate in normal population, where the incidence of clicking ranges from 6% to 48% (Andersson, Hallmer et al. 2007), and thus fractured condyles did not seem to have a major influence on the occurrence of joint sounds. In a study by Schmidt et al, the TMJ sounds were seen in 33% of surgically treated condyle (Stiesch-Scholz, Schmidt et al. 2005). Hochban et al. reported clicking in over 10% of TMJ after surgical treatment without additional differentiation of the side (Hochban, Ellers et al. 1996).

5.5.5 Assessment of the scar

The residual scar as a sequence of surgical intervention is frequently the subject of discussion after the surgical management of condylar fractures. The presence of a visible scar on the face reduces, without doubt the value of open treatment of condylar process fractures.

In respect of scarring stadium, the optimal time for postoperative rehabilitation is within the first 9 postoperative months, because the normal wound-healing process persists for more than 6 months (Chen, Feng et al. 2011).

81.6% (40/49) of patients in our series described their cosmetic outcome as good, and 12.2% (6/49) were moderately satisfied with the appearance of their scarring, while only 6.2% found the scar unsightly. This result is comparable with the study of Manisali, Amin et al. (2003). He interviewed 14 patients with open reduction via the retromandibular access 6 months after surgery. He showed that ten patients (72%) were satisfied with the cosmetic results of the operation, two patients (14%) rated the result as sufficient, and another two patients (14%) found the result unsatisfactory. Kallela et al reported that 1 of 11 patients who were treated by a submandibular approach complained about the scar (Kallela, Soderholm et al. 1995).

Joss et al indicated in a long-term study on surgical operated patients that the scar was in 92.5 % of cases unremarkable and aesthetically satisfactory, and in 7.5% of patients presented no satisfactory results because of keloid formation (Joss et al, 2007). The scarring from the viewpoint of the examiners (maxillofacial surgeons) was also subjectively evaluated regarding dimensions and color of the scar.

According to Landes et al, scarring was scored as unacceptable when the scar was >2mm in diameter and >1mm in height (Landes, Day et al. 2008). In our group, the majority of the patients had acceptable cosmetic appearance of the scar (barely visible or visible but thin and linearly integrated into Langer's lines). Only 6 of the 49 cases (12.3%) had scars that were either hypertrophic (n=2) or wide (n=4). two broad or hypertrophic scars (4.1%) were found in this study after metal removal.

In regard to scar color, the cosmetic outcome was acceptable (barely visible or visible but normal skin color), except 9 cases, where we observed a subjectively disturbing scars that were either red (n= 8) or hyper-pigmented (n=1).

This observation tallies with Ellis's results. A detailed study by Ellis et al found that the scar was perceptible in 79 of the 183 (43%) patients treated using the open approach; in 92 (50%) a scar was visible, but with normal skin texture; and in 4 patients (2%) the scar was hypertrophic; in 3 (2%) it was wide (Ellis, McFadden et al. 2000).

In summary, it can be stated in our study that scar situations were substantially good in long-term follow-up. This is due to the topographically favorable localization and the short length of the incision, so that the scar length was on average 36 mm, which is in agreement with literature values.

5.5.6 Assessment of facial nerve function

The risk of facial nerve damage is often discussed as an argument against an operative therapy of condylar fracture, so that open reduction of fracture is considered due to the complicated anatomic relationships as a risky and hazardous intervention to vital structures (Suzuki, Kawamura et al. 2004; Stiesch-Scholz, Schmidt et al. 2005).

In the current study, temporary weakening of the action of the marginal branch of the facial nerve occurred in (19/49) (38.8%) of fractures, which could still be seen in 5 patients (10.2%) after three months, but fortunately, lower lip "weakness" resolved in all patients in our series by the 6-month period, except that in 2 patients we recorded slight weakness grad of permanent facial palsy (noticeable only on close inspection of the mouth, and slight asymmetry of smile with maximal effort). The exact reason for nerve

damage was not definitively established in all patients. In most cases, the fractured condyle fragments were displaced medially, so the nerve distribution was caused probably by mechanical pressure from surgical retractors on the marginal branch of the facial nerve during surgery, so that retraction superiorly to expose the condylar process stretched the marginal or buccal branches to the most. In the two cases of permanent dysfunction, the facial nerve damage was presumably attributable to lack of operator's experience and skill. Our experience indicates that this procedure requires careful surgery with careful dissection; the nerve has to be identified and protected. Assael et al supported this premise. They indicated that the risk of facial nerve injury is closely related to prolonged traction on the operated site, experience of the surgeon, post injury edema, and other factors causing difficult wound access such as obesity (Assael 2003). In parallel with our findings, Manisali et al confirmed after a review of the literature that the incidence of temporary facial nerve palsy in the submandibular (Risdon) approach varies from 11 to 37%. Manisali, Amin et al. (2003) and Widmark et al reported that the incidence of facial nerve injury after submandibular incision was 5.3% to 48.1% (Widmark, Bagenholm et al. 1996), whereas this incidence varies from 8% to 19% for the retromandibular approach according to Ellis, McFadden et al. (2000); Lima, Asprino et al. (2011). The frequency of permanent damage after open reduction is noted by NEFF et al. to be 4.2% (Hlawitschka, Loukota et al. 2005).

5.5.7 Occlusal defects

One of the most important goals of treatment of condylar process fracture is restoring the pretraumatic occlusal relationship.

After the management of condylar fractures, discrepancy in occlusion is considered to be the most obvious problem for patients and also for the examiner. occlusal defects are a key source of complaints, because even a minor degree of malocclusion can annoy the patient. Ellis et al indicated, that posttraumatic dysfunction complaints following TMJ fractures might be mainly attributed to malocclusion (Ellis, Simon et al. 2000).

The assessment of post-trauma occlusion is usually difficult due to the lack of pre-traumatic information about original state of the occlusion (Vesnaver, Ahcan et al. 2011). In the literature, percentages of postsurgical malocclusion vary widely. This is most likely to be due to the difference of the criteria used for occlusion assessment, additionally, the occurrence of impaired dental occlusion is closely related with

a patient's dental condition, additional fractures in the maxillofacial region, dislocated bilateral condyle fractures, inadequate treatment, or inadequate adaptation of fractured fragments (Ellis, 1998) (Meyer, Zink et al. 2008).

In this study at follow-up, dental occlusion was completely re-established (as remembered by the patient) in (40/45) patients (89%). Altered occlusion developed in 5 cases, as a result of an unoperated condylar head fracture on the opposite side in 1 patient, and in 3 cases due to concomitant fractures in the mandibular or maxillofacial complex.

The results found in our study are in agreement with results reported in the literature, i.e., 8.3% to 12.5% of malocclusion by Eulert, Proff et al. (2007), and 9.1% to 12.1% after 6 months to 3 years in a group of patients treated with open reduction (Ellis, Simon et al. 2000).

5.6 Evaluation of calculated indexes

5.6.1 Assessment of clinical dysfunction index according Helkimo
restoration of function is one of the most important study parameter for the patients. In this research, the functional capabilities of the masticatory system were assessed using the Helkimo clinical dysfunction index. The standardized dysfunction index according to Helkimo includes the essential criteria of post-traumatic clinical findings and thus allows assessment of different symptoms of individual structures of the stomatognathic system (Helkimo M. 1974), and offers a better possibility for comparison of functional outcomes of studies (Eulert S. 2002).

In our group, the Helkimo index established that 75.6% of patient population (34/45) has a low score of D0 (symptom-free). Eulert et al found absence of dysfunction D0 in 17.5% of surgically operated patients (Eulert S. 2002). Also Schneider et al pointed out in one study on the surgically operated condylar fracture that 20% of patients were symptom-free (Schneider M. 2005). The further distribution in our series resulted 10 patients (22%) with D I (slight dysfunction), while only 2.2% of subjects (1/45) were classified as having moderate dysfunction, and no patient had a severe dysfunction. our results are in agreement with results reported in Pohlenz's et al study, showing that a D 0 score (symptom-free) was diagnosed in 64.5 of cases (20/31), and D I (mild dysfunction) was seen in 29% of subjects (9/31) and severe symptoms didn't appear

(Klatt, Pohlenz et al. 2010). Other studies reported a percentage of a severe dysfunction in 7.9% of the cases after open reduction with miniplate for condylar fracture (Eulert S.2002). Helkimo found different frequencies of all grades of dysfunction in one study on normal population. The clinical dysfunction index in his subjects showed: severe symptoms in 22%, moderate symptoms in 25%, mild symptoms in 41% and 12% had no symptoms (Helkimo M. 1985). Thus, the calculated degree of dysfunction in our research could be described as low compared with the Helkimo's findings on the general population.

Regarding the correlation between postsurgical position of the condyle and the clinical results, our statistical findings highlighted a significant relationship between the correct anatomical reduction of the fractured condyle and functional parameters. This aspect is supported by the finding of Kremer et al, indicating that good anatomical reduction of the fracture will improve the chance for uncompromised function for many years (Undt, Kermer et al. 1999). Otherwise, another randomized study showed approximately homogeneous functional treatment results after closed treatment and surgical reduction (Joos and Kleinheinz 1998).

5.6.2 classification according to Hochban (Hochban W. et al. 1996)

The pure functional parameters (mouth opening, lateral deviation by mouth opening, and laterotrusion) are only used to evaluate the dysfunction index according Hochban which is divided into 4 degrees (Hochban, Ellers et al. 1996). This classification provides objective criteria which is easy to rate, and offers the possibility of a more accurate differentiation of the mandibular motion.

84.6% of the patients (38/45) were classified as grade 0 (no dysfunction). Grade I (slight impairment) was seen in 11% of cases (5/45). 2 patients showed moderate dysfunction (grade II), and no patient showed severe dysfunction (grade III). Our outcomes thus correspond to the findings of Joss et al. A long-term follow-up by Joss et al after surgical therapy of unilateral condylar fractures found that 82.5% out of 40 patients had no dysfunction, and 17.5% of patients had light dysfunction (Stolzer, Joos et al, 2007).

5.7 Radiographic findings

As discussed in the introduction, exact postoperative assessment of open reduction of condylar process fractures is essential because of the limited surgical access and inappropriate intraoperative visibility (Ellis, McFadden et al. 2000; Meyer, Zink et al. 2008). Choi reported that conventional radiographs are inaccurate in the condylar region due to the superposition of anatomical bone structures in the area, a lack of sharpness, and image distortion (Choi, Huh et al. 2003). At the same time, digital volume tomography (DVT) provides an option for digital three-dimensional reconstructed imaging of routine cases with less metallic artifacts, short scanning period (10–70 seconds), and lower radiation doses than normal CT. In agreement with literature (Honda, Arai et al. 2004; Tsiklakis, Syriopoulos et al. 2004), we have found that the evaluation by use of DVT imaging guarantees the absence of superposition of adjacent structures and consequently enables high diagnostic value and satisfactory investigation of joint morphology and bony components of the TMJ. We found that the DVT is suitable for assessment of postoperative results after open reduction of condylar fracture, and it may therefore be recommended that this imaging technique should be considered as a choice for examination of bony changes of the TMJ.

5.7.1 pre- operative assessment:

In this study, the pretherapeutic degree of displacement, dislocation of condylar fragment, and the loss of vertical height of mandibular ramus were measured to decide whether treatment should be by open method and to allow the evaluation of accuracy of anatomical reduction.

According to the classification proposed by Hochban as commented under 3.5.5, the results of repositioning and fixation in the follow-up examination are considered as a correct reduction if the fracture is accurately reduced without any difference between the fractured and non-fractured sides. But Hochban found that the difference between the two sides should be considered as insignificant if the difference is less than 3° anteriorly/posteriorly, laterally medially $\leq 5^\circ$, and the shortening of ramus height less than 2 mm, indicating good reduction of the fractures in an anatomical position.

Based on our data, a satisfactory reduction (shortening less than 5 mm, anterior/posterior $\leq 5^\circ$, lateral/medial $\leq 10^\circ$) can be achieved in every case. But actually, our evaluation of follow-up radiographic measurements indicated that the anatomical repositioning of the fractured part was optimal in 23 fractures (46.9%).

These findings are not in line with the results reported by Pohlenz et al in a clinical follow-up examination of surgically treated fractures of the condylar process using the transparotid approach. He found the anatomical correct reduction just in 2 /26 fractures (7.6%), and good repositioning in 19/26 cases (73%) (Klatt, Pohlenz et al. 2010).

In another study Schneider re-examine 40 patients with displaced or dislocated fractures of the mandibular condyle. In 20 patients (21 fractures) an intraoral approach, in another 20 patients (24 fractures) an extraoral perimandibular approach was used. In the extraoral group, 21 (88%) out of 24 fractures had been reconstructed in an anatomically correct manner, whereas reconstruction was correct in only 11 (52%) of the 21 fractures in the intraoral group (Schneider, Lauer et al. 2007).

The visibility provided by the surgical access, the choice and number of internal fixation hardware play an important role for performing a correct anatomic reduction. The fractures in this study were all repositioned and fixed using the modified Risdon approach, which offers a good visibility over the fracture, allowing one to set the fracture fragment and facilitating the application of bone plates.

In this series, radiographs of 18 patients receiving the treatment from an inexperienced operator in this technique, confirmed that the fracture fragments had healed in the correct position in 4 cases (22.2%), while good reduction was achieved in 12/18 of the cases. On the other hand, the correct open reduction was possible in 61.2% of cases (19/31), which had been treated by an experienced surgeon, indicating that the experience of the surgeon is another major variable in the open reduction of the condylar fractures.

The relationship between the clinical and radiological findings has been debated in many writings. In our study of 23 cases of correct anatomical open reduction of the condylar process, minimal dysfunction existed only in 1 case, while 50% of the patients with inaccurate anatomical reduction showed dysfunction, indicating a strong correlation between the functional and x-rays analysis.

Haug and Assael found, in accord with our findings, that accurate repositioning of the fracture segments should permit rapid healing and rapid return to normal function

(Haug and Assael 2001; Assael 2003). However, in contrast to our data, Takenoshita, Ishibashi et al. 1990; Konstantinovic and Dimitrijevic 1992; Umstadt, Ellers et al. 2000 didn't find any correlation between functional and radiological results. Also Iizuka reported that accurate reduction of the fracture will not invariably result in a normal physiological function of the condyle (Iizuka, Ladrach et al. 1998).

5.7.2 Shortening in ramus height

The re-establishment of the vertical ramus dimension is one of the important aims of open reduction (Choi, Huh et al. 2003; Zachariades, Mezitis et al. 2006). The reduction of ramus height is reflected clinically in an abnormal occlusion, anterior open bite, and backward position of the mandible (Choi 1997).

In most cases examined in the present study, restoration of the original vertical ramus length following open reduction and internal fixation of the condylar process was evident. Similar to the data reported by Ellis and Throckmorton 2000, in our series the average radiological discrepancy in ascending ramus height between the operated and non-operated side was less than 1 mm. After all, the reduction of the mandibular ramus length between 1-3 mm was calculated in some cases 32.6% (16/49). 12/16 of these patients had concomitant fractures of the mandible or maxilla, and the rest were operated by an inexperienced surgeon.

However, on comparing radiological values of ramal vertical reconstruction and pre-operative measurements, a significant improvement was demonstrated with surgical reduction, which was accompanied by nearly complete recovery of the function.

5.7.3 complications of Osteosynthesis

failure in condylar osteosynthesis is discussed in the literature as one of the complications after surgical reduction of condylar fracture. These failures of condylar osteosynthesis are compounded if the hardware is deficient and if there are technical difficulties, difficulties in the selection of adequate dimensioning and difficulties in an adequate positioning of the hardware on the bone surface (Choi and Yoo 1999; Choi, Yi et al. 2001).

In our study, stabilization was performed with single (30 fractures) or double miniplates (18 fractures). This type of osteosynthesis showed adequate long-term results, although

we observed a screw loosening in 2 patients with a single plate, whilst the detection of a bent or fractured plate was not observed.

Our findings are supported by a similar outcome reported by Vogt, Roser et al. (2005), he observed miniplate fractures in 3 subjects (5.9%) from 48 patients with 52 condylar neck fractures classes II and IV according to the Spiessl and Schroll, who were treated using a transparotid approach. However, Hammer et al reviewed 31 condylar neck fractures in 30 patients for a minimum of 6 months. The fractures in 20 cases were managed with four-screw monocortical adaptation miniplates. Eight fractures exhibited complications associated with osteosynthesis requiring reoperation (4 plate fractures, 3 cases of screw loosening associated with infection, 1 malposition). Complications happened exclusively in the cases fixed with a single miniplate (Hammer, Schier et al. 1997).

Moreover, in agreement with studies by Rallis, Mourouzis et al. (2003); Jensen, Jensen et al. (2006), the present study shows that when 2 miniplates were applied, no complication of osteosynthesis was observed.

It is interesting to note that the double adaptation plating is approximately 4 to 5 times stronger than the single plating, it can allow to restore the tension and compression lines at the condylar region (Choi, Kim et al. 1999; Tominaga, Habu et al. 2006).

Therefore, and in keeping with the results in our group, we support the recommendation that condylar fractures should be managed with at least 2 miniplates or plates with high rigidity to resist the functional load during the period of bone healing as the 3D Condylar Fracture Plate. The use of the 3D miniplate system on the subcondylar and condylar neck fractures area is reliable and an effective treatment. It provides good stability in most cases and the operating time is shorter (Malhotra K, Sharma A et al. 2012).

6. Appendix

Follow-up questionnaire

Patientennr. □□□□□□□□

Name

Birth date □□□□□□□□

gender male

female

Age at time of surgery □□ years

Address and Telefonnr

date of accident □□ □□ □□□□

fracture classification according Spiessel and Schroll

Class I	condylar neck fracture, but there is virtually no deviation/ displacement of the fragments	
Class II	low condylar neck fracture with deviation/displacement	
Class III	high condylar neck fracture with anterior, posterior, medial, or lateral deviation/ displacement	
Class IV	low condylar neck fracture with dislocation	
Class V	high condylar neck fracture with dislocation	

the direction of displacement or dislocation	(anterior,posterior,lateral,medial)
the measured angle of displacement or dislocation	

• **fracture localization**

Collum	unilateral	right
		left
	bilateral	

accompanying fractures: 1- Yes 2- no

If so, where?

age of fracture at time of surgery(days)

0 bis 3	4 bis 7	8 bis 11	>12

occlusive support (dental status) : available- or absence of **occlusive support** in dentition of the patient **(EICHNER-classification):**

• **classification of occlusive support**

classification according to number of existing supporting zones **(EICHNER-classification):**

- consideration of gaps and occlusion situation (both jaws)

A- natural antagonistic teeth in contact in all 4 supporting zones

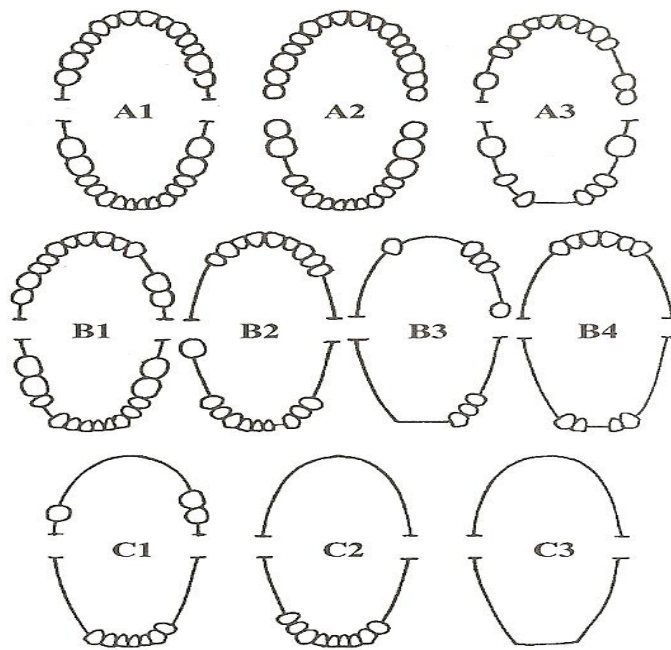
- A1: all teeth existent ◇
- A2: 1 gap ◇
- A3: multiple gaps ◇

B- some of the natural antagonistic teeth in contact

- B1: three supporting zones ◇
- B2: two supporting zones ◇
- B3: one supporting zone ◇

- B4 anterior tooth contact but no supporting zones ◇

C- no occlusal contact among the few remaining teeth



Eichner classification

the Operation:

- postoperative hospitalization time (**day**)

- date of Operation:

- duration of operation: hours, Min

• **the surgeon:**

• **the Assistant:**

- **Drainage** : yes, no which?

- **antibiotics** : yes, no

if so, which and the dose ?

duration of antibiotic (days):

• **osteosynthesis:**

• **postoperative intermaxillary fixation IMF (type and duration):**

Rigid	elastic	partly rigid ,partly elastisch	no

When yes, the duration:

• **Osteosyntheses material:**

miniplates number	Eckelt lag screw	other

• **hardware removal:**

Performed Date	Not performed and scheduled	Not performed and not scheduled

• **complications:** yes, no

When yes, what?

• **therapy duration: days**

hospitalization time (as a whole)	
hospitalization time (post-OP)	
Outpatient care	

• **Revision:**

Yes	no
-----	----

Diagnosis:

[clinical examination]:

1- mandibular mobility:

*** Interincisal Opening:**

A)- pain during maximum interincisal opening?

existent	slight existent	Not existent

B)- Do you feel that your mouth can not be opened as much as it would be possible?

yes	no
-----	----

C)- Evaluation of maximum interincisal opening: (Vertical Limitation)

The Value of mouth opening	passiv	
	Activ	

***Lateral Limitation**

D)- Lateral movement: (Laterotrusin)

The Value of Lateral movement	passiv	
	Activ	

2- TMJ function:

E)- do you feel that your chewing function is impaired through TMJ ?

yes	no
-----	----

F)- pain in TMJ region during chewing?

existent	slight existent	Not existent

G)- do you notice TMJ sounds during mouth opening?

Yes	no
-----	----

When yes, which?

H)- Score of TMJ Function impairment (TMJ Sounds):

A	Smooth movement without TM-joint sounds and deviation on opening or closing movements ≤ 2 mm	0
B	TM-joint sounds in one or both joints and/or deviation ≥ 2 mm on opening or closing movements	1
C	Locking and/or luxation of the TM-joint	5

3- masticatory muscles

I)- do you feel pain in masticatory muscles during chewing?

1- yes 2- no

When yes, where?

K)- Muscle pain during palpation:

A	No tenderness to palpation	0
B	Tenderness to palpation in 1-3 palpation sites	1
C	Tenderness to palpation in 4 or more palpation sites	5

L)- do you chew evenly on both sides?

yes	no
-----	----

4- TMJ Palpation:

No pain during Palpation	
Pain during Palpation, and where?	

5- oclussal disturbance:

M)- Midline Deviation: 1- Yes 2- no

When yes, how much and the direction?

N)- Do you feel when you close your mouth, that the teeth touch them on one side rather than on the other side?

ja	Nein
----	------

6- Assessment of the scar

P)- Patients' opinion of cosmetic outcome of scar ?

good	fair	disturbing
------	------	------------

P&)- status of scar:

The length	The width

The outcomes of assessed scar according to the observer

Scaring evaluation	No noticeable scar	Visible but thin and linear	Wide scar > 2mm in diameter	Hypertrophic scar > 1mm in elevation or keloid

Scaring color

Scaring color	No noticeable	Visible but normal skin color	Red scar	Hyper pigmented	Hypo pigmented

7- Assessment of facial nerve function

the grade of motor nerve function according to House Brackmann Facial Nerve Grading System:

Grade	Definition
I (no deficit)	Normal symmetrical function in all areas
II (mild weakness)	Slight weakness noticeable only on close inspection mouth. Slight asymmetry of smile with maximal effort.
III(moderate weakness)	Obvious weakness, but not disfiguring asymmetrical mouth movement with maximal effort
IV (severe weakness)	Obvious disfiguring weakness and only barely perceptible motion. At rest : asymmetry. Mouth : slight movement
V (absence of function)	No movement

the duration of postoperative weakness:

	Post-Operation(when yes , how many months)	> 6 monate post-Operation
yes		
No		

do you notice changes in your facial expression after the operation ?

existent	slight existent	Not existent
1	2	3

postoperativ Radiographic assessment :

A	Correct open reduction	(anatomically correct)
B	Good result of open reduction	(shortening less than 2 mm, anterior/ posterior $\leq 3^\circ$, lateral medial $\leq 5^\circ$)
C	Satisfactory result of open reduction	(shortening less than 5 mm, anterior/ posterior $\leq 5^\circ$, lateral / medial $\leq 10^\circ$)
D	Poor result of open reduction	(values above those mentioned)

- Shortening in ramus height

Vor der Operation	Nach der Operation

- complications of Osteosynthesematerial:

	Plate fracture	Incorrect position	Plate bending	Plate of screw loosening
yes				
no				

a comparison with the preoperative findings was required after each question:

had you this problem before the surgery on condylar fracture ?

In positive answer, the result of the previous question was not included in the review, because there was no direct correlation with the surgery.

7. Reference

- 1.** (1998). "Consensus Conference on Open or Closed Management of Condylar Fractures. 12th ICOMS. Budapest, 1995." Int J Oral Maxillofac Surg **27**(4): 243-267.
- 2.** Abbas, I., K. Ali, et al. (2003). "Spectrum of mandibular fractures at a tertiary care dental hospital in Lahore." J Ayub Med Coll Abbottabad **15**(2): 12-14.
- 3.** Abdel-Galil, K. and R. Loukota (2010). "Fractures of the mandibular condyle: evidence base and current concepts of management." Br J Oral Maxillofac Surg **48**(7): 520-526.
- 4.** Andersson, J., F. Hallmer, et al. (2007). "Unilateral mandibular condylar fractures: a 31-year follow-up of non-surgical treatment." Int J Oral Maxillofac Surg **36**(4): 310-314.
- 5.** Al Ahmed, H. E., M. A. Jaber, et al. (2004). "The pattern of maxillofacial fractures in Sharjah, United Arab Emirates: a review of 230 cases." Oral Surg Oral Med Oral Pathol Oral Radiol Endod **98**(2): 166-170.
- 6.** Arai, Y., E. Tammissalo, et al. (1999). "Development of a compact computed tomographic apparatus for dental use." Dentomaxillofac Radiol **28**(4): 245-248.
- 7.** Assael, L. A. (2003). "Open versus closed reduction of adult mandibular condyle fractures: an alternative interpretation of the evidence." J Oral Maxillofac Surg **61**(11): 1333-1339.
- 8.** *Austermann K.H., Lisiak O.: Untersuchungen zur Biomechanik von Kiefergelenkbrüchen In: Schuchardt K., Schwenzer N. (Hrsg.): Fortschr Kiefer Gesichtschir, Band 25. Thieme Stuttgart: 63-66, 1980*

- 9.** Banks, P. (1998). "A pragmatic approach to the management of condylar fractures." Int J Oral Maxillofac Surg **27**(4): 244-246.
- 10.** Barker, D. A., K. K. Oo, et al. (2011). "Timing for repair of mandible fractures." Laryngoscope **121**(6): 1160-1163.
- 11.** Basdra, E. K., A. Stellzig, et al. (1998). "Functional treatment of condylar fractures in adult patients." Am J Orthod Dentofacial Orthop **113**(6): 641-646.
- 12.** *Becker R. and Austerman K.H.:* In „ Zahn-Mund-Kieferheilkunde- spezielle Chirurgie“, Band 2, Schwenzer N. , Grimm G. (Hrsg.), Thieme Verlag, Stuttgart, 519-650, 1990.
- 13.** Biglioli, F. and G. Colletti (2008). "Mini-retromandibular approach to condylar fractures." J Craniomaxillofac Surg **36**(7): 378-383.
- 14.** Biglioli, F. and G. Colletti (2009). "Transmasseter approach to condylar fractures by mini-retromandibular access." J Oral Maxillofac Surg **67**(11): 2418-2424.
- 15.** Biller, J. A., S. D. Pletcher, et al. (2005). "Complications and the time to repair of mandible fractures." Laryngoscope **115**(5): 769-772.
- 16.** Boole, J. R., M. Holtel, et al. (2001). "5196 mandible fractures among 4381 active duty army soldiers, 1980 to 1998." Laryngoscope **111**(10): 1691-1696.
- 17.** Booth PW, Schendel S, Hausemen J-E: Radiology for maxillofacial trauma, *in* Booth PW, Hausemen J-E (eds): Maxillofacial Surgery, Volume 1 (ed 2). London, UK, Churchill Livingstone Elsevier, 2006, pp 266-298
- 18.** Bormann, K. H., S. Wild, et al. (2009). "Five-year retrospective study of mandibular fractures in Freiburg, Germany: incidence, etiology, treatment, and complications." J Oral Maxillofac Surg **67**(6): 1251-1255.
- 19.** Borstlap, W. A., P. J. Stoelinga, et al. (2004). "Stabilisation of sagittal split advancement osteotomies with miniplates: a prospective, multicentre study with two-

year follow-up. Part III--condylar remodelling and resorption." Int J Oral Maxillofac Surg **33**(7): 649-655.

20. Bos, R. R., R. P. Ward Booth, et al. (1999). "Mandibular condyle fractures: a consensus." Br J Oral Maxillofac Surg **37**(2): 87-89.

21. Bottini, D. J., G. Gnani, et al. (2006). "Traumas of the middle skull base with TMJ involvement. Case report." Minerva Stomatol **55**(3): 151-157.

22. Brandt, M. T. and R. H. Haug (2003). "Open versus closed reduction of adult mandibular condyle fractures: a review of the literature regarding the evolution of current thoughts on management." J Oral Maxillofac Surg **61**(11): 1324-1332.

23. Brown, J. S., M. Trotter, et al. (1989). "The fate of miniplates in facial trauma and orthognathic surgery: a retrospective study." Br J Oral Maxillofac Surg **27**(4): 306-315.

24. Buschang, P. H., G. S. Throckmorton, et al. (2001). "Incisor and mandibular condylar movements of young adult females during maximum protrusion and lateratrusion of the jaw." Arch Oral Biol **46**(1): 39-48.

25. Cascone, P., P. Sassano, et al. (1999). "Condylar fractures during growth: follow-up of 16 patients." J Craniofac Surg **10**(1): 87-92.

26. Cascone, P., F. Spallaccia, et al. (2008). "Rigid versus semirigid fixation for condylar fracture: experience with the external fixation system." J Oral Maxillofac Surg **66**(2): 265-271.

27. Cenzi, R., D. Burlini, et al. (2009). "Mandibular condyle fractures: evaluation of the Strasbourg Osteosynthesis Research Group classification." J Craniofac Surg **20**(1): 24-28.

28. Chacon, G. E., K. H. Dawson, et al. (2003). "A comparative study of 2 imaging techniques for the diagnosis of condylar fractures in children." J Oral Maxillofac Surg **61**(6): 668-672; discussion 673.

- 29.** Champy, M., J. P. Lodde, et al. (1977). "[Mandibular osteosynthesis and compression]." Ann Chir Plast **22**(2): 165-167.
- 30.** Champy, M., J. P. Lodde, et al. (1976). "[Mandibular osteosynthesis according to the Michelet technic. I. Biomechanical bases]." Rev Stomatol Chir Maxillofac **77**(3): 569-576.
- 31.** Chen, C. T., C. H. Feng, et al. (2011). "Functional outcomes following surgical treatment of bilateral mandibular condylar fractures." Int J Oral Maxillofac Surg **40**(1): 38-44.
- 32.** Choi, B. H. (1997). "Magnetic resonance imaging of the temporomandibular joint after functional treatment of bilateral condylar fractures in adults." Int J Oral Maxillofac Surg **26**(5): 344-347.
- 33.** Choi, B. H., K. N. Kim, et al. (1999). "Evaluation of condylar neck fracture plating techniques." J Craniomaxillofac Surg **27**(2): 109-112.
- 34.** Choi, B. H. and J. H. Yoo (1999). "Open reduction of condylar neck fractures with exposure of the facial nerve." Oral Surg Oral Med Oral Pathol Oral Radiol Endod **88**(3): 292-296.
- 35.** Choi, B. H., C. K. Yi, et al. (2001). "Clinical evaluation of 3 types of plate osteosynthesis for fixation of condylar neck fractures." J Oral Maxillofac Surg **59**(7): 734-737; discussion 738.
- 36.** Choi, B. H., J. Y. Huh, et al. (2003). "Computed tomographic findings of the fractured mandibular condyle after open reduction." Int J Oral Maxillofac Surg **32**(5): 469-473.
- 37.** Choudhary, A. B., M. B. Motwani, et al. (2011). "Utility of Digital Volume Tomography in Maxillofacial Trauma." J Oral Maxillofac Surg.
- 38.** *Clementschitsch F.*: Über die Röntgenologie des Kiefergelenkes. In: Schuchardt K. (Hrsg.): Fortschr Kiefer Gesichtschir, Band 6. Thieme, Stuttgart: 47-63, 1960.

- 39.** Conti, A. C., P. V. Oltramari, et al. (2007). "Examination of temporomandibular disorders in the orthodontic patient: a clinical guide." J Appl Oral Sci **15**(1): 77-82.
- 40.** Crivello, O. (2002). "[Evaluation of mandibular movement after condylar fracture]." Rev Stomatol Chir Maxillofac **103**(1): 22-25.
- 41.** Dahlstrom, L., K. E. Kahnberg, et al. (1989). "15 years follow-up on condylar fractures." Int J Oral Maxillofac Surg **18**(1): 18-23.
- 42.** Derfoufi, L., C. Delaval, et al. (2011). "Complications of condylar fracture osteosynthesis." J Craniofac Surg **22**(4): 1448-1451.
- 43.** De Riu, G., U. Gamba, et al. (2001). "A comparison of open and closed treatment of condylar fractures: a change in philosophy." Int J Oral Maxillofac Surg **30**(5): 384-389.
- 44.** Defabianis, P. (2003). "TMJ fractures in children and adolescents: treatment guidelines." J Clin Pediatr Dent **27**(3): 191-199.
- 45.** Dijkstra, P. U., P. M. Huisman, et al. (2006). "Criteria for trismus in head and neck oncology." Int J Oral Maxillofac Surg **35**(4): 337-342.
- 46.** Dimitroulis, G. (1997). "Condylar injuries in growing patients." Aust Dent J **42**(6): 367-371.
- 47.** Dingman, R. O. and W. C. Grabb (1962). "Surgical anatomy of the mandibular ramus of the facial nerve based on the dissection of 100 facial halves." Plast Reconstr Surg Transplant Bull **29**: 266-272.
- 48.** Donoff, R. B. and S. M. Roser (1973). "Management of condylar fractures in patients with cervical spine injury: report of cases." J Oral Surg **31**(2): 130-135.
- 49.** Dworkin, S. F. and L. LeResche (1992). "Research diagnostic criteria for temporomandibular disorders: review, criteria, examinations and specifications, critique." J Craniomandib Disord **6**(4): 301-355.
- 50.** Eckelt, U. and M. Hlawitschka (1999). "Clinical and radiological evaluation following surgical treatment of condylar neck fractures with lag screws." J Craniomaxillofac Surg **27**(4): 235-242.
- 51.** Eckelt, U. (2000). "[Fractures of the mandibular condyle]." Mund Kiefer Gesichtschir **4** Suppl 1: S110-117.

- 52.** Eckelt, U. and S. Gerber (1981). "[Draw-screw osteosynthesis with a novel osteosynthesis instrument set in mandibular condyle fractures]." Zahn Mund Kieferheilkd Zentralbl **69**(6): 485-490.
- 53.** Eichner, K. Über eine Gruppeneinteilung der Lückengebisse für die Prothetik. Dtsch Zahnärztl Z 1955. 10: 1831
- 54.** Ellis, E., 3rd, K. F. Moos, et al. (1985). "Ten years of mandibular fractures: an analysis of 2,137 cases." Oral Surg Oral Med Oral Pathol **59**(2): 120-129.
- 55.** Ellis, E., 3rd, C. Palmieri, et al. (1999). "Further displacement of condylar process fractures after closed treatment." J Oral Maxillofac Surg **57**(11): 1307-1316; discussion 1316-1307.
- 56.** Ellis, E., 3rd (1998). "Complications of mandibular condyle fractures." Int J Oral Maxillofac Surg **27**(4): 255-257.
- 57.** Ellis, E., 3rd, D. McFadden, et al. (2000). "Surgical complications with open treatment of mandibular condylar process fractures." J Oral Maxillofac Surg **58**(9): 950-958.
- 58.** Ellis, E., 3rd, P. Simon, et al. (2000). "Occlusal results after open or closed treatment of fractures of the mandibular condylar process." J Oral Maxillofac Surg **58**(3): 260-268.
- 59.** Ellis, E., 3rd and G. Throckmorton (2000). "Facial symmetry after closed and open treatment of fractures of the mandibular condylar process." J Oral Maxillofac Surg **58**(7): 719-728; discussion 729-730.
- 60.** Ellis, E., 3rd, G. S. Throckmorton, et al. (2000). "Open treatment of condylar process fractures: assessment of adequacy of repositioning and maintenance of stability." J Oral Maxillofac Surg **58**(1): 27-34; discussion 35.
- 61.** Ellis, E. and G. S. Throckmorton (2005). "Treatment of mandibular condylar process fractures: biological considerations." J Oral Maxillofac Surg **63**(1): 115-134.

- 62.** Eckelt, U., M. Schneider, et al. (2006). "Open versus closed treatment of fractures of the mandibular condylar process-a prospective randomized multi-centre study." J Craniomaxillofac Surg **34**(5): 306-314.
- 63.** Eulert, S., P. Proff, et al. (2007). "Study on treatment of condylar process fractures of the mandible." Ann Anat **189**(4): 377-383.
- 64.** Feifel, H., J. Albert-Deumlich, et al. (1992). "Long-term follow-up of subcondylar fractures in children by electronic computer-assisted recording of condylar movements." Int J Oral Maxillofac Surg **21**(2): 70-76.
- 65.** Fonseca RJ, Walker RV, Bettx NJ, Barber HD. Treatment of mandibular condylar fractures. In Fonseca RJ (eds): Oral and Maxillofacial Trauma. Philadelphia, WB Saunders 1991; 527-67
- 66.** Fonsica , Raymond J .Book of Oral and Maxillofacial Surgery: Trauma, 2000, Volume 3, side (93)
- 67.** Fonsica , Raymond J .Book of Oral and Maxillofacial Surgery: Temporomandibular Disorders, 2000, Volume 4
- 68.** Fuhrmann, R. A., H. Wehrbein, et al. (1993). "[Computed tomographic imaging of the dentoalveolar-maxillary sinus lacuna of the dentate jaw]." Schweiz Monatsschr Zahnmed **103**(3): 285-291.
- 69.** Gernet W., Rammelsberg P.: Kiefergelenkerkrankungen und Funktionsstörungen. In: Schwenzer N., Ehrenfeld M. (Hrsg.), Zahnärztliche Chirurgie, Band 3, 3. Aufl., Thieme, Stuttgart, New York, 2000, 263-265 (book)
- 70.** Giroto, R., P. Mancini, et al. (2011). "The retromandibular transparotid approach: Our clinical experience." J Craniomaxillofac Surg.
- 71.** Girthofer, K. and G. Goz (2002). "TMJ remodeling after condylar fracture and functional jaw orthopedics a case report." J Orofac Orthop **63**(5): 429-434.
- 72.** Gorgu, M., O. Deren, et al. (2002). "Prospective comparative study of the range of movement of temporomandibular joints after mandibular fractures: rigid or non-rigid fixation." Scand J Plast Reconstr Surg Hand Surg **36**(6): 356-361.

- 73.** *Guenther H., Schwenzer N., Metz H.J.:* Fraktur, Luxation und Kontusion des Kiefergelenkes. In: Schuchardt K. (Hrsg): Fortschr Kiefer Gesichtschir, Band 11. Thieme, Stuttgart: 174-186, 1966
- 74.** Gundlach, K. K., E. Schwipper, et al. (1991). "[The regenerative capability of the condylar process of the mandible]." Dtsch Zahnarztl Z **46**(1): 36-38.
- 75.** Hammer, B., P. Schier, et al. (1997). "Osteosynthesis of condylar neck fractures: a review of 30 patients." Br J Oral Maxillofac Surg **35**(4): 288-291.
- 76.** Hans Henning Horch (Hrsg.), Traumatologie des Gesichtsschädel . Mund- kiefer- Gesichtschirurgie , 4. Aufl.,Elsevier GmbH; München,2007 .109 (book)
- 77.** Haug, R. H. and L. A. Assael (2001). "Outcomes of open versus closed treatment of mandibular subcondylar fractures." J Oral Maxillofac Surg **59**(4): 370-375; discussion 375-376.
- 78.** Haug, R. H. and M. T. Brandt (2007). "Closed reduction, open reduction, and endoscopic assistance: current thoughts on the management of mandibular condyle fractures." Plast Reconstr Surg **120**(7 Suppl 2): 90S-102S.
- 79.** Hayward, J. R. (1947). "Fractures involving the mandibular condyle; a post-treatment survey of 120 cases." J Oral Surg (Chic) **5**(1): 45-73.
- 80.** Hayward, J. R. and R. F. Scott (1993). "Fractures of the mandibular condyle." J Oral Maxillofac Surg **51**(1): 57-61.
- 81.** Helkimo, M. (1974). "Studies on function and dysfunction of the masticatory system. II. Index for anamnestic and clinical dysfunction and occlusal state." Sven Tandlak Tidskr **67**(2): 101-121.
- 82.** Hinds, E. C. and W. J. Girotti (1967). "Vertical subcondylar osteotomy: a reappraisal." Oral Surg Oral Med Oral Pathol **24**(2): 164-170.

- 83.** Hirschfelder, U., D. Mussig, et al. (1987). "[Functional orthodontic treatment of condylar fractures--a clinical and computerized radiography study]." Fortschr Kieferorthop **48**(6): 504-515.
- 84.** Hlawitschka, M., R. Loukota, et al. (2005). "Functional and radiological results of open and closed treatment of intracapsular (diacapitular) condylar fractures of the mandible." Int J Oral Maxillofac Surg **34**(6): 597-604.
- 85.** Hochban, W., M. Ellers, et al. (1996). "[Surgical reposition and fixation of mandibular condyle fractures via intraoral approach]." Fortschr Kiefer Gesichtschir **41**: 80-85.
- 86.** Honda, K., Y. Arai, et al. (2004). "Evaluation of the usefulness of the limited cone-beam CT (3DX) in the assessment of the thickness of the roof of the glenoid fossa of the temporomandibular joint." Dentomaxillofac Radiol **33**(6): 391-395.
- 87.** Hoopes, J. E., F. G. Wolfort, et al. (1970). "Operative treatment of fractures of the mandibular condyle in children. Using the post-auricular approach." Plast Reconstr Surg **46**(4): 357-362.
- 88.** Hovinga, J., G. Boering, et al. (1999). "Long-term results of nonsurgical management of condylar fractures in children." Int J Oral Maxillofac Surg **28**(6): 429-440.
- 89.** Hyde, N., M. Manisali, et al. (2002). "The role of open reduction and internal fixation in unilateral fractures of the mandibular condyle: a prospective study." Br J Oral Maxillofac Surg **40**(1): 19-22.
- 90.** Iizuka, T., C. Lindqvist, et al. (1991). "Severe bone resorption and osteoarthritis after miniplate fixation of high condylar fractures. A clinical and radiologic study of thirteen patients." Oral Surg Oral Med Oral Pathol **72**(4): 400-407.
- 91.** Iizuka, T., K. Ladrach, et al. (1998). "Open reduction without fixation of dislocated condylar process fractures: long-term clinical and radiologic analysis." J Oral Maxillofac Surg **56**(5): 553-561; discussion 561-552.

- 92.** Ikemura, K. (1985). "Treatment of condylar fractures associated with other mandibular fractures." J Oral Maxillofac Surg **43**(10): 810-813.
- 93.** Jacobovicz, J., C. Lee, et al. (1998). "Endoscopic repair of mandibular subcondylar fractures." Plast Reconstr Surg **101**(2): 437-441.
- 94.** Jacobs, H. G., Jacobs-Müller, C., Müller, G. H. (1977): Die Bedeutung der klinischen und röntgenologischen Diagnostik von Kiefergelenkfortsatzfrakturen für das therapeutische Vorgehen. Fortschr Kieferorthop **38**, 133-147.
- 95.** Jensen, T., J. Jensen, et al. (2006). "Open reduction and rigid internal fixation of mandibular condylar fractures by an intraoral approach: a long-term follow-up study of 15 patients." J Oral Maxillofac Surg **64**(12): 1771-1779.
- 96.** Jing, J., X. Sun, et al. (2001). "[Surgical treatment of old dislocated condylar process fractures]." Zhonghua Kou Qiang Yi Xue Za Zhi **36**(1): 64-66.
- 97.** John, M. T., C. Hirsch, et al. (2006). "Translating the research diagnostic criteria for temporomandibular disorders into German: evaluation of content and process." J Orofac Pain **20**(1): 43-52.
- 98.** Joos, U. and J. Kleinheinz (1998). "Therapy of condylar neck fractures." Int J Oral Maxillofac Surg **27**(4): 247-254.
- 99.** Kallela, I., A. L. Soderholm, et al. (1995). "Lag-screw osteosynthesis of mandibular condyle fractures: a clinical and radiological study." J Oral Maxillofac Surg **53**(12): 1397-1404; discussion 1405-1396.
- 100.** Kellman, R. M. (2003). "Endoscopically assisted repair of subcondylar fractures of the mandible: an evolving technique." Arch Facial Plast Surg **5**(3): 244-250.
- 101.** Kellman, R. M. and R. Cienfuegos (2009). "Endoscopic approaches to subcondylar fractures of the mandible." Facial Plast Surg **25**(1): 23-28.
- 102.** Killey HC: Fractures of the Mandible. Bristol: Wright & Sons, 1974

- 103.** Klatt, J., P. Pohlenz, et al. (2010). "Clinical follow-up examination of surgically treated fractures of the condylar process using the transparotid approach." J Oral Maxillofac Surg 68(3): 611-617.
- 104.** Kleinheinz, J., G. E. Anastassov, et al. (1999). "Indications for treatment of subcondylar mandibular fractures." J Craniomaxillofac Trauma 5(2): 17-23; discussion 24-16.
- 105.** Kniggendorf, E.: Klinische und Röntgenologische Untersuchungen zur Kiefergelenkfraktur. Med Diss, Hannover, 1979
- 106.** Koehler A.: Diagnostik und Therapie der Kieferfrakturen. Hüthig Verlag, Heidelberg, 27-29, 1951
- 107.** Kolk A.: Validierung von Kernspintomographie, elektronischer Axiographie, Röntgen und klinischer Funktionsanalyse zur Objektivierung funktioneller Behandlungsergebnisse nach Unterkieferkollumfrakturen. Med. Diss. Greifswald, 2002
- 108.** Konstantinovic, V. S. and B. Dimitrijevic (1992). "Surgical versus conservative treatment of unilateral condylar process fractures: clinical and radiographic evaluation of 80 patients." J Oral Maxillofac Surg 50(4): 349-352; discussion 352-343.
- 109.** Kruger , G.O : Textbook of oral and maxillofacial surgery In : principles of surgical technique , 6th Edn . J.P Brothers , New Delhi : P. 31 (1990)
- 110.** Lachard, J., F. Guilbert, et al. (1981). "[Intracranial penetration of the mandibular condyle: report on three cases (author's transl)]." Ann Otolaryngol Chir Cervicofac 98(10-11): 543-546.
- 111.** Landes, C. A. and R. Lipphardt (2005). "Prospective evaluation of a pragmatic treatment rationale: open reduction and internal fixation of displaced and dislocated condyle and condylar head fractures and closed reduction of non-displaced, non-dislocated fractures. Part I: condyle and subcondylar fractures." Int J Oral Maxillofac Surg 34(8): 859-870.
- 112.** Landes, C. A. and R. Lipphardt (2006). "Prospective evaluation of a pragmatic treatment rationale: open reduction and internal fixation of displaced and

dislocated condyle and condylar head fractures and closed reduction of non-displaced, non-dislocated fractures Part II: high condylar and condylar head fractures." Int J Oral Maxillofac Surg 35(2): 115-126.

113. Landes, C. A. and R. Sader (2007). "Sonographic evaluation of the ranges of condylar translation and of temporomandibular joint space as well as first comparison with symptomatic joints." J Craniomaxillofac Surg 35(8): 374-381.

114. Landes, C. A., K. Day, et al. (2008). "Prospective closed treatment of nondisplaced and nondislocated condylar neck and head fractures versus open reposition internal fixation of displaced and dislocated fractures." Oral Maxillofac Surg 12(2): 79-88.

115. Lautenbach, E.: Nachuntersuchungen von Kiefergelenkfrakturen. Schweiz Monatsschr Zahnheilk 74: 575-86, 1964

116. Lee, C., R. V. Mueller, et al. (1998). "Endoscopic subcondylar fracture repair: functional, aesthetic, and radiographic outcomes." Plast Reconstr Surg 102(5): 1434-1443; discussion 1444-1435.

117. Lee, J. W., Y. C. Lee, et al. (2010). "Reappraisal of the surgical strategy in treatment of mandibular condylar fractures." Plast Reconstr Surg 125(2): 609-619.

118. Lima, S. M. J., L. Asprino, et al. (2011). "Surgical Complications of Mandibular Condylar Fractures." J Craniofac Surg 22(4): 1512-1515.

119. Levy, R. A., W. T. Edwards, et al. (1992). "Facial trauma and 3-D reconstructive imaging: insufficiencies and correctives." AJNR Am J Neuroradiol 13(3): 885-892.

120. Loukota, R. A., U. Eckelt, et al. (2005). "Subclassification of fractures of the condylar process of the mandible." Br J Oral Maxillofac Surg 43(1): 72-73.

121. Luyk, N. H. and J. W. Ferguson (1991). "The diagnosis and initial management of the fractured mandible." Am J Emerg Med 9(4): 352-359.

- 122.** Mac, L. W. (1952). "Consideration of 180 cases of typical fractures of the mandibular condylar process." Br J Plast Surg **5**(2): 122-128.
- 123.** MacArthur, C. J., P. J. Donald, et al. (1993). "Open reduction-fixation of mandibular subcondylar fractures. A review." Arch Otolaryngol Head Neck Surg **119**(4): 403-406.
- 124.** MacLennan, W. D. (1969). "Fractures of the mandibular condylar process." Br J Oral Surg **7**(1): 31-39.
- 125.** Manisali, M., M. Amin, et al. (2003). "Retromandibular approach to the mandibular condyle: a clinical and cadaveric study." Int J Oral Maxillofac Surg **32**(3): 253-256.
- 125** Malhotra K, Sharma A, Giraddi G, Shahi AK., 2012 Versatility of Titanium 3D Plate in Comparison with Conventional Titanium Miniplate Fixation for the Management of Mandibular Fracture.
- 126.** Marker, P., A. Nielsen, et al. (2000). "Fractures of the mandibular condyle. Part 1: patterns of distribution of types and causes of fractures in 348 patients." Br J Oral Maxillofac Surg **38**(5): 417-421.
- 127.** Marker, P., A. Nielsen, et al. (2000). "Fractures of the mandibular condyle. Part 2: results of treatment of 348 patients." Br J Oral Maxillofac Surg **38**(5): 422-426.
- 128.** Martini, M. Z., A. Takahashi, et al. (2006). "Epidemiology of mandibular fractures treated in a Brazilian level I trauma public hospital in the city of Sao Paulo, Brazil." Braz Dent J **17**(3): 243-248.
- 129.** Martin, M. and C. Lee (2003). "Endoscopic mandibular condyle fracture repair." Atlas Oral Maxillofac Surg Clin North Am **11**(2): 169-178.
- 130.** Meyer, C., J. L. Kahn, et al. (2002). "Photoelastic analysis of bone deformation in the region of the mandibular condyle during mastication." J Craniomaxillofac Surg **30**(3): 160-169.
- 131.** Meyer, C., L. Serhir, et al. (2006). "Experimental evaluation of three osteosynthesis devices used for stabilizing condylar fractures of the mandible." J Craniomaxillofac Surg **34**(3): 173-181.

132. Meyer, C., S. Zink, et al. (2008). "Clinical experience with osteosynthesis of subcondylar fractures of the mandible using TCP plates." J Craniomaxillofac Surg 36(5): 260-268.

133. Michelet, F. X., J. Deymes, et al. (1973). "Osteosynthesis with miniaturized screwed plates in maxillo-facial surgery." J Maxillofac Surg 1(2): 79-84.

134. Miles, B. A., J. K. Potter, et al. (2006). "The efficacy of postoperative antibiotic regimens in the open treatment of mandibular fractures: a prospective randomized trial." J Oral Maxillofac Surg 64(4): 576-582.

135. Miloro, M. (2003). "Endoscopic-assisted repair of subcondylar fractures." Oral Surg Oral Med Oral Pathol Oral Radiol Endod 96(4): 387-391.

136. Mohl ND, Zarb GA, Carlsson GE, Rugh JD: A Textbook of Occlusion. Chicago: Quintessence 1988; 192–197

137. Mokros S.: Die operative Behandlung von Gelenkfortsatzfrakturen des Unterkiefers über den intraoralen Zugang – Optimierung der Methodik, Ergebnisse. Magdeburg, 1997

138. *Mueller W.:* Klinische und experimentelle Untersuchungen zur Biomechanik, Diagnostik und Therapie der Frakturen des Kiefergelenkes. Dissertation B, Med. Fak., Universität Halle, 1973.

139. N. Hardt, J. Kuttenger, *Craniofacial Trauma*, 15 DOI: 10.1007/978-3-540-33041-7_2, © Springer-Verlag Berlin Heidelberg 2010

140. Neff, A., A. Kolk, et al. (1999). "[New aspects for indications of surgical management of intra-articular and high temporomandibular dislocation fractures]." Mund Kiefer Gesichtschir 3(1): 24-29.

141. Neff, A., A. Kolk, et al. (2005). "[Small fragment screws vs. plate osteosynthesis in condylar head fractures]." Mund Kiefer Gesichtschir 9(2): 80-88.

- 142.** Neff, A., A. Kolk, et al. (2002). "[Surgical vs. conservative therapy of diacapitular and high condylar fractures with dislocation. A comparison between MRI and axiography]." Mund Kiefer Gesichtschir **6**(2): 66-73.
- 143.** Newman, L. (1998). "A clinical evaluation of the long-term outcome of patients treated for bilateral fracture of the mandibular condyles." Br J Oral Maxillofac Surg **36**(3): 176-179.
- 144.** Norholt, S. E., V. Krishnan, et al. (1993). "Pediatric condylar fractures: a long-term follow-up study of 55 patients." J Oral Maxillofac Surg **51**(12): 1302-1310.
- 145.** Oezmen, Y., R. A. Mischkowski, et al. (1998). "MRI examination of the TMJ and functional results after conservative and surgical treatment of mandibular condyle fractures." Int J Oral Maxillofac Surg **27**(1): 33-37.
- 146.** Palmieri, C., E. Ellis, 3rd, et al. (1999). "Mandibular motion after closed and open treatment of unilateral mandibular condylar process fractures." J Oral Maxillofac Surg **57**(7): 764-775; discussion 775-766.
- 147.** Parascandolo, S., A. Spinzia, et al. (2010). "Two load sharing plates fixation in mandibular condylar fractures: biomechanical basis." J Craniomaxillofac Surg **38**(5): 385-390.
- 148.** Park, J. M., Y. W. Jang, et al. (2010). "Comparative study of the prognosis of an extracorporeal reduction and a closed treatment in mandibular condyle head and/or neck fractures." J Oral Maxillofac Surg **68**(12): 2986-2993.
- 149.** Persson, G., S. Hellem, et al. (1986). "Bone-plates for stabilizing Le Fort I osteotomies." J Maxillofac Surg **14**(2): 69-73.
- 150.** Perthes G: U"ber Frakturen und Luxationsfrakturen des Kiefergelenkkopfchens und ihre operative Behandlung. Verh Dtsch Ges 133: 418–434, 1924
- 151.** Pilling, E., U. Eckelt, et al. (2010). "Comparative evaluation of ten different condylar base fracture osteosynthesis techniques." Br J Oral Maxillofac Surg **48**(7): 527-531.
- 152.** Proffit, W. R., K. W. Vig, et al. (1980). "Early fracture of the mandibular condyles: frequently an unsuspected cause of growth disturbances." Am J Orthod **78**(1): 1-24.
- 153.** Rallis, G., C. Mourouzis, et al. (2003). "Plate osteosynthesis of condylar fractures: a retrospective study of 45 patients." Quintessence Int **34**(1): 45-49.

- 154.** Rasse, M. (2000). "[Recent developments in therapy of condylar fractures of the mandible]." Mund Kiefer Gesichtschir **4**(2): 69-87.
- 155.** Raustia, A. M., J. Pyhtinen, et al. (1990). "Conventional radiographic and computed tomographic findings in cases of fracture of the mandibular condylar process." J Oral Maxillofac Surg **48**(12): 1258-1262; discussion 1263-1254.
- 156.** Rees, A. M. and S. Weinberg (1983). "Fractures of the mandibular condyle: review of the literature and presentation of five cases with late complications." Oral Health **73**(7): 37-41.
- 157.** Reinhart, E., Reuther, J.R., Michel, Ch., Kübler, N., Pistner, H., Bill, J., Kunkel, E.: Behandlungsergebnisse und Komplikationen bei operativ und konservativ versorgten Unterkieferfrakturen. In: Schwenger, N. (Hrsg.): Fortschr Kiefer Gesichtschir, Band 41. Thieme, Stuttgart New York: 64-7, 1996
- 158.** Rocton, S., A. Chaine, et al. (2007). "[Mandibular fractures: epidemiology, therapeutic management, and complications in a series of 563 cases]." Rev Stomatol Chir Maxillofac **108**(1): 3-10; discussion 10-12.
- 159.** Roth FS, Kokoska MS, Awwad EE, Martin DS, Olson GT, Hollier LH, et al. The identification of mandible fractures by helical computed tomography and panorex tomography. J Craniofac Surg.2005;16:394–399.
- 160.** Rowe NL, Killey HC: Fractures of the facial skeleton, in Edinburgh, UK, E&S Livingstone Ltd, 1955
- 161.** Sahm, G. (1988). "[Success and failure in orthodontic treatment following temporomandibular condylar fractures]." Fortschr Kieferorthop **49**(6): 557-567.
- 162.** Sawazaki, R., S. M. Lima Junior, et al. (2010). "Incidence and patterns of mandibular condyle fractures." J Oral Maxillofac Surg **68**(6): 1252-1259.
- 163.** Schendel, K. U., A. Wiesinger, et al. (1991). "[Results of functional activator treatment of collum fractures in the growth period]." Dtsch Zahnarztl Z **46**(11): 726-728.
- 164.** Schimming, R., U. Eckelt, et al. (1999). "The value of coronal computer tomograms in fractures of the mandibular condylar process." Oral Surg Oral Med Oral Pathol Oral Radiol Endod **87**(5): 632-639.

- 165.** Schmelzeisen, R., R. Cienfuegos-Monroy, et al. (2009). "Patient benefit from endoscopically assisted fixation of condylar neck fractures--a randomized controlled trial." J Oral Maxillofac Surg **67**(1): 147-158.
- 166.** Schmitter, M., B. Ohlmann, et al. (2005). "Research diagnostic criteria for temporomandibular disorders: a calibration and reliability study." Cranio **23**(3): 212-218.
- 167.** *Schneider M.:* Die operative Behandlung von Gelenkfortsatzfrakturen des Unterkiefers. Dissertation, Technische Universität Dresden, 2005.
- 168.** Schneider, M., G. Lauer, et al. (2007). "Surgical treatment of fractures of the mandibular condyle: a comparison of long-term results following different approaches - functional, axiographical, and radiological findings." J Craniomaxillofac Surg **35**(3): 151-160.
- 169.** Schneider, M., F. Erasmus, et al. (2008). "Open reduction and internal fixation versus closed treatment and mandibulomaxillary fixation of fractures of the mandibular condylar process: a randomized, prospective, multicenter study with special evaluation of fracture level." J Oral Maxillofac Surg **66**(12): 2537-2544.
- 170.** Sear, A. J. (1972). "Intra-oral condylectomy applied to unilateral condylar hyperplasia." Br J Oral Surg **10**(2): 143-153.
- 171.** Seemann, R., K. Schicho, et al. (2007). "Clinical evaluation of mechanically optimized plates for the treatment of condylar process fractures." Oral Surg Oral Med Oral Pathol Oral Radiol Endod **104**(6): e1-4.
- 172.** Seemann, R., G. Undt, et al. (2011). "Is failure of condylar neck osteosynthesis predictable based on orthopantomography?" Oral Surg Oral Med Oral Pathol Oral Radiol Endod **111**(3): 362-371.
- 173.** Silvennoinen, U., T. Iizuka, et al. (1992). "Different patterns of condylar fractures: an analysis of 382 patients in a 3-year period." J Oral Maxillofac Surg **50**(10): 1032-1037.
- 174.** Simsek, S., B. Simsek, et al. (2007). "A comparative study of mandibular fractures in the United States and Turkey." Int J Oral Maxillofac Surg **36**(5): 395-397.

- 175.** Singh, V., A. Bhagol, et al. (2010). "Outcomes of open versus closed treatment of mandibular subcondylar fractures: a prospective randomized study." J Oral Maxillofac Surg **68**(6): 1304-1309.
- 176.** Smets, L. M., P. A. Van Damme, et al. (2003). "Non-surgical treatment of condylar fractures in adults: a retrospective analysis." J Craniomaxillofac Surg **31**(3): 162-167.
- 177.** Spiessl B, Schroll K: Gesichtsschädel. In: Nigst H (ed.), Gelenkfortsatz und Gelenkköpfchenfrakturen (fractures of the condylar neck and head), . I/1. Stuttgart: Georg Thieme Verlag Bd, 58e99, 136e152, 1972
- 178.** Stiesch-Scholz, M., S. Schmidt, et al. (2005). "Condylar motion after open and closed treatment of mandibular condylar fractures." J Oral Maxillofac Surg **63**(9): 1304-1309.
- 179.** Sugiura, T., K. Yamamoto, et al. (2001). "A comparative evaluation of osteosynthesis with lag screws, miniplates, or Kirschner wires for mandibular condylar process fractures." J Oral Maxillofac Surg **59**(10): 1161-1168; discussion 1169-1170.
- 180.** Suzuki, T., H. Kawamura, et al. (2004). "Resorbable poly-L-lactide plates and screws for the treatment of mandibular condylar process fractures: a clinical and radiologic follow-up study." J Oral Maxillofac Surg **62**(8): 919-924
- 181.** Takenoshita, Y., H. Ishibashi, et al. (1990). "Comparison of functional recovery after nonsurgical and surgical treatment of condylar fractures." J Oral Maxillofac Surg **48**(11): 1191-1195.
- 182.** Talwar, R. M., E. Ellis, 3rd, et al. (1998). "Adaptations of the masticatory system after bilateral fractures of the mandibular condylar process." J Oral Maxillofac Surg **56**(4): 430-439.
- 183.** Tang, W., C. Gao, et al. (2009). "Application of modified retromandibular approach indirectly from the anterior edge of the parotid gland in the surgical treatment of condylar fracture." J Oral Maxillofac Surg **67**(3): 552-558.

- 184.** Thangavelu, A., R. Yoganandha, et al. (2010). "Impact of impacted mandibular third molars in mandibular angle and condylar fractures." Int J Oral Maxillofac Surg **39**(2): 136-139.
- 185.** Thoren, H., T. Iizuka, et al. (1998). "Radiologic changes of the temporomandibular joint after condylar fractures in childhood." Oral Surg Oral Med Oral Pathol Oral Radiol Endod **86**(6): 738-745.
- 186.** Tominaga, K., M. Habu, et al. (2006). "Biomechanical evaluation of different types of rigid internal fixation techniques for subcondylar fractures." J Oral Maxillofac Surg **64**(10): 1510-1516.
- 187.** Trost, O., P. Trouilloud, et al. (2009). "Open reduction and internal fixation of low subcondylar fractures of mandible through high cervical transmasseteric anteroparotid approach." J Oral Maxillofac Surg **67**(11): 2446-2451.
- 188.** Tsiklakis, K., K. Syriopoulos, et al. (2004). "Radiographic examination of the temporomandibular joint using cone beam computed tomography." Dentomaxillofac Radiol **33**(3): 196-201.
- 189.** Umstadt, H. E., M. Ellers, et al. (2000). "Functional reconstruction of the TM joint in cases of severely displaced fractures and fracture dislocation." J Craniomaxillofac Surg **28**(2): 97-105.
- 190.** Undt, G., C. Kermer, et al. (1999). "Transoral miniplate osteosynthesis of condylar neck fractures." Oral Surg Oral Med Oral Pathol Oral Radiol Endod **88**(5): 534-543.
- 191.** Valiati, R., D. Ibrahim, et al. (2008). "The treatment of condylar fractures: to open or not to open? A critical review of this controversy." Int J Med Sci **5**(6): 313-318.
- 192.** Veras, R. B., M. S. Kriwalsky, et al. (2007). "Long-term outcomes after treatment of condylar fracture by intraoral access: a functional and radiologic assessment." J Oral Maxillofac Surg **65**(8): 1470-1476.
- 193.** Villarreal, P. M., F. Monje, et al. (2004). "Mandibular condyle fractures: determinants of treatment and outcome." J Oral Maxillofac Surg **62**(2): 155-163.
- 194.** Velich, N., Z. Nemeth, et al. (2002). "Removal of titanium plates coated with anodic titanium oxide ceramic: retrospective study." J Craniofac Surg **13**(5): 636-640.

- 195.** Vesnaver, A., U. Ahcan, et al. (2011). "Evaluation of surgical treatment in mandibular condyle fractures." J Craniomaxillofac Surg.
- 196.** Vogt, A., M. Roser, et al. (2005). "[Transparotidian approach to surgical management of condylar neck fractures. A prospective study]." Mund Kiefer Gesichtschir 9(4): 246-250.
- 197.** Walker, R. V. (1994). "Condylar fractures: nonsurgical management." J Oral Maxillofac Surg 52(11): 1185-1188.
- 198.** Webb, L. S., S. Makhijani, et al. (2009). "A comparison of outcomes between immediate and delayed repair of mandibular fractures." Can J Plast Surg 17(4): 124-126.
- 199.** Welk, A. and W. Sumnig (1999). "Morphometrical examinations of the mandibular ramus for the indication of lag screw osteosynthesis described by Eckelt in mandibular condylar fractures." Ann Anat 181(1): 69-72.
- 200.** *Westendorf, Wolfhart: Papyrus Edwin Smith. Bern/Stuttgart, 1966*
Widmark, G., T. Bagenholm, et al. (1996). "Open reduction of subcondylar fractures. A study of functional rehabilitation." Int J Oral Maxillofac Surg 25(2): 107-111.
- 201.** Wong, K. H. (2000). "Mandible fractures: a 3-year retrospective study of cases seen in an oral surgical unit in Singapore." Singapore Dent J 23(1 Suppl): 6-10.
- 202.** Yamaoka, M., K. Furusawa, et al. (1994). "The assessment of fracture of the mandibular condyle by use of computerized tomography. Incidence of sagittal split fracture." Br J Oral Maxillofac Surg 32(2): 77-79.
- 203.** Yang, W. G., C. T. Chen, et al. (2002). "Functional results of unilateral mandibular condylar process fractures after open and closed treatment." J Trauma 52(3): 498-503.
- 204.** Yasuoka, T. and N. Oka (1991). "Histomorphometric study of trabecular bone remodeling during condylar process fracture healing in the growing period: experimental study." J Oral Maxillofac Surg 49(9): 981-988.
- 205.** Zachariades, N., M. Meztis, et al. (2006). "Fractures of the mandibular condyle: a review of 466 cases. Literature review, reflections on treatment and proposals." J Craniomaxillofac Surg 34(7): 421-432.

- 206.** Zachariades, N., M. Meztis, et al. (2006). "Fractures of the mandibular condyle: a review of 466 cases. Literature review, reflections on treatment and proposals." J Craniomaxillofac Surg 34(7): 421-432.
- 207.** Zallen, R. D. and J. T. Curry (1975). "A study of antibiotic usage in compound mandibular fractures." J Oral Surg 33(6): 431-434.
- 208.** Ziccardi, V. B. and M. W. Ochs (1995). "Assessment of mandibular condylar fracture displacement." Am J Emerg Med 13(4): 474-476.
- 209.** Ziegler, C. M., R. Woertche, et al. (2002). "Clinical indications for digital volume tomography in oral and maxillofacial surgery." Dentomaxillofac Radiol 31(2): 126-130.
- 210.** Zinreich, S. J. (1992). "3-D reconstruction for evaluation of facial trauma." AJNR Am J Neuroradiol 13(3): 893-895.
- 211.** Zix, J. A., B. Schaller, et al. (2011). "Incidence, aetiology and pattern of mandibular fractures in central Switzerland." Swiss Med Wkly 141: w13207.

Eidesstattliche Versicherung

„Ich, Mohamed Saeed Zeno, versichere an Eides statt durch meine eigenhändige Unterschrift, dass ich die vorgelegte Dissertation mit dem Thema: „Long-term results after open reduction of the subcondylar fracture via- modified Risdon approach“ selbstständig und ohne nicht offengelegte Hilfe Dritter verfasst und keine anderen als die angegebenen Quellen und Hilfsmittel genutzt habe.

Alle Stellen, die wörtlich oder dem Sinne nach auf Publikationen oder Vorträgen anderer Autoren beruhen, sind als solche in korrekter Zitierung (siehe „Uniform Requirements for Manuscripts (URM)“ des ICMJE -www.icmje.org) kenntlich gemacht. Die Abschnitte zu Methodik (insbesondere praktische Arbeiten, Laborbestimmungen, statistische Aufarbeitung) und Resultaten (insbesondere Abbildungen, Graphiken und Tabellen) entsprechen den URM (s.o) und werden von mir verantwortet.

Meine Anteile an etwaigen Publikationen zu dieser Dissertation entsprechen denen, die in der untenstehenden gemeinsamen Erklärung mit dem/der Betreuer/in, angegeben sind. Sämtliche Publikationen, die aus dieser Dissertation hervorgegangen sind und bei denen ich Autor bin, entsprechen den URM (s.o) und werden von mir verantwortet.

Die Bedeutung dieser eidesstattlichen Versicherung und die strafrechtlichen Folgen einer unwahren eidesstattlichen Versicherung (§156,161 des Strafgesetzbuches) sind mir bekannt und bewusst.“

Datum

Unterschrift

8. Curriculum vitae (Lebenslauf)

Mein Lebenslauf wird aus datenschutzrechtlichen Gründen in der elektronischen Version meiner Arbeit nicht veröffentlicht.

Acknowledgments

I dedicate my time and efforts devoted to this work to my inspirational parents, Hisham and Aida, to my wife, best friend, and life-partner, Schahla and to our sweet daughter, Hala. Thank you all for loving support.

I would like to express my highest gratitude to Univ.-Prof. Dr. Dr. Bodo Hoffmeister for his caring, patience, and providing me the opportunity to fulfill my dissertation under his guidance. His critical reading and expert opinions for the dissertation and the manuscripts for publication left me a deep impression for her profound knowledge and penetrating insight in scientific research.

I would also like to thank Ltd. OA Dr. Dr. J.-D. Raguse, for his knowledge and commitment to the highest standards inspired and motivated me. Without his guidance and persistent help this dissertation would not have been possible.

