

2. Review of Literature

2. 1. Pathobiology of the joint

Joint disease in the equine patient can be ascribed to three etiologic factors: traumatic, developmental (osteochondrosis), and infectious (septic) (McILWRAITH 1996). Autoimmune joint diseases (e.g. lupus erythematosus) (VRINS and FELDMAN 1983; BYARS et al. 1984) as well as metabolic joint diseases diagnosed in humans (e.g. gout) (HERTSCH 2005) are considered rare in the horse and only very few reports of clinical and laboratory data in the literature suggest their existence. The rheumatic factor is present in a rather low percentage of the equine population (BUSCHMANN 1976) and low levels of autoimmune reactivity detected in several joint diseases propose just a minor role, if any, for autoimmune mechanisms of joint disease in the horse (CARTER et al. 1995).

Despite the multifactor nature of the etiology of joint disease in the horse, it is usually the same destructive mechanisms that operate in disease, although in differing intensities (LITTLE 1995; BERTONE 1996). The derangement of the function of diseased joints is a complex and dynamic process that involves the interaction of all the structures of the joint, synovial membrane, articular cartilage and subchondral bone and osteophyte formation (PRICE et al. 1992). Once initiated, these changes become cyclic unless controlled (CLYNE 1987). For this reason and regarding the main purpose of the present work, a brief description of these common pathological mechanisms is reviewed below.

2. 1. 1. Synovial membrane

Diarthrodial joints are enclosed by a fibrous capsule. The inner surface of the capsule is coated with the synovial membrane (synovium). This is comprised of the underlying lamina propria (subintima or subsynovium), a superficial microvasculature net and the intima (synovial lining). The intima is a modified mesenchyme consisting of an incomplete cell layer of 1-to-3 cells of depth with no true basement membrane, which lies over the lamina propria and stands in direct contact with the synovial fluid. It contains two morphologically different types of cells: bone marrow derived-macrophages (Type-A synoviocytes) and fibroblast-like cells (Type-B synoviocytes). The latter are responsible for the production of hyaluronate. The subsynovium is composed of connective tissue, adipose tissue or fibrous tissues, depending

on the mechanical demands and contains the synovial vascular plexus and several lymphatic vessels (GARNERO et al. 2000). High-pressure or low-motion joints present a subintima with a flattened surface and lacking villi, while abundant numbers of villi are seen in the subintima of low-pressure or high-motion joints (PALMER and BERTONE 1994).

Inflammation of the synovial membrane (synovitis) and the joint capsule (capsulitis) are common initial osteoarthritic changes in the horse (McILWRAITH 1982; McILWRAITH and VACHON 1988) and comprise a nonspecific typical inflammatory response, present to some extent in the majority of equine joint diseases, although with varied intensities (JOHANSSON and REJNÖ 1976; TEW and HOTCHKISS 1981; McILWRAITH 1987). Inflammation of soft tissues of the joint (capsule, synovium and ligaments) can have primary and secondary causes. Primary causes are traumatic injuries (such as repetitive overextension and subluxation) or chemical damage to soft tissue due to intraarticular injection of medications. Secondary causes are the result of release of cartilage-degradative products due to cartilage abrasation and intraarticular fractures (TODHUNTER and LUST 1990).

Synovitis is characterized by an augmented vascularisation, edema, inflammatory cell infiltration, increased number of synoviocytes and hypertrophy of villi when compared with normal synovial membrane (JOHANSSON and REJNÖ 1976). Joint stiffness and reduction of the range of flexion related to synovitis are due to cellular infiltration, hyperplasia and edema (SIMKIN 1997), while in chronic synovitis the range of motion may be impaired by fibrosis of the joint capsule (FIRTH 1996; KIDD et al. 2001). Synoviocytes are a source of inflammatory mediators and proteolytic enzymes that degrade the articular cartilage and induce catabolic programs on the chondrocytes (SPIERS et al. 1994a, b; KIDD et al. 2001; TUNG et al. 2002b; MARTEL-PELLETIER 2004). In the chronic stages of joint disease, synovial chondromas may be formed because of the accumulation of metaplastic synoviocytes in the synovial membrane. These new formations may undergo a process of osteochondral ossification becoming synovial osteochondromas, which may be observed in radiographs of chronically diseased joints (POOL 1996).

Increase of the vascular permeability, widening of intercellular spaces of the synovial membrane, and the proximity between the vasculature and the joint space lead to an increased content of total proteins, white blood cells and synovial fluid in the joint (effusion) (SIMKIN 1991). This increase of total protein and cells, leads to a rise in oncotic pressure, favoring a

net flow of water into the joint, increasing the degree of effusion (McILWRAITH 1987; WALLIS et al. 1987; TODHUNTER and LUST 1990).

Joint effusion may also impair the stability of the joint by increasing the physiological intraarticular subatmospheric pressure, leading to joint instability (SIMKIN 1997). Furthermore, this increased pressure may disturb the blood flow in the synovial capillaries, decreasing the availability of oxygen and potentially leading to reperfusion injury (LEVICK 1990).

2.1.2. Articular cartilage

Articular cartilage provides the joint with a load-bearing structure and contact surface constituted to resist the cyclic friction and significant deformation that this surface undergoes over time (MANKIN and RADIN 1997), serving as a shock transmitter (EHRlich 1987).

Articular cartilage is of hyaline type and is composed of a few chondrocytes scattered in an extracellular matrix of water, collagen and proteoglycans. Healthy articulate cartilage has a heterogeneous and translucent appearance and is made up of 50% collagen, 35% proteoglycan, 10% glycoproteins, 3% mineral, 1% lipids and between 1 to 12% chondrocytes. The most abundant type of collagen in articular cartilage is of type II (TODHUNTER 1996). Type II collagen is a homotrimer formed by three α -chains, and it is the basic fibrillar structure of the extracellular matrix, providing the articular cartilage with tensile strength (GARNERO et al. 2000). Proteoglycans are molecules formed by glycosaminoglycans (GAG) covalently attached to a core protein. The most abundant type of proteoglycan is aggrecan, which is normally attached to a linear molecule of hyaluronate through its G1 domain (TODHUNTER 1996). The chains of GAG bind great amounts of water, creating a swelling pressure leading to compressive stiffness to oppose deformation and compression of cartilage (POOLE et al. 2002).

Articular cartilage is divided into 4 different histological and biochemical zones: tangential zone (superficial), intermediate or transition zone, the deep zone and the mineralized cartilage zone (PALMER and BERTONE 1994). The chondrocytes are the cellular component of articular cartilage and synthesize all components of the matrix of the articular cartilage (LOTZ et al. 1995). Chondrocytes control the composition of the articular cartilage and a

great domain of matrix is controlled by each chondrocyte (HAWKINS and RICHARDSON 1999).

Articular cartilage is metabolically active and its homeostasis is characterized by a balance between degradation and synthesis of extracellular matrix (TRIPPEL 1995). The metabolism of the chondrocytes may be altered by mechanical and chemical stimuli (CLYNE 1987; MAY et al. 1992; POOL 1996). In diseased joints, proteolytic enzymes (MARTEL-PELLETIER and PELLETIER 1987; KOWANKO et al. 1989), reactive oxygen species (SCHILLER et al. 1996; YUDOH et al. 2005) and inflammatory mediators (LOTZ et al. 1995) alter the structure of the cartilage and the physiological homeostasis of the chondrocytes.

The biochemical, biomechanical, metabolic and morphologic changes of articular cartilage in joint disease are explained in the chapter of osteoarthritis in the present work.

A review of the most important proteolytic enzymes, inflammatory mediators and other factors mediating the destruction of articular cartilage are presented below (Figure 1).

Metalloproteinases: Metalloproteinases (MMPs) (also called matrixins) are a group of Zn^{2+} and Ca^{2+} dependent endopeptidases with the capacity to destroy all components of the extracellular matrix (NAGASE and WOESSNER 1999; LEE and MURPHY 2004). MMPs can be produced by monocytes, lymphocytes, synovial cells, tumor cells (GAUDIN et al. 1997) and neutrophils (MOREL et al. 1994). MMPs are secreted as inactive zymogens and are activated extracellularly (NAGASE and WOESSNER 1993).

More than 20 types of MMPs have been identified until now and are classified into four main classes, according to their structural similarities and substrate specificity as follows: collagenases, stromelysins, gelatinases, and membrane-type (CLEGG and CARTER 1999).

MMPs play an important role in the physiological remodeling and growth of articular cartilage (BRAMA et al. 2000). Briefly, collagenase is involved in the cleavage of type II collagen fibers at a single site of each α chain, creating $1/4$ and $3/4$ fragments (MITCHELL et al. 1996).

Stromelysin accounts for the digestion of proteoglycans (e.g. aggrecan) between the G1 and G2 domains (FLANNERY et al. 1992) and for the activation of collagenase (MURPHY et al. 1987). Gelatinases have a collagenase activity, being capable of cleaving collagen fibers (AIMES and QUIGLEY 1995).

MMPs are inhibited by the tissue inhibitors of metalloproteinase (TIMP), forming a 1:1 enzyme-inhibitor complex (NAGASE and WOESSNER 1993). Each individual TIMP differs in its ability to inhibit different MMPs (LEE and MURPHY 2004).

Increased activity and concentration of MMPs have been demonstrated in synovia of diseased joints in horses (CLEGG et al. 1997; BRAMA et al. 1998; CLEGG and CARTER 1999; BRAMA et al. 2000; JOUGLIN et al. 2000; BRAMA et al. 2004; van den BOOM et al. 2005).

Prostaglandin E₂: Prostaglandin E₂ (PGE₂) has been detected in synovial fluid of diseased joints in horses (GIBSON et al. 1996; KIRKER-HEAD et al. 2000; BERTONE et al. 2001). In the early phase of inflammation, PGE₂ enhances the sensation of pain, increases vascular permeability, vasodilation and bone resorption and inhibits chondrocyte synthesis via IL-1 (PALMER and BERTONE 1994). It also reduces proteoglycan synthesis and raises glycosaminoglycan loss from articular cartilage (FULKERSON et al. 1979; van de LOO and van den BERG 1990).

However, the role of PGE₂ in joint disease seems to be paradoxical, since an anti-inflammatory effect of PGE₂ on equine chondrocyte cultures has also been demonstrated (TUNG et al. 2002a). More research is required to elucidate the mode of action of this prostanoid in inflamed joints.

Serine Proteinases: Urokinase (uPA) and tissue type plasminogen activator (tPA) belong to the group of serine proteinases that catalyze the conversion of plasminogen into plasmin (BUSSO et al. 1997). The most important role of the system plasminogen activators/plasmin in joint disease is as activators of MMPs (MARTEL-PELLETIER 2004). Other serine proteinases are elastase and cathepsin G (PALMER and BERTONE 1994), acting at the proteoglycan core protein destroying cartilage proteoglycans.

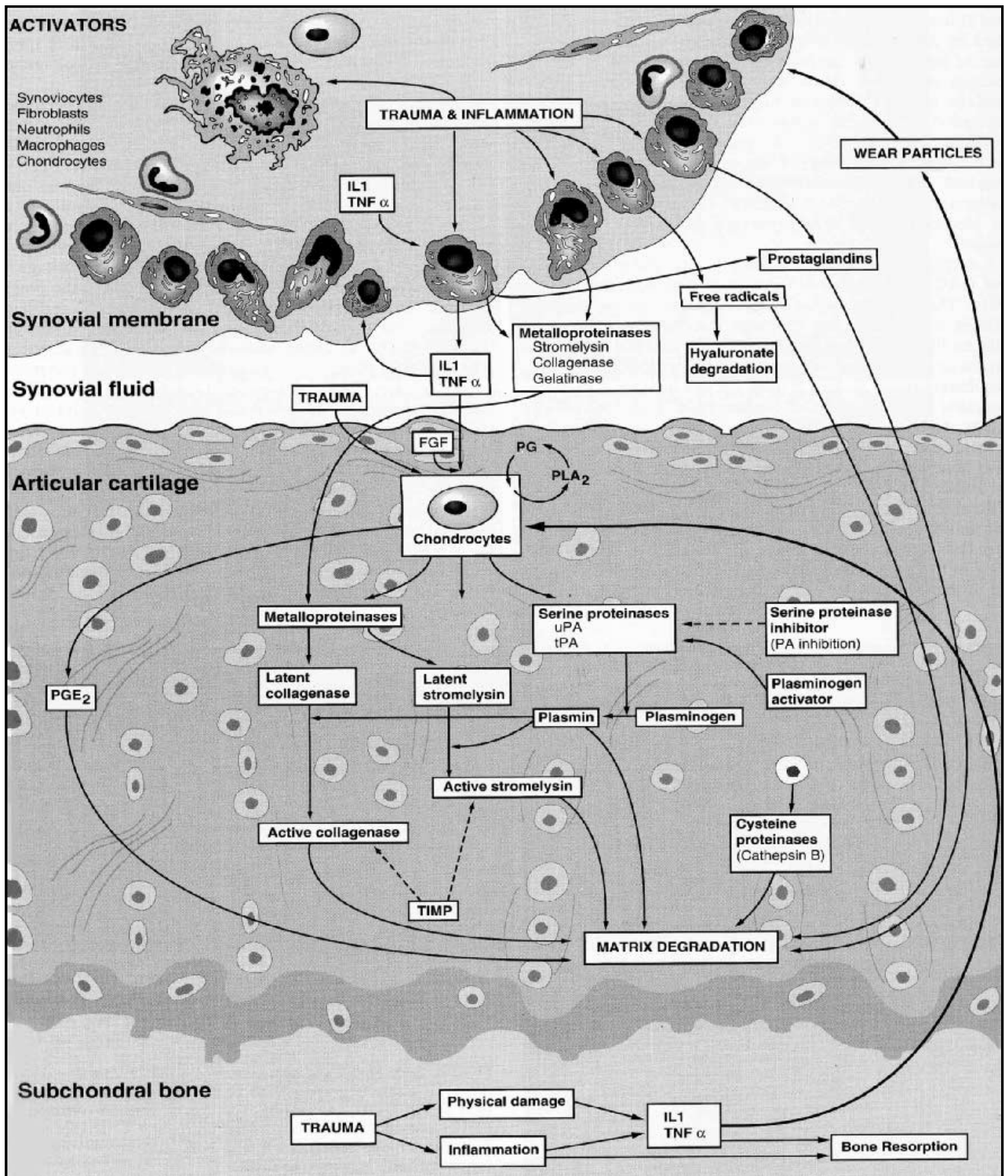


Figure 1. Factors involved in enzymatic degradation of articular cartilage matrix. IL 1 = interleukin 1; TNF α = Tumor necrosis factor α .; FGF: fibroblast growth factor; PG = prostaglandin; PLA₂ = phospholipase A₂; uPA = urokinase plasminogen activator; tPA = tissue plasminogen activator; PA = plasminogen activator; PGE₂ = prostaglandin E₂; TIMP = tissue inhibitor of metalloproteinase. Reprinted from "Joint Disease in the Horse". McILWRAITH, C.W.; TROTTER, G.W. Pathobiology of the joint and response to injury. Page 50. Copyright 1996, reprinted with permission from Elsevier.

Cytokines: Cytokines are soluble peptides produced by one cell and affecting the activity of other cell types (McILWRAITH 1996). Cytokines are also known as growth factors and exert their effects in an autocrine or a paracrine way (POOLE 1997).

Chondrocytes control the homeostasis of the articular cartilage by regulating the balance between anabolic and catabolic processes during growth, in the mature organism and aging as well as in remodeling after traumatic or inflammatory injury (LOTZ et al. 1995). The induction of these anabolic or catabolic programs in the chondrocytes is believed to be controlled by cytokines (LOTZ et al. 1995). Nowadays, interleukin-1 (IL-1) and the tumor necrosis factor – α (TNF- α) are considered to be the most important mediators of connective tissue destruction in joint disease. IL-1 in the joint is produced by monocyte/macrophage, chondrocytes, synoviocytes (PELLETIER et al. 1993) and neutrophils (TAKEICHI et al. 1994). IL-1 and TNF- α react with a specific receptor on the chondrocytes and exert their catabolic effects on the articular cartilage by increasing the synthesis of proteolytic enzymes (e.g. MMPs), inhibiting the synthesis of their physiological inhibitors, and suppressing the synthesis of collagen and proteoglycans (MARTEL-PELLETIER 2004). Increased concentrations of these and other cytokines have been found in synovia of diseased joints in the horse (BERTONE et al. 2001).

Reactive oxygen species: Reactive oxygen species (ROS) are molecules that can be categorized into two different groups: oxygen-derived free radicals (superoxide/ $O_2^{\cdot-}$ and hydroxyl radicals/ OH^{\cdot}) and their resulting non-radical species (hydrogen peroxide/ H_2O_2 , singlet oxygen/ 1O_2 , hypochlorous acid/ $HOCl$ and ozone/ O_3) (HALLIWELL 1993). ROS can be produced by chondrocytes, fibroblasts, macrophages and neutrophils (FLUGGE et al. 1999).

Antibodies, cytokines and unknown chemotactic factors can lead to the accumulation and activation of inflammatory cells within the joint (EDWARDS and HALLETT 1997). Trauma may cause a release of the component of the cells, leading to phagocyte accumulation and activation in the joint as well (KEHRER 1993).

In addition to proteolytic and microbicidal enzymes, activated phagocytes are responsible for the production of ROS (KEHRER 1993; PALMER and BERTONE 1994). Once phagocytes are activated, the NADPH-oxidase membrane-bound enzyme catalyzes the production of

superoxide from oxygen and NADPH (BABIOR 1999). Superoxide, in turn, serves as starting material for the production of several reactive oxidants through subsequent reactions, like hydrogen peroxide, singlet oxygen, hypochlorous acid, nitric oxide (BABIOR 2000).

During activation of phagocytes, ROS may be liberated into the extracellular milieu, exposing the host tissues to their harmful effect if antioxidants are insufficient or overwhelmed (HALLIWELL 1993). Within the joint, ROS are able to activate MMPs (PALMER and BERTONE 1994), oxidise and damage biomolecules, like proteoglycans (SCHILLER et al. 1996), collagen fibers (OLSZOLWSKI et al. 2003), and synovial fluid molecules (KOWANKO et al. 1989; GREEN et al. 1990; GROOTVELD et al. 1991; JAHN et al. 1999), and even the genetic material of chondrocytes, which may lead to chondrocyte senescence and cartilage ageing (YUDOH et al. 2005). In the horse, increased levels of free radicals in synovial fluid and their damaging effect on tissues of diseased joints have been demonstrated (AUER et al. 1993; DIMOCK et al. 2000).

2.1.3. Osteophytes and Enthesophytes

The term osteophyte describes bony formations at the osteochondral margins of diarthrodial joints (BLEVINS and WIDMER 1990; ALEXANDER 1980). The causes of osteophytosis are not completely understood (BRANDT and MANKIN 1994), but it seems that joint stability, mechanical stress (POOL 1996), and inflammatory mediators (WIDMER and BLEVINS 1994) may be possible causes. Pluripotent mesenchymal stem cells are differentiated into chondrocytes, forming a cartilaginous structure termed chondrophyte. After incursion of blood vessels, these chondrophytes experience a process of endochondral ossification, developing into an osteophyte (GILBERTSON 1975). Osteophytes are considered to be typical lesions of osteoarthritis together with articular cartilage degeneration (McILWRAITH 1982) and may be interpreted as a repair process in response to tissue damage (AYDELOTTE and KUETTNER 1993). However, they have been found in joints of horses with no signs of articular cartilage degeneration (McILWRAITH and van SICKLE 1981). Enthesophytes are bony exostoses in the fibrocartilage of the metabolically active attachments of fibrous joint capsule, tendons, and ligaments to the bone through the Sharpey's fibers (entheses) (WIDMER and BLEVINS 1994) and are believed to be caused by strains or trauma (POOL 1996). Enthesophytes can be observed associated with osteoarthritis, although they might be

present in clinically sound horses with no signs of cartilage degeneration (WIDMER and BLEVINS 1994; KIDD et al. 2001).

2.1.4. Subchondral bone

Subchondral bone fulfils two main tasks: shock absorption and preservation of the shape of the joint (KAWCAK et al. 2001). Sclerosis of the subchondral bone has been cataloged as one of the typical radiographic changes of osteoarthritis (McILWRAITH 1982). The subchondral bone plate adapts to cyclic loading by appositional bone growth, resulting in expansion of the trabeculae and visible subchondral bone sclerosis in radiographs (POOL 1996). This in turn places an increased tensile strength on the cartilage, probably causing fibrillation and cartilage breakdown (RADIN et al. 1991)

2.2. Joint diseases

2.2.1. Osteoarthritis

Osteoarthritis (OA) has been defined as “a disease of diarthrodial joints comprising destruction of articular cartilage to varying degrees accompanied by subchondral bone sclerosis and marginal osteophyte formation” (McILWRAITH 1982). Nowadays the name “osteoarthritis” has replaced the former “degenerative joint disease” (DJD) (KIDD et al. 2001) and corresponds interchangeably with the German terms “Arthrose” and “Osteoarthrose” (SPRENG and SCHAWALDER 1997).

Articular cartilage degradation is the hallmark of osteoarthritis and the most important factor impeding the return of athletic horses to competition (McILWRAITH and VACHON 1988).

Etiology: Osteoarthritis is regarded by several authors as a multifactor syndrome in which several causes may result in the degradation of the articular cartilage. Trauma is considered to be the most important cause of osteoarthritis in the horse, in the form of single event trauma or more insidious cyclic trauma following repetitive insults (DÄMMRICH 1993; McILWRAITH 1996; KIDD et al. 2001). Equine osteoarthritis is a natural age-related disease, as shown by the prevalence of osteoarthritis in older wild horses. In the athletic horse, increased stress and loading produced by racing and training speed up this aging-process (CANTLEY et al. 1999). Osteoarthritis can also develop secondarily to other joint ailments, as unresolved osteochondrosis dissecans (STRÖMBERG and REJNÖ 1978; DÄMMRICH 1985), septic arthritis (BERTONE et al. 1992), joint fractures, and sprains (McILWRAITH 2002).

Pathogenesis: In the athletic horse, trauma can inflict direct damage to the articular cartilage, especially in the areas subjected to higher impact (DÄMMRICH 1993). Conformational defects and shoeing may place additional high demands on the joint structure of athletic horses (McILWRAITH and VACHON 1988). An abnormal distribution of loading can result in localized sites of concentrated force transmission, resulting in cartilage damage (PELLETIER et al. 1997). However, it is more likely that trauma destroys cartilage indirectly, by injuring the subchondral bone, synovial membrane or chondrocytes (McILWRAITH 2002).

RADIN et al. (1991) proposed that early osteoarthritic changes begin in the subchondral bone. According to this theory, subchondral bone sclerosis develops as a result of an adaptive mechanism of the subchondral bone to the greater mechanical stress caused by trauma. This in turn, places an increased tensile strength on the cartilage, causing fibrillation and cartilage breakdown.

Synovitis may be the primary initiating factor of degenerative changes in the articular cartilage in the horse, especially in the high-motion joints (TROTTER and McILWRAITH 1996). Synovitis is a source of proteolytic enzymes and inflammatory mediators (PALMER and BERTONE 1994; SPIERS et al. 1994a, b; MARTEL-PELLETIER 2004), which damage the articular cartilage and perpetuate the inflammatory process. However, early degeneration of articular cartilage has been detected without signs of synovitis (ATTENBURROW and GOSS 1994).

Chondrocytes may be stimulated by trauma, shearing forces, and chemical stimuli (CLYNE 1987; MAY et al. 1992; POOL 1996). Trauma can also provoke apoptosis of chondrocytes (CHEN et al. 2001), altering the homeostasis of articular cartilage.

Despite the multifactorial nature of the causes of osteoarthritis, the enzymatic depletion of articular cartilage extracellular matrix is considered to be a common pathway of cartilage degeneration in osteoarthritis (NAGASE and WOESSNER 1993) (Figure 2).

Pathological changes of the articular cartilage: A description of the most important morphologic, biochemical, biomechanical and metabolic changes in the osteoarthritic cartilage is presented below.

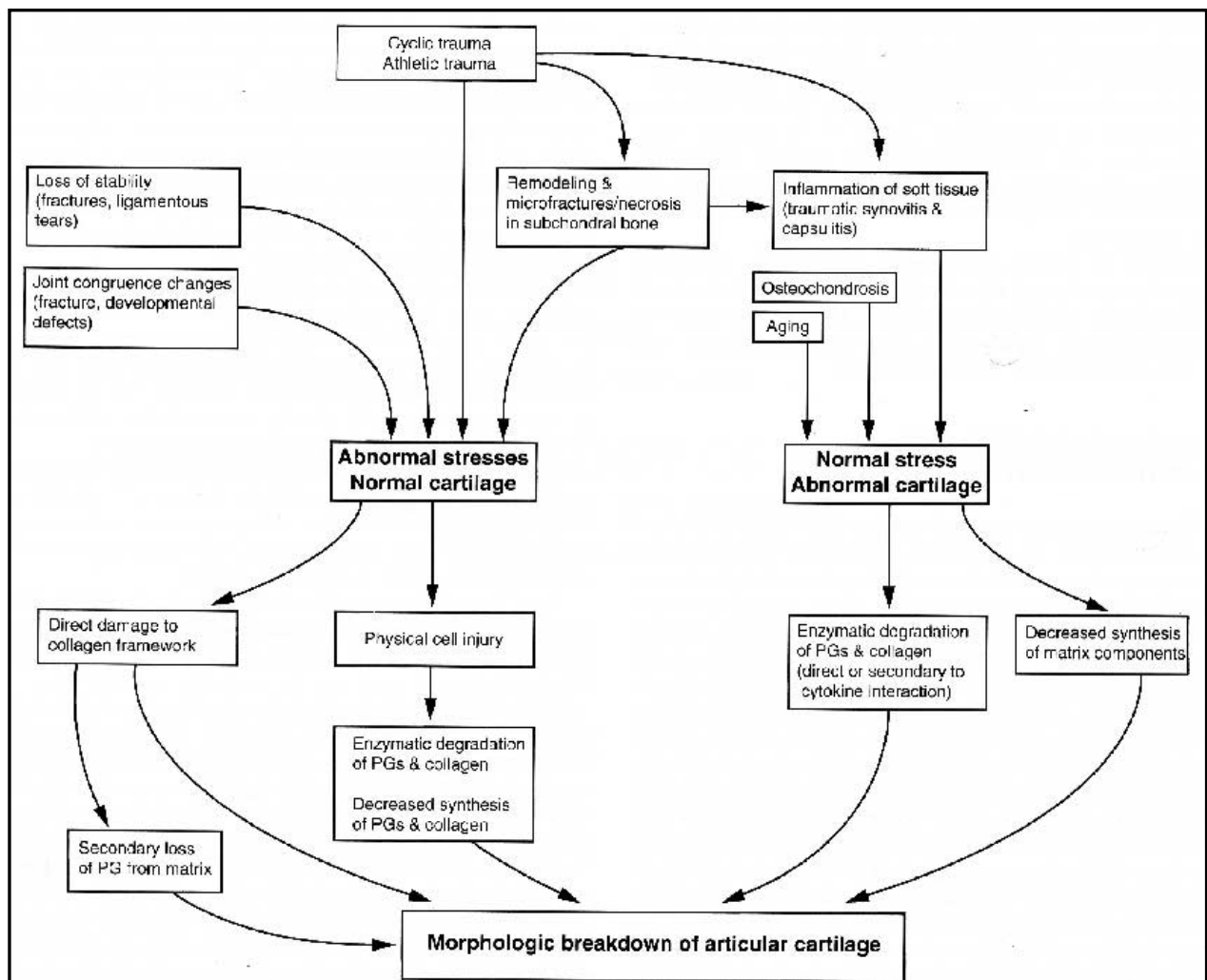


Figure 2. Factors involved in articular cartilage degradation in equine osteoarthritis. PG = proteoglycan. Reprinted from "Joint Disease in the Horse". McILWRAITH, C.W.; TROTTER, G.W. Pathobiology of the joint and response to injury. Page 42. Copyright 1996, reprinted with permission from Elsevier.

Morphologic changes: Articular cartilage degeneration is characterized macroscopically by the presence of fibrillation, partial and full thickness erosion, and wear lines (TROTTER and McILWRAITH 1996). The cartilage loses its normal luster and consistency, becoming yellow and soft (McILWRAITH 2002). Histologically, fibrillation of the surface of articular cartilage resulting from damage of the collagen fibrils is the first sign (POOLE et al. 2002). The articular cartilage disrupts along the level surface of the collagenous fibrils of the matrix (McILWRAITH 2002). As the disorder progresses, the surface seems more disrupted and fragmented, with pitting, vertical clefts and ulceration; in advanced disease, no cartilage remains and bare areas are seen in which the underlying bone is exposed (BRANDT and MANKIN 1994). An increased number of apoptotic chondrocytes is observed in direct proportion to the degree of cartilage degeneration (KIM et al. 2003). Viable chondrocytes

form clusters, the so called “brood capsules”, close to the margins of the fissures in the surface of the cartilage (HOUGH 1997). These chondrocytes are metabolically active and make an unsuccessful attempt to increase cartilage matrix synthesis, as they cannot move to the sites of damage (POOL 1996).

Biochemical alterations: The articular cartilage exhibits a net reduction in the proteoglycan content (POOLE et al. 1996). Denaturation of the collagen moiety is increased together with a net loss of this molecule (HOLLANDER et al. 1994). The water content of the articular cartilage is increased and following further disruption of the collagen network, more water is attracted to the negatively-charged glycosaminoglycan chains resulting in tissue swelling (KIDD et al. 2001).

Biomechanical alterations: The quality of the cartilage matrix is essential to uphold the functional characteristics of the cartilage (DIEPPE and LOHMANDER 2005). Fibrillation of the surface of articular cartilage decreases the resistance to shear forces (FASSBENDER 1983). The diminished content of proteoglycan of articular cartilage together with the destruction of its collagen network leads to a decreased resistance to compression and mechanical stress (PELLETIER et al. 1993). The compressive stiffness and elasticity of the matrix is dramatically reduced (BRANDT and MAKIN 1994), and the matrix is unable to resist joint loading, resulting in more cartilage loss (PELLETIER et al. 1997).

Metabolic changes: Chondrocytes undergo metabolic changes characterized by an increased production of collagen (NELSON et al. 1998) and proteoglycans, but these newly-synthesized components are defective and the high rate of production is not sufficient to cope with the net loss of matrix (RIZKALLA et al. 1992). Chondrocytes produce catabolic cytokines (PELLETIER et al. 1993) and ROS (FLUGGE et al. 1999), enhancing the process of cartilage degeneration.

Clinical Manifestations: Osteoarthritis is characterized by progressive lameness, which is often bilateral (KIDD et al. 2001). The most important radiographic signs of osteoarthritis are narrowing of the joint space, subchondral bone sclerosis, osteophytes, and soft tissue swelling (McILWRAITH and VACHON 1988; BLEVINS and WIDMER 1990). Early articular cartilage changes cannot be detected in normal radiographic examination; this is the so-called “pre-radiological” phase of osteoarthritis (LOHMANDER et al. 1992). Changes in articular

cartilage are obvious only after important irreversible damage has occurred (KIDD et al. 2001; DIEPPE and LOHMANDER 2005). On the other hand, there exists no correlation between the extent of the pathological changes and the clinical signs (McILWRAITH and VACHON 1988)

2.2.2. Septic Arthritis

Joint infection is “the inoculation of the synovial membrane fluid with bacteria or other organisms that incite an inflammatory reaction that allows the establishment of viable organisms” (BERTONE 1996).

Septic arthritis is the most destructive form of joint disease (McILWRAITH 2002) and is a potentially lethal condition (HAGUE and CARTER 1999). In fact, septic arthritis presents the most severe form of synovitis in the horse (BERTONE 1996; McILWRAITH 2002) with a guarded or poor prognosis (LAPOINTE et al. 1992), as it can lead to irreversible joint damage (SCHNEIDER et al. 1992b).

Etiology: Joint infection can be produced by metastatic hematogenous infection, traumatic injuries or iatrogenic methods (e.g. arthrocentesis, surgery) (HAGUE and CARTER 1999; McILWRAITH 2002). Hematogenous infection is more commonly seen in young foals (SCHNEIDER et al. 1992a) in association with infection of the umbilical stalk, respiratory or digestive systems (HAGUE and CARTER 1999; McILWRAITH 2002). In these cases, the bacteria reach the joint by direct colonization of the synovium or secondarily to osteomyelitis (HAGUE and CARTER 1999). In adult horses, traumatic or iatrogenic infections of joints are the most common causes of septic arthritis (SCHNEIDER et al. 1992a; McILWRAITH 2002).

A retrospective study of horses affected with septic arthritis shows that the most common causes of infection are traumatic articular injuries (24%), iatrogenic infections associated with intraarticular injections (22%), infections related to surgery (13%), hematogenous infections (17-34%) and idiopathic causes (6%) (SCHNEIDER et al. 1992a). Most common bacteria found in traumatic infection of joints (foals and adults) were Enterobacteriaceae and *E. coli* (SCHNEIDER et al. 1992a), whereas iatrogenic infections are mostly caused by staphylococcal infections (BERTONE et al. 1992; LAPOINTE et al. 1992; SCHNEIDER et al. 1992a).

Pathogenesis: Bacteria colonize the synovial membrane, leading to synovitis. Synoviocytes release proteolytic enzymes (SPIERS et al. 1994b) and pro-inflammatory cytokines (IL-1 and TNF- α) with harmful effects on the articular cartilage (HARDY et al. 1998). A decreased production of hyaluronate by the synoviocytes (HARDY et al. 1998) reduces the biochemical protection of joint tissues (BERTONE 1996). Large accumulation of fibrin within the joint may induce formation of synovial adhesions (BERTONE et al. 1987) and impair exchange of nutrients with the articular cartilage (BERTONE 1996). Synovial membrane necrosis, thrombosis, and pannus formation also affect the whole metabolism of the joint (McILWRAITH 2002).

Large numbers of neutrophils are attracted into the joint (BERTONE et al. 1987), where they release lysosomal enzymes (SPIERS et al. 1994b), pro-inflammatory cytokines, and free oxygen radicals to eradicate the infection (PALMER and BERTONE 1994). As mentioned elsewhere in the present work, these substances exert deleterious effects on the articular cartilage too. Moreover, bacterial lipopolysaccharides (JASIN and SIMMONS 1983), cytokines, and free oxygen radicals activate chondrocytes to produce proteolytic enzymes, enhancing the process of cartilage degradation (PALMER and BERTONE 1994). Proteolytic enzymes from neutrophils and synoviocytes are also harmful to bony tissues within the joint (GOLDENBERG 1994).

Clinical manifestations: Lameness is a consistent feature of septic arthritis. It can be absent or mild within the first hours after infection (TULAMO et al. 1989a, b) but generally progresses to severe as the infection is established within the joint (BERTONE 1996; HAGUE and CARTER 1999). Local heat (SCHNEIDER et al. 1992a), synovial effusion, periarticular swelling, local pain and edema are found in the affected joints (TULAMO et al. 1989a; TORRE and DECKER 1994; McILWRAITH 2002). Loss of appetite and fever might be present as well (TULAMO et al. 1989a, b; SCHNEIDER et al. 1992a). Iatrogenic infections related to the intraarticular injection of corticoids show a greater period of time until the onset of clinical signs becomes apparent (TULAMO et al. 1989b). Neutrophilic leukocytosis and hyperproteinemia were observed in a model of experimentally induced septic arthritis in horses (BERTONE et al. 1987).

Clinical signs can be seen after a variable time from contamination ranging from a few hours (BERTONE et al. 1987; TULAMO et al. 1989a) to several days (LAPOINTE et al. 1992; SCHNEIDER et al. 1992a). The horse's response to infection depends upon the number and

type of bacteria and the extent of its immune reaction (SCHNEIDER et al. 1992a; HAGUE and CARTER 1999).

Typical changes in septic synovia are explained in the chapter about synovial fluid in the present work. A bacterial culture is useful for the diagnostic procedure of joint infection. Culture of synovial fluid is more likely to lead to positive results than cultures from synovium; however only around 50% of the infected synovia are positive (McILWRAITH 1987; MADISON et al. 1991). Positive bacterial cultures are a good confirmation of sepsis in a joint but culture-negative synovial fluids do not rule out infection (MADISON et al. 1991; SCHNEIDER et al. 1992a).

Typical findings of the radiographic examinations are subchondral bone lysis, narrowing/widening of joint space and periosteal proliferation (TORRE and DECKER 1994; McILWRAITH 2002). However, radiographic changes cannot be seen within the first days of infection (SCHNEIDER et al. 1992a; TORRE and DECKER 1994) but weeks thereafter (McILWRAITH 2002). Osteomyelitis is more commonly seen in foals and can be readily diagnosed in radiographs a few days after infection (HAGUE and CARTER 1999). Radiological evaluation is nonetheless always indicated in acute cases to assess possible osteomyelitis, traumatic damage to the joint (BERTONE 1996; HAGUE and CARTER 1999), or the presence of foreign material that needs to be removed.

2.2.3. Osteochondrosis dissecans

Osteochondrosis dissecans (OCD) is defined as a “circumscribed aseptic necrosis of the subchondral tissue and articular cartilage in man and animals” (HERTSCH 1991).

Osteochondrosis is an exceptionally important developmental orthopedic disease in the horse, as more than 20 000 foals born in North-Western Europe will present a certain degree of osteochondrosis (van WEEREN and BARNEVELD 1999). In a clinical sense, osteochondrosis does not necessarily represent a career-ending disease for athletic horses, nor may it always affect their athletic performance (BREHM and STÄCKER 1994). However, the condition has a tremendous economic impact on the horse industry, since it is the reason why thousands of horses have to undergo surgery every year (van WEEREN 2005). In this regard,

this author highlights the fact that many stud-books will not inscribe horses with osteochondrosis, to the detriment of their economic value and transmission of their genes.

Etiology: No consensus exists about the exact etiopathogenesis of osteochondrosis. However, it is accepted that this ailment has a multifactorial origin, in which genetic and environmental factors interrelate (PHILIPPSON 1996). Possible etiologic factors of osteochondrosis dissecans are:

- Genetic predisposition (PHILLIPSON et al. 1993; VOÛTE et al. 1997)
- Nutrition (GLADE and BELLING 1986)
- Metabolism and hormones (OLDRUITENBORGH-OOSTERBAAN et al. 1999; HENSON et al. 1997)
- Growth and body size (SANDGREN et al. 1993)
- Trauma (FIRTH and GREYDANUS 1987; HERTSCH 1991)
- Mineral imbalances (BRIDGES and HARRIS 1988)

Pathogenesis: The hallmark of osteochondrosis is a failure in the process of subchondral ossification (ROONEY 1975). As a result of this defective epiphyseal endochondral ossification, the articular cartilage is irregular, exhibiting areas of excessive thickness that are more susceptible to traumatic injuries (McILWRAITH 1987; NIXON 1993)

Necrosis in areas of endochondral ossification may be due to a disruption of capillary vessels that extend from the subchondral bone and irrigate the epiphyseal cartilage (CARLSON et al. 1995). The hypertrophic areas of cartilage mentioned above may impose an abnormally longer passageway of diffusion for nutrients from the synovia into the deeper layers of cartilage, leading to necrosis (DÄMMRICH 1985).

The areas of defective cartilage may remain in the deep layer or dissecting lesions may occur, leading to the formation of a cartilaginous fragment. These flaps of cartilage can be avulsed and remain loosely attached to the articular cartilage. Fragments may fully separate and float in the synovial fluid or attach to the synovial membrane. Either way, they may subsequently be reabsorbed, proliferate or undergo ossification, due to the nutrition provided by the synovia and the process of endochondral ossification occurring within the fragments (McILWRAITH 1987).

Clinical manifestations: Clinical signs of osteochondrosis may be defined by joint effusion and mild lameness, whereas flexion tests may be positive or negative (HERTSCH 1991). Trauma may produce avulsion of osteochondral fragments, leading to varied degrees of synovitis and triggering the onset of clinical signs (McILWRAITH 1987). Yet, joint effusion and lameness has been observed in joint with integral OCD fragment (McINTOSCH and McILWRAITH 1993).

However, clinical manifestations are not always evident; OCD may be a silent disease presenting no clinical signs whatsoever (HERTSCH 1991; BREHM and STÄCKER 1994). In this regard, McILWRAITH (2002) described three categories of OCD lesions:

- 1) Lesions showing clinical and radiological signs
- 2) Lesions showing clinical signs without radiographic (but arthroscopic) signs.
- 3) Lesions showing radiographic signs but no clinical signs.

2.3. Synovial fluid

Synovial fluid is a dialysate of blood plasma modified by the addition of hyaluronate* and glycoproteins (PERSSON 1971; TEW and HOTCHKISS 1981; CLYNE 1987; LITTLE et al. 1990; McCARTY 1997; MAHAFFEY 2002).

The synovial membrane regulates the biochemical internal milieu of the joint, thus the composition of synovia, by controlling the diffusion pathway of substances between plasma and the synovial cavity (PALMER and BERTONE 1996). Movement of plasma molecules throughout the synovial membrane implies the passage of two barriers: 1) the fenestrated endothelial wall of the blood vessels within the subintima and, 2) the interstitial spaces between the synoviocytes in the intima (SIMKIN 1995). The lack of a basal membrane and the proximity of the blood vessels facilitate the exchange of substances (TODHUNTER 1996). The permeability of the synovial membrane is inversely proportional to the size of the molecules (SIMKIN 1997). The majority of small molecules (e.g. oxygen, lactate, tissue metabolites) traverse the synovial membrane through free diffusion, standing in perfect balance with plasma (TEW and HOTCHKISS 1981; SIMKIN 1997) while high-weight molecules (e.g. fibrinogen) are excluded (McILWRAITH 1987). Restricted passage of protein is mostly determined by the fenestrated endothelium while passage of small solutes is limited by the interstitial spaces between the synoviocytes (SIMKIN 1995). Efflux of proteins from synovia in joints takes place through lymphatic drainage (WALLIS et al. 1987).

Hyaluronate is a high weight non-sulfated GAG (POPOT et al. 2004), that provides the synovia with its characteristic viscosity (PERSSON 1971, van PELT 1974; GÄNGEL 1980). Together with lubricin, hyaluronate plays an important function in the lubrication of joint structures (GARNERO et al. 2000).

*Under physiological conditions, hyaluronic acid is associated with monovalent cations and is called hyaluronate. Hyaluronan is the name of the molecule when associated with unknown cations. Sodium hyaluronate is the commercially marketed sodium salt of hyaluronic acid (POPOT et al. 2004).

Synovial fluid fulfills three important tasks in the joint (SIMKIN 1997): 1) to supply the articular cartilage with necessary nourishment as well as the removal of waste products of the articular cartilage metabolism; 2) to provide low-friction lining by lubricating the joint surfaces; 3) to help maintaining joint stability. Changes in the characteristics of synovia in disease may indeed impair the functions mentioned above, with detrimental consequences to joint tissues (PALMER and BERTONE 1996; van den HOOGEN et al. 1998).

Changes in these physiological parameters of synovia reflect changes in the internal metabolism of the joint (GÄNGEL 1980; BOLBOL 1983; McILWRAITH 1987). An impairment of the exchange of substances between blood and synovia and a disorder in the metabolism of the joint occur in disease (van PELT 1962, 1967). For the purpose of the present work, physiological parameters as well as their alterations in disease will be presented together.

2.3.1. Biophysical characteristics

Appearance: Normal synovia is a colorless (McCARTY 1997) to light yellow clear fluid with no suspended particles (van PELT 1962; BOLBOL 1983; MAHAFFEY 2002). Red strings of blood observed during aspiration indicate lesions of the synovial membrane due to arthrocentesis, while homogeneous red coloration denotes a hemorrhage due to traumatic synovitis (TEW and HOTCHKISS 1981; HERTSCH 1983). Amber (xanthochromic) coloration indicates earlier hemorrhages (HERTSCH 1983) or long-lasting hemorrhages of low intensity (van PELT 1974). This amber color is due to the bilirubin, which is the product of the metabolism of the hem group of the erythrocytes (McCARTY 1997).

Cloudy fluids are observed when the synovial content of colloidal or formed substances increases. This cloudiness is directly proportional to the degree of synovitis, being maximal in septic arthritis. Chronic aseptic arthritis shows clear, light cloudy or cloudy fluids (GÄNGEL 1980), but non-inflammatory synovia is commonly transparent (McCARTY 1997). However, synovial fluid from joints suffering from osteoarthritis and OCD may appear cloudy because they may contain wear particles of cartilage (van PELT 1974).

Changes in synovial color are often seen in acute traumatic or septic joint disease, whereas it is often minimal in chronic osteoarthritis and OCD (McILWRAITH 1987). In septic

infections, the fluid is yellow to white-gray (GÄNGEL 1980) or cream colored (MAHAFFEY 2002). Its white coloration is due to the high concentration of leukocytes (McCARTY 1997). Hemorrhagic fluid is frequently seen and flocculent material is often suspended in the fluid, because of the severe synovitis in septic cases (GÄNGEL 1980).

Volume: Volume of synovia within the joint is directly proportional to the joint size (van PELT 1962, 1974). An increase in the synovia volume is observed in synovitis, although its degree may vary according to the degree of inflammation and stage of the disease (McILWRAITH 1987).

Viscosity: Synovia shows a non-newtonian flow behavior (McILWRAITH 1987). Synovial fluid is a viscous and elastic fluid, due to its content of hyaluronate. The degree of viscosity depends upon the concentration of hyaluronate and its degree of polymerization (PERSSON 1971; van PELT 1962, 1974; GÄNGEL 1980; McILWRAITH 1980). Horses in training show a minor decrease in viscosity in comparison to horses at stall rest and viscosity is conversely proportional to the size of the joint (van PELT 1962; PERSSON 1971; TEW and HOTCHKISS 1981).

In disease, the viscosity of synovia may decrease as a result of a dilution effect in joint effusion, synthesis of a low-quality hyaluronate by inflamed synoviocytes (EISENMENGER 1974), and the destruction of the hyaluronate molecule (McILWRAITH 1987; GREEN et al. 1990; MAHAFFEY 2002).

Viscosity of synovial fluid may vary widely in diseased joints. In degenerative and traumatic joint disease, viscosity may be normal or decreased and it is inversely proportional to the degree of effusion (MAHAFFEY 2002). Septic synovia shows a severely decreased viscosity (HERTSCH 1983; McILWRAITH 1987). The viscosity of synovia does not correlate with the rheologic properties of the synovia (REJNÖ 1976) and may not always show a relationship with the degree of synovitis, as cases of severely decreased synovia viscosity have been reported in cases suffering from only mild synovitis (McILWRAITH 1987; TROTTER and McILWRAITH 1996).

Thixotropism: Normal synovia does not clot, since it lacks fibrinogen and other clotting proteins (GÄNGEL 1980) but upon standing it becomes gelatinous. After gentle agitation,

normal synovia recovers its fluid state (van PELT 1974). The fall of the viscosity of a substance with increasing stress that is slowly recovered on standing is a phenomenon called thixotropism (REJNÖ 1976). Therefore, synovia is considered a thixotropic fluid. Thixotropism of synovial fluid is directly proportional to the amount of hyaluronate it contains. Clotting of synovia can be seen in inflammation, because of the increase of fibrinogen and clotting factors (EISENMENGER 1974) and it is mostly seen in synovia from traumatic and septic arthritis (van PELT 1974).

2.3.2. Cellular composition

Erythrocytes: Synovial fluid is free of red blood cells (van PELT 1962; HERTSCH 1983). Lesion of capillaries in the synovial membrane during sample collection is inevitable and accounts for the presence of some erythrocytes in normal synovial samples (van PELT 1962; GÄNGEL 1980; BOLBOL 1983; HERTSCH 1983; SANDER 1990; TROTTER and McILWRAITH 1996, McILWRAITH et al. 2001; MAHAFFEY 2002). Hyperemia in synovitis increases the predisposition for this contamination of the sample (McILWRAITH 1987).

Nucleated cell count: Several reports on the content of total white blood cell count (TWBC) in synovia of healthy horses show a great variability, not only between individual but also between joints of the same horse (BOLBOL 1983). PERSSON (1971) reported a normal cell count of 76 ± 99 cells/mm³, whereas van PELT (1974) details a normal count of 87 cells/mm³. On the other hand, BOLBOL (1983) reported mean values ranging from 131 to 398 cells/mm³ for different joints. TEW and HOTCHKISS (1981) reported values of less than 200 cells/mm³. DIRKS (2000) reported normal values of 500 cells/ μ l or less for healthy synovia using an automated cell coulter. A difference in the methods of measurement may explain the different values reported in the literature.

Daily trauma can slightly elevate the normal TWBC without pathologic implications (McILWRAITH 1980). On the other hand the nucleated cell count in traumatic arthritis and osteoarthritis varies widely, and values between 5 000 to 10 000 cells/mm³ can be found (McILWRAITH 1980, 1987). MAHAFFEY (2002) suggests that in degenerative or traumatic joint disease, TWBC may remain within the normal values or slightly higher. TEW and HOTCHKISS (1981) suggest that traumatic effusion may present a normal cell number. OCD

and idiopathic synovitis often have less than 1000 cells/mm³ (McILWRAITH 1980; 1987) and can also remain unchanged when compared with healthy controls (SANDER 1990). In general, reports in the literature indicate that non-septic joint conditions may present normal total counts of white blood cells.

Infectious arthritis presents the highest white blood cell counts (GÄNGEL 1980, McILWRAITH 1987; MAHAFFEY 2002) and values over 30 000 cells/mm³ and 100 000 cells/mm³ are almost pathognomonic of septic arthritis (McILWRAITH 1980). Synovial fluid of inflammatory joint disease shows counts of leukocytes above 5000 cells/μl and may well surpass the 100 000/ μl. Acute trauma may increase the white blood cell count to as high as 30 000 cells/mm³, but it usually dwells between 1 000 and 10 000 cells/mm³ (McILWRAITH 1980).

Differential cell count: Cells of healthy synovia are mainly mononuclear cells like monocytes/macrophages whereas neutrophils account for no more than 10% of the total normal cell count (McILWRAITH 1987; MAHAFFEY 2002). Samples with very low TWBC counts or strong blood contamination may show more than 10% neutrophils (MAHAFFEY 2002). Eosynophiles represent no more than 1% of total cells (van PELT 1962; MAHAFFEY 2002) while basophiles have not been observed (BOLBOL 1983).

Traumatic or degenerative joint disease shows a preponderance of macrophages while neutrophils normally comprise less than 10% (MAHAFFEY 2002). Lymphocytes are commonly found in old horses, horses in stall, and in chronic joint disease (EISENMENGER 1974). Neutrophils are the predominant cells in septic arthritis (McILWRAITH 1987) and may show nuclear degeneration (MAHAFFEY 2002). This can lead to a diagnosis in cases of septic arthritis (McILWRAITH 1980).

2.3.3. Biochemical characteristics

Total protein concentration: Total protein concentration of synovia in the horse is determined by the ultra filtrating properties of the synovial membrane. Synovial protein concentration is less than in plasma (van PELT 1974), containing about 30% of the total plasma protein concentration of the same horse (McILWRAITH 1987), showing decreased relative concentrations of alpha 2 and globulin levels but an increased relative concentration

of albumin (PERSSON 1971). Protein concentration displays a large interindividual variation, as well as between joints. Horses in training show higher protein concentrations (PERSSON 1971). Normal values reported in the literature vary broadly. van PELT (1974) reported $1,81 \pm 0,26$ g/dl. TEW and HOTCHKISS (1981) report 5 – 10 mg/ml while van PELT (1974) reported a reference range of 0,92 to 3,11 g/dl. Differences are probably due to the use of different analytical methods. KAWCACK et al. (1997), FRISBIE et al. (1999) and McILWRAITH (1987, 2002) reported a general physiological value of 2,5 g/dl or less with the use of a refractometer.

In synovitis, the protein content of synovia increases because of the increased vascular leakage allowing protein molecules of high weight to enter the joint (CLYNE 1987; SIMKIN 1991; PALMER and BERTONE 1996).

Values above 2,5 g/dl are considered pathologic and beyond 4 g/dl suggest a severe inflammation (McILWRAITH et al. 2001; McILWRAITH 1980, 2002). Protein concentration in fluid of traumatic, degenerative diseases (van PELT 1974; MAHAFFEY 2002) and OCD (SANDER 1990) may show little if any variation compared to normal fluids. On the other hand, increased concentration of total protein in cases of acute synovitis has been detected while no increase in chronic synovitis has been reported (TEW and HOTCHKISS 1981).

Septic arthritis shows a marked increase in the protein concentration, with an important reduction of the albumin:globulin ratio (van PELT 1974) with a total concentration that may be above 4 g/dl (McILWRAITH et al. 2001; McILWRAITH 1987, 2002). This increase is due to the increased synovial permeability and the products of cellular constituents (MAHAFFEY 2002) and takes place during the first three weeks of infection (BERTONE et al. 1987).

pH value: pH value of synovia is inversely proportional to the size of the joint (PERSSON 1971). Normal pH value in the synovia on the horse is lightly alkaline (7,34 – 7,51) (BOLBOL 1983). PERSSON (1971) found more elevated values (7,79 – 7,95). Values for pH decrease in septic arthritis (TULAMO et al. 1989a; LLOYD et al. 1990).

Glucose: Reports on the glucose concentration in normal synovia in the horse varies widely in the literature. van PELT (1962) found slightly increased concentrations in synovial fluid,

while others detail lower concentrations when compared to plasma (van PELT 1967; BOLBOL 1983).

High lactate concentrations are very suggestive of bacterial infection of the joint: 5, 5 mmol/l is “suspicious” and over 11,1 mmol/l is pathognomonic of joint infection (HERTSCH 1983).

Synovial fluid analysis provides information about the changes in the metabolism within the joint (BOLBOL 1983) and is to be used in conjunction with anamnesis, clinical, and roentgenographic examination. Information provided by synovial analysis is unspecific because of the instability of the responses of the synovial membrane and it does not lead to any specific diagnosis, except for the majority of cases of septic arthritis. (EISENMENGER 1974; van PELT 1974; TEW and HOTCHKISS 1981; McILWRAITH 1987; MAHAFFEY 2002).

Nowadays, the most important parameters of the synovial analysis in daily clinic work are total protein concentration and nucleated cell count (DAGLEISH et al. 2003). These parameters report the degree of synovitis but do not provide information about the degree of articular cartilage degeneration, nor about the early stages of osteoarthritis. This and the limitations of clinical and radiological examination to diagnose early phases of articular cartilage degeneration has led to the search for biomolecules that may lead to more specific assessment of the stage of disease within the joint. A review of the most important features of these markers is presented below.

2.4. Biomarkers of joint disease

2.4.1. General aspects

Biomarker, biochemical marker and molecular marker are terms used to designate indicators of anomalous skeletal tissue turnover (BILLINGHURST 2003). LOHMANDER and EYRE (2005) defined a biomarker as “a structural or physical measure or cellular, molecular, or genetic change in a biologic process that can be identified and monitored, with resulting diagnostic or prognostic utility”.

Markers of joint disease can be potentially used to:

1. Discriminate between healthy and diseased joints; to monitor the severity of the disease, variations in disease status and response to therapy; to detect patients likely to show rapid progression and to predict response to therapy (BILLINGHURST 2003).
2. Investigate pathobiological mechanisms and dynamics of disease; to recognize possible molecules that might be the subject for the development of future treatment and to adjust therapy according to the levels of biomarker being measured (LOHMANDER and EYRE 2005).

The ideal biomarker for joint disease should:

1. Relate to the nature of disease, the phase of degradation or ratio of the degrading process. The ideal biomarker should not be produced in normal tissue and it must be easily measured using chemical or immunological methods (RØRVIK and GRØNDAHL 1995).
2. Detect joint disease before conventional methods do; give an overview about the disease activity and the progression of joint damage, and prognosticate future illness and cause of joint disease (McILWRAITH 2005).
3. Be validated against measurements and should correlate with a gold standard (e.g. radiography, magnetic resonance imaging) (FULLER et al. 2001).

Biomarkers of joint disease can be measured in fluids like blood, urine and synovia. Synovial fluid presents several advantages when compared to other body fluids:

1. It is joint specific. Markers in blood or urine account for metabolites derived from any joint or cartilage structure of the body (THONAR et al. 1993).

2. Synovia would provide higher concentrations of the marker, since it stays in direct contact with the joint structures (LOHMANDER et al. 1992).
3. Synovia provides greater chances to identify high proportions of the marker (THONAR et al. 1993). Markers may undergo degradation processes within the joint, the lymphatic system (LOHMANDER et al. 1992), liver, or kidneys (LOHMANDER 2004) before being detected in blood or urine.

Disadvantages of selecting synovia as the fluid of choice are related to the difficulties and risks associated with arthrocentesis (septic arthritis and lesions of the synovial membrane). Besides, changes in fluid volume within the joint (LEVICK 1992) as well as changes in the clearance rate of compounds in the synovia due to inflammation (MYERS et al. 1996) may modify the concentration of marker in the synovia, thus probably providing misleading information to assess the disease.

Biomarkers for joint disease can be classified in **direct** and **indirect** (THONAR et al. 1999). **Direct biomarkers** account for compounds produced in cartilage or bone, or enzymes that are active exclusively in these tissues. **Indirect biomarkers** describe substances that are not mainly produced by joint tissues but that can potentially influence their metabolisms and structure. A brief description of biomarkers in synovia in the horse is presented below.

2.4.2. Direct biomarkers

Breakdown products of articulate cartilage

Analysis of metachromatically stained cartilage fragments in the synovial fluid after centrifugation was proposed as a marker by van PELT (1974). The depth of the cartilage lesions was assessed by comparing the arrangement of the cells observed in the fragments with the distribution pattern of cells in the normal layers of the articular cartilage. This method has not become very popular (McILWRAITH 2002).

Collagen and proteoglycans are almost specific components of articular cartilage. Therefore, fragment of these molecules are good prospects for biomarkers of joint disease (GARNERO et al. 2000). Total concentration of GAG in the synovial fluid has been assessed using the dimethyl methylene blue (DMMB) assay. The results have been contradictory. While some authors found increased concentrations on osteoarthritic joints (PALMER et al. 1995), others

have found decreased concentrations, whereas LITTLE et al. (1990) and FULLER et al. (2001) failed to find significant differences between normal and diseased joints. In addition, this biochemical assay is rather unspecific, since it accounts for the total GAG concentration independently of their origin (articular cartilage, menisci, synovial membrane) (McILWRAITH 2002).

Immunologic detection with antibodies has provided a more specific tool for a qualitative and quantitative analysis of cartilage degradation products. Detection of keratan sulphate (PALMER et al. 1995; FULLER et al. 2001) and chondroitin sulphate antibodies directed against specific native epitopes of GAG have been produced, although with inconsistent results. An even more specific approach has been accomplished by producing new antibodies that recognize “neoepitopes” in the GAG, i.e. new epitopes created by the action of the proteolytic enzymes, although with inconsistent results (McILWRAITH 2005).

Other macromolecules involved in the mechanisms of degradation of joint tissue have been proposed as putative markers.

High synovial concentrations of enzymes like alkaline phosphatase (ALP), aspartate aminotransferase (AST) and lactate dehydrogenase (LDH) (van PELT 1974) and LDH₄ and LDH₅ isoenzymes (REJNÖ 1976) were proposed in the literature as indicators of joint disease. However, they mostly result from synovitis, thus providing rather unspecific information (McILWRAITH 2002).

2.4.3. Indirect biomarkers

Substances related to the mechanism of articular cartilage degeneration

Increased concentrations and activity of several MMPs have been detected in diseased joints in the horse (CLEGG et al. 1997; BRAMA et al. 1998; CLEGG and CARTER 1999; BRAMA et al. 2000; BRAMA et al. 2004; van den BOOM et al. 2005) and a positive correlation between the activity of MMPs and the degree of articular cartilage degeneration has been reported (JOUGLIN et al. 2000). Nonetheless, MMPs are very unspecific because they can be produced by monocytes, lymphocytes, synovial cells, tumor cells (GAUDIN et al. 1997) and neutrophils (MOREL et al. 1994).

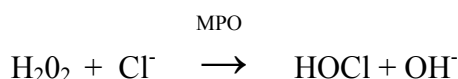
Cytokines (JOUGLIN et al. 2000; BERTONE et al. 2001), eicosanoids (GIBSON et al. 1996; BERTONE et al. 2001), and neutrophil elastase 2A (DAGLEISCH et al. 2003), among others, have been recently studied in synovia of diseased joints as possible biomarkers for joint disease in the horse.

2.4.4. Myeloperoxidase

Myeloperoxidase (MPO) is a heme enzyme contained in the azurophilic (primary) granules of the neutrophils (KLEBANOFF 1999)*. It was purified for the first time in humans by AGNER in 1941 and was called “verdoperoxidase” because of its green color. And indeed, pus owes its green appearance to its content of MPO (WEISS 1989; KLEBANOFF 1999). This enzyme has been studied in several species and was more recently purified for the first time from equine neutrophils by MARTHY-HARTERT et al. (1998).

Neutrophils belong to the group of phagocytic cells playing a critical role in the host defense (BABIOR 2000). Once activated, neutrophils destroy microorganisms by non-oxidative and oxidative mechanisms. The former mechanism implies the degranulation process of the two types of cytoplasmic granules leading to the discharge of their bactericidal enzymes into the phagosome (e.g. lactoferrin, elastase, cathepsin G) (CLARK 1983; KLEIN and HOŘEJŠI 1997). The latter relates to the production of highly reactive oxidants like superoxide ($O_2^{\cdot -}$), hydrogen peroxide (H_2O_2), nitric oxide (NO) and hypochlorous acid (HOCl) produced during the respiratory burst (BABIOR 1999, 2000).

In this regard, the role of MPO leads to the formation of highly oxidative species (WEISS 1989). MPO catalyzes the oxidations of halide ions (Cl^- , Br^- , I^-) to hypohalous acids by reacting with H_2O_2 (HAMPTON et al. 1998). Due to the high concentration of Cl^- in body fluids, the reaction principally occurs with Cl^- (BABIOR 2000) as follows:



The product of the MPO/ H_2O_2 / Cl^- system, the hypochlorous acid (HOCl), is the most toxic biological oxidant with cytolytic effects generated in large amounts by neutrophils (WEISS 1989). Several authors have determined that through subsequent reactions, the MPO system can also lead to the formation of other reactive species like nitric-oxide derived oxidants, chloramines, aldehydes, etc.

* Monocytes have cytoplasmic granules with MPO but in less quantity than in neutrophils (NICHOLS and BAINTON 1973). The enzyme is lost as monocytes mature into macrophages (KLEBANOFF 1999).

The MPO/H₂O₂/Cl⁻ system plays a crucial role in the destruction of viruses, bacteria, fungi and protozoa (KLEBANOFF 1999; BABIOR 2000). On the other hand, the system is considered a “double edge sword”, since it can also damage normal host tissue. Activation of phagocytes concomitantly with oxidant generation does not occur exclusively associated with phagocytosis of pathogens, but it can also be triggered by exposure to soluble stimuli, biological membranes, noningestible particulate materials or trauma. Independent of the stimuli triggering this activation of neutrophils, their proteolytic enzymes and ROS can be discharged into the extracellular milieu and damage nearby host cells and tissues (CLARK 1983; EDWARDS et al. 1987; WEISS 1989; KLEBANOFF 1999).

In the horse, an *in vitro* trial demonstrated the cytolytic effect of activity of MPO liberated by activated equine neutrophils on nearby endothelial cells (BENBAREK et al. 2000). High activity of MPO has been detected in intestinal tissue of equines undergoing with colonic ischemia and reperfusion (YARBROUGH et al. 1994) and acute colitis (McCONNICO et al. 1999), while increased concentration of MPO in plasma has been reported in cases of strangulated intestinal pathologies (DEBY-DUPONT 1998; GRULKE et al. 1999).

Research studies have focused on the effects of the products of the MPO/H₂O₂/Cl⁻ system on joint disease (Figure 3). Increased concentration, and/or activity of MPO, and evidence of its release *in vivo* has been found in synovial fluid of rheumatoid joints in humans (HADLER et al. 1979; EDWARDS et al. 1988; SCHILLER et al. 1996). *In vitro* studies have shown that HOCl may fragment collagen fibers (DAVIES et al. 1993) and modify amino acid side chains, secondary structure, and type of aggregate of collagen type II in the articular cartilage (OLSZOWSKI et al. 2003). An *in vitro* study carried out by KOWANKO et al. (1989) showed that HOCl can degrade proteoglycans of the articular cartilage and inhibit their synthesis. SCHILLER et al. (1996) demonstrated the role of HOCl in the degradation of N-acetyl groups of proteoglycans in rheumatoid joints. More recently, a synergistic interaction between superoxide radicals and HOCl in the destruction of extracellular matrix hyaluronate and proteoglycans has been suggested (REES et al. 2004). A mechanism of interaction between MPO and macrophages leading to the production of TNF- α has been proposed to account for the chronicity of inflammation observed in rheumatoid arthritis (LEFKOWITZ et al. 1999). On the other hand, it has been demonstrated that HOCl can activate MMPs (WEISS et al. 1985; FU et al. 2001), which could be an indirect mechanism of articular degradation mediated by HOCl.

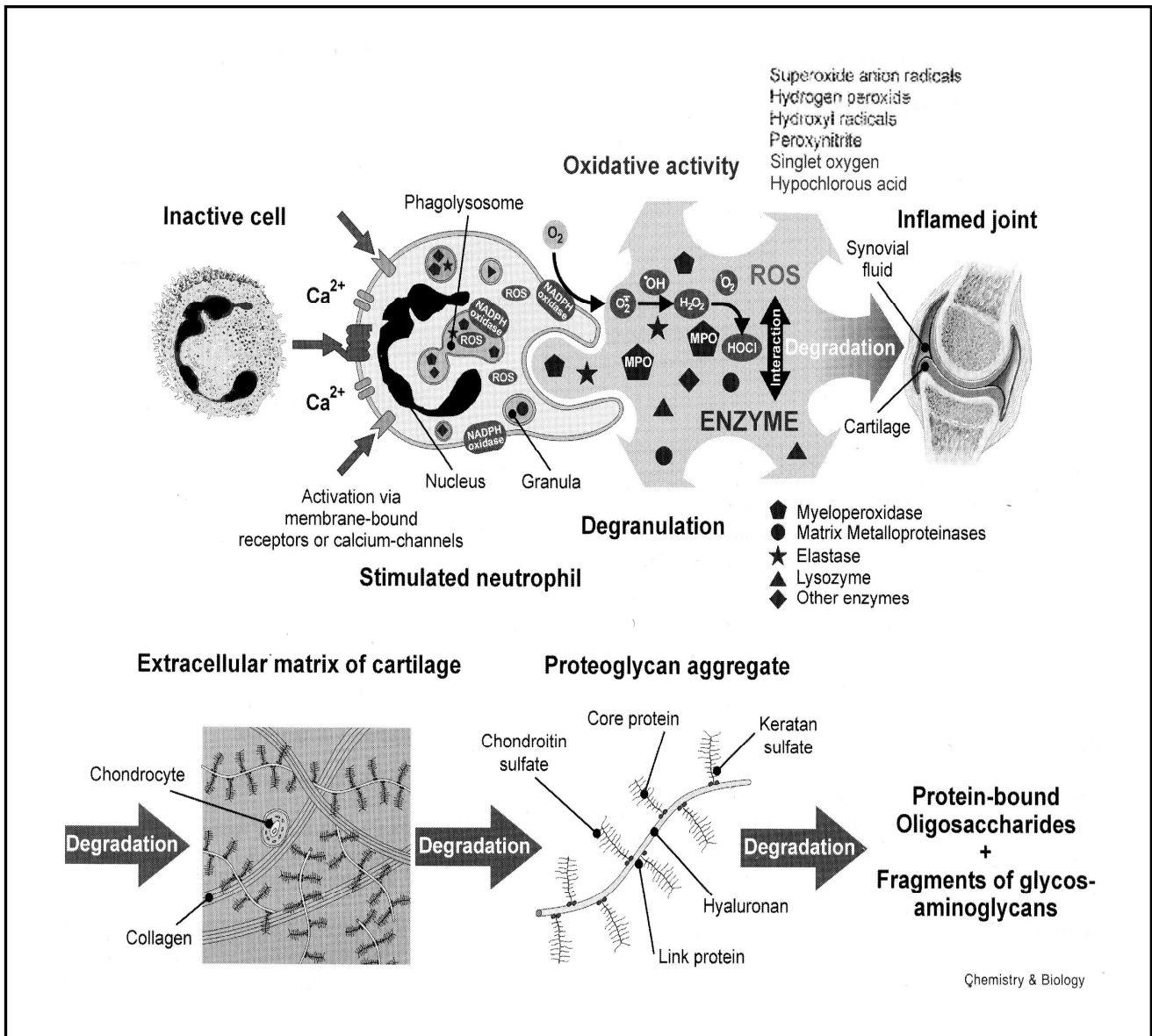


Figure 3. Proposed mechanism of cartilage degradation during rheumatic diseases: Neutrophils invade from the blood flow into the joint space. Upon stimulation they release different ROS and proteolytic enzymes. These damage-conferring products lead to the degradation of the high-mass components of articular cartilage under the formation of low-mass components. Reprinted from Chemistry & Biology, 7. SCHILLER, J.; BENARD, S.; REICHL, S.; ARNHOLD, J. and ARNOLD, K. "Cartilage degradation by stimulated human neutrophils: reactive oxygen species decrease markedly the activity of proteolytic enzymes". Pages 557 – 568.

Copyright 2000, reprinted with permission from Elsevier.

In synovia, studies have demonstrated that the MPO/H₂O₂/Cl⁻ system-products deplete purified hyaluronate, leading to a reduction in the viscosity of synovia (BAKER et al. 1989; GREEN et al. 1990). Moreover, due to its strong positive charge, MPO possibly binds to negatively-charged surfaces like hyaluronate, accelerating the destruction of hyaluronate and other negatively-charged structures within the joint, as the production of HOCl will occur close to the target structures (GREEN et al. 1990).

LAMMER (2001) and SPELLMEYER (2003) reported an increased activity of MPO in the synovia of dogs with joint disease when compared with healthy controls, suggesting the assessment of the activity of the MPO as a good biomarker for joint diseases in the dog.