

3. Investigation of possible mechanisms for reproductive inactivity in captive Namibian female cheetahs

3.1 Introduction

For captive female cheetahs, absent or irregular oestrous cycles have been demonstrated repeatedly (Wildt et al. 1993; Brown et al. 1996; Jurke et al. 1997; Wielebnowski & Brown 1998; Wielebnowski et al. 2002; Terio et al. 2003). Periods of reproductive inactivity were attributed to unnatural and stressful conditions in captivity (Brown et al. 1996, Jurke et al. 1997, Wielebnowski et al. 2002), later also to an endogenous circannual rhythm of the animals (Terio et al. 2003).

Long-term hormone studies did not reveal an unambiguous pattern of cheetah reproduction. Brown et al. (1996) monitored ovarian oestradiol excretion in faeces of seven adult females for more than 12 months in several facilities in North America. All females in their study expressed cyclic activity. However, these oestrous cycles were discontinuous and interrupted by anoestrous periods of 2 to 5 months in duration. These periods may explain previous results of ovarian inactivity described in the snapshot study of Wildt et al. (1993) using laparoscopy and the results from this study using ultrasonography (Chapter 2). Periods of prolonged anoestrous varied highly within and between individuals and were neither synchronous among females within facilities nor associated with seasonality (Brown et al. 1996). Wielebnowski et al. (2002) confirmed these findings and showed that housing of females in "behaviourally incompatible pairs" for 6 months led to anoestrous periods of up to 5.7 months. Jurke et al. (1997) suggested that the close proximity of conspecifics might be a source of stress, leading to the suppression of ovarian activity in susceptible cheetahs.

Terio et al. (2003) suggested another explanation for low reproductive activity in captive cheetah females. They conducted a study over 11.0 and 15.5 months on one and two captive females in Namibia, respectively, and demonstrated anoestrous periods in all three females lasting between 1.0 and 4.5 months (Terio et al. 2003). These animals, however, were housed under nearly natural conditions on Namibian farmland with exposure to natural photoperiods and temperatures. Periods of anoestrous in the three studied females preceded a season of significantly low rainfall whereas no anoestrous periods were identified during the preceding months of the following rainy season when rainfall was markedly higher. Although the authors did not suggest a mechanism for their idea, they proposed that reproductive cycling might be triggered by an endogenous circannual rhythm and that anoestrous periods preceding environmentally harsh situations would prevent females from raising offspring during comparatively difficult conditions, e.g. during

periods with low prey availability following low rainfalls (Terio et al. 2003). Terio et al. (2003) further suggested that these naturally occurring anoestrous periods might have lost their rhythm under captive conditions in North American facilities, resulting in non-seasonal anoestrous periods.

Recently, studies on captive white rhinoceros (*Ceratotherium simum sp.*, Hermes et al. 2004, 2006) and African and Asian elephants (*Loxodonta africana* and *Elephas maximus*, Hildebrandt et al. 2000) suggest an alternative explanation for irregular oestrous cycles. They demonstrated that females exhibiting long periods of reproductive inactivity, i.e. without pregnancy and lactation, have absent or irregular oestrous cycles after a certain age (Brown 2000; Hildebrandt et al. 2000; Hermes et al. 2004). Such absent or irregular oestrous cycles were found in 78% of 54 investigated captive female rhinoceros within the European and North American Species Survival Breeding Program (Hermes et al. 2006). They suggested that unnatural reproductive performance in captivity shortened the reproductive life span of females. In free-ranging populations, pregnancies and lactation dominate the endocrine status of females, with oestrous cycles being a rare event during their reproductive life. Non-breeding females in captivity, however, experience frequent maturation of follicles, ovulation and luteal phases, and their reproductive tracts are regularly exposed to extremely fluctuating oestrogen and progesterone concentrations throughout their continuous oestrous cycle activity. This causes a faster aging of reproductive organs than would be expected for a free-ranging female of similar age, leading to an 'asymmetric reproductive aging' process and a premature post-reproductive status (Hermes et al. 2004). At the end of this process, the ovaries turn into irreversible acyclicity, with the follicular stock being nearly depleted. Small, inactive ovaries dominated the clinical picture of acyclic white rhinoceros (Hermes et al., 2006). Such follicle depletion preceded by follicular activity and irregular oestrous cycles had been demonstrated before in mares (Hinrichs 1997) and rats (Sopelak & Butcher 1982).

Another consequence of frequent maturation of follicles is the development of hormone-dependent and age-related pathologic lesions of the reproductive tract (Hermes et al. 2006). In captive white rhinoceros, 56% of the examined females showed genital pathologies, with leiomyoma and cystic hyperplasia being the most common lesions. Nulliparous females showed a higher incidence of cystic hyperplasia than pluriparous females and also an increasing severity of cystic hyperplasia with age (Hermes et al. 2006). The model of asymmetric aging with a high incidence of reproductive pathologies might be applicable also to other captive species that show poor reproductive success (Hermes et al. 2004). To inhibit or delay such an asymmetric aging process and maintain reproductive health, Hermes et al. (2004) have suggested that a pregnancy early on during a female's reproductive life is important.

Using the minimally invasive technique of ultrasonography (Hildebrandt & Göritz 1998), captive female cheetahs in the current study were significantly more often in a reproductively inactive state than free-ranging females (Chapter 2). 67% of captive females showed no cycling activity whereas all free-ranging females were in a reproductively active state, i.e. they were cycling, lactating or raising weaned cubs (Chapter 2). By comparing additional results gathered with ultrasonography from free-ranging and captive females in the same study area and time period, possible mechanisms that might cause reproductive inactivity in captive cheetah females were investigated and predictions derived from hypotheses postulated in previous studies tested. Captive animals in this study were housed in large natural enclosures, similar to the study animals of Terio et al. (2003), and fed with prey species naturally occurring in the area, thus living under almost natural conditions that differ substantially from the conditions under which captive animals are kept in zoos.

To test whether reproductive inactivity and/or anoestrous periods in Namibian captive female cheetahs are associated with stressful conditions in captivity, the size of adrenal glands of captive and free-ranging females was measured. Stress often leads to an increased production of glucocorticoids. Chronic stress can result in a larger adrenal corticomedullary ratio (Terio et al. 2004), enlarged *zona fasciculata* in the adrenal cortex (Suleman et al. 2000) and abnormal adrenal gland morphology (Rideout et al. 1985). Thus, if reproductive inactivity and/or anoestrous periods in Namibian captive female cheetahs are associated with stressful conditions in captivity, then captive females would be expected to exhibit larger adrenal glands than free-ranging females. If, however, reproductive inactivity in cheetah females is influenced by climatically harsh conditions, i.e. low rainfall, and is triggered by an endogenous circannual rhythm, then reproductive inactivity in captive females should be absent during months preceding high rainfall. For this study, high rainfall was defined as higher than during the second rainy season in Terio et al.'s study (2003) that was suggested to be sufficiently high to inhibit anoestrous periods. Also, reproductive inactivity should not be found earlier than 5.7 months before the start of the rainy season, since this was the longest anoestrous period reported (Wielebnowski et al. 2002).

Alternatively, if irregular cycling activity in cheetahs is a consequence of the asymmetric aging process reported for captive white rhinoceros and elephants (Hermes et al. 2004, 2006; Hildebrandt et al. 2000), then ovarian inactivity and genital pathologies in captive females are expected to be found mainly in nulliparous and/or older females that have not reproduced for some time. Also, if genital pathologies are related to ovarian inactivity they should be found more often in captive than in free-ranging females.

3.2 Materials and Methods

Basic information on study sites and study periods are presented in Chapter 2 (Figure 2.1, Table 2.1), and details on all study animals, including immobilisation and anaesthesia protocols, are described there also (Tables 2.2, 2.3, 2.4 and Appendix 1). For this study only adult cheetah females were used. Data were available for 10 free-ranging and 9 captive animals. Seven of the captive females were nulliparous, one female (Z007) had one litter in captivity and for one female (Z002) the reproductive history was not known.

3.2.1 Ultrasonography

Transrectal ultrasound examination of reproductive organs was conducted as described in Chapter 2. For this study, liquid-filled structures in close proximity to the ovaries were measured and other pathologies of the reproductive organs were visualised. Additionally, the adrenal glands were imaged and measured. For this purpose, the rigid extension specifically designed for the ultrasound probe to conduct transrectal examination (Schnorrenberg, Woltersdorf, Germany) was introduced for about 40 cm to locate the adrenal glands situated cranially in proximity to the kidneys. The glands differed in their echogenicity from the surrounding tissue and were identified by their position, their kidney- to heart-like shape and their distinct edges.

In the ultrasonographic image, high echogenicity reflects tissues of high material density, thick mucus and/or low inter- or intracellular fluid content and appears light in the image whereas low echogenicity indicates low material density, thin mucus and/or high fluid content and appears darker in the image (Fritsch & Gerwing 1993). Measurements were made to an accuracy of 0.1 mm using an integrated calliper system. The length and medio-lateral thickness (cross-sectional diameter) of the adrenal glands and the maximum diameter of liquid filled structures were measured from the medial position of the ultrasound probe. The size of the adrenal glands was determined by calculating their cross-sectional area with the formula:

$$\text{Ellipse} = \left(\frac{\pi}{4}\right) * a * b$$

with a = maximum length and b = maximum cross-sectional diameter. When both adrenal glands were measured, the mean cross-sectional area was used for further analysis. For the two captive females that were examined twice (Z028, Z029) and the one examined three times (Z030), the measurements of the last examination were used, as they represent the adrenal gland sizes after the longest period in captivity.

3.2.2 Body measurements

When comparing adrenal gland sizes between captive and free-ranging females, possible differences in skeletal body size need to be taken into account (see section on Statistics below). This takes into account the allometric change in organ size with increasing body size. Body size was measured as body length from the tip of the nose along the medio-dorsal line to the sacro-coccygeal joint. Body length was recorded in cm to an accuracy of 0.5 cm.

3.2.3 Reproductive activity and annual rainfall

Data on rainfall were used to investigate whether reproductive inactivity in captive females preceded rainfall higher than those during the second rainy season in Terio et al.'s study (2003). Namibia is divided into three major seasons, with a hot-wet season from January to April, a cold-dry season from May to August and a hot-dry season from September to December (Berry et al. 1996). Annual average rainfall in the study area is usually between 300 and 400 mm per year with a rainfall peak in January and February (Mendelsohn et al. 2002). For this study, annual rainfall data of five representative farms in the study area covering 12 years from the 1993/1994 rainfall year (June 1993 to May 1994) to the 2004/2005 rainfall year (June 2004 to May 2005) were used (Figure 3.1). Mean rainfall during these 12 years was 336 mm, and rainfall was 233 mm in the rain reference year 2002/2003, 425 mm in 2003/2004 and 345 mm in 2004/2005 (Figure 3.1).

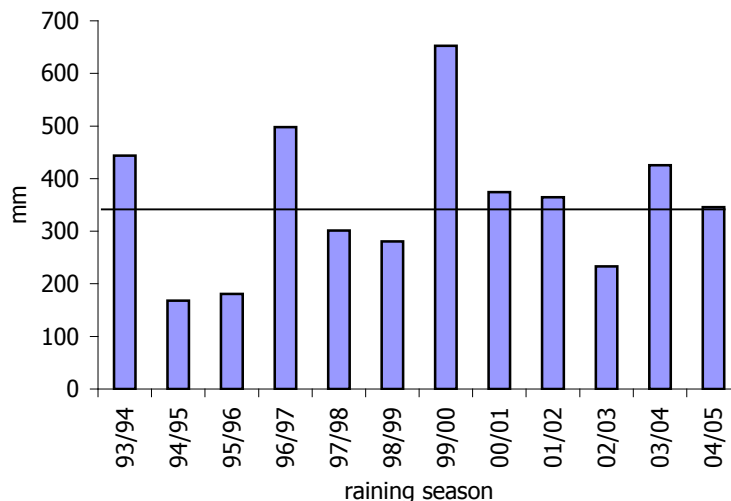


Figure 3.1 Average annual rainfall (for each reference year from June to May) in the study area. Data provided by five farmers within the study area. The line at 336 mm represents the average rainfall over the 12 years.

According to Mendelsohn et al. (2002) the same pattern for annual rainfall is likely to apply also to those areas further south and north where captive cheetahs were examined in this study and the study of Terio et al. (2003). Thus, rainfall in the rainfall years relevant to Terio et al.'s study (2003) was 168 mm in 1994/1995 and 181 mm in 1995/1996. Therefore, rainfall during the period of this study was 29%, 135% and 91% higher than in the 1995/1996 rainfall year. All females were investigated between June and December, i.e. during the seven months before the start of the rainy season and thus the period relevant to test Terio et al.'s prediction.

3.2.4 Number of oestrous cycles

The 'asymmetric reproductive aging' process is based on the assumption that in reproductively active free-ranging females oestrous cycles are rare events compared to reproductively inactive captive females. To estimate the number of oestrous cycles for these two female categories several assumptions about the reproductive life of female cheetahs were made. These assumptions were based on previous studies, whenever possible from Namibia (Marker et al. 2003). It was assumed that reproductively active free-ranging females have an average oestrous cycle of 14 days (Brown et al. 1996), a gestation period of 94 days (Brown et al. 1996), give birth to their first litter at an average age of 28.8 months (Kelly et al. 1998), lactate their cubs for 4 months (Caro 1994), have an average inter-birth interval of 24.0 months (Marker et al. 2003), raise on average 1.7 cubs to independence at 17.1 months during their lifetime, die at an average age of 6.2 years (Kelly et al. 1998) and reproduce until a maximum age of 12.0 years (Marker et al. 2003). It was further assumed that surviving cubs originate from one litter, not surviving cubs die in the first 2 months, the period when the large majority of cubs in the Serengeti died (Laurenson 1994), and females conceive on average after 19 days following the death of a litter (Laurenson et al. 1992). Finally, it was assumed that females start resuming their oestrous cycle immediately after cessation of lactation and cycle three times before conceiving for the first time. For captive females, the same length of oestrous cycle and longevity were assumed as for free-ranging females. In addition, a mean anoestrous period per year was calculated from females monitored for at least 12 months by Brown et al. (1996) and Terio et al. (2003). From Terio et al. (2003), females SB No. 2589 and SB No. 2590 were used with a duration of anoestrous periods of 136 days and 33 days, respectively, within the first 12 months of monitoring. From Brown et al. (1996) the females in figures 2a, 2b and 3a were used. The 12 month period of the female in figure 2a was selected from 1st of April 1993 to 31st of March 1994, i.e. the period after the non-pregnant luteal phase following mating, and the anoestrous period was estimated from the figure to be 68 days. For the females in figure 2b and 3a the first 12 months of

monitoring were used with estimated anoestrous periods of 144 and 100 days, respectively. From these data the mean anoestrous period was calculated to be 96 days (3.2 months) per year. Possible pseudopregnancies after spontaneous ovulation were not considered in the determination of cycle numbers for free-ranging and captive females.

3.2.5 Statistics

Statistical analysis was performed using SYSTAT 11.0 following procedures suggested by Engel (1997). All means are given with standard deviations and p-values are for two-tailed tests. For captive females without an exact knowledge of their age, the mean of the estimated age range was used for analysis.

To investigate the allometric relationship between the adrenal gland size and the body length, a reduced major axis regression was conducted. This modified linear regression is the appropriate regression model when both x and y variable are measured with errors and is the model of choice for allometric relationships (Sokal & Rohlf 1981). The allometric relationship is given by the equation

$$y = a * x^b$$

and its linearised form by

$$\log_{10}(y) = \log_{10}(a) + b * \log_{10}(x)$$

where y is a measure of organ size and x is a measure of body length. In a reduced major axis regression, the residuals are not calculated from least squares estimates but with the formula

$$[\log_{10}(y) - (\log_{10}(a) + b * \log_{10}(x))]^2 / |b|.$$

Subsequent statistical analyses used the residuals calculated in this way. Residuals were tested for normality with the Shapiro-Wilk Test (Shapiro & Wilk 2005). They did not significantly deviate from normal distribution. A Mann-Whitney U-Test was used to compare adrenal gland sizes between captive and free-ranging females.

3.3 Results

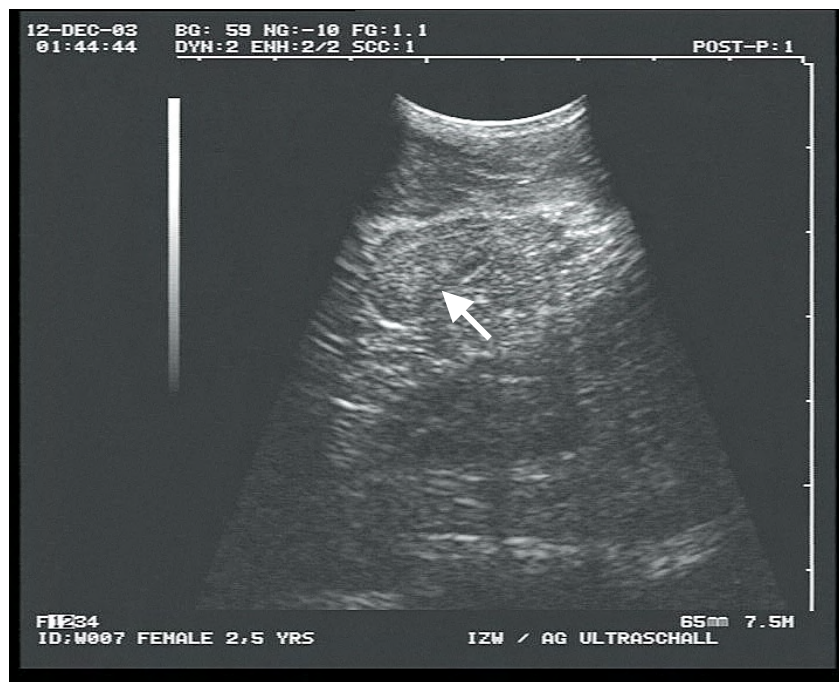
3.3.1 Adrenal gland sizes in free-ranging and captive females

Body length and cross-sectional area(s) of the adrenal gland(s) were both measured in eight adult free-ranging and six adult captive females. The reduced major axis regression revealed a significant increase of the cross sectional area of the adrenal glands with body length ($y = -16.35 * x^{5.95}$, $t = 3.26$,

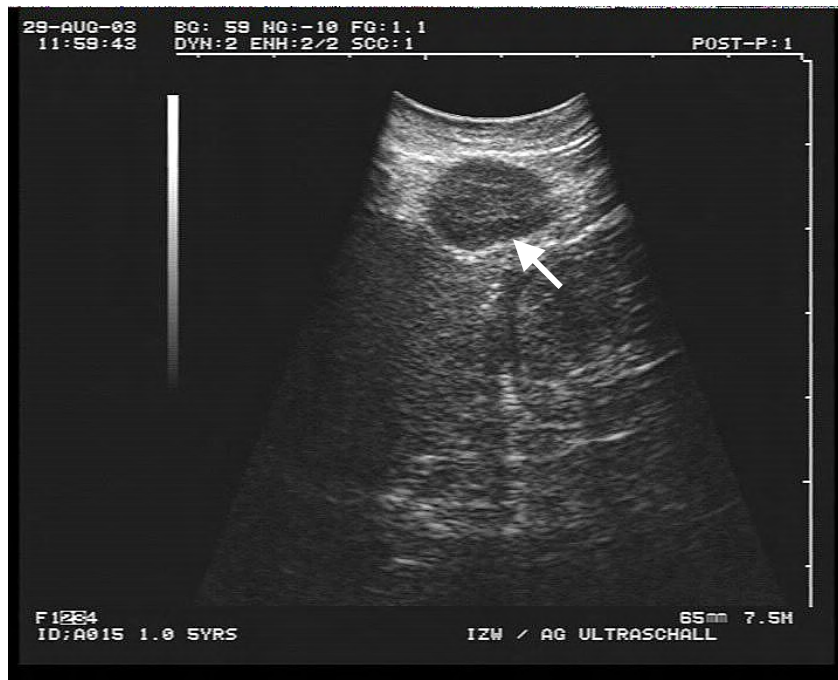
$N=14$, $p<0.01$). Subsequent comparison of the residuals of the reduced major axis regression between free-ranging and captive females showed no significant difference (Mann-Whitney U-Test, $U=15$, $N_1=8$, $N_2=6$, $p=0.25$), suggesting that there was no difference in stress levels between free-ranging and captive females.

The visual separation of medulla and cortex with ultrasonography was variable. Adrenal glands were therefore classified as having slight or no separation between medulla and cortex, having a medium separation or a clear separation (Figure 3.2).

a)



b)



c)

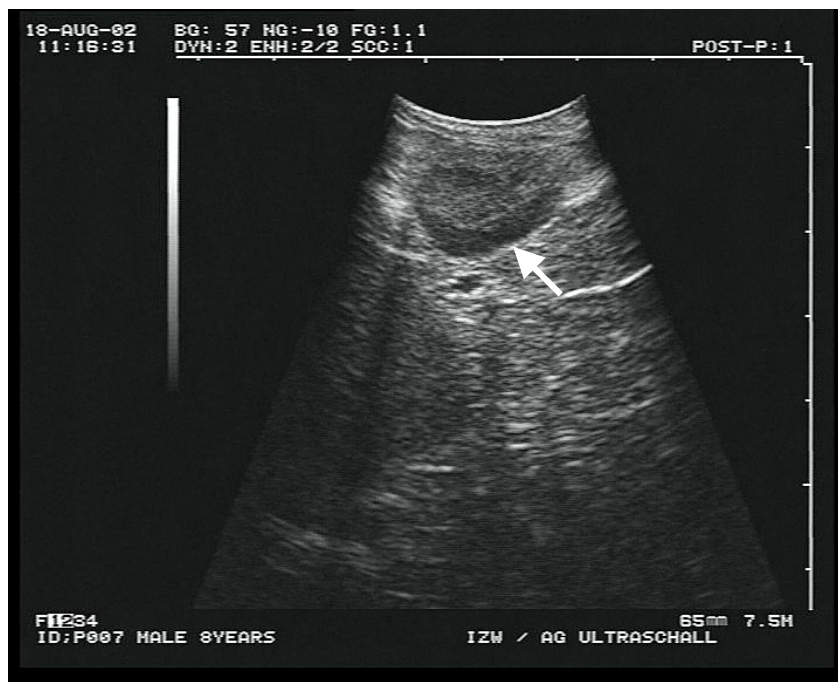


Figure 3.2 Ultrasonographic images of adrenal glands (white arrows) using three categories. a) slight or no separation between medulla and cortex, b) medium separation and c) clear separation.

Medulla and cortex of all but one free-ranging female were not clearly distinguishable whereas the ones of all but one captive females were clearly distinguishable (Figure 3.3). This difference was significant (Fisher exact test, $p=0.026$).

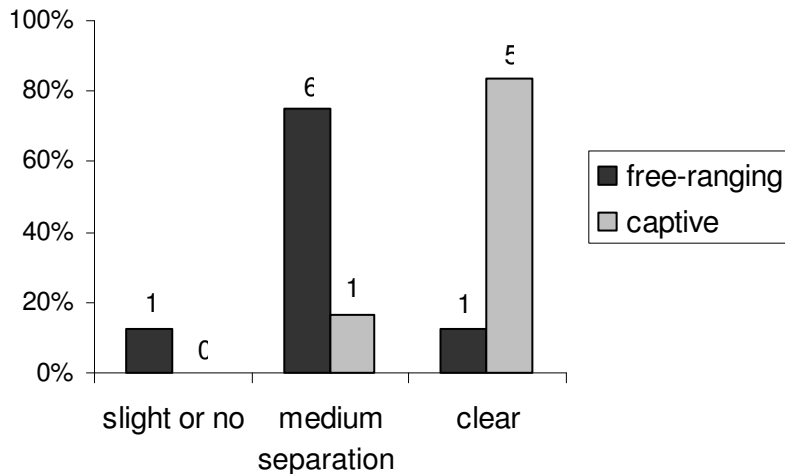


Figure 3.3 Classification of visual separation of medulla and cortex in adrenal glands for free-ranging and captive females using ultrasonography. The numbers above the bars represent absolute frequencies.

3.3.2 Reproductive activity and annual rainfall

All reproductive inactive states found in captive females were identified in months preceding high rainfall (see methods) (Table 3.1). All females in a reproductive inactive state during the first study year were found to be inactive in June, i.e. 7 months before the rainy season started, substantially earlier than the maximum 5.7 months predicted. All three females examined repeatedly were in a reproductive inactive state during all examinations.

Table 3.1 Reproductive state of captive females at time of examination, the following rain reference year and the respective annual rainfall in mm. Numbers in brackets in the ID-column represent the first, second and third examination.

ID	Reproductive state	Investigation date	Rain reference year	Rainfall (mm)
Z002	inactive	Jun 2002	2002/2003	233
Z007	inactive	Jun 2002	2002/2003	233
Z014	inactive	Jun 2002	2002/2003	233
Z028 (1)	inactive	Jun 2002	2002/2003	233
Z029 (1)	inactive	Jun 2002	2002/2003	233
Z030 (1)	inactive	Jun 2002	2002/2003	233
Z003	early luteal	Jun 2002	2002/2003	233
Z004	early luteal	Jun 2002	2002/2003	233
Z025	early luteal	Jun 2002	2002/2003	233
Z030 (2)	inactive	Oct 2003	2003/2004	425
Z028 (2)	inactive	Oct 2004	2004/2005	345
Z029 (2)	inactive	Oct 2004	2004/2005	345
Z030 (3)	inactive	Oct 2004	2004/2005	345

3.3.3 Number of oestrous cycles

On the basis of the available reproductive data accessible and the made assumption (see methods), a free-ranging female with an average longevity of 6.2 years has an expected reproductive lifespan of 50.1 months (i.e. 1523 days = 2263 days of longevity - 740 days when first cycle starts). During her reproductive life the female experiences only 44 oestrous cycles (Figure 3.4a), representing a total of 20.8 months oestrous cycle activity or 41.5 % of her reproductive lifespan (Figure 3.5a). For the remainder of her reproductive life she is pregnant (34.7 %) or lactates (23.8 %) (Figure 3.5a). In contrast, a non-reproductive captive female with anoestrous periods of 3.2 months per year experiences up to 82 oestrous cycles (Figure 3.4b), representing a total of 37.5 months of oestrous cycle activity or 74.8% of her reproductive lifespan

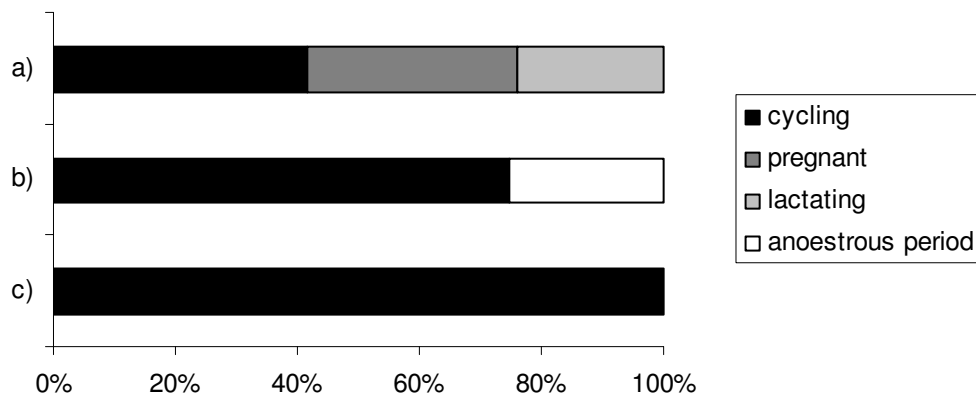


Figure 3.5 Proportion of different reproductive states for a) a reproducing female with an average longevity of 6.2 years ('cycling' also includes here the period of raising, see Figure 3.4a), b) a non-reproducing captive females with an average longevity of 6.2 years with regular cycles interrupted by 3.2 months of anoestrous and c) a non-reproducing captive female with an average longevity of 6.2 years without anoestrous periods, i.e. cycling constantly. For the underlying assumptions see methods.

Alternatively, a free-ranging female with a maximum longevity of 12.0 years experiences 56 oestrous cycles during her reproductive life, representing a total of 28.3 months of oestrous cycle activity or 23.6% of her reproductive lifespan (Figure 3.6a). For the remainder of her reproductive life she is pregnant (46.5%) or lactates (29.9%) (Figure 3.6a). A non-reproducing captive female with anoestrous periods and a longevity of 12.0 years experiences 192 oestrous cycles, representing 73.6% of her reproductive lifespan (Figure 3.6b), or 3.1 times as many cycles as the free-ranging female. When comparing a non-reproducing captive female cycling constantly, i.e. without anoestrous periods, with a reproducing free-ranging female, the former is likely to exhibit 4.2 times more oestrous cycles than the latter (Figure 3.6c). Such a female would have displayed the 56 oestrous cycles of a reproducing free-ranging female with a longevity of 12.0 years at the age of 52.6 month or 4.4 years.

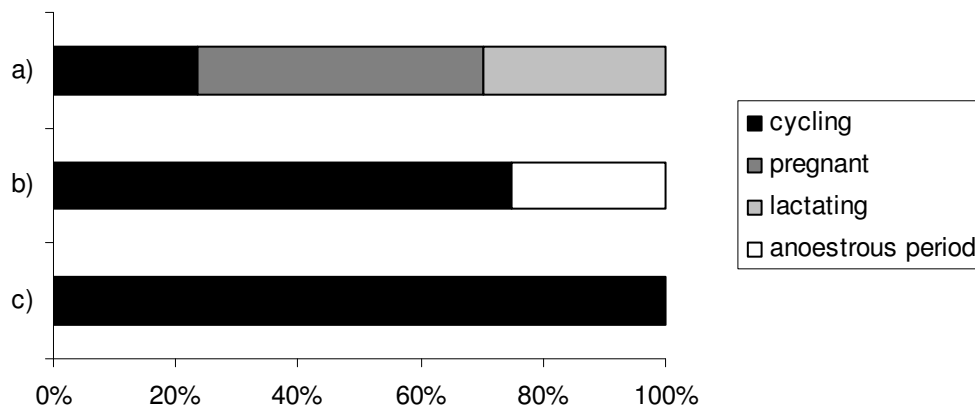


Figure 3.6 Proportion of different reproductive states for a) a reproducing female with a longevity of 12.0 years ('cycling' also includes here the period of raising cubs, see Figure 3.4a), b) a non-reproducing captive females with a longevity of 12.0 years with regular cycles interrupted by 3.2 months of anoestrus and c) a non-reproducing captive female with a longevity of 12.0 years without anoestrus periods, i.e. cycling constantly. For the underlying assumption see methods.

3.3.4 Pathologies of the reproductive organs

Uterus

During the second examination of a reproductively inactive captive female (Z028) an alteration of the uterus was diagnosed (Figure 3.7). A small quantity of echo low fluid was found in the corpus uteri and in both corni uteri. By putting slight pressure on the uterus with the ultrasound probe, the liquid was pushed away, indicating that it was not enclosed by any outer structure such as a capsule. Due to its mobility in the uterus lumen it could be differentiated from a possible trophoblast, which would have an outer wall and not be flexible in position due to their adhesion to the endometrium.

Fluid in the uterus is characteristic for an inflammatory process of the uterus, i.e. an endometritis, which can eventually develop into a pyometra. Liquid in the uterus is also characteristic for mucometra or hydrometra. If the pathological change of Z028 was a pyometra or a mucometra, the liquid in the uterine lumen would have appeared more echo dense, thus these two pathologies are unlikely in this case. Endometritis usually coincides with general signs of inflammation such as apathy and fever, which were not present in this female. Thus, the described alteration was diagnosed as a hydrometra. An investigation of the fluid itself would have been useful to support this diagnosis.

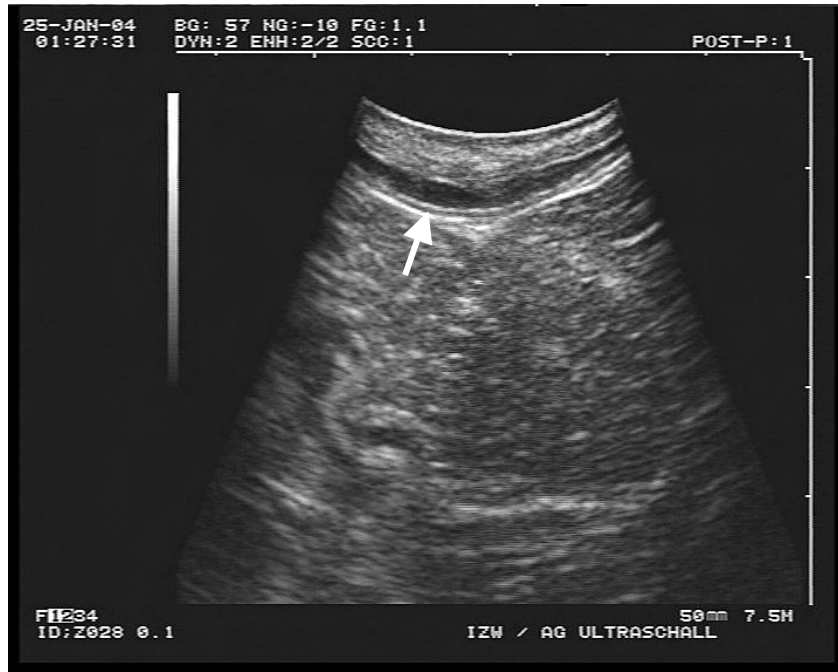

Figure 3.7 Sonogram of echo low fluid (white arrow) in the uterus of a reproductively inactive female diagnosed as a hydrometra.

Ovary

In two reproductively inactive captive females (Z002, Z029) the ultrasonography pictures showed enlarged areas of connective tissue on the ovaries. In Z029 these areas were found during the second investigation. Due to the difficulty of distinguishing inactive ovaries from the surrounding tissue, however, a histological investigation would have been necessary to verify the identified structures as connective tissue.

Oviduct

The oviduct lies in proximity along the side of the ovary and appears as a winded structure of medium echogenicity. In four captive females (Z004, Z007, Z014, Z030) local unilateral or bilateral enlargements of the oviduct were identified. By carefully scanning these oblong structures, clear, echo low liquid was detected within the oviduct lumen. Therefore, these enlargements were identified as hydrosalpinx. In the two females with bilateral dilatations, a single enlargement in the right and left oviduct lumen was visible, in the other two cases two dilatations were situated next to each other in one oviduct lumen (Table 3.2). The overall average oviduct enlargement per female was

6.9 ± 1.0 mm ($N = 4$), with minimum and maximum diameters of dilatations of 4.0 mm and 10.1 mm, respectively (Table 3.2). Three of the four females with dilatations (Z007, Z014, Z030) were in a reproductively inactive state and one (Z004) in a reproductively active state. The bilateral hydrosalpinx found in Z030 during the first investigation was not present during follow up examinations one and two years later.

Table 3.2 Localisation, number and maximum diameter (in mm) of enlargements of the oviduct lumen (hydrosalpinx) found in captive females. Number in brackets in the ID-column represent the first examination of Z030.

ID	Age (years)	Right			Left			Average diameter
		Number	Diameter		Number	Diameter		
Z004	4.0	1	6.2	-	1	10.1	-	8.2
Z007	6.5	0	-	-	2	6.3	5.9	6.1
Z014	4.5	1	7.5	-	1	6.8	-	7.2
Z030 (1)	5.0	2	8.3	4.0	0	-	-	6.2

Adnexes

One paraovarian cyst was found in one free-ranging female (W007) and in none of the captive females. The paraovarian cyst was clearly round shaped, had a distinct echodense wall and was filled with a clear liquid. The cyst was 6.0 mm in diameter. W007 was pregnant at the time of examination.

3.3.5 Asymmetric reproductive aging

The six captive females in a reproductively inactive state were significantly older (4.5 – 7.0 years) than the three captive females in a reproductively active state (2.0 – 4.0 years) (Mann-Whitney-U-Test, $U = 0$, $N_1=6$, $N_2=3$, $p=0.019$). Furthermore, genital pathologies in these nine females were found only in animals older than or at 4 years of age ($N=7$), 86% of those were reproductively inactive and 57% were reproductively inactive and nulliparous (Table 3.3).

Table 3.3 Reproductive state and history, and genital pathologies of captive females at time of investigation. Numbers in brackets in the ID-column represent the first or second examination.

ID	Age (years)	Reproductive state	Reproductive history	Genital pathology
Z002	5.0	inactive	unknown	connective tissue
Z003	2.0	active	nulliparous	none
Z004	4.0	active	nulliparous	hydrosalpinx
Z007	6.5	inactive	one litter	hydrosalpinx
Z014	4.5	inactive	nulliparous	hydrosalpinx
Z025	2.5	active	nulliparous	none
Z028 (2)	7.0	inactive	nulliparous	hydrometra
Z029 (2)	7.0	inactive	nulliparous	connective tissue
Z030 (1)	5.0	inactive	nulliparous	hydrosalpinx

In free-ranging females one paraovarian cyst was found in one female, while in seven captive females four times a hydrosalpinx was diagnosed, twice enlarged areas of connecting tissue on the ovaries and once a hydrometra (Table 3.3). Captive females had significantly more often a hydrosalpinx than free-ranging females (Fisher's exact test, $p=0.033$, $N=19$), while for the other genital pathologies no differences between captive and free-ranging females were found (Fischer's exact test, $p=0.47$ for hydrometra, $p=0.21$ for enlarged areas of connective tissue on the ovaries, $p=1.0$ for paraovarian cysts, $N=19$ for all tests). Overall, pathologies of the reproductive organs were found more often in captive ($N=7$) than in free-ranging female ($N=1$) (Fisher's exact test, $p=0.005$, $N=19$). The age structure of investigated free-ranging and captive females was similar (Fisher-Test, $p=1.0$, $N=19$, see Chapter 2), thus the results were not the consequence of a simple age difference between the two populations.

3.4 Discussion

3.4.1 Stress levels in captive and free-ranging cheetah females

Former studies suggested that unnatural or stressful husbandry conditions might lead to anoestrous periods in captive cheetahs (Brown et al. 1996; Jurke et al. 1997; Wielebnowski et al. 2002). It has been shown that stress induced elevation of glucocorticoids can impair fertility and reproductive function (Greenberg & Wingfield 1987, Rivier & Rivest 1991). Terio et al. (2004) found (after dissection) a larger adrenal corticomedullary ratio in cheetahs kept in North American zoos than in free-ranging Namibian cheetahs, indicating a higher production of glucocorticoids by the adrenal cortex and thus a higher level of stress in captive cheetahs. By using ultrasonography in the current study, no difference in adrenal gland size between females kept on Namibian farmland and free-ranging females was found, suggesting that (1) the more natural husbandry conditions on Namibian farmland are less stressful for the animals than the husbandry conditions in North American zoos, and (2) ovarian inactivity in females kept on Namibian farmland seems unlikely to be caused by stress. The findings on adrenal gland sizes are consistent with studies on faecal corticoid concentrations, showing that free-ranging Namibian cheetahs have similar corticoid concentrations as females kept on Namibian farmland but substantially lower ones than cheetahs in North American zoos (Terio et al. 2003; 2004).

An interesting finding of this study was that in captive females the distinction of medulla and cortex in adrenal glands was clearer and cortices were echo lower than in free-ranging females. It is at present not known whether a clear ultrasonographical separation of medulla and cortex reflects a higher activity in corticosteroid production. If so, then the corticosteroid production might be too moderate to lead to an enlarged adrenal gland measurable with the ultrasound technique.

Studies investigating the relationship between faecal corticoid concentrations and ovarian hormone pattern in cheetah females yield inconsistent results. Whereas Jurke et al. (1997) found higher faecal corticoid concentrations in two females that cycled irregularly than in five females that cycled regularly, Wielebnowski et al. (2002) found no relationship between faecal corticoid patterns and ovarian hormone pattern in eight females kept first in pairs of different compositions. Most females kept in pairs exhibited anoestrous periods and more agonistic than affiliative behaviours (Wielebnowski et al. 2002). After pair separation, all females resumed rapidly oestrous cyclicity, suggesting that pair housing is socially stressful for this solitary living species (Wielebnowski et al. 2002). The lack in relationship between faecal corticoid patterns and ovarian hormone pattern was suggested to be due to variation in individual ability to cope with social stress, and social stress not being adequately reflected in faecal glucocorticoids. This has been previously

suggested by Saltzman et al. (1998) and Wingfield & Ramenofsky (1999), arguing that the hypothalamo-pituitary-adrenal function is modulated by multiple behavioural and physiological variables, thus an inconsistent relationship between social stress and adrenal activity might not be surprising. If so, then social stress due to unnatural group housing of females in this study (Appendix 2) might also not be detectable in terms of enlargement of adrenal glands, but still be a reason for the inactivation of reproduction of captive females. Regular agonistic behaviour was observed in one captive group of three reproductively inactive females (Z028, Z029, Z030) used in this study (Beijen 2004), suggesting that social tension was manifested in this group.

Whether other potential “stress” factors in captivity on Namibian farmland such as exposure to people (particularly tourists), other large predators kept in adjacent enclosures, permanent visual and olfactory contact to males and restricted ranging possibilities are relevant but are not reflected in an enlargement of adrenal gland sizes is currently not known. Thus, stress not detectable by enlargement of adrenal gland size might still contribute to the reproductive inactivity of some investigated females.

3.4.2 Anoestrous periods as a consequence of endogenous rhythms

Terio et al. (2003) suggested that reproductive cycling in cheetah females kept under nearly natural conditions on Namibian farmland is triggered by an endogenous circannual rhythm that is linked to the intensity of the forthcoming rainy season. They also suggested that females exhibiting anoestrous periods in North American zoos have lost their natural rhythm under captive conditions, resulting in non-synchronous and non-seasonal anoestrous periods. How cheetahs might assess the intensity of the forthcoming rainy season is unclear. Since the results of this study were inconsistent with any of the predictions of this hypothesis, it is unlikely that reproductive inactivity is triggered by environmental conditions.

3.4.3 Asymmetric reproductive aging

Alternatively, a model of ‘asymmetric reproductive aging’ as described in captive white rhinoceros and elephants (Hildebrandt et al. 2000, Hermes et al. 2004; 2006) might be applicable to cheetahs. Under natural conditions, the reproductive cycle of a female is dominated by periods of pregnancy and lactation whereas oestrous is a rare event. White rhinoceros and elephants kept in zoos without experiencing pregnancy and lactation have absent or irregular oestrous periods and reduced fertility (Brown 2000; Hildebrandt et al. 2000; Hermes et al. 2004). Such reproductively impaired females often also exhibit leiomyoma of the reproductive tract and/or cystic hyperplasia (Montali

et al. 1997; Hermes et al. 2001). It was suggested that the frequent oestrous cycle activity or ovarian activity with absent ovulation, corresponding to long-term and extreme fluctuation of sex steroids in non-reproducing females, can lead to a faster utilisation of the follicular stock, irregular cycling activity and a progressive impairment of reproductive capacities (Hermes et al. 2004). This model of asymmetric reproductive aging was suggested to be applicable also for other species in captivity that experience poor reproductive success. As a possible mechanism to prevent or delay such an asymmetric reproductive aging process during long non-reproductive periods, pregnancies early on in reproductive life were proposed to be crucial (Hermes et al. 2004).

Irregular and anoestrous periods, reduced fertility, reproductive pathologies, genital tract lesions and permanent inactivity have also been found in numerous studies on captive cheetahs (Munson 1993; Wildt et al. 1993; Brown et al. 1996; Terio et al. 2003; Walzer et al. 2003). Munson (1993) diagnosed a depletion of germ cells in five captive females older than 12 years and Wildt et al. (1993) found degenerate and fibrous ovaries in two females older than 9 years. While it was not reported whether these females had ever reproduced, a 17 year old nulliparous female was reported to show uterine fibroleiomyoma (Walzer et al. 2003). Another reported alteration found also in younger females was cystic endometrial hyperplasia (Munson 1993). None of the females with cystic endometrial hyperplasia had produced cubs, despite having stayed together with males (Munson 1993). This alteration was clearly suggested to be the consequence rather than the cause for the lack of reproduction of the females. All of these observations are consistent with the model of asymmetric reproductive aging.

In this study, four cases of hydrosalpinges, two cases of enlarged connective tissue areas on the ovaries and one case of hydrometra were identified in six captive females, all being 4 years of age or older. The majority of these alterations were found in reproductively inactive and nulliparous females. The formation of dense connective tissue in the ovarian stroma is known from human menopausal ovaries (Motta et al. 2002) and might be expected also in captive cheetah females with ovaries that experienced an asymmetric aging process. Hydrosalpinx is mainly the consequence of a bacterial infection but also of serous overproduction or failing clearance (Hildebrandt, pers.comm.). Whether these lesions might also originate from a mechanical obstruction as a consequence of asymmetric aging of the reproductive organs remains to be determined. Similarly, a hydrometra has not been previously described as a pathology related to the asymmetric aging. However, it is possible that these genital pathologies are related to the reproductive inactivity of the captive females, since free-ranging females all of which were reproductively active, had fewer genital pathologies. The only genital lesion found in a free-ranging female was a paraovarian cyst, a common finding in other feline species (Munson 1993). Such cysts were histologically identified as dilatations of the

remains of the Wolffian duct (*ductus paramesonephricus*) and assumed not to influence a female's reproductive capacity (Munson 1993). This is also consistent with the finding that the free-ranging female with the paraovarian cyst was pregnant during the examination.

A rough estimate indicated that a reproducing free-ranging cheetah female with an average longevity of 6.2 years or a maximum longevity of 12.0 years experiences 44 and 56 oestrous cycles, respectively, during her reproductive lifespan. These are 2.4 and 4.2 times, respectively, fewer cycles than a non-reproducing captive female would experience if she cycled throughout her life. Such a female would have reached at the age of 3.8 and 4.4 years, respectively, the same number of oestrous cycles as a reproducing free-ranging female experiences throughout an average or maximum lifespan. When assuming a yearly anoestrous period of 3.2 months (see methods) for a captive female, then a reproducing free-ranging female with an average longevity of 6.2 years or a maximum longevity of 12.0 years would cycle 1.8 and 3.1 times, respectively, less frequently than a captive female.

If, however, the anoestrous periods change with age in their length and frequency and the constant cycling and high fluctuation of sex steroids from the beginning of the reproductive life leads to faster utilisation of the follicular stock, irregular cycling activity and genital pathologies then a non-reproducing captive female might not cycle many more times than a reproducing free-ranging female. Instead, she might experience a shortened reproductive lifespan with irregular anoestrous periods and reproductive lesions. The model of asymmetric reproductive aging might then also explain (1) the reported difficulties in inducing ovulation in cheetahs with treatments of ovulation-inducing gonadotropine (Howard et al. 1997), and (2) the low percentage (31%) of 45 female cheetahs with access to mating partners in North American zoos that had ever reproduced (Wildt et al. 1993).

If anoestrous periods or irregular oestrous cycles are a consequence of a lack of reproduction in captivity, then its occurrence should be found in females kept either in enclosures under nearly natural conditions (Terio et al. 2003, this study) or in North American zoos (Brown et al. 1996) but not in free-ranging females – which is the case.

Reproductive success in captivity has clearly increased over time with improved management practices (Wielebnowski 1996). Since successful reproduction was suggested to be important for the reproductive health of females (Hermes et al. 2004), it would be useful to know whether the occurrence of alterations or pathologies of the reproductive organs has generally decreased during this time. Furthermore, valuable information would be derived from a retrospective study investigating whether reproductively inactive females usually were older and/or nulliparous females. If the model of asymmetric aging is applicable to cheetahs this has clear management

implications for breeding facilities. The number of cycles and reproductive pathologies could be diminished by focussing on producing early pregnancies and allowing mothers to nurse their cubs until weaning age. This study suggests that nulliparous captive cheetah females might start to be reproductively impaired by an age of about 4 years. It thus might be advantageous to realize the first pregnancies before this age.

Earlier studies have emphasised the importance of a natural social environment for breeding females, i.e. keeping females of high priority for mating in solitary conditions or separating them from conspecifics before mating, and presenting mates only for short periods (Bertschinger et al. 1985, Wielebnowski et al. 2002). Such management implementations were proposed to increase normal ovarian activity and decrease social stress. This study additionally promotes early reproduction and natural raising of cubs to prolong reproductive lifetime of and decrease genital pathologies in captive cheetah females.

References

Beijen, M. 2004. Dominance hierarchies within cheetah groups held in captivity on Namibia farmland. Diploma thesis, Leibniz-Institute for Zoo and Wildlife Research & The University of Leiden.

Berry, H., Forge, O., Marker-Kraus, L., Nowell, K. & Seal, U.S. 1996. Life history Vortex modelling: working group report - cheetahs in Namibia. Namibian cheetah population and habitat viability assessment. IUCN Species Survival Commission, Otjiwarongo, Namibia.

Brown, J.L. 2000. Reproductive endocrine monitoring of elephants: an essential tool for assisting captive management. *Zoo Biology*, 19, 347-367.

Brown, J.L., Wildt, D.E., Wielebnowski, N., Goodrowe, K.L., Graham, L.H., Wells, S. & Howard, J.G. 1996. Reproductive activity in captive female cheetahs (*Acinonyx jubatus*) assessed by faecal steroids. *Journal of Reproduction & Fertility*, 106, 337-346.

Caro, T.M. 1994. Cheetahs of the Serengeti plains: group living in an asocial species. The University of Chicago Press, Chicago.

Engel, J. 1997. Signifikante Schule der schlichten Statistik. Fürth: Filander Verlag GmbH.

Fritsch, R. & Gerwing, M. 1993. Sonographie bei Hund und Katze. Stuttgart: Ferdinand Enke Verlag.

Hermes,R., Hildebrandt,T.B. & Göritz,F. 2004. Reproductive problems directly attributable to long-term captivity-asymmetric reproductive aging. *Animal Reproduction Science*, 82-83, 49-60.

Hermes,R., Hildebrandt,T.B., Schwarzenberger,F., Walzer,C., Fritsch,G. & Göritz,F. 2001. Reproductive disorders in white rhinoceros and the value of ultrasonographic assessment. *Recent research on elephants and rhinos* (Ed. by Schwammer, H. M., Foose, T. J., Fouraker, M., and Olson, D.), p 314. Abstracts of the International Elephant and Rhino Research Symposium, Zoologischer Garten, Vienna, Austria.

Hermes,R., Hildebrandt,T.B., Walzer,C., Göritz,F., Patton,M.L., Silinski,S., Anderson,M.J., Wibbelt,G., Tomasova,K. & Schwarzenberger,F. 2006. The effect of long non-reproductive periods on the genital health in captive female white rhinoceros (*Ceratotherium simum simum*, *C.s. cottoni*). *Theriogenology*, 65, 1492-1515.

Hildebrandt,T.B. & Göritz,F. 1998. Use of ultrasonography in zoo animals. (Ed. by M.E.&R.E.Fowler), pp. 44-54. Philadelphia: WB Saunders.

Hildebrandt,T.B., Göritz,F., Pratt,N.C., Brown,J.L., Montali,R.J., Schmitt,D.L., Fritsch,G. & Hermes,R. 2000. Ultrasonography of the urogenital tract in elephants (*Loxodonta africana* and *Elephas maximus*): an important tool for assessing female reproductive function. *Zoo Biology*, 19, 321-332.

Hinrichs,K. 1997. Irregularities of the estrous cycle and ovulation in mares. In: *Current therapy in large animal theriogenology* (Ed. by R.S.Youngquist), pp. 166-171. London, UK: W.B.Saunders Company.

Howard,J.G., Roth,T.L., Byers,A.P., Swanson,W.F. & Wildt,D.E. 1997. Sensitivity to exogenous gonadotropins for ovulation induction and laparoscopic artificial insemination in the cheetah and clouded leopard. *Biology of Reproduction*, 56, 1059-1068.

Jurke,M.H., Czekala,N.M., Lindburg,D.G. & Millard,S.E. 1997. Fecal corticoid metabolite measurement in the cheetah (*Acinonyx jubatus*). *Zoo Biology*, 16, 133-147.

Kelly,M.J., Laurenson,M.K., Fitzgibbon,C.D., Collins,D.A., Durant,S.M., Frame,G.W., Bertram B.C.R. & Caro,T.M. 1998. Demography of the Serengeti cheetah (*Acinonyx jubatus*) population: The first 25 years. *Journal of Zoology*, 244, 473-488.

Laurenson,M.K. 1994. High juvenile mortality in cheetahs (*Acinonyx jubatus*) and its consequences for maternal care. *Journal of Zoology*, 234, 387-408.

Laurenson,M.K., Caro,T.M. & Borner,M. 1992. Female cheetah reproduction. *National Geographic Research & Exploration.*, 8, 64-75.

Marker,L., Dickman,A.J., Jeo,R.M., Mills,M.G.L. & Macdonald,D.W. 2003. Demography of the Namibian cheetah. *Biological Conservation*, 114, 413-425.

- Mendelsohn,J., Jarvis,A., Roberts,C. & Robertson,T. 2002. Atlas of Namibia - a portrait of the land and its people. David Philip Publishers, Cape Town, RSA.
- Montali,R.J., Hildebrandt,T.B., Göritz,F., Hermes,R., Ippen,R. & Ramsay,E. 1997. Ultrasonography and pathology of genital tract leiomyomas in captive Asian elephants: Implications for reproductive soundness. *Verhandlungsberichte über die Erkrankungen der Zootiere*, 38, 253-258.
- Motta,P.M., Heyn,R. & Makabe,S. 2002. Three-dimensional microanatomical dynamics of the ovary in proreproductive aged women. *Fertility and Sterility*, 78, 360-370.
- Munson,L. 1993. Diseases of captive cheetahs (*Acinonyx jubatus*): Results of the Cheetah Research Council pathology survey, 1989-1992. *Zoo Biology*, 12, 105-124.
- Rideout,A.B., Gause,G.E., Benirschke,K. & Lasley,B.L. 1985. Stress-induced adrenal changes and their relation to reproductive failure in captive nine-banded armadillos (*Dasypus novemcinctus*). *Zoo Biology*, 4, 129-137.
- Saltzman,W., Schultz-Darken,N.J., Wegner,F.H., Wittwer,D.J. & Abbott,D.H. 1998. Suppression of cortisol levels in subordinate female marmosets: reproductive and social contributions. *Hormones & Behaviour*, 33, 58-74.
- Shapiro,S.S. & Wilk,M.B. 2005. An analysis of variance test for normality (complete samples). *Biometrika*, 52, 591-611.
- Sokal,R.R. & Rohlf,F.J. 1981. *Biometry*. 2nd ed., Freeman, San Francisco.
- Sopelak,V.M. & Butcher,R.L. 1982. Decreased amount of ovarian tissue and maternal age affect embryonic development in old rats. *Biology of Reproduction*, 27, 449-455.
- Suleman,M.A., Wango,E., Farah,I.O. & Hau,J. 2000. Adrenal cortex and stomach lesions associated with stress in wild male African green monkeys (*Cercopithecus aethiops*) in the post-capture period. *Journal of Medical Primatology*, 29, 338-342.
- Terio,K.A., Marker,L. & Munson,L. 2004. Evidence for chronic stress in captive but not free-ranging cheetahs (*Acinonyx jubatus*) based on adrenal morphology and function. *Journal of Wildlife Diseases*, 40, 259-266.
- Terio,K.A., Marker,L., Overstrom,E.W. & Brown,J.L. 2003. Analysis of ovarian and adrenal activity in Namibian cheetahs. *South African Journal of Wildlife Research*, 33, 71-78.
- Walzer,C., Kubber-Heiss,A. & Bauder,B. 2003 Spontaneous uterine fibroleiomyoma in a captive cheetah. *Journal of Veterinary Medicine - Series A*, 50, 363-365.
- Wielebnowski,N. 1996. Reassessing the relationship between juvenile mortality and genetic monomorphism in captive cheetahs. *Zoo Biology*, 15, 353- 369.
- Wielebnowski,N. & Brown,J.L. 1998. Behavioral correlates of physiological estrus in cheetahs. *Zoo Biology*, 17, 193-209.

Wielebnowski,N.C., Ziegler,K., Wildt,D.E., Lukas,J. & Brown,J.L. 2002. Impact of social management on reproductive, adrenal and behavioural activity in the cheetah (*Acinonyx jubatus*). *Animal Conservation*, 5, 291-301.

Wildt,D.E., Brown,J.L., Bush,M., Barone,M.A., Cooper,K.A., Grisham,J. & Howard,J.G. 1993. Reproductive status of cheetahs (*Acinonyx jubatus*) in North American zoos: The benefits of physiological surveys for strategic planning. *Zoo Biology*, 12, 45-80.

Wingfield,J.C. & Ramenofsky,M. 1999. Hormones and behavioural ecology of stress. In: *Stress physiology in animals*, pp. 1-51. Sheffield,UK: Sheffield Academic Press.