

# Cardiovascular magnetic resonance findings in non-hospitalized paediatric patients after recovery from COVID-19

Franziska Seidel<sup>1,2\*</sup> , Titus Kuehne<sup>2,3</sup>, Sebastian Kelle<sup>2,4</sup>, Patrick Doeblin<sup>4</sup>, Victoria Zieschang<sup>4</sup>, Carsten Tschoepe<sup>2,5</sup>, Nadya Al-Wakeel-Marquard<sup>1,2,3†</sup> and Sarah Nordmeyer<sup>1,3†</sup>

<sup>1</sup>Department of Congenital Heart Disease and Pediatric Cardiology, German Heart Center Berlin, Augustenburger Platz 1, Berlin, 13353, Germany; <sup>2</sup>DZHK (German Centre for Cardiovascular Research), partner site Berlin, Berlin, Germany; <sup>3</sup>Institute of Computer-assisted Cardiovascular Medicine, Charité – Universitätsmedizin Berlin, corporate member of Freie Universität Berlin, Humboldt-Universität zu Berlin, and Berlin Institute of Health, Berlin, Germany; <sup>4</sup>Department of Internal Medicine and Cardiology, German Heart Center Berlin, Berlin, Germany; and <sup>5</sup>Medical Department, Division of Cardiology, Charité – Universitätsmedizin Berlin, corporate member of Freie Universität Berlin, Humboldt-Universität zu Berlin, and Berlin Institute of Health, Berlin, Germany

## Abstract

**Aims** Our study aimed to investigate the cardiac involvement with sensitive tissue characterization in non-hospitalized children with coronavirus disease 2019 (COVID-19) infection using cardiovascular magnetic resonance (CMR) imaging.

**Methods and results** We prospectively enrolled children who recovered from mildly symptomatic COVID-19 infection between November 2020 and January 2021. Patients underwent CMR at 1.5 T (Achieva, Philips Healthcare, Best, the Netherlands) including cine images, native T1 and T2 mapping. Healthy children and paediatric patients with biopsy-proven myocarditis served as control groups. We performed CMR in 18 children with a median (25th–75th percentile) age of 12 (10–15) years, 38 (24–47) days after positive PCR test, and compared them with 7 healthy controls [15 (10–19) years] and 9 patients with myocarditis [10 (4–16) years]. The COVID-19 patients reported no cardiac symptoms. None of the COVID-19 patients showed CMR findings consistent with a myocarditis. Three patients (17%) from the COVID-19 cohort presented with minimal pericardial effusion. CMR parameters of COVID-19 patients, including volumetric and strain values as well as T1 and T2 times, were not significantly different from healthy controls, but from myocarditis patients. These had significantly reduced left ventricular (LV) ejection fraction ( $P = 0.035$ ), LV global longitudinal strain, and left atrial strain values as well as elevated native T1 values compared with COVID-19 patients ( $P < 0.001$ , respectively).

**Conclusions** There was no evidence of myocardial inflammation, fibrosis, or functional cardiac impairment in the studied cohort of children recently. CMR findings were comparable with those of healthy controls. Pericardial effusion suggests a mild pericarditis in a small subgroup. This is pointing to a minor clinical relevance of myocardial involvement in children after mildly symptomatic COVID-19 infections.

**Keywords** COVID-19; Paediatric; Myocarditis; Inflammation; CMR

Received: 18 June 2021; Revised: 1 October 2021; Accepted: 5 October 2021

\*Correspondence to: Dr. Franziska Seidel, Department of Congenital Heart Disease and Pediatric Cardiology, German Heart Center Berlin, Augustenburger Platz 1, 13353 Berlin, Germany. Tel: +49 30 4593 2800; Fax: +49 30 4593 2900. Email: seidel@dhzb.de

†These authors contributed equally.

## Background

The severe acute respiratory syndrome coronavirus 2 (SARS-CoV-2) has led to the global pandemic of coronavirus disease 2019 (COVID-19). Recent cardiovascular magnetic resonance (CMR) studies have reported frequent cardiac injury in adults with COVID-19 infections.<sup>1–3</sup> Data in

paediatric patients are limited and mainly related to the occurrence of multisystem inflammatory syndrome in children associated with SARS-CoV-2 infection (MISc), which presents mostly with a severe onset.<sup>4–7</sup> The prevalence and clinical role of cardiac injury in paediatric COVID-19 patients without systemic inflammation is not well studied using sensitive methods for myocardial tissue characteriza-

Table 1 Demographics and cardiovascular magnetic resonance findings

	COVID-19 n = 18	Healthy n = 7	Myocarditis n = 9	P-value COVID-19 vs. healthy	P-value COVID-19 vs. myocarditis	P-value Myocarditis vs. healthy
<b>Demographics</b>						
Age, years	12 (10;15)	15 (10;19)	10 (4;16)	0.270	0.463	0.174
Sex male, n (%)	6 (33)	5 (71)	4 (44)	0.683	0.177	0.358
BSA, m <sup>2</sup>	1 (1;2)	2 (1;2)	1 (1;2)	0.657	0.900	0.758
Time symptom onset—CMR, days	42.0 (37.8–54.0)	n.a.	7.0 (5.0–16.0)	n.a.	0.013	n.a.
<b>Functional parameters</b>						
LV EDVi, mL/m <sup>2</sup>	79 (75;87)	80 (78;86)	93 (77;172)	0.574	0.053	0.091
LV ESVi, mL/m <sup>2</sup>	32 (27;34)	31 (28;38)	48 (28;139)	0.574	0.053	0.142
LV EF, %	62 (58;67)	62 (54;67)	50 (19;64)	0.534	<b>0.035</b>	0.142
RV EDVi, mL/m <sup>2</sup>	79 (75;83)	80 (71;86)	69 (58;99)	0.929	0.375	0.606
RV ESVi, mL/m <sup>2</sup>	29 (25;34)	28 (27;37)	30 (21;41)	0.836	0.900	0.758
RV EF, %	63 (60;67)	64 (58;67)	58 (49;67)	0.883	0.322	0.351
Pericardial effusion, n (%)	3 (17)	0 (0)	6 (67)	0.534	<b>0.026</b>	<b>0.011</b>
Wall motion abnormalities, n (%)	0 (0)	0 (0)	9 (100)	n.a.	< <b>0.001</b>	< <b>0.001</b>
<b>Strain values</b>						
Endocardial LV longitudinal strain, %	-27 (-30;-25)	-25 (-31;-22)	-21 (-24;-12)	0.220	< <b>0.001</b>	0.054
Myocardial LV longitudinal strain, %	-26 (-28;-25)	-25 (-29;-22)	-20 (-21;-12)	0.297	< <b>0.001</b>	<b>0.014</b>
Endocardial LV circumferential strain, %	-30 (-34;-29)	-31 (-34;-25)	-21 (-32;-9)	0.495	0.059	0.252
Myocardial LV circumferential strain, %	-24 (-25;-22)	-22 (-23;-19)	-13 (-22;-8)	<b>0.034</b>	< <b>0.001</b>	0.055
Endocardial RV longitudinal strain, %	-27 (-30;-23)	-25 (-29;-22)	-26 (-30;-10)	0.458	0.461	0.867
Myocardial RV longitudinal strain, %	-27 (-29;-22)	-25 (-28;-22)	-24 (-29;-11)	0.615	0.397	0.779
LA strain, %	46 (41;62)	48 (37;56)	32 (-22;-36)	1.000	< <b>0.001</b>	<b>0.002</b>
RA strain, %	43 (33;53)	37 (24;57)	47 (-17;-54); n = 7	0.458	0.574	0.805
<b>Mapping</b>						
T1 native, ms	1034 (1005;1062)	1050 (1031;1071)	1151 (1090;1238)	0.357	< <b>0.001</b>	<b>0.001</b>
T2, ms	48 (47;50)	n = 0	56 (49;70); n = 4	n.a.	0.118	n.a.

BSA, body surface area; CMR, cardiovascular magnetic resonance imaging; EDVi, indexed end-diastolic volume; EF, ejection fraction; ESVi, indexed end-systolic volume; LA, left atrial; LV, left ventricular; n.a., not applicable; RA, right atrial; RV, right ventricular. Values are given as n (%) or median with median (25th–75th percentile). For comparison of the continuous variables, Mann–Whitney U-test was used, and for categorical variables, Pearson's  $\chi^2$  or Fisher's test were used; a P-value < 0.05 was considered significant. For incomplete set of data, n represents the number of subjects included in the analysis. Bold P-values represent significant P-values.

tion. One study on thoracic imaging reports a myocarditis in only one of 91 children with COVID-19 infections.<sup>8</sup>

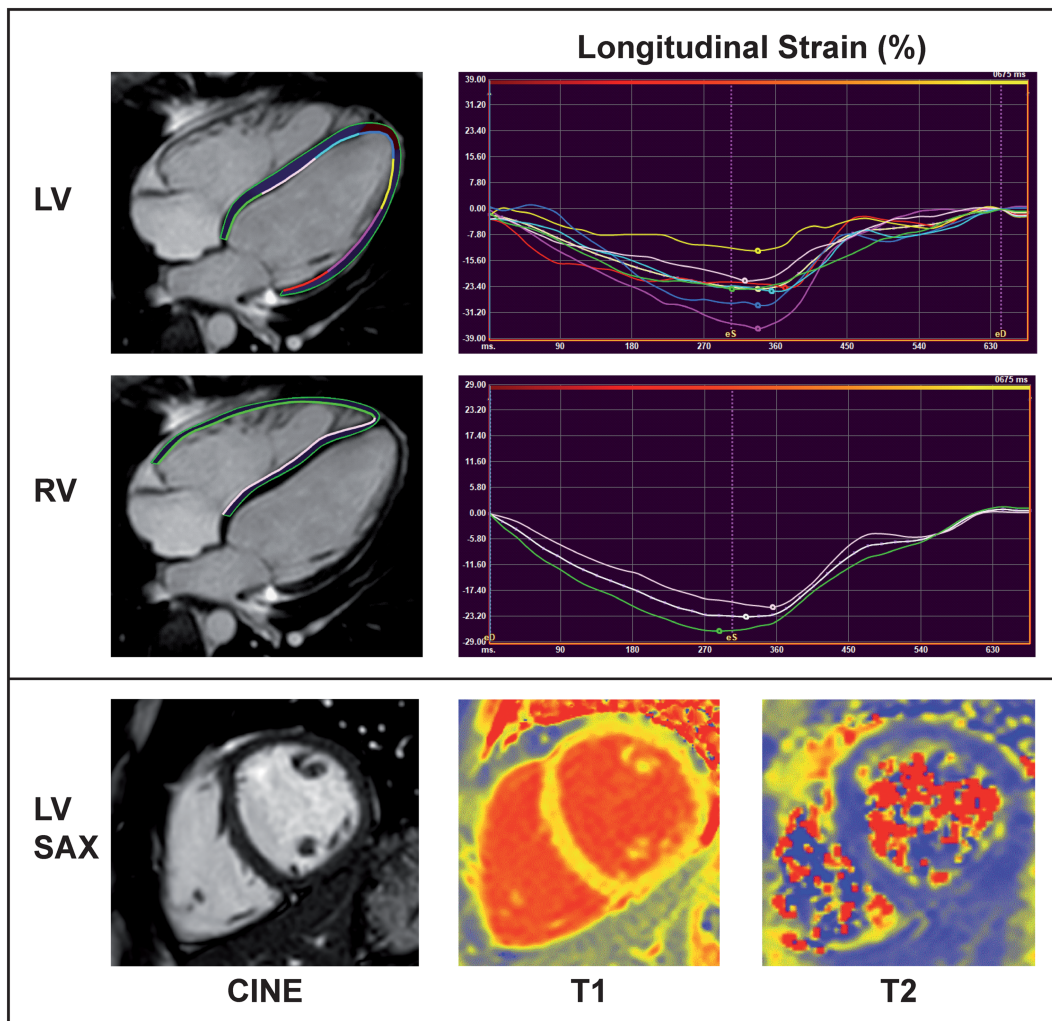
## Aims

Our study aimed to investigate the presence of cardiac involvement including functional impairment, myocardial inflammation, and fibrosis using CMR without contrast-enhancement and sensitive CMR methods for myocardial tissue characterization in non-hospitalized children with COVID-19.

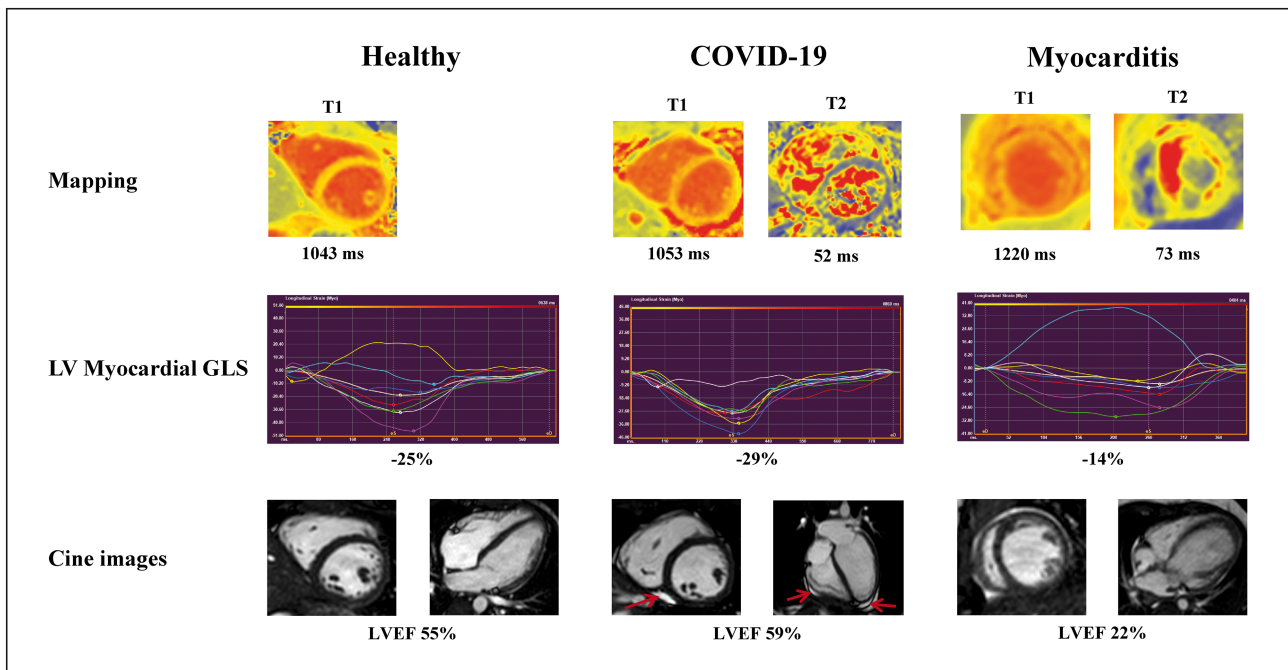
## Methods

We prospectively enrolled children who recovered from mildly symptomatic COVID-19 infection between November 2020 and January 2021. All infections were diagnosed by positive polymerase chain reaction (PCR). The presence of MISC was an exclusion criterion. No cardiac diagnostics have been performed before enrolment in relation to the COVID-19 infection. Patients underwent CMR at 1.5 T (Achieva, Philips Healthcare, Best, the Netherlands) including cine images, native T1 and T2 mapping. Images were analysed using commercially available software, mapping parameters by QMap RE Version 2.0, and global longitudinal strain (GLS) by QStrain (Medis Medical Imaging Systems, Leiden, the Netherlands).

**Figure 1** CMR findings in a 12-year-old girl 2 months after positive SARS-CoV2 PCR. Upper row: Cine image of the left ventricle (LV) in radial long-axis (LAX) view with corresponding endomyocardial longitudinal strain (LS) in %. LV ejection fraction was 60%, LV LS  $-25\%$ . Middle row: Cine image of the right ventricle (RV) in LAX view with corresponding endomyocardial LS of  $-24\%$ . Lower row: Cine image of the LV in short-axis (SAX) view with corresponding T1 and T2 maps (T1, 1001 ms; T2, 47 ms).



**Figure 2** CMR findings between healthy controls, COVID-19, and myocarditis patients. The upper row presents T1 (left) and T2 maps of a healthy control (left), a COVID-19 (middle), and a myocarditis patient (right). Corresponding, the middle row shows left ventricular (LV) myocardial global longitudinal strain (GLS) values and the lower row cine images in short-axis (left) and four-chamber (4CH) views. The red arrows point towards the mild pericardial effusion in the COVID-19 patient.



In addition, children who underwent cardiomyopathy screening due to a family history of cardiomyopathy, but without any pathologies and pathogenic cardiomyopathy variants were included as controls.<sup>9</sup> Paediatric patients with biopsy and CMR proven myocarditis enrolled within the MYKKE Registry served as a reference with myocardial inflammation.<sup>10</sup> Parents or legal guardians gave written informed consent. Ethical approval was obtained from the responsible ethics committee.

## Results

We performed CMR in 18 children recovered from COVID-19 infection with a median (25th–75th percentile) age of 12 (10–15) years, 38 (24–47) days after positive PCR test, and compared them with 7 healthy controls [15 (10–19) years] and 9 patients with myocarditis [10 (4–16) years]. CMR was performed significantly earlier after symptom onset in the myocarditis group compared with COVID-19 patients ( $P = 0.013$ , *Table 1*). Demographics and CMR parameters are presented in *Table 1*. The COVID-19 patients reported mild symptoms including fatigue (61%), fever (56%), respiratory symptoms (50%), loss of smell and taste (44%), gastrointestinal symptoms (39%), and dyspnoea (17%).

None of the COVID-19 patients showed CMR findings consistent with a myocarditis based on the updated Lake Louise Criteria. Findings of a 12-year-old female COVID-19 patient are displayed in *Figure 1*. Three patients (17%) from the COVID-19 cohort presented with minimal pericardial effusion. CMR parameters of COVID-19 patients, including volumetric and strain values as well as T1 and T2 times, were not significantly different from healthy controls. In contrast, myocarditis patients more often showed pericardial effusion (67% vs. 17%;  $P = 0.026$ ) and wall motion abnormalities ( $P < 0.001$ ) and had significantly reduced left ventricular (LV) ejection fraction ( $P = 0.035$ ), LV GLS, and left atrial strain as well as elevated native T1 values compared with COVID-19 patients ( $P < 0.001$ , respectively; *Table 1*). See *Figure 2* as an overview of different CMR findings between healthy controls, the COVID-19, and the myocarditis cohort.

## Conclusions

In the studied cohort of children, recently recovered from mildly symptomatic COVID-19 infections, no evidence of myocardial inflammation, fibrosis, or functional cardiac impairment was found. CMR findings were comparable with those of healthy controls but clearly different to findings in myocarditis patients. With a longer time difference between



symptom onset and CMR in COVID-19 patients, a cardiac involvement in the first 4 weeks cannot be ruled out. Especially myocardial oedema might have not been detected in our study more than 1 month after symptom onset.<sup>3</sup> In children, the cardiac involvement after mild COVID-19 infections was lower compared with studies in adults with mild or moderate COVID-19 infections, where high frequencies of CMR manifestations (30–78%) as ongoing myocardial inflammation, positive late gadolinium enhancement, and LV dysfunction were reported.<sup>1,2</sup> The minimal pericardial effusion might be a sign of mild pericarditis in this paediatric cohort, which could also be detected in adults studies in wide range of 0–58% within 10 studies.<sup>11</sup> High rates of cardiac involvement and myocardial inflammation (30–50%) were also seen young patients with MISc.<sup>4,5</sup> This difference to our cohort might be explained by the postulated cytokine storm, which seems not that distinctive in mild COVID-19 disease courses.<sup>12</sup>

Despite the small sample size, our study in paediatric patients is pointing to a minor clinical relevance of myocardial involvement in children after mildly symptomatic COVID-19 infections without need for hospitalization or signs of sys-

temic inflammation. A routinely diagnostic workup by CMR seems not to be necessary in this patient group.<sup>13</sup>

## Acknowledgements

We thank Alireza Khasheei for helping with CMR examinations.

Open Access funding enabled and organized by Projekt DEAL.

## Conflict of interest

None declared.

## Funding

This study was not supported by any grant.

## References

- Puntmann VO, Carerj ML, Wieters I, Fahim M, Arendt C, Hoffmann J, Shchendrygina A, Escher F, Vasa-Nicotera M, Zeiher AM, Vehrshchild M, Nagel E. Outcomes of cardiovascular magnetic resonance imaging in patients recently recovered from coronavirus disease 2019 (COVID-19). *JAMA Cardiol* 2020; **5**: 1265–1273.
- Wang H, Li R, Zhou Z, Jiang H, Yan Z, Tao X, Li H, Xu L. Cardiac involvement in COVID-19 patients: mid-term follow up by cardiovascular magnetic resonance. *J Cardiovasc Magn Reson* 2021; **23**: 14.
- Chen BH, Shi NN, Wu CW, An DA, Shi YX, Wesemann LD, Hu J, Xu JR, Shan F, Wu LM. Early cardiac involvement in patients with acute COVID-19 infection identified by multiparametric cardiovascular magnetic resonance imaging. *Eur Heart J Cardiovasc Imaging* 2021; **22**: 844–851.
- Valverde I, Singh Y, Sanchez-de-Toledo J, Theocharis P, Chikermane A, Di Filippo S, di Filippo S, Kucińska B, Mannarino S, Tamariz-Martel A, Gutierrez-Larraya F, Soda G, Vandekerckhove K, Gonzalez-Barlatay F, McMahon CJ, Marcora S, Napoleone CP, Duong P, Tuo G, Deri A, Nepali G, Ilina M, Ciliberti P, Miller O, Iriart X, Hubrechts J, Kuipers IM, Sousa AR, Donti A, Sharpe A, Reinhardt Z, Cairello F, de Wolf D, Vieira M, Lazea C, Gran F, Medrano-Lopez C, Ortiz-Garrido A, Vukomanovic V, Brent BE, Milanese O, Dewals W, Manso B, Valsangiacomo-Buchel E, Francisco A, Seghaye MC, Loecx I, Rodriguez-Gonzalez M, ReyGarcía SM, Ziesenitz VC, Bordin G, Doros G, Grangl G, Fadl SU, Perminow KV, Centeno F, Pinto F, Niemelä J, Kanthimathinathan HK, Randanne PC, Niszczota C, Zuccotti GV, Gordillo IL, Obeyasekhara M, Armstrong C, Butler K, Ciuffreda M, Villar AM, Pappula N, Caorsi R, Singh D, Durairaj S, McLeod K, Calcagni G, Quizad Y, Gewillig M, Kuijpers TW, Ataide R, Fabi M, Bharucha T, Abbas K, Magrass SA, Wong J, Iacob D, Balcells J, GilVillanueva N, Cuenca-Peiro V, Cerovi I, Sarfatt A, Zaout M, Sanchez-Valderrabanos E, Kelly-Geyer J, Diogo F, Cajgfinger N, Françoise M, Rueda-Nuñez F, Gorenflo M, Grison A, Mihailov D, Koestenberger M, Alcalde C, Trigo C, Arola A, Hanseus K. Acute cardiovascular manifestations in 286 children with multisystem inflammatory syndrome associated with COVID-19 infection in Europe. *Circulation* 2021; **143**: 21–32.
- Theocharis P, Wong J, Pushparajah K, Mathur SK, Simpson JM, Pascall E, Cleary A, Stewart K, Adhvaryu K, Savis A, Kabir SR, Uy MP, Heard H, Peacock K, Miller O. Multimodality cardiac evaluation in children and young adults with multisystem inflammation associated with COVID-19. *eur heart J cardiovasc. Imaging*. 2020; **22**: 896–903.
- Huang L, Zhao P, Tang D, Zhu T, Han R, Zhan C, Liu W, Zeng H, Tao Q, Xia L. Cardiac involvement in patients recovered from COVID-2019 identified using magnetic resonance imaging. *JACC Cardiovasc Imaging* 2020; **13**: 2330–2339.
- Bautista-Rodriguez C, Sanchez-de-Toledo J, Clark BC, Herberg J, Bajolle F, Randanne PC, Salas-Mera D, Foldvari S, Chowdhury D, Munoz R, Bianco F, Singh Y, Levin M, Bonnet D, Fraisse A. Multi-system inflammatory syndrome in children: an international survey. *Pediatrics* 2021; **147**: e2020024554.
- Caro-Dominguez P, Shelmerdine SC, Toso S, Secinaro A, Toma P, Damasio MB, Navallas M, Riaza-Martin L, Gomez-Pastrana D, Ghadimi Mahani M, Desoky SM, Ugas Charcape CF, Almanza-Aranda J, Ucar ME, Lovrenski J, Gorkem SB, Alexopoulou E, Ciet P, van Schuppen J, Ducou le Pointe H, Goo HW, Kellenberger CJ, Raissaki M, Owens CM, Hirsch FW, van Rijn RR, Collaborators of the European Society of Paediatric Radiology Cardiothoracic Task Force, Arthurs O, Banner M, Bianco F, Borazjani R, Born M, Buschl J, Lacalamita MC, de Luca F, di Maurizio M, Finazzo F, Jablonka K, Jenkins M, Kamali K, Maccioni L, Marín C, León MM, Morel B, Goitia IM, Napolitano M, Pan NY, Pourbkhityaran E, Prüfer F, Rossi E, Ruzal-Shapiro C, Dashti AS, Sangri Pinto AG, Seiler C, Gorone MSP. Thoracic imaging of coronavirus disease 2019 (COVID-19) in children: a series of 91 cases. *Pediatr Radiol* 2020; **50**: 1354–1368.

9. Al-Wakeel-Marquard N, Seidel F, Herbst C, Kuhnisch J, Kuehne T, Berger F, al-Wakeel-Marquard N, Seidel F, Herbst C, Kuhnisch J, Kuehne T, Berger F, Klaassen S, Messroghli DR. Diffuse myocardial fibrosis by T1 mapping is associated with heart failure in pediatric primary dilated cardiomyopathy. *Int J Cardiol* 2021; **333**: 219–225.
10. Messroghli DR, Pickardt T, Fischer M, Opgen-Rhein B, Papakostas K, Bocker D, Böcker D, Jakob A, Khalil M, Mueller GC, Schmidt F, Kaestner M, Udink ten Cate F, Wagner R, Ruf B, Kiski D, Wiegand G, Degener F, Bauer UMM, Friede T, Schubert S, MYKKE Consortium. Toward evidence-based diagnosis of myocarditis in children and adolescents: rationale, design, and first baseline data of MYKKE, a multicenter registry and study platform. *Am Heart J* 2017; **187**: 133–144.
11. Shafiabadi Hassani N, Talakoob H, Karim H, Mozafari Bazargany MH, Rastad H. Cardiac magnetic resonance imaging findings in 2954 COVID-19 adult survivors: a comprehensive systematic review. *J Magn Reson Imaging* 2021. <https://doi.org/10.1002/jmri.27852>
12. Imazio M, Klingel K, Kindermann I, Brucato A, De Rosa FG, Adler Y, de Rosa FG, Adler Y, de Ferrari GM. COVID-19 pandemic and troponin: indirect myocardial injury, myocardial inflammation or myocarditis? *Heart* 2020; **106**: 1127–1131.
13. Doebelin P, Kelle S. Going after COVID-19 myocarditis. *Eur Heart J Cardiovasc Imaging* 2021; **22**: 852–854.