

**Aus der Klinik für Dermatologie, Venerologie und Allergologie.  
Center of Experimental and Applied Cutaneous Physiology (CCP)  
der Medizinischen Fakultät Charité – Universitätsmedizin Berlin**

**DISSERTATION**

**Morphometric description of pig ear hair follicles and their  
similarity to human hair follicles  
(Morphometrische Beschreibung von Schweineohr-Haarfollikeln  
und ihrer Ähnlichkeit mit menschlichen Haarfollikeln)**

**zur Erlangung des akademischen Grades  
Doctor medicinae (Dr. med.)**

**vorgelegt der Medizinischen Fakultät  
Charité – Universitätsmedizin Berlin**

**von**

**Alexandra Zambrano  
aus Caracas, Venezuela**

**Datum der Promotion: 25 November 2022**

# Inhaltsverzeichnis

<b>PREFACE</b>	<b>1</b>
<b>ZUSAMMENFASSUNG</b>	<b>2</b>
<b>ABSTRACT</b>	<b>3</b>
<b>1. INTRODUCTION</b>	<b>4</b>
<b>2. MATERIALS AND METHODS</b>	<b>8</b>
2.1 PORCINE EAR SKIN AND PREPARATION OF SKIN BIOPSY	8
2.2 MORPHOMETRIC PARAMETERS OF THE HAIR FOLLICLES	9
2.3 STATISTICAL ANALYSIS	10
<b>3. RESULTS</b>	<b>11</b>
3.1 LENGTH OF THE HAIR FOLLICLE AND INFUNDIBULUM	11
3.2 LENGTH AND POSITION OF THE BULGE REGION	13
3.3 THE HAIR FOLLICLE OPENING	13
3.4 EPITHELIUM IN THE INFUNDIBULUM	13
3.5 EPIDERMIS INTERFOLLICULAR	13
3.6 COMPARING THE HAIR FOLLICLE MORPHOLOGY OF HUMAN SKIN AND PORCINE EAR SKIN	13
<b>4. DISCUSSION AND CONCLUSION</b>	<b>15</b>
<b>REFERENCES</b>	<b>18</b>
<b>EIDESSTÄTTLICHE VERSICHERUNG</b>	<b>22</b>
<b>ANTEILSERKLÄRUNG</b>	<b>23</b>
<b>AUSZUG AUS DER JOURNAL SUMMARY LIST (ISI WEB OF KNOWLEDGESM)</b>	<b>24</b>
<b>DRUCKEXEMPLAR DER PUBLIKATION</b>	<b>26</b>
<b>LEBENS LAUF</b>	<b>35</b>
<b>PUBLIKATIONSLISTE</b>	<b>37</b>
<b>DANKSAGUNG</b>	<b>38</b>

## **Preface**

The results of the present work have already been published in:

1. Zambrano A, Klein AL, Patzelt A. Analysis of the morphometric parameters of pig ear hair follicles. *Skin Research and Technology*. 2021; 00:1-9.

## Zusammenfassung

Zur Durchführung von Hautpenetrationsstudien wird häufig Schweineohrhaut als Ersatz oder Modell für die menschliche Haut verwendet, da Schweineohrhaut und menschliche Haut hinsichtlich Aufbaus und Struktur eine große Ähnlichkeit aufweisen, wie verschiedene Studien belegen.

Seit einigen Jahren ist der Haarfollikel als Penetrationsweg von topisch applizierten Substanzen in die Haut zunehmend in das Zentrum des Interesses gerückt und ebenso die Frage, ob die Haarfollikel der Schweineohrhaut hier ebenfalls als gutes Modell geeignet sind. Bislang wurden die morphometrischen Eigenschaften von Schweinehaarfollikeln jedoch noch nicht umfassend untersucht.

Das Ziel der vorliegenden Dissertation war daher die morphometrische Bestimmung der Haarfollikel im dorsalen Bereich der Schweineohrhaut, um einen Vergleich mit Haarfollikeln der menschlichen Haut durchzuführen und in naher Zukunft die Ergebnisse von Hautpenetrationsstudien an Schweineohrhaut auf den Menschen übertragen können.

Zur Durchführung dieser Studie wurde der dorsale Bereich des Schweineohrs verwendet. Insgesamt wurden 10 Schweineohren analysiert und insgesamt 345 Follikel untersucht. Hierzu wurden Kryoschnitte angefertigt. Durch Mikroskopie wurden insgesamt 7 Parameter für jeden Haarfollikel bestimmt: die Gesamtlänge des Follikels, der Durchmesser der Eintrittsöffnung des Follikels, die Länge des Infundibulums, die Dicke des Follikelepithels im Bereich des Infundibulums, die Position und Länge der Wulstregion sowie die Dicke der interfollikulären Epidermis.

Die Auswertung der morphometrischen Daten ergab, dass die Follikeldichte des Schweineohrs je nach untersuchtem Bereich variiert, wobei der kraniale Bereich des Ohrs die höchste Follikeldichte aufwies. Ferner wurde unter anderem festgestellt, dass die Haarfollikel eine mittlere Länge von  $1458 \pm 286 \mu\text{m}$  aufwiesen und dass die Länge des Infundibulums direkt proportional zur Gesamtlänge des Follikels war.

Beim Vergleich der erhobenen Daten mit morphometrischen Haarfollikeldaten humaner Haut aus früheren Studien konnte gezeigt werden, dass eine große Ähnlichkeit zwischen den Haarfollikeln von Menschen und Schweinen besteht. Daher scheint die Schweineohrhaut ein geeignetes Modell für die menschliche Haut in dermalen und insbesondere follikulären Penetrationsstudien zu sein.

## **Abstract**

Porcine ear skin is frequently used as a substitute or model for human skin in skin penetration studies due to the significant similarity that both present and several studies verified.

For several years, the hair follicle has moved to focus of interest as a penetration pathway of topically applied substances. Moreover, it is important if the hair follicle of porcine ear skin represents a good model for human hair follicles. Unfortunately, there are no comprehensive morphometric data of porcine hair follicles available.

The aim of this thesis was the morphometric description of the hair follicles of the dorsal pig ear with the purpose to compare the data with the available data of human hair follicles and to be able to extrapolate the results of the cutaneous penetration studies carried out on the skin of the pig ear to humans in the near future.

The investigations were performed on the back zone of porcine ears. In total, 10 pig ears and cryosection of 345 hair follicles were analyzed. Through microscopy, 7 parameters were studied for each hair follicle: the length of the follicle, the orifice of the follicle, the length of the infundibulum, the thickness of the follicular epithelium in the infundibular area, the position and length of the bulge region as well the thickness of the interfollicular epidermis.

The analysis of the results revealed that the follicular density in the skin of the pig ear varied according to the studied area, whereby the cranial area offered the highest follicular density.

Moreover, it was determined that the hair follicles had an average length of approximately  $1458 \pm 286 \mu\text{m}$  and that the length of the infundibulum varied directly proportional to the total length of the follicle.

Comparing the present data to morphometric data obtained in previous studies performed in human skin, it was observed that there was a remarkable similarity between the hair follicles of humans and pigs. Considering these results, it can be postulated that pig ear skin is a suitable human skin model in cutaneous and follicular penetration studies.

# 1. Introduction

Skin penetration studies, in general, are of significant importance in dermatological research. They help to understand to what extent topically applied substances are absorbed by the skin and become bioavailable. Hereby, their efficacy and efficiency can be assessed.

In the last years, the focus of interest of skin research moved, among other things, to the different available penetration pathways through the skin, which are the intercellular, the intracellular and the follicular penetration pathway (1). The intercellular penetration pathway along the corneocytes' lipid layers is broadly considered the most effective one for topically applied substances (2). On the other hand, the follicular penetration pathway provides different structures, such as epidermal stem cells or dendritic cells, which are of therapeutic interest, especially for immune and regenerative therapy. (3). In figure 1, the different routes of skin penetration are schematically represented.

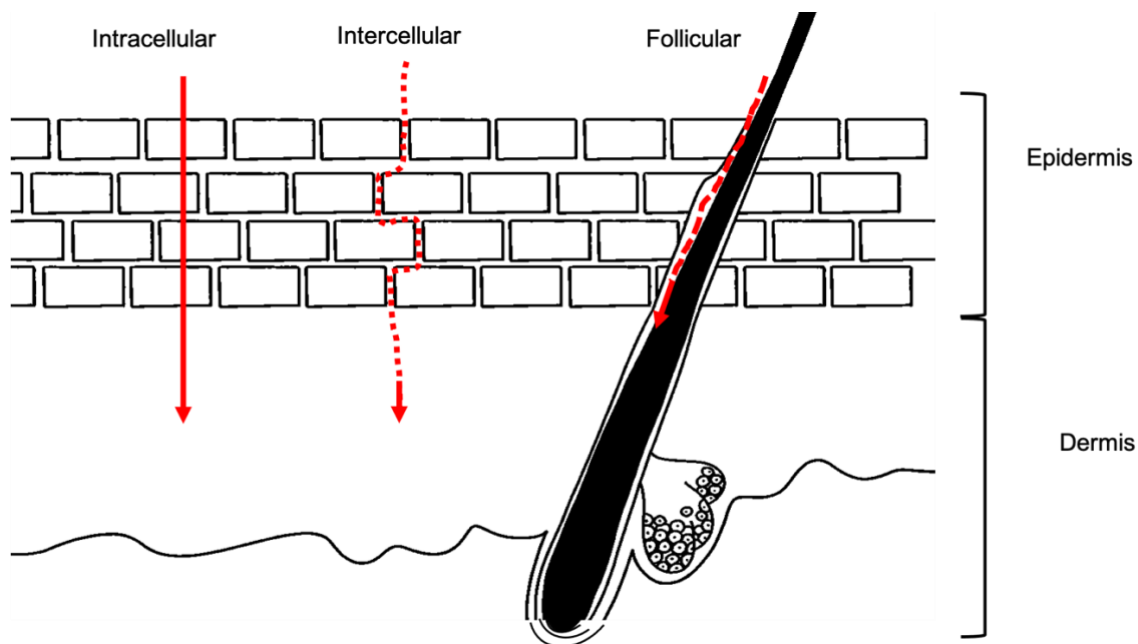


Figure 1: Illustration of skin penetration pathways.

The hair follicle as penetration pathway has received increasing attention, although the establishment of appropriate skin models to investigate follicular penetration is still a significant challenge mainly due to the structure of skin and skin appendages (4).

The architecture of the skin is relatively complex, consisting of different layers. The stratum corneum is the outermost layer of the skin and acts as the leading skin barrier. Topically applied substances must pass through this thick layer to penetrate the skin and take effect. However, in the areas where the hair follicles are located, this layer is discontinued, facilitating the rapid absorption of different substances in these areas (5).

At birth, about 5 million hair follicles are distributed over the human body. Genes establish the precise spacing and distribution of the follicles expressed early in the morphogenesis of the follicles (6). Although hairs vary in length, diameter, color, and cross-sectional shape between different ethnic groups, unique individuals, and various body parts, they always have the same structure (7). Anatomically, the hair follicle can be divided into two sections (upper and lower). The main structures of the hair follicle are the hair bulb, the hair shaft, the bulge region, the isthmus, the infundibulum, the sebaceous gland, and the exertion of erector pili muscle (8) (see Figure 2).

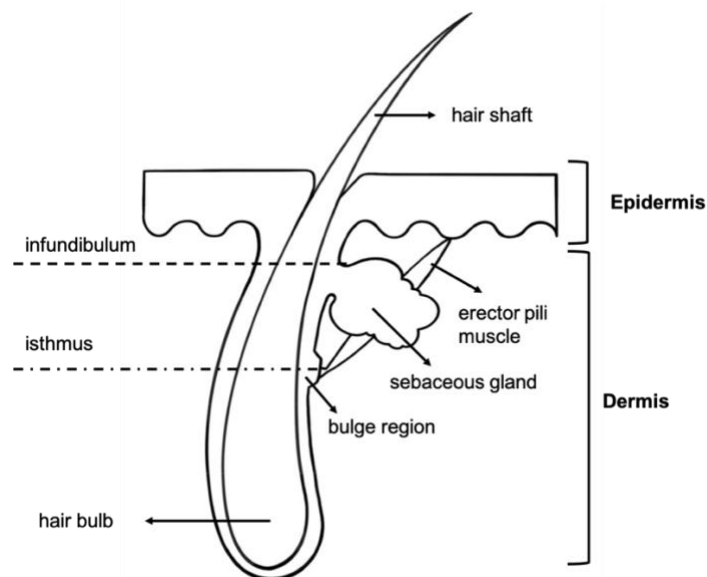


Figure 2. Schematic representation of the hair follicle and skin.

The function of hair follicles is diverse. Hair follicles act as a sensory organ by detecting mechanical stimuli from the skin's surface. Any hair movement activates neuroreceptors in the follicle, relaying crucial sensory information to the nervous system. Moreover, hair follicles have an important immunologic guard role for the skin. The outer-root sheath of the hair follicle contains melanocytes, Langerhans cells and Merkel cells. All these cells repopulate the epidermis after injury; the Langerhans cells at the follicle's opening detect surface pathogens and activate the immune system (6).

It has been observed that not all topically applied substances can overcome the skin barrier, which can be, among other reasons, an effect of size. Most particulate substances, especially when they exceed a particular diameter (e.g., >40 nm), are not able to penetrate through an intact stratum corneum (9). Previous studies have shown that hair follicles play an essential role concerning penetration, storage, and transport (10). Several studies suggest that particles that mainly remain on the skin surface or in the upper layers of the stratum corneum after the topical application was almost removed after one day. On the contrary, particles that entered the hair follicles could be stored there for more than ten days (10). In other study performed it could be observed that after two weeks of the last topical application of itraconazole, there were relevant itraconazole concentrations in the hair follicles, which indicates that hair follicles act as a long-term reservoir for formulations applied locally to the skin (11).

Moreover, it has been observed in several studies that in skin areas with a higher number of hair follicles, the absorption of certain substances was increased. In contrast, in skin areas with lower numbers of hair follicles, penetration was decreased (12). Wahlberg demonstrated, e.g. that the absorption of NaCl and Mercury chloride was greater in hairy guinea pig skin than in the non-hairy region of their skin (13). Likewise, another study showed that the percutaneous absorption was considerably lower in scarred skin as compared to normal hairy skin (14, 15). Skin models utilized for these kinds of studies were different. Whereas Maibach et al. performed their investigations on various skin sites, which physiologically provided different hair follicle densities (16), other authors carried out their experiments on newborn animals and adult animals as hair follicles were developed later in some species. However, all skin models and studies suggested the participation of the hair follicles in the penetration process (17).

Due to the close contact of the blood capillaries with the hair follicle, different substances are rapidly transported to the bloodstream as soon as they have penetrated the hair follicle (18,19). This phenomenon was observed in a study carried out with caffeine, where it was shown that after a topical application, caffeine became bioavailable already after 5 minutes when the hair follicles were available for penetration, but only after 20 minutes when hair follicles were excluded from the penetration process (20).

In analogy, it has been proposed that nanoparticles could be picked up by dendritic cells, transported to local lymph nodes and could induce immune responses (10) as a dense network of dendritic cells likewise surrounds them.

Lately, there has been increasing interest in nano-sized drug delivery systems in the medical field. Thanks to the small size of these particles, nanocarriers can optimize site-specific delivery and therapeutic effect of drugs that suffer from poor solubility, poor stability, and unwanted toxicity. By generating a better tissue distribution and pharmacokinetics, the side effects of some substances can be reduced (21).



Another fact to consider when talking about skin penetration via hair follicles is the size of the substances used. Since it has been shown in certain studies that medium-sized particles (643 and 646 nm) penetrate deeper into porcine hair follicles than particles of smaller (122 nm) or larger size (860 nm) (22). Likewise, it has been shown that by varying the particle size, specific areas can be reached selectively within the hair follicle (22). Similar studies performed on human hair follicles revealed results that support this hypothesis. A study conducted by Toll et al. (23) revealed that particles with a size of approximately 750 nm penetrated deeply into the terminal follicles of the human scalp, whereas larger particles (3000-6000 nm) rather accumulated and remained in the opening holes of the follicles (23).

Likewise, nanoparticulate substances penetrate much more deeply into the hair follicles after massage than the non-particle substances. Regarding the storage of the substance, it has been shown that the nanoparticles are stored in the hair follicles for up to 10 days, while the non-particle substances were only detected in the follicle up to 4 days after their application (24).

In other studies, it was demonstrated that metallic particles smaller than 10 nm managed to penetrate the skin through the lipid matrix of the stratum corneum and the holes of the hair follicle, reaching the deepest layers of the stratum corneum and, in some cases, the highest strata of the viable epidermis (25). In 2007, another group carried out a penetration study with sunscreen formulation containing TiO<sub>2</sub> nanoparticles and reported that the particles sized about 20 nm penetrated to a depth of 400 µm in the hair follicles of human and porcine skin (26).

Another interesting fact regarding the penetration of substances is the application of massages on the skin. It has been shown that the follicular penetration depth of particulate substances can be increased by massaging the skin (27). An *ex vivo* study demonstrated that particles with an optimal size of approximately 300–600 nm penetrated more deeply into hair follicles after massage application. They suggested that the moving hair acts as a geared pump, transporting the nanoparticles deeply into the hair follicles (up to 1500 µm deep). It is thought that a combination of a nano-based delivery system with a physical technique such as massage will lead to enhanced treatments (28, 29). In a study carried out in 2007 by Lekki et al., it was likewise observed that particles penetrated deeper due to the gentle rubbing and mechanical movement of skin and hair during the topical application of sunscreens (26).

Based on the observation that hair follicles play an essential role in the skin penetration process, many *in vivo* and *ex vivo* studies have been carried out, analyzing human hair follicle morphology and the skin penetration process (30,31).

However, human skin often is not easily available either due to regulatory or practical reasons. In addition, its use generates specific problems, especially if the follicular penetration process is studied (32). More specifically, immediately after excision, human skin shrinks significantly as the elastic fibers around the follicle contract. This again induces an occlusion of the hair follicle. Consequently, the follicular reservoir decreases by approximately 90% (29).

To find an appropriate animal skin model to extrapolate skin penetration studies in humans, several studies have recently been carried out comparing hair follicle morphology and skin structure in different animal species (33). Based on these studies, it has been concluded that the morphology and skin penetration via the hair follicles in mammalian animals generally tends to vary according to the animal species and the area of the body studied (33). In this study, dog, cat, and rabbit skin provided the most significant differences compared to human skin (33). Another study showed that pig skin and its hair follicle structure, especially in the ear area, presented a considerable similarity to human skin (32). An additional advantage of porcine ear skin is that it is readily available. Moreover, the skin can remain fixed in the ear cartilage during experiments and therefore does not contract after excision (34,17).

Different studies in which the penetration process of multiple substances in human skin and pig skin were compared showed that the skin penetration process in both species is similar (35,36). This led to the conclusion that pig ear skin can be considered a suitable *ex vivo* model for conducting skin penetration studies, especially when the follicular penetration route is investigated (12).

Regrettably, a complete morphological description of hair follicles was so far only available for human skin (37) but not for pig ear skin. Therefore, the present thesis aimed to investigate in detail the morphology of the hair follicle of the pig ear skin. It was hypothesized that pig ear hair follicle morphometry is comparable to that of human hair follicles. This would allow to use pig ears as an *ex vivo* skin model for performing follicular and skin penetration studies and extrapolate data from pig skin experiments to human skin.

## **2. Materials and Methods**

### ***2.1 Porcine ear skin and preparation of skin biopsy***

The morphometric characteristics of porcine ear hair follicles were analyzed in 345 hair follicles of 10 porcine ears. Seven different parameters were determined. The skin of the ear was selected because it is very frequently used as an *ex vivo* skin model to analyze the skin penetration of products applied on the skin.

The skin of the back area of ten pig ears was studied (German domestic pig, half-year-old). This skin was supplied by a local butcher (Gerald Nusche, Rind- und Schweineschlachtereij, Königs Wusterhausen, Germany). The investigations were carried out on the same day of slaughtering. Tap water was used to clean the ears, and excess moisture was removed with paper towels.

Each ear was zoned into three areas:

- Area A: the caudal end of the ear
- Area B: the region between A and C
- Area C: the cranial end of the ear

In the middle part of each ear, two segments of 6 cm<sup>2</sup> were demarcated. Then, 8 squared biopsies of 5 mm x 5mm were taken from each of these segments. Figure number 3 represents the division of the ear.

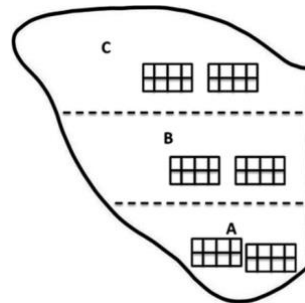


Figure 3. Division of the porcine ear. The figure is taken from Zambrano et al. (38)

Subsequently, the samples were frozen through direct contact with liquid nitrogen and then preserved at  $-20^{\circ}$  Celsius. By means of a cryotome, the skin biopsies were cut perpendicular to the skin surface in sections of  $7\ \mu\text{m}$  thickness (Microm cryo-Star HM 560, MICROM International GmbH, Walldorf, Germany). Then, the sections were placed on glass slides. At least 10 hair follicles were analyzed for each area (A, B, and C) of each porcine ear skin sample.

## ***2.2 Morphometric parameters of the hair follicles***

In order to carry out a broad description of the morphology of porcine hair follicles, seven parameters were defined for each hair follicle: length of the hair follicle [1], length of the infundibulum [2], length and position of the bulge region [3 and 4], diameter of the opening of the hair follicle [5], the thickness of the hair follicle epithelium in the area of the infundibulum [6] and thickness of the interfollicular epidermis [7] as indicated in Figure 4. In addition, the follicular density of each biopsy was determined macroscopically.

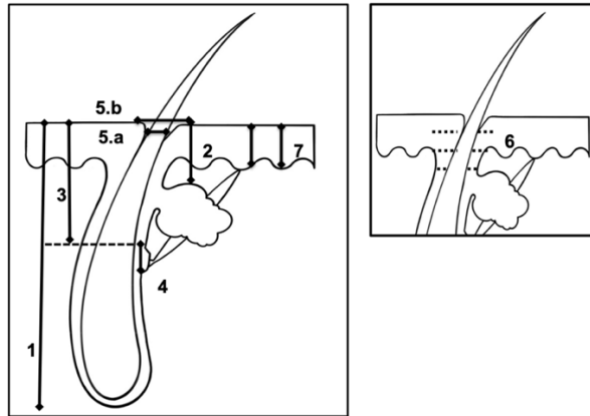


Figure 4. Parameters evaluated in porcine hair follicles. Total length of the hair follicle [1], length of the infundibulum [2], position and the length of the bulge region [3,4], hair follicle opening at the skin surface [5.a without epithelium, 5.b with epithelium], the thickness of the hair follicle epithelium in the area of the infundibulum: upper, middle and lower part at the entrance of the sebaceous gland [6] and thickness of the interfollicular epidermis with intervals of 150 and 200  $\mu\text{m}$  from the opening of the follicle [7].

As the longitudinal sections of the hair follicles did not show the complete hair follicle in all cases, it was not possible to evaluate all parameters in each hair follicle, so for each area and parameter, a different number of follicles was determined:

- Hair follicle density: 203 hair follicles.
- Length of the hair follicle: 259 hair follicles.
- The hair follicle opening: 305 hair follicles.
- Length of the Infundibulum: 172 hair follicles.
- Epithelium in the infundibulum: 152 hair follicles.
- Length of the bulge region: 76 hair follicles.
- Position of the bulge region: 67 hair follicles.
- Epidermis interfollicular: 284 hair follicles.

For the measurements, a microscope (BX60, Olympus, Münster, Germany) was used in combination with the software Olympus “cellSens Dimension” (Olympus, Münster, Germany)

### **2.3 statistical analysis**

For the statistical analysis of the results, the Microsoft® Excel 2007 and SPSS 24 IBM (IBM Corporation; Endicott, NY, US) statistic software was used. To find out the differences between the various parameters in the three ear zones (A, B and C), the descriptive statistical analysis Wilcoxon test was used. The significance level was set at  $p < 0.05$ .

### 3. Results

The density of the hair follicles was determined macroscopically. The number of hair follicles varied in the different skin areas. In area A  $8 \pm 2$  follicles per  $\text{cm}^2$  were detected, in area B  $10 \pm 1$  follicles per  $\text{cm}^2$  and in area C  $15 \pm 3$  follicles per  $\text{cm}^2$ . Therefore, the cranial region of the ear provided the highest number of hair follicles per  $\text{cm}^2$ .

#### **3.1 Length of the hair follicle and infundibulum**

All 345 follicles were studied. However, only in 259 follicles, the total hair length was determined because all longitudinal sections did not show the entire hair follicle. Following standard histological parameters, the follicles were classified according to their growth phases in anagen or telogen.

Because the total length of the hair follicles in pig ear skin is very inhomogeneous, the evaluated follicles were also classified into two groups depending on their whole length ( $<2000 \mu\text{m}$  and  $> 2000 \mu\text{m}$ ) as classification systems such as terminal and vellus hair follicles are not established in pig skin.

Out of a total of  $n= 259$  follicles studied, 64% ( $n= 166$ ) were in the anagen growth phase, and most of them ( $n=104$ ) provided a length of less than  $2000 \mu\text{m}$  (MV  $1458 \pm 296 \mu\text{m}$ ). Only 36% of the follicles were in the telogen phase ( $n = 93$ ), and 92% of the hair follicles in the telogen phase were shorter than  $2000 \mu\text{m}$  (MV  $1240 \pm 359 \mu\text{m}$ ). No significant statistical difference was obtained between the 3 areas of the ear for this parameter ( $p > 0.05$ ). All results are summarized in Table 1.

The length of the infundibulum was determined in 172 follicles and varied according to the growth stage and length of the hair follicle. Anagen hair follicles with a total length of  $<2000 \mu\text{m}$  had an infundibulum length of  $373 \pm 72 \mu\text{m}$ . Anagen hair follicles with a total length of  $>2000 \mu\text{m}$  had an infundibulum length of  $516 \pm 107 \mu\text{m}$ . Telogen hair follicles with a total length  $<2000 \mu\text{m}$  provided an infundibulum length of  $458 \pm 131 \mu\text{m}$ . Telogen hair follicles with a total length greater than  $2000 \mu\text{m}$  had an infundibulum length of  $516 \pm 107 \mu\text{m}$ .

No significant statistical difference was obtained between the 3 areas of the ear for this parameter ( $p > 0.05$ ). However, the descriptive statistical analysis revealed that there was a significant difference ( $p < 0.05$ ) regarding the infundibulum length between the two groups of hair follicles (longer than  $2000 \mu\text{m}$  and shorter than  $2000 \mu\text{m}$ ). Furthermore, this difference was present in the anagen phase and the telogen phase. The results are summarized in Table 1.

**TABLE 1.** Results were obtained for the total follicular length (LHF) and the infundibulum length (LI). Data are presented as mean  $\pm$  SD. The table is taken from Zambrano et al. 2021. Analysis of the morphometric parameters of pig ear hair follicles.2021 (38)

HF	Anagen (n=166)			Telogen (n=93)		
	LHF ( $\mu\text{m}$ )		LI ( $\mu\text{m}$ )	LHF ( $\mu\text{m}$ )		LI ( $\mu\text{m}$ )
<b>Area A</b>	<b>MV <math>\pm</math></b>	<b>n=</b>	<b>MW <math>\pm</math></b>	<b>MV <math>\pm</math></b>	<b>n=</b>	<b>MV <math>\pm</math></b>
<2000 $\mu\text{m}$	1440 $\pm$ 300	n=37	402 $\pm$ 79	1237 $\pm$ 388	n=27	412 $\pm$ 138
>2000 $\mu\text{m}$	2380 $\pm$ 242	n=21	486 $\pm$ 84	2137 $\pm$ 58	n=3	567 $\pm$ 102
Total	1780 $\pm$ 532	n=58	438 $\pm$ 91	1237 $\pm$ 475	n=30	418 $\pm$ 140
<b>Area B</b>						
<2000 $\mu\text{m}$	1440 $\pm$ 308	n=35	357 $\pm$ 64	1296 $\pm$ 301	n=34	460 $\pm$ 111
>2000 $\mu\text{m}$	2506 $\pm$ 272	n=16	559 $\pm$ 125	2384 $\pm$ 150	n=2	823 $\pm$ 0
Total	1775 $\pm$ 577	n=51	386 $\pm$ 104	1331 $\pm$ 390	n=36	482 $\pm$ 124
<b>Area C</b>						
<2000 $\mu\text{m}$	1498 $\pm$ 274	n=32	355 $\pm$ 58	1313 $\pm$ 373	n=25	512 $\pm$ 140
>2000 $\mu\text{m}$	2416 $\pm$ 290	n=25	536 $\pm$ 115	2163 $\pm$ 68	n=2	698 $\pm$ 51
Total	1901 $\pm$ 536	n=57	446 $\pm$ 129	1376 $\pm$ 423	n=27	518 $\pm$ 140
<b>Total A+B+C &lt;2000 <math>\mu\text{m}</math></b>	1458 $\pm$ 286	63% n=104	373 $\pm$ 72	1240 $\pm$ 359	92% n=86	458 $\pm$ 131
<b>Total A+B+C &gt;2000 <math>\mu\text{m}</math></b>	2427 $\pm$ 275	37% n= 62	516 $\pm$ 107	2215 $\pm$ 144	8% n=7	619 $\pm$ 152
<b>Total A+B+C &lt;2000 + &gt;2000 <math>\mu\text{m}</math></b>	1820 $\pm$ 551	100 % n= 166	426 $\pm$ 111	1314 $\pm$ 432	100 % n= 93	472 $\pm$ 140

### **3.2 Length and Position of the bulge region**

The bulge region of the hair follicle is of great importance because it represents the reservoir of the epidermal stem cells, which are of special interest for regenerative treatments (3). It is situated between the opening of the sebaceous gland and the insertion of the arrector pili muscle (39,40).

In many sections, identifying this structure was difficult. Therefore, the parameters related to this structure were only determined in anagen hair follicles because the increased size of the follicle during this growth phase facilitated its identification.

In 67 follicles, the bulge region was found at a depth of  $881 \pm 208 \mu\text{m}$  from the surface of the skin. Its length was identified in 76 follicles. The mean length of the bulge region was  $272 \pm 36 \mu\text{m}$ . Among the three areas of the ear, there was no statistical significance ( $p > 0.05$ ).

### **3.3 The hair follicle opening**

The size of the follicular orifice was analyzed in 305 hair follicles. The follicular orifices were measured both with ( $326 \pm 58 \mu\text{m}$ ) and without ( $113 \pm 43 \mu\text{m}$ ) integrating the infundibular epithelium. Likewise, no statistical difference was found between the 3 zones of the studied areas ( $p > 0.05$ ).

### **3.4 Epithelium in the infundibulum**

The thickness of the infundibular epithelium was measured in three different regions of the infundibulum as well as at the right and left sides of the infundibulum. In the upper infundibulum, the epithelium was  $59 \pm 11 \mu\text{m}$  thick. In the middle part, it was  $51 \pm 10 \mu\text{m}$  thick, and in the lower part, it was  $46 \pm 11 \mu\text{m}$  thick. Therefore, the thickness of the infundibular epithelium was lower in the deeper hair follicle than in the upper part. No significant differences were found between both sides of the infundibulum and between the 3 different areas of the ear ( $p > 0.05$ ).

### **3.5 Epidermis interfollicular**

The thickness of the interfollicular epidermis was evaluated at a distance of 150 and 200  $\mu\text{m}$  from the hair follicle orifices. The thickness of the epidermis on the right side of the follicular orifice was  $101 \pm 2 \mu\text{m}$  and  $100 \pm 1 \mu\text{m}$ , and on the left side of the follicular orifice, the epidermis was  $101 \pm 2 \mu\text{m}$  and  $100 \pm 0 \mu\text{m}$  thick. There were no differences between the 3 areas of the ear ( $p > 0.05$ ).

### **3.6 Comparing the hair follicle morphology of human skin and porcine ear skin**

As the aim of this thesis was to determine the morphometric characteristics of pig ear hair follicles to enable a comparison of human and porcine hair follicles, the results obtained in the present study were compared with the data obtained from human hair follicles in an earlier study by Vogt et al. (37).

For the comparison of the values between humans and pigs, the data obtained for the parameters "diameter of the opening of the hair follicle", "interfollicular epidermis", and "thickness of the infundibular epithelium" were made without classifying the follicles according to the total length. For the comparison of the parameters "length of the hair follicle", "length of the infundibulum", and "position and length of the bulging region", only the follicles of the anagen phase were considered. The values of both studies are presented in Table 2.

Table 2. Data comparison of human and porcine hair follicles. Values are in  $\mu\text{m}$ , and data are presented as mean  $\pm$  SD. Data from humans from the study of Vogt et al. (37).

	Hair follicles human skin		Hair follicles pig skin
	Terminal hair follicle	Vellus hair follicle	Hair follicle anagen stage
Length of the hair follicle	3864 $\pm$ 605 $\mu\text{m}$	646 $\pm$ 140 $\mu\text{m}$	1458 $\pm$ 296 $\mu\text{m}$ 2427 $\pm$ 275 $\mu\text{m}$
Length of the infundibulum	580 $\pm$ 84 $\mu\text{m}$	225 $\pm$ 34 $\mu\text{m}$	426 $\pm$ 111 $\mu\text{m}$
Position of the bulge region	1191 $\pm$ 23 $\mu\text{m}$	362 $\pm$ 88 $\mu\text{m}$	881 $\pm$ 208 $\mu\text{m}$
Length of the bulge region	240 $\pm$ 52 $\mu\text{m}$	91 $\pm$ 27 $\mu\text{m}$	272 $\pm$ 36 $\mu\text{m}$
Hair follicle opening at skin surface level	172 $\pm$ 70 $\mu\text{m}$	86 $\pm$ 37 $\mu\text{m}$	113 $\pm$ 2 $\mu\text{m}$
Interfollicular epidermis	136 $\pm$ 37 $\mu\text{m}$		101 $\pm$ 2 $\mu\text{m}$



## 4. Discussion and Conclusion

Considering that pig ear skin is frequently used to carry out skin penetration studies, the objective of this work was to describe the morphometry of hair follicles in the dorsal zone of 10 pig ears. A complete description of the morphometry of the follicles was not available before.

One of the parameters evaluated was the number of hair follicles per  $\text{cm}^2$  in different areas of pig ear skin. As a result, it was found that the density of the follicles was different depending on the skin area. The cranial region of each ear provided a higher number of hairs per  $\text{cm}^2$  than the caudal part. The outcome was correlated with those obtained in other studies, where the density of the follicles was also determined. However, the other authors did not specify in their publications in which area of the pig ear the measurements were performed. Depending on the study, the authors reported the existence of 11-25 hair follicles per  $\text{cm}^2$  (12), 11-42 follicles per  $\text{cm}^2$  (41) or 22 follicles per  $\text{cm}^2$  (33). It should be emphasized that macroscopically, the density of the hairs on the margin of the ear is even superior. However, usually, this area of the ear is not applied for penetration studies, as in this region, the skin is not even enough, making handling difficult (42).

Also, in humans, the number of hair follicles usually varies depending on the body site. As skin area with the lowest follicular density, the calf region is known with approximately 14 hair follicles per  $\text{cm}^2$ . On the contrary, a more significant number of follicles can be found in other areas such as the chest area (25 hair follicles /  $\text{cm}^2$ ), in the back (29 hair follicles /  $\text{cm}^2$ ), arms (18-32 hair follicles /  $\text{cm}^2$ ), thigh (17 hair follicles /  $\text{cm}^2$ ), abdomen (70 hair follicles /  $\text{cm}^2$ ). The highest density has been found in the forehead area with an average of 292 follicles /  $\text{cm}^2$  (30, 43). Since most in vivo human skin penetration experiments are performed on the flexor forearm, it can be concluded that porcine ear skin is very suitable as an ex vivo skin model in terms of follicular density.

On the contrary, studies carried out with other animal species skin models are less suitable compared to human skin because they mostly have a higher density of hair follicles per  $\text{cm}^2$ , which is, for example, 367 in dogs, 627 in cats, 1598 in rats, and approx. 1728 in rabbits (33).

Another fact is that pig skin and human skin hair follicles have the same growth phases (12). In a healthy human scalp, the vast majority of hair follicles is in the anagen growth stage (approximately between 80 and 90%), whereas only 10% to 20% are in the final telogen phase (44). The present study revealed that 64% of the total number of hair follicles investigated were in the anagen stage. Only 36% were in the telogen stage, representing another similarity between human and pig skin.

The variation in the growth phase of the hair follicle in pigs has also been observed in other studies. Most of the follicles found in newborn pigs were also in the anagen stage (97%). However, the proportion of follicles in the anagen, catagen and telogen phases

tended to vary according to the age of the pigs; most of the follicles were always in the anagen phase (45).

These results of the anagen rate are interesting because it has been shown in previous studies that only hair follicles in the anagen growth stage are open to follicular penetration (31). Thus, using pig skin as an *ex vivo* model for future skin penetration studies would be a good option since most hair follicles can be found in the anagen phase.

As already described in the introduction, different hair follicle areas are of particular interest for new therapeutic options. By choosing a specific particle size, different areas within the hair follicles can be targeted selectively (46). Therefore, the knowledge about the precise position of the different hair follicle structures is more than essential. Although the structure of human and pig hair follicles is very similar, the position of these structures (such as infundibulum, isthmus, bulge region, bulb region, sebaceous gland and insertion of erector pili muscle) in porcine ear skin has not been determined yet.

As described in the results, the follicles were grouped into two classes, depending on their total length. The length for the anagen hairs of class 1 ( $> 2000 \mu\text{m}$ ) was  $2,427 \pm 275 \mu\text{m}$ , and the length for the anagen hairs of class 2 ( $<2000 \mu\text{m}$ ) was  $1,458 \pm 297 \mu\text{m}$ . Without classification, the average length of the anagen hairs was  $1,820 \pm 551 \mu\text{m}$ . In humans, the total length of terminal hairs in the anagen phase is approx.  $3,000 \mu\text{m}$  (37). Comparing human and pig ear results, it can be stated that both species provide comparable large hair follicles. However, in humans, the length of vellus hair follicles is significantly smaller and accounted for  $646 \pm 140 \mu\text{m}$  (37). Vellus hairs, defined as short, non-pigmented and generally non-medullated hairs, cannot be found in the pig ear (47).

Another parameter studied was the length of the infundibulum, which varied according to the total length of the hair follicle. For example, anagen hair follicles with a length  $<2,000 \mu\text{m}$  provided an infundibulum length of approximately  $373 \pm 72 \mu\text{m}$ , and anagen hair follicles with a length of  $> 2,000 \mu\text{m}$  offered a longer infundibulum, which had a length of  $516 \pm 107 \mu\text{m}$ . The results are in concordance with other studies in porcine skin, in which the approximate length of the infundibulum was around  $500 \mu\text{m}$  (12).

In humans, the infundibulum of the terminal hairs in the anagen phase is approximately  $500 \mu\text{m}$  long, and the length of the infundibulum of vellus hair is  $225 \pm 34 \mu\text{m}$  (37). Comparing the data obtained in pig skin with those of human skin, it can be observed that there is a remarkable similarity in terms of the length of the infundibulum.

Due to the importance of the bulge region as a reservoir of stem cells, which participate in the proliferation and regeneration process of the hair follicles as well as of the epidermis (48), the position and length of this region were determined in the present study. It was obtained that in pig anagen hair follicles, the bulge region was located at  $881 \pm 208 \mu\text{m}$  from the skin surface. In humans, the bulge region is located at a depth

of  $1,191 \pm 23 \mu\text{m}$ , which is quite comparable. Likewise, the data for the length of the bulge region in porcine anagen hair follicles and human hair follicles ( $272 \pm 36 \mu\text{m}$  and  $240 \pm 52 \mu\text{m}$ ) were very good comparable (37).

A phenomenon that draws attention in the present study and that also occurs in human hair follicles is the thickness of the follicular epithelium at the level of the infundibulum. It was demonstrated that the epithelium's thickness continually declined in deeper parts of the hair follicle (12). Data for human and porcine hair follicles were shown to be well comparable (upper part of the hair follicle: human  $65 \mu\text{m}$ , pig:  $59 \mu\text{m}$ ; distal portion of infundibulum: human  $53 \mu\text{m}$ , pig:  $46 \mu\text{m}$ ) (37).

A further parameter for which the similarity between pig and human hair follicles can be appreciated is the follicular orifice on the skin surface. The opening diameter of the follicular orifice in pigs was  $113 \pm 2 \mu\text{m}$ ; other studies also carried out on porcine ears suggest a diameter of  $200 \pm 24 \mu\text{m}$ . In humans, this value usually varies according to the body area evaluated and shows similarity to the pig skin (for example, human scalp  $172 \pm 70 \mu\text{m}$ , forearm approx.  $78 \mu\text{m}$  and against  $66 \mu\text{m}$ ) (33,37,43).

In humans, the thickness of the interfollicular epidermis tends to vary according to the area of the body evaluated. The following values have been described for different regions: buttock  $97 \mu\text{m}$ , shoulder  $81 \mu\text{m}$ , scalp and retroauricular region  $136 \mu\text{m}$ , dorsal forearm  $75 \mu\text{m}$  (37, 49). In the present study, the thickness of the interfollicular epidermis in pig skin was approximately  $100 \mu\text{m}$ , similar result were described in other studies carried out with pig skin, where the epidermis was  $72 \mu\text{m}$  thick (12). Both results are very similar to the data described in humans.

It is interesting to mention that, in general, the thickness of the infundibular epithelium is lower than that of the interfollicular epidermis and that the thickness of the epithelium in the infundibular area decreases in thickness in the lower part of the hair follicle. Therefore, it can be assumed that the barrier properties are continuously reduced in deeper parts of the hair follicles and that percutaneous absorption can be enhanced when the substances reach deeper parts of the hair follicles (37)

After analyzing the data obtained and comparing the results between pig skin and human skin, it can be concluded that the morphometry of pig hair follicles is very similar to human skin follicles. So, it can be concluded that pig skin and especially the dorsal area of the ear represents a good ex vivo skin model for the investigation of skin penetration of topically applied substances and that an extrapolation of the results to the human situation should be possible, although this needs further experiments.

The results obtained in the present study allow us to know in detail the morphometric characteristics of the structures of the hair follicle in pigs skin, which would be of great help when carrying out subsequent studies of follicular penetration with a specific target inside the follicle, which could be important in the clinical application of topical substances for the treatment of various pathologies. However, different limitations can

be observed when carrying out studies in pig ears; although follicular structures in pigs and humans are very similar since it is an ex vivo animal model, the pharmacology of the applied substances and their effects on human skin in vivo cannot be known with certainty. Therefore, in later studies, they could be raised as questions: is the absorption and pharmacology of substances applied topically to pig skin similar to human skin? Would they have the same adverse effects? Would it be safe to experiment with substances in pig skin and then extrapolate these results to human skin?

For this reason, we invite future working groups to continue studying this area of dermatology and cutaneous physiology.

## References

1. Rosen J, Landriscina A, Friedman A. Nanotechnology-Based Cosmetics for Hair Care. *Cosmetics*. 2015; 2(3):211-24.
2. Kalia, Y.N. and R.H. Guy. Modeling transdermal drug release. *Advanced drug delivery reviews*, 2001;48(2-3):159-172.
3. L Mak WC, Patzelt A, Richter H, Renneberg R, Lai KK, Rühl E, Sterry W, Lademann J. Triggering of drug release of particles in hair follicles. *Journal of controlled release*. 2012;160(3):509-14.
4. Otberg N, Patzelt A, Rasulev U, Hagemeister T, Linscheid M, Sinkgraven R, Sterry W, Lademann J. The role of hair follicles in the percutaneous absorption of caffeine. *British journal of clinical pharmacology*. 2008; 65(4): 488-92.
5. Vogt A, Blume-Peytavi U. Die Biologie des menschlichen Haarfollikels. *Der Hautarzt*. 2003;54(8):692-8.
6. Paus R, & Cotsarelis G. The Biology of Hair Follicles. *The New England journal of medicine*. 1999; 341(7):491-7.
7. Buffoli B, Rinaldi F, Labanca M, Sorbellini E, Trink A, Guanziroli E, Rezzani R, Rodella LF. The human hair: from anatomy to physiology. *International Journal of Dermatology* 2014; 53(3):331–341
8. Araucaria D, Alfaro N, Sandoval-Tress C. Hairs molecular structure and development. *Dermatología cosmética, médica y quirúrgica*. 2010; 8 (1):54-61.
9. Patzelt A, Richter H, Knorr F, Schäfer U, Lehr C.-M, Sterry W, Lademann J. Selective follicular targeting bz modification of the particle sizes. *Journal of Controlled Release*. 2011; 150 (1): 45-8.
10. Nohynek GJ, Lademann J, Ribaud C, Roberts MS. Grey goo on the skin? Nanotechnology, cosmetic and sunscreen safety. *Critical reviews in toxicology*. 2007;37(3):251-77.
11. Lademann J, Patzelt A, Schanzer S, Richter H, Thiede G, Havlickova B, Günther C, Friedrich M, Sterry W, Fluhr JW, Seifert S. Non-invasive analysis of

- penetration and storage of Isoconazole nitrate in the stratum corneum and the hair follicles. *European Journal of Pharmaceutics and Biopharmaceutics*. 2021; 80(3): 615-20
12. Jacobi U, Kaiser M, Toll R, Mangelsdorf S, Audring H, Otberg N, et al. Porcine ear skin: an in vitro model for human skin. *Skin Research Technology*. 2007;13(1):19-24.
  13. Walberg JE. Percutaneous Absorption. In: Mali JWH, ed. *Current Problems in Dermatology*. Basel, Karger, 1973. p.1-36
  14. Hueber F, Besnard M, Schaefer H, Wepierre J. **Percutaneous absorption of estradiol and progesterone in normal and appendage-free skin of hairless rat: Lack of importance of nutritional blood flow.** *Skin Pharmacol*.1994; 7(5): 245-56
  15. Tenjarla SN, Kasina R, Puranajoti P, Omar MS, Harris WT. **Synthesis and evaluation of N-acetylprolinate esters—Novel skin penetration enhancers.** *International Journal of Pharmaceutics*. 1999; 192(2):147-158
  16. Maibach HI, Feldman RJ, Milby TH, Serat WF: Regional variation in percutaneous penetration in man. *Arch Environ Health*. 1971; 23:208–11
  17. Lademann J, Knorr F, Richter H, Jung S, Meinke MC, Rühl E, Alexiev U, Calderon M, Patzelt A. Hair follicles as a target structure for nanoparticles. *Journal of Innovative Optical Health Sciences*. 2014; 8(4): 1530004
  18. Lademann J, Richter H, Meinke M, Sterry W, Patzelt A. Which skin model is the most appropriate for the investigation of topically applied substances into the hair follicles? *Skin Pharmacology and Physiology*. 2010;23(1):47-52.
  19. Wosicka H, Cal K. Targeting to the hair follicles: current status and potential. *Journal of dermatological science*. 2010;57(2):83-9.
  20. Otberg N, Teichmann A, Rasuljev U, Sinkgraven R, Sterry W, Lademann J. Follicular penetration of topically applied caffeine via a shampoo formulation. *Skin Pharmacol Physiology*. 2007;20(4):195-8.
  21. Grazu V, Moros M, Sánchez-Espinel C. Nanocarriers as nanomedicines: design concepts and recent advances. *Frontiers of nanoscience*. 4: Elsevier; 2012. p. 337-440.
  22. Patzelt A, Richter H, Knorr F, Schäfer U, Lehr C-M, Dähne L, Sterry W, Lademann J. Selective follicular targeting by modification of the particle sizes. *Journal of controlled release*. 2011;150(1):45-8.
  23. Toll R, Jacobi U, Richter H, Lademann J, Schaefer H, Blume-Peytavi U. Penetration profile of microspheres in follicular targeting of terminal hair follicles. *The journal of investigative dermatology*. 2004 Jul;123(1):168-76.
  24. Lademann J, Richter H, Teichmann A, Otberg N, Blume-Peytavi U, Luengo J, Weiß B, Schaefer UF, Lehr CM, Wepf R, Sterry W. Nanoparticles – An efficient carrier for drug delivery into the hair follicles. *European Journal of Pharmaceutics and Biopharmaceutics*, 2007; 66 (2): 159-164.

25. Baroli B, Ennas MG, Loffredo F, Isola M, Pinna R, López-Quintela MA. Penetration of metallic nanoparticles in human full-thickness skin. *The journal of investigative dermatology*. 2007; 127(7):1701-12.
26. Lekki J, Zbigniew S, Dabros W, Stachura J, Menzel F, Reinert T, Butz T, Pallon J, Gontier E, Ynsa M, Moretto P, Kertész Zs. On the follicular pathway of percutaneous uptake of nanoparticles: Ion microscopy and autoradiography studies. *Nuclear Instruments & Methods in Physics Research Section B-beam Interactions With Materials and Atoms*. 2007; 260(1): 174-77.
27. Trauer S, Richter H, Kuntsche J, Büttemeyer R, Liebsch M, Linscheid M, Fahr A, Schäfer-Korting M, Lademann J, Patzelt A. Influence of massage and occlusion on the ex vivo skin penetration of rigid liposomes and invasomes, *European Journal of Pharmaceutics and Biopharmaceutics*. 2014; 86(2): 301-6
28. Lademann J, Patzelt A, Richter H, Antoniou C, Sterry W, Knorr F. Determination of the cuticula thickness of human and porcine hairs and their potential influence on the penetration of nanoparticles into the hair follicles. *journal of biomedical optics*. 2009; 14(2):021014
29. Vânia LS, Mandelli de Almeida M, Fradin A, Grice JE, Roberts MS. (2012) Delivery of drugs applied topically to the skin, *Expert Review of Dermatology*. 2012; 7(4): 383-397
30. Hueber F, Schaefer H, Wepierre J. Role of transepidermal and transfollicular routes in percutaneous absorption of steroids: in vitro studies on human skin. *Journal of Skin Pharmacology Physiology*. 1994;7(5):237-44.
31. Lademann J, Otberg N, Jacobi U, Hoffman RM, Blume-Peytavi U, editors. Follicular penetration and targeting. *Journal of Investigative Dermatology Symposium Proceedings*; 2005; 10(3): 301-3.
32. Jacobi U, Toll R, Sterry W, Lademann J. Do follicles play a role as penetration pathways in vitro studies on porcine skin? -An optical study. *Laser Physics*. 2005;15(11):1594-8.
33. Mangelsdorf S, Vergou T, Sterry W, Lademann J, Patzelt A. Comparative study of hair follicle morphology in eight mammalian species and humans. *Skin Research Technology*. 2014;20(2):147-54.
34. Patzelt A, Richter H, Buettemeyer R, Huber HJR, Blume-Peytavi U, Sterry W, Lademann J. Differential stripping demonstrates a significant reduction of the hair follicle reservoir in vitro compared to in vivo. *European journal of pharmaceutics biopharmaceutics*. 2008;70(1):234-8.
35. Frum Y, Eccleston GM, Meidan VM. In-vitro permeation of drugs into porcine hair follicles: is it quantitatively equivalent to permeation into human hair follicles? *Journal of Pharmacy Pharmacology*. 2008;60(2):145-51.
36. Schmook FP, Meingassner JG, Billich A. Comparison of human skin or epidermis models with human and animal skin in in-vitro percutaneous absorption. *International journal of pharmaceutics*. 2001;215(1-2):51-6.

37. Vogt A, Hadam S, Heiderhoff M, Audring H, Lademann J, Sterry W, Blume-Peytavi U. Morphometry of human terminal and vellus hair follicles. *Experimental dermatology*. 2007;16(11):946-50.
38. Zambrano A, Klein AL, Patzelt A. Analysis of the morphometric parameters of pig ear hair follicles. *Skin Research and Technology*. 2021; 00:1-9.
39. Alonso L, Fuchs E. The hair cycle. *Journal of cell science*. 2006;119(3):391-3
40. Wang X, Shi Y, Zhou Q, Liu X, Xu S, Lei T. Detailed histological structure of human hair follicle bulge region at different ages: a visible niche for nesting adult stem cells. *Journal of Huazhong University of Science Technology*. 2012;32(5):648-56.
41. Turner NJ, Pezzone D, Badylak SF. Regional variations in the histology of porcine skin. *Tissue Engineering Part C: Methods*. 2015;21(4):373-84.
42. Meyer W, Kacza Johannes, Zschemisch NH, Godynicki S, Seeger J. Observations on the actual structural conditions in the stratum superficiale dermis of porcine ear skin, with special reference to its use as model for human skin. *Ann Anat* 189 (2007) 143-156
43. Otberg N, Richter H, Schaefer H, Blume-Peytavi U, Sterry W, Lademann J. Variations of hair follicle size and distribution in different body sites. *Journal of Investigative Dermatology*. 2004;122(1):14-9.
44. Oh JW, Kloepper J, Langan EA, Kim Y, Yeo J, Kim MJ, Hsi TS, Rose C, Yonn GS, Lee SJ, Seykora J, Kim JC, Sung YK, Kim M, Paus R, Plikus MV. A guide to studying human hair follicle cycling in vivo. *Journal of Investigative Dermatology*. 2016;136(1):34-44.
45. Watson SA, Moore GP. Postnatal development of the hair cycle in the domestic pig. *Journal of anatomy*. 1990; 170:1-9.
46. Patzelt A, Knorr F, Blume-Peytavi U, Sterry W, Lademann J. Hair follicles, their disorders and their opportunities. *Drug Discovery Today: Disease Mechanisms*. 2008;5(2):e173-e81.
47. Erdoğan B. Hair and Scalp Disorders: Anatomy and Physiology of Hair. 2017. 2: 14-27.
48. Ohyama M. Hair follicle bulge: a fascinating reservoir of epithelial stem cells. *Journal of dermatological science*. 2007;46(2):81-9.
49. Sandby-Moller J, Poulsen T, Wulf HC. Epidermal thickness at different body sites: relationship to age, gender, pigmentation, blood content, skin type and smoking habits. *Acta Dermato Venereologica*. 2003;83(6):410-3.

## Eidesstattliche Versicherung

„Ich, Alexandra Zambrano, versichere an Eides statt durch meine eigenhändige Unterschrift, dass ich die vorgelegte Dissertation mit dem Thema: Morphometric description of pig ear hair follicles and their similarity to human hair follicles/Morphometrische Beschreibung von Schweineohr-Haarfollikeln und ihrer Ähnlichkeit mit menschlichen Haarfollikeln selbstständig und ohne nicht offengelegte Hilfe Dritter verfasst und keine anderen als die angegebenen Quellen und Hilfsmittel genutzt habe.

Alle Stellen, die wörtlich oder dem Sinne nach auf Publikationen oder Vorträgen anderer Autoren/innen beruhen, sind als solche in korrekter Zitierung kenntlich gemacht. Die Abschnitte zu Methodik (insbesondere praktische Arbeiten, Laborbestimmungen, statistische Aufarbeitung) und Resultaten (insbesondere Abbildungen, Graphiken und Tabellen) werden von mir verantwortet.

Ich versichere ferner, dass ich die in Zusammenarbeit mit anderen Personen generierten Daten, Datenauswertungen und Schlussfolgerungen korrekt gekennzeichnet und meinen eigenen Beitrag sowie die Beiträge anderer Personen korrekt kenntlich gemacht habe (siehe Anteilserklärung). Texte oder Textteile, die gemeinsam mit anderen erstellt oder verwendet wurden, habe ich korrekt kenntlich gemacht.

Meine Anteile an etwaigen Publikationen zu dieser Dissertation entsprechen denen, die in der untenstehenden gemeinsamen Erklärung mit dem/der Erstbetreuer/in, angegeben sind. Für sämtliche im Rahmen der Dissertation entstandenen Publikationen wurden die Richtlinien des ICMJE (International Committee of Medical Journal Editors; [www.icmje.org](http://www.icmje.org)) zur Autorenschaft eingehalten. Ich erkläre ferner, dass ich mich zur Einhaltung der Satzung der Charité – Universitätsmedizin Berlin zur Sicherung Guter Wissenschaftlicher Praxis verpflichte.

Weiterhin versichere ich, dass ich diese Dissertation weder in gleicher noch in ähnlicher Form bereits an einer anderen Fakultät eingereicht habe.

Die Bedeutung dieser eidesstattlichen Versicherung und die strafrechtlichen Folgen einer unwahren eidesstattlichen Versicherung (§§156, 161 des Strafgesetzbuches) sind mir bekannt und bewusst.“

Datum

Unterschrift



## Anteilserklärung

Alexandra Zambrano hatte folgenden Anteil an den folgenden Publikationen:

Publikation 1: Zambrano A, Klein AL, Patzelt A. Analysis of the morphometric parameters of pig ear hair follicles. Skin Research and Technology. 2021; 00:1-9.

### Beitrag im Einzelnen:

- Erstautorenschaft.
- Entwicklung der Fragestellung und der Hypothesen gemeinsam mit der ersten Betreuerin PD Dr. med Alexa Patzelt.
- Planung der Studie gemeinsam mit der ersten Betreuerin PD Dr. med. Alexa Patzelt.
- Durchführung aller Experimente sowie Erhebung aller Daten, insbesondere:
  - Anfertigung von Biopsien und histologischen Schnitten.
  - Mikroskopische Analyse von allen histologischen Schnitten und Erhebung der Messdaten der Haarfollikel.
- Tabellarische Zusammenstellung der Primärdaten und Auswertung aller erhobenen Daten.
- Erstellung von allen Abbildungen und Tabellen.
- Statistische Analyse der Daten nach ausführlicher Beratung durch einen Statistiker des Instituts für Biometrie und Klinische Epidemiologie der Charité.
- Interpretation und kritische Bewertung der Ergebnisse gemeinsam mit der ersten Betreuerin PD Dr. med. Alexa Patzelt und Frau Anna Lena Klein.
- Eigenständige Erstellung des ersten Entwurfs des Manuskripts inklusive der Literaturrecherche, eigenständige Erstellung der finalen Version des Manuskripts nach kritischer Bewertung durch PD Dr. med. Alexa Patzelt und Frau Anna Lena Klein.

---

Unterschrift, Datum und Stempel des/der erstbetreuenden Hochschullehrers/in

---

Unterschrift des Doktoranden/der Doktorandin

# Auszug aus der Journal Summary List (ISI Web of KnowledgeSM)

Journal Data Filtered By: **Selected JCR Year: 2019** Selected Editions: SCIE,SSCI  
 Selected Categories: **"DERMATOLOGY"** Selected Category Scheme: WoS  
**Gesamtanzahl: 68 Journale**

Rank	Full Journal Title	Total Cites	Journal Impact Factor	Eigenfactor Score
1	JOURNAL OF THE AMERICAN ACADEMY OF DERMATOLOGY	30,658	8.277	0.034840
2	JAMA Dermatology	5,680	7.738	0.018120
3	JOURNAL OF INVESTIGATIVE DERMATOLOGY	30,375	7.143	0.034150
4	BRITISH JOURNAL OF DERMATOLOGY	28,429	7.000	0.030250
5	JOURNAL OF THE EUROPEAN ACADEMY OF DERMATOLOGY AND VENEREOLOGY	12,492	5.248	0.020170
6	AMERICAN JOURNAL OF CLINICAL DERMATOLOGY	2,994	5.056	0.004680
7	ACTA DERMATO-VENEREOLOGICA	6,694	4.016	0.008160
8	Dermatitis	1,427	3.988	0.002330
9	CONTACT DERMATITIS	6,326	3.952	0.003550
10	DERMATOLOGY	5,372	3.695	0.003850
11	Pigment Cell & Melanoma Research	4,674	3.683	0.005900
12	JOURNAL OF DERMATOLOGICAL SCIENCE	5,287	3.681	0.006810
13	JOURNAL DER DEUTSCHEN DERMATOLOGISCHEN GESELLSCHAFT	2,626	3.664	0.003210
14	MYCOSES	4,188	3.575	0.005910
15	EXPERIMENTAL DERMATOLOGY	6,936	3.368	0.010370
16	SKIN PHARMACOLOGY AND PHYSIOLOGY	1,829	3.314	0.001240
17	DERMATOLOGIC CLINICS	2,369	3.164	0.003370
18	Burns & Trauma	538	3.088	0.001320
19	JOURNAL OF DERMATOLOGY	5,229	3.072	0.007870

Rank	Full Journal Title	Total Cites	Journal Impact Factor	Eigenfactor Score
20	LASERS IN SURGERY AND MEDICINE	5,435	3.020	0.003720
21	International Wound Journal	3,446	2.825	0.005580
22	Advances in Wound Care	2,313	2.813	0.004830
23	EUROPEAN JOURNAL OF DERMATOLOGY	2,939	2.782	0.003030
24	Dermatology and Therapy	692	2.761	0.001720
25	MELANOMA RESEARCH	2,450	2.750	0.003740
26	Indian Journal of Dermatology Venereology & Leprology	2,122	2.712	0.002100
27	DERMATOLOGIC SURGERY	8,112	2.567	0.006930
28	WOUND REPAIR AND REGENERATION	5,833	2.471	0.005030
29	CLINICS IN DERMATOLOGY	3,846	2.458	0.003140
30	Journal of Tissue Viability	624	2.410	0.000910
31	PHOTODERMATOLOGY PHOTOIMMUNOLOGY & PHOTOMEDICINE	1,656	2.387	0.001230
32	ARCHIVES OF DERMATOLOGICAL RESEARCH	3,777	2.339	0.003460
33	Dermatologic Therapy	1,988	2.327	0.002140
34	JOURNAL OF DERMATOLOGICAL TREATMENT	2,425	2.156	0.003970
35	SKIN RESEARCH AND TECHNOLOGY	2,358	2.079	0.001980
36	INTERNATIONAL JOURNAL OF DERMATOLOGY	7,833	2.067	0.007720
37	BURNS	7,880	2.066	0.007350
38	CLINICAL AND EXPERIMENTAL DERMATOLOGY	4,863	1.977	0.003840
39	Clinical Cosmetic and Investigational Dermatology	1,161	1.970	0.002370
40	JOURNAL OF CUTANEOUS MEDICINE AND SURGERY	1,297	1.909	0.001900

2

Selected JCR Year: 2019; Selected Categories: "DERMATOLOGY"

Quelle: Medizinische Bibliothek Charité. Zugriff am 14. Mai 2021

## Analysis of the morphometric parameters of pig ear hair follicles

Alexandra Zambrano | Anna Lena Klein | Alexa Patzelt

Department of Dermatology Venereology and Allergology, Center of Experimental and Applied Cutaneous Physiology, Humboldt-Universität zu Berlin, and Berlin Institute of Health, Charité – Universitätsmedizin Berlin, Corporate member of Freie Universität Berlin, Charité Universitätsmedizin Berlin, Berlin, Germany

### Correspondence

Anna Lena Klein, Department of Dermatology Venereology and Allergology, Center of Experimental and Applied Cutaneous Physiology, Charité – Universitätsmedizin Berlin, Charitéplatz 1, 10117 Berlin, Germany.  
Email: anna-lena.klein@charite.de

### Abstract

**Background:** Porcine ear skin is used in studies of percutaneous penetration as a substitute for human skin. The objective of the present study was to determine the structure of the hair follicles on the dorsal area of porcine ear skin and make a morphometric comparison with the hair follicles of human skin.

**Materials and Methods:** Sections of frozen biopsies were cut vertically to the skin surface in longitudinal sections using a cryotome and were investigated using microscopy. For each hair follicle, various parameters were determined.

**Results:** The follicular density in porcine ear skin varies according to the area studied, and the length of most of the follicles was approximately  $1458 \pm 286 \mu\text{m}$ . The size of the follicular orifice was also determined in a total of 305 follicles. It showed a diameter of roughly  $113 \pm 43 \mu\text{m}$ .

**Conclusion:** The results showed a very good similarity between human and pig hair follicles. Therefore, porcine ear skin can be considered as a very suitable model of human skin in dermal and especially follicular penetration studies.

### KEYWORDS

hair follicle morphology, human skin, in vitro model, porcine ear skin

## 1 | INTRODUCTION

In recent years, the relevance of hair follicles in the process of skin penetration has been demonstrated in many studies. The stratum corneum is the outermost layer of the skin and represents the main skin barrier. The stratum corneum is discontinuous in the region of the hair follicles, which facilitates faster absorption of certain substances and drugs in these areas.<sup>1</sup> Additionally, the presence of numerous blood capillaries, in close contact with the hair follicle, enables a rapid uptake of various actives into the bloodstream.<sup>2,3</sup> This previous statement could be corroborated in a study conducted by Otberg et al demonstrating that, after a caffeine application for 2 minutes in a shampoo formulation, caffeine penetrated through the hair follicles and the stratum corneum. However, absorption through the hair follicles and relevant levels of caffeine in the blood

was already found 5 minutes after topical application. Comparable levels could not be obtained before 20 minutes when caffeine penetrated exclusively through the stratum corneum of the interfollicular epidermis.<sup>4</sup> Whereas the intercellular penetration pathway along the lipid layers around the corneocytes can still be considered as the most relevant one for most topically applied substances, the follicular penetration pathway offers entrance to further target structures of interest. The epidermal stem cells, for example, which are located in the bulge region of the hair follicle, are of special interest for regenerative therapy approaches, the dendritic cells, which are surrounding the infundibular part of the hair follicle, can be targeted if transfollicular immune therapy is desired.<sup>5</sup>

Likewise, in recent years, a growing interest has been developed in nanometer-sized drug delivery systems in the field of medicine. Due to their small size, nanocarriers can improve the

This is an open access article under the terms of the Creative Commons Attribution-NonCommercial-NoDerivs License, which permits use and distribution in any medium, provided the original work is properly cited, the use is non-commercial and no modifications or adaptations are made.

© 2021 The Authors. *Skin Research and Technology* published by John Wiley & Sons Ltd.

site-specific drug delivery and therapeutic effect of drugs that suffer from poor solubility, poor stability, and unwanted toxicity. This helps to generate better tissue distribution and pharmacokinetics and thus a reduction of the adverse effects of certain drugs in the body.<sup>6</sup>

However, it has been observed that not all of the topically applied particles or substances can cross the epidermis. Consequently, the hair follicles play a fundamental role again in their penetration, storage, and transport. The results of many studies suggested that particles located in the stratum corneum were nearly quantitatively removed after 1 day.<sup>7</sup> In contrast, particles in the hair follicles remained for more than 10 days. This could be observed, for example, in a study carried out with Itraconazole applied topically onto the forearm of male and female volunteers. 2 weeks after the last application of the substance, relevant concentrations of it were observed in the hair follicles, stating that these represent a long-term reservoir for topically applied substances.<sup>8</sup> It has also been suggested that nanoparticles after penetrating the skin might be taken up by local lymph nodes and then transported into the blood.<sup>7</sup> Another aspect that is important to highlight when we talk about skin penetration through hair follicles is the size of the particle. In a study by Patzelt et al, it was determined that the particles of medium size (643 and 646 nm) penetrated deeper into porcine hair follicles than smaller (122 nm) or larger particles (860 nm).<sup>9</sup> It was also concluded that by varying the particle size, different sites within the porcine hair follicle can be targeted selectively.<sup>9</sup> Studies conducted with human hair follicles revealed similar results, showing that particles with a size of approximately 750 nm penetrated deeper into the terminal follicles of human Scalp.<sup>10</sup> Due to the confirmed impact of the hair follicles in the process of transdermal penetration, different authors have carried out multiple *in vivo* or *ex vivo* studies on the morphology of the hair follicles and the follicular penetration of various substances into human skin.<sup>11,12</sup>

However, access to human skin as a skin model is usually limited, and its use has certain disadvantages for follicular penetration studies.<sup>13</sup> For example, upon excision, human skin shrinks due to the contraction of the elastic fibers, producing a contraction and permanent occlusion of the hair follicular orifice and decreasing the follicle reservoir, significantly limiting the penetration process by up to 90%.<sup>14</sup>

Therefore, and in search for an appropriate animal skin model to extrapolate skin penetration studies in humans, different comparative studies of hair follicle morphology and skin structure in different species have been carried out in the recent past. The morphology and skin penetration of various substances through the hair follicles in mammals generally vary according to the species and area of the body.<sup>15</sup> However, porcine skin and the hair follicle morphology in the area of the ear have high similarity with human skin in contrast to other pig skin regions. For this reason, it has been concluded that porcine ear skin should be a suitable *ex vivo* model for percutaneous penetration studies, especially when the follicular penetration pathway is investigated.<sup>16</sup> Studies comparing the penetration behavior of

various substances in human skin, as well as pig skin, revealed that the penetration process in both models is similar.<sup>17,18</sup>

Unfortunately, the morphological description of hair follicles is only available for human skin<sup>10</sup> but not for porcine ear skin, yet. Therefore, the objective of the present study was to determine the morphometric characteristics of the hair follicles in pig ears in order to enable a more specific comparison of human and porcine hair follicles, and to allow a better extrapolation of data obtained from pig skin experiments to the in the human situation.

## 2 | MATERIALS AND METHODS

The morphometry of porcine ear hair follicles was investigated on 345 longitudinal sections of hair follicles of  $n = 10$  individuals by determining seven different parameters. The ear skin was selected, as porcine ear skin is a frequently utilized *ex vivo* skin model to investigate the intercellular and especially the follicular penetration of topically applied compounds. Thus, the knowledge of the exact morphometry is very relevant but only partly available yet.

### 2.1 | Porcine ear skin

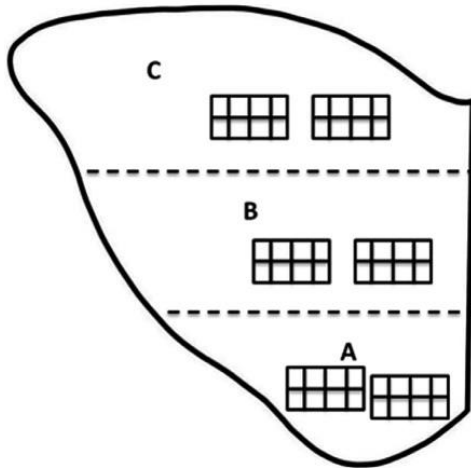
The investigations were performed using ear skin (dorsal region) from 10 pigs (German domestic pig, 6 months old). The ears were kindly provided by a regional butcher and were investigated on the day of slaughtering. After arrival, the ears were cleaned using cold water. The experiments were authorized by the Federal Ministry of Consumer Protection and Agriculture, Landkreis Dahme-Spreewald. In preparation for the experiments, the ears were washed under cold tap water and dried using soft paper towels.

### 2.2 | Preparation of longitudinal hair follicle sections

As hair follicle density is verifiably varying in different parts of porcine ears, each ear was divided into three areas (A, B, and C), whereby area A was determined to be the caudal end of the ear, area B the middle part, and area C the cranial end of the ear. For each area, 2 fields of 6 cm<sup>2</sup> were marked in the central region and 8 square biopsies sized 5 mm × 5 mm were removed from each field, as demonstrated in Figure 1.

The follicular density of each biopsy was determined macroscopically. Afterward, the biopsies were shock-frozen in liquid nitrogen and stored at -20°C. The frozen biopsies were cut vertically to the skin surface in longitudinal sections of 7 μm thickness using a cryotome (Microm cryo-Star HM 560, MICROM International GmbH). The sections were transferred to glass slides (Menzel Gläser Superfrost®, Thermo Fischer Scientific Inc Waltham). For

each hair follicle, various sections were prepared. For each area (A, B, and C) of each porcine ear skin sample, a minimum of 10 hair follicles was investigated.



**FIGURE 1** Schematic representation of the division of the porcine ears

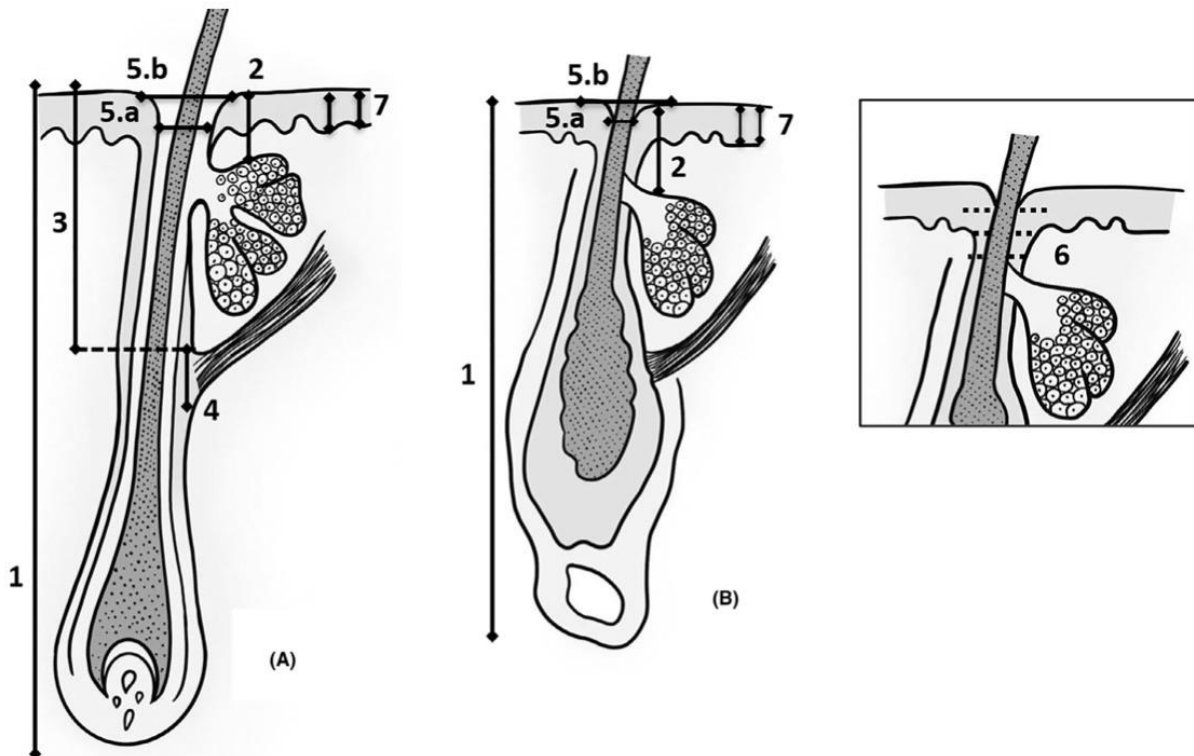
### 2.3 | Determination of the morphometric parameters of the hair follicles

Using a microscope (BX60, Olympus), Camera (XC10, Olympus), and the software "cellSens Dimension" (Olympus), multiple parameters were determined for each hair follicle: the length of the hair follicle (a), the length of the infundibulum (b), the length and position of the bulge region (c and d), the opening of the hair follicle (e), the thickness of the hair follicle epithelium in the area of the infundibulum (f) and the thickness of the interfollicular epidermis (g) as depicted in Figure 2.

As the longitudinal sections of the hair follicles often did not display the complete hair follicle, the numbers of hair follicles assessed for the specific parameters are presented in Table 1.

### 2.4 | Statistical results

The statistical analyses were performed using the software program Microsoft® Excel 2007 and SPSS 24 IBM Statistic software (IBM Corporation). Mean values and standard deviations were calculated. The descriptive statistical analysis Wilcoxon test was used to



**FIGURE 2** Morphometric measurements on porcine hair follicles from the dorsal auricular region. Total length of the hair follicle (1), length of the infundibulum (2), position and the length of the bulge region (3,4), hair follicle opening at the skin surface (5.a without epithelium, 5.b with epithelium), thickness of the hair follicle epithelium in the area of the infundibulum: upper, middle and lower part at the entrance of the sebaceous gland (6) and thickness of the interfollicular epidermis with intervals of 150 and 200  $\mu\text{m}$  from the opening of the follicle (7). Figure A representation of the anagen phase and figure B telogen phase hair follicle

determine the significance of the differences between the different parameters in three areas of the ear (A, B and C).

### 3 | RESULTS

#### 3.1 | Hair follicle density

The density of the hair follicles in the dorsal skin area of the porcine ears was determined. The results revealed that the number of hair follicles varied according to the area of the ear. The area indicated as zone C (cranial region) had the highest density of hair follicles per  $\text{cm}^2$ , while the area with the lowest density of follicles was the most caudal area (area A). The results are presented in Table 2.

#### 3.2 | Length of the hair follicle

A total of 345 follicles were investigated. The total length of the hair follicles was only determined in  $n = 259$  follicles and they were classified according to their anagen and telogen growth phases. Histologically, it is possible to recognize the follicles in the anagen phase, because these follicles are long, very straight and angled. In the telogen phase, the hairs are shorter, and the hair shaft is closer to the surface of the skin.<sup>19</sup> Figure 3 shows an example of a microscopic image that was used for the evaluations. 64% of the hair follicles ( $n = 166$ ) were in

the anagen phase, and 36% were in the telogen phase ( $n = 93$ ). The follicles were also classified into two groups according to their length ( $<2000 \mu\text{m}$  and  $>2000 \mu\text{m}$ ). 64% of the hair follicles in the anagen phase had a length  $<2000 \mu\text{m}$  (MV  $1458 \pm 296 \mu\text{m}$ ), whereas 92% of the hair follicles in the telogen phase measured less than  $2000 \mu\text{m}$  (MV  $1240 \pm 359 \mu\text{m}$ ). No significant difference in follicle length was found for the different ear skin areas ( $P > .05$ ).

#### 3.3 | Length of the infundibulum

The length of the infundibulum was determined in a total of 172 follicles. For the anagen hair follicles with a total length of  $<2000 \mu\text{m}$ , the infundibulum length was  $373 \pm 72 \mu\text{m}$  ( $n = 64$ ), for telogen hair follicles ( $<2000 \mu\text{m}$ ), the infundibulum length was  $458 \pm 131 \mu\text{m}$  ( $n = 64$ ).

In hair follicles  $>2000 \mu\text{m}$ , the length of the infundibulum was  $516 \pm 107 \mu\text{m}$  ( $n = 38$ ) in anagen hair follicles and  $619 \pm 152 \mu\text{m}$  ( $n = 6$ ) in telogen hair follicles. There were no statistical differences ( $P > .05$ ) for the infundibulum length between the different skin areas A, B, and C.

The descriptive statistical analysis with the Wilcoxon test revealed that there was a significant difference ( $P < .05$ ) between the two hair follicle groups ( $<2000 \mu\text{m}$  and  $>2000 \mu\text{m}$ ) concerning the infundibulum length. This was observed in follicles in the anagen phase as well as in the telogen phase. All results concerning the total follicular length and the length of the infundibulum are summarized in Table 3.

**TABLE 1** Numbers of hair follicles evaluated by parameter per area in the dorsal region of porcine ear skin

Parameter	Area A	Area B	Area C
Hair follicle density	50	62	90
Length of the hair follicle	88	87	84
The opening of the hair follicle	106	103	96
Length of the Infundibulum	63	54	55
Epithelium in the area of the infundibulum	60	45	47
Length of the bulge region	33	15	28
Position of the bulge region	26	15	26
Epidermis interfollicular	100	91	93

Note: The values by category were combined for the total sum of follicles evaluated.

**TABLE 2** Mean density of hair follicles per  $\text{cm}^2$  in the dorsal area of the porcine ears

Ear area	Number of hair follicles per $\text{cm}^2$
A	$8 \pm 2$
B	$10 \pm 1$
C	$15 \pm 3$

Note: Data are presented as mean  $\pm$  SD.

#### 3.4 | Length and position of the bulge region

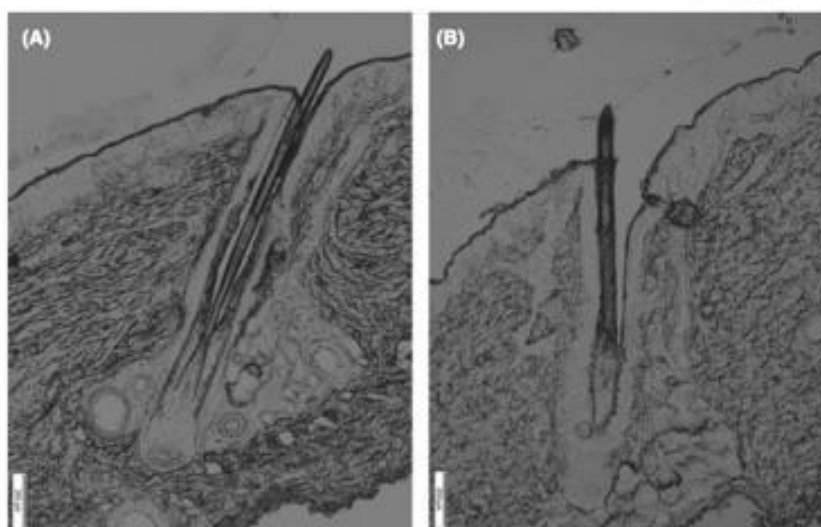
The bulge region is generally viewed as a prominent epithelial protrusion of the outer sheath of the follicle root. It is located between the opening of the sebaceous gland and the attachment site of the arrector pili muscle. In most cases, it is challenging to identify this lateral protrusion.<sup>19,20</sup> The parameters were only determined in the follicles in the anagen phase because the size of the follicle during this growth phase made it easier to identify it.

The position of the bulge region could be identified in 67 follicles. For these follicles, it was found at a depth of  $881 \pm 208 \mu\text{m}$  from the surface of the skin. The length of the bulge region was  $272 \pm 36 \mu\text{m}$  ( $n = 76$ ). There was no significant statistical difference between the three areas of the ear ( $P > .05$ ). To assess the position and length of the bulbar region, all the follicles found were added, without classifying them by their total length, because the values were similar in all the follicles. The results are summarized in Table 4.

#### 3.5 | Opening of the hair follicle

The size of the follicular orifice in the infundibulum area was determined in a total of 305 follicles. Measurements were made with and without the infundibular epithelium. The mean diameter of the opening of the hair follicle, including the infundibular epithelium, was  $326 \pm 58 \mu\text{m}$ , and

**FIGURE 3** Photographic representation of the hair follicles in pig ears in their different growth phases (A. anagen phase and B. telogen phase)



**TABLE 3** Summary of the data obtained for total follicular length (LHF) and length of the infundibulum (LI)

HF	Anagen (n = 166)			Telogen (n = 93)		
	LHF		LI	LHF		LI
	MV $\pm$	n=	MW $\pm$	MV $\pm$	n=	MV $\pm$
<b>Area A</b>						
<2000 $\mu$ m	1440 $\pm$ 300	37	402 $\pm$ 79	1237 $\pm$ 388	27	412 $\pm$ 138
>2000 $\mu$ m	2380 $\pm$ 242	21	486 $\pm$ 84	2137 $\pm$ 58	3	567 $\pm$ 102
Total	1780 $\pm$ 532	58	438 $\pm$ 91	1237 $\pm$ 475	30	418 $\pm$ 140
<b>Area B</b>						
<2000 $\mu$ m	1440 $\pm$ 308	35	357 $\pm$ 64	1296 $\pm$ 301	34	460 $\pm$ 111
>2000 $\mu$ m	2506 $\pm$ 272	16	559 $\pm$ 125	2384 $\pm$ 150	2	823 $\pm$ 0
Total	1775 $\pm$ 577	51	386 $\pm$ 104	1331 $\pm$ 390	36	482 $\pm$ 124
<b>Area C</b>						
<2000 $\mu$ m	1498 $\pm$ 274	32	355 $\pm$ 58	1313 $\pm$ 373	25	512 $\pm$ 140
>2000 $\mu$ m	2416 $\pm$ 290	25	536 $\pm$ 115	2163 $\pm$ 68	2	698 $\pm$ 51
Total	1901 $\pm$ 536	57	446 $\pm$ 129	1376 $\pm$ 423	27	518 $\pm$ 140
Total A + B + C < 2000 $\mu$ m	1458 $\pm$ 286	63%	373 $\pm$ 72	1240 $\pm$ 359	92%	458 $\pm$ 131
		104			86	
Total A + B + C > 2000 $\mu$ m	2427 $\pm$ 275	37%	516 $\pm$ 107	2215 $\pm$ 144	8%	619 $\pm$ 152
		62			7	
Total A + B + C <2000 $\mu$ m + >2000 $\mu$ m	1820 $\pm$ 551	100%	426 $\pm$ 111	1314 $\pm$ 432	100%	472 $\pm$ 140
		166			93	

Note: Values are given in  $\mu$ m. The LHF and LI were determined on histological sections of the dorsal area of pig ears. The follicles were divided into different categories according to their length (HL) and growth phase (anagen and telogen). Data are presented as mean  $\pm$  SD.

without the epithelium  $113 \pm 43 \mu$ m. No statistical differences were observed for the different porcine ear areas ( $P > .05$ ) (Figure 4).

### 3.6 | Epithelium in the area of the infundibulum

Also, the thickness of the infundibular epithelium was measured. The measurements were made at three different regions of the

infundibulum. In the upper part of the infundibulum, the epithelium was  $59 \pm 11 \mu$ m thick. In the middle part, it was  $51 \pm 10 \mu$ m thick and in the lower part at the entrance of the sebaceous gland  $46 \pm 11 \mu$ m thick. The measurements were made on the right and left side of each hair follicle. No significant differences were found in the thickness between both sides as well as between the 3 different areas (A, B, and C) of the ear ( $P > .05$ ) (Figure 5).



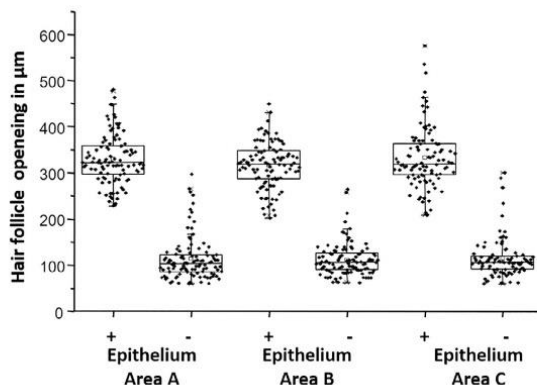
### 3.7 | Thickness of the interfollicular epidermis

The thickness of the interfollicular epidermis was also determined in the three areas of the ear (A, B, and C) with a lateral distance on both sides of the follicular orifice of 150 and 200  $\mu\text{m}$ . The following results were obtained: Right side of the follicular orifice  $101 \pm 2 \mu\text{m}$

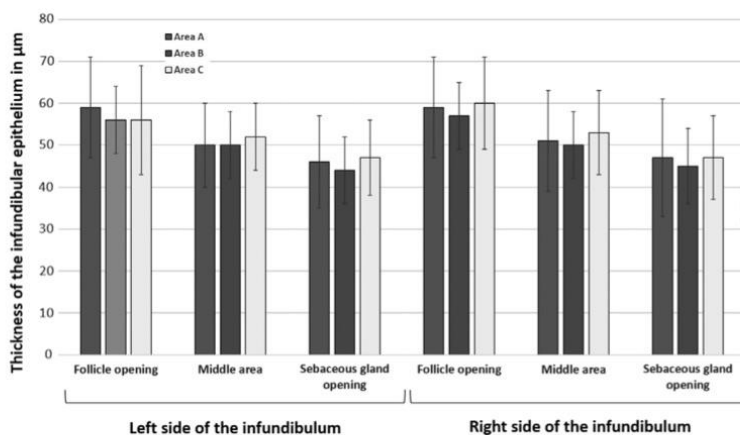
**TABLE 4** Summary of the data obtained for the position and length of the bulge region of porcine hairs per area on histological sections of dorsal area of pig ears

	Position of the bulge region	Length of the bulge region
Area A	$924 \pm 196$	$270 \pm 37$
Area B	$803 \pm 176$	$281 \pm 36$
Area C	$883 \pm 223$	$270 \pm 34$
Total A + B + C	$881 \pm 208$	$272 \pm 36$

Note: Values are given in  $\mu\text{m}$ , data are presented as mean  $\pm$  SD.



**FIGURE 4** Size of the hair follicular orifices. The diameter of the hair follicular orifices was measured with epithelium (+) and without epithelium (-) at the skin surface. Data are presented as mean  $\pm$  SD. ( $P > .05$ )



**FIGURE 5** Thickness of the infundibular epithelium of porcine hair follicles. The thickness was measured at three different points and on both sides of the infundibulum from the skin surface down to the entry level of the sebaceous duct. The diagram illustrates that the thickness of the infundibular epithelium decreases continuously with increasing depth of the hair follicle

and  $100 \pm 1 \mu\text{m}$ ; left side of the follicular orifice  $101 \pm 2 \mu\text{m}$  and  $100 \pm 0 \mu\text{m}$ . No significant difference between the three areas of the ear ( $P > .05$ ) could be determined (Figure 6).

### 3.8 | Comparing results: human skin vs porcine ear skin

Table 5 compares the results obtained from the measurements of the different structures of the hair follicle in humans and pig ears. The data from humans originate from the study of Vogt et al.<sup>10</sup>

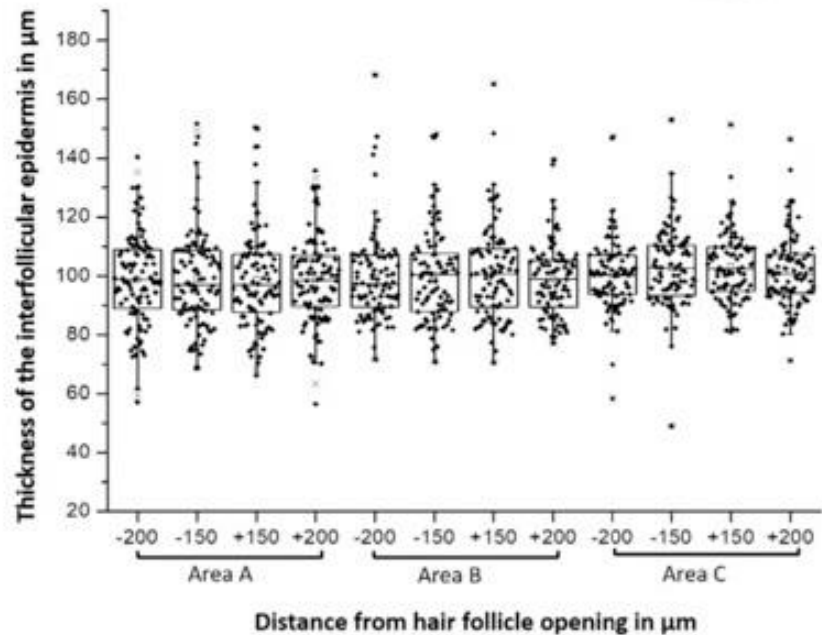
In pig ear, a greater variation in the length of the hair follicles could be found. Due to this, the follicles were classified into two groups. The classification was based on whether the hair was longer or shorter than 2000  $\mu\text{m}$ . Only follicles in the anagen phase were evaluated. The other results obtained in this study by parameters were grouped into a single category in order to enable a clearer representation and comparison of the values.

## 4 | DISCUSSION

The morphometry of the hair follicles in three different central dorsal areas of 10 pig ears was studied, as this skin area is frequently utilized as an ex vivo skin model for penetration investigations and a complete overview of the morphometric data was not available yet but would be useful to evaluate obtained data correctly.

The results of this study showed that the average density of hair follicles per  $\text{cm}^2$  is different depending on the skin area under investigation. The cranial zone presented on average a higher number of hairs per  $\text{cm}^2$ , with a maximum number of 18. The area with the lowest average number of hairs per  $\text{cm}^2$  was the caudal area with 10 hairs. The results obtained were compared to other publications determining the follicular density in pig ears. The density of hair follicles per  $\text{cm}^2$  varied in these studies; however, their results are similar. Some described the presence of 11-25 hair follicles per  $\text{cm}^2$ <sup>16</sup>; others 11-42 per  $\text{cm}^2$ .<sup>21</sup> Unfortunately, the authors did not specify

**FIGURE 6** Thickness of the interfollicular epidermis on both sides of the hair follicle (+right side, -left side). The thickness was measured at 150  $\mu\text{m}$  and 200  $\mu\text{m}$  from the hair follicular orifice of porcine ear skin. Data are presented as mean  $\pm$  SD



**TABLE 5** Comparison of human and porcine hair follicles

	Human skin	Pig ear
Length of the hair follicle (anagen stage)	3864 $\pm$ 605	1458 $\pm$ 296 2427 $\pm$ 275
Length of the infundibulum (anagen stage)	580 $\pm$ 84	426 $\pm$ 111
Position of the bulge region (anagen stage)	1191 $\pm$ 23	881 $\pm$ 208
Length of the bulge region (anagen stage)	240 $\pm$ 52	272 $\pm$ 36
Diameter of the hair follicle opening at skin surface level	172 $\pm$ 70	113 $\pm$ 2
Interfollicular epidermis	136 $\pm$ 37	101 $\pm$ 2

Note: Values are given in  $\mu\text{m}$ , data are presented as mean  $\pm$  SD (includes data from humans originate from the study of Vogt et al<sup>10</sup>).

the area of the ear in which the hair follicles were quantified. In principle, it should be noted that macroscopically the density of hairs at the edge of the ear is much higher. However, typically this area is not utilized for penetration studies, as the skin is not sufficiently flat within this area.<sup>22</sup>

In humans, the number of hair follicles likewise varies depending on the area of the body. On the calf region, on average a number of 14 hair follicles per  $\text{cm}^2$  can be found, whereas a higher density can be determined in the region of the chest (25 hair follicles/ $\text{cm}^2$ ), on the back (29 hair follicles/ $\text{cm}^2$ ), on the arms (18–32 hair follicles/ $\text{cm}^2$ ), on the thigh (17 hair follicles/ $\text{cm}^2$ ), or on the abdomen (70 hair follicles/ $\text{cm}^2$ ). The highest density has been described on the forehead with an average of 292 follicles/ $\text{cm}^2$ .<sup>11,23</sup> As most *in vivo* skin experiments are performed on the arm, it can be stated that with regard to follicular density, the porcine ear skin is well suitable as *ex vivo* skin model. Other models of animal skin are less suitable compared

to human skin due to their much higher density of follicles per  $\text{cm}^2$ , which is, for example, 367 in dogs, 627 in cats, 1598 in rats, and approx. 1728 in rabbits.<sup>15</sup>

A further similarity between porcine skin and human skin is that the hair follicles undergo the same growth cycle and the hairs show the same growth stages.<sup>16</sup> At any given time, the vast majority of the hair follicle in healthy human scalp are considered to be in the anagen stage (80%–90%) and between 10% and 20% in the telogen one.<sup>24</sup> In the present study, 64% of the total number of follicles was found to be in the anagen stage and 36% were in the telogen phase. No data were found to compare our results with other studies in pig skin. These results are interesting for future skin penetration studies using pig skin as a model because in previous studies, it could be demonstrated that the growth stage of a hair follicle has an influence on the penetration process. It was shown that only hair follicles, which are in the anagen stage and thus show hair growth activity, are open for follicular penetration.<sup>12</sup>

As already described in the introduction part, different areas of the hair follicle are of specific interest for new therapeutic approaches. Selective targeting of these areas within the hair follicle can be reached by selecting a specifically sized drug delivery system such as nanocarriers.<sup>25</sup> Therefore, it is crucial to know the exact localization of the corresponding structure within the hair follicle. In principle, the structure of human and porcine hair follicles is comparable as both provide an infundibulum, an isthmus, a bulge region, and a bulb region. A sebaceous gland and an erector pili muscle are also associated with the hair follicles of both species.<sup>25</sup> It has not been investigated if these structures within the hair follicles are localized in the same position and have a comparable size in human and porcine hair follicles.

In the present study, we decided to classify the hair follicles into two groups (group 1:  $>2000 \mu\text{m}$  and group 2:  $<2000 \mu\text{m}$ ), as

classification into terminal and vellus hairs as available for human hair follicles is not usual in pigs.

The average length for the hairs of group 1 (>2000  $\mu\text{m}$ ) was  $2427 \pm 275 \mu\text{m}$ , the average length for hairs of group 2 (<2000  $\mu\text{m}$ ) was  $1458 \pm 297 \mu\text{m}$ . In humans, the total length of terminal hairs in the anagen stage is even greater, with a mean dermal depth of approx. 3000  $\mu\text{m}$ .<sup>10</sup> If we compare the results, we can see that in pig ear we can find hair follicles of great size just like in human skin. However, there is a variation in the length of the hair follicles of the pig skin, with an average length of  $1820 \pm 551 \mu\text{m}$ . In humans, the length of vellus hair follicles is smaller  $646 \pm 140 \mu\text{m}$ .<sup>10</sup> Vellus hairs, which are defined as short, non-pigmented and generally non-medullated hairs, were not found in the pig ear.<sup>26</sup>

The length of the infundibulum of the hair follicles in the anagen phase varied depending on the total length of the hair follicle. Hair follicles <2000  $\mu\text{m}$  had an infundibulum length of approximately  $373 \pm 72 \mu\text{m}$ , hair follicles >2000  $\mu\text{m}$  provided a longer infundibulum, with an average length of  $516 \pm 107 \mu\text{m}$ . These results are in concordance with previous studies in pigs, where the length of the infundibulum was approximately 500  $\mu\text{m}$ .<sup>16</sup> In humans, the length of the infundibulum is comparable with an average value of 500  $\mu\text{m}$  in terminal hairs, which are in the anagen phase. The length of the infundibulum in human vellus hair is  $225 \pm 34 \mu\text{m}$ .<sup>10</sup>

Due to the importance of the bulge region as a reservoir of stem cells, which participate in the process of proliferation and regeneration of both the hair follicles and the epidermis,<sup>27</sup> the position and length of the bulge region were also studied. In pig hair follicles, the bulge region was located at  $881 \pm 208 \mu\text{m}$  from the skin surface and in humans at  $1191 \pm 23 \mu\text{m}$ , which is well comparable. The length of the bulge region was also well comparable in porcine hair follicles and human hair follicles ( $272 \pm 36 \mu\text{m}$  and  $240 \pm 52 \mu\text{m}$ ).<sup>10</sup>

The follicular orifice on the skin surface also demonstrated similarity between porcine ear skin and human skin. Concerning the diameter of the entrance hole of the follicle in the infundibular area, in pigs, the opening diameter of the follicle was  $113 \pm 2 \mu\text{m}$  and in humans  $172 \pm 70 \mu\text{m}$ .

Additionally, the thickness of the follicular epithelium in the area of the infundibulum was determined and was shown to decrease continuously with increasing depth of the hair follicle. This phenomenon can also be observed in human follicles.<sup>16</sup> Data for human and porcine hair follicles were demonstrated to be relatively comparable (upper part of hair follicle: human 65  $\mu\text{m}$ , pig: 59  $\mu\text{m}$ ; distal part of infundibulum: human 53  $\mu\text{m}$ , pig: 46  $\mu\text{m}$ ).<sup>10</sup> The thickness of the interfollicular epidermis was approximately 100  $\mu\text{m}$  in the present study. In other studies, also performed with pig skin, values of 72  $\mu\text{m}$  were given.<sup>16</sup> However, both results are similar to human data available although the thickness of interfollicular epidermis also varies according to the region of the body: buttock 97  $\mu\text{m}$ , shoulder 81  $\mu\text{m}$ , scalp and retroauricular region 136  $\mu\text{m}$ , forearm dorsal 75  $\mu\text{m}$ .<sup>10,28</sup>

However, all studies confirmed that the thickness of the infundibular epithelium is lower than the thickness of the interfollicular

epidermis with decreasing thickness in the lower part of the infundibulum. Therefore, it can be assumed that the barrier properties continuously decrease inside the hair follicles with increasing depth and that percutaneous absorption can be enhanced when substances reach deeper parts of the hair follicles.

## 5 | CONCLUSION

In summary, our results reveal that the morphometric characteristics of the central part of the porcine hair follicles have good similarity with the human hair follicles. Thus, it can be stated that the porcine ear skin is a good ex vivo skin model for skin penetration studies. Furthermore, it can be concluded that, apart from the follicular density, there are no significant differences in the investigated morphometric data of the hair follicles between the 3 areas of the central ear.

## ACKNOWLEDGMENTS

We would like to thank Mr Gerald Nusche for providing the porcine ears for the experiments. Open access funding enabled and organized by ProjektDEAL.

## ORCID

Anna Lena Klein  <https://orcid.org/0000-0002-8169-2541>

Alexa Patzelt  <https://orcid.org/0000-0002-8350-6757>

## REFERENCES

- Vogt A, Blume-Peytavi U. Die Biologie des menschlichen Haarfollikels. *Der Hautarzt*. 2003;54(8):692-698.
- Lademann J, Richter H, Meinke M, Sterry W, Patzelt A. Which skin model is the most appropriate for the investigation of topically applied substances into the hair follicles? *Skin Pharmacol Physiol*. 2010;23(1):47-52.
- Wosicka H, Cal K. Targeting to the hair follicles: current status and potential. *J Dermatol Sci*. 2010;57(2):83-89.
- Otberg N, Teichmann A, Rasuljev U, Sinkgraven R, Sterry W, Lademann J. Follicular penetration of topically applied caffeine via a shampoo formulation. *Skin Pharmacol Physiology*. 2007;20(4):195-198.
- Mak WC, Patzelt A, Richter H, et al. Triggering of drug release of particles in hair follicles. *J Controlled Release*. 2012;160(3):509-514.
- Grazu V, Moros M, Sánchez-Espinel C. Nanocarriers as nanomedicines: design concepts and recent advances. *Front Nanosci*. Elsevier; 2012;4:337-440.
- Nohynek GJ, Lademann J, Ribaud C, Roberts MS. Grey goo on the skin? Nanotechnology, cosmetic and sunscreen safety. *Crit Rev Toxicol*. 2007;37(3):251-277.
- Lademann J, Patzelt A, Schanzer S, et al. Non-invasive analysis of penetration and storage of isoconazole nitrate in the stratum corneum and the hair follicles. *Eur J Pharm Biopharm*. 2012;80(3):615-620.
- Patzelt A, Richter H, Knorr F, et al. Selective follicular targeting by modification of the particle sizes. *J Controlled Release*. 2011;150(1):45-48.
- Vogt A, Hadam S, Heiderhoff M, et al. Morphometry of human terminal and vellus hair follicles. *Exp Dermatol*. 2007;16(11):946-950.

11. Hueber F, Schaefer H, Wepierre J. Role of transepidermal and trans-follicular routes in percutaneous absorption of steroids: in vitro studies on human skin. *J Skin Pharmacol Physiol*. 1994;7(5):237-244.
12. Lademann J, Otberg N, Jacobi U, Hoffman RM, Blume-Peytavi U. Follicular penetration and targeting. *J Investig Dermatol Symp Proc*. 2005;10(3):301-303.
13. Jacobi U, Toll R, Sterry W, Lademann J. Do follicles play a role as penetration pathways in in vitro studies on porcine skin?-. An optical study. *Laser Phys*. 2005;15(11):1594-1598.
14. Patzelt A, Richter H, Buettemeyer R, et al. Differential stripping demonstrates a significant reduction of the hair follicle reservoir in vitro compared to in vivo. *Eur J Pharm Biopharm*. 2008;70(1):234-238.
15. Mangelsdorf S, Vergou T, Sterry W, Lademann J, Patzelt A. Comparative study of hair follicle morphology in eight mammalian species and humans. *Skin Research Technology*. 2014;20(2):147-154.
16. Jacobi U, Kaiser M, Toll R, et al. Porcine ear skin: an in vitro model for human skin. *Skin Research Technology*. 2007;13(1):19-24.
17. Frum Y, Eccleston GM, Meidan VM. In-vitro permeation of drugs into porcine hair follicles: is it quantitatively equivalent to permeation into human hair follicles? *J Pharm Pharmacol*. 2008;60(2):145-151.
18. Schmook FP, Meingassner JG, Billich A. Comparison of human skin or epidermis models with human and animal skin in in-vitro percutaneous absorption. *Int J Pharm*. 2001;215(1-2):51-56.
19. Alonso L, Fuchs E. The hair cycle. *J Cell Sci*. 2006;119(119):391-393.
20. Wang X, Shi Y, Zhou Q, Liu X, Xu S, Lei T. Detailed histological structure of human hair follicle bulge region at different ages: a visible niche for nesting adult stem cells. *J Huazhong Univ Sci Technol*. 2012;32(5):648-656.
21. Turner NJ, Pezzone D, Badylak SF. Regional variations in the histology of porcine skin. *Tissue Eng Part C Methods*. 2015;21(4):373-384.
22. Meyer W, Kacza J, Zschemisch N-H, Godynicki S, Seeger J. Observations on the actual structural conditions in the stratum superficiale dermidis of porcine ear skin, with special reference to its use as model for human skin. *J Ann Anat-Anatomischer Anzeiger*. 2007;189(2):143-156.
23. Otberg N, Richter H, Schaefer H, Blume-Peytavi U, Sterry W, Lademann J. Variations of hair follicle size and distribution in different body sites. *J Investig Dermatol*. 2004;122(1):14-19.
24. Oh JW, Kloepper J, Langan EA, et al. A guide to studying human hair follicle cycling in vivo. *J Investig Dermatol*. 2016;136(1):34-44.
25. Patzelt A, Knorr F, Blume-Peytavi U, Sterry W, Lademann J. Hair follicles, their disorders and their opportunities. *Drug Discovery Today Dis Mechanisms*. 2008;5(2):e173-e181.
26. Erdogan B. Anatomy and Physiology of Hair. 2017.
27. Ohyama M. Hair follicle bulge: a fascinating reservoir of epithelial stem cells. *J Dermatol Sci*. 2007;46(2):81-89.
28. Sandby-Moller J, Poulsen T, Wulf HC. Epidermal thickness at different body sites: relationship to age, gender, pigmentation, blood content, skin type and smoking habits. *Acta Derm Venereol*. 2003;83(6):410-413.

**How to cite this article:** Zambrano A, Klein AL, Patzelt A. Analysis of the morphometric parameters of pig ear hair follicles. *Skin Res Technol*. 2021;00:1-9. <https://doi.org/10.1111/srt.13008>

## **Lebenslauf**

Mein Lebenslauf wird aus datenschutzrechtlichen Gründen in der elektronischen Version meiner Arbeit nicht veröffentlicht

Mein Lebenslauf wird aus datenschutzrechtlichen Gründen in der elektronischen Version meiner Arbeit nicht veröffentlicht

## Publikationliste

1. Zambrano A, Klein AL, Patzelt A. Analysis of the morphometric parameters of pig ear hair follicles. *Skin Research and Technology*. 2021; 00:1-9.

## Danksagung

An dieser Stelle möchte ich die Gelegenheit nutzen, um meiner Betreuerin Frau PD Dr. med. Alexa Patzelt recht herzlich zu danken. Sie hat mir die Möglichkeit gegeben, diese Arbeit durchzuführen. Vielen Dank für Ihre Geduld, Motivationen, Anregungen, Hilfestellungen und Unterstützung und sehr wichtig, danke für Ihre Zeit.

Danke an das Arbeitsteam des Center of Experimental and Applied Cutaneous Physiology (CCP). Ihr habt die Arbeitsatmosphäre jeden Tag angenehm gemacht und wart immer bereit zu helfen.

Und nicht zuletzt danke ich meinem Mann für seine Unterstützung und den stetigen Glauben an mich. Er hat mir die Kraft und den Rückhalt gegeben, um die Balance zwischen Familie, Freunden, Berufsleben und der Doktorarbeit zu finden.