



# Movement disorders after hypoxic brain injury following cardiac arrest in adults

F. Scheibe<sup>a,b,c</sup> , W. J. Neumann<sup>a,d</sup>, C. Lange<sup>e</sup>, M. Scheel<sup>d</sup>, C. Furth<sup>e</sup>, M. Köhnlein<sup>a</sup>, P. Mergenthaler<sup>a,b,f,g</sup> , J. Schultze-Amberger<sup>h</sup>, P. Triebkorn<sup>a,f,i</sup>, P. Ritter<sup>a,f,i</sup>, A. A. Kühn<sup>a</sup> and A. Meisel<sup>a,b,g</sup>

<sup>a</sup>Department of Neurology, Charité – Universitätsmedizin Berlin, Berlin; <sup>b</sup>NeuroCure Clinical Research Center, Charité – Universitätsmedizin Berlin, Berlin; <sup>c</sup>German Center for Neurodegenerative Diseases (DZNE), Berlin; <sup>d</sup>Department of Radiology, Charité – Universitätsmedizin Berlin, Berlin; <sup>e</sup>Department of Nuclear Medicine, Charité – Universitätsmedizin Berlin, Berlin; <sup>f</sup>Berlin Institute of Health, Charité – Universitätsmedizin Berlin, Berlin; <sup>g</sup>Center for Stroke Research Berlin, Charité – Universitätsmedizin Berlin, Berlin; <sup>h</sup>Neurorehabilitation Center Berlin-Kladow, Berlin, and <sup>i</sup>Bernstein Center for Computational Neuroscience, Berlin, Germany

## Keywords:

cardiac arrest, hypoxic-  
ischaemic  
encephalopathy,  
intrathecal baclofen,  
levomepromazine,  
myoclonus, post-hypoxic  
movement disorder

Received 3 March 2020  
Accepted 7 May 2020

*European Journal of  
Neurology* 2020, **27**: 1937–  
1947

doi:10.1111/ene.14326

**Background and purpose:** Post-hypoxic movement disorders and chronic post-hypoxic myoclonus are rare complications after cardiac arrest in adults. Our study investigates the clinical spectrum, neuroimaging results, therapy and prognosis of these debilitating post-hypoxic sequelae.

**Methods:** This retrospective study included 72 patients from the neurological intensive care unit at a university hospital, who were diagnosed with hypoxic-ischaemic encephalopathy after cardiac arrest between January 2007 and September 2018. Clinical records were screened for occurrence of post-hypoxic movement disorders and chronic post-hypoxic myoclonus. Affected patients were further analysed for applied neuroprognostic tests, administered therapy and treatment response, and the outcome of these movement disorders and neurological function.

**Results:** Nineteen out of 72 screened patients exhibited post-hypoxic motor symptoms. Basal ganglia injury was the most likely neuroanatomical correlate of movement disorders as indicated by T1 hyperintensities and hypometabolism of this region in magnetic resonance imaging and positron emission tomography computed tomography. Levomepromazine and intrathecal baclofen showed first promising and mostly prompt responses to control these post-hypoxic movement disorders and even hyperkinetic storms. In contrast, chronic post-hypoxic myoclonus best responded to co-application of clonazepam, levetiracetam and primidone. Remission rates of post-hypoxic movement disorders and chronic post-hypoxic myoclonus were 58% and 50%, respectively. Affected patients seemed to present a rather good recovery of cognitive functions in contrast to the often more severe physical deficits.

**Conclusions:** Post-hypoxic movement disorders associated with pronounced basal ganglia dysfunction might be efficiently controlled by levomepromazine or intrathecal baclofen. Their occurrence might be an indicator for a more unfavourable, but often not devastating, neurological outcome.

## Introduction

Sudden cardiac arrest is a frequent cause of death with an incidence of 55/100 000 per year and survival rates of ~22% [1]. In a subpopulation of survivors, recovery is severely compromised by the development of rare hyperkinetic or hypokinetic motor symptoms

Correspondence: F. Scheibe, Department of Neurology, Charité – Universitätsmedizin Berlin, Charitéplatz 1, 10117 Berlin, Germany (tel.: +4930450660406; fax: +49304507530902; e-mail: franziska.scheibe@charite.de).

comprising post-hypoxic movement disorder (PMD) and/or chronic post-hypoxic myoclonus (CPM) (Lance–Adams syndrome) [2,3]. The clinical spectrum of PMD involves post-hypoxic dystonia, ballism, choreoathetosis or akinetic-rigid syndrome [2] that can exacerbate to therapy-resistant hyperkinetic storms [4]. CPM presents with focal or generalized, stimulus-sensitive myoclonic jerks beginning a couple of days to weeks after cardiac arrest without reliable correlate in electroencephalography (EEG) [5]. In contrast, acute post-hypoxic myoclonus occurs within the first 24 h after cardiac arrest and displays typical EEG findings [6].

The therapy of these often hard to treat movement disorders still relies on smaller case studies. PMD treatment is based on medications used for isolated and combined dystonia (e.g. benzhexol, pimozide, tetra-benazine) first described by Marsden *et al.* [7], but their use is compromised by side effects and limited treatment response. Other medications (e.g. opioids, benzodiazepines, clonidine, tiapride, trihexyphenidyl) have been suggested over the last decades, but with inconsistent results [8]. The current literature for therapy of CPM recommends the application of anticonvulsants like clonazepam, levetiracetam, piracetam and valproate leading to partial reduction of myoclonus, but frequently incomplete symptom control [9].

Over the last few years, advances in medicine including targeted temperature management increased the frequency of successful resuscitation and survival after cardiac arrest [1], probably resulting in consecutive increases of PMD and CPM on intensive care units (ICUs). There, patients are mostly treated by intensivists who are often not familiar with these disorders. Since these motor phenomena are often regarded as poorly treatable, these patients are at increased risk to be misjudged as having a poor prognosis resulting in early end-of-life decisions with premature withdrawal or withholding of ICU therapy.

To obtain deeper insights into the pathophysiology, treatment responses and outcome of patients with chronic PMD including myoclonus, our study investigated the clinical features, neuroimaging results, therapy and prognosis of these movement disorders and the neurological outcome of PMD/CPM patients after cardiac arrest.

## Materials and methods

### Study design

This retrospective study included all patients treated on the neurological ICU at Charité – University Hospital Berlin (Germany) between January 2007 and

September 2018 who were diagnosed with hypoxic-ischaemic encephalopathy after cardiac arrest. Most patients were referred from other Charité ICUs or external hospitals for management of post-hypoxic motor symptoms, for neuroprognostication and after surviving the acute phase following cardiac arrest. Records of all patients were analysed for demographic data, overall survival and occurrence of PMD and CPM. The classification into PMD, PMD + CPM and CPM patients was chosen to allow a straightforward differentiation of the respective motor phenomena according to their semiology with respect to the different treatment requirements. Patients with PMD and/or CPM received more detailed chart review with analysis of neuroprognostic testing (neuron-specific enolase, EEG, somatosensory-evoked potentials, neuroimaging), applied therapy and treatment response, as well as outcome assessment of movement disorders and neurological function. Encephalitis panel testing for 21 antigens of serum and cerebrospinal fluid (CSF) samples were analysed by either Euroimmun (Lübeck, Germany) or Labor Berlin (Berlin, Germany).

### Neuroimaging studies

Computed tomography based grey/white matter ratios were determined by a neuroradiologist as described previously (a cut-off < 1.16 predicted poor outcome) [10]. Magnetic resonance imaging (MRI) scans were carried out on different MRI scanners (1.5 or 3 T, Siemens, Erlangen, Germany) with standard clinical imaging protocols (including T2w, diffusion weighted, susceptibility weighted, and T1w pre- and post-contrast) and were analysed by experienced neuroradiologists.

Cerebral positron emission tomography computed tomography (PET-CT) was performed with  $236 \pm 73$  MBq of the glucose analogue F-18-fluorodeoxyglucose on a Gemini TF16 PET/CT (Philips Medical Systems, Best, The Netherlands). Spatial resolution in the reconstructed PET images was about 7 mm for full width at half maximum. Reconstructed PET data were preprocessed as previously described [11] and repeated with other reference regions, i.e. whole brain parenchyma, pons and cerebellum, to compare the effect of anaesthetics on the sensitivity of statistical testing. Region-of-interest-wise calculation of mean F-18-fluorodeoxyglucose uptake was derived from the automatic anatomic labelling atlas using masks of the caudate nucleus, anterior/posterior putamen, thalamus, pons, midbrain and medulla oblongata. Each subject was compared against a group of 32 healthy controls on a voxel-by-voxel basis using the two-sample *t* test implemented in statistical

parametric maps with age as covariate [11]. Cortical areas and the cerebellum were excluded from voxel-wise analysis due to the effects of anaesthetics.

### Magnetic resonance imaging preprocessing and lesion analysis

For patients with available non-contrast enhanced T1-weighted MRI acquisitions ( $n = 16$ ), manual lesion segmentation was performed using ITK-Snap (<http://www.itksnap.org>) [12]. In these patients, MRI scans were transformed to MNI 2009b NLIN ASYM space using the advanced normalization pipeline of the in-house LEAD-DBS toolbox version 2.3 ([www.lead-dbs.org](http://www.lead-dbs.org)) [13]. The pipeline is specifically validated for optimal transformation of subcortical nuclei and is based on the symmetric image normalization method (SyN) provided with the advanced normalization tools (<http://stnava.github.io/ANTs/>). The derived normalization was applied to the lesion segmentations and a lesion heatmap was created by calculating voxel-wise sums across patients. Statistical analyses by group-wise comparison of signal alterations and lesion topography on these images were not done, as acquisition parameters and scan time point with respect to hypoxic and demographic parameters were very heterogeneous. The imaging alterations shown may be related to various factors.

### Therapy regimen and treatment response

Since assessment of treatment response for applied medications was complicated by the lack of movement disorder severity scales/scores acknowledging the requirements of critically ill ICU patients such as sedation depth or artificial ventilation, the degree of symptom control was evaluated by the following simplified categories: (i) sufficient control (complete/nearly complete symptom remission; termination of sedation allowing weaning from the respirator), (ii) moderate control (substantial symptom improvement; moderate reduction of sedation), (iii) mild improvement (slight symptom control; no/only mild reduction of sedation), (iv) no effect and (v) worsening.

### Outcome assessment

Long-term follow-up of PMD, CPM and final neurological outcome was performed by structured telephone interview of patients and/or their legal guardians, review of hospital records and inquiries of the date of death from state authorities. A board-certified and ICU-experienced neurologist assessed patients' neurological status after ICU discharge by

neurological outcome scores like the Barthel Index, modified Rankin Scale, Glasgow Outcome Scale – Extended and outcome of cognitive function. Severity of cognitive dysfunction was classified as unresponsive wakefulness syndrome, minimal conscious state (MCS) or better than MCS and was evaluated by a questionnaire with items of the Coma Recovery Scale – Revised during a structured telephone interview [14] and/or from information of readmission/discharge letters. Intensity, onset and if applicable time point of remission of PMD and/or CPM were recorded.

### Statistical analysis

Data are presented as mean  $\pm$  standard deviation if not otherwise specified. Differences in patient age, sex, duration on ICU and duration of artificial ventilation were statistically evaluated by Kruskal–Wallis analysis with Dunn's *post hoc* test. Statistical analysis of survival rates was performed by the log-rank test.  $P$  values  $\leq 0.05$  were regarded as statistically significant.

### Standard protocol approvals and patient consent forms

The study was approved by our institutional ethics committee. Patients and/or their legal guardians gave their informed consent for participation in the study and for publication.

## Results

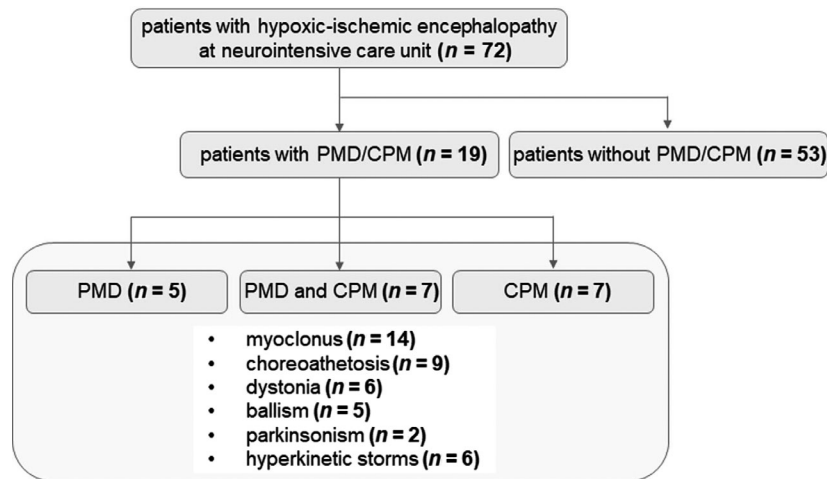
### Patient characteristics and clinical spectrum of PMD and CPM

Demographic data of the 72 identified patients with hypoxic-ischaemic encephalopathy comprised a gender ratio male/female of 54%/46% ( $n = 39/33$ ), age at disease onset  $55 \pm 19$  years; the overall survival rate reached 36% ( $n = 26$ ) during a median observation period of 27 months (range 4–139 months) (Table 1). As a subgroup, 26.4% of patients ( $n = 19$ ) developed PMD and/or CPM. These patients were subjected to further analysis (Fig. 1): 6.9% exhibited PMD ( $n = 5$ ), 9.7% PMD + CPM ( $n = 7$ ) and 9.7% isolated CPM ( $n = 7$ ). Patients with PMD and/or CPM showed a variable, partly mixed clinical phenotype encompassing CPM ( $n = 14$ ), choreoathetosis ( $n = 9$ ), dystonia ( $n = 6$ ), ballism ( $n = 5$ ) or parkinsonism ( $n = 2$ ) that exacerbated to therapy-refractory hyperkinetic storms in 50% of PMD patients ( $n = 6$ ). Patients with and without movement disorders showed no differences concerning age and gender distribution, but survival rates of 63% of PMD/CPM patients ( $n = 12$  of 19)

**Table 1** Characteristics of patient cohort

	PMD ( <i>n</i> = 5)	PMD + CPM ( <i>n</i> = 7)	CPM ( <i>n</i> = 7)	All PMD/CPM patients ( <i>n</i> = 19)	All patients ( <i>n</i> = 72)
Patient age (years)	37 ± 14	46 ± 21	45 ± 23	43 ± 19	55 ± 19
Male, <i>n</i> (%)	3 (60)	5 (71)	4 (57)	12 (63)	39 (54)
Survival, <i>n</i> (%)	5 (100)	3 (43)	4 (57)	12 (63)*	26 (36)
Duration on ICU (days)	148 ± 93*	120 ± 69	39 ± 15	97 ± 76	n.a.
Duration of artificial ventilation (days)	134 ± 103*	143 ± 48* ( <i>n</i> = 6) <sup>a</sup>	35 ± 18 ( <i>n</i> = 6) <sup>a</sup>	102 ± 78	n.a.

CPM, chronic post-hypoxic myoclonus; ICU, intensive care unit; n.a., detailed data were not available for a relevant proportion of patients; PMD, post-hypoxic movement disorder. <sup>a</sup>Duration of artificial ventilation was not documented in two patients. \**P* < 0.05.

**Figure 1** Frequency of post-hypoxic motor symptoms.

greatly exceeded the survival of patients with hypoxic-ischaemic encephalopathy without PMD/CPM (26%, *n* = 14 of 53, *P* = 0.005) (Table 1).

Patients with PMD had longer ICU stays than patients with PMD + CPM or CPM (*P* = 0.0126) and patients with PMD and PMD + CPM required longer durations of artificial ventilation than CPM patients (*P* = 0.0072) (Table 1). The most frequent type of cardiac arrest was ventricular fibrillation (*n* = 9), followed by asystole/pulseless electrical activity (*n* = 6) and cardiac arrest during cardiothoracic surgery (*n* = 3) (Table 2). The most common causes of cardiac arrest were myocardial infarction (*n* = 5), cardiothoracic surgery (*n* = 3) and pulmonary embolism (*n* = 2) (Table 2). The detailed results from neuroprognostic testing are presented in Table S1. CSF analysis was carried out in 11 out of 19 patients at a median time of 88 days (range 18–572 days) after cardiac arrest. All CSF samples showed normal acute parameters. The results of encephalitis panel testing of serum (*n* = 2) or serum and CSF (*n* = 5) did not reveal a concurrent autoimmune phenomenon as the cause of movement disorders.

### Neuroimaging results

Sixteen out of 19 PMD/CPM patients were investigated by MRI (three patients had MRI contraindications) at a median time of 25 days (range 5–580 days) after cardiac arrest (Table S1). Hypoxic brain damage induced moderate to severe loss of cortical volume with marked short-term progression, most prominent in the temporal, frontal and occipital lobe and basal ganglia. Moreover, post-hypoxic T1 hyperintensity of the lenticular nucleus, most prominently in the posterior parts of the putamen and pallidum, was observed in 15 of 16 patients (Fig. 2a). Less commonly, striatal T2/fluid-attenuated inversion recovery hyperintensity was seen. Further lesion overlap analysis with averaged T1 images (*n* = 16) showed marked hyperintensity of the posterior putamen and the internal and external pallidum. Signal alterations were accompanied by and probably reflective of atrophy of the entire lenticular and caudate nuclei (Fig. 2b).

Brain PET-CT (*n* = 8) demonstrated hypometabolism in the evaluated subcortical regions including the left caudate nucleus, bilateral anterior and posterior

**Table 2** Patient characteristics

No.	Age at CA	Sex	Type of CA	Cause of CA	Time until ROSC	Hypothermia $\leq 34^{\circ}\text{C}$	Duration on ICU (days)	
PMD	1	18	M	Ventricular fibrillation	Unknown	35–50 min	Yes	150
	2	27	F	Not documented	Status epilepticus/amitriptyline intoxication	30 min	Yes	130
	3	40	F	Ventricular fibrillation	Unknown	Unknown	Yes	301
	4	52	M	PEA/asystolia	Arterial lung embolism	25 min	No	53
	5	49	M	Ventricular fibrillation	Unknown	15–20 min	Yes	105
PMD + CPM	6	58	M	Ventricular fibrillation	Unknown	60 min	Yes	108
	7	26	M	Ventricular fibrillation	Myocardial infarction	15–20 min	Yes	181
	8	53	F	Cardiothoracic surgery	Bypass surgery with valve replacement/reconstruction	85 min	Yes (during surgery)	223
	9	28	M	Asystolia	Unknown	>30 min	Yes	141
	10	19	F	Cardiothoracic surgery	Fallot tetralogy	80 min	Yes (during surgery)	114
	11	68	M	Ventricular fibrillation	Dilatative cardiomyopathy	>25 min	Yes	33
	12	69	M	Cardiothoracic surgery	Stanford A/B aortal dissection	32 min	Yes (during surgery)	43
CPM	13	18	M	Asystolia	Myasthenic crisis with hypoxia-induced CA	6 min	Yes	35
	14	33	F	Asystolia/PEA	Arterial lung embolism	25 min	Yes	33
	15	21	M	Asystolia	Strangulation on a fence	Unknown	Yes	37
	16	83	F	Asystolia/PEA	Aspiration/myocardial infarction	27 min	Yes	48
	17	45	M	Ventricular fibrillation	Myocardial infarction	35 min	Yes	66
	18	55	M	Ventricular fibrillation	Myocardial infarction	15 min	Yes	21
	19	60	F	Ventricular fibrillation	Myocardial infarction	30–50 min	Yes	30

CA, cardiac arrest; CPM, chronic post-hypoxic myoclonus; F, female; ICU, intensive care unit; M, male; PEA, pulseless electrical activity; PMD, post-hypoxic movement disorder; ROSC, return of spontaneous circulation.

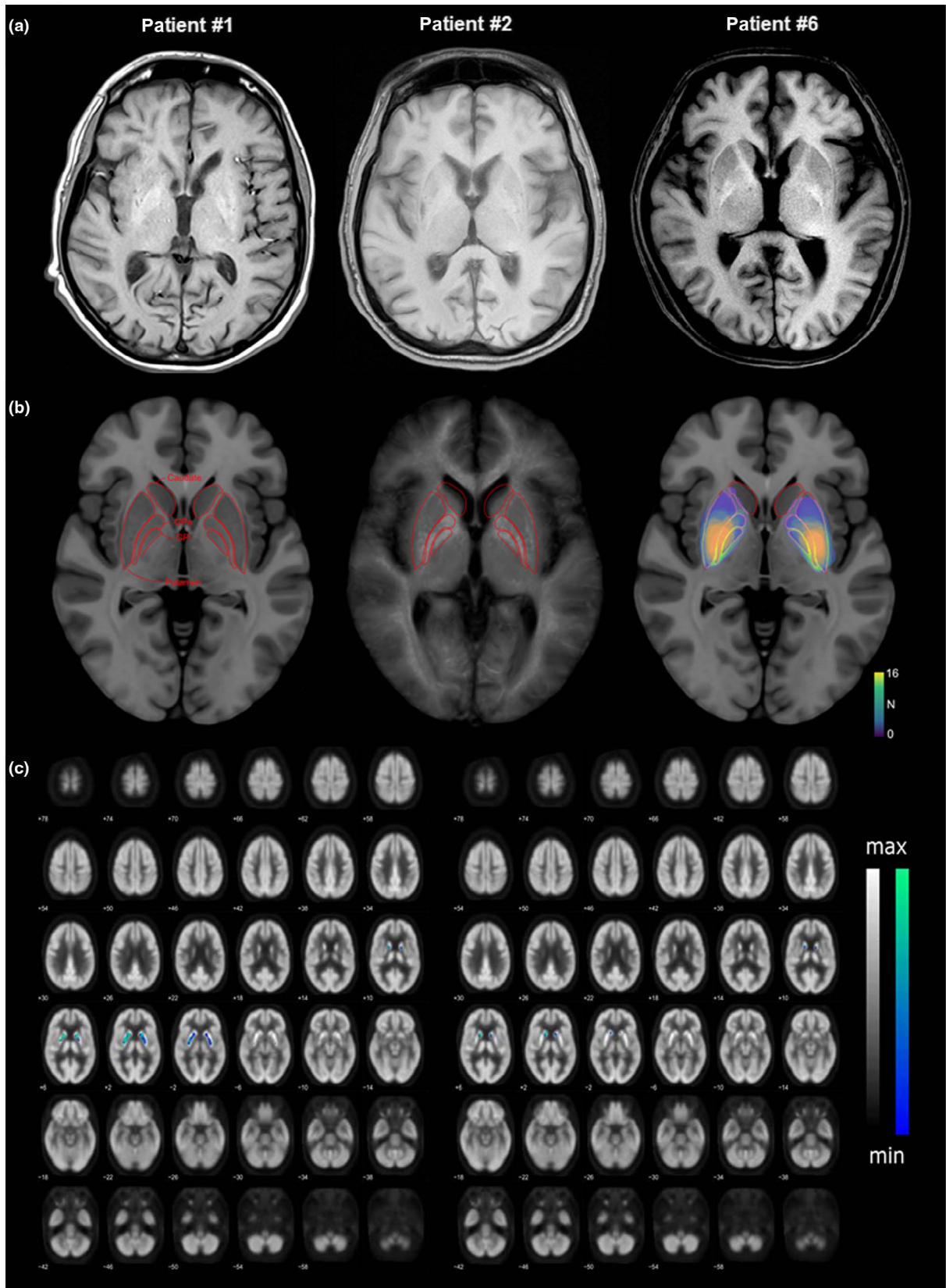
putamen, thalamus and pons, compared to healthy controls ( $P \leq 0.05$ ) (Fig. 2c, Table S2).

### Therapy of PMD and CPM

Post-hypoxic movement disorders could exacerbate to life-threatening hyperkinetic storms, mostly presenting as status dystonicus, partly associated with ballism and/or choreoathetosis, but no patient developed a post-anoxic myoclonic status. Initially, these patients required sedation to prevent self-injury (haematoma/skin abrasion, decannulation) by uncontrolled movements. Final control of movement disorders allowing sedation withdrawal was best achieved by the following treatments (Fig. 3a, Table S3): choreoathetosis and ballism were best controlled by tetrabenazine and akinetic-rigid symptoms by levodopa/benserazide. Levomepromazine was incidentally found to improve dystonia and was applied in dosages of up to 250 mg/day iv and 600 mg/day by mouth under QT<sub>c</sub> monitoring with good cardiac tolerability. Levomepromazine enabled complete or nearly complete symptom

remission in three patients (#2, 3, 5). Even in patients with hyperkinetic storms (#1, 2, 3, 6, 7, 10), levomepromazine terminated movement disorders in two patients (#2, 3) and achieved moderate control in three patients (#1, 6, 7). All PMD patients with limited treatment response (#1, 6, 7, 9) showed sufficient control of PMD after exposure to intrathecal baclofen by baclofen bump allowing termination of sedation and even reduction or stopping of other co-medications. Patient #10 presented a ballistic storm that could be controlled by tetrabenazine and clonazepam. Other medication like clonidine, tiapride, trihexyphenidyl, oral baclofen or tetrahydrocannabinol achieved no or only minor improvement. Remarkably, administration of typical and atypical neuroleptic drugs like haloperidol and olanzapine resulted in massive exacerbation of dystonia (#3, 7).

Best treatment results for therapy of CPM (Fig. 3b) were obtained after co-application of clonazepam, levetiracetam and primidone, partly supplemented by lacosamide (sufficient control  $n = 5$ , moderate control  $n = 7$ , mild/no effect  $n = 1$ ). The addition of valproate



**Figure 2** (a) Axial T1-weighted cerebral MR images of three patients (#1, 2, 6) demonstrated striatal and/or pallidal T1 hyperintensities. (b) Group level visualization of T1 hyperintensities. The left panel shows the MNI 2009b NLIN ASYM template at the height of the largest diameter of the internal segment of the pallidum. The distal atlas [31] is overlaid for orientation. The middle panel shows the averaged T1 signal across patients ( $n = 16$ ). Note the inverse relation of the T1 signal in the posterior part of the lenticular nucleus, spanning putamen, external and internal segment of the pallidum. Furthermore, relevant basal ganglia atrophy also of the caudate head can be appreciated. Finally, the right panel shows a heatmap of lesion location (colour map codes for the number of overlapping lesions across patients) that overlaps with the region of average T1 hyperintensity in the middle panel. (c) PET-CT comparison of eight patients against 32 healthy controls identified hypometabolism of the left caudate nuclei, bilateral putamen, thalamus and pons ( $P \leq 0.05$ , family-wise, error corrected). Results are plotted on a brain F-18-fluorodeoxyglucose-PET template without/with age as covariate in the left/right panel, respectively. [Colour figure can be viewed at wileyonlinelibrary.com]

( $n = 6$ ), piracetam ( $n = 4$ ) or carbamazepine ( $n = 2$ ) was less effective and resulted in only mild or no improvement.

**Neurological outcome and prognosis of PMD and CPM**

In all, 58% of PMD patients ( $n = 7$  of 12) and even 66% of all patients with hyperkinetic storms ( $n = 4$  of 6) yielded complete remission of symptoms at a median time period of 3 months (range 1–15 months) after cardiac arrest allowing discontinuation of PMD therapy (Table 3). Five patients had persisting PMD

sufficiently controlled by medication over a median follow-up time of 13 months (range 4–62 months). CPM was in remission in 50% of patients ( $n = 7$  of 14) after a median time of 3 months (range 1–6 months) and persisted in seven further patients during a median observation time of 18 months (range 3–62 months). The neurological outcome of the 19 PMD and/or CPM patients was associated with a disabling but not always devastating outcome (Table 3, Table S1). One patient reached a favourable outcome with a modified Rankin Scale (mRS) score of 3, 58% ( $n = 11$ ) had residual severe disability (mRS 4,  $n = 5$ ;

**(a) Therapy of posthypoxic movement disorder (PMD)**

Patient #	Sedation – Exacerbation phase					Medication – Acute and stabilisation phase													
	PRO	MID	LMZ	DXM	SUF	BAI	LMP	TBZ	CLZ	MO	CLO	TIA	THP	LB	BAO	THC	QUT	HP	OLA
1																			
2																			
3																			
4																			
5																			
6																			
7																			
8																			
9																			
10																			
11																			
12																			

**(b) Therapy of chronic posthypoxic myoclonus (CPM)**

Patient #	Sedation – Exacerbation phase					Medication – Acute and stabilisation phase							
	PRO	MID	LMZ	DXM	SUF	CLZ	LEV	PRI	LAC	VPA	PIR	CBZ	BAI
6													
7													
8													
9													
10													
11													
12													
13													
14													
15													
16													
17													
18													
19													

- Sufficient control
- Moderate control
- Mild improvement
- No effect
- Worsening
- Medication not applied

**Figure 3** Applied pharmacotherapy and evaluation of treatment responses for (a) PMD and (b) CPM. Left side, anaesthetic medication to suppress hyperkinetic storms; right side, medication for final control of motor symptoms. BAI, intrathecal baclofen; BAO, oral baclofen; CBZ, carbamazepine; CLO, clonidine; CLZ, clonazepam; DXM, dexmedetomidine; HP, haloperidol; LAC, lacosamide; LB, levodopa/benserazide; LEV, levetiracetam; LMP, levomepromazine; LMZ, lormetazepam; MID, midazolam; MO, morphine/opioids; OLA, olanzapine; PIR, piracetam; PRI, primidone; PRO, propofol; QUT, quetiapine; SUF, sufentanil; TBZ, tetrabenazine; THC, tetrahydrocannabinol; THP, trihexyphenidyl; TIA, tiapride; VPA, valproate. [Colour figure can be viewed at wileyonlinelibrary.com]

**Table 3** Summary of onset, severity, outcome of movement disorders, final neurological outcome and time of follow-up in PMD and CPM patients

No.	Phenotype of PMD/CPM	Onset after CA		Severity of		Final outcome		Final neurological outcome			Time of follow-up after CA
		PMD	CPM	PMD	CPM	PMD	CPM	BI	mRS	CF	
PMD											
1	Stimulus-sensitive generalized dystonia/opisthotonus, choreoathetosis <sup>a</sup>	20 days	-	++++	-	+++	-	0	5	MCS	1 year 2 months
2	Stimulus-sensitive generalized dystonia, choreoathetosis, ballism <sup>a</sup>	~14 days	-	++++	-	R (5 months)	-	65	4	>MCS	1 year 1 month
3	Stimulus-sensitive generalized dystonia/opisthotonus, choreoathetosis <sup>a</sup>	~30 days	-	++++	-	R (13 months)	-	0	5	MCS	4 years 7 months
4	Focal choreoathetosis of head and arms	~14 days	-	++	-	R (2 months)	-	95	3	>MCS	3 years
5	Stimulus-sensitive generalized dystonia/opisthotonus, ballism	~30 days	-	+++	-	+++	-	0	5	UWS	4 months
PMD + CPM											
6	Stimulus-sensitive generalized dystonia, choreoathetosis, CPM <sup>a</sup>	20 days	1 month	++++	+	+++	R (2 months)	40	4	>MCS	8 months
7	Stimulus-sensitive generalized choreoathetosis, ballism, dystonia/opisthotonus, CPM <sup>a</sup>	7 days	7 days	++++	+	R (15 months)	R (<5 months)	20	4	>MCS	1 year 1 month
8	Choreoathetosis, worsening of preexisting idiopathic Parkinson syndrome, CPM	8 days	6 days	+	+	R (1 month)	R (3 months)	0	6	MCS	7 months (†)
9	Stimulus-sensitive generalized dystonia and CPM	n.a.	1 day <sup>b</sup>	+++	+++	+++	++	0	6	UWS	5 years 2 months (†)
10	Choreoathetosis, ballism, CPM <sup>a</sup>	30 days	1 day <sup>b</sup>	++++	+++	R (3 months)	++	70	4	>MCS	4 months
11	Focal choreoathetosis/ballism of the head, CPM	13 days	13 days	+	+	R (1 month)	R (1 month)	70	6	>MCS	1 year 4 months (†)
12	Akinetic-rigid syndrome/tremor, CPM	4-9 months	1-4 months	++	++	++	++	0	6	>MCS	1 year 7 months (†)
CPM											
13	Stimulus-sensitive generalized CPM	-	1 month	-	+++	-	+++	0	5	MCS	1 year 7 months
14	Stimulus-sensitive generalized CPM	-	1 day <sup>b</sup>	-	++++	-	++	80	4	>MCS	4 years 7 months
15	Stimulus-sensitive generalized CPM	-	2 days <sup>b</sup>	-	+++	-	R (6 months)	0	6	UWS	2 years 8 months (†)
16	Stimulus-sensitive CPM of left neck, shoulder and arm	-	1 day <sup>b</sup>	-	+++	-	+++	0	6	UWS	3 months (†)
17	-	-	1 day <sup>b</sup>	-	+++	-	R (unknown)	0	5	UWS	4 years

(continued)



Table 3 (Continued)

No.	Phenotype of PMD/CPM	Onset after CA		Severity of		Final outcome		Final neurological outcome			Time of follow-up after CA
		PMD	CPM	PMD	CPM	PMD	CPM	BI	mRS	CF	
	Stimulus-sensitive CPM of right body and face										9 months
18	Stimulus-sensitive generalized CPM	-	5 days	-	+++	-	R (4 months)	0	6	UWS	3 years
19	Stimulus-sensitive generalized CPM	-	1 day <sup>b</sup>	-	+++	-	+	0	5	>MCS	11 months (†) 4 years 9 months

Severity assessment of PMD and CPM: +++++ very severe, +++ severe, ++ moderate, + mild, - absent. Outcome assessment of PMD and CPM: +++ sufficient control, ++ moderate control, + mild/insufficient improvement, R remission (with regard to time point after cardiac arrest), (†), death after CA; BI, Barthel Index; CA, cardiac arrest; CF, cognitive function; CPM, chronic post-hypoxic myoclonus; MCS, minimal conscious state; >MCS, emergence from minimal conscious state; mRS, modified Rankin Scale; PMD, post-hypoxic movement disorder; UWS, unresponsive wakefulness syndrome. <sup>a</sup> Patients who suffered from hyperkinetic storms; <sup>b</sup> in some cases, myoclonus after cardiac arrest incidentally started as acute post-hypoxic myoclonus (APM) with smooth transition to CPM after a latency of days to weeks that complicated exact determination of CPM onset. Therefore, the beginning of myoclonus (APM) is presented in these patients.

mRS 5,  $n = 6$ ) and 37% ( $n = 7$ ) died during a median observation period of 17 months (range 3–62 months). Nonetheless, partial restoration of everyday life abilities was reached in 37% of patients ( $n = 7$ ) as measured by the Barthel Index (score between 20 and 90 points). In contrast, cognitive function showed better recovery, and 47% of patients ( $n = 9$ ) emerged from MCS, 21% ( $n = 4$ ) remained in MCS, whereas 32% ( $n = 6$ ) persisted in an unresponsive wakefulness syndrome.

## Discussion

Our study investigated hypoxia-induced movement disorders after cardiac arrest and revealed that (i) these phenomena are currently under-reported as indicated by PMD and CPM frequencies of 16.7% and 19.4%, (ii) their occurrence is associated with structural basal ganglia dysfunction, (iii) levomepromazine and intrathecal baclofen might be promising novel treatment approaches to control PMD and (iv) their occurrence could be a surrogate marker for a better recovery of cognitive function, but more severe physical disabilities.

Current literature indicates that secondary movement disorders, especially combined dystonia and hyperkinetic storms, predominantly occur in children or younger adults with dyskinetic cerebral palsy [15], traumatic brain injury, encephalitis, cerebral ischaemia or haemorrhage [16]. In contrast, our study could not confirm a statistically significant age-specific effect of PMD manifestation after cardiac arrest which might be related to the inclusion of only adults and the small sample size of the cohort.

Pathophysiological concepts of PMD originate mostly from isolated dystonia and focus on differences of vascular supply, high oxidative metabolism, loss of inhibition, altered sensory gating and impaired plasticity of basal ganglia–thalamo–cortical circuits [17]. Since global hypoxia during cardiac arrest injures several brain regions involved in movement control, PMD probably reflects a neuronal network disorder with variable phenotypes depending on the injury pattern of affected neuroanatomical structures [18].

In line with the literature results, our MRI data revealed most prominent hypoxia-induced brain damage in the putamen and pallidum and less pronounced in the caudate nuclei and thalamus [19]. However, with the present archival dataset with varying imaging time points and sequence parameters, it was impossible to interpret these findings with respect to the patients' phenomenology. In the absence of a post-hypoxic non-movement disorders control group, it can only be stated that signal abnormalities were probably

associated with hypoxic neural injury of subcortical nuclei. In correspondence to MRI data, this first PET-CT case series in PMD identified hypometabolism in the putamen, thalamus and left caudate nucleus.

Currently, the therapy of PMD remains empiric and is often frustrating in clinical practice. Our study identified levomepromazine as a promising drug for treatment of post-hypoxic dystonia. Its mode of action remains speculative, but seems to rely on its capacity to inhibit serotonin 5HT<sub>2A</sub> and  $\alpha_1$ -adrenergic receptors, different dopamine receptors, H<sub>1</sub> receptors and muscarinic acetylcholine receptors [20,21]. In view of missing clinical trials and considering our clinical observations as class IV evidence, the following treatment regimen is recommended: dystonia can be treated with levomepromazine, choreoathetosis/ballism with tetrabenazine and akinetic-rigid syndromes with levodopa/benserazide. These mostly stimulus-sensitive movement disorders can reach further improvement by co-administration of opioids and benzodiazepines resulting in modification of sensory input control. The therapy of hyperkinetic storms requires a multistep concept. (i) Patients with predominant dystonia should first receive levomepromazine in combination with sedation (midazolam/propofol, sufentanil) and where appropriate (e.g. in the case of coexisting choreoathetosis/ballism) supplemented by tetrabenazine. (ii) Addition of opioids and benzodiazepines can further improve symptoms by reduction of sensory threshold. (iii) Medications like tiapride, trihexyphenidyl, oral baclofen or others can be optionally applied within the first 4 weeks. (iv) Patients with insufficient sedation withdrawal during this time, prominent dystonia or coexisting spasticity should be considered for intrathecal baclofen testing followed by baclofen pump implantation in the case of a positive therapeutic response. The suspected mechanism of intrathecal baclofen in dystonia hypothesizes potential inhibition of excessive stimulation in supplementary motor and premotor cortex by thalamic efferents [22]. The therapeutic effect of intrathecal baclofen has been reported in patients with dyskinetic cerebral palsy [22], but so far in only one adult patient with hypoxic-ischaemic encephalopathy after cardiac arrest [23].

Due to a selection bias, survival rates of our cohort after cardiac arrest were higher compared to the literature since many patients were referred after surviving the initial phase after cardiac arrest. Interestingly, PMD and CPM presented an unexpected favourable prognosis with remission rates  $\geq 50\%$ , but their value on prediction of neurological prognosis of hypoxic-ischaemic encephalopathy is currently unclear.

Nonetheless, the neurological outcome of the patients was rather unfavourable, but not devastating as previously thought. Noteworthy, it is also reported that 10% of patients with acute post-hypoxic myoclonus could reach good outcomes [24] indicating that post-hypoxic motor phenomena should not be considered as a sign of futility in general. This assumption should be reserved to patients with additional unfavourable neuroprognostic parameters (e.g. acute post-hypoxic myoclonic status) in line with current neuroprognostic guidelines after cardiac arrest [25–27].

The limitations of this study comprise the retrospective study design, small sample size and single centre experience. Also, clinical classification of the respective motor phenomena can be very challenging since the distinct clinical semiologies can be hard to distinguish and underlie a certain inter-rater variability, especially in acute post-hypoxic myoclonus [28,29]. Assessment of therapy response was impaired by an observer bias and the use of a non-validated scale since standard movement disorder severity scales like the Burke–Fahn–Marsden dystonia rating scale [30] are not eligible in the ICU setting.

## Conclusions

Post-hypoxic movement disorders after cardiac arrest are under-reported phenomena most probably related to basal ganglia dysfunction. Levomepromazine and intrathecal baclofen showed first promising results to treat these often therapy-refractory movement disorders, but our findings warrant prospective clinical trials and further imaging studies to improve the scientific foundation and therapeutic management of these disabling movement disorders.

## Acknowledgements

The study was funded by NeuroCure Excellence Cluster (EXC 257). P.R. was funded by H2020 Research and Innovation Action grants VirtualBrainCloud 826421, Human Brain Project 650003, 785907 and ERC 683049; German Research Foundation CRC 1315, grant RI 2073/6-1; Berlin Institute of Health and Foundation Charité, Johanna Quandt Excellence Initiative.

## Disclosure of conflicts of interest

Dr Mergenthaler reports grants from Bundesministerium für Bildung und Forschung, grants from Else Kröner Fresenius Stiftung, grants from European Commission H2020, other from Health Next Gen Inc. All other authors report no disclosures.

### Data availability statement

The data that support the findings of this study are available from the corresponding author upon reasonable request.

### Supporting Information

Additional Supporting Information may be found in the online version of this article:

**Table S1.** Neuroprognostic evaluation and final neurological outcome of patients with post-hypoxic movement disorder (PMD) and chronic post-hypoxic myoclonus (CPM)

**Table S2.** PET-CT results including group comparison with respect to regional F-18-fluorodeoxyglucose uptake scaled to global mean

**Table S3.** Detailed pharmacotherapy of patients with post-hypoxic movement disorder (PMD) and chronic post-hypoxic myoclonus (CPM)

### References

- Girotra S, Nallamothu BK, Spertus JA, *et al.* Trends in survival after in-hospital cardiac arrest. *N Engl J Med* 2012; **367**: 1912–1920.
- Lu-Emerson C, Khot S. Neurological sequelae of hypoxic-ischemic brain injury. *NeuroRehabilitation* 2010; **26**: 35–45.
- van Zijl JC, Beudel M, vd Hoeven HJ, Lange F, Tijssen MAJ, Elting JWJ. Electroencephalographic findings in posthypoxic myoclonus. *J Intensive Care Med* 2016; **31**: 270–275.
- Manji H, Howard RS, Miller DH, *et al.* Status dystonicus: the syndrome and its management. *Brain* 1998; **121**: 243–252.
- English WA, Giffin NJ, Nolan JP. Myoclonus after cardiac arrest: pitfalls in diagnosis and prognosis. *Anaesthesia* 2009; **64**: 908–911.
- Venkatesan A, Frucht S. Movement disorders after resuscitation from cardiac arrest. *Neurol Clin* 2006; **24**: 123–132.
- Marsden CD, Marion MH, Quinn N. The treatment of severe dystonia in children and adults. *J Neurol Neurosurg Psychiatry* 1984; **47**: 1166–1173.
- Fehlings D, Brown L, Harvey A, *et al.* Pharmacological and neurosurgical interventions for managing dystonia in cerebral palsy: a systematic review. *Dev Med Child Neurol* 2018; **60**: 356–366.
- Krauss GL, Bergin A, Kramer RE, Cho YW, Reich SG. Suppression of post-hypoxic and post-encephalitic myoclonus with levetiracetam. *Neurology* 2001; **56**: 411–412.
- Scheel M, Storm C, Gentsch A, *et al.* The prognostic value of gray-white-matter ratio in cardiac arrest patients treated with hypothermia. *Scand J Trauma Resusc Emerg Med* 2013; **21**: 23.
- Lange C, Suppa P, Frings L, Brenner W, Spies L, Buchert R. Optimization of statistical single subject analysis of brain FDG PET for the prognosis of mild cognitive impairment-to-Alzheimer's disease conversion. *J Alzheimers Dis* 2016; **49**: 945–959.
- Yushkevich PA, Piven J, Hazlett HC, *et al.* User-guided 3D active contour segmentation of anatomical structures: significantly improved efficiency and reliability. *NeuroImage* 2006; **31**: 1116–1128.
- Horn A, Li N, Dembek TA, *et al.* Lead-DBS v2: towards a comprehensive pipeline for deep brain stimulation imaging. *NeuroImage* 2019; **184**: 293–316.
- Petzinka VN, Endisch C, Streitberger KJ, *et al.* Unresponsive wakefulness or coma after cardiac arrest – a long-term follow-up study. *Resuscitation* 2018; **131**: 121–127.
- Monbaliu E, Himmelmann K, Lin JP, *et al.* Clinical presentation and management of dyskinetic cerebral palsy. *Lancet Neurol* 2017; **16**: 741–749.
- Scott BL, Jankovic J. Delayed-onset progressive movement disorders after static brain lesions. *Neurology* 1996; **46**: 68–74.
- Quartarone A, Hallett M. Emerging concepts in the physiological basis of dystonia. *Mov Disord* 2013; **28**: 958–967.
- Kojovic M, Paresi I, Kassavetis P, *et al.* Secondary and primary dystonia: pathophysiological differences. *Brain* 2013; **136**: 2038–2049.
- Bhatt MH, Obeso JA, Marsden CD. Time course of postanoxic akinetic-rigid and dystonic syndromes. *Neurology* 1993; **43**: 314–317.
- Green B, Pettit T, Faith L, Seaton K. Focus on levomepromazine. *Curr Med Res Opin* 2004; **20**: 1877–1881.
- Lal S, Nair NP, Cecyre D, Quirion R. Levomepromazine receptor binding profile in human brain – implications for treatment-resistant schizophrenia. *Acta Psychiatr Scand* 1993; **87**: 380–383.
- Albright AL. Intrathecal baclofen in cerebral palsy movement disorders. *J Child Neurol* 1996; **11**: S29–S35.
- Kuoppamaki M, Bhatia KP, Quinn N. Progressive delayed-onset dystonia after cerebral anoxic insult in adults. *Mov Disord* 2002; **17**: 1345–1349.
- Seder DB, Sunde K, Rubertsson S, *et al.* Neurologic outcomes and postresuscitation care of patients with myoclonus following cardiac arrest. *Crit Care Med* 2015; **43**: 965–972.
- Sandroni C, D'Arrigo S, Nolan JP. Prognostication after cardiac arrest. *Crit Care* 2018; **22**: 150.
- Ruijter BJ, Tjepkema-Cloostermans MC, Tromp SC, *et al.* Early electroencephalography for outcome prediction of postanoxic coma: a prospective cohort study. *Ann Neurol* 2019; **86**: 203–214.
- Wijdicks EF, Parisi JE, Sharbrough FW. Prognostic value of myoclonus status in comatose survivors of cardiac arrest. *Ann Neurol* 1994; **35**: 239–243.
- van Zijl JC, Beudel M, Elting JJ, *et al.* The inter-rater variability of clinical assessment in post-anoxic myoclonus. *Tremor Other Hyperkinet Mov* 2017; **7**: 470.
- Mikhaeil-Demo Y, Gavvala JR, Bellinski II, *et al.* Clinical classification of post anoxic myoclonic status. *Resuscitation* 2017; **119**: 76–80.
- Burke RE, Fahn S, Marsden CD, Bressman SB, Moskowitz C, Friedman J. Validity and reliability of a rating scale for the primary torsion dystonias. *Neurology* 1985; **35**: 73–77.
- Ewert S, Horn A, Finkel F, Li N, Kuhn AA, Herrington TM. Optimization and comparative evaluation of nonlinear deformation algorithms for atlas-based segmentation of DBS target nuclei. *NeuroImage* 2019; **184**: 586–598.