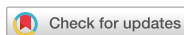

Original Article  
Internal Medicine



# Preliminary study on the effects of pergolide on left ventricular function in the horses with pituitary pars intermedia dysfunction

Heidrun Gehlen <sup>1</sup>, Judith Fisch <sup>1</sup>, Roswitha Merle <sup>2</sup>, Dagmar S. Trachsel <sup>1\*</sup>

<sup>1</sup>Department of Veterinary Medicine, Equine Clinic: Surgery and Radiology, Freie University Berlin, Berlin 14163, Germany

<sup>2</sup>Department of Veterinary Medicine, Institute for Veterinary Epidemiology and Biostatistics, Freie University Berlin, Berlin 14163, Germany



**Received:** Jan 8, 2021  
**Revised:** May 25, 2021  
**Accepted:** Jun 4, 2021  
Published online: Jul 23, 2021

**\*Corresponding author:**

**Dagmar S. Trachsel**

Department of Veterinary Medicine, Equine Clinic: Surgery and Radiology, Freie University Berlin, Oertzenweg 19B, Berlin 14163, Germany.  
E-mail: dagmarsenta.trachsel@fu-berlin.de

© 2021 The Korean Society of Veterinary Science

This is an Open Access article distributed under the terms of the Creative Commons Attribution Non-Commercial License (<https://creativecommons.org/licenses/by-nc/4.0>) which permits unrestricted non-commercial use, distribution, and reproduction in any medium, provided the original work is properly cited.


**ORCID iDs**

Heidrun Gehlen 


<https://orcid.org/0000-0001-5451-4232>

Judith Fisch 

<https://orcid.org/0000-0002-1192-7069>

Roswitha Merle 

<https://orcid.org/0000-0002-8688-2926>

Dagmar S. Trachsel 

<https://orcid.org/0000-0001-5103-8402>

## ABSTRACT

**Background:** Pituitary pars intermedia dysfunction (PPID), a neurodegenerative disease leading to reduced dopamine production, is a common disease in aged horses. The treatment is based on administration of the dopamine agonist pergolide. This drug has been related to valvular fibrosis in humans, but the cardiovascular effect of this drug has not yet been investigated in horses.

**Objectives:** To determine whether pergolide induces valvular disease in horses or affects the cardiac function.

**Methods:** Standard, tissue Doppler (TDE) and two-dimensional speckle tracking (STE) echocardiography were performed in horses with diagnosed PPID based on adrenocorticotrophic hormone dosage. Measurements taken in horses treated with pergolide were compared with those from untreated horses with nonparametric *t*-tests. Furthermore, measurements from follow-up examinations performed at least three months after the initial exam were compared with a Wilcoxon signed rank test for repeated measurements in each group.

**Results:** Twenty-three horses were included. None of the 12 horses under treatment developed valvular regurgitation. Furthermore, no differences in the measurements of the left ventricular systolic or diastolic function could be seen between the group of horses with treatment and those without treatment. Measurements taken in the follow-up exam did not differ compared to those taken in the initial exam in both groups.

**Conclusions:** No changes of the left ventricular function assessed by TDE and STE could be shown in a small population of horses with confirmed PPID. Treatment with pergolide did not affect the ventricular function nor induce valvular disease.

**Keywords:** Ultrasonography; heart; horses; equine Cushing syndrome; tissue Doppler echocardiography; speckle tracking

### Funding

The open access publication of this study was supported by the Open Access Publication Fund of the Freie Universität Berlin.

### Conflict of Interest

The authors declare no conflicts of interest.

### Author Contributions

Conceptualization: Gehlen H, Fisch J; Formal analysis: Fisch J, Merle R, Trachsel DS; Investigation: Gehlen H, Fisch J; Methodology: Gehlen H, Trachsel DS; Project administration: Gehlen H; Writing - original draft: Gehlen H, Fisch J, Merle R, Trachsel DS; Writing - review & editing: Gehlen H, Fisch J, Merle R, Trachsel DS.

## INTRODUCTION

Pituitary pars intermedia dysfunction (PPID) is a common disease in aged horses [1]. An increasing number of aged horses in the equine population [2] means that PPID will gain in importance. Firstly, PPID has been related to the development of micro- and macroadenomas in the pars intermedia [3,4], however, more recent studies have indicated that PPID is a neurodegenerative disease leading to reduced dopamine-related inhibition of the melanotrope cells in the pars intermedia [3,4]. As a result, more melanotrope hormones, such as pro-opiomelanocortin are synthesized and, subsequently, cleaving products, such as the adrenocorticotropic and  $\alpha$ -melanocyte-stimulating hormone or the  $\beta$ -endorphin-related peptide are secreted in higher amounts and their concentration in the blood increases [3,4]. Therefore, the main treatment strategy relies on the administration of a dopamine agonist, such as pergolide [3-5].

However, the administration of pergolide in human medicine has been related to fibrotic lesions at the atrio-ventricular valves [6-9]. A second mechanism of action of pergolide has been proposed in further investigation. The stimulation of the serotonin receptor 5-hydroxytryptamine receptor 2B (5-HT<sub>2B</sub>) by pergolide could lead to the proliferation of fibroblasts in the valvular tissue [9,10]. In addition, patients with Cushing's syndrome have shown altered myocardial function. The peak E myocardial velocity and the E/A ratio were particularly reduced, while the peak S myocardial velocity, the A myocardial velocity and the isovolumetric relaxation were not altered [11,12]. However, a reduced peak E myocardial velocity in another study was accompanied by an increased A myocardial velocity and fibrosis in the myocardium [13]. Moreover, a positive correlation between the serum cortisol level and the E/A ratio and a negative correlation between the serum cortisol and peak S myocardial velocity, E myocardial velocity and the ejection fraction has been shown in patients with Cushing's syndrome [12].

Studies on cardiac function in horses with PPID are lacking in equine medicine. Therefore, the aim of the present preliminary study was to report the cardiac function of horses with PPID by using the tissue Doppler technique. Our hypothesis was that horses under treatment with the dopamine agonist pergolide would have fewer changes in cardiac function over time than those without treatment. Furthermore, we hypothesized that treatment with pergolide would lead to the development of valvular diseases via the effect on local serotonin receptors.

## MATERIALS AND METHODS

### Animals

Patients presented at the equine hospital of the Freie University Berlin between August 2014 and October 2015 were included in the study. Inclusion criteria were that the horses had been diagnosed with PPID based on blood adrenocorticotropic hormone (ACTH) concentration prior to the inclusion and had a complete echocardiographic exam performed that showed that the horse was free of cardiovascular diseases, including absence of relevant valvular regurgitation. The study population was composed of 23 animals of different breeds (Warmbloods, n = 6; Shetland ponies, n = 6; other pony breeds, n = 2; light saddle horses, n = 2; Haflinger, n = 2; Arabian cross, n = 1; Islandic horses, n = 1; Trakehner, n = 1; Welsh-Mix, n = 1; and Norwegian, n = 1). The history and clinical exam of each horse was reviewed. The clinical signs in relation to PPID [4,14] were then classified to obtain a PPID score (PPIDs;

**Table 1.** Clinical signs with the assigned points considered to form the PPID scores

Clinical signs	Points accorded to form the PPIDs						
	Absent		Light		Moderate		Severe
Hypertrichosis	0	0.5	1	1.5	2	2.5	3
Hyperhidrosis	0	0.5	1	1.5	2	2.5	3
Reduced exercise capacity	0	0.5	1	1.5	2	2.5	3
Apathy	0	0.5	1	1.5	2	2.5	3
Polyuria/polydipsia	0		1 (if present)				
Muscular atrophy	0	0.5	1	1.5	2	2.5	3
Sway back	0	0.5	1	1.5	2	2.5	3
Abdominal fat distribution	0	0.5	1	1.5	2	2.5	3
Weight loss	0	0.5	1	1.5	2	2.5	3
Laminitis	0	0.5	1	1.5	2	2.5	3

PPIDs, pituitary pars intermedia dysfunction score.

**Table 1)** [15]. Points from 0 to 3 points were assigned for each of the clinical signs depending on their severity. If the sum was  $\leq 3.5$ , the horses were classified as PPIDs 1; if the sum was  $> 3.5$ , the horses were classified as PPIDs 2.

The presence of acute laminitis was excluded based on the findings of the clinical exam. In addition, sex was recorded and the study population was classified as females (F) and males (M), including geldings and stallions. Age was categorized as  $\leq 23$  years old (group middle-aged, MA), between 24 and 26 years old (group old, O) and  $\geq 27$  year of age (group very old, VO).

The population was divided in 2 groups according to the German Equestrian Federation guidelines [16]: Horses with a wither height  $\leq 148$  cm were ponies (breed 1, BR1), and larger horses were classified as breed 2 (BR2).

Whether the horses were in therapy was also recorded. When the horses received the dopamine agonist pergolide at the time of inclusion in the study, they were assessed in the treatment (T) group, and when the horses received no pergolide, they were assessed in the no treatment (NT) group. Whether the horse had any other treatment for the PPID diagnosed was additionally recorded.

The demographic data and categorization of the population studied are shown in **Table 2**.

A follow-up echocardiography (EchCG) performed after at least three months was available for 14 horses.

### Ethical approval

The blood samples taken for the ACTH dosage were part of the clinical work-up to diagnose PPID. They were performed prior to the inclusion in the study and performed according to standard protocols at our hospital. The EchCG was performed to verify normal valvular function prior to the administration of long-term pergolide treatment or to exclude valvular fibroses under pergolide treatment. Therefore, all exams were done with a clinical indication and according to the German law, and not classified as an animal experiments by the State Office of Health and Social Affairs (*Landesamt für Gesundheit und Soziales*) Berlin. Owners' verbal consent to involve their horses in the study was obtained during the admission process at the hospital.

**Table 2.** Demographic data of the population studied including the 23 horses without preexisting heart diseases

Variables	Values
Age (years) $\pm$ SD (range)	24.6 $\pm$ 3.6 (19–30)
Number of horses $<$ 23 years old (MA)	9
Number of horses 24–26 years old (O)	5
Number of horses $\geq$ 27 years old (VO)	9
Body weight (kg) $\pm$ SD (range)	380.4 $\pm$ 180.7 (128.9–735)
Wither height (cm) $\pm$ SD (range)	144.0 $\pm$ 27.17 (98–184)
Number of horses $<$ 148 cm (BR1)	13
Number of horses $>$ 148 cm (BR2)	10
Sex	
Number of Females (F)	9
Number of Males (M)	14
PPIDs	
Number of horses in group PPIDs 1	11
-With pergolide treatment	6
-Without treatment	5
Number of horses in group PPIDs 2	12
-With pergolide treatment	6
-Without treatment	6

BR, breed; F, females, M, males; MA, middle-aged; O, old, PPIDs, pituitary pars intermedia dysfunction score; VO, very old.

### EchCG

The complete EchCG including two-dimensional, M-mode and color flow Doppler images [17-20] was performed with a portable ultrasound system (Vivid I; GE Healthcare GmbH, Germany) and a phased array transducer utilizing the frequency form 1.7/3.4 MHz with activated octave harmonics. Cineloops were stored and analyzed offline with EchoPac PC Software (Version 110.1.1; GE Healthcare GmbH).

The echocardiographic exam also included tissue Doppler echocardiography (TDE) on a right-sided short axis view at a level just below the mitral valve and a minimum of three heart cycles were recorded for each measurement [21-23]. The sampling gate for the pulsed-wave TDE (pw-TDE) was placed subendothelial during diastole either in the interventricular septum (IVS) or in the left ventricular free wall (LFW) and recordings were stored with a time velocity scale from  $-20$  to  $+20$  cm/s. The sector width and the imaging depth of the views were individually adapted to achieve a frame rate of 40–80 frames per second. The color TDE (c-TDE) measurement was performed on an additional three heart cycles on the same image plan and a resolution of 4 kHz. Two-dimensional speckle tracking echocardiography (STE) was performed offline on a two-dimensional echocardiographic image of the right-sided short axis view at a level just below the mitral valve, as described previously [21,23,24]. A simultaneous EchCG was recorded for each EchCG, and the measurements of radial strain and strain rate were averaged over three cycles.

### Statistical analyses

The statistical analyses were performed with commercially available software (Microsoft Excel 2016 Ink.; Microsoft Corporation, USA; SPSS Statistics, version 24.0.0; IBM Deutschland GmbH, Germany; GraphPad Prism, version 5.01; GraphPad Software, USA).

The normal distribution of data was checked by assessing histograms, boxplots, kurtosis and skewness, and by applying the Shapiro-Wilk test. Age, wither height and body weight showed a normal distribution and were reported with mean  $\pm$  SD and range. However, several data in the TDE and SET did not meet the criteria for normal distribution and

these results are reported as median and interquartile range. Furthermore, due to the low number of horses included, no effort was made to transform the data and a nonparametric approach was chosen for analyses. Results are reported as median with interquartile range. Differences between groups were compared with a Mann-Whitney *U* test and when more than 2 groups, were compared with a Kruskal-Wallis test with the Dunn's correction for multiple comparisons. A Wilcoxon signed rank test for repeated measurements was used for comparison between initial and follow-up exams. A univariable regression analysis was performed for variables that showed a statically significant difference between the groups.

Equal distribution in sex, breed, age and PPIDs in the T horses in comparison to the NT ones was assessed by a Fisher's exact test.

The statistical significance level was defined as  $p \leq 0.05$ .

## RESULTS

The initial two-dimensional, M-mode and color Doppler echocardiographic exam revealed that these horses had no abnormal echocardiographic findings or in 2 cases, narrow regurgitation jets visible during a minor part of the cardiac cycle and, therefore, prejudged clinically irrelevant [25,26].

There were 12 horses that were under treatment at the time of inclusion (pergolide once a day in the mean dosage of 2.8  $\mu\text{g}/\text{kg}$ , range 0.5–7.7 $\mu\text{g}/\text{kg}$ , mean duration of treatment 1 year and 7 months, range between 14 day and 6 years) and 11 had no treatment. None of the horses had another treatment for PPID. The Fisher's exact test did not identify any statistically significant differences in the distribution of sex (F and M,  $p > 0.99$ ), breeds (BR1 and BR2,  $p = 0.68$ ) or PPIDs (PPIDs 1 and PPIDs 2,  $p > 0.99$ ) between the T and NT horses. However, the age distribution in the treatment groups was not homogenous (Fisher's exact test,  $p = 0.02$ ) and young horses were overrepresented in the group with treatment, whereas older horses appeared to be treated less often (**Table 3**).

### Initial exam

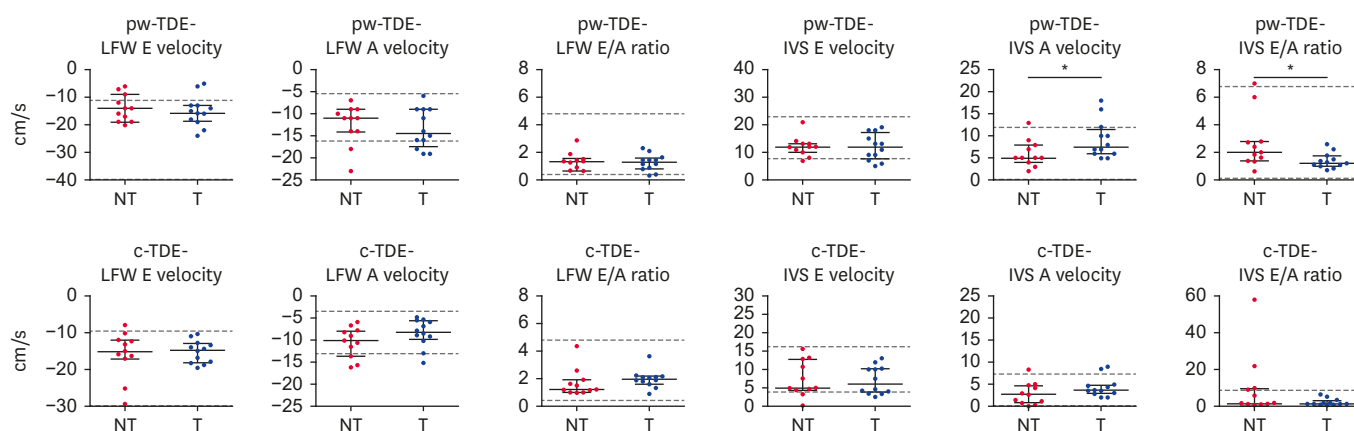
Regarding the TDE measurements, the isovolumetric contraction and the isovolumetric relaxation of the IVS and LFW were not analyzed because measurement could not be recorded with enough quality. The analyses, therefore, included the systolic (S) myocardial velocity, and the early (E) and late (A) diastolic myocardial velocity of the IVS and LWF.

The Mann–Whitney *U* tests did not reveal any statistically significant differences in the pw- or the c-TDE measurements of the S myocardial velocity ( $p = 0.14$  and  $p = 0.69$ , respectively), E myocardial velocity ( $p = 0.76$  and  $p = 0.74$ , respectively), A myocardial velocity ( $p = 0.55$  and  $p = 0.14$ , respectively) or the E/A ratio ( $p = 0.97$  and  $p = 0.12$ , respectively) for measurement of the LWF when comparing T with NT horses. Regarding the measurements of the IVS, there were

**Table 3.** Distribution in the age groups of horses with treatment and without treatment

Groups	$\leq 23$ years (MA)	24–26 years (O)	$\geq 27$ years (VO)
With pergolide treatment	8 (67%)	1 (8%)	3 (25%)
Without treatment	1 (9%)	4 (36%)	6 (55%)

MA, middle-aged; O, old; VO, very old.



**Fig. 1.** pw-TDE and c-TDE measurements of the diastolic left ventricular function in horses treated with pergolide (T) and without treatment (NT) reported as scatter dot blots with median with interquartile range.

pw-TDE, pulsed-wave tissue Doppler echocardiography; c-TDE, color tissue Doppler echocardiography; T, treatment; NT, no treatment; IVS, interventricular septum; LFW, left ventricular free wall; IE, initial exam; FE, follow-up exam.

The dashed line represents the reference range established for a similar population [39]. \* $p$  value < 0.05 in the Mann-Whitney  $U$  test.

similarly no statistically significant differences in all c-TDE measurements (S myocardial velocity,  $p = 0.78$ ; E myocardial velocity,  $p = 0.56$ ; A myocardial velocity,  $p = 0.14$ ; E/A ratio,  $p = 0.18$ ) and for S myocardial velocity ( $p = 0.55$ ) and E myocardial velocity ( $p = 0.92$ ) measurements in pw-TDE. However, T horses had significantly higher A myocardial velocity ( $p = 0.04$ ) and subsequently also lower E/A ratio ( $p = 0.03$ ) than NT horses (**Fig. 1, Supplementary Tables 1 and 2**).

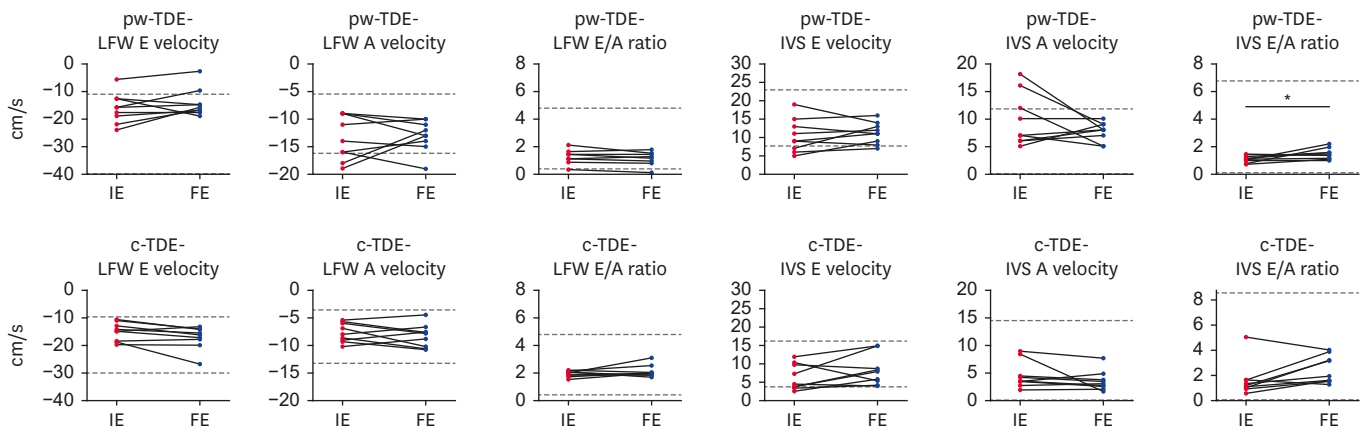
The univariable regression analyses could not confirm any influence of age ( $p = 0.36$  and  $p = 0.56$ ) or treatment ( $p = 0.15$  and  $p = 0.09$ ) on pw-TDE A myocardial velocity and pw-TDE E/A ratio, respectively

Regarding the STE, none of the measurements taken (i.e., radial strain, or strain rate [SR] of the S myocardial velocity, E myocardial velocity and A myocardial velocity) in the anterioseptal and the posterior wall segments showed statistically significant differences in the Mann-Whitney  $U$  test between the T and the NT horses (anterioseptal segment:radial strain  $p = 0.89$ , SR S myocardial velocity  $p = 0.69$ , SR E myocardial velocity  $p = 0.78$ , SR A myocardial velocity  $p = 0.22$ , posterior segment:radial strain  $p = 0.48$ , SR S myocardial velocity  $p = 0.31$ , SR E myocardial velocity  $p = 0.06$ , SR A myocardial velocity  $p = 0.21$ ) (**Supplementary Table 3**).

### Follow-up exam

Nine T horses were available for the follow-up exam and five NT horses. The average follow-up period (minimum to maximum) for the T horses was 5.3 months (3–8 months) and 6.8 months (6–7 months) for the NT horses. None of the horses had developed a heart murmur over time.

Regarding the nine T horses available in the follow-up exam, the Wilcoxon signed rank test showed no statistically significant difference between measurements taken in the initial exam and those in the follow-up exam in any of the pw-TDE (S myocardial velocity in the LFW  $p = 0.68$  and in the IVS  $p = 0.40$ ; E myocardial velocity in the LFW  $p = 0.23$  and in the IVS  $p = 0.47$ ; A myocardial velocity in the LFW  $p = 0.95$  and in the IVS  $p = 0.40$ ; E/A ratio in the LFW  $p = 0.38$ ) or c-TDE measurements (S myocardial velocity in the IVS  $p = 0.31$ ; E myocardial

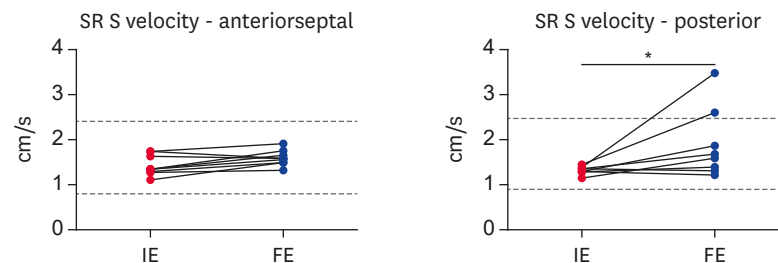


**Fig. 2.** The pw-TDE and c-TDE measurements of the diastolic left ventricular function in horses treated with pergolide at the IE and at the FE reported as before-after blots. pw-TDE, pulsed-wave tissue Doppler echocardiography; c-TDE, color tissue Doppler echocardiography; IE, initial exam; FE, follow-up exam; IVS, interventricular septum; LFW, left ventricular free wall. The dashed line represents the reference range established for a similar population [39], \**p* value < 0.05 in the Wilcoxon signed rank test for repeated measurements.

velocity in the LFW *p* = 0.05 and in the IVS *p* = 0.20, A myocardial velocity in the LFW *p* = 0.20 and in the IVS *p* = 0.20, E/A ratio in the LFW *p* = 0.45 and in the IVS *p* = 0.05), except for the pw-TDE E/A ratio (*p* = 0.04) in the IVS and the c-TDE S myocardial velocity (*p* = 0.04) in the LFW. The pw TDE E/A ratio in the IVS was higher in the follow-up exam than in the initial exam (**Fig. 2, Supplementary Tables 5 and 6**) and the c-TDE S myocardial velocity in the LFW was lower in the follow-up exam (median, 6.65; interquartile range, 6.24–8.42) in comparison to the initial exam (median, 6.74; interquartile range, 5.44–8.07).

Similarly, there was no statistically significant difference in the SET measurements between the initial exam and the follow-up exam for the anteriorseptal (radial strain *p* = 0.25, SR S myocardial velocity *p* = 0.06, SR E myocardial velocity *p* = 0.16, and SR A myocardial velocity *p* = 0.64) or the posterior wall segment (radial strain *p* = 0.10, SR E myocardial velocity *p* = 0.31, and SR A myocardial velocity *p* = 0.25), with the exception of the SR S wave in the posterior wall (*p* = 0.02) (**Fig. 3, Supplementary Table 4**).

Regarding the 5 NT horses that were available for a follow-up exam, there were no statistically significant differences seen in any of the pw-TDE, c-TDE or STE measurements (**Supplementary Tables 3-6**).



**Fig. 3.** Two-dimensional STE measurements of systolic SR in horses treated with pergolide at the IE and at the FE reported as before-after blots. STE, speckle tracking echocardiography; SR, strain rate; IE, initial exam; FE, follow-up exam. The dashed line represents the reference range established for a similar population [39], \**p* value < 0.05 in the Wilcoxon signed rank test for repeated measurements.

## DISCUSSION

The main result of our small orientation study was that treatment with pergolide of a duration between 3 and 8 months in a horse population with confirmed PPID did not seem to affect the left ventricular function assessed by TDE and STE. Furthermore, none of the horses developed valvular regurgitation in the observation period.

In human medicine a reduced diastolic function indicated by a reduced E myocardial velocity, reduce E/A ration has been related to higher cortisol levels in Cushing syndrome [11,12,27,28]. In addition to a reduced peak E myocardial velocity, an increased A myocardial velocity was seen in another human study [13]. This effect could not be shown in our study population because the NT horses did not show any change in the E myocardial velocity or A myocardial velocity over the follow-up period. There might be many explanations for this discrepancy. In addition to the low number of horses in this group, the duration of the disease prior to inclusion was heterogenous in our study population. Furthermore, the follow-up period was rather short and might not have been sufficient to make the effect become visible. Therefore, our result should be considered as preliminary.

The treatment with pergolide showed few effects on the ventricular function in our study population. The T horses showed a significantly higher A myocardial velocity in the IVS and, subsequently, a higher E/A ratio than NT horses, even if the regression analyses did not allow us to confirm this association. Moreover, the SR of the S myocardial velocity in the posterior segment was higher in the follow-up exam than in the initial treatment in T horses. These effects seemed to be largely related to outliers in the population as the effects were no longer visible when excluding these outliers. Therefore, further studies are needed with a larger more homogenous population to make definitive conclusions.

Furthermore, younger horses received a treatment more often than older horses. The inhomogeneous distribution of ages could have affected our results as a reduced diastolic function with compensatory increased A myocardial velocity with advancing ages has been reported in horses [22,24,29] and in humans [30,31]. However, the regression analyses did not show an effect of age on A myocardial velocity or E/A ratio. All horses included were over 19 years of age and were, therefore, already aged. Therefore, an effect of age might have been reduced because the age of the groups was too similar.

The absence of effect seen in our study could also possibly be related to the fact that only short axis echocardiographic views were available for analyses. Therefore, only radial movements were assessed. Analyses were focused on the anterioseptal and the posterior wall segment in the STE due to quality issues in some of the views. Therefore, assessing all segments and the inclusion of longitudinal measurements would have allowed us to assess the complex movement of the heart more in detail. Such longitudinal measurements are available in STE as has been recently shown [32-34], but are technically not feasible for TDE in horse [35-37]. Concerning the TDE, rapid movement, such as the isovolumetric contraction and relaxation, are difficult to measure in horses [35,36,38] because the frame rate is often limited when high image depth is needed, for example, in EchCG in horses. Consequently, these measures were not assessed in the present study.

A further limitation of the study is the low number of horses included at initial exam, but even more for the follow-up exam. Furthermore, the population included was quite



heterogenous regarding breeds. Outliers have much more effect in such a small heterogenous population and this affected our results. Therefore, studies with a larger population are needed before drawing any further conclusions. In addition, a control group representing a similar population in age and breed without PPID should be included in future studies.

The duration of the treatment was not homogenous at the initial exam and the follow-up period was quite short. Therefore, the treatment period might not have been long enough to show a measurable effect and studies with longer follow-up periods are needed. In addition, there were very few horses in the follow-up exam that were not in treatment and this further reduced the effect that might have been seen in this group.

Lastly, even if the diagnosis of PPID had been confirmed in all horses by a previously measured increased ACTH blood concentration, there was no other effort made to exclude equine metabolic syndrome than to judge the level of adiposities of the horses at initial exam and to exclude horses that showed obvious fat depots that could be a sign of an equine metabolic syndrome. Additionally, the ACTH concentration was not checked under treatment to verify that the dosage was effective and, thus, we cannot exclude that an effect on the left ventricular function could appear at a higher dosage.

Finally, technical difficulties with TDE and STE could have influenced our results.

In conclusion, no changes of the left ventricular function assessed by TDE and STE could be shown in a small population of horses with confirmed PPID under treatment with pergolide. The administration of pergolide did not seem to induce valvular changes over an observation period of 5.3 months. However, the results of our studies should be considered as preliminary due to the limitations mentioned and further studies are needed especially with a larger population and longer follow-up period.

## SUPPLEMENTARY MATERIALS

### Supplementary Table 1

pw-TDE measurements in horses treated with pergolide (T) and without treatment (NT) compared with a Mann-Whitney *U* test

[Click here to view](#)

### Supplementary Table 2

c-TDE measurements in horses treated with pergolide (T) and without treatment (NT) compared with a Mann-Whitney *U* test

[Click here to view](#)

### Supplementary Table 3

Two-dimensional STE measurements obtained in horses that received NT and in horses treated with pergolide (T) compared with a Mann-Whitney *U* test

[Click here to view](#)

**Supplementary Table 4**

Two-dimensional STE measurements obtained during the IE and in the FE, compared with a Wilcoxon signed rank test for repeated measurements

[Click here to view](#)

**Supplementary Table 5**

pw-TDE measurements at IE and at the FE in horses that received no treatment and in horses treated with pergolide, compared with a Wilcoxon signed rank test for repeated measurements

[Click here to view](#)

**Supplementary Table 6**

c-TDE measurements at IE and at the FE in horses that received no treatment and in horses treated with pergolide, compared with a Wilcoxon signed rank test for repeated measurements

[Click here to view](#)

**REFERENCES**

1. Ireland JL, McGowan CM. Epidemiology of pituitary pars intermedia dysfunction: a systematic literature review of clinical presentation, disease prevalence and risk factors. *Vet J.* 2018;235:22-33.  
[PUBMED](#) | [CROSSREF](#)
2. Traub-Dargatz JL, Long RE, Bertone JJ. Chapter 1. What is an “old horse” and its recent impact? In: Bertone JJ, editor. *Equine Geriatric Medicine and Surgery*. St. Louis: Saunders Elsevier; 2006, 1-4.
3. Schott HC 2nd. Pituitary pars intermedia dysfunction: equine Cushing's disease. *Vet Clin North Am Equine Pract.* 2002;18(2):237-270.  
[PUBMED](#) | [CROSSREF](#)
4. McFarlane D. Equine pituitary pars intermedia dysfunction. *Vet Clin North Am Equine Pract.* 2011;27(1):93-113.  
[PUBMED](#) | [CROSSREF](#)
5. Durham AE. Therapeutics for equine endocrine disorders. *Vet Clin North Am Equine Pract.* 2017;33(1):127-139.  
[PUBMED](#) | [CROSSREF](#)
6. Antonini A, Poewe W. Fibrotic heart-valve reactions to dopamine-agonist treatment in Parkinson's disease. *Lancet Neurol.* 2007;6(9):826-829.  
[PUBMED](#) | [CROSSREF](#)
7. Baseman DG, O'Suilleabhain PE, Reimold SC, Laskar SR, Baseman JG, Dewey RB Jr. Pergolide use in Parkinson disease is associated with cardiac valve regurgitation. *Neurology.* 2004;63(2):301-304.  
[PUBMED](#) | [CROSSREF](#)
8. Zanettini R, Antonini A, Gatto G, Gentile R, Tesei S, Pezzoli G. Valvular heart disease and the use of dopamine agonists for Parkinson's disease. *N Engl J Med.* 2007;356(1):39-46.  
[PUBMED](#) | [CROSSREF](#)
9. Tran T, Brophy JM, Suissa S, Renoux C. Risks of cardiac valve regurgitation and heart failure associated with ergot- and non-ergot-derived dopamine agonist use in patients with Parkinson's Disease: a systematic review of observational studies. *CNS Drugs.* 2015;29(12):985-998.  
[PUBMED](#) | [CROSSREF](#)
10. Jähnichen S, Horowski R, Pertz HH. Agonism at 5-HT<sub>2B</sub> receptors is not a class effect of the ergolines. *Eur J Pharmacol.* 2005;513(3):225-228.  
[PUBMED](#) | [CROSSREF](#)

11. Bayram NA, Ersoy R, Aydin C, Gul K, Keles T, Topaloglu O, et al. Assessment of left ventricular functions by tissue Doppler echocardiography in patients with Cushing's disease. *J Endocrinol Invest.* 2009;32(3):248-252.  
[PUBMED](#) | [CROSSREF](#)
12. Baykan M, Erem C, Gedikli O, Hacıhasanoglu A, Erdogan T, Kocak M, et al. Assessment of left ventricular diastolic function and Tei index by tissue Doppler imaging in patients with Cushing's Syndrome. *Echocardiography.* 2008;25(2):182-190.  
[PUBMED](#) | [CROSSREF](#)
13. Yiu KH, Marsan NA, Delgado V, Biermasz NR, Holman ER, Smit JW, et al. Increased myocardial fibrosis and left ventricular dysfunction in Cushing's syndrome. *Eur J Endocrinol.* 2012;166(1):27-34.  
[PUBMED](#) | [CROSSREF](#)
14. Pongratz MC, Graubner C, Wehrli Eser M. Equine Cushing's syndrome: long-term effect of pergolide therapy. *Pferdeheilkunde.* 2010;26(4):598-603.  
[CROSSREF](#)
15. Bradarić Z. Investigation on the equine Cushing syndrome and evaluation of the efficacy of Vitex agnus castus (chaste berry) in the treatment of the equine Cushing syndrome [doctoral thesis]. Berlin: Freie Universität Berlin; 2012.
16. Düe M, Hertsch B, Hoffmann G, Miesner K, Veltjens-Otto-Erley C, Zeeb K. *Richtlinien für Reiten und Fahren-Haltung, Fütterung, Gesundheit und Zucht*, vol. 4. Warendorf: FNVerlag; 1997.
17. Stadler P. Echocardiography in the horse. *Pferdeheilkunde.* 1988;4(3):111-115.  
[CROSSREF](#)
18. Stadler P, Robine F. B-mode echocardiographic measurement of heart dimensions in warm blooded horses without heart disease. *Pferdeheilkunde.* 1996;12(1):35-43.  
[CROSSREF](#)
19. Gehlen H, Stadler P. Atrial fibrillation in warmblood horses – echocardiography, therapy, prognosis and outcome in 72 cases. *Pferdeheilkunde.* 2002;18(6):530-536.  
[CROSSREF](#)
20. Slater JD, Herrtage ME. Echocardiographic measurements of cardiac dimensions in normal ponies and horses. *Equine Vet J Suppl.* 1995;27(19):28-32.  
[PUBMED](#) | [CROSSREF](#)
21. Gehlen H, Neukirch S. Tissue Doppler imaging and two-dimensional speckle tracking of left ventricular function in horses affected with recurrent airway obstruction before and after clenbuterol treatment. *J Equine Vet Sci.* 2014;34(4):471-478.  
[CROSSREF](#)
22. Gehlen H, Bildheim LM. Evaluation of age-dependent changes of myocardial velocity using pulsed wave and colour tissue Doppler imaging in adult warmblood horses. *J Anim Physiol Anim Nutr (Berl).* 2018;102(6):1731-1742.  
[PUBMED](#) | [CROSSREF](#)
23. Gehlen H, Neukirch S. Tissue Doppler imaging and two-dimensional speckle tracking of left ventricular function in healthy horses after clenbuterol application. *J Equine Vet Sci.* 2013;33(12):1076-1081.  
[CROSSREF](#)
24. Gehlen H, Bildheim LM. Speckle-tracking analysis of myocardial deformation in correlation to age in healthy horses. *J Vet Sci.* 2018;19(5):676-682.  
[PUBMED](#) | [CROSSREF](#)
25. Reef VB, Bonagura J, Buhl R, McGurrin MK, Schwarzwald CC, van Loon G, et al. Recommendations for management of equine athletes with cardiovascular abnormalities. *J Vet Intern Med.* 2014;28(3):749-761.  
[PUBMED](#) | [CROSSREF](#)
26. Young LE, Rogers K, Wood JL. Heart murmurs and valvular regurgitation in thoroughbred racehorses: epidemiology and associations with athletic performance. *J Vet Intern Med.* 2008;22(2):418-426.  
[PUBMED](#) | [CROSSREF](#)
27. Muiesan ML, Lupia M, Salvetti M, Grigoletto C, Sonino N, Boscaro M, et al. Left ventricular structural and functional characteristics in Cushing's syndrome. *J Am Coll Cardiol.* 2003;41(12):2275-2279.  
[PUBMED](#) | [CROSSREF](#)
28. Pereira AM, Delgado V, Romijn JA, Smit JW, Bax JJ, Feelders RA. Cardiac dysfunction is reversed upon successful treatment of Cushing's syndrome. *Eur J Endocrinol.* 2010;162(2):331-340.  
[PUBMED](#) | [CROSSREF](#)
29. Gehlen H, Lagershausen HL. Influence of age on echocardiographic B- and M-mode parameters in juvenile German warmblood horses. *Pferdeheilkunde.* 2017;33(3):231-241.

30. Kloch-Badelek M, Kuznetsova T, Sakiewicz W, Tikhonoff V, Ryabikov A, González A, et al. Prevalence of left ventricular diastolic dysfunction in European populations based on cross-validated diagnostic thresholds. *Cardiovasc Ultrasound*. 2012;10(1):10.  
[PUBMED](#) | [CROSSREF](#)
31. Kuznetsova T, Thijs L, Knez J, Cauwenberghs N, Petit T, Gu YM, et al. Longitudinal changes in left ventricular diastolic function in a general population. *Circ Cardiovasc Imaging*. 2015;8(4):e002882.  
[PUBMED](#) | [CROSSREF](#)
32. Decloedt A, Verheyen T, Sys S, De Clercq D, van Loon G. Quantification of left ventricular longitudinal strain, strain rate, velocity, and displacement in healthy horses by 2-dimensional speckle tracking. *J Vet Intern Med*. 2011;25(2):330-338.  
[PUBMED](#) | [CROSSREF](#)
33. Decloedt A, Verheyen T, Sys S, De Clercq D, van Loon G. Tissue Doppler imaging and 2-dimensional speckle tracking of left ventricular function in horses exposed to lasalocid. *J Vet Intern Med*. 2012;26(5):1209-1216.  
[PUBMED](#) | [CROSSREF](#)
34. Decloedt A, Ven S, De Clercq D, Rademakers F, van Loon G. Assessment of left ventricular function in horses with aortic regurgitation by 2D speckle tracking. *BMC Vet Res*. 2020;16(1):93.  
[PUBMED](#) | [CROSSREF](#)
35. Schwarzwald CC, Schober KE, Bonagura JD. Methods and reliability of tissue Doppler imaging for assessment of left ventricular radial wall motion in horses. *J Vet Intern Med*. 2009;23(3):643-652.  
[PUBMED](#) | [CROSSREF](#)
36. Decloedt A, Verheyen T, Sys S, De Clercq D, van Loon G. Evaluation of tissue Doppler imaging for regional quantification of radial left ventricular wall motion in healthy horses. *Am J Vet Res*. 2013;74(1):53-61.  
[PUBMED](#) | [CROSSREF](#)
37. Gehlen H, Iversen C, Stadler P. Tissue Doppler imaging in the horse. *Pferdeheilkunde*. 2009;25(1):4-10.  
[CROSSREF](#)
38. Koenig TR, Mitchell KJ, Schwarzwald CC. Echocardiographic assessment of left ventricular function in healthy horses and in horses with heart disease using pulsed-wave tissue Doppler imaging. *J Vet Intern Med*. 2017;31(2):556-567.  
[PUBMED](#) | [CROSSREF](#)
39. Wittschorek J. VII. Summary. Myocardial function in horses during general anaesthesia evaluated by echocardiography. In: *Echokardiographische Untersuchung zum Einfluss der Allgemeinanästhesie auf die Myokardkontraktilität beim Pferd [Inaugural Dissertation]*. Berlin: Freie Universität Berlin; 2015, 122-124.