

## IMAGES IN SMALL ANIMAL PRACTICE

## Periarticular histiocytic sarcoma in a domestic rabbit

Articular tumours have only rarely been described in rabbits (*Oryctolagus cuniculus*). An 8-year-old, male castrated, domestic rabbit was presented with progressive right hindlimb lameness and its owners requested humane euthanasia. Radiography and a full *post-mortem* examination revealed a tumour in the location of the stifle joint with extension along tendon sheaths and extensive infiltration into the bone and bone marrow of the femur and tibia, the surrounding soft tissue and skeletal musculature (Fig 1A, B). Metastatic disease was not identified at *post-mortem* examination. Following an established immunohistochemical protocol for rabbit tissues (supplemental information), tumour cells were strongly positive for the macrophage scavenger receptor CD204 and vimentin, however, showed no expression of cytokeratin and smooth-muscle-actin. Pathological findings were consistent with a localised, periarticular histiocytic sarcoma (Fig 1C).

In rabbits, disseminated or localised histiocytic sarcomas have been reported to be predominately located in the lungs and less commonly in abdominal organs and skin, however, not in periarticular locations. In contrast, localised histiocytic sarcomas are the most common tumour type of the synovium of diarthrodial joints in dogs and likely arise from type A synoviocytes, a cell type of the histiocytic lineage. Other tumours such as synovial cell sarcoma may arise in the location of the joint (some with controversial cell origin), however, immunohistochemical staining

confirmed histiocytic lineage in the present case. Radiographic, gross and histological features of the present case were consistent with descriptions in dogs. Early treatment of articular histiocytic sarcoma, such as amputation, may be curative if no metastases are present. While rabbits commonly have disseminated histiocytic sarcoma, biological behaviour of these tumours in articular location is currently unknown.

**Acknowledgements**

Open access funding enabled and organized by Projekt DEAL.

**Supporting Information**

The following supporting information is available for this article:

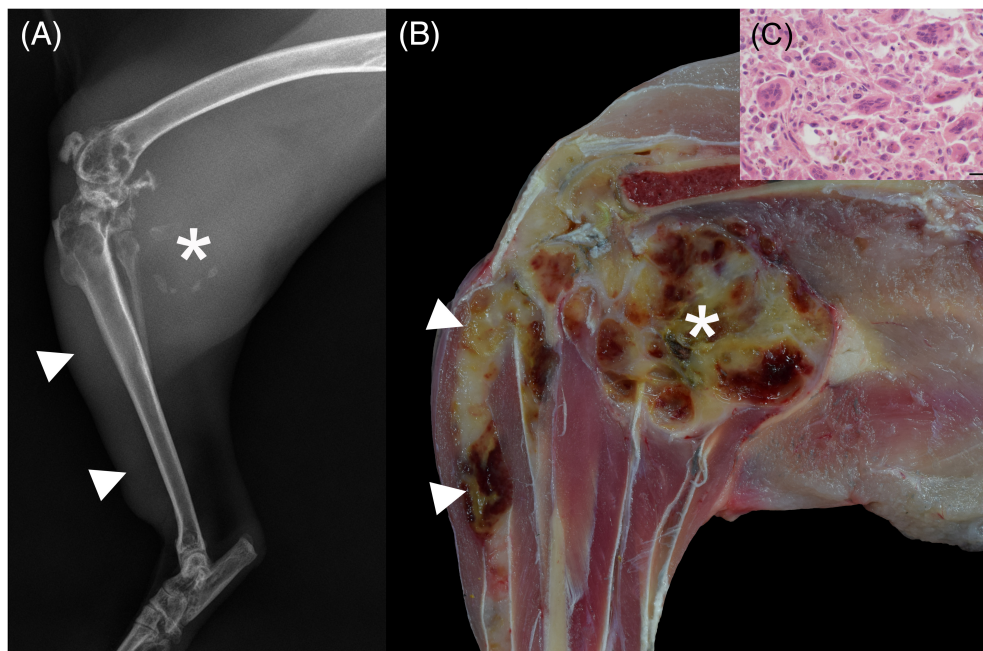
**Appendix S1:** Supporting information

C. A. BERTRAM\*, S. KUZMINSKIY†, K. MÜLLER†  
AND L. MUNDHENK<sup>1,\*</sup>

\*Institute of Veterinary Pathology, Freie Universität Berlin,  
Robert-von-Ostertag-Straße 15, Berlin, 14163, Germany

†Small Animal Clinic, Freie Universität Berlin, Oertzenweg 19b,  
Berlin, 14163, Germany

<sup>1</sup>Corresponding author email: lars.mundhenk@fu-berlin.de



**FIG 1.** Periarticular histiocytic sarcoma in a domestic rabbit (*Oryctolagus cuniculus*) with progressive right hindlimb lameness. (A) Radiographic image (laterolateral projection) of the right hind leg shows a soft-tissue dense mass with central mineral-dense inclusions (due to osseous metaplasia) caudally to the stifle joint (asterisk) and extension along the cranial aspect of the tibia (arrowhead). Lytic and proliferative bone alterations of distal femur and proximal tibia are present. (B) Gross image (longitudinal section) of the same location with a multinodular, 3,9 × 3,5 × 2,5 cm large, tan to red, periarticular mass (asterisk) that is connected to the stifle joint, infiltrating the bone, the bone marrow, the soft tissue and skeletal musculature and extends along tendon sheaths (arrowhead). (C) Histological image of the highly cellular mass comprised of neoplastic polygonal to round cells and abundant multinucleated giant cells. H&E stain. Bar = 20 μm