

4.13. Group II

4.13.1. Presentation and Clinical Appearance

Group II consisted of 14 dogs with 14 tumors that received definitive RT for sarcoma of the oral cavity. The median follow-up period for Group II was 401 days (range 52-1,560 days). Nine dogs received surgical treatment prior to irradiation and five dogs were treated for macroscopic disease. Eight spayed females, four neutered males and two intact males of the following breeds: Golden Retriever (6), Mixed breed (2), Labrador (2), Dalmatian (1), Weimeraner (1), Springer Spaniel (1) and Bernese Mountain Dog (1) were represented in Group II. Median weight was 30 kg, mean weight was 32 kg with a range of 15–45 kg. Ages ranged from 2.8–11.3 years with a median of 7.4 years and a mean of 7.6 years.

Group II included 14 tumors of the following types: FSA (n=9), undifferentiated sarcoma (n=3), MPNST (n=1) and MFH (n=1). Eleven of fourteen tumors were graded. Four were evaluated as high-grade, four were intermediate-grade and three were low-grade. Locations represented in the oral sarcoma group were: maxilla (n=7), hard-palate (n=3), lip (n=2) and soft-palate (n=2). Two dogs with palatine tumors had invasion into the nasal passages. Bony involvement was documented in twelve dogs prior to the initiation of radiation therapy either radiographically or on biopsy.

Of the five dogs with measurable disease, four had FSA (Grade I, (2); Ungraded, (1); Grade III, (1)) and one dog was diagnosed with an undifferentiated sarcoma. One dog with a macroscopic lesion (low-grade, FSA) also had thoracic mass that likely represented thoracic metastasis and led to euthanasia 52 days after completing radiation therapy. The early effects of radiation did not limit treatment in 13 of 14 dogs. Mucositis was noted in 12/14 dogs, six dogs required corticosteroids and toxicity was managed with systemic antibiotics in six dogs. Acute toxicity prohibited delivery of the last prescribed radiation fraction in one dog that received low-dose doxorubicin as a radiation sensitizer. All dogs in Group II are summarized in Table 21.

-Results-

Breed	Age (Years)	Location	Tumor Type	Grade	State of Disease	Alive/Dead	Tumor cause of death?	Survival in Days	Local Recurrence	DFI in days
1 Dalmatian	7	Hard palate + Nasal passages	UDSA	NG	Measurable	Dead	Yes	226	N/A	N/A
2 Mixed Breed	4.8	Maxilla	FSA	Low	Measurable	Dead	Yes	188	N/A	N/A
3 Golden Retriever	3.6	Maxilla	FSA	Low	Measurable	Dead	Yes	52	N/A	N/A
4 Yellow Labrador	10.6	Maxilla	FSA	High	Measurable	Dead	No	473	N/A	N/A
5 Springer Spaniel	10	Soft palate	FSA	NG	Measurable	Dead	Yes	371	N/A	N/A
6 Golden Retriever	6.5	Maxilla	FSA	Low	Residual	Dead	Yes	1572	Recurrence	752
7 Golden Retriever	9.7	Maxilla	FSA	Interm	Residual	Dead	Yes	430	Recurrence	303
8 Golden Retriever	7.4	Maxilla	UDSA	High	Residual	Dead	Yes	513	Recurrence	396
9 Golden Retriever	7.3	Soft palate	UDSA	High	Residual	Dead	Yes	194	Recurrence	93
10 Bernese Mt. Dog	11.3	Upper lip	MPNST	NG	Residual	Dead	No	202	No Recurrence	202
11 Mixed Breed	5.4	Maxilla	FSA	Interm	Residual	Alive	No	250	No Recurrence	250
12 Weimeraner	2.8	Upper lip	FSA	Interm	Residual	Alive	No	1129	No Recurrence	1,129
13 Golden Retriever	10.7	Hard palate + Nasal passages	MFH	Interm	Residual	Alive	No	705	No Recurrence	705
14 Lab Ret.	9	Hard palate	FSA	High	Residual	Dead	No	1378	No Recurrence	1,378

Table 21 Summary of all 14 dogs in Group II (UDSA=undifferentiated sarcoma, NG=Not graded, Interm=Intermediate, N/A=not applicable).

4.13.2. Survival Analysis of Group II

Of the fourteen dogs in Group II, eight died of tumor related causes and six dogs were censored for the purposes of survival analysis. Four of five dogs with measurable disease died of tumor related causes, as did four dogs that underwent surgery prior to radiation treatment. Two dogs developed osteosarcoma in the radiation field (one with measurable disease, one underwent resection), which led to death. Survival was calculated at 180-day intervals (Table 22) based on Kaplan-Meier analysis (Figure 25). Median survival was estimated at 513 days.

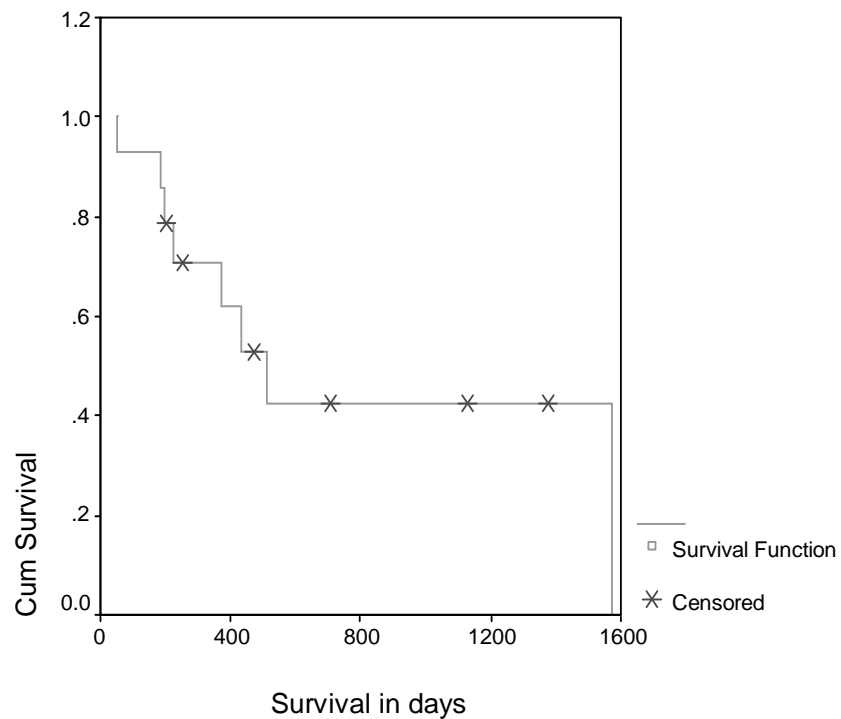


Figure 25 Kaplan-Meier curve depicting survival of dogs in Group II.

-Results-

Survival in days (post-RT)	Percentage alive
180	93
360	71
540	42
720	42

Table 22 Survival rates at 180 day intervals for dogs in Group II.

All dogs that experienced recurrence following excision died of tumor related causes, although one dog did not die of STS recurrence but developed OSA in the treatment field. All five dogs that were treated for macroscopic disease were dead at the end of the study. Four of the five dogs died of causes related to STS. A fifth dog that died of transitional cell carcinoma 473 days after completing radiation experienced a marked response to radiation and surgery was undertaken when control was lost and re-growth was noticed.

Dogs that died of tumor related causes included:

A seven-year-old Dalmatian with an undifferentiated sarcoma of the hard palate that had been removed and irradiated five-years previously at another institution developed recurrence. The recurrent tumor extended into the nasal passages, rostral to the location of the original tumor. Re-irradiation with a definitive protocol was undertaken. The radiation fields were not identical, however they did overlap to some degree. Ulceration was noted on the mucous membranes 143 days after the completion of RT and a biopsy of the lesion revealed the presence of extraosseous osteosarcoma. Euthanasia was performed 226 days following the second course of radiation.

A ten-year-old Springer Spaniel with an ungraded FSA of the soft palate was treated with doxorubicin and radiation. Euthanasia was performed 371 days after completing radiation therapy due to local progression.

A five-year-old mixed breed dog received radiation therapy for an intermediate-grade FSA of the maxilla. Two previous surgeries had been conducted but both resulted in recurrence. At the time radiation therapy was conducted, the tumor was not amenable to excision. The mass was stable for 85 days after completing radiation treatment, but progression led to euthanasia 188 days post-RT.

-Results-

A low-grade FSA of the rostral maxilla extending into the roof of the mouth was removed from a 3.5 year-old Golden Retriever. The mass recurred four months later and additional aggressive surgery was performed that also resulted in re-growth of the tumor. Prior to beginning radiation therapy, thoracic radiography revealed a mass lesion of the thorax. Computed tomographic examination of the thorax revealed a 3x3x4 cm mass located in the mediastinum. The owners elected to pursue RT despite of the possibility of a metastatic lesion or other neoplastic process. The dog was euthanized 52 days after the completion of radiation therapy.

A seven-year-old Golden Retriever underwent surgery for a histological low-grade biological high-grade FSA of the rostral maxilla. Incomplete removal prompted radiation therapy. Local recurrence was detected 752 days post-RT and subsequently successfully excised. Two years after the tumor recurred, a new mass was noted in the radiation field that was shown to be an osteosarcoma on biopsy. The tumor eventually led to death 1,572 days post RT.

A 9.7-year-old Golden Retriever with an intermediate-grade tumor of the right zygomatic arch that was resected prior to irradiation experienced tumor return 303 days after RT was completed. Doxorubicin was then administered and resulted in slight shrinkage of the tumor (circa 10%) that was short lived. Local progression prompted euthanasia 430 days after the last radiation fraction was administered.

A 7.5-year-old Golden Retriever with a high-grade undifferentiated sarcoma of the soft palate underwent incomplete excision. Ninety-three days after radiation therapy was complete, the tumor returned, causing respiratory distress. Symptoms were managed with corticosteroids until euthanasia was undertaken 100 days after recurrence was noted.

A 7.5 year-old Golden Retriever received RT for an undifferentiated high-grade tumor of the maxilla that had previously undergone multiple excisions. Computed tomography showed the tumor extending from the carnissial tooth to the last pre-molar. Tumor recurrence was noted 396 days after the completion of radiation therapy tumor. Euthanasia was undertaken 513 days after RT due to tumor related causes.

In addition to the dogs that died of causes directly related to the tumors (n=8), three dogs died of other causes that included renal failure (202 days post RT), megaesophagus (1,372 days post RT) and transitional cell carcinoma 473 (days post -RT). All totaled, 11 died and three dogs were censored. Kaplan-Meier analysis of overall survival is shown in Figure 26. Six-month, one-year, two-year and 3-year survival intervals were calculated based on Kaplan-Meier analysis (Table 23).

-Results-

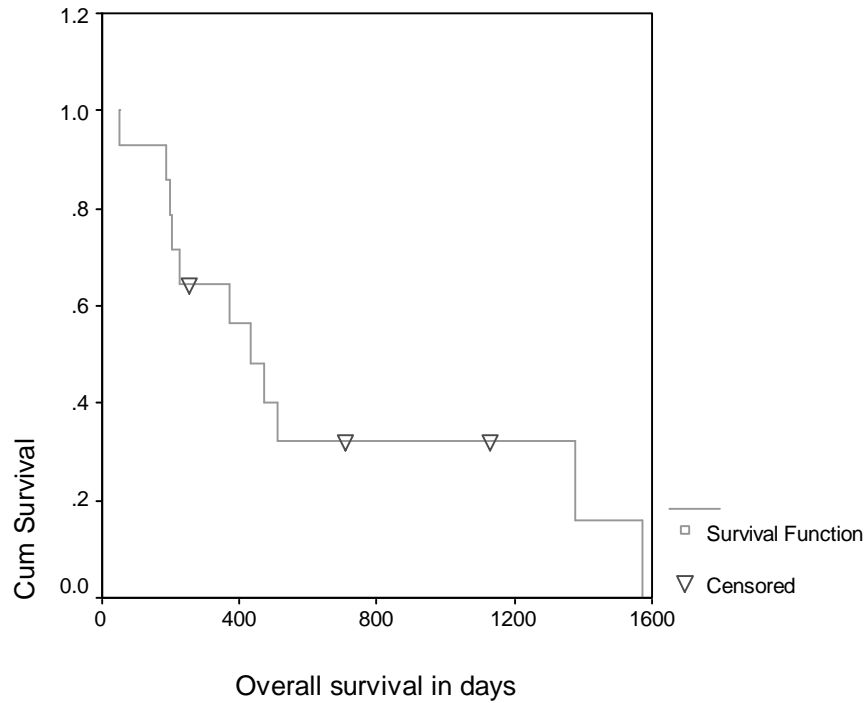


Figure 26 Kaplan-Meier curve of overall survival of 14 dogs with oral sarcoma.

Time in days	Percent alive
180	93
360	64
540	32
720	32

Table 23 Overall survival rates at 180-day interval for dogs in Group II.

Median overall survival is estimated at 473 days. The last death occurred 1,572 days after RT and earliest death occurred on day 52 after completing radiation therapy.

4.13.3. DFI

-Results-

Of the nine dogs that received surgery before proceeding with RT, four developed recurrence. Seventy-four percent were disease free at one-year and 54% were disease free at two-years. Median DFI was estimated at 752 days (Figure 27).

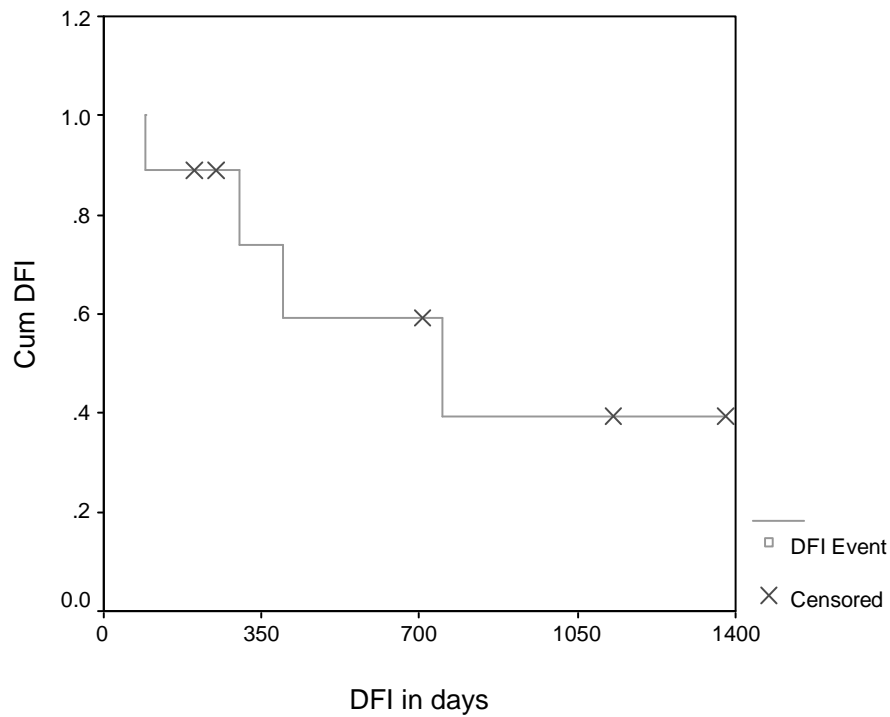


Figure 27 Kaplan-Meier curve of DFI of nine dogs in Group II. All nine dogs underwent resection prior to radiation therapy.

4.13.4. Irradiation of Measurable vs. Residual Disease

Survival analysis was undertaken based on the state of disease; the survival of animals that had macroscopic disease at the time RT was initiated was compared to survival of animals that underwent excision prior to receiving radiation therapy (Figure 28).

-Results-

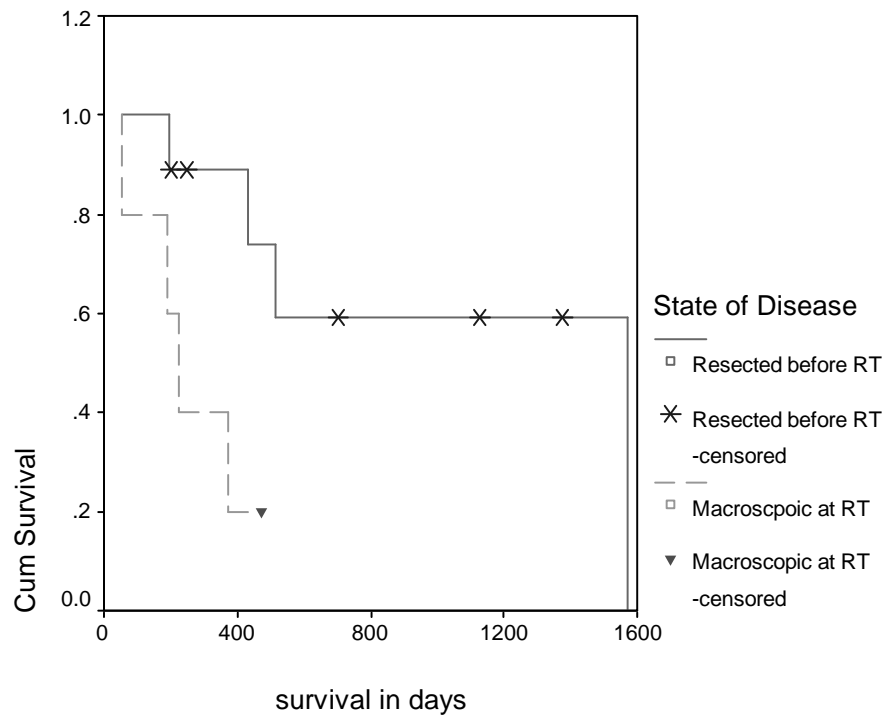


Figure 28 Kaplan-Meier survival analysis based on disease state at the time of RT.

Median survival time of dogs treated for macroscopic disease was 226 days. Median survival was estimated at 1,572 days for dogs that underwent cytoreduction prior to RT. A difference in survival between the two groups was apparent ($P=0.026$, Log-Rank). At one-year, 40% of dogs treated with macroscopic disease were alive compared to 89% of dogs treated for residual disease. Of the nine dogs that underwent resection prior to radiation therapy, four developed recurrence. A survival event did not occur in any dog in any dog in Group II that underwent cytoreduction prior to receiving RT and that did not develop recurrence. Of the four dogs that developed recurrent disease, all four died due to tumor related causes.

4.14. Group III

4.14.1. Presentation

Three dogs with measurable sarcoma in non-oral locations, two with HPC and one with an infiltrative lipoma, were treated with a definitive radiation protocol. All three dogs had a history of attempted surgical excision. Two dogs had previously undergone tumor reduction to microscopic disease but developed recurrence. At the time radiation was undertaken, surgical options for all dogs involved amputation, which was not pursued in any dog. All surgeries were conducted under the care of the primary veterinarian. All three tumors were located in the trunk or proximal extremity. None of the tumors showed bony involvement

None of the animals in this group received chemotherapy. One of the dogs was lost to follow-up shortly after the completion of radiation therapy; another was alive at the end of the study and the third dog died related to the tumor.

4.14.2. Summary of Dogs in Group III

A ten-year-old malamute with a hemangiopericytoma of the caudal thigh extending into perianal region of approximately 10x8x5 cm received radiation treatment. Surgical exploration revealed that the mass had adopted an intimate relationship with the ischiadic nerve, precluding an attempt at complete resection. The suggestion of amputation was declined. A definitive radiation protocol was delivered in an attempt to stabilize the mass. During the end of radiation treatment, lameness and discharge were noted and the dog was treated with corticosteroids. Seven-hundred and eight-four days after the completion of radiation therapy, the dog was euthanized for loss of ambulation and weight bearing ability of the rear legs. Lameness was noted approximately three weeks prior to euthanasia, but the owner had reported an excellent quality of life until that point.

Irradiation was undertaken in a 17-month-old neutered male Labrador Retriever diagnosed with a large infiltrative lipoma (20 cm) extending along the lateral

-Results-

thoracic wall and medial to the scapula, resulting in scapular displacement. An attempt at surgical excision failed to remove all gross disease. Tumor tissue was visualized with the aid of advanced imaging (CT) prior to radiation treatment, at that time lateralization of the scapula could be detected. Three months after completing radiation treatment slight lameness was noted and follow-up CT showed tumor tissue medial to the scapula. Amputation was considered but not pursued. At last contact (949 days post RT), the owner reported that the tumor was stable and amputation had not been undertaken.

A mixed-breed dog was irradiated for a 5x5x10 cm hemangiopericytoma located in the caudal shoulder. Post operative examination conducted three weeks after the completion of radiation therapy revealed that tumor volume had decreased by roughly 30-40%. Unfortunately, the case was lost to follow-up when dog left the area, 102 days after completing radiation treatment.

4.15. Group IV

Six dogs received a hypofractionated protocol consisting of 3-4 radiation fractions of 800 cGy to total dose of 2400-3200 cGy as a sole radiotherapeutic modality. The six dogs in Group III were all male, five were castrated and one dog was intact. Mean age was 13 years with a median of 12.7 years and a range of 9-16 years. Weights ranged from 10-47 kg (mean 30 kg, median 32.5 kg) and the following breeds were represented: Jack Russell Terrier, Boxer, Golden Retriever, Labrador, Mixed breed, and Tibetan Terrier.

Three dogs had tumors of the face (maxilla, caudal oral cavity/retrobulbar, os nasale/periocular) and three dogs were treated for tumors of the extremities (foreleg (2), elbow (1)).

Five dogs had macroscopic disease at the time of radiation therapy, and one dog was treated post surgically for residual disease. The following tumor types were treated in the group studied: FSA (n=3), HPC (n=2), undifferentiated sarcoma (n=1). Three of the tumors were not assigned a histological grade, two tumors were identified as histological low-grade biological high-grade FSA, and one tumor was of intermediate-grade. The presentation is summarized in Table 24.

Location	Tumor Type	Grade	Other
Forearm (2)	FSA, HPC	Intermediate, NG	
Elbow	HPC	NG	Resected prior to RT
Supramolar	FSA	HLGBHG	
Oral/retrobulbar	Undifferentiated SA	NG	
Nasal Bone/Periocular	FSA	HLGBHG	

Table 24 Summary of six dogs that received palliative radiation. (NG=Not graded, HLGBHG=Histological low-grade biological high-grade fibrosarcoma, SA=Sarcoma)

Two animals that were treated in Group IV had significant co-morbidity. One dog had a non-resectable MPNST of the thorax and a sub-molar mass in addition to a carpal HPC that received RT. Another dog had severe pulmonary fibrosis with a progressive chronic cough.

-Results-

Five dogs received hypofractionated radiation for palliation of advanced disease. One dog that received hypofractionated radiation for a resected tumor had significant pulmonary disease. A definitive protocol was not pursued, as the dog was not evaluated as a good candidate for repeated anesthesia. Of the five dogs that were treated for advanced disease, two dogs received RT in an attempt to improve limb function and prolong preservation of the extremity. In one case a hypofractionated protocol was selected because the tumor mass extended around the carpus and precluded the possibility of sparing lymphatic drainage (Figure 29). Another dog presented with multiple soft-tissues sarcomas, the most discomfort was caused by a carpal HPC 8 cm in diameter. A hypofractionated protocol was elected due to co morbidity and to improve function of the affected limb.

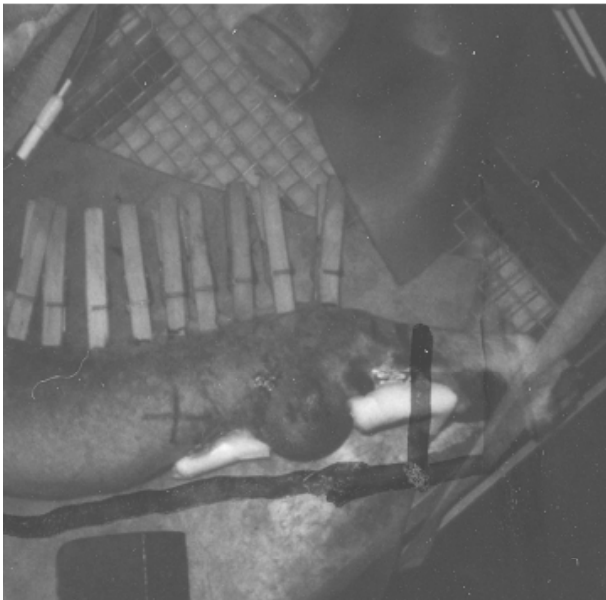


Figure 29 A tumor extending from the carpus to the elbow was treated with a palliative protocol.

4.15.1. Palliation

Of the five dogs treated for macroscopic disease four dogs (80%) experienced a decrease in tumor size ranging from 10-25%. Pain relief was achieved in four of five cases, and short-term stabilization was achieved in four of five dogs. Both dogs that were treated for macroscopic disease present in the foreleg showed an improvement in gait following the second fraction. One dog (Figure 29), exhibited tumor control for approximately 12 months after RT. After stabilization was lost, the tumor ulcerated and the owner elected to continue treating

the dog with serial bandage changes every 3-4 days, opiates and antibiotics until ulceration and uncontrollable bleeding prompted euthanasia one-month after the loss of stabilization. In the one dog that was treated with a hypofractionated protocol for an incompletely resected tumor of the elbow, re-growth was not noted when the dog was last examined 379 days following radiation therapy.

All dogs tolerated treatment well; no significant radiation induced changes were noted. Treatment for acute radiation toxicity was not required in any dog and

long-term complications were not reported in any dog. Two dogs had the eye included in the radiation field, but both dogs died before long-term complications were expected.

4.15.2. Survival

Of the six dogs that were treated with a hypofractionated protocol, four were deceased at the conclusion of the study and two were censored (one lost to follow-up at 140 days). Survival ranged from 128 days to 387 days (two animals censored at 379 and 140 days), with a mean of 231 days (n=4). All four dogs that died were euthanized for tumor related causes. A Kaplan-Meier curve was generated (Figure 30). The longest known survival was 387 days and the last censored value occurred at 379 days. The dog that was still alive at 379 days underwent resection prior to treatment.

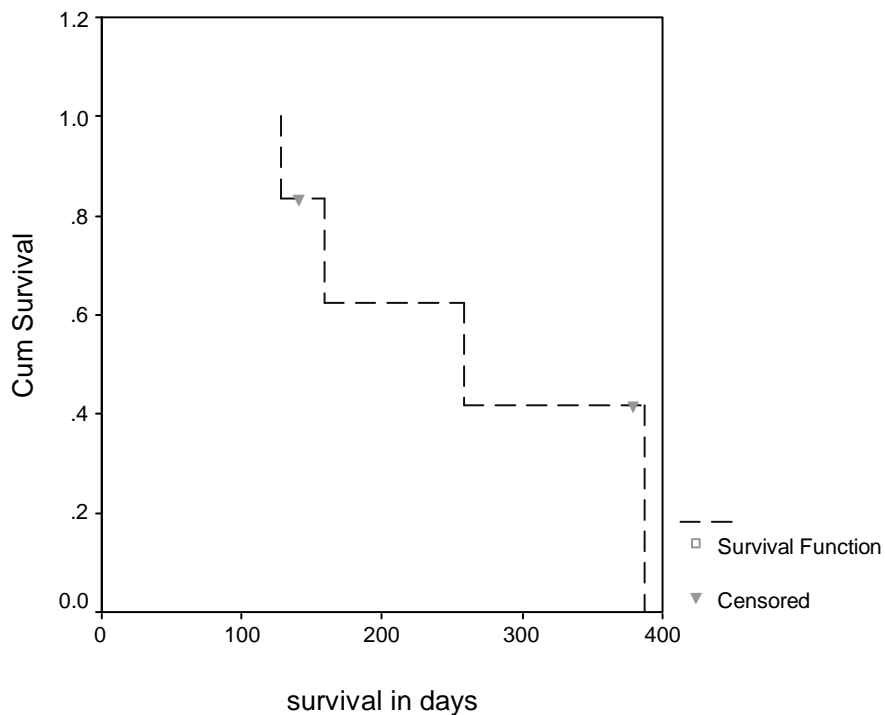


Figure 30 Kaplan-Meier curve of survival of all six dogs in Group IV.

The group of six dogs that received a hypofractionated protocol for STS contained:

-Results-

A sixteen year-old mixed breed dog that presented with multiple STS including a painful HPC 8 cm in diameter on the left carpus, a non-resectable MPNST of the thorax and a sub-molar mass of unknown origin; all three tumors were progressing. The carpal tumor was causing lameness. Palliative radiation resulted in a decrease in tumor size of approximately 10% and improvement of limb function. The dog was euthanized 152 days after the completion of radiation therapy.

A Chocolate Lab, nine-years of age, was treated for a histological low-grade yet biological high-grade FSA of the left maxilla at the level of the premolars that was not amenable to resection. Survival was 258 days. A palliative effect was noted although tumor shrinkage was not apparent.

A thirteen-year old Tibetan Terrier received treatment for an undifferentiated sarcoma of the right caudal oral cavity. The dog presented with pain on opening the mouth, dysphagia and decreased retropulsion of the eye. Computed tomographic examination showed a lesion extending from the ventral ramus to the retrobulbular space. The dog was censored at last contact, 140 days after radiation, as the exact date of death was not known.

A Golden Retriever was treated for a periorbital low-grade FSA invading the nasal bone and extending into the oral cavity. A previous attempt at excision was unsuccessful. Short-term stabilization occurred but progression led to euthanasia 128 days following RT.

A 13-Year-old boxer was irradiated for an intermediate-grade FSA of the right foreleg. The mass extended from the carpus to the elbow. Conservative resection was not an option and the entirety of the tumor was not treatable due to concerns of lymphatic. Survival was 387 days with preservation of the limb. Eventually, euthanasia was undertaken when the lesion was ulcerated and bleeding was no longer controllable.

A 15-year-old Jack Russell Terrier underwent surgery for a HPC of the elbow. Excision was incomplete as the mass was intimately involved with the cephalic vein and the radial nerve. The dog had severe pulmonary fibrosis and a chronic productive cough, and was not evaluated a good candidate for a definitive treatment protocol due to anesthesia concerns. The dog was alive and without evidence of recurrence 379 days following RT.