



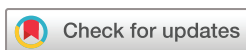# Randomised clinical trial showing the curative effect of bandaging on M2-stage lesions of digital dermatitis in dairy cows

Marcus Klawitter,<sup>1</sup> Dörte Döpfer,<sup>2</sup> Theo Broderick Braden,<sup>3</sup> Ermias Amene,<sup>2</sup> Kerstin Elisabeth Mueller<sup>1</sup>

**To cite:** Klawitter M, Döpfer D, Braden TB, *et al.* Randomised clinical trial showing the curative effect of bandaging on M2-stage lesions of digital dermatitis in dairy cows. *Veterinary Record Open* 2019;6:e000264. doi:10.1136/vetreco-2017-000264

Preliminary results were presented at the 29th World Buiatrics Congress, Dublin, Ireland, July 2016 and the 19th International Symposium and 11th International Conference on Lameness in Ruminants, Munich, Germany, September 2017

Received 29 November 2017  
Revised 10 February 2019  
Accepted 13 February 2019



© British Veterinary Association 2019. Re-use permitted under CC BY-NC. No commercial re-use. Published by BMJ.

<sup>1</sup>Faculty of Veterinary Medicine, Clinic for Ruminants and Swine, Freie Universität Berlin, Berlin, Germany

<sup>2</sup>Department of Medical Sciences, University of Wisconsin—Madison, Madison, Wisconsin, USA

<sup>3</sup>MSSW, School of Medicine, University of Wisconsin—Madison, Madison, Wisconsin, USA

## Correspondence to

Marcus Klawitter; marcus.klawitter@fu-berlin.de

## ABSTRACT

**Objectives and design** This trial evaluated the effect of bandaging of acute painful ulcerative bovine digital dermatitis (DD) lesion (stage M2) in dairy cows, tested using two different topical treatments.

**Design** Randomised clinical trial.

**Setting** This study was conducted using Holstein-Friesian cows ranging in age from heifers to fourth lactation in a single dairy herd and diagnosed with acute ulcerative DD lesions (stage M2) on the first examination (week 0). Cows were randomly assigned into either a non-bandaged or bandaged group across two treatment conditions: topical chlortetracycline spray (CTC) and Intra Hoof-Fit Gel (IHF). Lesions received standardised bandaging and treatment on a weekly basis. Unhealed lesions could receive up to five repeated treatments, at weekly intervals, within a four-week period. Both M-stage and locomotion were also evaluated and scored weekly. Cows with healthily formed skin (stage M0) were deemed healed and subsequently released from the study.

**Results** In total, 163 M2 lesions were diagnosed at week 0. Bandaged M2 lesions had a significantly higher probability of cure than non-bandaged lesions regardless of treatment type (HR: 4.1;  $P < 0.001$ ; 95 per cent CI: 2.5 to 6.8). Most healing occurred within the first three weeks of trial. Furthermore, bandaged lesions (group 2 and group 4) were significantly less likely to progress into the chronic hyperkeratotic or proliferative stage (M4) than non-bandaged lesions in group 1 and group 3 (HR: 0.10;  $P < 0.001$ ; 95 per cent CI: 0.04 to 0.22). Out of concern for the cow's wellbeing, this study investigated the effects of bandaging on locomotion. Bandaging had no effect on locomotion for either cows treated with CTC (group 1: median Sprecher score, 2; IQR=1–2; group 2: median Sprecher score, 2; IQR=1–3;  $P=0.3$ ) or IHF (group 3: median Sprecher score, 2; IQR=1–2; group 4: median Sprecher score, 2; IQR=1–3;  $P=0.3$ ).

## INTRODUCTION

Digital dermatitis (DD) is a painful disease that causes lameness in cattle worldwide.<sup>1 2</sup> Signs of DD include ulcerative circular lesions that emit a distinct odour and have a strawberry-like appearance, typically on the skin between the heels.<sup>3</sup> The precise aetiology of

DD is not fully understood.<sup>4</sup> Previous studies have linked multiple bacterial species to DD lesions.<sup>5</sup> Nonetheless, spirochetes, of the genus *Treponema*, have been consistently found deep within the dermis of infected cows.<sup>6–8</sup> DD largely appears to be multifactorial including a combination of intrinsic and environmental risk factors: stock purchase, low parity, early lactation and moist unhygienic housing conditions.<sup>2 9 10</sup>

Improving environmental hygiene and prompt treatment are critical to controlling DD.<sup>11</sup> However, due to the complexities around improving environmental hygiene, greater emphasis is placed on treatment.<sup>12</sup> Topical antibiotics like tetracyclines are most effective at treating DD in cows individually, while non-antibiotic footbaths, to a lesser degree, are effective at controlling DD in cows collectively.<sup>12–14</sup> While timely detecting and treating acute lesions are critical to preventing the spread of DD,<sup>15</sup> clinical trials often underemphasise the importance of management practices, like bandaging, in treatment protocols. Research on identifying the best combination of products, regimens and approaches to treating DD is needed.<sup>16</sup>

The use of bandaging in the treatment of DD is questionable. Exposure to dirtiness may both weaken the skin and impact the bioavailability of active compounds in treatment, thereby suspending the healing process.<sup>14</sup> Thus, proper bandaging could facilitate the healing process through ensuring lesion cleanliness and prolonging exposure to treatment.<sup>17–19</sup> However, bandages left on too long may cause ischaemic tissue damage and provide a hospitable environment for treponemas.<sup>20–22</sup> More research is needed on the degree and the time to which bandaging facilitates or impedes the healing of DD lesions.<sup>23</sup> Therefore, the aim of this study was

to evaluate the effect of bandaging on healing following topical antibiotic and non-antibiotic treatment.

## MATERIALS AND METHODS

This study was designed as a randomised clinical trial. This trial follows the reporting guidelines for randomised controlled trials in livestock and food safety (REFLECT statement)<sup>24</sup>.

### Farm and study design

The trial took place between July 2013 and November 2014 on a commercial Holstein dairy farm in North-eastern Germany. All cows were free-stall housed, had access to concrete flooring and participated in routine claw trimming two to three times a year. This study included heifers and cows with acute, ulcerative DD lesions that were more than 2 cm in diameter (classified as stage M2) on the digital skin on first examination. All lesions were located adjacent to the plantar or palmar coronary band on digital skin between the heels. Lesions on the interdigital skin were not included. A random number chart from a randomisation generator was used to assign lesions to treatment groups. Taking place between July 2013 and June 2014, the first phase of the study focused on bandaging following topical antibiotic treatment. The second phase of the study, taking place between July 2014 and November 2014, focused on bandaging following topical non-antibiotic treatment. The use of footbaths was not allowed during the time of the trial. Parity ranged from heifers to cows in their fourth lactation. The 305-day milk production for each cow was standardised to 4 per cent fat and 3.3 per cent protein using the energy corrected milk (ECM) formula<sup>25</sup>:

$$\text{ECM milk} = (\text{milk production} \times (0.383 \times \% \text{ fat} + 0.242 \times \% \text{ protein} + 0.7832)) / 3.1138$$

Cows were also categorised into the following scheme based on past hoof treatments and previous trial findings<sup>26</sup>: (A) type I cows with no M2 lesions, (B) type II cows with M2 lesions but no reoccurrence, (C) type III cows with two or more lesions within a period of time.

### Foot examination

All hooves were brushed, cleaned with soap and water, dried with a towel and trimmed by a professional hoof trimmer. Lesion size and locomotion were evaluated, measured and photographed at week 0 and every seven days ( $\pm$ three days) for four consecutive weeks, resulting in a total of five observations. DD lesions were macroscopically classified and recorded using a standardised scoring system comprising six stages.<sup>7 15</sup> Feet with normal skin, without any macroscopical signs of DD, were classified as M0. M1 is an early stage lesion (0–2 cm in diameter) with a moist, ragged red-grey surface. M2 is the acute, classical ulcerative stage manifesting as painful lesions that are more than 2 cm in diameter. M3 comprises the healing stage when the lesion is covered by a scab, which is not painful on touch. M4 is the chronic stage manifesting as hyperkeratosis or surface proliferation. Chronic lesions

with new M1 lesions occurring on the surface were documented as M4.1. Lesions were digitally photographed and magnified using a special software package to measure changes in lesion size and diameter width with enhanced precision (Jalomed, Jalomed GmbH, Germany). A five-point locomotion scoring system<sup>27</sup> was used to evaluate and record lameness in cows by assessing for the presence or absence of an arched back when walking or standing. Locomotion was always scored by the same person when cows were walking and standing on a 12 m alley with concrete flooring. Locomotion scores for normal to mildly lame cows ranged from 1 to 2; scores for moderately lame to severely lame cows ranged from 3 to 5.

### Treatment

Treatment took place in two phases. Cows in the first phase of the study received an antibiotic spray treatment, containing chlortetracycline (CTC) (Cyclo Spray, Albrecht, Aulendorf, Germany), on M2 lesions twice for 3 seconds at 30 seconds intervals ( $n=41$ , group 1). Lesions in group 2 ( $n=44$ ) received the same antibiotic treatment, along with a standardised bandaging technique, administered by the examiner to ensure methodological reliability. First, a 10×20 cm gauze square (NOBATOP8, NOBA Verbandmittel Danz GmbH, Wetter, Germany) was applied to the affected area. Afterwards cotton wool (Klauen- und Polsterbinde, Albrecht GmbH, Aulendorf, Germany) was wrapped around the distal extremity starting at the dew claws through the interdigital cleft, followed by two circular layers. The sole of the hooves was spared. Next, a strong, rigid bandage (NOBASOLID, NOBA Verbandmittel Danz GmbH) was placed to hold these layers in place and tied into a knot at the lateral side of the hoof. Finally, a layer of beech tar (Beech tar WDT, Wirtschaftsgenossenschaft deutscher Tierärzte eG, Garbsen, Germany) was brushed onto the bandage to waterproof it against slurry.

Nearly a 2 mm layer of non-antibiotic gel (Intra Hoof-Fit Gel [IHF]; Intracare, Veghel, The Netherlands), containing copper and zinc chelate, was brushed directly onto the M2 lesions of cows in the second phase of the study using the enclosed IHF paintbrush. Slightly more cows were assigned to the non-bandaged group ( $n=40$ , group 3) than the bandaged group ( $n=38$ , group 4). The bandaging protocol and technique for group 2 were replicated for group 4 (table 1). All cows remained on a dry surface for 30 min post-treatment. When two legs of a cow were affected with an M2 lesion at week 0, both were treated with the same product (CTC or IHF) and randomly assigned to a bandaged or non-bandaged group.

Using the aforementioned procedure, the same person inspected all animals at weekly intervals. Treatment ended for cows deemed healed (M0, table 2). Unhealed lesions ( $\neq$ M0) received up to five repeated applications of treatment during weekly visual inspections for up to four weeks after inclusion into study.

**Table 1** Treatment group assignment and effect of different therapeutic protocols for DD therapy of 163 M2 lesions in 135 cows

Group	Treatment	No. of lesions	No. of healed lesions* (%)
1	CTC	41	18 (43.9)
2	CTC+bandaging	44	38 (86.36)
3	IHF	40	12 (30.0)
4	IHF+bandaging	38	27 (71.1)

\*All transitions from painful M2 lesions to M0 at week 4. CTC, chlortetracycline spray; DD, digital dermatitis; IHF, Intra Hoof-Fit Gel.

### Statistical analysis

Data analyses were performed using Microsoft Excel 2010 software (Microsoft, Redmond, Washington, USA) and R (V.3.2.0, R Core Team 2015<sup>28</sup>). Differences in bivariate populations were measured using a Wilcoxon rank-sum statistical test. A Kruskal-Wallis test measured group differences in parity, 305-day ECM production and initial lesion size. Results of Wilcoxon rank-sum statistical test and Kruskal-Wallis test are reported as median and IQR. For tests denoting significance, a Conover's test was used to make post hoc multiple pairwise comparisons between groups to identify differences precisely. Kaplan-Meier survival functions and Cox proportional hazard regression were performed to estimate the time until cure of DD lesions and the development of the chronic (M4) stage. The multivariate Cox proportional hazard regression was performed in a backward stepwise manner. The first

analysis measured the event of cure and other baseline variables like bandaging, treatment group, parity, initial lesion size and an interaction term for bandaging and treatment group. The variable with the highest P value was eliminated at each step with reanalysis between steps, until the final model was obtained. A second multivariate Cox proportional hazard regression was performed in the same way for the event of the chronic (M4) stage. For all tests, values of  $P < 0.05$  were considered to be statistically significant. Results of survival analysis are reported as HR with 95 per cent CIs. It is assumed that the probability of the event of interest (either to cure or progress into chronic M4 stage) is the same for DD lesions recruited early and late in the study. This assumption was tested by splitting a cohort of lesions in those who were recruited early and those recruited late and checking if their survival curves were different.

## RESULTS

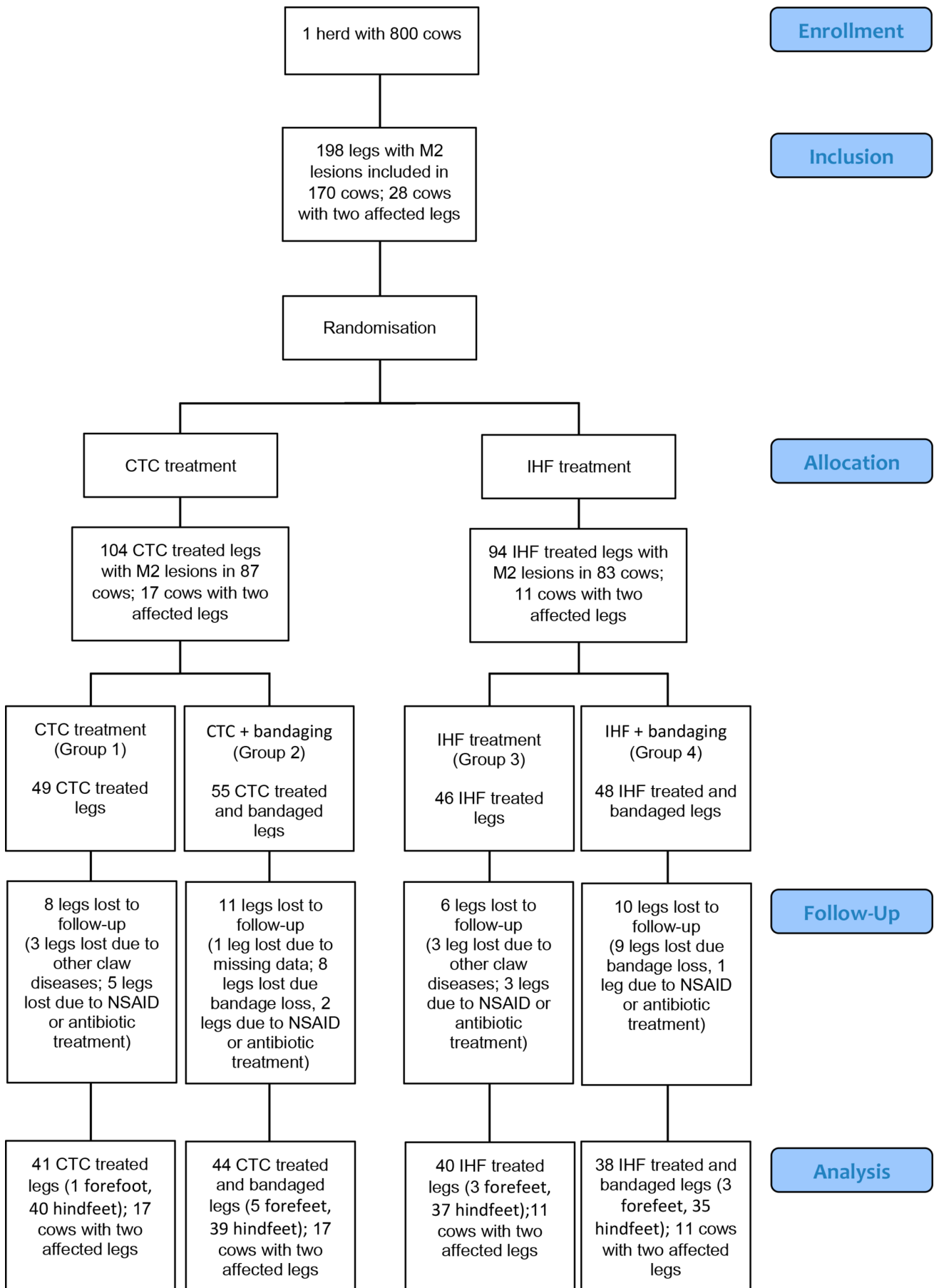
### Distribution of animals and lesions

In total, 198 M2 lesions from 170 cows were diagnosed at week 0. Cows that either lost their bandage at the time of follow-up, received a systemic antibiotic treatment, NSAIDs or suffered from other claw diseases besides DD were excluded from this study ( $n=35$  lesions in 35 cows), resulting in a final sample size of 135 cows with 163 lesions. Twelve DD lesions were located on the fore-feet (7.4 per cent) and 151 lesions on the hind feet (92.6 per cent). A detailed flow diagram of leg inclusion is shown in [figure 1](#). Group differences for parity, 305-day

**Table 2** Scoring of DD lesions from week 1 to week 4 after treatment of M2 DD at week 0

Week	Group	M0	M1	M2	M3	M4	M4.1	Total number
1	1	1	2	11	14	13	0	41
	2	17	7	12	8	0	0	44
	3	2	3	19	4	12	0	40
	4	3	7	26	2	0	0	38
2	1	6	3	8	9	14	0	40
	2	10	7	5	4	1	0	27
	3	5	1	2	3	27	0	38
	4	10	12	9	3	1	0	35
3	1	8	2	4	5	14	1	34
	2	9	3	4	0	1	0	17
	3	3	3	1	2	22	2	33
	4	11	7	7	0	0	0	25
4	1	3	1	4	7	11	0	26
	2	2	1	4	0	1	0	8
	3	2	5	0	3	19	1	30
	4	3	4	5	1	1	0	14

M0 healed stage, M1 early stage, M2 ulcerative stage, M3 healing stage, M4 chronic stage, M 4.1 chronic lesion with a small area of ulceration; total number of observations at week 0: group 1 (CTC) had  $n=41$  lesions, group 2 (CTC + bandaging) had  $n=44$  lesions, group 3 (IHF) had  $n=40$  lesions, group 4 (IHF + bandaging) had  $n=38$  lesions. DD, digital dermatitis.



**Figure 1** Flow diagram of leg inclusion. CTC, chlortetracycline spray; IHF, Intra Hoof-Fit Gel.

**Table 3** Baseline measures and comparisons among different treatment groups on basis of parity, energy corrected milk (ECM) and initial size of digital dermatitis lesions

	Group 1 CTC (n=41)	Group 2 CTC+bandage (n=44)	Group 3 IHF (n=40)	Group 4 IHF+bandage (n=38)	P value
Parity	2	1	2	1.5	0.01*
Median±IQR†	±1	±1.25	±2	±1	
305-day ECM (kg)	9233	8718	8595	7941	0.85
Median±IQR†	±3874	±5171	±4827	±3755	
DIM (days)	51.5	75	92.5	91.5	0.14
Median±IQR†	±311	±187	±90.5	±109	
Initial lesion size (cm <sup>2</sup> )	6.01	4.65	5.85	8.13	0.03*
Median±IQR†	±6.57	±7.10	±3.54	±4.75	

\*Denotes significance at the P<0.05 level.

†IQR was calculated.

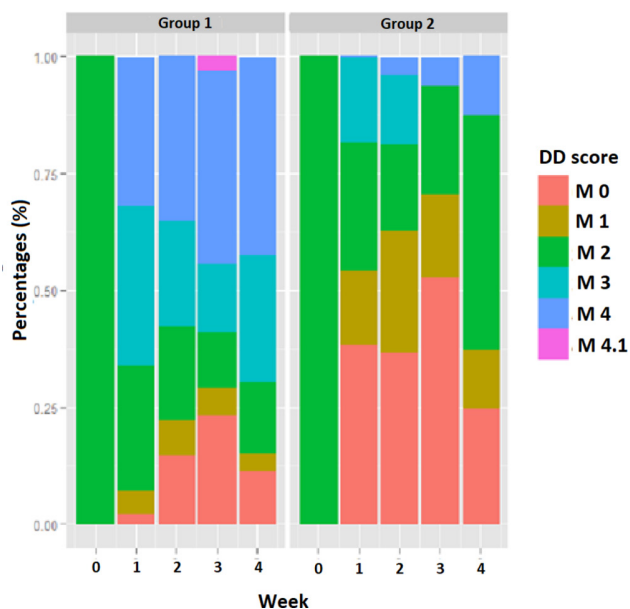
IQR, interquartile range; DIM, days in milk; ECM, energy corrected milk CTC, chlortetracycline spray; IHF, Intra Hoof-Fit Gel.

ECM production and initial lesion size are shown in table 3. Multiple post hoc pairwise analysis (Conover's test) identified significant group differences between groups 2 and 3 (P=0.01) and groups 2 and 4 (P=0.04), respectively in parity and initial lesion size. The distribution of M stages during the four weeks period is shown in percentages in figures 2 and 3.

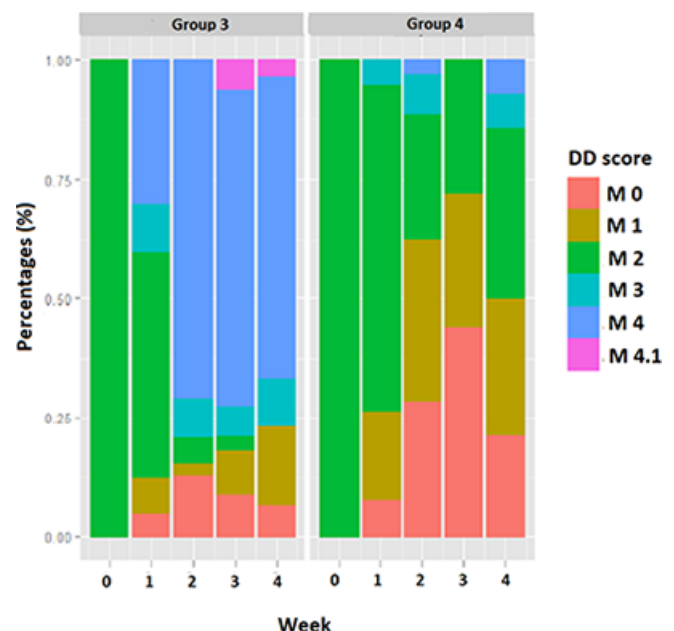
### Bivariate analysis

Bandaging had no effect on locomotion for either cows treated with CTC (group 1: median Sprecher score, 2; IQR=1–2; group 2: median Sprecher score, 2; IQR=1–3; P=0.3) or IHF (group 3: median Sprecher score, 2; IQR=1–2; group 4: median Sprecher score, 2; IQR=1–3; P=0.3). However, wound size was significantly larger for lame cows (locomotion scores between 3 and 5; groups 1

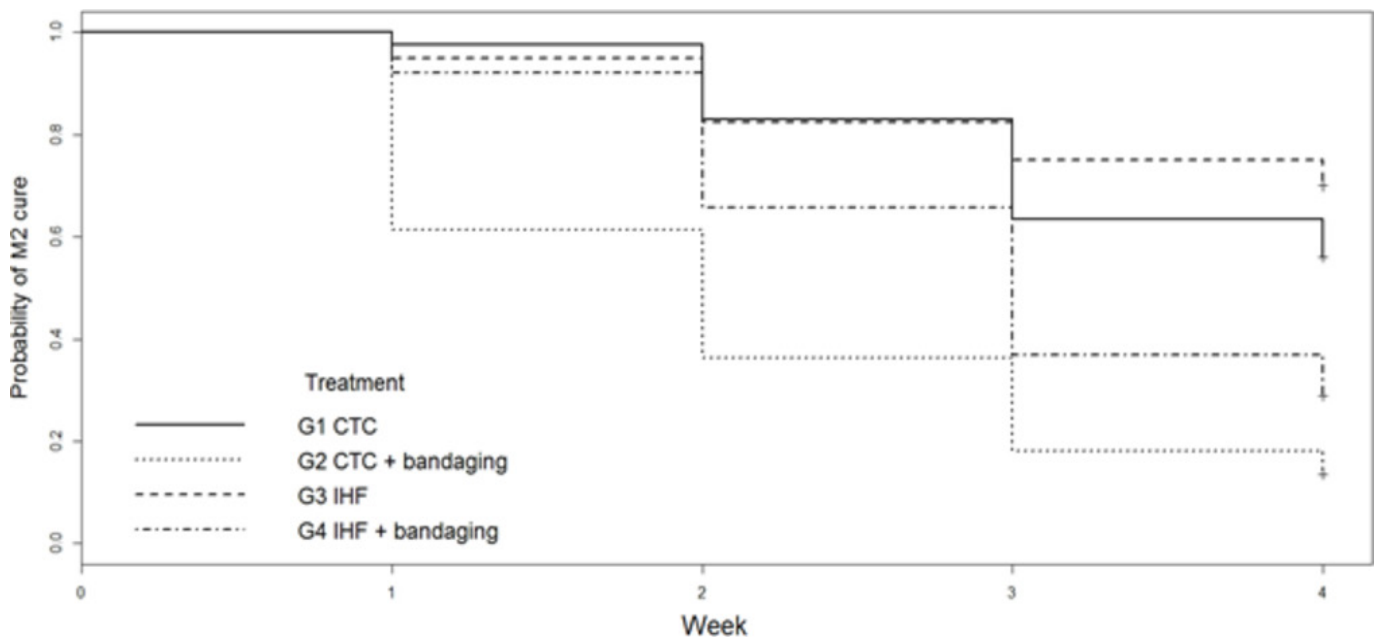
and 2: median lesion size, 4.49 cm<sup>2</sup>; IQR=2.08–8.02 cm<sup>2</sup>; groups 3 and 4: median lesion size, 5.74 cm<sup>2</sup>; IQR=3.03–8.36 cm<sup>2</sup>) than for cows with healthier locomotion scores (lower scores 1 and 2) for both CTC (groups 1 and 2: median lesion size, 3.37 cm<sup>2</sup>; IQR=1.15–5.82 cm<sup>2</sup>; P=0.02) and IHF treatment groups (groups 3 and 4: median lesion size, 3.64 cm<sup>2</sup>; IQR=1.60–6.30 cm<sup>2</sup>; P<0.001). The clustering of cows in cow type II and III showed no significant impact on lesions size neither at the beginning of the trial for lesions treated with CTC (type II cows: median lesion size, 8.89 cm<sup>2</sup>; IQR=3.33–16.10 cm<sup>2</sup>; type III cows: median lesion size, 5.26 cm<sup>2</sup>; IQR=3.74–8.30 cm<sup>2</sup>; P=0.2) and IHF (type II cows: median lesion size, 7.41 cm<sup>2</sup>; IQR=5.11–9.08 cm<sup>2</sup>; type III cows: median lesion size, 6.58 cm<sup>2</sup>; IQR=4.68–9.17 cm<sup>2</sup>; P=0.6) nor during the healing process (week 0–4) (CTC: type II



**Figure 2** Distribution of M-stages treated with chlortetracycline spray at each examination. DD, digital dermatitis.



**Figure 3** Distribution of M-stages treated with Intra Hoof-Fit Gel at each examination. DD, digital dermatitis.



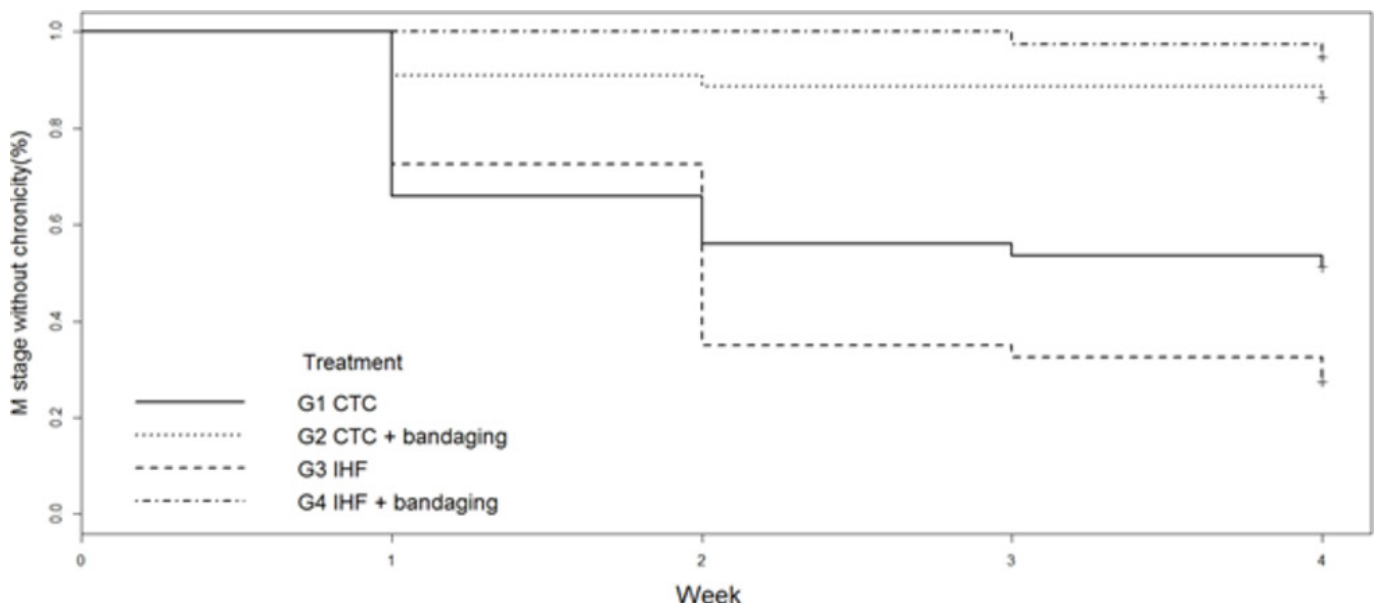
**Figure 4** Kaplan-Meier survival analysis plots for digital dermatitis (DD) lesions stratified by different treatment groups and time until cure of DD (M0) as the outcome of interest. CTC, chlortetracycline spray; IHF, Intra Hoof-Fit Gel.

cows: median lesion size, 2.57 cm<sup>2</sup>; IQR=0.0–6.22 cm<sup>2</sup>; type III cows: median lesion size, 3.95 cm<sup>2</sup>; IQR=1.83–6.45 cm<sup>2</sup>; P=0.08 and IHF: type II cows: median lesion size, 4.39 cm<sup>2</sup>; IQR=1.72–6.53 cm<sup>2</sup>; type III cows: median lesion size, 4.27 cm<sup>2</sup>; IQR=1.99–6.97 cm<sup>2</sup>; P=0.6).

#### Survival analysis: time until healing and transition to chronic (M4) stage

Eighty-six per cent of bandaged (n=38, group 2) and 44 per cent (n=18, group 1) of non-bandaged cows receiving CTC treatment were deemed macroscopically healed by week 4, whereas 71 per cent of bandaged (n=27, group 4) and 30 per cent (n=12, group 3) of non-bandaged

cows receiving IHF treatment were healed at the same time. Bandaged lesions had a significantly higher probability of cure than non-bandaged lesions regardless of treatment type (HR: 4.1; P<0.001; 95 per cent CI: 2.5 to 6.8; [figure 4](#)). A Kaplan-Meier graph estimated the overall time until chronic (M4) stage. Specifically, the Cox proportional hazards model compared time until progression into chronic M4 lesions. Results indicated that bandaged lesions (group 2 and group 4) were significantly less likely to progress into chronic M4 stage lesions than non-bandaged lesions in group 1 and group 3 (HR: 0.1; P<0.001; 95 per cent CI: 0.04 to 0.22; [figure 5](#)).



**Figure 5** Kaplan-Meier survival analysis plots for digital dermatitis lesions stratified by different treatment groups and survival without the chronic (M4) stage as the outcome of interest. CTC, chlortetracycline spray; IHF, Intra Hoof-Fit Gel.

Furthermore, the multivariate Cox proportional hazard regression identified bandaging as the only variable in the model with a significant effect on the probability of cure as well as on the prevention of the chronic (M4) stage. Most lesions were healed within two to three weeks of the study. Despite significant group differences at the beginning of the trial, results demonstrate that parity ( $P=0.7$ ) and initial lesion size ( $P=0.4$ ) had no significant impact on healing.

Of the 28 cows with two affected legs, 17 and 11 cows were assigned to CTC and IHF treatment groups, respectively. Results for cows with both bandaged and non-bandaged lesions are consistent with overall findings. Cure rates for bandaged CTC lesions had a cure rate of 76 per cent ( $n=13$ ) while 41 per cent ( $n=7$ ) of non-bandaged CTC lesions were cured. Bandaged IHF lesions had a cure rate of 55 per cent ( $n=6$ ), while 9 per cent ( $n=1$ ) of non-bandaged IHF lesions were cured. Transition to chronic (M4) stage was lower for bandaged CTC lesions (6 per cent;  $n=1$ ) than non-bandaged CTC lesions (53 per cent,  $n=9$ ). Similarly, 82 per cent ( $n=9$ ) of non-bandaged IHF lesions transitioned to chronic M4 stage while 9 per cent ( $n=1$ ) of bandaged IHF lesions transitioned.

## DISCUSSION

The aim of this study was to evaluate the effect of bandaging in healing lesions with different topical DD treatments. Overall, the cure rate was significantly higher for bandaged lesions (groups 2 and 4) than non-bandaged lesions (groups 1 and 3) regardless of antibiotic (eg, CTC) and non-antibiotic (eg, IHF) treatment. An increased cure rate of painful ulcerative M2 lesions using bandages reduces pain among affected animals, thereby improving animal welfare. Although both groups had the highest cure rates, a 15 per cent difference in cure rates between the groups was detected. A difference in efficacy between the two treatments (CTC and IHF) could be possible explanations, even if they were not identified by the Cox regression as a significant factor in risk of cure. To detect if this was due to sample size, a power analysis with 80 per cent power at  $P\leq 0.05$  level of significance determined that the authors needed a sample size of 115 animals per group to evaluate the effect of the active component on cure.

Specifically, 86 per cent and 71 per cent of lesions were cured under bandaged CTC and IHF treatment, respectively by week 4. By contrast, the cure rates for non-bandaged CTC (44 per cent) and IHF (30 per cent) treatment were nearly half that of bandaged lesions within the same period of time. Most healing occurred within the first three weeks of trial. This suggests that maybe longer treatment is less effective. Cure rates for bandaged antibiotic treatment match previous findings of 86–87 per cent.<sup>18 19</sup> The cure rates for bandaged IHF (71 per cent) and non-bandaged tetracycline (44 per cent) align with a previous study on IHF (Holzhauer and others,<sup>29</sup> IHF: 92 per cent

and CTC: 68 per cent), whereby differences in layout of the study, definition of 'cure' and environmental factors, like barn cleanliness and moisture, as well as the M-stage and the anatomical location of the lesion<sup>30 31</sup> may explain small differences in results. Researchers should further explore the impact of the environment on bandage effectiveness.

Surprisingly, the authors found that bandaging had a significant effect in reducing the transition of M2 into M4 lesions. Many researchers agree that preventing lesions from progressing to M4 is the key to controlling DD<sup>15</sup> because M4 lesions tend to be more hyperkeratotic compared with M2 lesions,<sup>32</sup> which complicates the penetrability of topical treatments.<sup>31</sup> Schultz and Capion<sup>31</sup> found that M4 lesions were 13.3 times less likely to improve than their M2 equivalents ( $P>0.01$ ). Cows with a history of M4 lesions suffer recurrent lesions that often progress into open lesions on proliferated skin (M4.1).<sup>15</sup>

Considering the findings, the authors must address four limitations. First, this study omitted a placebo group for animal welfare reasons. In fact, previous studies find that, M2 lesions, the most painful stage of DD, either show no improvement or even worsen when treated with water spray.<sup>33</sup> Toholj and others<sup>19</sup> researched the effect of bandaging alone. They concluded that bandaging lesions after cleaning with a dry towel had no effect on healing. However, lesions receiving bandaged CTC treatment had significantly higher cure rates. To minimise animal distress, the authors decided to compare the effect of two registered products rather than using a placebo group. Still, the authors acknowledge the importance of having a control group as cure rates are influenced by a myriad of factors (eg, floor cleanliness, cow-to-cubicle ratio and correct cubicle size).<sup>34</sup> Replicating this study with negative control groups could entail washing the lesion with soap and water, drying it with a towel and then either bandaging or non-bandaging at weekly intervals, up to five times. Second, the authors must mention that the CTC treatment did not follow the instructions of the manufacturer, who recommends two applications at 30 seconds intervals, once or twice daily for three consecutive days. It was only feasible for us to treat cows once per week, which is comparable to the study by Toholj and others.<sup>19</sup> This may have reduced the cure rate of lesions treated with CTC. Third, detecting the presence of treponemes in histological samples of lesion post-treatment was beyond the scope of this project. While the findings strongly suggest that bandaging prevented the transition of M2 lesions into the chronic M4 stage, the potential lingering presence of treponemes on the skin may cause recurrent infections. Berry and others<sup>15</sup> found that all lesions receiving bandaged lincomycin treatment histologically healed by day 12. However, only roughly half were histologically healed by days 23 and 37. Their findings are consistent with other studies.<sup>35 36</sup> Future studies should further explore histological long-term reoccurrence rates of bandaged DD lesions. Fourth, this study only examined the effects of bandaging on lesions

adjacent to the coronary band between the heels as these heal significantly faster than lesions on interdigital skin.<sup>37</sup> Further studies are required to analyse the effects of bandaging on interdigital lesion.

In this study, cure rates did not differ significantly between bandaged CTC and IHF treatment. The implications of this is that farmers can choose treatment options based on their needs and concerns. The hazard potential of extensive antibiotic treatment, namely antibiotic resistance and the presence of antibiotic residue in milk, meat and surrounding soil of treated animals,<sup>38–40</sup> may influence strong preference for non-antibiotic formulations. Furthermore, a long history of tetracycline treatment on a farm can cause a reduced efficacy under field conditions.<sup>37</sup> Therefore, some researchers have tested different non-antibiotic treatments to overcome these challenges. One study showed that a non-antibiotic paste (Protexin Hoof-Care) containing metallic salts and organic acids is effective against DD.<sup>41</sup> Another study revealed that salicylic acid and polyurethane dressings are useful for the treatment of DD lesions.<sup>42</sup> A recent study by Chiba and others<sup>43</sup> showed that allyl isothiocyanate, a natural extract from plants of family Brassicaceae, is also effective in treating DD. These studies demonstrate that non-antibiotic agents are effective alternatives in the treatment of DD. The authors results highlight an increased efficacy of non-antibiotic treatment in combination with bandaging.

Despite showing the effect of bandaging in promoting healing in treated cows, this study also acknowledges the impracticality of bandaging. The costliness of bandaging, in terms of time and resources,<sup>19</sup> may fatigue farmers. The bandaging process demands skill in applying and removing bandages to protect cows from ischaemic injuries.<sup>20</sup> This study used a moderately complex bandaging technique, whereby a layer of beech tar was added to a padded bandage. This technique might have been effective in healing 70 per cent–86 per cent of bandaged lesions because the beech tar layer waterproofed and stabilised the bandage which protected the lesion and prolonged exposure to treatment. Future studies should explore alternatives that mimic the effect of bandaging in protecting and prolonging treatment to lesions,<sup>18 44</sup> but are more practical in terms of time and application. Such information could help farmers make informed decisions about resources and costs, which may further increase adherence.

## CONCLUSION

In this study, the authors found that cure rates for bandaged treatment were significantly higher than non-bandaged treatment regardless of treatment condition (CTC vs IHF), that bandaging significantly prevented the transition of M2 into chronic M4 lesions and that the highest cure rate for bandaging was roughly during the first three weeks of treatment. The authors also found that wound size rather than bandaging had a significant effect on locomotion.

**Acknowledgements** The authors would like to thank the dairy farmers Mr. Jürgen Tripke and Mrs. Mohr for their participation and interest in this study and the claw trimmers of 'Klaupflege Findeisen GmbH & Co. KG' and Holger Mehler for their patience and accurate trimming of the dairy cows.

**Contributors** MK and KEM contributed substantially to the conception and design of this study, as well as the acquisition of data. MK, TB, EA and DD analysed and interpreted data. MK and TB wrote an early version of the manuscript, which KEM, EA and DD revised critically for important intellectual content. All authors finally approved the version to be published.

**Funding** Funding for this project was partly provided by Cusanuswerk scholarship. The study was also supported by the Open Access Publication Fund of Freie Universität Berlin.

**Competing interests** None declared.

**Ethics approval** This study was approved for ethical and medical issues by the Regional Veterinary Department Berlin (Landesamt für Gesundheit und Soziales, Number StN 0014-18).

**Provenance and peer review** Not commissioned; externally peer reviewed.

**Data sharing statement** Additional unpublished data are not available.

**Open access** This is an open access article distributed in accordance with the Creative Commons Attribution Non Commercial (CC BY-NC 4.0) license, which permits others to distribute, remix, adapt, build upon this work non-commercially, and license their derivative works on different terms, provided the original work is properly cited and the use is non-commercial. See: <http://creativecommons.org/licenses/by-nc/4.0/>

## REFERENCES

- 1 Blowey RW, Sharp MW. Digital dermatitis in dairy cattle. *Vet Rec* 1988;122:505–8.
- 2 Wells SJ, Garber LP, Wagner BA. Papillomatous digital dermatitis and associated risk factors in US dairy herds. *Prev Vet Med* 1999;38:11–24.
- 3 Cornelisse JL, Peterse DJ, Toussaint-raven E. A digital disorder in dairy cattle, digital dermatitis? *Neth J Vet Assoc* 1981;106:452–5.
- 4 Wilson-Welder JH, Alt DP, Nally JE. The etiology of digital dermatitis in ruminants: recent perspectives. *Vet Med Res Rep* 2015;6:155–64.
- 5 Krull AC, Shearer JK, Gorden PJ, et al. Deep sequencing analysis reveals temporal microbiota changes associated with development of bovine digital dermatitis. *Infect Immun* 2014;82:3359–73.
- 6 Blowey R. Diseases of the bovine digit: Part 1 Description of common lesions. *In Pract* 1992;14:85–90.
- 7 Döpfer D, Koopmans A, Meijer FA, et al. Histological and bacteriological evaluation of digital dermatitis in cattle, with special reference to spirochaetes and *Campylobacter faecalis*. *Vet Rec* 1997;140:620–3.
- 8 Miliinovich GJ, Turner SA, McLennan MW, et al. Survey for papillomatous digital dermatitis in Australian dairy cattle. *Aust Vet J* 2004;82:223–7.
- 9 Read D, Walker R. Comparison of papillomatous digital dermatitis and digital dermatitis of cattle by histopathology and immunohistochemistry. In *Proceedings of the 10th international symposium on lameness in ruminants*, Lucerne, 1998:268
- 10 Somers JG, Frankena K, Noordhuizen-Stassen EN, et al. Risk factors for digital dermatitis in dairy cows kept in cubicle houses in The Netherlands. *Prev Vet Med* 2005;71:11–21.
- 11 Oliveira VHS, Sørensen JT, Thomsen PT. Associations between biosecurity practices and bovine digital dermatitis in Danish dairy herds. *J Dairy Sci* 2017;100:8398–408.
- 12 Laven RA, Logue DN. Treatment strategies for digital dermatitis for the UK. *Vet J* 2006;171:79–88.
- 13 Reichenbach H, Jones B, Bewley J. Comparison of Two Footbath Solutions for Digital Dermatitis Control in Dairy Cattle: Two Point Percent (2.2%) Copper Sulfate with an Acidifier versus Five Percent (5%) Copper Sulfate. *Intern J Appl Res Vet Med* 2017;15 <https://www.jarvm.com/articles/Vol15Iss2/Vol15%20Iss2Jones.pdf>.
- 14 Relun A, Lehebel A, Bareille N, et al. Effectiveness of different regimens of a collective topical treatment using a solution of copper and zinc chelates in the cure of digital dermatitis in dairy farms under field conditions. *J Dairy Sci* 2012;95:3722–35.
- 15 Berry SL, Read DH, Famula TR, et al. Long-term observations on the dynamics of bovine digital dermatitis lesions on a California dairy after topical treatment with lincomycin HCl. *Vet J* 2012;193:654–8.





- 16 Relun A, Guatteo R, Auzanneau MM, *et al.* Farmers' practices, motivators and barriers for adoption of treatments of digital dermatitis in dairy farms. *Animal* 2013;7:1542–50.
- 17 Cramer G, Lissemore KD, Guard CL, *et al.* Herd- and cow-level prevalence of foot lesions in Ontario dairy cattle. *J Dairy Sci* 2008;91:3888–95.
- 18 Manske T, Hultgren J, Bergsten C. Topical treatment of digital dermatitis associated with severe heel-horn erosion in a Swedish dairy herd. *Prev Vet Med* 2002;53:215–31.
- 19 Toholj B, Kos J, Smolec O, *et al.* Efficiency of different therapeutic protocols in treating digital dermatitis in dairy cows. *Veterinarski arhiv* 2012;82:133–42 [www.vet.unizg.hr/vetarhiv/papers/2012-82-2-2.pdf](http://www.vet.unizg.hr/vetarhiv/papers/2012-82-2-2.pdf).
- 20 Anderson DM, White RA. Ischemic bandage injuries: a case series and review of the literature. *Vet Surg* 2000;29:488–98.
- 21 Gomez A, Döpfer D, Cook NB, *et al.* Non-healing hoof lesions in dairy cows. *Vet Rec* 2011;169:642.
- 22 Cutler JH, Cramer G, Walter JJ, *et al.* Randomized clinical trial of tetracycline hydrochloride bandage and paste treatments for resolution of lesions and pain associated with digital dermatitis in dairy cattle. *J Dairy Sci* 2013;96:7550–7.
- 23 Nishikawa A, Taguchi K. Healing of digital dermatitis after a single treatment with topical oxytetracycline in 89 dairy cows. *Vet Rec* 2008;163:574–6.
- 24 O'Connor AM, Sargeant JM, Gardner IA, *et al.* The REFLECT statement: methods and processes of creating reporting guidelines for randomized controlled trials for livestock and food safety by modifying the CONSORT statement. *Zoonoses Public Health* 2010;57:95–104.
- 25 Flachowsky G, Jeroch H, Kirchgeßner M, *et al.* *Empfehlungen zur Energie- und Nährstoffversorgung der Milchkühe und Aufzuchtinder.* Frankfurt: DLG-Verlag, 2001.
- 26 Döpfer D, Van Boven M, Jong DE. A mathematical model for the dynamics of digital dermatitis in dairy cattle. In *Proceedings of the 13th ICPD*, Lansing, USA, 2004:37.
- 27 Sprecher DJ, Hostetler DE, Kaneene JB. A lameness scoring system that uses posture and gait to predict dairy cattle reproductive performance. *Theriogenology* 1997;47:1179–87.
- 28 R Core Team. *R: A language and environment for statistical computing.* Vienna, Austria: R Foundation for Statistical Computing, 2015.
- 29 Holzhauer M, Bartels CJ, van Barneveld M, *et al.* Curative effect of topical treatment of digital dermatitis with a gel containing activated copper and zinc chelate. *Vet Rec* 2011;169:555.
- 30 Bathina H, Lising J, Hemling T, *et al.* Correlation of the stage of lesion to the effectiveness of treatment of digital dermatitis. In *Proc. 12th Intern. Symp. Lameness Ruminants*, Orlando, FL, 2002:381–2.
- 31 Schultz N, Capion N. Efficacy of salicylic acid in the treatment of digital dermatitis in dairy cattle. *Vet J* 2013;198:518–23.
- 32 Klitzgaard K, Boye M, Capion N, *et al.* Evidence of multiple *Treponema* phylotypes involved in bovine digital dermatitis as shown by 16S rRNA gene analysis and fluorescence in situ hybridization. *J Clin Microbiol* 2008;46:3012–20.
- 33 Esch M. Untersuchungen zur Wirksamkeit eines Poly-Vinyl-Pyrrolidon (PVP)-Jodkomplexes zur Behandlung der Dermatitis digitalis (D.d.) und zum Bewegungsverhalten von an D.d. erkrankten Milchkühen. 2004. Dissertation [https://edoc.ub.uni-muenchen.de/2661/1/Esch\\_Monika.pdf](https://edoc.ub.uni-muenchen.de/2661/1/Esch_Monika.pdf).
- 34 Holzhauer M. Foot bathing dairy cows with antibiotics. *Vet Rec* 2017;181:270.1–270.
- 35 Berry SL, Read DH, Walker RL, *et al.* Clinical, histologic, and bacteriologic findings in dairy cows with digital dermatitis (footwarts) one month after topical treatment with lincomycin hydrochloride or oxytetracycline hydrochloride. *J Am Vet Med Assoc* 2010;237:555–60.
- 36 Holzhauer M, Bartels CJ, Döpfer D, *et al.* Clinical course of digital dermatitis lesions in an endemically infected herd without preventive herd strategies. *Vet J* 2008;177:222–30.
- 37 Shearer JK, Hernandez J. Efficacy of two modified nonantibiotic formulations (Victory) for treatment of papillomatous digital dermatitis in dairy cows. *J Dairy Sci* 2000;83:741–5.
- 38 Britt JS, Carson MC, von Bredow JD, *et al.* Antibiotic residues in milk samples obtained from cows after treatment for papillomatous digital dermatitis. *J Am Vet Med Assoc* 1999;215:833–6.
- 39 Hamscher G, Sczesny S, Abu-Qare A, *et al.* [Substances with pharmacological effects including hormonally active substances in the environment: identification of tetracyclines in soil fertilized with animal slurry]. *Dtsch Tierarztl Wochenschr* 2000;107:332–4.
- 40 Wallmann J, Schröter K, Wieler L, *et al.* Antibiotic sensitivity in selected veterinary pathogens from sick food animals in Germany: Results 2001 from the study model of the national antibiotic resistance monitoring. *Tierarztl Prax Ausg G* 2003;31:122–31.
- 41 Kofler J, Pospichal M, Hofmann-Parisot M. Efficacy of the Non-antibiotic Paste ProtexinR Hoof-Care for Topical Treatment of Digital Dermatitis in Dairy Cows. *J Vet Med A* 2004;51:447–52.
- 42 Fiedler A, Sauter-Louis C, Maierl J. Polyurethane dressing, tetracycline and salicylic acid use for treatment of digital dermatitis in cattle. A comparative study. *Tierarztl Prax Ausg G* 2015;43:350–8.
- 43 Chiba K, Miyazaki T, Sekiyama Y, *et al.* The therapeutic efficacy of allyl isothiocyanate in cows with bovine digital dermatitis. *J Vet Med Sci* 2017;79:1191–5.
- 44 Watson C. *Bandaging. Lameness in cattle.* London: The Crowood Press, 2007.