

Images in medicine

Klippel-Feil syndrom: a duplicated thumb

Aryé Weinberg^{1,&}, Andreas Eberhard Albers²

¹Prosper-Hospital, Department of Otorhinolaryngology, Head and Neck Surgery, Recklinghausen, Germany, ²Department of Otorhinolaryngology, Head and Neck Surgery, Berlin Institute of Health, Charité Universitätsmedizin Berlin, Campus Benjamin Franklin, Berlin, Germany

[&]Corresponding author: Aryé Weinberg, Prosper-Hospital, Department of Otorhinolaryngology, Head and Neck Surgery, Recklinghausen, Germany

Key words: Klippel-Feil syndrom, duplicated thumb, skeletal disease

Received: 12/06/2018 - Accepted: 26/07/2018 - Published: 20/09/2018

Pan African Medical Journal. 2018;31:42. doi:10.11604/pamj.2018.31.42.16327

This article is available online at: <http://www.panafrican-med-journal.com/content/article/31/42/full>

© Aryé Weinberg *et al.* The Pan African Medical Journal - ISSN 1937-8688. This is an Open Access article distributed under the terms of the Creative Commons Attribution License (<http://creativecommons.org/licenses/by/2.0>), which permits unrestricted use, distribution, and reproduction in any medium, provided the original work is properly cited.

Image in medicine

A 71-year-old woman was admitted to our hospital because of vertigo. At clinical examination a duplicated right thumb was noticed. The Patient revealed that she was suffering from Klippel-Feil Syndrom (KFS). KFS is a rare skeletal disease where a mutation of the GDF6 and GDF3 genes can be found. It is characterized by congenital fusion of any of the 7 cervical vertebrae. There can be associations with other malformations such as congenital elevation of the scapula (Sprengel's deformity), spina bifida, scoliosis, cleft palate, malformations of the heart, head, face, arms, legs and fingers. Because of these heterogeneous medical conditions treatment for KFS is symptomatic and can include surgery.

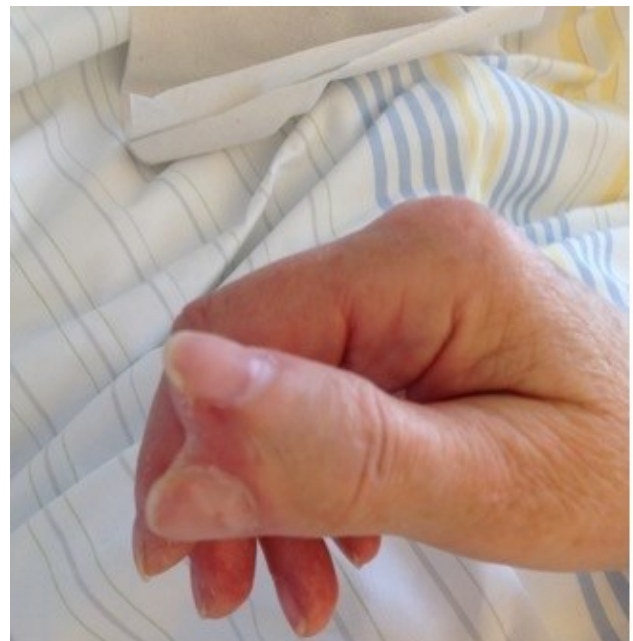


Figure 1: duplicated thumb