

## 4.5 Selected clinical cases

### 4.5.1 Case No.1 (Figure 58-63)

#### History:

A two-year-old, 2 kg castrated male ferret (Nr.37) was presented to the Small Animal Clinic due to a decrease in exercise tolerance for 3 weeks.

#### Physical examination:

On the physical examination, he was quiet and had a normal body condition. The mucous membranes were pink and moist, the capillary refill time < 2 sec. Heart rate was around 220 bpm. Cardiac auscultation showed a 2/5 heart murmur on the left side of the thorax.

The lateral thoracic radiography revealed a heart silhouette around 3 ICS in width. The trachea was elevated dorsally indicating cardiac enlargement (Figure 58).

A six lead electrocardiogram was performed. The ECG heart rate was 360 bpm. P wave was 0.05 mV x 0.02 sec, RII 2.0-2.2 mV, QRS 0.02 sec, PQ 0.05 sec. The patients had a sinus rhythm at the beginning, interrupted by VPC (Figure 59).

Echocardiography revealed LVWd 0.22 cm, LVDd 1.38 cm, IVSd 0.21 cm, LVWs 0.31 cm, LVDs 1.08 cm, IVSs 0.27 cm, FS 22.17%, AO 0.44 cm, LA 0.64 cm, LA/AO = 1.45 (Figure 60). Doppler examination showed a regurgitation jet on both AV valves (Figure 61). No regurgitation jet was detected at the aortic and pulmonic valves.

#### Diagnosis and treatment:

DCMP was diagnosed and the patient was treated with Lanoxin (digoxin 0.005 mg/kg SID). At the next examination after 2 months duration of treatment the patient showed an improvement in exercise tolerance. On the lateral thoracic radiograph the cardiac silhouette was reduced to 2½ ICS in size. The trachea had an angle around 15 degree with the thoracic vertebral column. The ECG showed a normal sinus rhythm reduced to a rate of 280 bpm. The normal sinus rhythm was interrupted by only one VPC during the ambulatory examination (Figure 62). M-mode echocardiography showed the FS increased to 35% and no regurgitation was detected on both AV valves by Doppler echocardiography. (Figure 63)

## Results

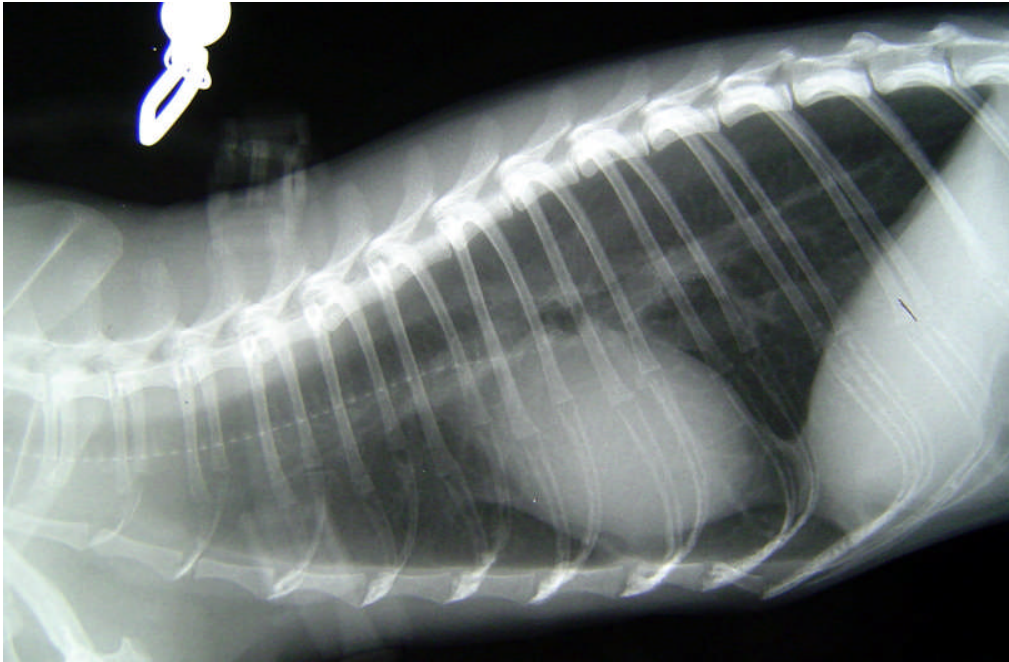
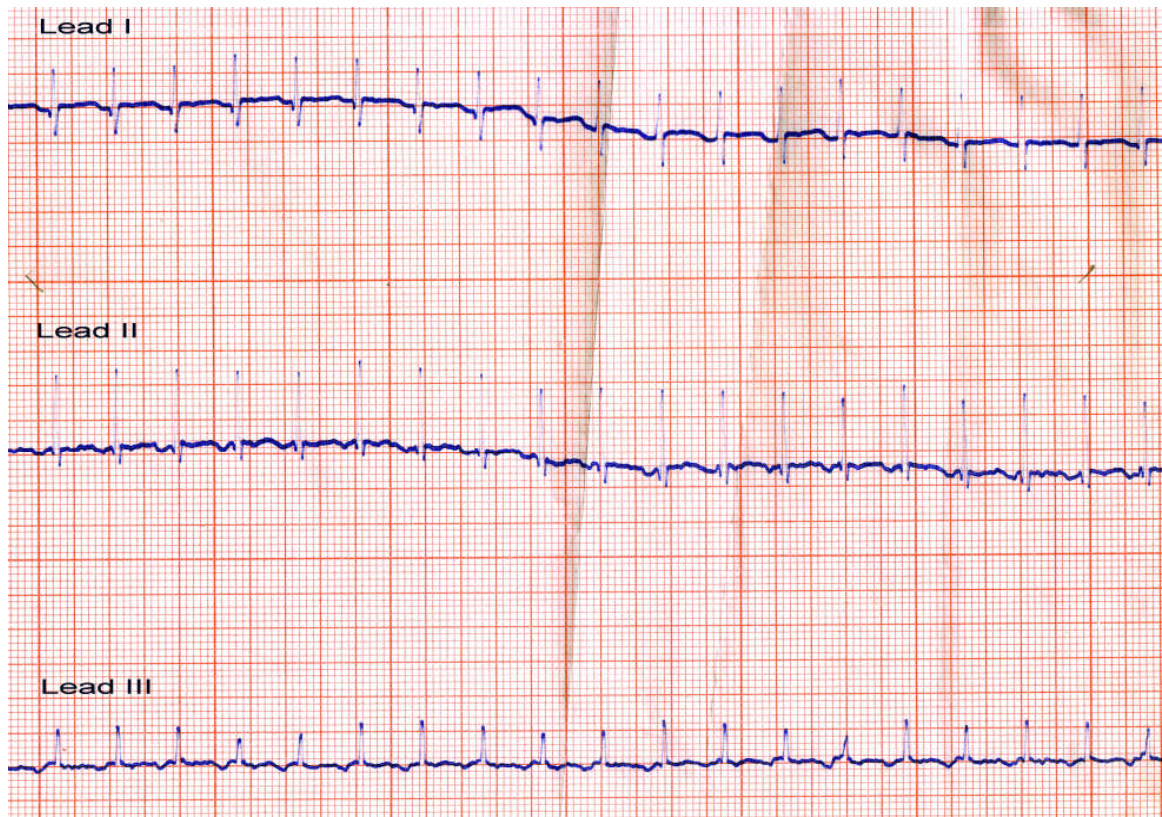


Figure 58: A two year old male ferret the lateral thoracic radiography shows the heart around 3 ICS wide. The trachea is elevated. The heart has no contact with the sternum.

## Results

A



B

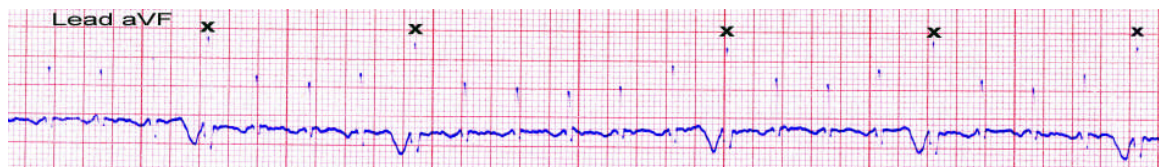

Figure 59: ECG recorded at the first visit. A, lead I, II, III ECG recorded at the beginning of examination. The rhythm reveals normal sinus rhythm. P is negative 0.1 mV x 0.04 sec, RII 2.0-2.2 mV, QRS 0.02 sec, PQ 0.05 sec; B, on lead aVF the sinus rhythm is broken by ventricular ectopic beats (X). (Paper speed 50 mm/sec, sensitivity 0.5 cm/mV)

## Results

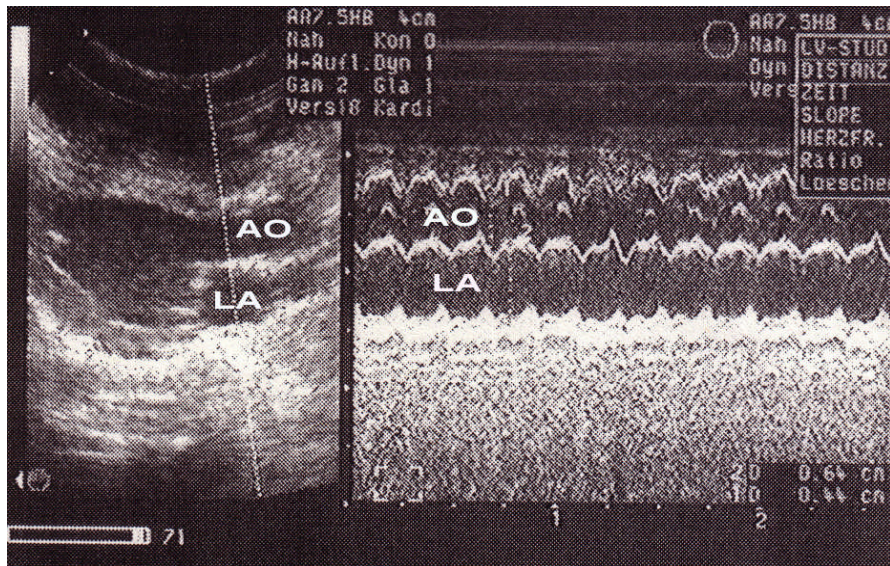


Figure 60: M-mode echocardiography demonstrates a 0.44 cm dimension of the aortic root (AO) and 0.64 cm of the left atrial size (LA).

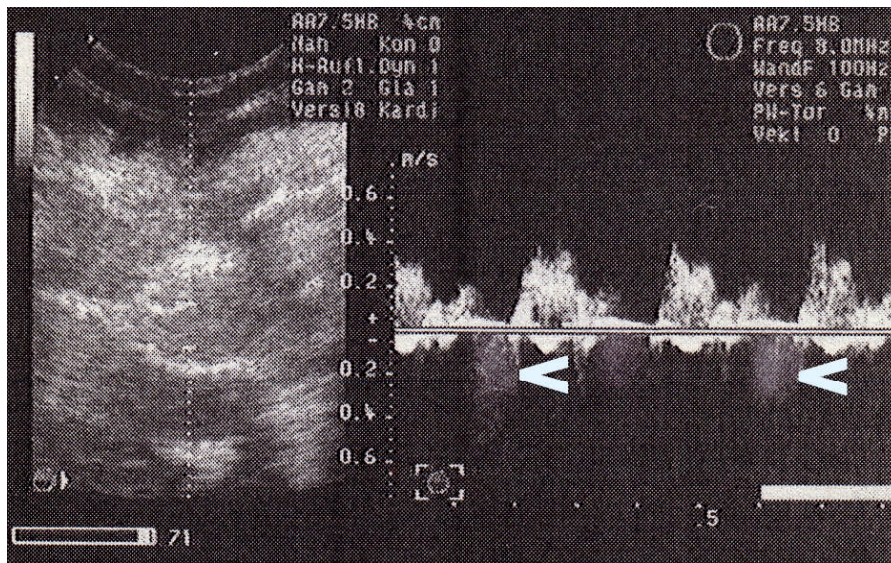


Figure 61: Doppler echocardiography indicates the regurgitation at the AV valve (open arrow) in the first examination.

Results

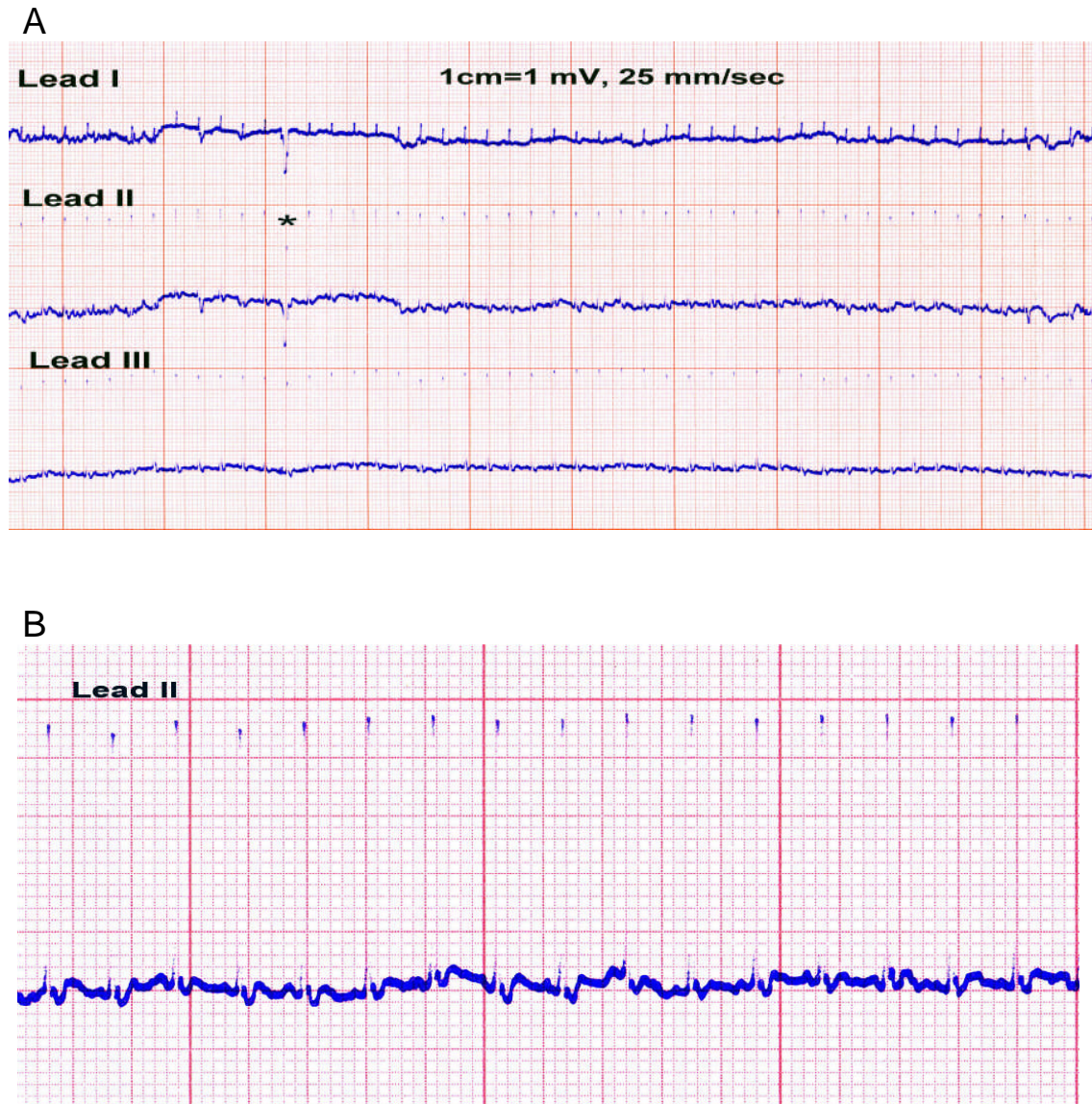


Figure 62: Electrocardiograph recorded at the 2<sup>nd</sup> visit. A, The ECG shows a normal sinus rhythm reduced to a rate of 280 bpm and interrupts by one VPC(\*) during the ambulatory examination; B, Lead II enlarged from A, the P waves show positive deflections and PQ intervals vary from 0.06-0.08 sec. (Paper speed 25 mm/sec, sensitivity 1 cm/mV)

## Results

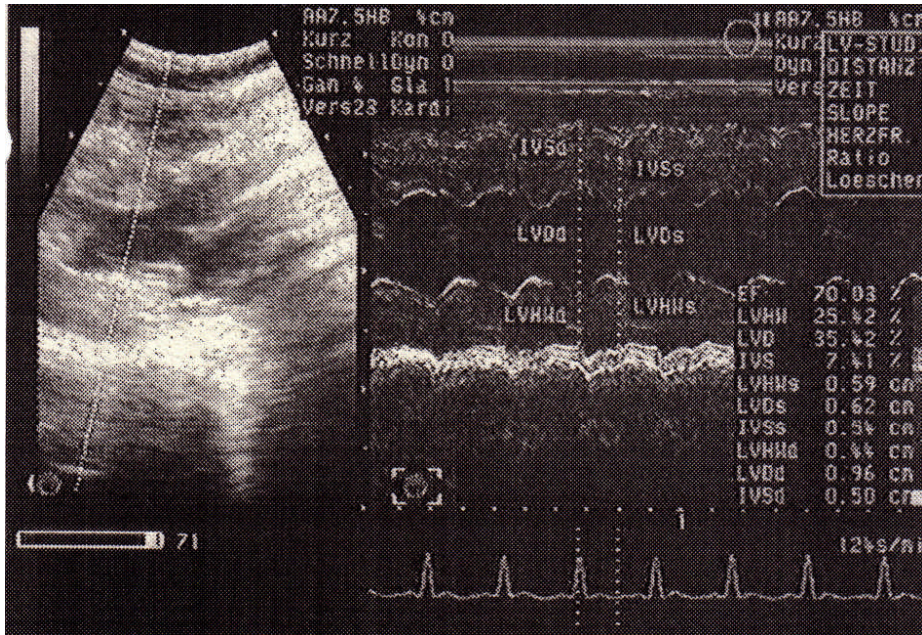


Figure 63: M-mode echocardiography recorded 2 month after the beginning of treatment. The left ventricular function has improved as the FS increases to 35.42% compared to 22.17% at the first visit.

#### 4.5.2 Case No.2 (Figure 64-71)

History:

A six year old, male ferret (Nr. s31) was presented to the Small Animal Clinic due to acute dyspnea.

Physical examination:

During the physical examination, mucous membranes were slightly pale. The capillary refill time was about 2 sec. Cardiac auscultation showed muffled heart and lung sounds.

The lateral thoracic radiograph revealed a generalized cardiomegaly (more than 3 ICS in width). The trachea was elevated dorsally. Pleural effusion was evident on the lateral radiograph. The lung lobes were compressed dorsally and had a leaflike appearance (Figure 64). Abdominal radiograph revealed evidence of ascites.

A thoracocentesis was performed initially to stabilize the patients condition before making any further examinations. It was performed with a butterfly catheter in sternal recumbency position and 30 ml of reddish fluid were withdrawn.

Electrocardiography and echocardiography were performed after the patient was breathing more comfortably. An ECG was registered at a paper speed 50 mm/sec and 0.5 mm/ mV in sensitivity. On the ECG heart rate was 230 bpm. P wave was 0.2 mV x 0.04 sec, RII 2.4 mV, QRS 0.02 sec, PQ 0.08 sec. The rhythm was irregular at a rate of 230 bpm. (Figure 65)

Two-dimensional echocardiogram revealed LV as well as LA enlargement. The mitral valve leaflets were normal (Figure 66). M-mode echocardiogram showed a LVWd of 0.02 cm, LVDd 1.5 cm, IVSd 0.02 cm, LVWs 0.03 cm, LVDs 1.1 cm, IVSs 0.03 cm and FS 26.7% (Figure 67).

Diagnosis and treatment:

Decompensated DCMP was diagnosed. The patient was treated with furosemide 1 mg/kg, BID and 0.005 mg/kg digoxin once a day. Taurine supplement was also added up into the therapy regimen. The patient clinical signs improved. A reexamination was performed 2 months after the first visit. On the lateral thoracic radiograph, the cardiac size was reduced to 3 ICS. The lung fields were normal in appearance, no pleural effusion was detected. The trachea was still elevated (Figure 68). The heart rate was 210 bpm. P wave was 0.2 mV x 0.03 sec, RII 3.2-3.4 mV, QRS 0.02 sec, PQ 0.08-0.10 sec. The rhythm showed a second degree AV block (Figure 69). In a control examination a third degree systolic heart murmur was heard and a nonselective angiocardiology performed to exclude any congenital cardiovascular lesion. (Figure 70)

## Results

The patient died 2 month later and a postmortem examination was performed. The gross pathological findings showed the LV dilatation. Right and left atria were also dilated and the atrial walls were thickened. The left ventricular wall and septum were decreased in thickness. (Figure 71)

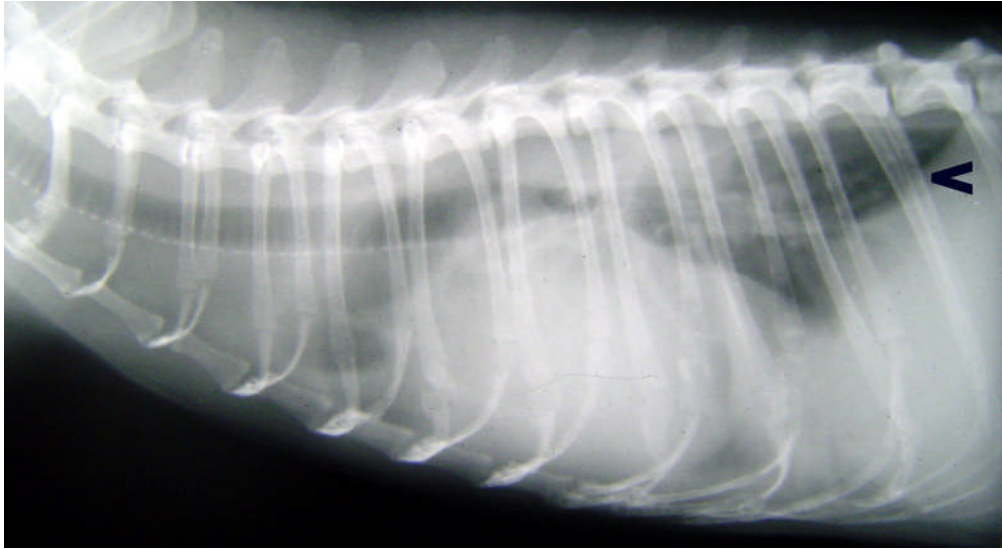


Figure 64: A six year old, male ferret is presented to the Small Animal Clinic due to acute dyspnea. The thoracic radiograph reveals cardiomegaly with evidence of pleural effusion. The lung lobes show a leaflike appearance (open arrow). The trachea is elevated dorsally.

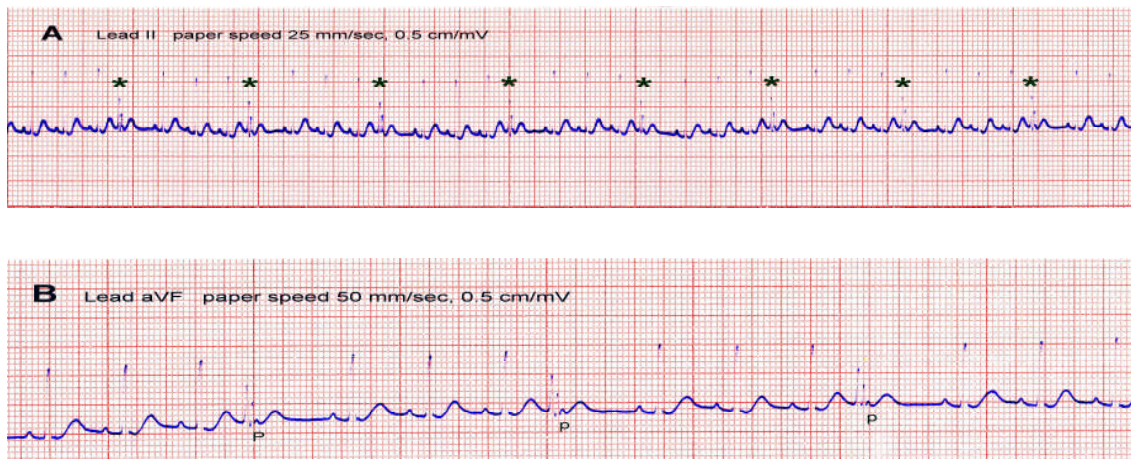


Figure 65: ECG records at the first visit. A, Lead II shows multiple ventricular premature complexes (\*) with some type of compensatory pause; B, In a short strip with 50 mm/sec paper speed the retrograde P waves (P) of the ventricular premature complexes are visible which can not be recognized at a paper speed of 25 mm/sec.



## Results

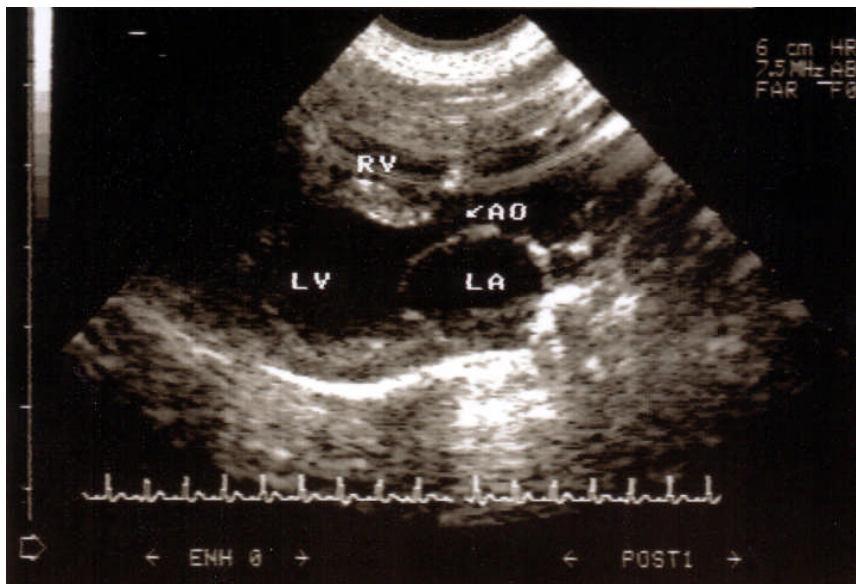


Figure 66: The right parasternal long axis with the left ventricular out flow view recorded at the first presentation. The LV chamber is dilated as well as LA. AO, aorta; LA, left atrium; LV, left ventricle; RV, right ventricle.

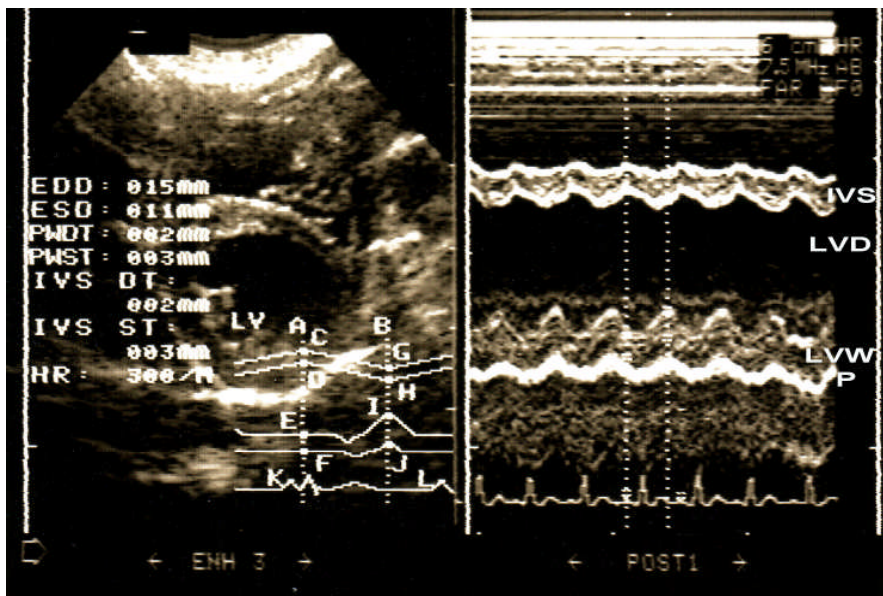


Figure 67: M-mode echocardiogram performed on the right parasternal short axis. There is massive LV enlargement. LVDd is 1.5 cm, LVWd 0.02 cm, IVSd 0.02 cm, LVWs 0.03 cm, LVDs 1.1 cm and the IVSs 0.03 cm. Fractional shortening is decreased to 26.7%.

## Results

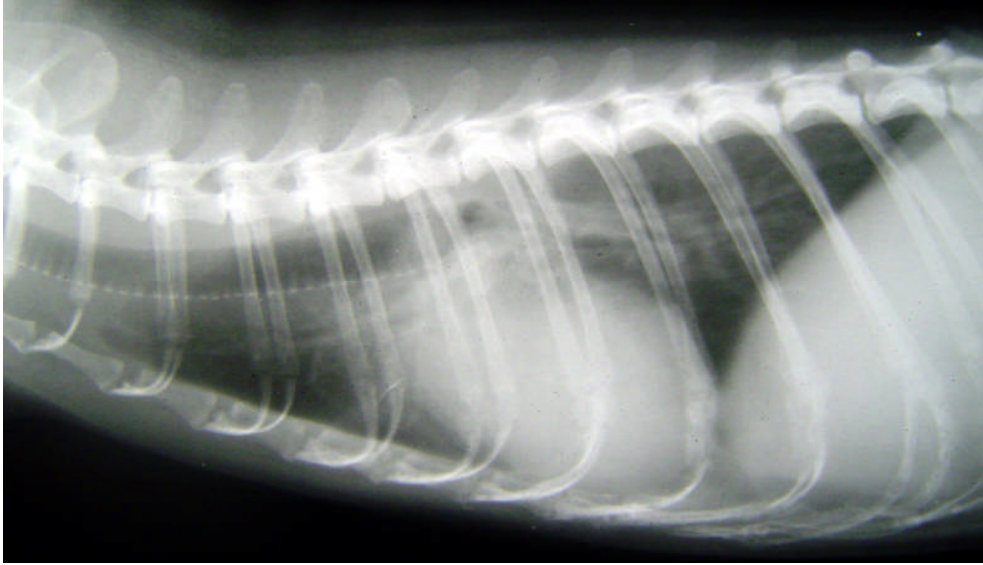


Figure 68: Thoracic radiograph performed two month after therapy. The heart is 3 ICS in width. The lung fields are almost normal in appearance compared to Figure 64.

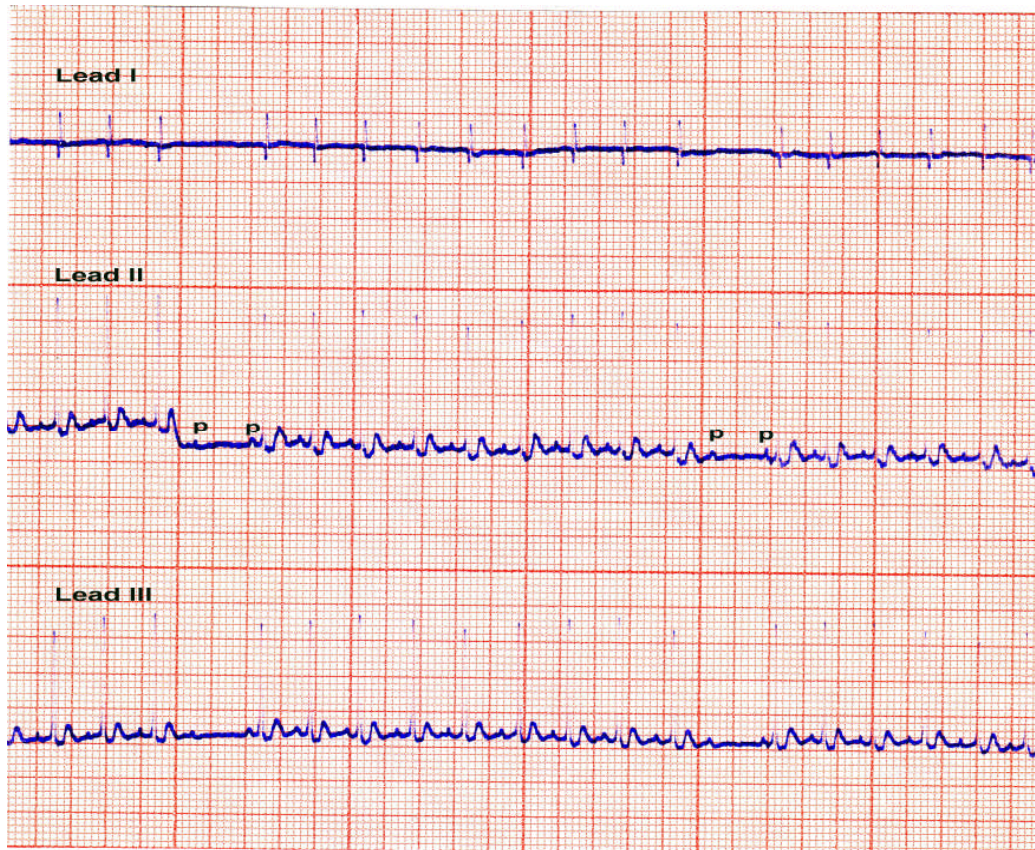
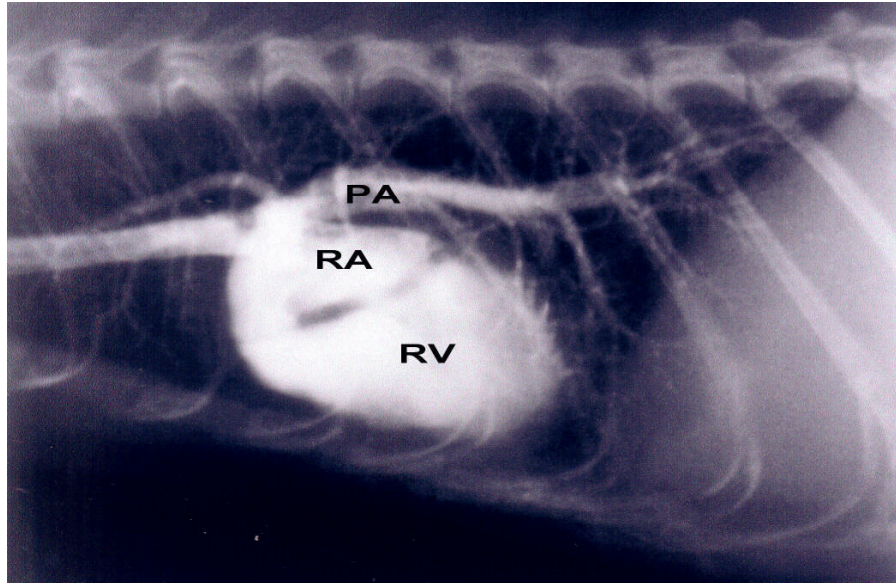


Figure 69: ECG records about two months after the start of therapy. No SVP are registered but a second degree AV block occurred. There is no prolongation of the PQ interval before the skipped beat. However the PQ interval is variable in length without any regularity. (Paper speed 25 mm/sec, sensitivity 0.5 cm/mV)

## Results

A



B

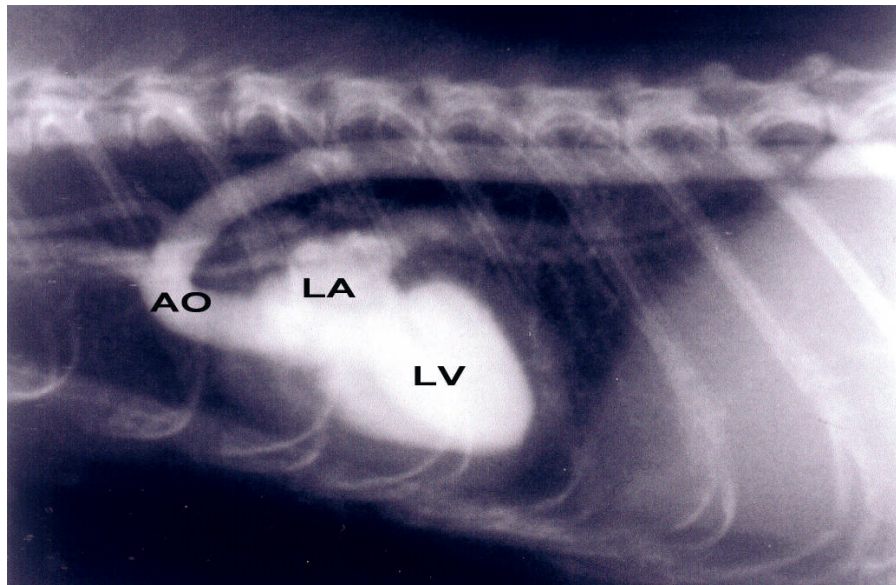


Figure 70: A, Nonselective angiocardiology through an indwelling canula in the jugular vein. The cranial vena cava, the right atrium, the right ventricle and pulmonary arteries are opacified. Note the large right ventricle. B, Presentation of the left atrium, left ventricle and aorta after lung circulation are completely circulated by the iodine salt solution about 4 seconds after injection. There is a definitive enlargement of the left atrium and left ventricle. Serial expositions for 30 seconds show only little change of the left ventricular configuration during the whole series of X-rays. AO, aorta; LA, left atrium; LV, left ventricle; PA, pulmonary artery; RA, right atrium; RV, right ventricle.

*Results*

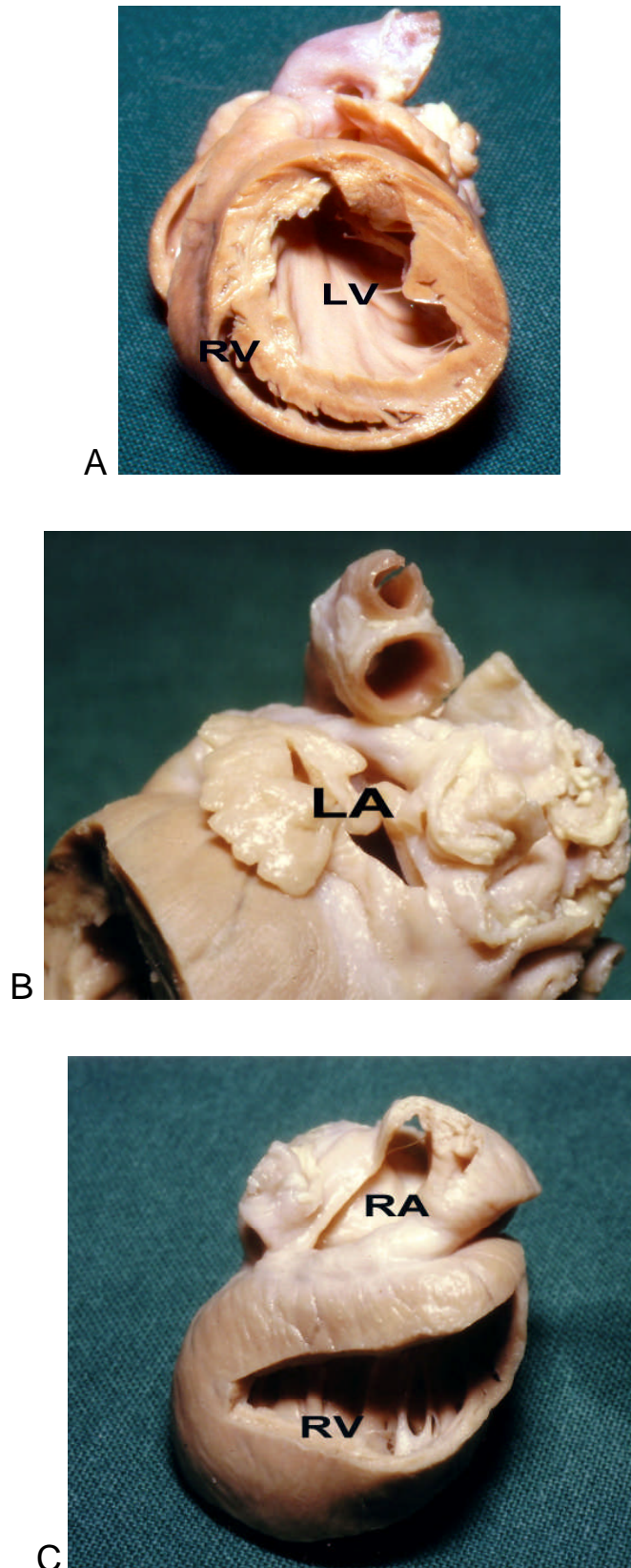


Figure 71: Postmortem cardiac specimen demonstrates general enlargement of the heart, especially the left and right atrium and the left ventricle are dilated. The interventricular septum appears thinner than normal. A; the left ventricle (LV), B; left atrium (LA), C; right atrium (RA) and right ventricle (RV).

### 4.5.3 Case No.3 (Figure72-75)

#### History:

A ten year old male ferret (Nr.10) was presented for evaluation of lethargy and coughing. Initially the patient was diagnosed to have pneumonia by a private practitioner.

#### Physical examination:

On auscultation, the heart sounds were rapid and decreased in intensity. The heart rate revealed tachycardia. Thoracic radiography showed a cardiomegaly with 3 ICS wide. The lung fields were increased in density. The trachea was elevated but no reliable signs of pleural effusion were detected (Figure 72). Electrocardiography showed a heart rate at 340 bpm, irregular rhythm with ventricular ectopic beats. The P wave was 0.3 mV, PQ interval 0.06 sec, RII 2.3 mV and QRS duration 0.02 sec (Figure 73). Two-dimensional echocardiography revealed a mitral valve thickening, left atrial enlargement and pericardial effusion (Figure 74). Pericardiocentesis was not performed because of the small amount of fluid and no signs of cardiac tamponade. M-mode showed hyperdynamic contraction of the left ventricle. The LVDd was 1.47 cm, LVWd 0.45 cm, IVSd 0.02 cm and FS 50.34% (Figure 75). Doppler echocardiography revealed a regurgitation jet over both AV valves but more severe on the left side. Hematology and blood chemistry profiles showed azotemia (BUN 178 mg/dl, normal values 10-45 mg/dl and creatinine 0.97 mg/dl, normal value 0.4-0.9 mg/dl (Brown, 1997) and an otherwise normal blood count.

#### Diagnosis and treatments:

Congestive heart failure was diagnosed. The fibrotic thickened AV valves could be the underlying cause based on echocardiographic findings. The pericardial effusion was most likely of congestive origin. The patient was treated with furosemide. The patient improved clinically but the owner did not show up for regular cardiovascular controls.

## Results

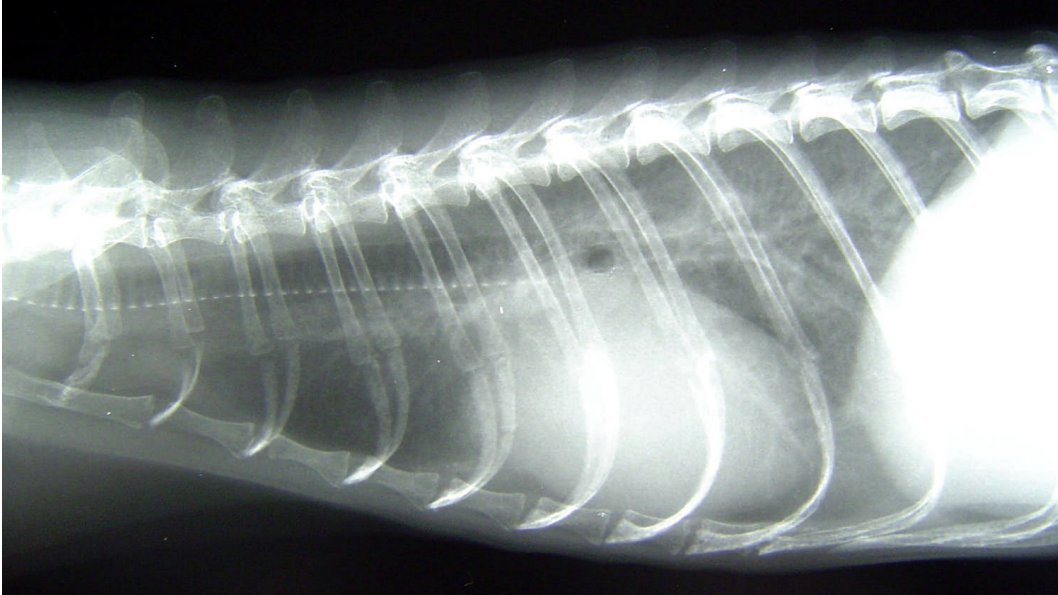


Figure 72: Ten year old male ferret. Thoracic radiograph shows cardiac enlargement. The heart is 3 ICS wide. Trachea is elevated. Especially the dorsocaudal lung field is increased in density.

Results

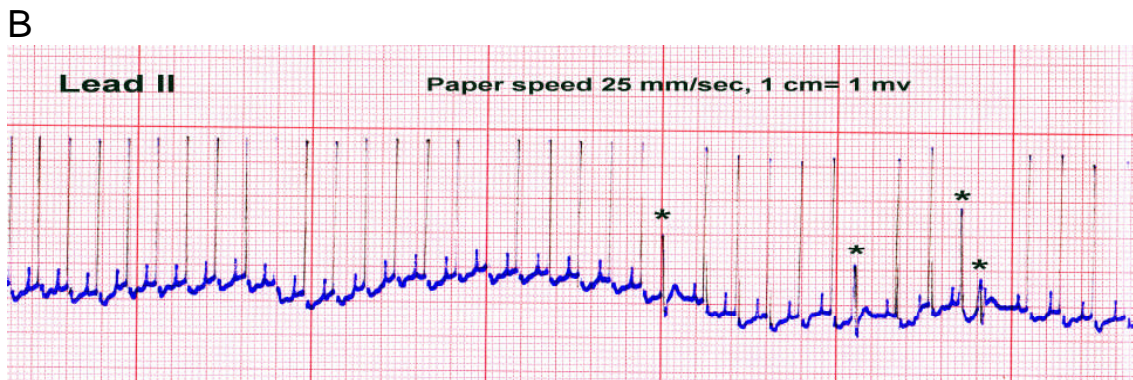
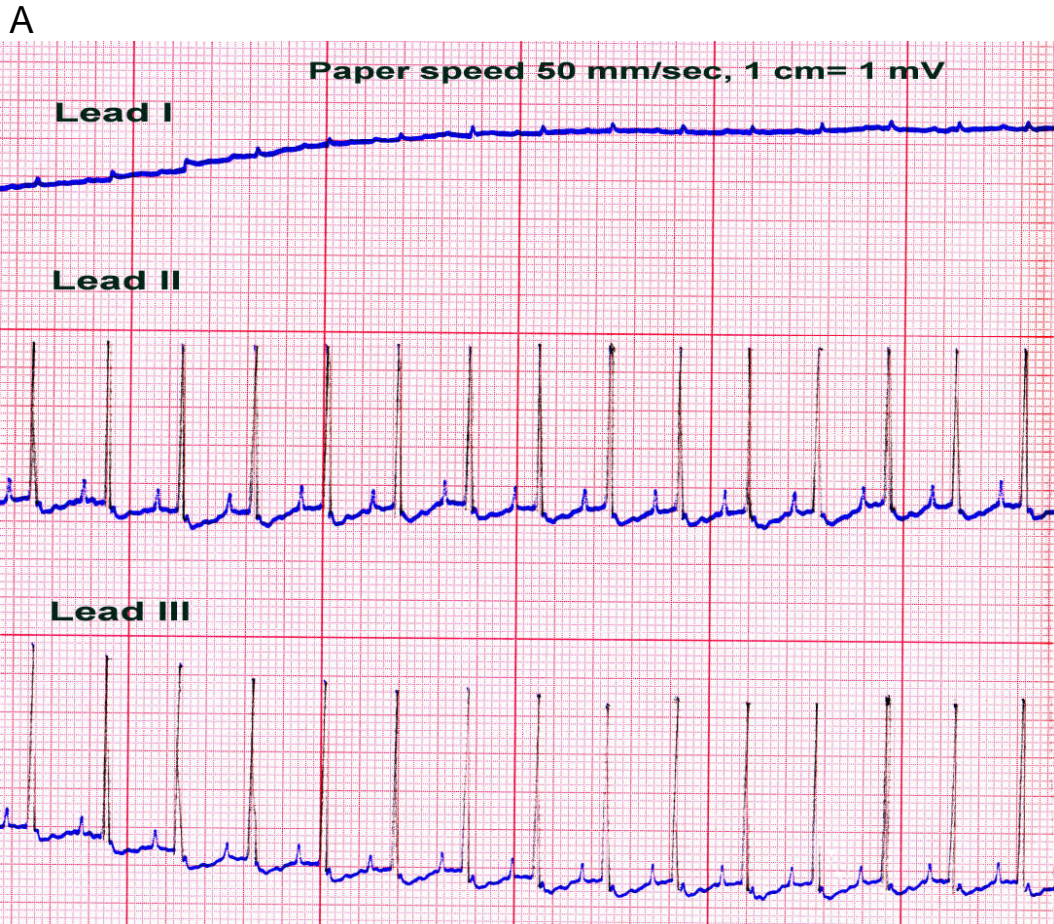


Figure 73: A, The unipolar limb leads demonstrate P pulmonale with a 0.3 mV height. PQ interval is 0.06 sec, RII 2.3 mV and QRS duration 0.02 sec. B, The SA node depolarizes at rate of 340 bpm. The normal rhythm is broken by three VPC (\*) at the last half of the tracing on the right.

## Results

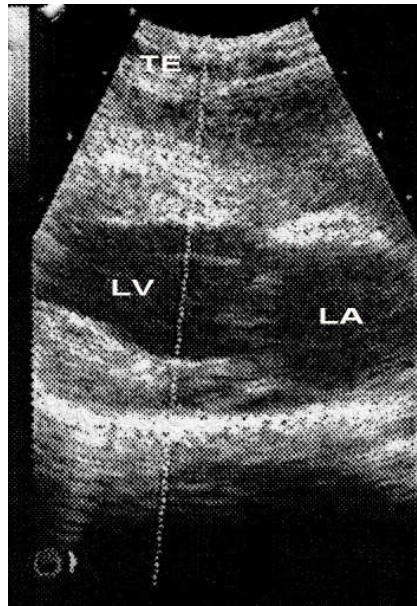


Figure 74: Two-dimensional echocardiography demonstrates left atrial enlargement and mitral valve thickening. Pleural effusion is detected (TE).

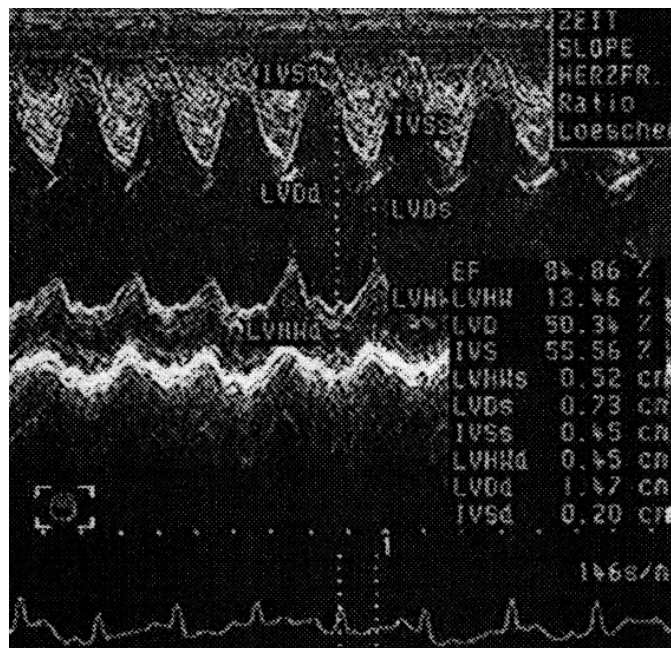


Figure 75: M-mode reveals a hyperdynamic LV wall motion. The contractility is increased due to an increase of the sympathetic tone.



## 5. Discussion

### Auscultation

All 96 animals included in this study underwent a standard auscultation. Systolic murmurs were detected mostly on the left chest wall. The murmurs were detected in 27 out of 96 animals (28.13%). More than two third (77.77%) of the murmurs had low intensity sounds that graded from one to two degrees. In detail, the first and second degree heart murmurs were detected in 29.62% and 48.15% respectively. Twenty four ferrets out of the 27 cases with systolic murmurs (92.59%) were diagnosed to have cardiomyopathy by all classical cardiovascular examination methods and confirmed by echocardiography. The other two cases with soft murmurs were clinically normal animals. Heart murmurs are common with DCMP and also relatively common with the hypertrophic form in ferrets (Hoefer, 2001B). The soft murmurs could be detected in some individuals with normal cardiovascular anatomy. These murmurs can be produced by a high velocity flow or low fluid viscosity (e.g. severe anemia) (Kvart and Haeggstroem, 2002). Murmurs also could be created in normal ferrets by holding the animals upright or by placing undue pressure on the chest with the stethoscope (Ivey and Morrisey, 1999) therefore the auscultation as well as the positioning of the animal during examination should be performed with caution. In small animals the murmurs that have a duration of more than 50% of the systole are often caused by pathological conditions such as valvular regurgitation (Kvart and Haeggstroem, 2002). The relative small size of ferrets may produce some obstacle to localize the area of the actual valve causing the murmur. Because of the small size of the thoracic cavity the localization of the valvular area may sometimes be difficult therefore it is suggested to record all murmurs in this species according to their timing in the heart cycle and their acoustic characteristics (Ivey and Morrisey, 1999). The high heart rate is another factor that makes the auscultation in this species difficult.

Auscultation in ferrets may be troublesome and time consuming owing to panting in CHF situation or other disturbing sounds from the restless ferrets. The auscultation should be carefully interpreted in CHF cases with difficult breathing because respiratory sounds could disturb the perception of cardiac murmurs.

A gallop rhythm was detected in just one case. The gallop sounds in small animals are associated with significant myocardial failure, caused by acquired or congenital heart diseases and are most common with HCMP. Hyperthyroidism or renal disease with hypertension in cats may cause secondary cardiac hypertrophy accompanied by gallop rhythms (Kvart and Haeggstroem, 2002). Since the ferrets have been reported to suffer from cardiomyopathy as well as renal disease and hyperthyroidism (Hillyer, 1994A-B; Rosenthal, 1994; Fox, 1998; Bixler and Ellis, 2004) these abnormalities should be considered in ferrets

## Discussion

with gallop rhythms. Ferrets with DCMP may present a gallop rhythm as well. (Bixler and Ellis, 2004)

The intensity of the murmurs could be graded into 2 systems, 1 to 5 scale system and 1 to 6 scale system (Detweiler and Patterson, 1967; Kittleson, 1998A). We suggested that ferrets might be more suitably to use the 1 to 5 scale system than 1 to 6 scale system. Because of the small thoracic size that reflects small heart size and no precordial thrills. No fifth grade murmurs were detected in this study because cardiomyopathy mostly produces soft murmurs unlike primary valvular lesions e.g. valvular fibrosis or congenital abnormalities.

## Electrocardiography

ECG was difficult to perform in some ferrets. That might be caused by the pressure of the electrode clip. Others suggested to flatten the clip or applying a wad of alcohol-soaked cotton between clip and skin in order to decrease the discomfort during examination (Hoefler, 2001A). Hoefler (2001A) suggested to reserve ECG examinations in the cases with an auscultable abnormalities or history of syncopal episode. Sedation can reduce artifacts during examination which made the ECG interpretation more easily and reliably (Bone et al., 1988). In our study all patients were examined electrocardiographically and repeated up to six controls.

Wave form (See Table 18, page 96)

Although the size and shape of the ferret heart and the thorax resemble more that of the feline conditions, ECG wave configuration in normal ferrets resemble more the canine pattern as far as the QRS complex is concerned (tall R waves) otherwise the P waves are small as in the cats. In general the amplitude of each wave may vary slightly depending on the individual study.

### P wave

The P amplitude in clinical normal ferrets was less than 0.2 mV in our study that agrees with the other studies published (Randolph, 1986; Fox, 1998; Hoefler, 2001A; Bublot et al., 2006). P duration in our normal groups is 0.02-0.04 sec compared to 0.01-0.03 sec from the previous reports (Randolph, 1986; Fox, 1998; Bublot et al., 2006). Eventhough the P duration reported so far are a little shorter they are in the same range. Both of the P wave abnormalities, P pulmonale and P mitrale, were noted in our study which occurs mostly associated with DCMP. In the echocardiographic examinations, most of DCMP patients showed some degree of atrial dilation which may result in a prolongation of the conduction time through the atrium or a asynchronous depolarization of the atria. The dilated left atrium depolarizes fractionally later than the right atrium which may also cause abnormal P morphology (Kittleson, 1998D; Martin, 2002). An increase in volume or pressure within both

## *Discussion*

atria may produce a P wave abnormality as well. It should be noted that the ECG should not be viewed as a mean of diagnosing cardiac enlargement in small animals and the criteria of RA or LA enlargement are also insensitive in dogs and cats (Kittleson, 1998D). Nevertheless, these enlargement criteria might also be a statement of lesser reliability in the ferret ECG.

### QRS complex

The occurrence of Q waves was very rare in lead II out of 96 ECG tracings a Q wave was detected in only three in ECGs with only -0.1 mV in amplitude. Q waves occurred most often in lead aVR and aVL in which leads QS complexes were also observed. The Q wave amplitude has been reported ranging from 0 to -0.1 mV in previous publications (Fox, 1998; Bublot et al., 2006).

The R amplitude in lead II of the normal groups ranged from 0.5 to 2.7 mV (mean 1.68 mV). The R amplitude was reported previously ranging from 1.0 to 3.0 mV in normal ferrets (Bone et al., 1988; Bublot et al., 2006). The R amplitude of 0.5 mV might be considered as the lower limit for normal ferrets based on the findings in this study. The small voltage R wave is possibly occurring in obese normal ferrets as it is found in other small animals (Ware, 1998). R amplitudes higher than 3.0 mV were found in 6 ferrets in our disease groups. Four of them were suffering from dilated cardiomyopathy. DCMP results in eccentric hypertrophy from volume overload that increases the size of the electrical wavefront traveling through the left ventricle and results in an increase of the R wave. High amplitude R waves can be found in concentric hypertrophy responding to a pressure overload as well but the ECG can not distinguish between volume and pressure overloads (Hamlin, 1968). R amplitudes greater than 6.0 mV were also reported in normal ferrets in one study (Smith and Bishop, 1985).

### PR interval

PR intervals in normal ferrets were reported in a range between 0.03 to 0.08 sec in previous publications which is in agreement with our finding (Randolph, 1986; Bone et al., 1988; Bublot et al., 2006). Since the PR interval is measured from the beginning of the P wave to the first deflection of the QRS complex which is normally the Q wave, the proper name should be PQ interval but most of the medical literatures are still using the term PR interval. In any case one should remember that the PR/PQ interval ends at the beginning of the QRS complex. PR interval may get longer or shorter than normal in pathological situations. Prolongation of the PR interval may be found in AV node and bundle branch disorders. Very short PR intervals can be created by abnormal bypass tracts between the SA and the AV node resulting in a so called WPW or preexcitation syndrome. In this syndrome specialized bypasses have been identified and are called Kent-, James- or Mahaim-bundles depending on their specific fibers and tracts.

### ST segment

In cats, the ST segment is considered as abnormal when it lies below or above the base line (Bolton, 1975). ST segment depression is an abnormal finding in our study and rarely detected in this study. It was reported as a response to several causes in dogs such as left ventricular hypertrophy, myocardial hypoxia, myocarditis, or electrolyte imbalance. ST segment elevation may be caused by myocardial hypoxia, transmural myocardial infarction, pericardial effusion and digoxin toxicity (Goodwin, 2001). ST segment elevations may also occur in normal ferrets as mentioned by Hoefler (2001A).

### QT interval

QT intervals in our normal groups remained in the same range which was reported by previous investigators (Randolph, 1986; Bone et al., 1988; Bublot et al., 2006). But the upper limit observed is a little shorter than in other reports (0.12 sec versa 0.14-0.18 sec). QT intervals may vary depending on the rate of depolarization. The variation of QT intervals in individual studies might be affected by the heart rate of the animals. It should be noted that most of the reference values were recorded from sedated/anesthetized animals that could prolong QT interval or decrease HR compared to the conscious situation. Various pathological factors could also influence the QT interval. In pathological conditions such as hypercalcemia and digitalis intoxication shortening of QT interval typically occurs. QT interval prolongation can be caused by various factors, including imbalance of electrolytes such as hypokalemia and hypocalcemia (Koyama et al., 2004).

### Heart rate (See Table 18)

Ferrets have a faster heart rate than dogs and cats. That should be produced by a high metabolic rate due to a large surface area/body weight ratio in this species (Smith and Bishop, 1985). The heart rates in normal ferrets were reported in a very wide range (Andrews et al., 1979; Andrew, 1988; Bone et al., 1988; Hillyer, 1994A; Fox, 1998; Ivey and Morrissey, 1999; Hoefler, 2001A; Bublot et al, 2006). The heart rate in our non sedated normal group is higher than in the sedated normal group (mean value 260 bpm versa 221 bpm) that is most likely caused by the anesthetic drugs. Ketamine in combination with xylazine has been reported to slow the HR in normal ferrets (Moreland and Glaser, 1985). On the other hand using ketamine alone may increase the HR in ferrets (Smith and Bishop, 1985). Hoefler (2001A) reported that during rest, ferrets which are suffering from cardiomyopathy often have a much higher heart rate (above 280) compared to normal animals. Heart rates more than 300 bpm were detected in 17/61 (27.87%) cases in the non sedated group and 3/35 (8.57%) cases in the sedated group. Among 17 cases in the non sedated group, 53% (9/17) were clinically normal animals, 35% (6/17) were identified to have DCMP. The high HR may be caused by excitation during physical examination in normal ferrets. This finding implies

## Discussion

that high HR during examination may be found in both the clinical normal as well as in the disease group and it may not be an useful value to identify patients with cardiac disease. In experimental dogs, heart rate above 200 bpm can cause myocardial failure (Wilson et al., 1987). There is no report about the correlation of high HR to myocardial failure in this species. We found that the mean HR in the disease groups shows values not different from the normal groups. It should be noted that many DCMP patients were examined under ketamine-xylazine combinations and that may decrease the mean HR in the disease groups. In DCMP, systolic dysfunction is the major effect. When cardiac output decreases, the sympathetic, hormonal and renal compensation are activated. An increasing HR in cardiomyopathy patients may be interpreted as a response to these compensatory mechanisms (Abbot, 2000; Borgarelli et al., 2001).

If we look at our extreme HR in normal groups and in disease groups, the rates in the disease groups are little lower and also remarkably higher in the minimum-maximum values. This may indicate some influence of the damaged cardiac muscle toward slower and very fast rhythms. On the other hand we feel that the most important matter is to evaluate the individual condition in each animal examined. It seems to be very informative for later evaluation to register the state of restlessness, calmness, relaxation or other major signs of incooperation during the electrocardiographic examination and take these notes into consideration for the final judgment.

Table 18: Comparative ECG parameters among individual studies. (NA, not available)

ECG parameter	Randolph, 1986	Bone et al., 1988	Bublout et al, 2006	Normal groups
Heart rate (bpm)	150-340	140-240	250-430	160-360
P amplitude (mV)	0.05-0.20	NA	≤ 0.2	0.05-0.2
P duration (sec)	0.015-0.04	NA	0.01-0.03	0.02-0.04
PR interval (sec)	0.04-0.08	0.04-0.08	0.03-0.06	0.03-0.08
Q amplitude (mV)	NA	NA	-0.5-0	-0.1-0
QRS duration (sec)	0.04-0.06	0.035-0.06	0.02-0.05	0.02-0.04
R amplitude (mV)	0.6-3.15	1.4-3.0	1-2.8	0.5-2.7
QT interval (sec)	0.10-0.18	0.08-0.14	0.06-0.16	0.08-0.12
MEA (degree)	65-100	26.6-90	75-100	-10-104.5

### Heart rhythm

Regarding normal heart rhythm reports are somewhat controversial in the literature. Normal sinus rhythm was reported in two studies (Smith and Bishop, 1985; Bublot et al., 2006) and animals with cardiac disease as well as normal ferrets may exhibit sinus rhythm (Stamoulis et al., 1997). On the other hand respiratory sinus arrhythmia was reported commonly in normal ferrets as well (Ko et al., 1998A-C; Ivey and Morrissey, 1999). Sinus rhythm was predominant in our study. Determination of cardiac rhythm is the most important reason for evaluating an ECG (Kittleson, 1998C). In veterinary medicine, arrhythmias may be classified into sinoatrial arrhythmia, ectopic arrhythmia and conduction disturbances (See Table 3). Ventricular premature complexes (VPC) are the most common arrhythmia found in this study and occurred mostly together with heart disease (DCMP). VPC were also the prevailing abnormalities found in normal ferrets sedated with various drugs (Moreland and Glaser, 1985). The VPC can originate from any part of the ventricle and the original site of the VPC can be interpreted by observing the configuration of the ectopic beat. When a VPC originates from the right ventricle the QRS wave looks identical to the LBBB pattern. Because the ectopic depolarization was fired on the right site, the force advances toward the positive poles of leads I, II, III, and aVF revealing the positive QRS complexes in these leads. On the other side if the ectopic beat originates from the left ventricle, the depolarization forces spread from the left to the right ventricle toward the negative poles of leads I, II, III and aVF. This produces negative QRS complexes like a RBBB pattern. Sometime it can be troublesome to differentiate between VPC and SVP associated with a bundle branch block. There is no definitive way of absolutely distinguishing between these abnormalities on an ECG (Kittleson, 1998D).

Atrioventricular blocks (AV block) are the second most abnormality found in arrhythmic patients in this study (30%, 9 out of 30 cases). So far conduction disturbances including second and third degree AV block were reported rarely associated with primary cardiac disease in ferrets (Stamoulis et al., 1997). Second degree AV blocks are absolute dominating and a third degree AV block is found in only one case. The third degree AV block is the most severe disturbance of conduction. The third degree AV block found in this study resembles the pattern reported in most cats with third degree AV block (Kellum and Stepien, 2006). In this study, the atrial depolarization rate was in normal range (250 bpm) but the ventricular depolarization rate was lower at 70 bpm and shows a narrow complex feature (see Figure 34). The narrow complexes in our ferret with third degree AV block look like that found in cats but in contrast to the wide QRS complexes frequently seen in canine third degree AV block (Johnson and Sisson, 1993; Kittleson, 1998C). The narrow escape complexes imply the complexes originate in the AV node or bundle of His (Johnson and Sisson, 1993). Because the escape complexes play a major role in support of the cardiac

## *Discussion*

output, medication of an antiarrhythmic drug such as calcium channel blocker or beta blocker in this situation are contraindicated. In small animal patients with second and third degree AV block associated with relevant clinical signs are definitive candidates for pacemaker implantation (Johnson and Sisson, 1993; Goodwin, 2001; Ferasin et al., 2002). A pacemaker implantation was reported recently in a 7.5 year old ferret with third degree AV block. This patient lived about 5 month after implantation and died with HF caused by extensive myocardial mineralization (Sanche-Migallon Guzman et al., 2006).

Atrial fibrillation (AF) is one of the most common arrhythmias encountered in veterinary medicine. AF is rarely detected in ferrets in this study and it is always found associated with heart diseases. In dogs, AF is the most common and clinically significant cardiac arrhythmia it is also the most commonly diagnosed electrocardiographic abnormality in canine DCMP patients (Tidholm et al., 1997). In cats, AF is reported rarely and it is only found in conjunction with severe atrial enlargement associated with underlying heart disease (Gelzer and Kraus, 2004). Because of the genesis of AF a certain atrial surface area is required to propagate thus it might be expected a common finding in patients with cardiac disease resulting from severe atrial enlargement. In human patients, the LA size is one of the most powerful predictor of AF (Olivotto et al., 2001).

Idiopathic AF or lone AF (AF in absence of underlying heart disease or clinical signs secondary to heart disease) was reported in some dogs (Vollmar, 2000; Takemura et al., 2002) but it has not been reported in cats (Gelzer and Kraus, 2004) and in ferrets. We also do not have detected AF in the normal groups of this study. AF in ferrets could sometimes be difficult to diagnose due to the rapid atrial activation and the small voltage of fibrillation waves. Baseline noise or artifacts in an ECG can stimulate wave forms like these as well (Gelzer and Kraus, 2004). For the easier recognition of f waves it might be better to set the calibration always at 1 cm/mV. The RR interval are almost always irregular during AF but in high HR it may look regular on a quick visual inspection. Thus the paper speed at 50 mm/sec and using a caliper might help to prove an irregularity.

### Mean electrical axis

The frontal vector in clinical textbooks is also called mean electrical axis (MEA). MEA in normal ferrets has been described in previous reports in which ranges from 26.6 to 100 degree (Smith and Bishop, 1985; Bone et al., 1988; Hofer, 2001A; Bublot et al., 2006). MEA in normal ferrets (n=25) in our study showed the value range from -10 to 104.5 degree. Most animals (21/25, 84%) of the normal groups have a MEA angle during 30 to 100 degree that agrees with other reports (Smith and Bishop, 1985; Bone et al., 1988; Hofer, 2001A; Bublot et al., 2006). Three out of 25 ferrets in the normal groups (12%) have a MEA angle less than 30 degree (-10, 11.5 and 23 degree respectively) and only one case (4%) has an

angle more than 100 degrees (104.5 degree) (see Figure 37). Malpositioning of the limbs in relationship to the body were reported to cause a dramatic ECG distortion and consequently abnormal MEA angle. Bond (2005) reported that the feline MEA can be different from 90 degree in a proper positioning ECG to -150 degree when the limbs are not properly positioned perpendicular to the spine (Bond, 2005). Since ferrets have shorter legs than cats lesser malpositioning could explain some of the divergent frontal vectors at the lower and upper angles.

The MEA or frontal vector can be calculated in several different ways and each method may give little different results and it should be kept in mind that none are more accurate. It is of no value to try to determine the MEA down to the exact degree. Instead, calculation within 20 to 30 degrees difference should be sufficient (Kittleson, 1998D).

## Radiography

A total of 74 (43/31) thoracic radiographs were evaluated for this study. Thirty one of these were collected from the dyspnic patients. Radiographs are considered as one of the most important diagnostic techniques used in ferret heart disease. It is sometimes difficult to get a good quality thoracic radiograph and therefore a few animals need sedation (Rosenthal, 1997; Stefanacci and Hoefer, 1997). The quality of the radiographic picture such as positioning and exposure should always be evaluated before attempting to interpret the thoracic radiograph. Some criteria were proposed for evaluating the quality of the films (Wyburn and Lawson, 1967; Schelling, 2001):

1. The entire bony thorax should be included on the plate.
2. The forelimbs should be pulled forward and the scapula should be excluded from the lung fields.
3. The outline of the heart should be clear and sharp and the aorta and the posterior vena cava clearly visible on the lateral view.
4. The outline of the dome of the diaphragm should be clear and sharply defined.
5. The vascular markings of the lungs are visible from hilus to periphery.
6. The ribs should show good bony detail.
7. On the lateral view, dorsal heads of ribs should be superimposed on each other.
8. On the DV view, the dorsal spine processes of the thoracic vertebrae should be centered over the vertebral bodies along the full length of the thoracic spine. The thoracic sternbra also should be imposed under the thoracic spine and be essentially indistinguishable radiographically.



## Discussion

In canine patients, the phase of respiration may affect the size of the thoracic cavity and, consequently, the determination of the heart size. In an inspiration film, the heart appears smaller than it does during expiration. Conversely, during expiration the heart appears larger than it does during inspiration. These differences appear to both lateral and dorsoventral projection (Farrow, 2000). Ideally, the thoracic radiography should be performed during an inspiration. (Figure 76)

The body position may also affect the cardiac size. In general, the heart appears longer and narrower when projected ventrodorsally than projected dorsoventrally (Figure 75). This difference results in large part from the caudal displacement of the cardiac apex, owing to its relatively weak moorings compared to that of its base. For the same reason, the heart often tips to the right or left of midline, in the same instances markedly altering its silhouette. Overall, the DV projection more accurately portrays the cardiac anatomy than does the VD view (Farrow, 2000). Although these statements may play a major role in canine and feline radiographic examinations they might be of less importance in the ferret because of the somewhat different anatomy with a long and narrow thorax. However considering the high heart rates the cardiac silhouette may vary only very little.

In ferrets, the thoracic morphology on the radiographs showed a long appearance cranially narrow at the thoracic inlet getting wider caudally. The ferrets thoracic cavity is fairly consistent in morphology similar to the feline thorax which has also less variation compared to the dogs (van den Broek and Darke, 1987; Brown, 1997; Kittleson, 1998B). On the lateral radiographs the trachea is looking longer than in dogs and cats and the bronchi are relatively wide. As also observed by Smith and Bishop (1985) the heart in the ferret is positioned more caudally between the 6<sup>th</sup> and 8<sup>th</sup> ribs. Therefore it is not only a impression but a fact: the trachea is a little longer than in other species. In healthy dogs with normal thoracic configuration, the angle between the trachea and spine is around 30 degree (Kittleson, 1998B). A distal trachea displaced upward toward the spine suggests a large heart or moderate to severe left atrial and ventricular enlargement (Lord and Suter, 1999). In ferrets the tracheal angle is different from that reported in dogs. In normal ferrets 17 out of 18 animals exhibited a tracheal angle almost parallel to the spine. That means the trachea was either completely parallel to the vertebral column or forming an angle of less than ten degrees. That might be caused by the long narrow thoracic cavity in this species.

The heart apex looks more rounded than in dogs and cats and the heart is sometimes elevated above the sternum. The floated heart has been reported previously and considered a normal variation in healthy ferrets (Rosenthal, 2001). A heart silhouette directly in contact with the sternum may suggest an early sign of cardiac enlargement in ferrets (Brown, 1997). We found both elevated hearts and hearts in contact with the sternum in normal ferrets. However we recognized most of the elevated ferret hearts (8 out of 9 cases) were suffering

## Discussion

from cardiac disease (mostly DCMP). Ivey and Morrisey stated in 1999 that ferrets experience a seasonal weight fluctuation. The body weight might gain up to 40% of their initial body weight in fall, and will then lose in the following spring. Many ferrets in this study showed an evidence of fat accumulation around the region of the heart apex and the phrenicopericardial ligament. Some cases revealed also an accumulation of fat within the thoracic wall. A more horizontal cardiac position was found often in older cats (10 -17 years of age) without clinical signs of heart disease and is suggested to be a normal variation in geriatric cats (Moon et al., 1993). This characteristic was not found in our older ferrets.

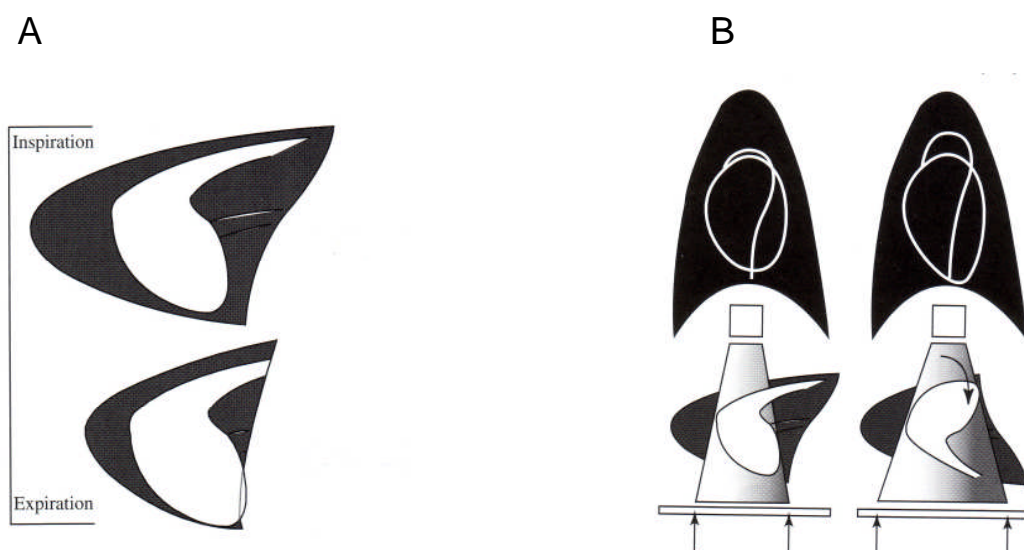


Figure 76: Figures show the effect of respiratory phase and body position to the cardiac silhouette. A, during inspiration the thoracic cavity is expanded and made the cardiac silhouette relative smaller compared to the thoracic cavity. On the other hand, the heart appeared relative large compared to the thoracic cavity during expiration. B, the heart appears longer and narrower when projected ventrodorsally than when projected dorsoventrally. (Modified from Farrow, 2000)

### Interpretation of the heart size

In the normal groups, the mean VHS on the right lateral view was 5.57 compared to 5.33 in a previous publication (Stepien et al., 1999). We decided to use the modified VHS system because the vertebral column in ferrets are shorter than in dogs therefore the measurement of the vertebral column to the nearest 0.1 vertebra may be difficult to estimate. The VHS on the DV view are always bigger than the lateral view. In obese cats, the average short axis on the VD view was reported increasing which was attributed to the fat indistinguishable from the myocardium (Litster and Buchanan, 2000). Because of this finding the heart silhouette in ferrets with gained weight should be interpreted with caution. We found the VHS in the normal and the disease groups have the same median value (5.75) and it may not be a valuable method to differentiate the normal groups from the disease groups. The VHS was

## *Discussion*

more than or equal to 6.0 found in six cases of 17 clinically normal ferrets (32.29%). It should be noted that ferrets may have a seasonal weight fluctuation as mentioned previously. The fat deposit may be responsible to the high VHS value in some normal ferrets. A remarkably deposition of fat may be troublesome for radiographic interpretations in any case. In obese cats, the cranial border of the cardiac silhouette may be obscured on the lateral projection (Farrow, 1994). Fat deposits around the phrenicopericardial ligament could also obscure the heart silhouette and make the interpretation of VHS more difficult. In order to maximize radiographic contrast between the heart and surrounding fat one author suggested to use a relative low kVp radiographical technique (Lamb, 2000). In contrast to the modified VHS method, traditional ICS system proved to be a more useful method to differentiate normal from the abnormal. In the normal groups the mean ICS value was 2.28 compared to 2.70 ICS in the disease groups. The heart/thorax ratio does not allow to identify the diseased heart from the normal heart as well. The median values of both groups are the same. One should note that radiography is not an ideal tool for evaluating patients with cardiovascular disease and it may also be an inaccurate tool for determining overall cardiac size at least in cases with milder changes of the cardiac silhouette (Kittleson, 1998B). Changes in cardiac contour can exist without cardiac enlargement. For example, cardiac concentric hypertrophy, which typically develops secondary to pressure overload, may develop at the expense of cardiac chamber volume, and the size of the heart may appear normal radiographically (Buchanan and Patterson, 1965). Therefore radiography should be used as an additional tool with other examination methods and as far as heart failure is concerned a possible congestion of the lung should always be taken into consideration.

## **Echocardiography**

A complete echocardiography was performed in 45 ferrets. In general, echocardiographic techniques resemble that used in other small animals and for a complete and accurate echocardiographic examination required a reasonable immobilization of the subject (Gaber, 1991). The most abnormalities that were detected by echocardiography were DCMP (57.78%, 26/45) and HCMP (6.67%, 3/45). Pericardial effusion and AV lesion found in one of each case (2.22%).

### Two-dimensional mode echocardiography

The cardiac anatomy found in 2-D mode echocardiography resemble that found in other small animals. The LA in ferrets may be a little bigger than aortic root which is also the case in cats. Unlike in cats, dogs have the same size of LA and AO diameter when interpreted subjectively. The dominant abnormality found in our study was LA enlargement. This was found mostly in ferrets suffering from DCMP. The measurement of the LA/AO ratio may be controversial in one single ice peaked picture of the echocardiogram because the aortic root and LA are not located at the same anatomical level, when the two dimensional echo reveals a clear LA image the aortic root does look less clear (O'Leary et al., 2003). This limitations reported in dogs (Nakayama et al., 2001) might be a limitation in ferrets as well. The LA/AO can be assessed in variable echocardiographic planes and shows little variation depending on the echo view (Rishniw and Erb, 2000; Abbott and MacLean, 2006). Eventhough some limitations were recognized, the LA/AO ratio is still a useful method to detect a relative left atrial enlargement which was found in dogs with chronic, acquired mitral regurgitation and DCMP (Muzzi et al., 2006) and in ferrets it was always detected in association with DCMP. In dogs, the body weight does not have an effect on the LA/AO ratio (Lombard, 1984). In contrast the body weight showed a strong association of LV dimensions as well as the aortic diameter (Rishniw and Erb, 2000). We did not evaluate the effect of body weight to LA/AO because of the little variation in size and body weight. Thickening of the mitral valve is well documented by using two-dimensional echocardiography and we only found it in one patient. Thickening of the mitral valves were found mostly in canine degenerative mitral valve disease which show small nodules on the free edge of the valves or the valves may bulge in the LA causing a mitral valve prolapse (Ware, 1998; Haeggstroem et al., 2004). Mitral valve thickening is also found in other disease such as endocarditis. Although the most frequent cardiovascular disease found in ferrets is DCMP, valvular disease has also been documented in increasing frequency (Hillyer, 1994A; Stamoulis et al., 1997, Bixler and Ellis, 2004).

### M-mode echocardiography

The LV, LA, AO, LA/AO as well as systolic function (FS) were evaluated. Most of the M-mode echocardiographic findings in our study approach the values reported by previous investigators except LA and AO (See Table 19) (Stamoulis et al., 1997; Stepien et al., 2000; Vastenburg et al., 2004). In dogs, the size of LA and AO were influenced by body weight as previously mentioned. Therefore the difference of LA and AO size in our patients compared to Vastenburg et al 2004 is possibly caused by the variation of a body weight. Anyway LA/AO is still in the same range compared to other studies. It might be more valuable to detect LA enlargement compared to the AO value. In our study, 3 cases with HCMP had a FS up to 52.07%. FS values were reported in a wider range depending on the different

## Discussion

studies. The three conditions affecting the fractional shortening are preload, afterload and contractility. Each one of these may act individually or together to affect the FS (Boon, 1998; O’Leary et al., 2003). In dogs, FS was also influenced by echocardiographic plane. O’Grady and O’ Sullivan (2004) found that the FS determined from the right parasternal short axis view is greater than FS determined from a long axis view. Following this statement it suggests to measure the FS by always using the same 2-D mode plane each time of examination. DCMP is reported the most common cardiac disease found in ferrets (Ensley and van Winkle, 1982; Greenlee and Stephens, 1984; Lipman et al., 1987; Rosenthal, 2001) and the diagnosis in small animals is usually based on echocardiographic findings such as a dilated left cardiac chamber, relatively thin walls and systolic dysfunction (Richardson et al., 1996; Calvert et al., 1997; McEwan, 2000; Tidholm et al., 2001; Vollmar et al., 2003). In our disease groups, the left ventricular dimension in both systolic and diastolic period is bigger than in normal groups. The IVS was recognized thinner than in the normal groups but the left ventricular free wall was still in the normal range value. The LA/AO was bigger compared to the normal group. Based on these findings the LVD, IVS and LA/AO are useful parameters to differentiate ferrets who are suffering from DCMP from ferrets with normal cardiac function.

Table 19: Comparative mean value of the selected echocardiographic parameters in clinical normal ferrets. (NA, not available)

Parameter	Stamoulis et al., 1997	Stepien et al., 2000	Vastenburger et al., 2004	Normal groups
LVDd (cm)	1.10	0.88	0.98	1.04
LVDs (cm)	0.64	0.59	0.69	0.60
IVSd (cm)	NA	0.36	0.34	0.35
IVSs (cm)	NA	0.48	0.44	0.49
LVWd (cm)	0.33	0.42	0.27	0.36
LVWs (cm)	NA	0.58	0.38	0.49
FS (%)	42.0	33	29.5	42.5
LA (cm)	NA	0.71	0.58	0.74
AO (cm)	NA	0.53	0.44	0.56
LA/AO	NA	1.33	1.30	1.32

Doppler echocardiography

Regurgitations across the AV valves were the predominant abnormality in our study. Most of these regurgitations were found at the mitral valve area in DCMP patients. In small animal cardiology, mitral insufficiency is a very common acquired condition found in degenerative valve disease, DCMP, HCMP, endocarditis and congenital malformations (Boswood and Lamb, 2005). In ferrets, DCMP was reported a common cardiac disease compared to other heart abnormalities. DCMP produces mitral regurgitation because the valves fail to close completely during systolic period. This incomplete closure of the valves also reported in humans are caused by dilation of the atrioventricular annulus and papillary muscle displacement due to LV enlargement in DCMP patients (Kono et al., 1991; Kono et al., 1992). Mild regurgitations were also recorded at the AV valves and semilunar valves in our study. Mild regurgitation at the AV valves might be caused by a non severe stage of cardiomyopathy or viewed as a physiological condition. Physiologic valve regurgitation (PVR) have also been reported in other small animals. It occurs when a small amount of blood is pushed back across the valve during normal valve closure. In normal cats, PVR of the tricuspid valve was found most commonly (Adin and McCloy, 2005). In contrast to the cats, a physiologic pulmonary regurgitation was detected mostly in normal canine patients but no physiologic tricuspid regurgitation could be demonstrated by Nakayama et al., 1994. Normal pulmonic and aortic velocities were rarely reported in ferrets. We found the pulmonic flow velocity between 0.5 to 1.15 m/sec and the aortic flow velocity between 0.6 to 1.0 m/sec. The only other study by Stepien (2000) measured similar pulmonic and aortic velocity with a tendency to slightly higher Vmax in the PA (0.78 to 1.38 m/sec of the pulmonic flow and 0.58 to 1.34 m/sec of the aortic flow). In ferrets, the aortic velocity seems to be lower than pulmonic velocity. Possibly caused by the anatomical position of the heart in ferrets. In ferrets, a good alignment with the aortic outflow tract from the left apical position was occasionally difficult to accomplish and that may cause an underestimation of aortic blood flow. The aortic peak velocities may have been underestimated by more than 6% when the flow intercept angle was more than 20 degree. The use of other views may reduce the level of suboptimal flow angles and may produce a more correct maximal blood flow (Vmax) in the ferret aorta (Stepien et al., 2000). Nevertheless the blood flow in both large vessels is very close to one another and the small differences in velocity measurements may have more technical than biological reasons.

## 6. Zusammenfassung

### Kardiologische Untersuchungen an gesunden und herzkranken

#### Frettchen

Sechshundneunzig Frettchen wurden in eine kardiovaskuläre Untersuchungsstudie aufgenommen. Zusätzlich konnten 31 Frettchen mit Dyspnoe, die im Notdienst vorgestellt wurden, vornehmlich klinisch und roentgenologisch beurteilt werden, die ganz überwiegend keiner kompletten kardiologischen Untersuchung unterzogen werden konnten. Die Patienten der kardiovaskulären Studie wurden in vier Untergruppen je nach klinischen Ergebnissen und Notwendigkeit zur Sedation eingeteilt. Die Gruppe A umfasst die nicht sedierten normalen Tiere (NSN Gruppe). Die Gruppe B enthält alle nicht sedierten herzkranken Tiere (NSD Gruppe). Während die Gruppe C die sedierten herzgesunden/normalen (SN Gruppe) und Gruppe D die sedierten herzkranken (SD Gruppe) Tiere enthält. Zur Anaesthetisierung bzw. Sedation wurde Ketamin/Xylazin in niedrigen Dosen eingesetzt. Herzgeräusche wurden hauptsächlich an der linken Brustwand festgestellt und waren überwiegend von geringer Intensität (Grad 1/5 oder 2/5). Die normalen durchschnittlichen EKG-Werte (Abl. II) sind Amplituden: P: 0,08; R: 1,68 mV; und Zeitwerte P: 0,02 sec; PQ: 0,05 sec; QRS: 0,03 sec und QT: 0,10 sec. S und Q Zacken sind bei herzgesunden Frettchen kaum vorhanden. Die T-Wellen können sowohl positiv als auch negativ sein wobei die positiven T-Wellen mit einer durchschnittlichen Amplitude von 0,15 mV überwiegen. Die Herzschlagfrequenz bei herzgesunden Tieren ohne Sedation variierte zwischen 190 bis zu 360 Schlägen/min. Ventrikuläre Extrasystolen dominieren bei den registrierten Arrhythmien. Im übrigen konnten darüberhinaus Bradykardien, Tachykardien, supraventrikuläre Extrasystolen, Vorhofflimmern, atrioventrikuläre Blockierungen und Erregungsausbreitungs-Störungen wie Rechtbündelblock und Linksbündelblock aufgezeichnet werden. Herzgesunde Frettchen haben einen EKG Frontalvektor zwischen 30 und 100 Grad (84%). Bei herzkranken Frettchen liegt der Frontalvektor zwischen 43,5 und 125 Grad. Die brauchbarste Methode zur roentgenologischen Unterscheidung zwischen herzgesunden und herzkranken Tieren war die Bestimmung der Mittelwerte mit dem intercostalen Score System (ICS). Die Mittelwerte liegen bei gesunden bei 2,28 und bei herzkranken bei 2,70 ICS. Ein modifiziertes System zur Bestimmung der Vertebral-Herz Summe (VHS) erwies sich als wenig geeignet normale von krankhaft veränderten Herzsilhouetten zu unterscheiden: VHS norm 5,57 zu VHS krank: 5,79. Das mittlere Herz/Thorax Verhältnis (Herzhöhe/Thoraxhöhe, Kealy 1991) beträgt zwischen den beiden Gruppen 0,55 (normal) zu 0,54 (krank), obwohl eine globoide Herzsilhouette auch bei gesunden Tieren beobachtet werden konnte, überwiegt diese Form des Herzschattens bei den herzkranken Tieren. Als eine Besonderheit kann bei Thorax aufnahmen von Frettchen gelten, dass die Herzsilhouette häufiger keinen Kontakt

## Zusammenfassung

mit dem Sternum (9 von 43 Roentgenaufnahmen) hat. Ebenso ist die deutliche Darstellung des Ligamentum phrenicopericardiacum infolge des fehlenden Sternalkontaktes und moeglicher Fetteinlagerung eine frettchenspezifische Roentgenbeobachtung. Im zweidimensionalen Echokardiogramm aehneln die wesentlichen Befunde denjenigen bei anderen kleinen Haustieren. Bei den herzkranken Tieren war eine Vergroesserung des linken Ventrikels, des linken Atriums sowie die verminderte Kontraktitaet des linken Ventrikels der haeufigste pathologische Echokardiographiefund. Diese echokardiographischen Befunde wurden hauptsaechlich bei Tieren mit einer dilatativen Kardiomyopathie erhoben. Bei den gesunden Frettchen wurden folgende Durchschnittswerte im eindimensionalen (M-mode) Echokardiogramm ermittelt: LVDd 1,04 cm, IVSd 0,35 cm, LVWd 0,36 cm, LVDs 0,60 cm, IVSs und LVWs waren mit 0,47 cm gleich dick. Die Verkuerzungsfraktion (FS) als Mass der Kontraktionsfaehigkeit ist bei herzgesunden Tieren mit 42,48% deutlich hoeher als bei herzkranken Tieren mit 30,42%. Das mittlere Verhaeltnis zwischen linksatrialem und aortalem Durchmesser (LA/AO) betraegt bei den gesunden Frettchen 1,32. Bei den herzkranken Tieren, die ueberwiegend an einer dilatativen Kardiomyopathie leiden liegt der LA/AO Verhaeltniswert bei 1,41. In den dopplerechokardiographischen Untersuchungen dominieren deutliche atriale Regurgitationen via Mitralklappe. Geringere (klappennahe) Regurgitationen konnten auch an anderen Klappen beobachtet werden. Die Flussgeschwindigkeiten konnten verlaesslich bei neun gesunden Tieren an der Pulmonalarterie mit 0,5 bis 1,15 m/sec und bei vierzehn Tieren an der Aorta mit 0,6 bis 1,0 m/sec bestimmt werden. Einige klinische Faelle mit typischen roentgenologischen elektrokardiographischen echokardiographischen und morphologischen Befunden sind beschrieben.



## 7. Summary

### Cardiologic examination in ferrets with and without heart disease

Ninety six ferrets have been enrolled in a cardiovascular study. Thirty one additional cases with dyspnea were collected from the emergency unit but underwent no standard cardiologic examination. The patients were classified into 4 subgroups due to the results of clinical examination and anesthetic status: Group A (non sedated-normal group, NSN group), Group B (non sedated-disease group, NSD group), Group C (sedated-normal group, SN group) and Group D (sedated-disease group, SD group). A low dose ketamine and xylazine was used to anesthetize the animals. Auscultation was performed in all animals. Heart murmurs were found mostly on the left side of the thorax and more than half of the murmurs had a low intensity graded from 1 to 2 from a 5 grade scale. The normal ECG mean values were: P amplitude of 0.08 mV; P duration of 0.02 sec. R amplitude was 1.68 mV. QRS duration was 0.03 sec. S and Q waves in lead II were found rarely in normal ferrets. T waves were found as positive and negative deflections but mostly were positive in lead II with a mean amplitude of 0.15 mV. The mean value for the PQ interval and QT interval was 0.05 sec and 0.10 sec respectively. Heart rate ranged between 190 to 360 bpm in normal animals without sedation. Ventricular premature complexes were the predominant arrhythmia found in this study. Many types of arrhythmias were also detected such as bradycardia, tachycardia, supraventricular premature complexes, atrial fibrillation, atrioventricular block, and excitation spread disturbances such as right bundle branch block and left bundle branch block. In 84% of the normal population the mean electrical vector ranged from 30 to 100 degree. In ferrets with heart disease the mean electrical vector ranged from 43.5 to 125 degrees. The most useful radiographic method to differentiate the cardiac silhouette between the normal and the disease groups is the intercostal score (ICS) system. In the normal groups, the mean values were 2.28 ICS compared to 2.70 ICS in the disease groups. We found that the modified vertebral heart sum (VHS) as well as heart/thoracic ratio have less ability to differentiate normal from abnormal in the cardiac silhouette. The mean modified VHS score of the normal groups was 5.57 compared to 5.79 in the disease groups. The mean heart/thoracic ratio in the normal groups was 0.55 and 0.54 in the disease groups. A globoid cardiac shape was found in both groups (normal/disease) but it was found mostly in ferrets suffering from heart disease. Cardiac silhouette without sternal contact are a special finding in ferrets and occurred in both groups. More than fifty percent of cardiac silhouettes showed some evidence of fat in the phrenicopericardial ligament area. In normal 2-D echocardiography the features resembled the findings in small animals. In the disease groups, the most frequent abnormalities were an enlargement of the

### *Summary*

LV and LA as well as a hypocontractility of the left ventricle. These features were found mostly in patients with DCMP. M-mode echocardiography in the normal groups showed a mean of LVDd 1.04 cm, IVSd 0.35 cm, LVWd 0.36 cm, LVDs 0.60 cm. IVSs and LVWs were equal in thickness at 0.47 cm. The mean value of the fractional shortening (FS) in normal groups was a 42.48% which is remarkable higher than in the disease groups (FS=30.42%). The mean LA/AO ratio was 1.32 in the normal groups. In the disease groups (mostly suffering from DCMP) showed a mean LA/AO at 1.41. In the Doppler examination, a mitral regurgitation was most often recorded. Some regurgitation jets could be detected on the other valves as well. The pulmonic and aortic velocities were recorded in nine and fourteen cases respectively in which the pulmonic flow velocity (n=9) was detected at a range from 0.5 to 1.15 m/sec and the aortic flow velocity (n=14) ranged from 0.6 to 1 m/sec. Clinical cases with typical radiographic, electrocardiographic, echocardiographic and morphologic findings are described.

## 8. References

Abbot, J.A. (2000):

Canine dilated cardiomyopathy.

In: Abbott, J.A. (ed): Small animal cardiology secrets.

Hanley & Belfus, Inc., Philadelphia, S. 230-237.

Abbott, J., MacLean, H.N. (2006):

Two-dimensional echocardiographic assessment of the feline left atrium.

J Vet Intern Med. 20, 111-119.

Adin, D. B., McCloy, K. (2005):

Physiologic valve regurgitation in normal cats.

J Vet Cardiol. 7, 9-13.

Andrews, P.L.R. (1988):

The physiology of the ferret.

In: Fox, J.G. (ed): Biology and diseases of the ferret.

Lea & Febiger, Philadelphia, S. 100-129.

Andrews, P.L.R., Bower, A.J., Illman, O. (1979):

Some aspects of the physiology and anatomy of the cardiovascular system of the ferret, *Mustela putorius furo*.

Lab Anim. 13, 215-220.

Besch-Williford, C.L. (1987):

Biology and medicine of the ferret.

Vet Clin North Am Small Anim Pract. 17, 1155-1183.

Bixler, H., Ellis, C. (2004):

Ferret care and husbandry.

Vet Clin Exot Anim. 7, 227-255.

Bolton, G. R. (1975):

Handbook of canine electrocardiography.

W.B. Saunders Company, Philadelphia.

## References

Boon, J.A. (1998):

Manual of veterinary echocardiography.

Williams & Wilkins, USA.

Boon, J.A. (2002):

Two dimensional and M-mode echocardiography for the small animal practitioner.

TNM Innovative Publishing, USA.

Bond, B.R. (2005):

Fine tuning the history and physical examination: correlations with miscellaneous techniques.

Clin Tech Small Anim Pract. 20, 203-210.

Bone, L., Battles, A.H., Goldfarb, R.D., Lombard, C.W., Moreland, A.F. (1988):

Electrocardiographic values from clinical normal, anesthetized ferrets (*Mustela putorius furo*).

Am J Vet Res. 49, 1884-1887.

Borgarelli, M., Tarducci, A., Tidholm, A., Haeggstroem, J. (2001):

Canine idiopathic dilated cardiomyopathy. part II: pathophysiology and therapy.

Vet J. 162, 182-195.

Boswood, A., Lamb, C. (2005):

Doppler ultrasound examination in dogs and cats. 3. assessment of cardiac disease.

In Practice. 27, 286-292.

Brown, S.A. (1997):

Basic anatomy, physiology, and husbandry.

In: Hillyer, E.V., Quesenberry, K.E. (ed): Ferrets, rabbits, and rodents clinical medicine and surgery.

W.B. Saunders, Philadelphia, S. 3-25.

Buchanan, J.W. (1991):

Vertebral scale system to measure heart size.

Proc. 9<sup>th</sup> ACVIM Forum, S. 689-690.

## References

Buchanan, J.W., Buecheler, J. (1995):

Vertebral scale system to measure canine heart size in radiographs.

JAVMA. 206, 194-199.

Buchanan, J.W., Patterson, D.F. (1965):

Selective angiography and angiocardiology in dogs with congenital cardiovascular disease.

J Am Vet Radiol Soc. 6, 21-39.

Bublott, I., Randolph, R.W., Chalvet-Monfray, K., Edwards, N.J. (2006):

The surface electrocardiogram in domestic ferrets.

J Vet Cardiol. 8, 87-93.

Budras, K-D., Fricke, W., Richter, R. (2000):

Atlas der Anatomie des Hundes 6 Auflage.

Schlütersche GmbH & Co. KG, Hannover.

Calvert, C. A., Pickus, C. W., Jacobs, G.J., Brown, J. (1997):

Signalment, survival and prognostic factors in Doberman pinschers with end-stage cardiomyopathy.

J Vet Intern Med. 11, 323-6.

Detweiler, D.K. (1984A):

The heart: gross structure, myocardial cell.

In: Swenson, M.J. (ed): Dukes' physiology of domestic animal 10<sup>th</sup> ed.

Cornell University press, S. 88-102.

Detweiler, D.K. (1984B):

Mechanical activity of the heart.

In: Swenson, M.J. (ed): Dukes' physiology of domestic animal 10<sup>th</sup> ed.

Cornell University press, S. 131-149.

Detweiler, D.K. (1984C):

Regulation of the heart.

In: Swenson, M.J. (ed): Dukes' physiology of domestic animal 10<sup>th</sup> ed.

Cornell University press, S. 150-162.

## References

Detweiler, D.K., Patterson, D.F. (1967):

Abnormal heart sounds and murmurs of the dog.

J Small Anim Pract. 8, 193-204.

Edwards, N.J. (1987):

Bolton's handbook of canine and feline electrocardiography, second edition.

W.B. Saunders Company, Philadelphia.

Ensley, P.K., Winkle, T.V. (1982):

Treatment of congestive heart failure in a ferret (*Mustela putorius furo*).

J Zoo An Med. 13, 23-25.

Evan, H.E., An, N.Q. (1998):

Anatomy of the ferret.

In: Fox, J.G. (ed): Biology and diseases of the ferret 2<sup>nd</sup> ed.

Williams & Wilkins, S. 19-70.

Farrow, C.S. (1994):

The thorax.

In: Farrow CS. Radiology of the cat.

Mosby, Inc., St. Louis, S. 50-52.

Farrow, C.S. (2000):

Canine cardiac radiology.

In: Abbott, J.A. (ed): Small animal cardiology secrets.

Hanley & Belfus, Inc., Philadelphia, S. 119-127.

Ferasin, L., van de Stadt, M., Rudolf, H., Langford, K., Moore, A.H. (2002):

Syncope associated with paroxymal AV block and ventricular standstill in cat.

J Small Anim Pract. 43, 124-128.

Fisher, E.W. (1967):

Heart sound recording.

J Small Anim Pract. 8, 171-173.

## References

Fox, J.G. (1998A):

Taxonomy, history and use.

In: Fox, J.G. (ed): *Biology and diseases of the ferret* 2<sup>nd</sup> ed.

Williams & Wilkins, S. 3-18.

Fox, J.G. (1998B):

Normal clinical and biological parameters.

In: Fox, J.G. (ed): *Biology and diseases of the ferret* 2<sup>nd</sup> ed.

Williams & Wilkins, S. 183-210.

Fox, J.G., Bell, J.A. (1998):

Growth, reproduction, and breeding.

In: Fox, J.G. (ed): *Biology and diseases of the ferret* 2<sup>nd</sup> ed.

Williams & Wilkins, S. 211-227.

Fox, P.R., Moise, N.S., Evan, H.E., Bishop, S.P. (1999):

Cardiovascular anatomy.

In: Fox, P.R., Sisson, D., Moise, N.S. (ed): *Textbook of canine and feline cardiology principles and clinical practice* 2<sup>nd</sup> ed.

W.B. Saunders Company, Philadelphia, S. 67-106.

Gaber, C. (1991):

Doppler echocardiography.

Prob Vet Med. 3, 479-499.

Gavahan, B. (2003):

Cardiology in dogs and cats. Continuing education program, the veterinary practitioners association of Thailand.

Chulalongkorn University, Bangkok, Thailand.

Gelzer, A.R.M., Kraus, M.S. (2004):

Management of atrial fibrillation.

Vet Clin Small Anim. 34, 1127-1143.

## References

Goddard, P.J. (1995):

General principles.

In: Goddard, P.J. (ed): Veterinary ultrasonography.

University press, Cambridge, UK, S. 1-19.

Gompf, R.E. (1988):

The clinical approach to heart disease: history and physical examination.

In: Fox, P.R. (ed): Canine and feline cardiology.

Churchill Livingstone Inc., USA, S. 29-42.

Gompf, R.E. (2001):

The history and physical examination.

In: Tilley, L.P. and Goodwin, J.K. (ed): Manual of canine and feline cardiology 3<sup>rd</sup> ed.

W.B. Saunders Company, Philadelphia, S. 3-16.

Goodwin, J.K. (2001):

Electrocardiography.

In: Tilley, L.P. and Goodwin, J.K. (ed): Manual of canine and feline cardiology 3<sup>rd</sup> ed.

W.B. Saunders Company, Philadelphia, S. 43-70.

Grauwiler, J. (1965):

Herz und Kreislauf der Saeugetiere.

Birkhaeuser Verlag, Basel.

Greenlee, P.G., Stephens, E. (1984):

Meningeal cryptococcosis and congestive cardiomyopathy in a ferret.

J Am Vet Med Assoc. 184, 840-841.

Haeggstroem, J., Pederson, H.D., Kwart, C. (2004):

New insights into degenerative mitral valve disease in dogs.

Vet Clin Small Anim. 34, 1209-1226.

Hamlin, R.L. (1968):

Electrocardiographic detection of ventricular enlargement in the dog.

J Am Vet Med Assoc. 153, 1461.



## References

Harpster, N.K., Zook, B.C. (1987):

Thoracic radiography.

In: Holzworth J. Diseases of the cat medicine and surgery.

W.B. Saunders Company, Philadelphia, S. 825-831.

Hillyer, E.V. (1994A):

Cardiovascular disease.

In: Birchard, S.J., Sherding, R.G. (ed): Saunders manual of small animal practice.

W.B. Saunders Company, Philadelphia, S. 1335-1338.

Hillyer, E.V. (1994B):

Urinary system.

In: Birchard, S.J., Sherding, R.G. (ed): Saunders manual of small animal practice.

W.B. Saunders Company, Philadelphia, S. 1341-1344.

Hillyer, E.V., Brown, S.A. (1994):

Ferrets.

In: Birchard, S.J., Sherding, R.G.(ed): Saunders manual of small animal practice.

W.B. Saunders Company, Philadelphia, S. 1317-1344.

Hoefler, H.L. (2001A):

EKG's in ferrets: a clinical brief.

Proc of the North American Veterinary Conference. 15, 866.

Hoefler, H.L. (2001B):

Thoracic disease rule-outs in the ferret.

Proc of the North American Veterinary Conference. 15, 867.

Isenbuegel, E., Frank, W. (1985):

Heimtierkrankheiten.

Stuttgart, S. 132-136.

Ivey, E., Morrisey, J. (1999):

Ferrets examination and preventive medicine.

Vet Clin North Am Exot Anim Pract. 2, 471- 494.

## References

- Johnson, L., Sisson, D.D. (1993):  
Atrioventricular block in cats.  
Con Educ Sm Anim. 15, 1356-1368.
- Kvart, C., Haeggstroem, J. (2002):  
Cardiac auscultation and phonocardiography in dogs, horses and cats.  
TK i Uppsala AB, Sweden, S. 16.
- Kealy, J.K. (1999):  
Roentgendiagnostik bei Hund und Katze. 2. Aufl.  
Enke Verlag, Stuttgart, S. 1-280.
- Kellum, H.B., Stepien, R.L. (2006):  
Third-degree atrioventricular block in 21 cats (1997-2004).  
J Vet Intern Med. 20, 97-103.
- Kienle, R.D. (1998):  
Echocardiography.  
In: Kittleson, M.D., Kienle, R.D. (ed): Small animal cardiovascular medicine.  
Mosby Inc, St. Louis, USA, S. 95-117.
- Kirchhoff, B. (2003):  
Zur roentgenologischen Beurteilung der Herzsilhouette bei Katzen mit kongenitalen Anomalien des Herzens, Dissertation FU, Berlin.  
Mensch & Buch Verlag, Berlin, S. 45.
- Kittleson, M.D.(1998A):  
Signalment, history, and physical examination.  
In: Kittleson, M.D., Kienle, R.D. (ed): Small animal cardiovascular medicine.  
Mosby Inc, St. Louis, USA, S. 36-46.
- Kittleson, M.D. (1998B):  
Radiography of the cardiovascular system.  
In: Kittleson, M.D., Kienle, R.D. (ed): Small animal cardiovascular medicine.  
Mosby Inc, St. Louis, USA, S. 47-71.

## References

Kittleson, M.D.(1998C):

Diagnosis and treatment of arrhythmias (Dysrhythmias).

In: Kittleson, M.D., Kienle, R.D. (ed): Small animal cardiovascular medicine.

Mosby Inc, St. Louis, USA, S. 449-494.

Kittleson, M.D. (1998D):

Electrocardiography: basic concepts, diagnosis of chamber enlargement, and intraventricular conduction disturbances.

In: Kittleson, M.D., Kienle, R.D. (ed): Small animal cardiovascular medicine.

Mosby Inc, St. Louis, USA, S. 77- 94.

Ko, J.C.H., Nicklin, C.F., Montgomery, T., Kuo, Wei-Chen. (1998A):

Comparison of anesthetic and cardiorespiratory effects of tiletamine-zolazepam-xylazine and tiletamine-zolazepam-xylazine -butorphanol in ferrets.

J Am Anim Hosp Assoc. 34, 164-174.

Ko, J.C.H., Smith, T.A., Kuo, Wei-Chen., Nicklin, C.F. (1998B):

Comparison of anesthetic and cardiorespiratory effects of diazepam-butorphanol-ketamine, acepromazine-butorphanol-ketamine, and xylazine-butorphanol-ketamine in ferrets.

J Am Anim Hosp Assoc. 34, 407-416.

Ko, J.C.H., Villarreal, A., Kuo, Wei-Chen., Nicklin, C.F. (1998C):

Evaluation of sedative and cardiorespiratory effects of diazepam-butorphanol, acepromazine-butorphanol, and xylazine-butorphanol in ferrets.

J. Am Anim Hosp Assoc. 34, 242-250.

Kono, T., Sabbah, H.N., Rosman, H., et al. (1992):

Left ventricular shape is the primary determinant of functional mitral regurgitation in heart failure.

J Am Coll Cardiol. 20, 1594.

Kono, T., Sabbah, H.N., Stein, P.D., et al. (1991):

Left ventricular shape as a determinant of functional mitral regurgitation in patients with severe heart failure secondary to either coronary disease or idiopathic dilated cardiomyopathy.

J Am Coll Cardiol. 68, 355.

## References

Koyama, H., Yoshii, H., Yabu, H., Kumada, H., Fukuda, K., Mitani, S., Rousselot, J-F., Hirose, H., Uchino, T. (2004):

Evaluation of QT interval prolongation in dogs with heart failure.

J Vet Med Sci. 66, 1107-1111.

Kvart, C., Häggström, J. (2002):

Cardiac auscultation and phonocardiography in dogs, horses and cats.

TK i Uppsala AB, Sweden.

Lamb, C.R. (2000):

Ability to visualize the cardiac silhouette in animals with pleural fluid: the pericardial fat stripe.

Vet Radiol Ultrasound. 41, 519-520.

Lipman, N.S., Murphy, J.C., Fox, J.G. (1987):

Clinical, functional and pathologic changes associated with a case of dilatative cardiomyopathy in a ferret.

Lab Anim Sci. 37, 210-212.

Litster, A.L., Buchanan, J.W. (2000):

Radiographic and echocardiographic measurement of the heart in obese cats.

Vet Radiol Ultrasound. 41, 320-325.

Lombard, C.W. (1984):

Normal values of the canine M-mode echocardiogram.

Am J Vet Res. 45, 2015–2018.

Lord, P.F., Suter, P.F. (1999):

Radiology.

In: Fox, P.R., Sisson, D., Moise, N.S.(ed): Textbook of canine and feline cardiology principle and clinical practice 2<sup>nd</sup> ed.

W.B. Saunders Company, Philadelphia, S. 107-129.

Marino, T.A. (1979):

The atrioventricular node and bundle in the ferret heart: a light and quantitative electron microscope study.

Am J Anat. 154, 365-392.

## References

Martin, M. (2002):

ECG interpretation in small animals 3. practical guidelines.

In Practice. 24, 250-261.

Martin, M; Corcoran, B.M. (2006):

Notes on cardiorespiratory diseases of the dog and cat.

Blackwell Publishing Ltd, S. 1-12.

McEwan, J.D. (2000):

Canine dilated cardiomyopathy 1. breed manifestations and diagnosis.

In Practice. 22, 520-530.

Miller, M.S., Tilley, P.L., Smith, F.W.K.Jr., Fox, P.R. (1999):

Electrocardiography.

In: Fox, P.R., Sisson, D., Moise, N.S.(ed): Textbook of canine and feline cardiology principle and clinical practice 2<sup>nd</sup> ed.

W.B. Saunders Company, Philadelphia, S. 67-106.

Moon, M.L., Keene, B.W., Lessard, P., Lee, J. (1993):

Age related changes in the feline cardiac silhouette.

Vet Radiol Ultrasound. 34, 315-320.

Moreland, A.F., Glaser, C. (1985):

Evaluation of ketamine, ketamine-xylazine and ketamine-diazepam anesthesia in the ferret.

Lab Anim Sci. 35, 287-290.

Morgan, P.J., Travers, E.K. (1998):

Used of the ferret in cardiovascular research.

In: Fox, J.G.(ed): Biology and diseases of the ferret 2<sup>nd</sup> ed.

Williams & Wilkins, S. 499-510.

Muzzi, R.A.L., Muzzi, L.A.L., de Araújo, R.B., Marcos Cherem, M. (2006):

Echocardiographic indices in normal German shepherd dogs.

J Vet Sci. 7, 193–198.

## References

Nakayama, H., Nakayama, T., Hamlin, R.L. (2001):

Correlation of cardiac enlargement as assessed by vertebral heart size and echocardiographic and electrocardiographic findings in dogs with evolving cardiomegaly due to rapid ventricular pacing.

J Vet Intern Med. 15, 217–221.

Nakayama T, Wakao Y, Takiguchi S, et al. (1994):

Prevalence of valvular regurgitation in normal beagle dogs detected by color Doppler echocardiography.

J Vet Med Sci. 56: 973-975.

O'Leary, C.A., Mackay, B.M., Taplin, R.H., Atwell, R.B. (2003):

Echocardiographic parameters in 14 healthy english bull terriers.

Aust Vet J. 81, 535-542.

O'Grady, M.R., O'Sullivan, M.L. (2004):

Dilated cardiomyopathy: an update.

Vet Clin Small Anim. 34, 1187-1207.

Olivotto, I., Cecchi, F., Casey, S.A., Dolara, A., Traverse, J.H., Maron, B.J. (2001):

Impact of atrial fibrillation on the clinical course of hypertrophic cardiomyopathy.

Circulation. 104, 2517-2524.

Oxenham, M. (1991):

Ferrets.

In: Beynon, P.H., Cooper, J.E. (ed): Manual of exotic pets.

BSAVA. S. 97-110.

Oyama, M.A. (2004):

Advances in echocardiography.

Vet Clin Small Anim. 34, 1083-1104.

Pipers, F.S., Hamlin, R.L. (1977):

Echocardiography in the horse.

JAVMA. 170, 815-819.

## References

Randolph, W.R. (1986):

Preventive medical care for the pet ferret.

In: Kirk, R.W., ed. Current veterinary therapy IX: small animal practice.

W.B. Saunders Company, Philadelphia, S. 772-774.

Richardson, P., McKenna, W., Bristow, M., Maisch, B., Mautner, B., O'Connell, J., Olsen, E., Thiene, G., Goodwin, J., Gyarfás, I., Martin, I., Nordet, P. (1996):

Report of the 1995 World Health Organisation/International Society and Federation of Cardiology Task Force on the definition and classification of cardiomyopathies.

Circulation. 93, 637-640.

Rihal, C.S., Nishimura, R.A., Hatle, L.K., Bailey, K.R., Tajik, A.J. (1994):

Systolic and diastolic dysfunction in patients with clinical diagnosis of dilated cardiomyopathy. Relation to symptoms and prognosis.

Circulation. 90, 2772-2779.

Rishniw, M., Erb, H. (2000):

Evaluation of four 2-dimensional echocardiographic methods of assessing left atrial size in dogs.

J Vet Intern Med. 14, 429-435.

Rogers, W.A., Bishop, S.P. (1971):

Electrocardiographic parameters of the normal domestic cat: a comparison of standard limb leads and an orthogonal system.

J Electrocard. 4, 315-321.

Rosenthal, K. (1994):

Ferrets.

Vet Clin North Am Small Anim Pract. 24, 1-23.

Rosenthal, K. (1997):

Management of cardiac disease in ferrets.

The 21st Annual Waltham/OSU Symposium, S. 39-40.

## References

Rosenthal, K.L. (2001):

Small animal radiology.

TNAVC 2001 Proceedings, S. 902.

Sanchez-Migallon Guzman, D., Mayer, J., Melidone, R., McCarthy R.J., McCobb, E., Kavirayani, A., Rush, J.E. (2006):

Pacemaker implantation in a ferret (*Mustela putorius furo*) with third-degree atrioventricular block.

Vet Clin North Am Exot Anim Pract. 9, 677-87.

Schelling, C.G. (2001):

Radiology of the heart.

In: Tilley, L.P., Goodwin, J-K. (ed): Manual of canine and feline cardiology 3<sup>rd</sup> edition.

W.B. Saunders Company, Philadelphia, S 17-42.

Sisson, D.D., Ettinger, S.J. (1999):

The physical examination.

In: Fox, P.R., Sisson, D., Moise, N.S.(ed): Textbook of canine and feline cardiology principle and clinical practice 2<sup>nd</sup> ed.

W.B. Saunders Company, Philadelphia, S. 46-64.

Skrodzki, M., Trautvetter, E. (1991):

Kardiologische Untersuchungen an gesunden und herzkranken Frettchen.

Proceedings WSAVA Congress, Vienna, S. 598.

Sleeper, M.M., Buchanan, J.W. (2001):

Vertebral scale system to measure heart size in growing puppies.

JAVMA. 219, 57-59.

Smith, S.H., Bishop, S.P. (1985):

The electrocardiogram of normal ferrets and ferrets with right ventricular hypertrophy.

Lab Anim Sci. 35, 268-271.



## References

Stamoulis, M.E., Miller, M.S., Hillyer, E.V. (1997):

Cardiovascular disease.

In: Hillyer, E.V., Quesenberry, K.E. (ed): Ferrets, rabbits, and rodent clinical medicine and surgery.

W.B. Saunders Company, Philadelphia, S. 63-76.

Stefanacci, J.D., Hofer, H.L. (1997):

Small mammal radiology.

In: Hillyer, E.V., Quesenberry, K.E. (ed): Ferrets, rabbits, and rodent clinical medicine and surgery.

W.B. Saunders Company, Philadelphia, S. 358-360.

Stepien, R.L., Benson, K.G., Forrest, L.J. (1999):

Radiographic measurement of cardiac size in normal ferrets.

Vet Radiol Ultrasound. 40, 606-610.

Stepien, R.L., Benson, K.G., Wenholz, B.S. (2000):

M-mode and Doppler echocardiographic findings in normal ferrets sedated with ketamine hydrochloride and midazolam.

Vet Radiol Ultrasound. 41: 452-456.

Takemura, N., Nakagawa, K. Hirose, H. (2002):

Lone atrial fibrillation in dog.

J Vet Med Sci. 64, 1057-1059.

Thomas, W.P., Gaber, C.E., Jacobs, G.J. (1993):

Recommendations for standards in transthoracic two-dimension echocardiography in dog and cat.

J Vet Intern Med. 7, 247-252.

Tidholm, A., Haeggstroem, J., Borgarelli, M., Tarducci, A. (2001):

Canine idiopathic dilated cardiomyopathy. part I: aetiology, clinical characteristics, epidemiology and pathology.

Vet J. 162, 92-107.

## References

- Tidholm, A., Svensson, H., Sylven, C. (1997):  
Survival and prognostic factors in 189 dogs with dilated cardiomyopathy.  
J Am Anim Hosp Assoc. 33, 364-8.
- Tilley, L.P. (1985):  
Essential of canine and feline electrocardiography. Interpretation and management 2<sup>nd</sup> ed.  
Lea & Febiger, Philadelphia.
- Tilley, L.P. (1992):  
Essential of canine and feline electrocardiography. Interpretation and management 3<sup>rd</sup> ed.  
Lea & Febiger, Philadelphia.
- Tilley, L.P., Goodwin, J-K. (2001):  
Manual of canine and feline cardiology 3<sup>rd</sup> edition.  
W.B. Saunders Company, Philadelphia.
- Trautvetter, E. (1986):  
Herz und Blutkreislauf.  
In: Klinik der Hundekrankheiten, Teil I.  
Gustav Fischer Verlag, Stuttgart, S. 367-418.
- Truex, R.C., Belej, R., Ginsberg, L.M., Hartman, R.L. (1974):  
Anatomy of the ferret heart: an animal model for cardiac research.  
Anat Rec. 179, 411-422.
- van den Broek, A.H.M., Darke, P.G.G. (1987):  
Cardiac measurements on thoracic radiographs of cats.  
J Small Anim Pract. 28, 125-135.
- Vastenburger, M.H.A.C., Boroffka, S.A.E.B., Schoemaker, N.J. (2004):  
Echocardiographic measurements in clinically healthy ferrets anesthetized with isoflurane.  
Vet Radiol Ultrasound. 45, 228-232.
- Vollmar, A.C. (2000):  
The prevalence of cardiomyopathy in the Irish Wolfhound: a clinical study of 500 dogs.  
J Am Anim Hosp Assoc. 36, 125-32.

## References

Vollmar, A., Fox, P.R., Meurs, K.M., Lui, S-K. (2003):

Dilated cardiomyopathy in juvenile Doberman pinschers.

J Vet Cardiol. 5, 23-27.

Ware, W.A. (1998):

Disorders of the cardiovascular system.

In: Nelson, R.W., Couto, C.G. (ed): Small animal internal medicine 2<sup>nd</sup> edition.

Mosby, Inc, St. Louis, S. 1-204.

Willis, L.S., Barrow, M.V. (1971):

The ferret (*Mustela Putorius Furo L.*) as a laboratory animal.

Lab Anim Sci. 21, 712-716.

Wilson, J.R., Douglas, P., Hivkey, W.F. et al. (1987):

Experimental congestive heart failure produced by rapid ventricular pacing in the dog: cardiac effects.

Circulation. 75, 857.

Wyburn, R.S., Lawson, D.D. (1967):

Simple radiography as an aid to the diagnosis of heart disease in the dog.

J Small Animal Pract. 8, 163-170.

[www.VetGo.com](http://www.VetGo.com)

## Acknowledgements

This dissertation could not have been complete without the continuous supports and encouragements of many people. I would like to express my deepest sincere gratitude to:

My Doktorvater, Professor Dr. Eberhard Trautvetter, the first who fired me an idea in small animal cardiovascular medicine especially in electrocardiography, for his kind advices and nonlimited supports in every facet of my life, for a ton of endurances to prove my thesis, for all of his gracious heedfulness since 29 October 2003 the first day which he picked me up from Tegel Airport, Berlin.

Professor Dr. Dr. Franz Hoerchner who made my opportunity to study in Germany came true and for his unbounded supports over seven years, for his mercifully counsel during my study in FU.

My special thanks give to the veterinarian Juergen Eichler and other coworkers in cardiology unit, who provided his ferret materials for this study.

Dr. Alan Kovacevic, for teaching me cardiology as well as the practical techniques especially in echocardiography, for a constant friendship since 2004.

Professor Dr. E. Schein, head of parasitology department, for providing me a working room and allow me to use facilities in his department.

My parents, for a limitless support and love.

My wife, Thacharot, soul mate, and the most optimistic person I have ever known, for teaching me values of love, for the eternal and unconditional love and for a large dose of forbearances with my imperfection.

## Biography

Mein Lebenslauf wird aus Datenschutzgruenden in der elektronischen Version meiner Arbeit nicht mit veroeffentlicht.

## Erklaerung

Hiermit erkläre ich, dass ich die vorliegende Arbeit selbständig ohne fremde Hilfe, unter Verwendung der im Literaturteil genannten Quellen, angefertigt habe.