

(5) Methods

5.1 Two-dimensional echocardiography

All the normal subjects and the ASD and TOF patients were examined using a 2.5/3.5 transducer interfaced with a Vingmed system V (GE Vingmed, Horten, Norway). Initially routine diagnostic imaging was performed, including color flow mapping, and pulsed and continuous wave Doppler. The standard apical four-chamber view was recorded. The right atrial area was measured along its endocardium in three different phases of the cardiac cycle, as previously described [22], when the right atrium reaches maximum, onset of electrocardiographic P wave and minimum (figure 5). The right atrial active emptying area was calculated as: area at onset of atrial contraction – minimal area, while the right atrial passive emptying area was calculated as: maximal area – area at onset of atrial contraction. The ratio between right atrial active emptying area and passive emptying area was computed. The right atrial active emptying area fraction was calculated as $(\text{area at onset of atrial contraction} - \text{minimal area}) / \text{area at onset of atrial contraction} * 100\%$ [51, 52]. All the two dimensional echocardiographic measurements were undertaken by one person.

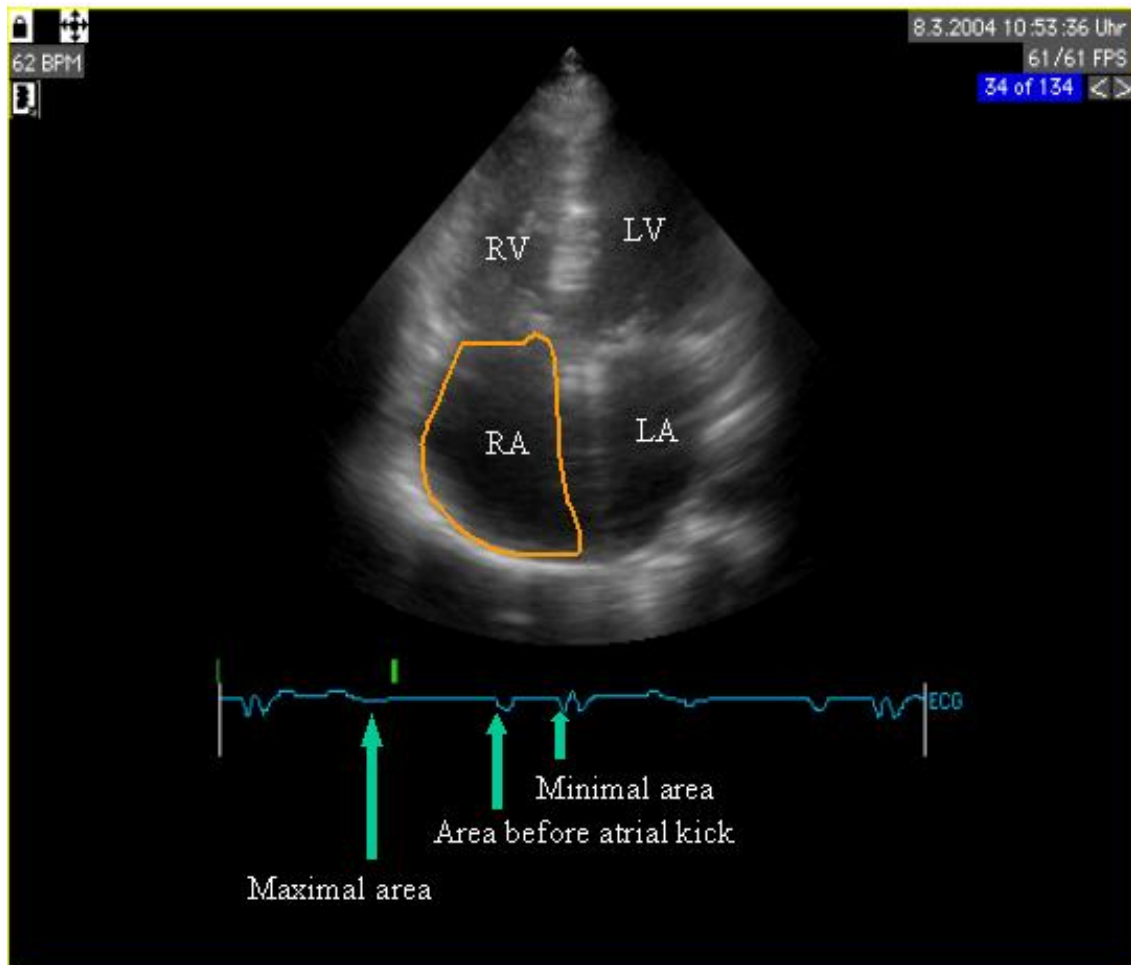


Figure 5 Method applied in measuring the right atrial areas from echocardiographic apical four chamber view. Right atrial areas were measured when the atrium reaches maximum, onset of atrial contraction and minimum.

LA: left atrium; LV: left ventricle; RA: right atrium; RV: right ventricle

5.2 Tissue Doppler imaging (TDI)

After the normal echocardiographic examination, color Doppler myocardial imaging was performed with the same apical four-chamber view in all subjects. Sector size and depth were chosen to achieve a frame rate of 130 ± 20 per second. Gain settings, filters and pulse repetition frequency were adjusted to optimize color saturation. Three consecutive cardiac cycles were recorded during normal quiet respiration. The myocardial color Doppler data were stored in digital format and transferred to a computer workstation for off-line analysis with a dedicated software (TVI; GE Vingmed, Echopack). In all the normal subjects and TOF patients right atrial and right ventricular strain rate curves were assessed in the middle of the corresponding lateral walls (figure 6). In ASD patients both the middle right atrial lateral wall and the atrial septum near the atrio-ventricular valves were assessed before and after ASD closure. A pixel of 1×1 was applied and strain rate was estimated by measuring the spatial velocity gradient over a computation distance of around 2-3 mm in measuring direction. Just like the strain rate curve obtained from ventricular walls, the atrial strain rate curve was characterized by the three main waves - systolic, early diastolic and late diastolic - which coincided with the ventricular systolic, early diastolic and late diastolic periods, respectively. The direction of the atrial strain rate curve was the opposite to that of the ventricular strain rate curve (figure 1).

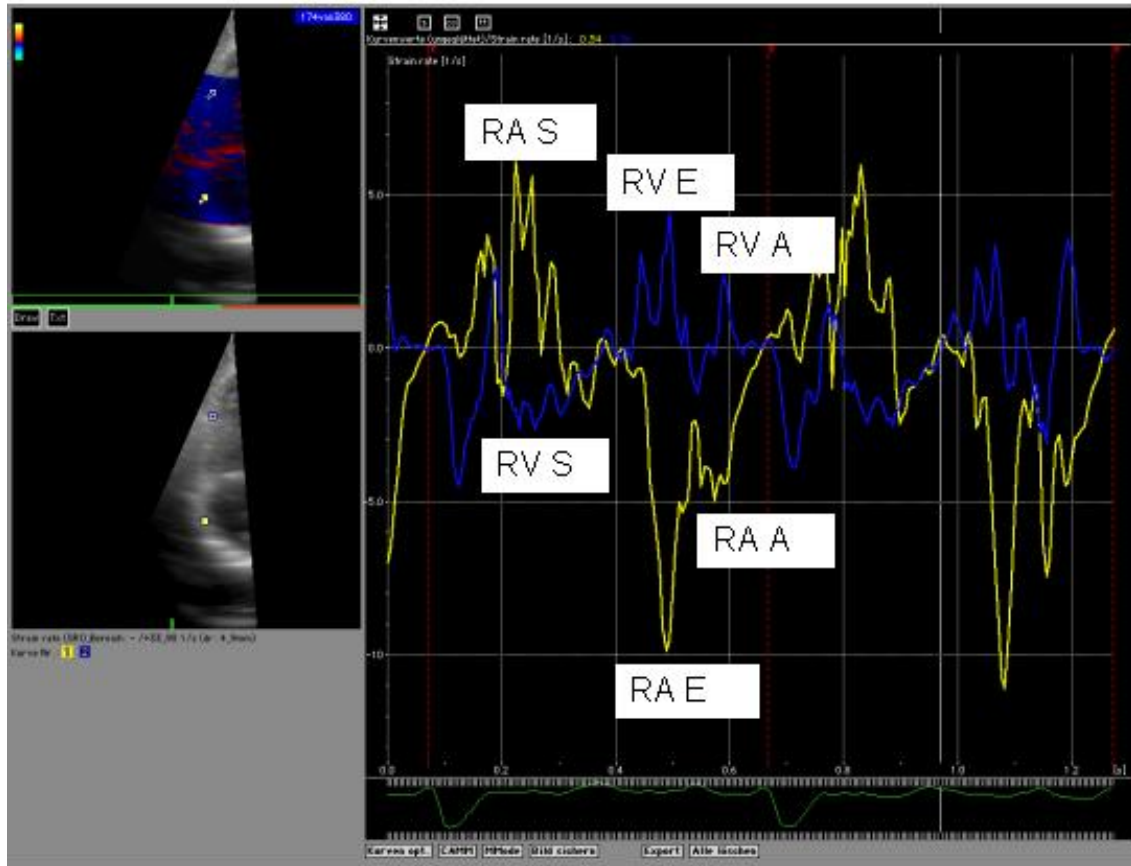


Figure 6 Tissue Doppler imaging derived strain rate curve obtained at the middle of the lateral walls of the atrium and ventricle respectively. In ventricular strain rate (blue curve) three distinct waves can be recognized: one negative systolic wave and two positive diastolic waves corresponding to early filling phase and late atrial contraction. The atrium strain rate curve is also characterized by the three main waves systolic, early diastolic and late diastolic waves, which coincided with the ventricular systolic, early diastolic and late diastolic periods respectively. The direction of atrial strain rate curve is the opposite to that of ventricular strain rate curve.

A_{sx} : late diastolic peak strain rate; ASD: secundum type atrial septum defect; ASO: atrial septum occluder;
 E_{sx} : early diastolic peak strain rate; LA: left atrium; LV: left atrium; RA: right atrium; RV: right atrium;
 S_{sx} : systolic peak strain rate; SR: strain rate; TDI: tissue Doppler imaging

5.3 Magnetic resonance tomography (MRT)

Twenty out of 50 patients with TOF underwent magnetic resonance tomography study on the same day as tissue Doppler examination for the evaluation of ventricular function. For magnetic resonance imaging a 1.5 Tesla Philips instrument (Philips, Eindhoven, Netherlands) was used. Using previously published methods [53], the ventricular volumes were measured by a third independent observer, who was blinded to the results of the tissue Doppler derived data analysis. The ventricular ejection fraction was calculated as $(\text{end-diastolic volume} - \text{end-systolic volume}) / \text{end-diastolic volume} * 100\%$.

5.4 Routine catheter examination and interventional closure of ASD with Amplatzer Septal Occluder

In 21 ASD patients a diagnostic cardiac catheterization was performed prior to ASD closure. Guided by transesophageal echocardiography (TEE) and/or fluoroscopy the blood pressures in the right ventricle, right atrium, left atrium and vessels were recorded and blood samples were drawn for oxymetry at these locations. Qp/Qs was calculated using the Fick principle. After sizing of the ASD defects with balloons, an interventional defect closure was undergone by 19 patients immediately while the other two patients were referred for surgical procedure because of unsuitability for intervention. All device occlusions in this study were performed with the Amplatzer Septal Occluder (AGA

Corporation, Golden Valley, Minnesota, USA). The procedures were in accordance with institutional guidelines and were approved by the institutional review committee.

5.5 Surgical closure of ASD

For surgical repair of ASD, an oblique incision was made in the right atrium, beginning in the right atrial appendage and extending well anteriorly to the sinoatrial area toward the inferior vena cava. The decision in favour of primary closure or patch closure was based on the size and shape of the defect and on the integrity and pliability of the defect edges. With either primary or patch closure, a running suture of propylene was used. After ASD closure the right atriotomy was also closed with a running suture. Cardiopulmonary bypass and anesthetic techniques were routine.

5.6 Statistics

The statistical software used was SPSS 10.0. Data were expressed as median (range). The nonparametric Mann-Whitney test was used to assess the difference between two independent groups and the Wilcoxon test to assess the difference between two paired groups. For analysis of correlations the nonparametric Spearman-rank-correlation was performed. $P < 0.05$ was taken as being statistically significant.

The box-whisker plots were applied to delineate the data distribution. The box itself indicates the interquartile range (IQR). The line within the box refers to the median.

Values which lie maximally more than $1.5 * IQR$ above or below the box will form the whiskers. The horizontal lines above or below the whiskers represent the highest and lowest values within this range ($1.5 * IQR$) respectively.