

5. Discussion

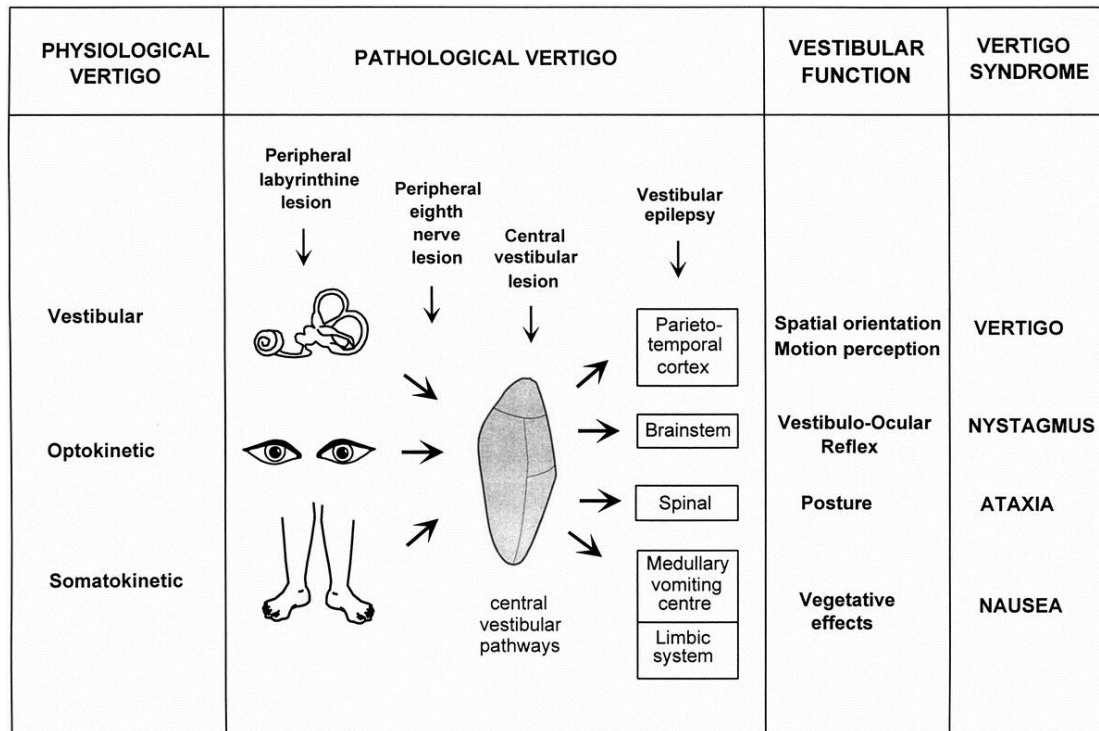
5.1 Vertiginous syndrome

5.1.1 Unspecific vertiginous syndrome

Vertigo, nystagmus, nausea and vomiting, imbalance and ataxia can be seen in all forms of vertigo. These 4 manifestations correlate with different aspects of vestibular anatomy and physiology (Figure 4):

- (1) vertigo is caused by a disturbance of cortical spatial orientation;
- (2) nystagmus can be caused by an imbalance in the vestibulo-ocular reflex activating brainstem neuronal circuitry; some types of nystagmus can strongly suggest vertigo origin,
- (3) nausea and vomiting are caused by an activation of the reticular formation, the vomiting center, in the medullary brainstem .
- (4) imbalance and vestibular ataxia can be caused by an abnormal vestibulo-spinal reflex.

Figure 4: Vertigo—a multisensory syndrome. Figure adapted from Brandt and Daroff,1980(75)



In our study, 18 patients (2 in G1, 16 in G2) showed unspecific nystagmus, 49 patients (5 in G1, 44 in G2) suffered from vomiting or nausea, 42 patients (3 in G1, 39 in G2) complained that they could not keep postural balance when they stood or walked during vertiginous attacks. But in the clinical examination, only 32 patients (5 in G1, 27 in G2) showed symptoms of ataxia. This can be explained by the time delay between the onset of the symptoms and the examination in the clinic, as some symptoms may have faded.

The occurrence of vertigo is reported to be higher in female patients (1,21,63). In our study, 67 cases (62%) were female, supporting this information.

5.1.2 Criteria of selecting patients with isolated vertigo

Vertigo with ear symptoms is often considered to be of peripheral origin, and vertigo with neurological signs is usually considered to be of central origin. The whole vestibular system's blood supply comes from the vertebrobasilar system.

In labyrinthine and in lateral pontomedullary ischemia, the patient can also have ear symptoms such as hearing loss (67). Therefore, slight ear symptoms are not necessarily proof of peripheral vertigo. In our study, 15 patients had some slight ear symptoms, but none could be diagnosed as being of peripheral origin, and 11 of them received an ENT consultation to exclude vertigo of peripheral origin.. Patients with new onset of obvious neurological symptoms such as aphasia, weakness in a limb, dysarthria, hemianopia, facial paralysis, ophthalmoplegia and unconsciousness, were excluded from our study because these symptoms would strongly suggest vertigo of central origin. Patients with spontaneous nystagmus, inexhaustible nystagmus, vertical nystagmus, falling to one side while standing or walking, Dix-Hallpike test positive nystagmus, which can strongly suggest vertigo of central or peripheral origin, were also excluded; spontaneous nystagmus with rotatory-horizontal beating clockwise-left or counterclockwise-right in combination with pathological caloric testing suggests peripheral vertigo. Pure vertical or linear or torsional spontaneous nystagmus implies a central etiology. Inexhaustible nystagmus, vertical nystagmus can strongly suggest vertigo of central origin (26,27,121). A tendency to sway or fall to one side may indicate ipsilateral cerebellar dysfunction (121).

Patients with possible mild neurological symptoms such as subjective local paraesthesia but with no reproducible pathologic symptoms during neurological examination were not excluded.

According to our patient selection criteria, only patients with isolated vertigo without indications that the vertigo is of central or peripheral origin before cranial MRI were included.

5.2 The clinical value of MRI in isolated vertigo

5.2.1 CT and MRI in central vertigo

MRI has the advantage of eliminating artifacts of the posterior fossa structures including cerebellum and brain stem, which often can be problematic with CT.

CT can diagnose most cerebellar hemorrhages, tumors and some cerebellar and brainstem ischemia, but MRI is better than CT scan for evaluating the posterior fossa, which is an important part of the vestibular system.

Brain ischemia and MS are the two most frequent causes of vertigo of central origin. As a diagnostic tool in MS, CT has a low positive predictive value. CT imaging in MS is nonspecific and insensitive. Chronic lesions of MS can appear normal in CT scans. An acute MS lesion may enhance and appear simply as an enhancing white matter lesion on CT scans, but the appearance is highly nonspecific. MRI is a tool in the diagnosis and monitoring of MS. MRI typically reveals more than 2 hyperintense lesions in the white matter, including the periventricular white matter, brainstem, cerebellum, and spinal cord (76,77).

Cranial CT is an important imaging technique for the assessment of acute stroke patients. It can exclude intracranial bleeding, but in acute ischemia within the first hours after symptom onset, CT may show normal results. MRI does not use ionizing radiation to create images. It takes advantage of the body's water molecules in combination with a powerful magnetic unit and radio frequencies to obtain images. There are several different kinds of MRI image sequence such as T1, T2, DWI (diffusion weighted imaging). MRI is being increasingly used in the diagnosis and management of acute ischemic stroke. DWI has been primarily used to assess acute ischemic stroke because it has proven highly sensitive and specific in identifying acute ischemic infarction. DWI hyperintensity is believed to indicate the presence of cytotoxic edema. Restricted diffusion has been observed as early as <30 min after an acute neurologic deficit. This decreased diffusion is markedly hyperintense on DWI (78,79).

5.2.2 MRI in isolated vertigo

Isolated vertigo not associated with any auditory or neurological symptoms is a common reason for referral to a neurotology clinic. Even after an intensive

neurotological evaluation including cranial CT, some cases remain undiagnosed. Although some cases reveal abnormalities with cranial MRI, most of these studies are case reports. MRI is costly and time-consuming, and abnormal findings are not always detected with MRI in these patients. It still remains unknown how often the etiologies in these patients can be clarified using MRI.

In our study, after cranial MRI in 108 patients with isolated vertigo, 13 patients (12%) were found to have vertigo of proven central origin. In these 13 patients, fresh infarcts appeared on MRI. Norrvig (74) has studied 22 isolated vertigo patients with MRI, and found 4 patients with cerebellar infarct (18%). In our study the lesion areas were pons, cerebellum, medullary oblongata, temporo-occipital lobe, parietal lobe, nucleus thalamus, splenium corpus callosum, both periventricular area, and the frontal lobe. Most of these regions are supplied by the vertebrobasilar arterial system, which also supplies the vestibular system. However, the lesions in the corpus callosum, both periventricular areas, and frontal lobe are not typical areas of the vestibular system. In humans, the cortical representation of the vestibular system is commonly assumed to be located in distinct parietal and temporal regions of the brain. In fact, PET has even provided results indicating a frontal area involvement in vestibular function (25). The exact anatomy of vestibular system is still unclear, and the lesion of corpus callosum, both periventricular areas, and frontal lobe may also cause vertigo. Another possible explanation for these findings is that in these few patients, the subjective sensation described as vertigo was not vertigo in the strict meaning, but may have resembled dizziness in a more general meaning.

DWI can also show acute ischemia in TIA or RIND (reversible ischemic neurologic deficit). Marx reported that of 42 patients with reversible brainstem or cerebellar symptoms classified as TIA or RIND, DWI demonstrated acute ischemia in 42.8% (83). Inatomy also reported that 57 of 129 patients with TIA

(44%) had DWI abnormalities (84). So not only infarcts but also clinically defined TIA or RIND can show abnormalities in DWI. That means isolated vertigo caused by TIA or RIND could also be revealed to a certain degree with MRI.

DWI has demonstrated its high sensitivity for acute ischemic lesions including brainstem and cerebellum within minutes of onset (78,80). However, some studies demonstrated that even DWI sometimes showed false-negative diffusion changes in small brainstem lacunar infarction. This could be explained as follows: the lesions could be too small for the resolution of the DWI echo-planar sequence, and magnetic susceptibility artifacts occurring in echo-planar imaging cause brain stem distortions that could blur image analysis (81,82). So if isolated vertigo is caused by a very small brainstem infarct, MRI diffusion studies may be false negative.

In our study, MRI revealed abnormalities in 13 of 108 patients (12%), a somewhat low detection rate. Patients in G1(67.69 ± 14.45) were older than patients in G2(59.95 ± 14.46). The prevalence of cerebrovascular risk factors such as hypercholesterolemia, hypertension, hyperglycemia, hyperlipidemia, hypercoagulable state, smoking in G1 (12/13) was higher than that in G2 (74/95). But there was no significant difference in clinical characters between the two groups. Vertigo is a common symptom in elderly people. Some research showed that patients with VUC also had high prevalence of hypertension, overweight, diabetes mellitus, which are proven to be risk factors of cerebrovascular disease (60,61,62). In these patients with isolated vertigo of undetermined origin, clinical characteristics such as age, gender and vascular risk factors cannot be used in deciding who should be investigated with MRI.

5.3 Clinical manifestation in isolated vertigo with VUC

5.3.1 Vertigo characteristics

5.3.1.1. Type of vertigo

Vertigo can be rotational or linear tilting or both. BPPV, MD, VN often manifest rotational vertigo, PPV often manifests with linear vertigo, and many vertigo disorders can show either rotational or linear vertigo. Rotational vertigo often results from disorders affecting the semicircular canals, linear tilting or swaying vertigo often stems from disorders affecting the otolithic organs (16). The type of vertigo can be regarded as an important factor but not specific for a diagnosis. There was no typical form of vertigo in either patients in G1 or patients in G2. The frequency of vertigo types was not significantly different in the two groups. Patients with VUC or central vertigo can present with any type of vertigo.

5.3.1.2 The duration of vertigo

The duration of vertigo is important for the diagnosis. BPPV often lasts only seconds, MD often lasts a few hours, VN often lasts some days to weeks, vertebrobasilar TIA often lasts minutes to hours. The duration of central vertigo is often longer. Tumor and multiple sclerosis can last for long times until the etiologies are sufficiently treated. Bleeding- and infarct- related vertigo can last days to weeks. In our study, patients with VUC and those with central vertigo showed no common characteristics in terms of duration of vertigo.

5.3.1.3 The intensity of vertigo

Generally speaking, peripheral vertigo may have a stronger subjective intensity than central vertigo, and it is more common in the peripheral vertigo that the intensity changes with the movement of head or body (16). In G1, 2 patients experienced strong vertigo, in the others the intensity of vertigo was not

recorded. In G2, the intensity of vertigo was mentioned in 37 patients. Only one had mild vertigo, while 36 patients suffered severe vertigo. It could be postulated that our patients were all inpatients whose vertiginous symptoms might be severe, because patients who suffered mild vertigo did not present to the emergency room or were not admitted to the hospital. Also, this could support the theory that peripheral disease may have been the cause in many patients with strongly felt vertigo, but due to the short duration of symptoms could not be positively diagnosed.

5.3.2 Vertebrobasilar artery system in VUC with MR angiography

Several studies showed that VUC might be associated with a higher prevalence of abnormalities in vertebrobasilar arterial system, and therefore suggested vertebrobasilar ischemia might be the cause. In our study, 30 patients had an MRA examination in G2, only 3 patients had abnormal results in vertebrobasilar (VB) artery system, including vertebral artery stenosis, vertebral artery elongation, hypoplasia of a vertebral artery. Do MRA and VUC reveal a link between VB artery system abnormalities?

Yahya et al. (53) studied morphological abnormalities of the distal vertebral arteries with MRA. The abnormalities included hypoplasia, absence of VA and termination of VA as posterior inferior cerebellar artery. A total of 88 cases of abnormalities were found in 768 patients with vertigo/dizziness (12%), but only 4 cases of abnormalities in 150 persons (3%) were found in the control group. They suggested that the abnormalities in vertebral artery were possibly related to vertigo/dizziness. Toru et al. (52) studied 31 patients with vertigo of unknown origin and 14 patients with BPPV as a control group. The abnormalities of VB artery system were classified as obstruction, bending, kinking and narrowing. A significant difference in the abnormalities was noticed between the two groups. They suggested that vertigo of unknown origin might result from VB ischemia. Lee et al. (86) found a patient who presented with transient spontaneous vertigo and bilateral sudden simultaneous hearing loss. The patient's general

and neurological examinations were normal except for the bilateral hearing loss. Magnetic resonance imaging of the brain, including diffusion images, was normal. Magnetic resonance angiography showed severe stenosis of the middle third of the basilar artery and blockage of the right distal vertebral artery. Lee suggested that this vertigo might be caused by vertebrobasilar ischemia.

The VB arterial system consists of the vertebral arteries, the basilar artery, posterior arteries, and branches including the posterior inferior cerebellar artery, the anterior inferior cerebellar artery and the superior cerebellar artery. As is well known, there are many normal variants in VB artery system. The vertebral artery originates most frequently from the subclavian artery, it ascends through the transverse foramina of C6 to C1 vertebrae, and passes intracranially through the foramen magnum before joining the opposite vertebral artery to form the basilar artery. The vertebral arteries are frequently asymmetric. The left artery is dominant in 35.8% of individuals, and the hypoplastic or atretic vertebral artery was described on the left side in 5.7%, on the right side in 8.8% (87). The VA terminates in the PICA in 1% of cases. Tortuosities or kinking in VA are common, occurring approximately in 40% of the V1 segments (88). The VB system has many normal anatomical variants, these variants have little or no clinical significance. Early studies showing anatomical abnormalities in the VB system in vertiginous patients are not convincing, because most of these studies did not consider VB anatomical variants.

MRA has a lower resolution than conventional angiography, and has also led to overestimation of the degree of stenosis, but it can exactly show the occlusion of VB artery (54,89). Fujita et al. (85) studied 33 central and peripheral vertigo patients with MRA, and found that both had abnormalities in the VB artery system, although central vertigo accompanied by vertebral artery occlusion was more common than peripheral vertigo accompanied by vertebral artery occlusion. There was no significant correlation between MRA abnormalities and the rate of central disorders.

Jellici et al. (90) found that kinking or tortuosity of the vertebral artery was not associated with hemodynamic disturbance and the patient had no specific symptoms. Vertebral artery stenosis or occlusion can be an important aetiology of posterior circulation stroke, but stenosis or occlusion in the VA without stroke is not necessarily always associated with posterior circulation symptoms such as vertigo, dysphagia, diplopia etc. (91).

MRA may play a minor role in the study of the patients with VUC. The abnormalities in VB are not frequently found with MRA in our study. Although the abnormalities in the VB system can be an aetiology of posterior circulation stroke, they were not correlated with vertebrobasilar ischemia. So we cannot draw the conclusion that some VUC may be caused by vertebrobasilar ischemia through the VB abnormalities revealed by MRA in our investigation.

5.3.3 Psychiatric manifestations and VUC

In G2, 20 patients had some form of psychological complaint or had a psychiatric disease. The prevalence of psychiatric symptoms in G2 was higher than in G1, but there was no significant difference between the two groups. Mood or emotional changes may occur with vertigo but were not specific in the patients with VUC in our study.

5.3.3.1 Prevalence of psychiatric symptoms in vertigo.

The high prevalence of psychiatric manifestation in vertigo has been repeatedly reported (103-107). Psychiatric manifestation is proven to coexist in certain vertigo diseases. Monzani D et al. (108) studied 206 vertiginous patients (including central vertigo, BPPV, Meniere's disease and other peripheral vertigo) and 86 healthy control subjects. There appeared to be no relationship between psychological change and the various types of clinical vertigo, but there was a significantly higher rate of anxiety and depression distress in vertiginous patients than in controls. Garcia et al. (109) studied 60 vertiginous patients over a 2-year period, and found 38 patients (63.4%) that

had some form of psychopathological complaint. In certain vertigo diseases such as MD, BPPV, vestibular neuronitis, and central vertigo, a high prevalence of psychiatric disorders can be constituted (103-106,110).

Vice versa, there is also a high prevalence of vestibular dysfunction in psychiatric disorders (111-113). Jacob et al. (114) were the first investigators to employ a standardized otoneurologic test battery in patients with panic disorder who reported symptoms of vertigo, 75% patients with panic disorder were identified as having a subjective vestibular abnormality. Tecer et al. (111) studied 34 panic disorder patients and 20 healthy control subjects. On vestibular testing, abnormal responses were more prevalent in panic disorder patients compared to healthy controls. There is no doubt that psychiatric disorders can cause vertigo. In these instances it is typically called psychogenic vertigo or PPV (phobic postural vertigo).

5.3.3.2 The possible mechanism of vertigo and psychiatric manifestations

The relationship of vertigo and psychiatric disorder are thought to be bi-directional (115). A psychiatric disorder can cause vestibular imbalance, such as PPV. Dysfunction of the vestibular system can in turn trigger the onset of a psychiatric illness in a previously mentally healthy person. Godemann et al. (104) studied patients with vestibular neuronitis. Anxiety levels of 92 patients in the 6 weeks after experiencing an acute vestibular disorder were examined. Acute vestibular disorder was accompanied by intensive anxiety. In most patients, anxiety decreased as vertigo regressed. Staab et al. (116) retrospectively studied 132 patients with psychogenic dizziness, and equally prevalent patterns of illness were found: anxiety disorders as the sole cause of dizziness (33% of cases), neurologic conditions exacerbating preexisting psychiatric disorders (34% of cases), and neurologic conditions triggering new anxiety or depressive disorders (33% of cases). Staab suggested that physical neurologic conditions might trigger psychopathology as often as primary anxiety disorders cause dizziness.

What is the linkage between vertigo and psychiatric disorders? Since vertigo arousal is often unpredictable, most patients with vestibular disorders may have a fear of a new episode, and their tendency to anxiety and panic is well established (108,116). Hyperventilation associated with psychological complaints and anxiety arousal may amplify the somatic symptoms induced by balance disorder (117,118). Anatomic and functional connections between the vestibular system and structures involved in the pathogenesis of psychiatric disorders further corroborate this concept. Vertigo and anxiety may arise from common abnormalities of neurotransmitters such as monoaminergic inputs, and the superior and medial vestibular nuclei are connected to the parabrachial nucleus, which is an important part of the limbic system (108,119,24).

5.3.4 VUC and migraine

Hyung et al. (55) have prospectively studied 72 consecutive patients who suffered isolated recurrent vertigo of unknown cause. All these patients underwent extensive neurotological evaluation to exclude identifiable causes of vertigo. And 100 orthopedic patients in the same hospital matched by age and sex were chosen as control group. The prevalence of migraine in the isolated recurrent vertigo group was much higher than in the control group (61.1%, 10%, $p < 0.01$). Thakar (97) retrospectively studied 334 vertigo patients and among them found 19 cases with migraine according to defined criteria (IHS), causation of vertigo by migraine was implied in 10 of 19 cases where the headache and vertigo occurred simultaneously and in two other cases where the vertigo improved with anti-migraine prophylactic treatment. In our study, 19 patients in group 2 experienced headache during the vertiginous attacks or had a migraine history: 15 patients only had headache during the vertiginous attack, 1 patient had headache during the vertiginous attack and a migraine history, and 3 patients had no headache during vertiginous attack but a migraine history. The link between VUC and migraine may be suggested but remains unproven in our findings.

5.3.4.1 The prevalence of migraine in vertiginous patients

Migraine is a common disease, with a prevalence of 15 to 17% in women and 5 to 8% in men in the course of a lifetime (92). Vertigo is also one of the most common complaints of patients presenting to the clinic. Some previous retrospective studies have revealed that the incidence of migraine in patients with dizziness or vertigo is higher than in the general population (93,94). Neuhauser et al. (95) prospectively studied 200 dizziness clinic patients (both vertigo and non-vestibular dizziness) and 200 patients from an orthopedic clinic with an age- and sex-matched control group. They found that the prevalence of migraine according to the criteria of the International Headache Society (IHS) (96) in dizziness patients was 1.6 times higher than in the control group (38% vs. 24%, $p < 0.01$).

5.3.4.2 Vestibular migraine

According to the criteria of the International Headache Society (IHS) (96), vertigo can be a migrainous symptom in basilar migraine. Basilar migraine is a disease in which vasoconstriction localized to the vertebrobasilar circulation produces posterior circulation ischemia, and headache occurs with the secondary vasodilatation. It can include vertigo as an aura symptom. However, in recent years several articles (98-102) suggest that vertigo can be an independent symptom and is sometimes not accompanied by aura and headache in migraine patients. In this situation it was called vestibular migraine or migrainous vertigo.

The symptoms of vestibular migraine can be a spontaneous or positional vertigo that lasts seconds to days, with or without migrainous headache, photophobia, phonophobia, or visual auras. The physical examination can show spontaneous or positional nystagmus, or saccadic pursuit. These patients don't fulfill the criteria of basilar migraine according to IHS. Researchers (96,99,100,101) have suggested the following diagnostic criteria

for vestibular migraine:

1. Episodic vestibular symptoms of at least moderate severity (rotational vertigo, other illusory self or object motion, positional vertigo, head motion intolerance, i.e., sensation of imbalance or illusory self or object motion that is provoked by head motion),
2. migraine according to the IHS criteria,
3. at least one of the following migrainous symptoms during at least two vertiginous attacks: migrainous headache, photophobia, phonophobia, visual or other auras,
4. other causes ruled out by appropriate investigations.

The diagnosis of probable migrainous vertigo was based on the following criteria:

1. Episodic vestibular symptoms of at least moderate severity (rotational vertigo, other illusory self or object motion, positional vertigo, head motion intolerance),
2. at least one of the following: migraine according to the criteria of the IHS; migrainous symptoms during vertigo; migraine-specific precipitants of vertigo, e.g., specific foods, sleep irregularities, hormonal changes; response to antimigraine drugs,
3. other causes ruled out by appropriate investigations.

In our study, it was not always possible to determine whether the vertigo of some patients in group 2 was caused by vestibular migraine, but we do know that migraine can coexist with isolated vertigo without known cause in the same patient.

5.3.5 Cerebrovascular risk factors in VUC

In group 2, 74 patients (77.9%) had one or more cerebrovascular risk factors such as hypertension, hyperlipidemia, hyperglycemia, stroke history, hypercoagulable state, smoking, etc. The prevalence of cerebrovascular risk

factors in VUC was relatively high. There was no significant difference of cerebrovascular risk factors between central vertigo and VUC in our study. Hypertension is the most frequent cerebrovascular risk factor in VUC with 40 patients having high blood pressure or a hypertension history. In a previous study, causes of vertigo in hypertensive patients were investigated (120). It revealed that vertigo in hypertensive patients was not caused by elevated pressure but instead was related to concomitant neurological or peripheral vestibular disease.

5.4 Limitations of the study

There are some limitations in our study: Our study is retrospective, so not all parameters were recorded in detail. In addition, all patients were inpatients in a neurological department of a university hospital. Therefore, our patient cohort may have had a higher prevalence of vertigo of central origin, and the study population may not be representative of a primary care population.