


The inside-out surgical anatomy of the paraglottic space a video-guided endoscopic dissection

Hazem Mohamed Aly Saleh MD DEA^{1,2}  | Nadja Seidel³ | Thomas Jöns MD³ |
Dirk Mürbe MD² | Tadeus Nawka MD²

¹Otorhinolaryngology Unit, National Institute of Laser Enhanced Sciences, Cairo University, Giza, Egypt

²Klinik für Audiologie und Phoniatrie, Charité - Universitätsmedizin Berlin, Berlin, Germany

³Berliner Simulations & Trainingszentrum (BeST), Department of Anatomy, Charité - Universitätsmedizin Berlin, Berlin, Germany

Correspondence

Hazem Mohamed Aly Saleh,
Otorhinolaryngology Unit, National Institute of Laser Enhanced Sciences, Cairo University,
12613 Giza, Egypt.
Email: profhazemsaleh@nils.edu.eg

Funding information

The German Academic Exchange Service (DAAD)/German Egyptian Research Short-Term Scholarship Programme (GERSS), Grant/Award Number: 57522433

Abstract

Objectives: The paraglottic space is an essential anatomic compartment of the larynx. It is central to the spread of laryngeal cancer and to the choice of conservative laryngeal surgery and many phonosurgical procedures. Since its description, 60 years ago, the surgical anatomy of the paraglottic space was sparsely revisited. Amid the era of endoscopic and transoral microscopic functional surgery of the larynx, we provide here a long-awaited description of the inside-out anatomy of the paraglottic space.

Methodology: Using an endoscope equipped with a 3D camera, we dissected 10 hemilarynges from 5 fresh frozen cadavers from the inside out. Before dissection, we labeled the vessels through injecting them with colored latex. We explored the paraglottic space emphasizing its shape, boundaries, and contents. We documented our findings through endoscopic photography and video recordings.

Results: The paraglottic space is a spacious tetrahedral space located parallel not only to the glottic, but also to the subglottic and the supraglottic compartments of the laryngeal lumen. It has musculo-cartilaginous, musculo-fibrous, and mucosal boundaries. It is separated from the pyriform sinus only by mucosa. A cushion of fat surrounds its vascular and to a lesser extent its neural contents. Harbored intrinsic laryngeal muscles are endoscopically identifiable within the space, namely the thyroarytenoid, the lateral, and posterior cricoarytenoid muscles.

Conclusion: The endoscopic description of the paraglottic space partly fills the knowledge gap on the laryngeal anatomy from the inside out. It opens the door for novel diagnostic methods and for ultraconservative functional laryngeal interventions under endoscopic control.

Level of Evidence: N/A

KEYWORDS

anatomy, endoscopic, inside out, larynx, paraglottic

This is an open access article under the terms of the [Creative Commons Attribution-NonCommercial-NoDerivs](https://creativecommons.org/licenses/by-nc-nd/4.0/) License, which permits use and distribution in any medium, provided the original work is properly cited, the use is non-commercial and no modifications or adaptations are made.

© 2022 The Authors. *Laryngoscope Investigative Otolaryngology* published by Wiley Periodicals LLC on behalf of The Triological Society.

1 | INTRODUCTION

The paraglottic space is an important anatomic compartment of the larynx. As described initially by Tucker and Smith,¹ it is bounded antrolaterally by the thyroid cartilage, inferomedially by the conus elasticus, medially by the laryngeal ventricle of Morgagni and the quadrangular membrane, and dorsally by the mucosal lining of the pyriform sinus. It communicates with the deep neck spaces posterosuperiorly through a foramen in the thyrohyoid membrane allowing the entry of the superior laryngeal vessels and the internal branch of the superior laryngeal nerve. It is continuous with the preepiglottic space anterosuperiorly and communicates with the prelaryngeal tissues anteroinferiorly through a gap in the cricothyroid membrane.^{1,2} Reidenbach did not consider the paraglottic space a typical anatomic compartment enclosed within connective tissue membranes, but viewed it as a space of adipose and connective tissue connected to adjacent anatomic regions and continuous with them at specific points.³

The boundaries and contents of the paraglottic space are also debatable. Tucker and Smith¹ and Tucker⁴ considered the laryngeal ventricle of Morgagni and the quadrangular membrane the medial boundary of the paraglottic space and hence included the thyroarytenoid muscle within its contents. Maguire and Dayal⁵ and Sato et al.⁶ confined the term “paraglottic” space to a slit of areolar tissue bordered by the thyroarytenoid muscle medially, the thyroid cartilage laterally, and the piriform sinus dorsally. Hence, they excluded this muscle from the contents of the space. Sato et al.⁶ suggested that the rest of the medial boundary of the paraglottic space is formed by the “thyroglottic ligament” advocating that this ligament separates the paraglottic space from the preepiglottic space. Tucker and Smith¹ had used the term “thyroglottic ligament” earlier, to describe a fibrous layer stretched between the anterior part of the vocal fold and the thyroid cartilage in a 24-week-old fetal larynx, not in an adult larynx.

The paraglottic space is of utmost importance regarding laryngeal cancer spread.^{7,8} The local spread of laryngeal cancer depends primarily on its site of origin, which is predominantly the mucosa. The route of invasion is highly determined by the anatomy of the adjacent tissues, especially their muscular content.⁹

Transglottic cancer was described as the one that invades both the false and true vocal folds across the ventricle, passing through the muscle harboring paraglottic space. It was long stigmatized by its ominous prognosis. Therefore, laryngeal cancer invading the paraglottic space was treated exclusively by total laryngectomy.¹⁰ The introduction of surgical techniques that allow the complete resection of the primary tumor, together with resection of the paraglottic space, flagged the beginning of the era of partial (functional) laryngeal cancer surgery.^{10,11} Today, the extent of cancer invasion in the paraglottic space and the possibility of its safe oncologic excision occupy a central role in the TNM classification of laryngeal cancer and in the choice of one of the oncologic conservative laryngeal surgeries.^{12,13}

Since the endoscopic flexible and rigid laryngoscopy became the standard method for laryngeal examination,¹⁴ the classic layered

trans-cervical anatomy no more mirrors our clinical practice. Modern laryngologists and phonosurgeons have no choice than to master the anatomy of areas, muscles, cartilages, and neurovascular structures of the larynx from the inside out.¹⁵ Novel anatomic dissections should help. The inside-out perspective is not only the portal for endoscopic and microlaryngeal surgery^{16,17}; moreover, it follows the main route of local spread of laryngeal cancer.¹⁸

This study provides an anatomic description of the paraglottic space from the inside out. This work was accomplished using a 3D video laryngoscope (Xion GmbH, Germany) that gives a more real perspective, especially on the depth, like the one provided by a stereoscopic microscope. The wider angle of vision, the possibility to come in close proximity with the studied structures and the video-documentation and photo-documentation in a 3D fashion were advantages provided by the 3D endoscope. The laryngeal vessels were marked primarily to allow their identification and secondarily to locate the plans of dissection defined by them. In brief, our technique combined a postmortem injection of colored latex into the cervical vessels¹⁹ with an inside-out laryngeal dissection by a sophisticated video-guided endoscope. To the best of our knowledge, this is the first-ever report describing the surgical anatomy of the larynx and of the paraglottic space from the inside out using a 3D endoscope.

2 | METHODOLOGY

Five donor bodies (fresh cadavers) were transferred to the Department of Anatomy, Charité - Universitätsmedizin Berlin. Their age, sex, race, and cause of death were noted. All data were obtained in accordance with Charité guidelines for cadaveric use in research.

The common carotid arteries and the internal jugular veins on both sides were meticulously dissected according to the approach of surgical neck dissection. Any breach of the vessels or their branches/tributaries was avoided. The subclavian artery was also dissected bilaterally with dislocation of the clavicle when needed. Plastic tubes/cannulas were introduced into the main vessels through a small incision secured by sutures. We flushed the arterial and venous systems with saline to remove debris or clots. Leaking points, if any, were identified and secured by a hemostat. Colored latex (Ward Science, California) was injected into the great neck vessels of the fresh cadavers: red latex into the arterial system and blue latex into the venous system. In total, 20–45 cc of red latex was injected into the arterial system and 60–120 cc of blue latex into the venous system. The injection was continued until the colored latex spilt out from the contralateral side. After injection, the cadavers were frozen for at least 1 week at -20°C . Once the latex had solidified, the necks were transected at the level of C7–T1 and stored at -20°C until the start of the transoral video-endoscopic dissection of the larynx. Each specimen was dissected in an average of three dissection sessions on 3 nonconsecutive days. Before each session, the specimens were allowed to defrost for 20 h at room temperature. Each dissection session lasted for 5 h in average. After each session, the heads were refrozen at -20°C for at least 24 h.

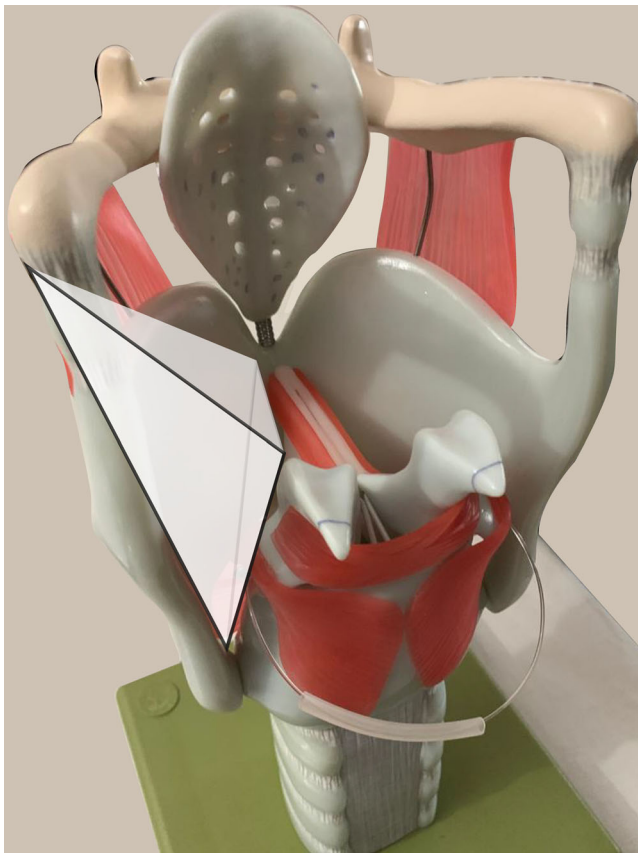


FIGURE 1 Schematic presentation of the tetrahedral aspect of the left paraglottic space. It is like a triangular pyramid with a dorsal base and a ventral summit

The larynges of the cadaveric heads and necks were dissected from the inside out using microphonosurgical instruments and an endoscope-bearing laryngoscope (Spiggle & Theis, Germany). The laryngoscope was equipped with a whole-length socket encompassing a 0°, 14 cm long endoscope mounted to an EndoSURGERY 3D Spectar camera (Xion GmbH, Germany).

The cadaveric heads were put in a position similar to that during transoral microsurgery with the neck hyperextended. The light guide was used to position the laryngoscope by the naked eye. The laryngoscope displaced the epiglottis ventrally and was suspended by a support.

The dissection started, under videoendoscopic guidance, by an incision in the mucosa of the aryepiglottic fold. A mixture of sharp and blunt dissections was adopted. Adipose tissue was extracted from the paraglottic and the adjacent preepiglottic spaces, preserving the muscles and neurovascular structures. Dissection was video-recorded and photos were shot. Photos and videos were reviewed several times.

3 | RESULTS

We dissected 10 hemilarynges from 5 donor-fresh frozen cadavers. The donors' ages ranged between 73 and 98 years (mean = 85 years).

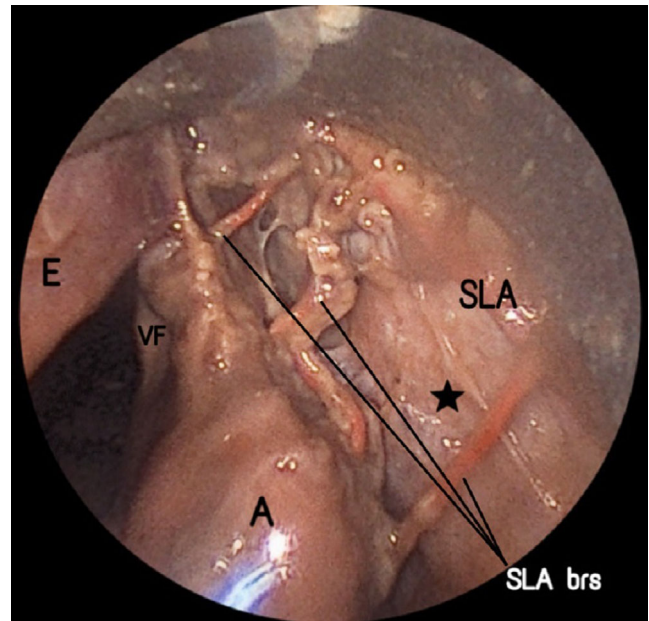


FIGURE 2 * Muscle-lined thyroid cartilage forming the anterolateral boundary of the right paraglottic space. The mucosa was incised at the right aryepiglottic fold. The right thyroid cartilage ala is seen from inside lined by muscle * while forming the anterolateral boundary of the right paraglottic space. From the orientation of the fibers, we think that this layer is rather an inner extension from the thyropharyngeal part of the inferior constrictor muscle. Branches of the right superior laryngeal artery are seen bridging the right paraglottic space. A, right arytenoid; E, epiglottis; SLA brs, branches of the right superior laryngeal arteries; SLA, right superior laryngeal artery; VF, right vocal fold

They were four females and one male, all were Caucasians. The five donors had died from systemic conditions and did not have any known laryngeal pathology.

The red latex filled the laryngeal arteries in 7 out of the 10 hemilarynges. The blue latex did not reach the laryngeal veins in any cadaver except in one cadaver where some superficial mucosal veins were stained blue.

Our video-guided, endoscopic inside-out dissection of the larynx found that the paraglottic space in all specimens is a true space, far from being a potential or a presumed space (Supplementary Video S1). The paraglottic space was capacious. Its largest transverse dimension was equal to that of the ipsilateral pyriform sinus. It was triangular in shape as previously described,¹ or rather tetrahedral (triangular pyramid lying on its side with a dorsal base and a ventral summit; Figure 1). We noticed that the anterolateral boundary of the paraglottic space was musculo-cartilaginous. It was formed cranially by the thyrohyoid membrane and caudally by the inner surface of the thyroid cartilage, which is lined by a muscle layer (Figure 2). From the orientation of the fibers, we think that this layer is rather an inner extension from the thyropharyngeal part of the inferior constrictor muscle.

The paraglottic space was bounded medially at this level by the aryepiglottic fold, which is actually a fibro-muscular fold wrapped with mucosa. The aryepiglottic fold contained not only the quadrangular

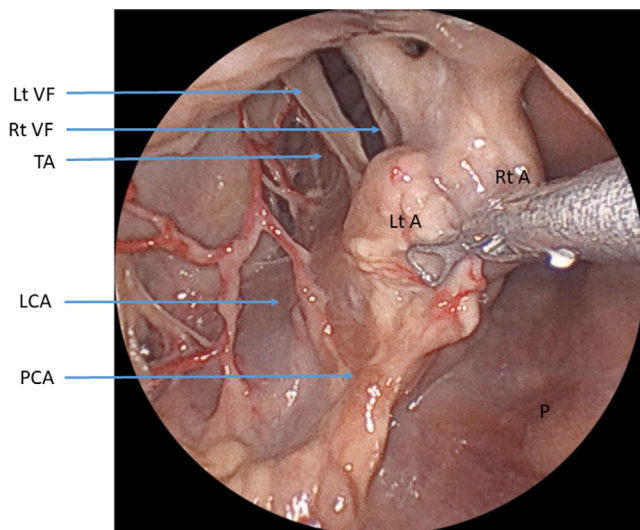


FIGURE 3 Trifurcation of the thyroarytenoid muscle (TA), the lateral cricoarytenoid muscle (LCA) and the posterior cricoarytenoid muscle (PCA) from the muscular process and adjacent body of the left arytenoid in the left paraglottic space. The left arytenoid is retracted superiorly and posteromedially by the forceps (the muscular process was palpable but not identified visually being wrapped in muscles). E, epiglottis; Lt A, left arytenoid; Lt VF, left vocal fold; P, posterior pharyngeal wall; Rt A, right arytenoid; Rt VF, right vocal fold; T, Thyroid lamina

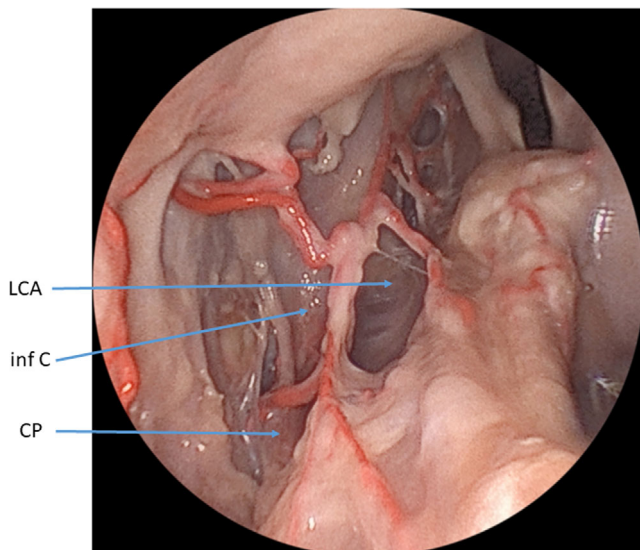


FIGURE 4 A closer view on the contents of the left paraglottic space, showing the area of the inferior cornu (inf C) of the left thyroid lamina which demarcates the lateral cricoarytenoid (LCA) muscle fibers coursing antrolaterally and caudally from the cricopharyngeus (CP) muscle fibers coursing posterolaterally and cranially

membrane but also muscle fibers constituting the aryepiglottic muscle, which is an extension from the oblique arytenoid muscle as we noticed and as was described by Sato.²⁰

Inside the paraglottic space and at the glottic and subglottic levels, the thyroarytenoid and the lateral cricoarytenoid muscles were

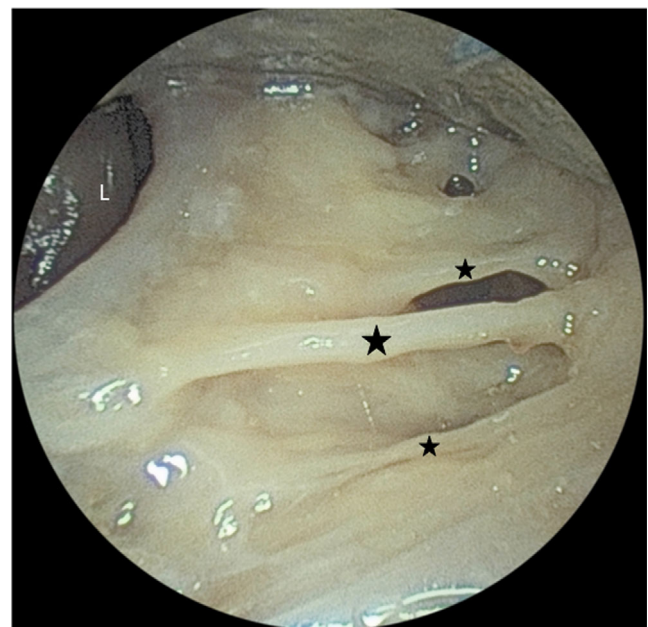

FIGURE 5 * Ramifications from the internal branch of the right superior laryngeal nerve coursing from lateral to medial immediately deep to the mucosa of the right aryepiglottic fold and aiming towards the right arytenoid area. The incised mucosa wrapping the right aryepiglottic fold was retracted medially. L, laryngeal lumen

identified, intimately close but separable, the vessels and adipose tissue of the paraglottic space were seen extending between them. The vessels and adipose tissue of the paraglottic space extended also between the lateral cricoarytenoid muscle, the posterior cricoarytenoid muscle, and the cricopharyngeus muscle. This latter muscle was seen, from the inside-out perspective, constituting the posterolateral boundary of the paraglottic space at the subglottic level. The thyroarytenoid, the lateral and posterior cricoarytenoids trifurcated from the muscular process and the adjacent body of arytenoid and coursed in a craniocaudal orientation, anteriorly, antrolaterally, and posterolaterally, respectively (Figure 3). In the subglottic part of the paraglottic space, the inferior cornu of the thyroid cartilage demarcated the lateral cricoarytenoid muscle, whose fibers run antrolaterally ventral to the inferior cornu and in a caudal direction, from the cricopharyngeus muscle, whose fibers run posterolaterally dorsal to the inferior cornu but in a cranial direction (Figure 4).

The adipose tissue in the paraglottic space mainly formed a cushion of fat around the superior laryngeal artery and its branches. A vein lied lateral to the main artery at its entry to the larynx. Ramifications from the internal branch of the superior laryngeal nerve, coursing towards the arytenoid area, were apparent immediately deep to the mucosa of the aryepiglottic fold, being surrounded by adipose tissue (Figure 5). The nerve and its branches did not remain tucked to the inner surface of the thyroid cartilage, contrary to the superior laryngeal artery and its main branches. The amount and consistency of the adipose tissue differed between the paraglottic and the preepiglottic spaces. Adipose tissue was more abundant and looser in the latter. We did not observe any apparent anatomical differences between the

five cadavers regarding the shape, boundaries, or contents of the paraglottic space. A radiologic study is planned to assess—between others—the exact dimensions of the paraglottic space with the use of an ultramodern MRI.

4 | DISCUSSION

Pressman et al.²¹ investigated the spread of dyes injected into various regions of the larynx and related their experimental findings to the laryngeal cancer growth pattern. They concluded that there is a zone of minimal resistance against tumorous growth between the thyroid cartilage and the intrinsic laryngeal muscles. This zone is nothing but the paraglottic space described few years later.¹ Reidenbach stressed that there is no definite anatomic barrier or well-developed collagenous fiber septa separating the muscle fibers from the paraglottic adipose tissue⁹ adding to the low resistance of the whole space against cancer.

Since the MRI sensitivity and specificity for infiltration of the paraglottic space by cancer is only 67% and 50%, respectively, with a tendency to upgrade the tumor,²² the extent of cancer invasion of the paraglottic space and the identification of the invaded intrinsic muscle(s) are prone to be explored by microscopic or novel endoscopic techniques. Surgical endoscopic paraglottic visual exploration may constitute, in the future, an adjuvant to the assessment of the laryngeal muscular activity, which is done now mainly by transoral vocal folds mobility inspection.^{13,15}

Besides its role played in laryngeal cancer staging and in the choice of open laryngeal cancer surgery, the paraglottic space is nowadays also home for many other surgical procedures.¹⁵ During transoral partial laryngectomies, laser cordectomies, transoral laser excision of hypopharyngeal tumors, Botulinum toxin injection, arytenoid adduction, and medialization laryngoplasty, surgeons blindly enter the paraglottic space.²³⁻²⁶ Despite its surgical importance, few reports described the surgical anatomy of the paraglottic space during the last six decades. Beyond its initial description by Tucker and Smith,¹ and the pioneering work of Reidenbach^{3,9,27} in the 90s of the last century, the surgical anatomy of the paraglottic space was sparsely revisited. The endoscopic inside-out dissection of the paraglottic space does not necessitate removal of the thyroid cartilage. In addition, it is more accurate, real, and rapid than conventional anatomic methods.²⁸ Serial sections of plastinated adult human larynges done by Reidenbach took more than 3 months of preparation.³

In accordance with Sato,²⁰ we advocate that the paraglottic space—despite its name—is neighboring not only the glottic and subglottic levels of the laryngeal lumen, but also the supraglottic level. It is also intimately bordering the pyriform sinus. As we observed at the supraglottic level, Chitose et al.²⁵ found no muscular demarcation between the pyriform sinus and the posterior aspect of the paraglottic space. This explains the early invasion of cancer of the pyriform sinus into the paraglottic space.

From the functional anatomic aspect, the paraglottic space may be viewed as a technical room seconding the laryngeal lumen, where

the ancillary vascular and muscular machinery are protected uninterrupted, and away from interrupting the vibratory functions of the vocal folds.

Our dissection showed that the paraglottic space is more than a potential space containing a rim of adipose tissue insinuated between the intrinsic laryngeal muscles. It is rather the whole area enclosed between the thyrohyoid membrane, the thyroid lamina, and the cricoid cartilage laterally and the mucosa lining the laryngeal lumen at the ventricle of Morgagni, the quadrangular membrane and the conus elasticus medially (Figure 1). The paraglottic space contains intrinsic laryngeal muscles separated by adipose tissue containing neurovascular structures. Accordingly, we suggest rebaptizing this space: the “paraluminal laryngeal” space, a suggestion that we submit here to the relevant scientific authorities for discussion and approval.

5 | CONCLUSION

The paraglottic space is a real and important anatomic compartment of the larynx. It is situated in vicinity of the glottic, the supraglottic, and the subglottic compartments. Laryngologists and phonosurgeons should become familiar with the transoral perspective of the surgical anatomy of the larynx, especially the anatomy of the paraglottic space. Mastering the surgical anatomy of the paraglottic space from the inside out will promote the development of new visual diagnostic techniques, paving the way for more precise and ultraconservative functional laryngeal and hypopharyngeal interventions.

FUNDING INFORMATION

Professor Hazem Mohamed Aly Saleh received a short-term scholarship from The German Academic Exchange Service (DAAD)/German Egyptian Research Short-Term Scholarship Programme (GERSS), 2020 Grant # (57522433).

ORCID

Hazem Mohamed Aly Saleh  <https://orcid.org/0000-0001-7405-1351>

REFERENCES

1. Tucker GF Jr, Smith HR Jr. A histological demonstration of the development of laryngeal connective tissue compartments. *Trans Am Acad Ophthalmol Otolaryngol.* 1962;66:308-318.
2. Tucker G Jr. Some clinical inferences from the study of serial laryngeal sections. *Laryngoscope.* 1963;73:728-748.
3. Reidenbach MM. Borders and topographic relationships of the paraglottic space. *Eur Arch Otorhinolaryngol.* 1997;254:193-195.
4. Tucker RG. Effect of metal ions and polyamines on the development of bacteriophage phi-R. *J Gen Microbiol.* 1963;32:287-294.
5. Maguire A, Dayal VS. Supraglottic anatomy the pre- or the periepiglottic space? *Can J Otolaryngol.* 1974;3:432-445.
6. Sato K, Kurita S, Hirano M. Location of the preepiglottic space and its relationship to the paraglottic space. *Ann Otol Rhinol Laryngol.* 1993; 102:930-934.
7. Vilaseca I, Aviles-Jurado FX, Valduvico I, et al. Transoral laser micro-surgery in locally advanced laryngeal cancer: prognostic impact of

- anterior versus posterior compartments. *Head Neck*. 2021;43:3832-3842.
8. Kirchner JA, Carter D. Intralaryngeal barriers to the spread of cancer. *Acta Otolaryngol*. 1987;103:503-513.
 9. Reidenbach MM. Topographical anatomy and oncologic implications of the anterolateral surface of the arytenoid cartilage. *Eur Arch Otorhinolaryngol*. 1998;255:140-142.
 10. Kim MS, Sun DI, Park KH, Cho KJ, Park YH, Cho SH. Paraglottic space in supracricoid laryngectomy. *Arch Otolaryngol Head Neck Surg*. 2002;128:304-307.
 11. Piquet JJ, Desaulty A, Decroix G. Supraglottal horizontal laryngectomy in the treatment of supraglottal cancers of the laryngeal border. (apropos of 104 cases). *Ann Otolaryngol Chir Cervicofac*. 1972;89:35-46.
 12. Locatello LG, Pietragalla M, Taverna C, Bonasera L, Massi D, Mannelli G. A critical reappraisal of primary and recurrent advanced laryngeal cancer staging. *Ann Otol Rhinol Laryngol*. 2019;128:36-43.
 13. Succo G, Crosetti E, Bertolin A, et al. Benefits and drawbacks of open partial horizontal laryngectomies, Part B: Intermediate and selected advanced stage laryngeal carcinoma. *Head Neck*. 2016;38(Suppl 1):E649-E657.
 14. Kendall KA, Leonard RJ. *Laryngeal Evaluation*. Thieme; 2010.
 15. Hinni ML, Lott DG. *Contemporary transoral surgery for primary head and neck cancer*. Plural Publishing Inc.; 2013.
 16. Daniero JJ. Expanding perspectives in airway stenosis. *JAMA Otolaryngol Head Neck Surg*. 2017;143:505-506.
 17. Daniero JJ, Garrett CG, Francis DO. Framework surgery for treatment of unilateral vocal fold paralysis. *Curr Otorhinolaryngol Rep*. 2014;2:119-130.
 18. Pearson BW. Laryngeal microcirculation and pathways of cancer spread. *Laryngoscope*. 1975;85:700-713.
 19. Riepertinger A, Heuckendorf E. E20 color-injection and plastination of the brain. *J Int Soc Plastination*. 1993;7:8-12.
 20. Sato K. *Functional Histoanatomy of the Human Larynx*. Springer-Verlag; 2018.
 21. Pressman JJ, Simon MB, Monell C. Anatomical studies related to the dissemination of cancer of the larynx. *Trans Am Acad Ophthalmol Otolaryngol*. 1960;64:628-638.
 22. Banko B, Djukic V, Milovanovic J, Kovac J, Novakovic Z, Maksimovic R. MRI in evaluation of neoplastic invasion into preepiglottic and paraglottic space. *Auris Nasus Larynx*. 2014;41:471-474.
 23. Caffier PP, Nasr AI, Weikert S, Rummich J, Gross M, Nawka T. The use of injectable calcium hydroxylapatite in the surgically pretreated larynx with glottal insufficiency. *Laryngoscope*. 2017;127:1125-1130.
 24. Nawka T, Hosemann W. Surgical procedures for voice restoration. *GMS Curr Top Otorhinolaryngol Head Neck Surg*. 2005;4:Doc14.
 25. Chitose S, Sato K, Fukahori M, et al. Histoanatomical characteristics to increase the success in transoral surgery for hypopharyngeal cancer. *Laryngoscope*. 2016;126:1783-1789.
 26. Volk GF, Pototschnig C, Mueller A, et al. Teaching laryngeal electromyography. *Eur Arch Otorhinolaryngol*. 2015;272:1713-1718.
 27. Reidenbach MM. The paraglottic space and transglottic cancer: anatomical considerations. *Clin Anat*. 1996;9:244-251.
 28. Perotti P, Ferrari M, Montalto net al. Anatomical cadaver study of Endolaryngeal vascularization: focus on the glottis, Supraglottis, and subglottis from the Transoral microsurgical point of view. *Front. Oncologia*. 2018;8:138.

SUPPORTING INFORMATION

Additional supporting information can be found online in the Supporting Information section at the end of this article.

How to cite this article: Saleh HMA, Seidel N, Jöns T, Mürbe D, Nawka T. The inside-out surgical anatomy of the paraglottic space a video-guided endoscopic dissection. *Laryngoscope Investigative Otolaryngology*. 2023;8(1):162-167. doi:[10.1002/lio2.979](https://doi.org/10.1002/lio2.979)