






BRIEF COMMUNICATION

Teleproctoring for Training in Structural Heart Interventions: Initial Real-World Experience During the COVID-19 Pandemic

Niklas Beyhoff , MD; Miry Zhu, cand. med; Lukas Zanders, MD; David M. Leistner , MD; Anthony Nobles , PhD; Mark Schroeder, MSc; Fabian Barbieri , MD, PhD; Ulf Landmesser , MD; Markus Reinthaler, MD

BACKGROUND: Proctoring represents a cornerstone in the acquisition of state-of-the-art cardiovascular interventions. Yet, travel restrictions and containment measures during the COVID-19 pandemic limited on-site proctoring for training and expert support in interventional cardiology.

METHODS AND RESULTS: We established a teleproctoring setup for training in a novel patent foramen ovale closure device system (NobleStitch EL, HeartStitch Inc, Fountain Valley, CA) at our institution using web-based real-time bidirectional audiovisual communication. A total of 6 patients with prior paradoxical embolic stroke and a right-to-left shunt of grade 2 or 3 were treated under remote proctorship after 3 cases were performed successfully under on-site proctorship. No major device/procedure-related adverse events occurred, and none of the patients had a residual right-to-left shunt of grade 1 or higher after the procedure. Additionally, we sought to provide an overview of current evidence available for teleproctoring in interventional cardiology. Literature review was performed identifying 6 previous reports on teleproctoring for cardiovascular interventions, most of which were related to the current COVID-19 pandemic. In all reports, teleproctoring was carried out in similar settings with comparable setups; no major adverse events were reported.

CONCLUSIONS: Teleproctoring may represent a feasible and safe tool for location-independent and cost-effective training in a novel patent foramen ovale closure device system. Future prospective trials comparing teleproctoring with traditional on-site proctoring are warranted.

Key Words: COVID-19 ■ patent foramen ovale ■ PFO closure ■ remote proctoring ■ teleproctoring

The rapid evolution of catheter-based therapies for congenital and structural heart diseases is accompanied by an increasing number of devices and technologies that require comprehensive and specialized training. Proctoring represents a cornerstone in the acquisition of state-of-the-art procedures, especially during the initial learning curve for a new structural intervention. Indeed, current consensus papers recommend the presence of a physician proctor for a certain number of procedures performed for the first time, for example, during the initial 3 to 5 implantations of a new patent foramen ovale (PFO) closure device.¹

Although successful use of web-based telecommunications for the purpose of remote proctoring has been reported by other procedure-orientated medical specialties,^{2,3} data on the feasibility and safety of teleproctoring in the context of interventional cardiology are scarce.

Since the outbreak of the COVID-19 pandemic, containment measures like travel restrictions and social distancing have been a great challenge for scientific and educational exchange including on-site proctoring. As the pandemic progressed, there has been an increasing interest in technical solutions that

Correspondence to: Niklas Beyhoff, MD, Department of Cardiology, Charité – Universitätsmedizin Berlin, Campus Benjamin Franklin, Hindenburgdamm 30, D-12203 Berlin, Germany. E-mail: niklas.beyhoff@charite.de

For Sources of Funding and Disclosures, see page 5.

© 2022 The Authors. Published on behalf of the American Heart Association, Inc., by Wiley. This is an open access article under the terms of the Creative Commons Attribution-NonCommercial-NoDerivs License, which permits use and distribution in any medium, provided the original work is properly cited, the use is non-commercial and no modifications or adaptations are made.

JAHA is available at: www.ahajournals.org/journal/jaha

may facilitate daily clinical practice despite these limitations.⁴ In a pioneering approach, Goel et al recently described their initial experience with teleproctoring for expert support in a case of intentional laceration of the anterior mitral valve leaflet to prevent left ventricular outflow obstruction during the pandemic.⁵

In this single-center experience from a large tertiary-care center, we report on the first patients with PFO and prior paradoxical embolic stroke treated with a novel PFO closure system under remote proctorship for training purposes. In addition, we provide an overview of current literature available on teleproctoring in interventional cardiology.

METHODS

All patients provided informed consent. This retrospective report was approved by the local ethics committee (EA4/013/21). The authors declare that all supporting data are available within the article.

PFO Closure Device

The NobleStitch™ EL system (HeartStitch, Fountain Valley, CA, USA) is a novel percutaneous approach, in which the septum primum and the septum secundum are approximated by 2 polypropylene sutures and a single polypropylene knot that are deployed via a dedicated delivery system.⁶ Initial registry data indicated effective PFO closure comparable to established occluder systems without any device-related complications.⁶ A corresponding prospective multicenter trial is currently being conducted (ClinicalTrials.gov; Identifier: NCT04339699).

Teleproctoring Setup

With regard to travel restrictions during the COVID-19 pandemic, the manufacturer offered to provide teleproctoring after the initial 3 cases were treated successfully under on-site proctorship at our institution. All procedures were performed together by 2 trained interventional cardiologists with extensive experience in other PFO closure systems (D. M. L. and M. R.). The proctor (A. N.) had experience with on-site proctoring for PFO for more than 12 years and already provided remote proctoring for the same procedure in 5 previous cases.

Before the first procedure under remote proctorship, both operators and the proctor carried out a briefing via video call reviewing the procedural steps and handling of the device system.

The setup, which was based on the proctor's experience in previous cases, as illustrated in Figure. The proctor was connected to the catheter laboratory via real-time bidirectional audiovisual communication using GoToMeetings (LogMeIn, Boston, MA, USA). The catheter laboratory's integrated screens for

fluoroscopy and echocardiography were shared via the same application. A portable camera with real-time 2-way audio communication was used to transmit live images and audio from the operating area according to the teleproctor's guidance. Additionally, there was a screen and speaker in the catheter laboratory allowing the operators to see and hear the proctor who had the PFO device on hand to provide visual feedback of the steps and real-time review of the necessary anatomical landmarks, allowing for detailed instruction. No personal identifiers of the patients were transmitted.

Literature Database Search

Electronic databases (MEDLINE, PubMed, The Cochrane Library, Web of Science) were searched from their earliest records to November 2021 for studies on teleproctoring/remote proctoring/telesupport in the field of interventional cardiology.

RESULTS

Patient characteristics, procedural details, and outcomes are reported in Table 1. Between August 7, 2020 and August 13, 2020, a total of 6 patients (4 men, mean age 45±13) were treated under remote proctorship. At baseline, all patients had a right-to-left shunt of grade 2 or 3 at rest or under Valsalva maneuver. Procedure length varied from 49 to 127 minutes, and the average radiation dose per patient was 35.5±15.8 Gy·cm² (radiation time 18±5 minutes). Five procedures were performed without sedation under fluoroscopic guidance, whereas additional transesophageal echocardiography under general anesthesia was used in 1 case with complex PFO morphology (2 defects). None of the patients had a residual right-to-left shunt of grade 1 or higher as assessed by contrast-enhanced transthoracic echocardiography after conducting the procedure. No major device/procedure-related adverse events occurred, and all patients were discharged on postoperative day 1 to 3. There was no need for major modifications of the teleproctoring setup during the procedures; minor acoustic problems were solved by using a headset instead of the built-in audio system. Both operators were able to apply the device autonomously after a total of 8 cases were implanted under remote proctorship (of which the first 6 are reported here, 2 others were performed after initial article submission).

The literature search identified 6 publications reporting on the use of teleproctoring for cardiac interventions (Table 2). All studies were either case reports or case series; no randomized control trials were found. Procedures comprised percutaneous coronary intervention,^{7,8} transcatheter aortic valve replacement,⁹ catheter ablations,^{7,10,11} and a single case of intentional laceration of the anterior mitral valve leaflet to prevent left ventricular outflow

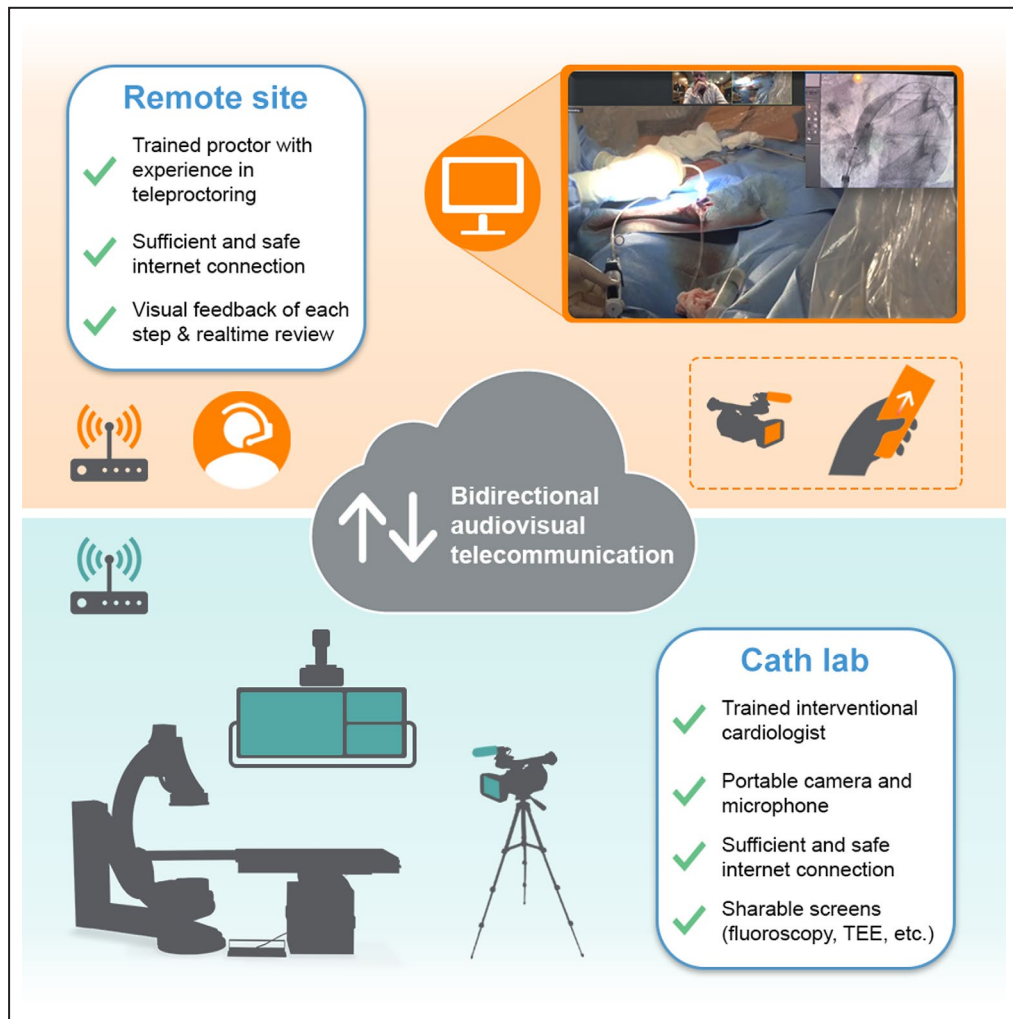

Figure. Illustration of used teleproctoring setup. TEE indicates transesophageal echocardiography.

obstruction.⁵ Bidirectional audiovisual telecommunication was used in all cases, whereas specialized equipment like smartglasses or dedicated hardware solutions was applied only occasionally. In all studies, at least 1 operator had experience in cardiovascular interventions related to the procedure. The first reported application of teleproctoring in interventional cardiology dates back to 2017, where a telesupport system for performing percutaneous coronary interventions and catheter ablations has been established in a remote region hospital in Japan.^{7,10} Since then, all other available publications (n=4) were related to the outbreak of the COVID-19 pandemic.

DISCUSSION

Here, we provide the first report on teleproctoring for training in a novel PFO occlusion system together with

a summary of current literature in other cardiac interventions. Our initial real-world experience indicates that remote proctoring may be feasible and safe, which supports previous studies using teleproctoring successfully for other procedures. Our proposed setup is in line with ones described in the literature and may be easily adapted by others. Therefore, it contributes to the establishment of teleproctoring as a new modality for training and expert support in cardiovascular interventions.

The COVID-19 pandemic with its long-lasting restrictions in daily clinical practice has accelerated the digital transformation in various health care areas including cardiology.¹² Although being used by other medical specialties for several years,^{2,3} teleproctoring represents an emerging technology in the context of cardiac interventions. Interestingly, all published reports were related to the ongoing pandemic except for the pioneering work from a Japanese group starting in 2017. Nevertheless, it appears likely that teleproctoring

Table 1. Patient Characteristics, Procedural Details, and Outcomes

Patient #	1	2	3	4	5	6
Age, y	58	55	56	36	39	26
Sex	Female	Male	Male	Male	Male	Female
Shunt grade before procedure	II	II	III	III	III	III
Procedural length, min:s	48:59	67:16	126:47	114:32	80:39	89:48
Contrast agent volume, mL	132	160	150	210	240	245
Transesophageal echocardiography	No	No	Yes	No	No	No
Radiation dose, Gy·cm ²	26.4	58.8	47.0	17.3	23.7	39.7
Radiation time, min	15	17	25	17	17	17
Shunt grade after procedure	—	—	I	—	—	—
Postprocedural days until discharge	2	1	3	1	2	2

will complement traditional on-site proctoring in the future beyond the current health care crisis in face of the many advantages like location-independent collaboration, cost-effectiveness, or expert consultation for specific interventions that are performed only at a limited number of centers. In addition, teleproctoring has the potential to provide access to training and expert support for hospital sites located in remote or less developed areas, as demonstrated before.^{3,7}

There are several pitfalls that should be acknowledged. In contrast to most surgical procedures, the majority of cardiovascular interventions are performed in conscious subjects. Therefore, we believe that careful and detailed patient information, avoidance of technical malfunction, and an appropriate communication during the audiovisual transmission are even more critical in interventional cardiology than in other fields of application. Indeed, all patients consistently gave positive feedback on enquiry after the procedure.

However, these aspects, together with various technical and legal issues, should be considered before the implementation of teleproctoring (as summarized in detail by Orrú et al¹³). Lastly, teleproctoring depends on a fast, stable, and safe internet connection as well as distinct technical equipment, which slightly limits its broad application. Consensus recommendations regarding best clinical practice and standardization in remote proctorship are warranted with its increasing application.

Limitations

As for any case series, our real-world experience should be considered hypothesis generating, and future trials are needed to assess the value of teleproctoring in a randomized controlled setting. Because all procedures were performed together by 2 operators, individual learning curves were not assessable in this report. In addition, both operators had extensive

Table 2. Reports on Teleproctoring in the Field of Interventional Cardiology

Study	Area	Teleproctoring setup	Setting	Related to COVID-19 pandemic
Adachi et al 2020 ⁷	Coronary intervention/ electrophysiology	Audiovisual telecommunication, shared screens	21 patients undergoing PCI and 9 patients undergoing catheter ablation	No
Shinoda et al 2020 ¹⁰	Electrophysiology	Bidirectional audiovisual telecommunication, shared screens	19 patients undergoing radiofrequency catheter ablation for different types of tachyarrhythmia (same hospital as in ⁷)	No
Goel et al 2020 ⁵	Structural intervention	Specialized robot, bidirectional audiovisual telecommunication	1 patient with transcatheter mitral valve intervention (intentional laceration of the anterior mitral valve leaflet to prevent left ventricular outflow obstruction)	Yes
Glowniak et al 2021 ¹¹	Electrophysiology	Bidirectional audiovisual telecommunication, shared screens	3 patients undergoing cryoballoon ablation for atrial fibrillation	Yes
Wojtek et al 2021 ⁸	Coronary intervention	Specialized remote proctoring system, shared screens, bidirectional audio telecommunication	6 patients with acute coronary syndrome or cardiac decompensation undergoing high-risk PCI with mechanical circulatory support	Yes
Arslan et al 2021 ⁹	Structural intervention	Smartglasses with integrated visor projector and 2 cameras, bidirectional audio telecommunication	2 patients undergoing complex transcatheter aortic valve replacement	Yes

PCI indicates percutaneous coronary intervention.

experience in various cardiovascular interventions including different PFO closure device systems. Hence, the role of teleproctoring for training of novice operators remains to be established.

CONCLUSIONS

Teleproctoring may represent a feasible and safe tool for location-independent and cost-effective training in a novel PFO closure device system. Future prospective trials comparing teleproctoring with traditional on-site proctoring are warranted.

ARTICLE INFORMATION

Affiliations

Department of Cardiology, Campus Benjamin Franklin, Charité – Universitätsmedizin Berlin, corporate member of Freie Universität Berlin and Humboldt-Universität zu Berlin, Berlin, Germany (N.B., M.Z., L.Z., D.M.L., F.B., U.L., M.R.); German Centre for Cardiovascular Research (DZHK), partner site Berlin, Berlin, Germany (N.B., L.Z., D.M.L., U.L.); Berlin Institute of Health at Charité – Universitätsmedizin Berlin, Berlin, Germany (N.B., U.L.); School of Biomedical Engineering, Westsächsische Hochschule, Zwickau, Germany (A.N.); and Institute of Biomaterial Science, Helmholtz-Zentrum Geesthacht, Teltow, Germany (M.S., M.R.).

Sources of Funding

Niklas Beyhoff is a participant in the BIH-Charité Junior Clinician Scientist Program funded by the Charité - Universitätsmedizin Berlin and the Berlin Institute of Health.

Disclosures

Anthony Nobels is the chief executive officer and Chief Clinical Proctor for HeartStitch, Inc. and Nobles Medical Technologies II, Inc. The remaining authors have no disclosures to report.

REFERENCES

- Horlick E, Kavinsky CJ, Amin Z, Boudoulas KD, Carroll JD, Hijazi ZM, Leifer D, Lutsep HL, Rhodes JF, Tobis JM. SCAI expert consensus statement on operator and institutional requirements for PFO closure for secondary prevention of paradoxical embolic stroke: the American Academy of Neurology affirms the value of this statement as an educational tool for neurologists. *Catheter Cardiovasc Interv.* 2019;93:859–874. doi: 10.1002/ccd.28111
- Smith CD, Skandalakis JE. Remote presence proctoring by using a wireless remote-control videoconferencing system. *Surg Innov.* 2005;12:139–143. doi: 10.1177/155335060501200212
- Huang EY, Knight S, Guetter CR, Davis CH, Moller M, Slama E, Crandall M. Telemedicine and telementoring in the surgical specialties: a narrative review. *Am J Surg.* 2019;218:760–766. doi: 10.1016/j.amjsurg.2019.07.018
- Hollander JE, Carr BG. Virtually perfect? Telemedicine for Covid-19. *N Engl J Med.* 2020;382:1679–1681. doi: 10.1056/NEJMp2003539
- Goel SS, Greenbaum AB, Patel A, Little SH, Parikh R, Wyler von Ballmoos MC, Lumsden AB, Reardon MJ, Kleiman NS. Role of teleproctoring in challenging and innovative structural interventions amid the COVID-19 pandemic and beyond. *JACC Cardiovasc Interv.* 2020;13:1945–1948. doi: 10.1016/j.jcin.2020.04.013
- Gaspardone A, De Marco F, Sgueglia GA, De Santis A, Iamele M, D'Ascoli E, Tusa M, Corciua A, Mullen M, Nobles A, et al. Novel percutaneous suture-mediated patent foramen ovale closure technique: early results of the NobleStitch EL Italian Registry. *EuroIntervention.* 2018;14:e272–e279. doi: 10.4244/EIJ-D-18-00023
- Adachi T, Sato A, Kuroki K, Terai T, Hanaoka D, Hiraya D, Machino T, Nogami A, Ieda M, Aonuma K. Audiovisual telesupport system for cardiovascular catheter interventions: a preliminary report on the clinical implications. *Catheter Cardiovasc Interv.* 2020;95:906–910. doi: 10.1002/ccd.28421
- Woitek FJ, Haussig S, Mierke J, Linke A, Mangner N. Remote proctoring for high-risk coronary interventions with mechanical circulatory support during COVID-19 pandemic and beyond. *Clin Res Cardiol.* 2021;110:1525–1530. doi: 10.1007/s00392-021-01890-3
- Arslan F, Gerckens U. Virtual support for remote proctoring in TAVR during COVID-19. *Catheter Cardiovasc Interv.* 2021;98:E733–E736. doi: 10.1002/ccd.29504
- Shinoda Y, Sato A, Adach T, Nishi I, Nogami A, Aonuma K, Ieda M. Early clinical experience of radiofrequency catheter ablation using an audiovisual telesupport system. *Heart Rhythm.* 2020;17:870–875. doi: 10.1016/j.hrthm.2020.01.018
- Glowniak A, Petkanych M, Wojewoda K, Komiataj V, Sudol M, Dyomenko O, Torres K, Wysokinski A, Sorgente A, Chierchia G-B, et al. Remote proctoring for cryoballoon ablation of atrial fibrillation: a challenge or an opportunity in the COVID-19 era? *Cardiol J.* 2021;28:970–972. doi: 10.5603/CJ.a2021.0100
- Wahadat AR, Sadeghi AH, Tanis W. Heart Team meetings during COVID-19. *Eur Heart J.* 2020;41:1872–1874. doi: 10.1093/eurheartj/ehaa412
- Orru' E, Marosfoi M, Patel NV, Coon AL, Wald C, Repucci N, Nicholson P, Pereira VM, Wakhloo AK. International teleproctoring in neurointerventional surgery and its potential impact on clinical trials in the era of COVID-19: legal and technical considerations. *J Neurointerv Surg.* 2021;13:1022–1026. doi: 10.1136/neurintsurg-2020-017053