

ORIGINAL ARTICLE

Diagnosis and outcome following tenoscopic surgery of the digital flexor tendon sheath in German sports and pleasure horses

Andrea N. Cender  | Kathrin Mählmann | Anna Ehrle  | Roswita Merle |
Laura Pieper | Christoph J. Lischer

Equine Clinic at the Faculty of Veterinary Medicine, Free University of Berlin, Berlin, Germany

Correspondence

Andrea N. Cender, Equine Clinic at the Faculty of Veterinary Medicine, Free University of Berlin, Oertzenweg 19b, 14163 Berlin, Germany.
Email: andeanogcen@hotmail.com

Abstract

Background: Digital flexor tendon sheath (DFTS) pathology is an important cause of lameness in horses. The outcome after surgical treatment is variable and depends on the exact diagnosis.

Objectives: To (1) describe the prevalence of lesions associated with lameness caused by nonseptic DFTS tenosynovitis in a large population of German sports and pleasure horses; (2) determine the sensitivity and specificity of diagnostic imaging techniques for identifying lesions within the DFTS with tenoscopic diagnosis being the gold standard; (3) explore associations between tenoscopically diagnosed lesions and signalment, purpose, and limb affected; and (4) describe the outcome following DFTS tenoscopy with nonseptic DFTS tenosynovitis in this population.

Study design: Retrospective case series.

Methods: Medical records of horses admitted for tenoscopic surgery of nonseptic DFTS tenosynovitis between 2011 and 2020 were reviewed. Follow-up information was obtained via telephone contact. Sensitivity and specificity of ultrasonography and contrast tenography were determined using tenoscopic diagnosis as gold standard and univariable analysis was used to explore associations between signalment, case history, and tenoscopic diagnosis.

Results: Medical records from 131 horses were retrieved, of which 8 horses had bilateral disease and 6 horses were presented for tenoscopy on two separate occasions (3 for tenoscopy in the same limb, 3 in a different limb), thus, making a total of 145 limbs. Lesions were most commonly diagnosed in the deep (DDFT; $n = 55$ limbs) and superficial (SDFT; $n = 55$ limbs) digital flexor tendons. Manica flexoria (MF) lesions were detected in 44 limbs and palmar/plantar annular ligament (PAL) constriction in 99 limbs. In 36 limbs, only one structure within the DFTS was injured, whereas in 109 limbs a combination of lesions was noted, the most common being the combination of a SDFT lesion with PAL constriction. All affected limbs were

This is an open access article under the terms of the [Creative Commons Attribution-NonCommercial-NoDerivs](https://creativecommons.org/licenses/by-nc-nd/4.0/) License, which permits use and distribution in any medium, provided the original work is properly cited, the use is non-commercial and no modifications or adaptations are made.

© 2022 The Authors. *Equine Veterinary Journal* published by John Wiley & Sons Ltd on behalf of EVJ Ltd.

examined with diagnostic ultrasonography; contrast tenography was performed in 86 limbs. For diagnosis of MF and DDFT tears, tenography was more sensitive (89% [confidence interval, CI: 65.4%–95.2%]; 72% [CI: 46.4%–89.3%], respectively) than specific (64% [CI: 52.5%–77.6%]; 53% [CI: 42.2%–73.3%], respectively) whereas ultrasonography was more specific (92% [CI: 84.5%–96.3%]; 92% [CI: 83.6%–96.0%]) with lower sensitivity (64% [CI: 47.7%–77.2%]; 54% [CI: 39.5%–67.9%]). For SDFT lesions, ultrasonography was highly specific (94% [CI: 86.9%–97.9%]) with lower sensitivity (66% [CI: 51.3%–77.4%]). Follow-up information following first surgery was obtained for 118 horses (132 limbs): 18 (15.3%) of 118 horses remained chronically lame, 40 (33.8%) performed at a reduced level and 60 (50.8%) performed at the same or higher level following rehabilitation after tenoscopy. Horses with DDFT lesions had the poorest outcomes with only 36.6% returning to the same or higher level of exercise.

Main limitations: Retrospective analysis of clinical records and subjective outcome assessment based on owner follow-up with potential recall bias. Findings on diagnostic imaging are impacted by many factors including equipment quality and operator expertise and experience.

Conclusion: Diagnostic imaging techniques were complimentary and contrast tenography was sensitive and ultrasonography was specific for the diagnosis of MF and DDFT lesions. Following tenoscopic surgery for nonseptic tenosynovitis of the DFTS, approximately half the cases were able to return to preinjury level of exercise.

KEYWORDS

horse, lameness, tendon, tendon sheath, tenoscopy, ultrasonography

1 | INTRODUCTION

The digital flexor tendon sheath (DFTS) extends from the middle third of the second phalanx to a level approximately 4–7 cm proximal to the proximal sesamoid bones.¹ The two main structures confined within the DFTS are the superficial digital flexor tendon (SDFT) and the deep digital flexor tendon (DDFT). The DDFT is surrounded by the manica flexoria (MF), a collar of tendinous tissue that is attached to the SDFT and wraps around the DDFT proximal to the metacarpal/metatarsophalangeal joint.^{2–4} The palmar/plantar annular ligament (PAL) forms the wall of the DFTS as it attaches to the abaxial surface of the proximal sesamoid bones.²

Nonseptic tenosynovitis of the DFTS may be associated with DDFT^{3,5,6} and SDFT⁷ tendonitis, MF tears^{4,5,8,9} and PAL^{2,10,11} desmitis. With a reported prevalence of 59% and 30%, respectively, DDFT and MF lesions are the most common causes of nonseptic DFTS tenosynovitis in the horse.⁵ MF tears are frequently diagnosed in hindlimbs with a greater incidence found in Cobs and ponies compared with other breeds.^{8,9} DDFT lesions have been detected in forelimbs more often than hindlimbs.^{3,5}

The initial diagnosis of DFTS pathology is often based on diagnostic analgesia followed by ultrasonographic examination and contrast radiography of the DFTS. Ultrasonography has limited accuracy for

the diagnosis of intrasynovial tendinous lesions, with a particularly low sensitivity and specificity reported for the detection of MF and DDFT tears.^{5,6} Contrast tenography offers added diagnostic value, especially for the detection of MF tears where a sensitivity as high as 96% and a specificity of up to 80% have been reported.^{8,9} Magnetic resonance imaging is useful for the diagnosis of marginal tears of the SDFT or DDFT, and PAL desmitis, and proximal or distal digital annular desmitis.^{12,13} Ultimately, tenoscopic examination of the DFTS under general anaesthesia appears to be the most reliable technique to confirm the presence of marginal tendon lesions associated with nonseptic DFTS tenosynovitis and tenoscopy also facilitates immediate treatment of lesions detected during the surgical procedure.^{3,5}

The prognosis for horses with nonseptic DFTS tenosynovitis following DFTS tenoscopy may be variable and depends on the affected structure and lesion severity. In general, tenoscopic removal of the MF is associated with a better prognosis when compared with longitudinal tears of the DDFT.^{3–6} However, the predisposition of certain breeds to, and limbs affected by specific lesions, as well as lesions occurring singularly or in combination, may influence the prognosis.

There are a limited number of studies evaluating the diagnosis and outcome following DFTS tenoscopy with nonseptic DFTS tenosynovitis. Our objectives were to (1) describe the prevalence of lesions associated with lameness caused by nonseptic DFTS

tenosynovitis in a large population of German horses, (2) determine the sensitivity and specificity of diagnostic imaging techniques for identifying lesions within the DFTS with tenoscopic diagnosis being the gold standard, (3) explore associations between tenoscopically diagnosed lesions and signalment, purpose and limb affected and (4) report the outcome following DFTS tenoscopy with nonseptic DFTS tenosynovitis in this population.

2 | MATERIALS AND METHODS

2.1 | Study population and clinical examination

Medical records were searched to identify surgeries in which DFTS tenoscopy was performed at the equine clinic between November 2011 and March 2020. All lesions diagnosed tenoscopically were noted and categorised as affecting DDFT, SDFT, MF and/or PAL. Before tenoscopy, pain had been localised to the distal limb using diagnostic analgesia: low 4-point block in forelimbs, low 6-point block in hindlimbs or intrasynovial DFTS anaesthesia. Horses undergoing tenoscopy for septic or contaminated DFTS tenosynovitis were excluded.

The following data were collected: sex (categorised as mare, gelding, stallion), age (range and median in years), breed (categorised as Warmblood, pony, Cob-type, Standardbred and other) and purpose (categorised as showjumping, dressage, pleasure riding and other). The duration of lameness (months) and previous treatment was recorded. Clinical findings before each tenoscopy were described as the presence of DFTS effusion (categorised as mild-moderate or severe), any other swelling, degree of lameness using the AAEP grading system and response to diagnostic analgesia.

2.2 | Diagnostic imaging techniques

Preoperative diagnostic imaging included radiography, contrast radiography, and ultrasonography. All images were examined and classified by one clinician (A.N.C.). Four standard radiographic views (lateromedial, dorsopalmar/dorsoplantar, dorsolateral-palmaro/plantaromedial oblique and palmaro/plantarolateral-dorsomedial oblique) were obtained to identify concurrent osseous abnormalities. For contrast tenography, mepivacaine hydrochloride (5–8 ml; Scandicain; AstraZeneca GmbH) mixed with iopamidol contrast solution (5–8 ml; Solustrast 300; Bracco Imaging Deutschland GmbH) was injected into the affected DFTS using a standard approach at the axial margin of the lateral sesamoid bone.^{1,14} Radiographic findings were recorded and contrast tenograms were evaluated based on previous descriptions.^{8,9} Briefly, contrast accumulation dorsal to the DDFT at the level of the MF and/or the presence of one instead of two radiopaque lines at the level of the MF and/or the dorsal of the two parallel lines not extending distally to meet the proximal border of the proximal sesamoid bones was indicative of a MF tear. Longitudinal DDFT tears were suspected if a longitudinally oriented accumulation of contrast

was present within the outline of the DDFT, at the level of or distal to the proximal sesamoid bones.

Ultrasonographic images were obtained using a 7.5 or 10 MHz linear transducer (Esaote MyLab Five VET or TOSHIBA Aplio500). The presence of DFTS effusion, lesions of the DDFT, SDFT, MF and PAL were recorded. The ultrasonographic changes that were considered indicative for a lesion of the DDFT or SDFT included an irregular surface and intratendinous hypoechoic areas, reduced linear echo alignment and extra-tendinous hyperechoic material associated with the tendon. MF tears were suspected if it was not possible to identify the MF borders ultrasonographically; if the borders of the SDFT were irregular at the level of the MF or if there was hyperechoic material associated with the MF margins. PAL desmitis was defined as thickening of the PAL >2 mm.

2.3 | Tenoscopy

Tenoscopy was performed by one of five ECVS board certified equine surgeons. Horses were anaesthetised and placed in lateral recumbency with the affected limb positioned upper- or lowermost, depending on the localisation of the suspected lesion. Following aseptic preparation, the DFTS was distended by injection of sterile polyionic isotonic fluids (lactated Ringer's solution; Braun GmbH) and a stab incision using an #11 blade was made into the distended lateral or medial pouch of the DFTS between the PAL and proximal digital annular ligament to introduce a 4 mm 30° forward oblique endoscope (Karl Storz Veterinary Endoscopy).¹⁵ An instrument portal was created in the ipsilateral proximal pouch of the DFTS under arthroscopic guidance and a hook probe was introduced to palpate the different structures within the DFTS. An Esmarch bandage was only applied in surgeries where excessive bleeding was present during surgery.

Tenoscopic findings and surgical treatment were recorded based on the surgery report and endoscopic images were reviewed by the one clinician (A.N.C.) who classified tendon lesions subjectively as mild, moderate or severe, depending on the amount of tendon fibrillation, size (<2, 2–7 and >7 cm) and depth (<2, 2–5, >5 mm) of the lesion. The hook probe was used as reference to measure the size and depth of the lesions. MF pathology was categorised as mild (localised fibrillation), moderate (focal tear) or severe (complete rupture of the MF border from its attachment on the SDFT) (Figure 1). PAL constriction was diagnosed in those surgeries where the surgeon had difficulty manoeuvring the tenoscope inside the fetlock canal due to insufficient space.

Tendon lesions such as fibrillation or granulomas were debrided either with motorised synovial resectors (Shaver System Unidrive SIII Arthro SCB; Karl Storz Veterinary Endoscopy) (Figure 2) or manually using an arthroscopic suction punch. Arthroscopic rongeurs were also used to remove loose tendon fibres or to break down adhesions between the DFTS and the flexor tendons.

MF lesions classified as mild to moderate were locally trimmed with the arthroscopic punch whereas severe lesions were managed with total MF resection. Resection was accomplished by using a hook

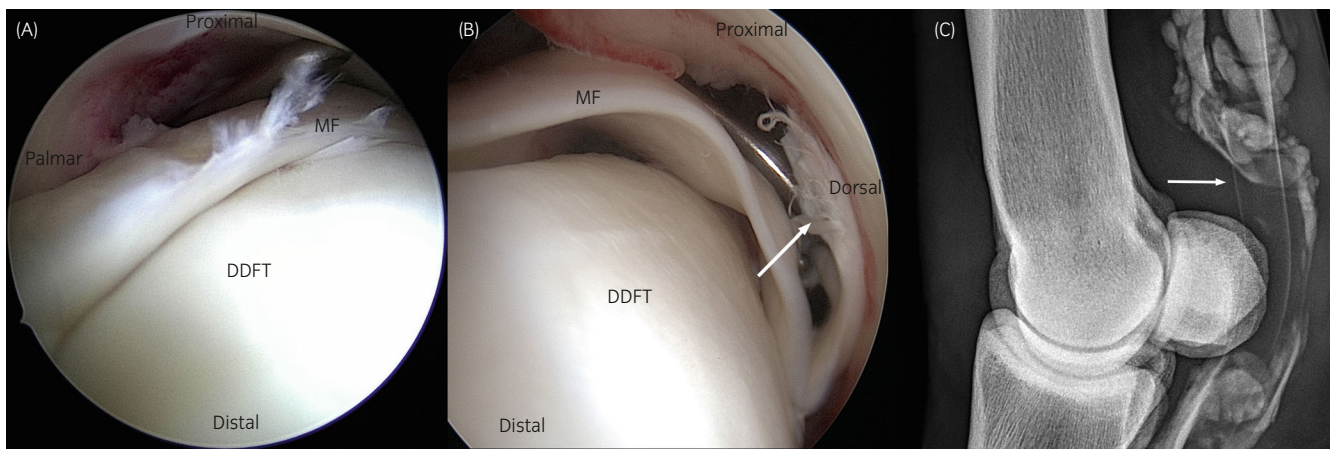


FIGURE 1 (A) Tenoscopic view of the digital flexor tendon sheath (DFTS); the telescope is inserted at the level of the base of the lateral proximal sesamoid bone and directed to the proximal pouch of the tendon sheath. View of a minor fibrillation seen at the distal margin of the manica flexoria (MF); this lesion was classified as mild. (B) Tenoscopic view of a case with complete rupture of the MF, categorised as severe. Note the complete separation of the MF (arrow) from its medial attachment. DDFT, deep digital flexor tendon. (C) Contrast tenogram of the DFTS corresponding with the case shown above with a rupture of the MF. Note the manica flexoria is not present (only one line, instead of two, at the level of the MF proximal to the proximal sesamoid bones) (arrow)

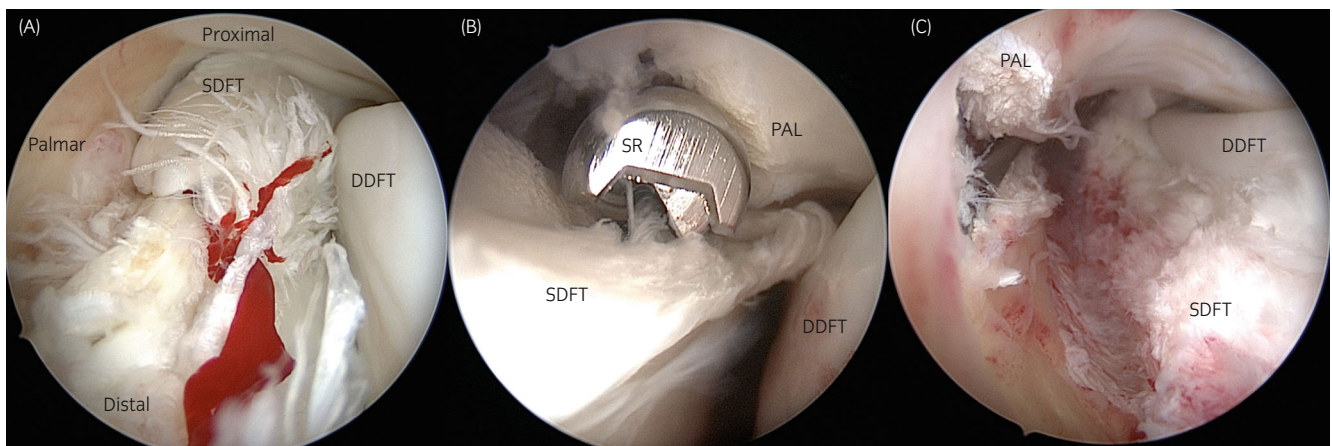


FIGURE 2 (A) Tenoscopic view of a severe longitudinal tear at the lateral margin of the superficial digital flexor tendon (SDFT) distal to the level of the manica flexoria. The telescope is inserted at the level of the base of the lateral proximal sesamoid bone and directed to proximal. Torn tendon fibres can be seen protruding into the lumen of the digital flexor tendon sheath. (B) Motorised synovial resector (SR) was introduced via an ipsilateral proximal instrument portal for debridement of the torn tendon fibres. Transection of the palmar annular ligament (PAL) was additionally performed. (C) Tenoscopic view of the same SDFT lesion after debridement. DDFT, palmar border of the deep digital flexor tendon

knife in combination with arthroscopic scissors and/or an arthroscopic micro scalpel, as described previously.¹⁶ If judged necessary by the surgeon depending on the surgical findings, desmotomy of the PAL was performed under endoscopic guidance using a hook knife in a distoproximal direction.

Flunixin meglumine (Flunisolil; 1.1 mg/kg bwt. p.o.; CP-Pharma Handelsoges mbH) was administered perioperatively; one dose before surgery and once daily for 2–5 days after surgery, depending on the level of comfort on the operated limb. Bandaging was maintained for 2 weeks after tenoscopy. Horses remained on box rest for 3 weeks, followed by 2 months of hand walking and/or paddock turnout. Horses were reassessed 10 to 12 weeks after tenoscopy. Variable rehabilitation was individually adjusted based on the severity of the

original lesion as well as clinical progress and ultrasonographic findings during repeated evaluation.

2.4 | Outcome

Follow-up information was obtained from case records and a structured telephone conversation with the owner (Supporting Information Item S1). The first 6 months after tenoscopy were regarded as short-term follow-up. Long-term follow-up was defined as the period of time following 6 months after tenoscopy. Information about postoperative complications, period of convalescence, and current performance level of the horse was recorded. Outcome was described but

not formally analysed statistically. The pre- and post-operative performance was compared by the owner and outcome categories were defined as retired due to chronic lameness; returned to exercise at a lower level or returned to exercise at the same or higher level. Horses were considered lost to follow-up when the owner could not be reached after four attempts. Horses that were euthanised due to DFTS pathology were added to the 'chronic lame' outcome group. Where horses were euthanised for reasons unrelated to DFTS pathology, they were considered to be lost to follow-up. For horses which underwent bilateral tenoscopy during the same anaesthesia, for description of the impact of lesion on outcome, lesions were categorised on the basis of the most severely affected limb. The outcome of each horse was described once regardless of whether tenoscopy was performed unilaterally or bilaterally (i.e., using horse as unit for description not limb). Where horses underwent repeated tenoscopy during a later anaesthesia, these individuals were assigned to one of the three outcome groups based on their status immediately before the repeat procedure.

2.5 | Data analysis

Data were analysed using SPSS Version 25 Software (IBM SPSS Statistics for Windows; IBM Corp.). The tenoscopically diagnosed lesions of the DDFT, SDFT, MF and PAL were each dichotomised into affected and not affected. The sensitivity and specificity with 95% confidence intervals of ultrasonography and contrast tenoscopy for lesion detection (MF and DDFT both imaging techniques; SDFT

ultrasonography only) were calculated using the tenoscopic diagnosis as the gold standard. Lesion was used as unit of analysis regardless of whether it was identified unilaterally, bilaterally or before a repeated tenoscopy.

Chi-square, Fishers exact and Wilcoxon rank sum tests were performed for each tenoscopically diagnosed lesion category to examine associations between each lesion category and age, sex, breed, purpose and affected limb (fore- vs. hindlimb). For this analysis, lesion category was dichotomised into affected and not affected. Breeds were also dichotomised, for example, pony breed or nonpony breed and Cob-type or non-Cob-type. Continuous data are presented as range and median and categorical data as percentages. The unit of analysis for determining the association between signalment, use, and fore versus hindlimb was the lesion regardless of whether it was identified unilaterally, bilaterally or before a repeated tenoscopy.

3 | RESULTS

3.1 | Study population and clinical examination

In total 131 horses with nonseptic DFTS tenosynovitis underwent 145 surgeries (Figure 3). In eight horses bilateral tenoscopy was performed during the same anaesthesia (i.e., accounting for 16 limbs). Six horses underwent DFTS tenoscopy on two separate occasions due to persistence or recurrence of lameness (12 limbs). In three of these horses, repeated tenoscopy was performed on a different limb 14, 16 and 18 months after the initial tenoscopy. In three horses,

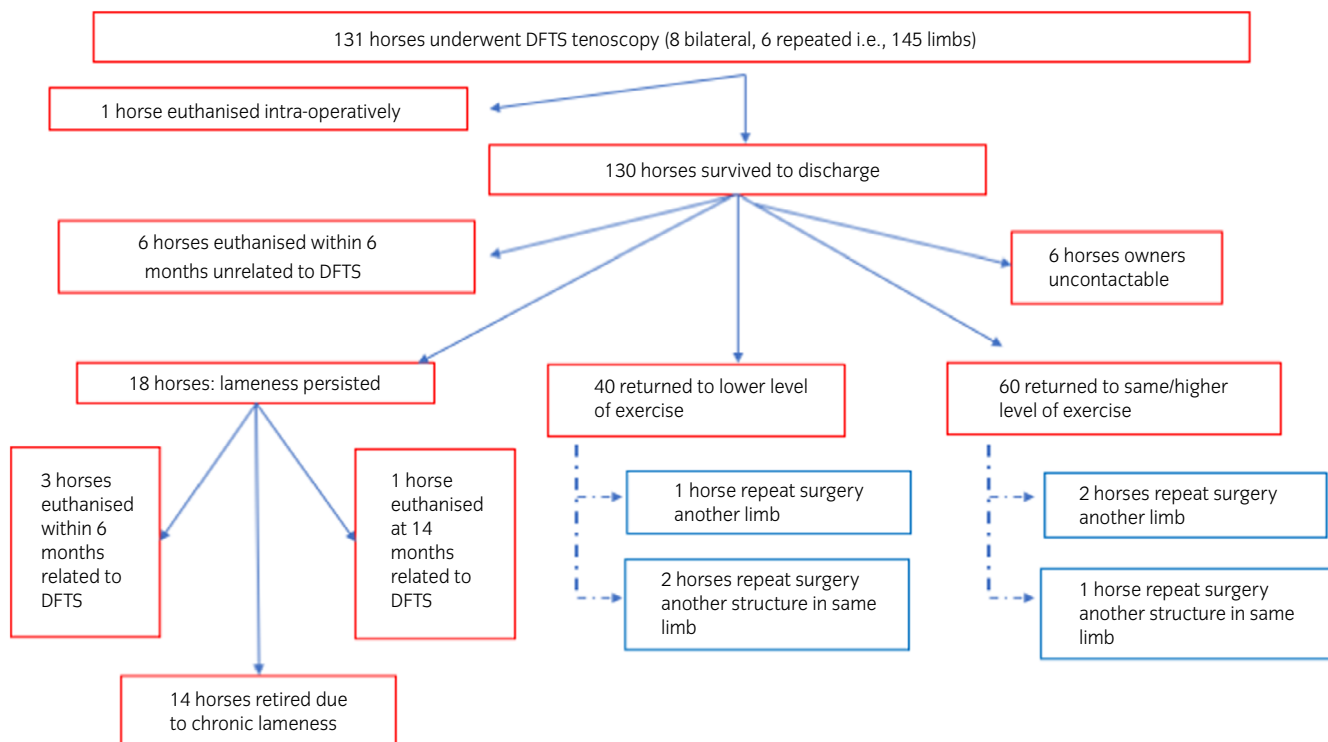


FIGURE 3 Flow chart illustrating case inclusion, follow-up and outcome after tenoscopy

repeated tenoscopy was performed on the same limb 17, 20 and 24 months after the initial tenoscopy. In these three horses, injury to a different structure was identified at the second surgery.

The cases included 75 mares, 53 geldings and 3 stallions aged 1–23 years (median age: 13.2 years). Breeds consisted of 61 Warmbloods, 28 ponies, 17 Cob-type horses (Welsh Cob, Haflinger, Tinker and Norwegian horses), 4 Standardbreds and 21 horses categorised as ‘other’ including American Quarter Horse, Appaloosa, Paint Horse, Pura Raza Española, Arabian and Draught horse breeds. Horses were used for the following purposes: showjumping ($n = 16$), dressage ($n = 33$), pleasure riding ($n = 70$) and other purposes ($n = 12$).

The duration of lameness before tenoscopy ranged from 1 to 24 months with a median of 4 months. In 33 horses it was less than 4 weeks, in 76 horses 5–16 weeks, in 11 horses 17–48 weeks and this information was not available for 11 horses. Rest and systemic administration of nonsteroidal anti-inflammatory drugs was the most common treatment horses had received before hospital admission (82 horses); 12 horses had intrasynovial medication with steroids alone or in combination with hyaluronic acid; 3 horses had previous surgery of the affected limb (extrasynovial PAL desmotomy performed at another clinic), 22 horses had not received any previous treatment and for 12 horses this information was not available.

On clinical examination, distension of the DFTS was identified in 103 limbs before tenoscopy, varying from mild–moderate (53 limbs) to severe (50 limbs). Before tenoscopy, there was a diffuse swelling at the level of the palmar/plantar fetlock in 28 limbs; the remaining limbs undergoing tenoscopy did not show any obvious abnormalities. All horses were lame at admission or had a history of lameness, with a median grade of 2/5, range 1/5–4/5. Lameness improved or resolved in all horses following a low 4-point or 6-point block or intrasynovial analgesia of the DFTS.

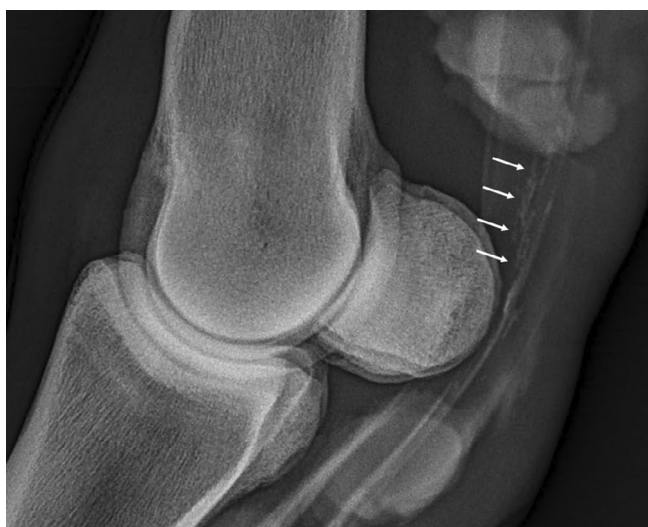

FIGURE 4 Contrast radiography of the digital flexor tendon sheath of a horse with a longitudinal tear at the deep digital flexor tendon (DDFT). See the linear contrast accumulation within the outline of the DDFT (arrows)

3.2 | Diagnostic imaging

Radiographs of the fetlock area were available for 127 limbs. Bone remodelling and irregular new bone formation at the palmar/plantar aspect of the proximal sesamoid bones was detected in 28 limbs. Other findings including bone remodelling at the palmar/plantar aspect of the first or second phalanx or a longitudinal radiopacity palmar/plantar to the metacarpo/metatarsophalangeal joint corresponding with calcification of the soft tissues in 28 limbs. There were no radiographic abnormalities found in 71 limbs.

Preoperative contrast DFTS tenography was performed in 86 limbs. The MF appeared to be intact in 50 limbs whereas 3 limbs had abnormal orientation of the MF and 33 limbs had one radiopaque line delineating the MF instead of two.^{8,9} In seven limbs, linear contrast accumulation was found within the outline of the DDFT which was considered indicative of a DDFT tendinitis (Figure 4). The sensitivity of contrast tenography for detection of MF tears was of 89% (confidence interval [CI]: 65.4%–95.2%) with specificity of 64% (CI: 52.5%–77.6%) and its sensitivity for diagnosis of DDFT tears was 72% (CI: 46.4%–89.3%) with specificity of 53% (CI: 42.2%–73.3%).

The ultrasonographic findings are listed in Figure 5 and included DDFT lesions (35 limbs), SDFT lesions (41 limbs), MF lesions (36 limbs), PAL desmitis (99 limbs) and distension of the DFTS (119 limbs). For the diagnosis of MF tears, ultrasonography had a sensitivity of 64% (CI: 47.7%–77.2%) and a specificity of 92% (CI: 84.5%–96.3%). For the diagnosis of DDFT lesions, ultrasonography had a sensitivity of 54% (CI: 39.5%–67.9%) and a specificity of 92% (CI: 83.6%–96.0%). For the detection of SDFT lesions, ultrasonography had a sensitivity of 66% (CI: 51.3%–77.4%) and specificity of 94% (CI: 86.9%–97.9%). PAL desmitis

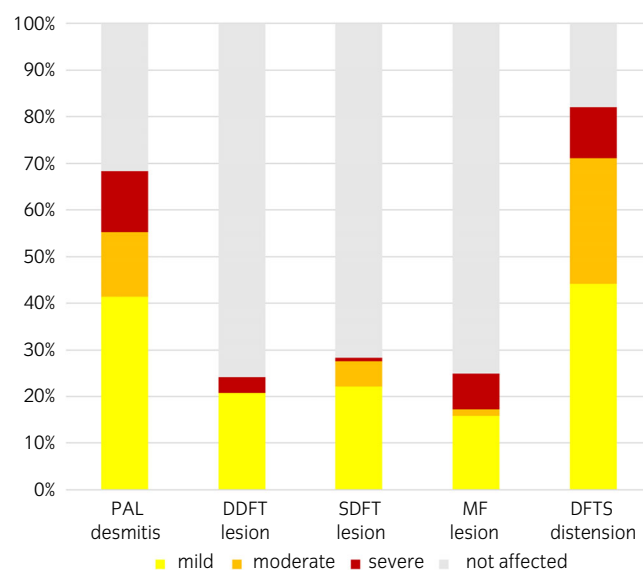


FIGURE 5 Distribution of the different digital flexor tendon sheath (DFTS) pathologies as detected during preoperative ultrasonographic examination. Lesions of the deep digital flexor tendon (DDFT); superficial digital flexor tendon (SDFT); manica flexoria (MF) and palmar/plantar annular ligament (PAL) are listed as percentage of the total number of affected limbs

was seen alone or in combination with subcutaneous fibrosis and/or poor definition of the palmar/plantar SDFT margin (Figure 6).

3.3 | Tenoscopy

Tenoscopy was performed on 47 forelimbs and 98 hindlimbs. Tenoscopic findings are summarised in Table 1. In 36 of 145 limbs, only one structure within the DFTS was injured. In 109 of 145 limbs, a combination of lesions was noted (Figure 7), with the most common

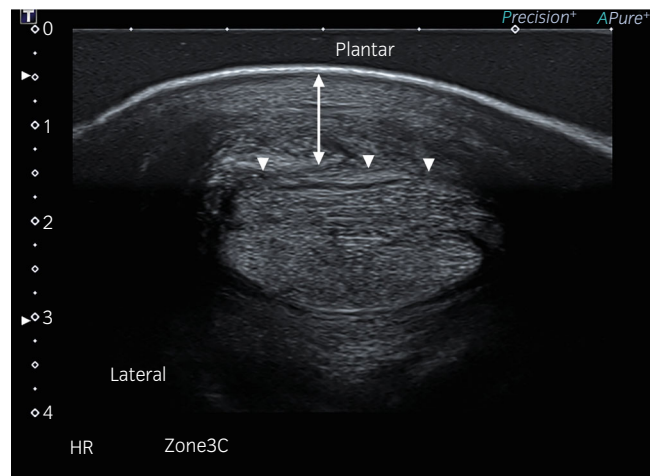


FIGURE 6 Transverse ultrasonographic image of the digital flexor tendons at the level of the plantar annular ligament (PAL). Note the thickening of the subcutaneous tissue (arrow) and poor definition of the PAL and the plantar margin of the superficial digital flexor tendon (arrowheads)

being the combination of a SDFT lesion with constriction of the PAL, found in 38 limbs. Most SDFT lesions were characterised by superficial fibrillation or a rough, hyperaemic palmar/plantar tendon surface at the level of the PAL (Figure 8). DDFT lesions mostly consisted of longitudinal tears at the tendon border (Figure 9).

The tenoscopic diagnosis did not appear to be biased by the horses' sex or discipline, however, statistically significant association between the horses' age, breed and affected limb were identified for several lesion types. Hindlimbs were less likely to be affected by a DDFT lesion compared with forelimbs ($p < 0.001$, odds ratio [OR]: 0.26, CI: 0.125–0.547; Table 1). SDFT lesions were seen significantly more frequently in Cob-type horses when compared with non-Cob-type horses ($p = 0.004$, OR = 5.530, CI: 1.568–19.500). MF lesions occurred more often in hindlimbs in this study population ($p = 0.04$,

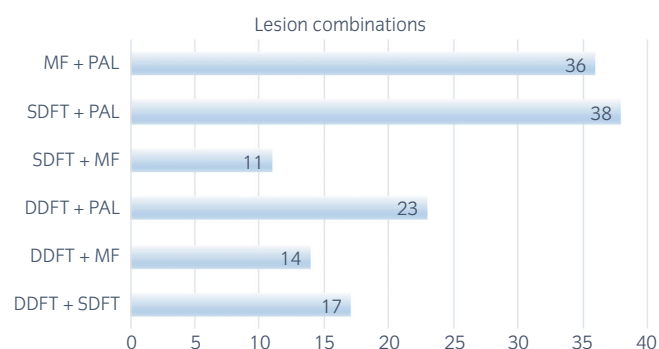


FIGURE 7 Bar graph showing combinations of lesions of the deep digital flexor tendon (DDFT), superficial digital flexor tendon (SDFT), manica flexoria (MF) and palmar/plantar annular ligament (PAL) as detected during tenoscopic surgery of the digital flexor tendon sheath in 145 limbs

	DDFT lesion	SDFT lesion	MF lesion	PAL constriction
All limbs lesion present (%)	55 (38%)	55 (38%)	44 (30%)	99 (68%)
Mild	23 (16%)	23 (16%)	11 (8%)	48 (33%)
Moderate	18 (12%)	18 (12%)	7 (5%)	38 (26%)
Severe	14 (10%)	14 (10%)	26 (18%)	13 (9%)
All limbs lesion not present (%)	90 (62%)	90 (62%)	101 (70%)	46 (32%)
Total limbs	145	145	145	145
Forelimbs lesion present (%)	26 (55%)	21 (45%)	9 (19%)	26 (55%)
Forelimb lesion not present	21 (45%)	26 (55%)	38 (81%)	21 (45%)
Total forelimbs	47	47	47	47
Hindlimbs lesion present (%)	24 (24%)	34 (35%)	35 (36%)	73 (75%)
Hindlimbs lesion not present	74 (76%)	64 (65%)	63 (64%)	25 (25%)
Total hindlimbs	98	98	98	98
<i>p</i> value	<0.001	0.3	0.04	0.02

TABLE 1 Tenoscopic diagnosis in 145 limbs with nonseptic tenosynovitis of the digital flexor tendon sheath

Note: *p* values represent the comparison between lesion prevalence in fore and hindlimbs. Note that the percentage of deep digital flexor tendon (DDFT) lesions is significantly higher in forelimbs, whereas manica flexoria (MF) lesions and palmar annual ligament (PAL) constriction occur predominantly in hindlimbs. Lesion combinations are presented in Figure 7.

Abbreviation: SDFT, superficial digital flexor tendon.

OR: 2.34, CI: 1.017–5.412; Table 1). The likelihood of PAL constriction increased with age ($p = 0.005$, OR: 1.156, CI: 1.046–1.287); ponies were more affected than nonpony breeds ($p = 0.004$, OR = 23.85, CI: 2.8–202.9) and hindlimbs were significantly more at risk of PAL constriction compared with forelimbs ($p = 0.02$, OR: 2.36, CI: 1.133–4.908; Table 1).

Tendon lesions were debrided in 82 limbs. In 18 limbs, the injured MF was trimmed with the arthroscopic punch whereas in 26 limbs total resection of the MF was performed. Desmotomy of the PAL was

performed under endoscopic guidance in 123 limbs. PAL desmotomy was performed using an extrasynovial open approach¹⁷ due to severe PAL constriction, precluding the entry of the tenoscopic cannula and conical obturator into the DFTS in 2 limbs. In these two procedures, the surgical incision was closed following desmotomy and diagnostic tenoscopy of the DFTS was performed subsequently.

3.4 | Outcome

One horse was euthanised intraoperatively due to the severity of the lesions detected during tenoscopy (severe SDFT lesion). No postoperative complications were recorded for the remaining 130 horses (144 tenoscopies) while hospitalised and all horses were discharged from the hospital.

Two horses developed septic tenosynovitis of the operated DFTS after they were discharged from hospital. Both cases were tenoscopically lavaged and received systemic and intrasynovial antimicrobial medication. In one of these horses, an extrasynovial approach for PAL desmotomy had been performed initially and the horse returned to the clinic 18 days after tenoscopy. This horse returned to its prior level of performance 1 year after a single DFTS lavage. The other horse had undergone minimally invasive MF resection, it was presented again 15 days after initial tenoscopy and subsequently two tenoscopic lavages were performed. The horse remained chronically lame and was thereafter used as a brood mare.

Nine horses were euthanised during the short-term follow-up period (mean: 3.2 months, range: 3–6 months): six for reasons other than pathology of the DFTS (one proximal suspensory desmitis, three colic, one head trauma and one severe bilateral forelimb lameness of unknown aetiology), whereas three were euthanised due to DFTS pathology on the operated limb (two SDFT lesion and one DDFT lesion). For the purposes of description of long-term outcome, all the horses (3/9) euthanised because of DFTS pathology were added to the ‘chronic lame’ outcome group. The remaining six of nine dead horses were removed from the long-term follow-up group. Six horses were lost to follow-up, leaving long-term outcome data for 118 horses (132 surgeries) (Figure 3) which completed rehabilitation. In these

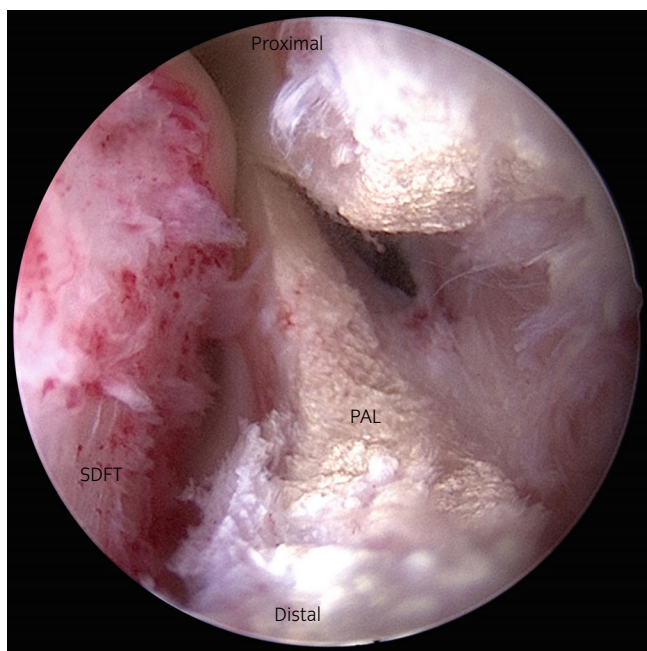


FIGURE 8 Tenoscopic visualisation of the digital flexor tendon sheath of a typical lesion seen at the plantar aspect of the superficial digital flexor tendon (SDFT) in a case with a concurrent plantar annular ligament (PAL) constriction; the tenoscope is inserted at the level of the base of the lateral proximal sesamoid bone and directed to proximal. The PAL has been transected using a hook knife. Left in the image the plantar surface of the SDFT can be seen; note the marked superficial fibrillation and hyperemic surface of the tendon in the area in contact with the PAL

FIGURE 9 (A) Ultrasonographic image of a longitudinal lesion at the lateral border of the deep digital flexor tendon (DDFT) at the level of the manica flexoria (MF). Note the irregular appearance of the lateral DDFT margin with an area of decreased echogenicity (arrow). (B) Tenoscopic view of the same DDFT lesion. The tenoscope is inserted at the level of the base of the lateral proximal sesamoid bone and directed to proximal. Note the significant tendon fibrillation along the lateral edge of the tendon, the case was classified as severe

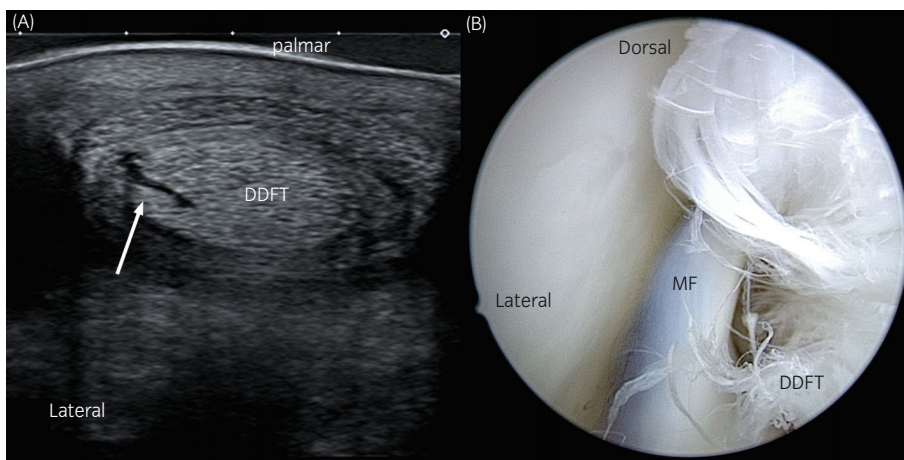


TABLE 2 Long-term outcome for 118 horses which underwent tenoscopy for management of nonseptic tenosynovitis with a range of additional lesions

	Deep digital flexor tendon lesion (n = 41)	Superficial digital flexor tendon lesion (n = 41)	Manica flexoria lesion (n = 36)	All cases n (%) in outcome category
Lameness persisted N (% of lesion group)	8 (19.5%)	5 (12.2%)	5 (13.8%)	18 (15.3%)
Returned to work at lower level N (% of lesion group)	18 (43.9%)	11 (26.8%)	11 (30.5%)	40 (33.8%)
Returned to work at same or higher level N (% of lesion group)	15 (36.6%)	25 (61%)	20 (55.5%)	60 (50.8%)

Note: Horses that underwent bilateral surgery were classified based on the more severely affected limb. Where horses underwent repeated tenoscopy during a later anaesthesia, these individuals were assigned to one of the three outcome groups based on their status immediately before the repeat procedure and outcomes following the 2nd procedure are not presented in this table.

horses, the mean follow-up period was 3 years; range 6 months to 6 years. One horse was euthanised 14 months after tenoscopy due to worsening of the lameness on the operated limb. This horse had a DDFT lesion and for reporting outcome it was included in the 'chronic lame' outcome group.

The time of convalescence and rehabilitation following surgery was less than 6 months in 55 surgeries, 7–12 months in 58 surgeries and more than 12 months in 16 surgeries. Long-term outcome for the diagnosed lesions after tenoscopy was as follows: 18 of 118 horses remained chronically lame and 100 of 118 horses were free of lameness and ridden again after tenoscopy, of which 40 performed at a reduced level and 60 at the same or higher level when compared with the preinjury performance. Table 2 summarises these cases depending on whether or not they had DDFT, SDFT and/or MF lesions. Descriptively, horses with DDFT lesions had a poorer long-term outcome compared with horses without a DDFT lesion.

4 | DISCUSSION

This is the first study evaluating the diagnosis and the long-term outcome following DFTS tenoscopy in a large population of German horses. Retrospective analysis of surgeries presented with nonseptic DFTS tenosynovitis identified a particularly high prevalence of SDFT lesions in combination with PAL constriction in this horse population. Contrast radiography resulted in improved lesion detection for MF tears when compared with ultrasonography and the long-term prognosis was favourable for most lesions except for those affecting the DDFT.

DDFT lesions were seen in forelimbs more often than hindlimbs, and at a slightly lower prevalence than in previous reports.^{3,5,18} In our population, DDFT and SDFT were equally prevalent while previous reports suggest that SDFT lesions are less common than DDFT lesions and have been diagnosed with a prevalence of 14% in a study of non-septic digital tenosynovitis from the United Kingdom.⁵ In the current case series, mild lesions at the palmar/plantar aspect of the SDFT, characterised by superficial fibrillation or a rough surface at the level of the proximal sesamoid bones were common. It is suspected that this lesion is associated with narrowing at the level of the fetlock

canal due to the pressure exerted by the PAL over the palmar/plantar tendon surface. SDFT and PAL injury was the most common lesion combination in our population and we speculate that the higher prevalence of SDFT lesions seen in the current case series compared with a previous report⁵ might relate by the concurrent high level of PAL injury.

MF lesions occurred more frequently in hindlimbs, similar to the result of studies performed in British horses.^{4,8,9} Kent et al.⁸ showed that fetlock extension results in distal displacement of the MF. Since hindlimb fetlocks are often more extended,^{19,20} these authors hypothesised that a more distal position of the MF in the hindlimb would increase the risk of this structure getting caught on the proximal scutum leading to MF tearing. Whilst Cob-type horses and ponies were significantly more affected by MF tears when compared with other breeds in the United Kingdom,^{4,8,9} a similar breed predilection was not identified in the current study. The difference might be explained by the fact that Warmblood horses were over-represented in this German population.

Owen et al.²¹ diagnosed PAL constriction more commonly in hindlimbs of aged horses and hypothesised that a more distal position of the proximal sesamoid bones in hindlimbs when compared with forelimbs likely results in a different force distribution leading to increased tension on the PAL. In addition, age-related loss of elasticity of the PAL may predispose this structure to injury.^{10,21} Differentiation between primary desmitis of the PAL or PAL constriction secondary to an intrasynovial tendinous lesion is difficult. In the current study, diagnosis of primary PAL desmitis was based on ultrasonographic findings. During tenoscopy, where the surgeon had a subjective feeling of a narrow fetlock canal 'PAL constriction' was diagnosed, which included both limbs with and those without ultrasonographically evident PAL desmitis. Due to the lack of sensitivity and specificity for the detection of PAL constriction previously described by Kent et al.,⁸ contrast tenograms were not used for detection of this pathology in our population.

Whilst a substantial number of horses were initially referred with the diagnosis of PAL desmitis for desmotomy, this lesion was rarely seen as a sole cause of DFTS tenosynovitis. As PAL pathology usually occurred in combination with flexor tendon or MF lesions, the outcome for the diagnosis 'PAL constriction' was not examined

separately. The DFTS should be assessed carefully for the presence of additional lesions when PAL desmitis is identified.

PAL desmotomy is indicated when PAL desmitis impairs the normal gliding of the flexor tendons within the fetlock canal and results in lameness that does not respond to conservative management²². Whilst several reports promote the advantages of surgical PAL desmotomy resulting in local decompression of the fetlock canal, a clear association with improved outcomes following PAL transection is lacking^{3,6,23}. In the current study, PAL desmotomy was performed where the fetlock canal appeared narrowed during tenoscopy and potentially also in preparation for complex surgical procedures like the minimally invasive resection of the MF, which required maximal space within the DFTS.

For reporting the outcomes, we decided not to include the horses which were euthanised during the first 6 months following tenoscopy for reasons unrelated to DFTS pathology, since they were not able to complete rehabilitation following tenoscopy, whereas euthanasia in another four horses (three within 6 month, one at 14 months) related to lameness persistence or worsening and are reported in that outcome category (Table 2).

We decided to include the horses operated in two different limbs within the description of the outcome, since the contralateral pathology was in all cases a mild to moderate PAL desmitis. For outcome description in bilateral tenoscopy cases, the most severely affected limb was used for assigning lesion. For those cases that underwent repeat tenoscopy, to ensure that each horse's outcome was categorised once only, the first tenoscopy was used for outcome categorisation since in our opinion the second pathology will not have as much chance of a good outcome as a horse which had no previous pathology at all.

DDFT tears, which were typically longitudinal at the lateral border of the tendon⁶ in forelimbs, had the poorest outcome after tenoscopy. Similarly, Wilderjans et al.,³ Smith et al.⁵ and Arensburg et al.⁶ found lesions of the DDFT, especially longitudinal tendon tears, had a poorer prognosis compared with other intrasynovial pathologies.

Overall, the results of this case series show that only 60 of 118 (51%) of horses were able to return to the same or higher level of exercise compared with preinjury. In contrast to previous reports, the majority of horses included in the current study were used for general purpose riding rather than high level competitive athletic activity. Therefore, horses returning to their proposed use were not intended to pursue a high level of athletic performance and owner expectations may have been fairly easy to meet and some owners may have been cautious about workload due to fear of reinjury. Reliance on owner description of outcome is a limitation of the current study.

Our results are comparable to the outcome documented by Thünker et al., who reported 47.5% (19/40) of the horses treated tenoscopically returning to their original level of performance. Further research is needed to assess adjunctive treatment options, such as corrective shoeing or different types of postoperative intrasynovial medications (such as hyaluronic acid, platelet-rich plasma, autologous conditioned serum, mesenchymal signalling cells) in order to improve the outcome after tenoscopy.

Synovial sepsis following DFTS tenoscopy occurred in two of 145 surgeries in this study and in one of 90 surgeries in the report of Smith et al.²⁴. The open approach for PAL desmotomy (first case) and the tenoscopic resection of the MF (second case), which resulted in a longer and potentially more traumatic surgery likely led to an increased risk of infection.

Similar to previous reports, the sensitivity of ultrasonography for the prediction of DDFT and MF lesions was low.^{5,6} This may be related to several factors such as the operators experience or the skin thickness of the horse. Holding the limb in a semi-flexed position during ultrasound examination may improve visualisation of marginal tears of the flexor tendons. With this position, the lower tension in the tendon allows some opening of the tear making it easier to detect the lesion²⁵.

Contrast tenography performed in line with intrasynovial analgesia improved the diagnostic capacity, especially for the identification of MF tears. Kent et al. reported a sensitivity of 92% and specificity of 56% for the detection of MF tears and a sensitivity of 54% and specificity of 73% for DDFT tears, similar to the values obtained in this study.⁸ The results of both studies provide evidence to encourage the use of contrast tenography as a routine part of a lameness investigation in horses with suspected tenosynovitis of the DFTS. Nevertheless, tenoscopy of the DFTS should be considered the gold standard for diagnosis of soft tissue lesions associated with digital flexor tenosynovitis.

The main limitations of this study are its retrospective nature, the lack of a control group and reliance on owner-reported information for outcome assessment. The diagnosis of specific lesions and the recognition of the exact localisation and severity on the basis of recorded patient data might have introduced some bias. In addition, a large proportion of horses included in the study were used for general purpose riding and long-term follow-up was obtained via conversations with the owners, so the level of athletic activity pre- and post-tenoscopy was not objectively assessed. Although our study population was fairly large, the large variation in lesion types and combinations, precluded more formal analysis of outcome and this was limited to description only.

In conclusion, the overall prognosis for horses with nonseptic tenosynovitis of the DFTS following tenoscopy is fair, with DDFT lesions having the poorest outcome. Intrasynovial lesions of the DDFT and MF were not consistently predicted during ultrasonographic examination but the addition of DFTS contrast tenography as part of a routine investigation in horses with DFTS pathology improves the likelihood of lesion identification, particularly for the diagnosis of MF tears.

AUTHOR CONTRIBUTIONS

Andrea N. Cender analysed the data and prepared the manuscript. Roswita Merle and Laura Pieper performed the statistical analysis of the data. Kathrin Mählmann, Anna Ehrle and Christoph J. Lischer contributed to preparation of the manuscript. All authors approved the final version.

ACKNOWLEDGEMENT

The authors thank their referring vets. Open Access funding enabled and organized by Projekt DEAL.

CONFLICT OF INTEREST

The authors declare no conflict of interest.

PEER REVIEW

The peer review history for this article is available at <https://publons.com/publon/10.1111/evj.13856>.

DATA AVAILABILITY STATEMENT

The data that support the findings of this study are available from the corresponding author upon reasonable request.

ETHICAL ANIMAL RESEARCH

Research ethics committee oversight not required by this journal: retrospective analysis of clinical data.

INFORMED CONSENT

Horse owners gave consent for the inclusion of their animals in the study.

ORCID

Andrea N. Cender  <https://orcid.org/0000-0002-4500-2304>

Anna Ehrle  <https://orcid.org/0000-0001-5338-6195>

REFERENCES

- Denoix J-M. Functional anatomy of tendons and ligaments in the distal limbs (manus and pes). *Vet Clin North Am Equine Pract.* 1994;10:273–322.
- Fraser BS, Bladon BM. Tenoscopic surgery for treatment of lacerations of the digital flexor tendon sheath. *Equine Vet J.* 2004;36:528–31.
- Wilderjans H, Boussauw B, Madder K, Simon O. Tenosynovitis of the digital flexor tendon sheath and annular ligament constriction syndrome caused by longitudinal tears in the deep digital flexor tendon: a clinical and surgical report of 17 surgeries in warmblood horses. *Equine Vet J.* 2003;35:270–5.
- Findley JA, De Oliveira F, Bladon B. Tenoscopic surgical treatment of tears of the manica flexoria in 53 horses. *Vet Surg.* 2012;41:924–30.
- Smith MRW, Wright IM. Noninfected tenosynovitis of the digital flexor tendon sheath: a retrospective analysis of 76 surgeries. *Equine Vet J.* 2006;38:134–41.
- Arensburg L, Wilderhans H, Simon O, Dewulf J, Boussauw B. Nonseptic tenosynovitis of the digital flexor tendon sheath caused by longitudinal tears in the digital flexor tendons: a retrospective study of 135 tenoscopic procedures. *Equine Vet J.* 2011;43:660–8.
- McIlwraith CW, Wright IM, Nixon AJ. Diagnostic and surgical arthroscopy of the carpal joints. *Diagnostic and surgical arthroscopy in the horse.* 3rd ed. Philadelphia, PA: Mosby Elsevier; 2005. p. 368–71.
- Kent AV, Chesworth MJ, Wells G, Gerdes C, Bladon BM, Smith RKW, et al. Improved diagnostic criteria for digital flexor tendon sheath pathology using contrast tenography. *Equine Vet J.* 2019;52:205–12.
- Fiske-Jackson AR, Barker WHJ, Eliashar E, Foy K, Smith RKW. The use of intrathecal analgesia and contrast radiography as preoperative diagnostic methods for digital flexor tendon sheath pathology. *Equine Vet J.* 2013;45:36–40.
- Dik KJ, Dyson SJ, Vail TB. Aseptic tenosynovitis of the digital flexor tendon sheath, fetlock and pastern annular ligament constriction. *Vet Clin North Am Equine Pract.* 1995;11:151–62.
- Fortier LA. Indications and techniques for tenoscopic surgery of the digital flexor tendon sheath. *Equine Vet Educ.* 2010;17:218–24.
- Gonzalez LM, Schramme MC, Robertson ID, Thrall DE, Redding RW. MRI features of metacarpo(tarso)phalangeal region lameness in 40 horses. *Vet Radiol Ultrasound.* 2010;51:404–14.
- King JN, Zubrod CJ, Schneider RK, Sampson SN, Roberts G. MRI findings in 232 horses with lameness localized to the metacarpo(tarso)phalangeal region and without a radiographic diagnosis. *Vet Radiol Ultrasound.* 2013;54:36–47.
- Hassel DM, Stover SM, Yarbrough TB. Palmar-plantar axial sesamoid approach to the digital flexor tendon sheath in horses. *J Am Vet Med Assoc.* 2000;217:1343–7.
- Nixon AJ. Endoscopy of the digital flexor tendon sheath in horses. *Vet Surg.* 1990;19:266–71.
- Noguera Cender A, Mählmann K, Lischer CJ. Ex vivo evaluation of an alternative technique for resection of the proximal manica flexoria in horses. *Vet Surg.* 2020;49(2):401–8.
- Hawkins D, Churchill E. Extrasynovial palmar-plantar annular ligament desmotomy. *Proc Am Assoc Equine Pract.* 1998;44:210–2.
- Wright IM, McMahon PJ. Tenosynovitis associated with longitudinal tears of the digital flexor tendons in horses: a report of 20 surgeries. *Equine Vet J.* 1999;31:12–8.
- Back W, Schamhardt HC, Savelberg HH, Bogert AJ, Bruin G, Hartman W, et al. How the horse moves: 1. Significance of graphical representations of equine forelimb kinematics. *Equine Vet J.* 1995;27:31–8.
- Back W, Schamhardt HC, Savelberg HH, Bogert AJ, Bruin G, Hartman W, et al. How the horse moves: 2. Significance of graphical representations of equine hind limb kinematics. *Equine Vet J.* 1995;27:39–45.
- Owen KR, Dyson SJ, Parkin TD, Singer ER, Kristoffersen M, Mair TS. Retrospective study of palmar/plantar annular ligament injury in 71 horses: 2001–2006. *Equine Vet J.* 2008;40:237–44.
- Kummerle JM, Theis F, Smith RKW. Diagnosis and management of tendon and ligament disorders. In: Auer JA, Stick JA, editors. *Equine surgery.* 5th ed. St Louis, MO: Elsevier; 2018. p. 1411–44.
- Thünker F, Oosterlinck M, Vanderperren K, Martens A. Long-term results of tenoscopic treatment of lesions in the digital flexor tendon sheath: a retrospective study of fifty horses. *Vlaams Diergeneeskd Tijdschr.* 2019;88:9–18.
- Smith LJ, Mellor DJ, Marr CM, Mair TS. What is the likelihood that a horse treated for septic digital tenosynovitis will return to its previous level of athletic function? *Equine Vet J.* 2006;38(4):337–41.
- Bertuglia A, Mollo G, Bullone M, Riccio B. Identification of surgically-induced longitudinal lesions of the equine deep digital flexor tendon in the digital flexor tendon sheath using contrast-enhanced ultrasonography: an ex-vivo pilot study. *Acta Vet Scand.* 2014;25:56–8.

SUPPORTING INFORMATION

Additional supporting information can be found online in the Supporting Information section at the end of this article.

How to cite this article: Cender AN, Mählmann K, Ehrle A, Merle R, Pieper L, Lischer CJ. Diagnosis and outcome following tenoscopic surgery of the digital flexor tendon sheath in German sports and pleasure horses. *Equine Vet J.* 2023;55(1):48–58. <https://doi.org/10.1111/evj.13856>