

Intra-articular osteoma in the stifle joint of a cat

Sebastian Jaenich¹ , Grace Klass², Beate Bosch³, Martin Unger¹ and Pavel Slunsky¹

Journal of Feline Medicine and Surgery Open Reports
1–5

© The Author(s) 2022

Article reuse guidelines:

sagepub.com/journals-permissions

DOI: 10.1177/20551169221122847

journals.sagepub.com/home/jfmsopenreports

This paper was handled and processed by the European Editorial Office (ISFM) for publication in *JFMS Open Reports*



Abstract

Case summary A 13-year-old male castrated cat was referred to our clinic for a 2-month history of right hindlimb lameness. Radiographs and CT showed a solid bony mass within the stifle joint. The mass was resected by arthrotomy and osteotomy of the tibial tuberosity. Histopathological examination revealed the diagnosis of osteoma. Recovery from surgery was uneventful. At the 8-week follow-up examination, the cat was free of clinical signs.

Relevance and novel information Feline osteomas are rare; only few cases have been reported. To the best of our knowledge, this is the first report of an intra-articular osteoma in the stifle joint of a cat and description of its surgical resection.

Keywords: Osteoma; neoplasia; stifle joint; surgical resection

Accepted: 11 August 2022

Introduction

Primary bone tumours in cats are rare and about 83% are malignant.¹ An osteoma is a benign bone tumour characterised by slow growth. Osteomas are typically located in oral and maxillofacial regions and their anatomical origin is either within the bone or from the periosteum.^{2,3} Jabara and Paton described a case of an osteoma arising from soft tissue next to the olecranon of a cat (extraskelatal osteoma).⁴ While tumours are generally found in older patients, osteomas have been reported in a wide range of ages, with the youngest reported case occurring in a 1-year-old cat. Most (6/7) cases have occurred in male castrated cats.²

The aetiology of osteomas is poorly understood. It has been suggested that osteomas can arise after trauma or infection; however, this has yet to be proven. In veterinary medicine, osteomas have been more commonly reported in horses, cows and small ruminants.^{2,3}

Case description

A 13-year-old male castrated domestic shorthair cat was referred to our clinic for a 2-month history of hindlimb lameness. In addition to progressive lameness, clinical signs included the cat avoiding jumping and withdrawing to rest most of the day. The owner did not witness any trauma prior to the onset of lameness; however,

as the cat was allowed to go outdoors as it pleased, a traumatic event could not be excluded. The orthopaedic examination revealed a decreased passive range of motion of the right hindlimb and moderate pain upon palpation of the stifle joint. Initial radiographs of the right stifle joint (Figure 1) revealed a solid bony mass-like lesion and additional smaller, partially ill-defined mineralisations superimposed on the cranial aspect of the stifle joint. There were mild periosteal new bone formations mainly at the distal aspect of the patella, and no signs consistent with an aggressive bone lesion. Thoracic radiographs and blood work were reviewed and judged to be within normal limits.

CT scans (Somatom Emotion; Siemens) of both hindlimbs were performed pre- and postcontrast (Xenetic;

¹AniCura Kleintierspezialisten Augsburg, Augsburg, Germany

²Department of Veterinary Medicine, Institute for Parasitology and Tropical Veterinary Medicine, Freie Universität Berlin, Berlin, Germany

³AniCura Kleintierspezialisten Ravensburg, Ravensburg, Germany

Corresponding author:

Sebastian Jaenich Mag med vet AniCura Kleintierspezialisten Augsburg, Max-Josef-Metzger-Straße 9, Augsburg 86157, Germany

Email: sebastian.jaenich@anicura.de



Guerbet [Figures 2 and 3]). The images revealed a large, well-delineated mineralised mass-like lesion with a cauliflower multilobulated shape, positioned within the cranial aspect of the right stifle joint at the level of the patellar fat pad with secondary cranial and proximal

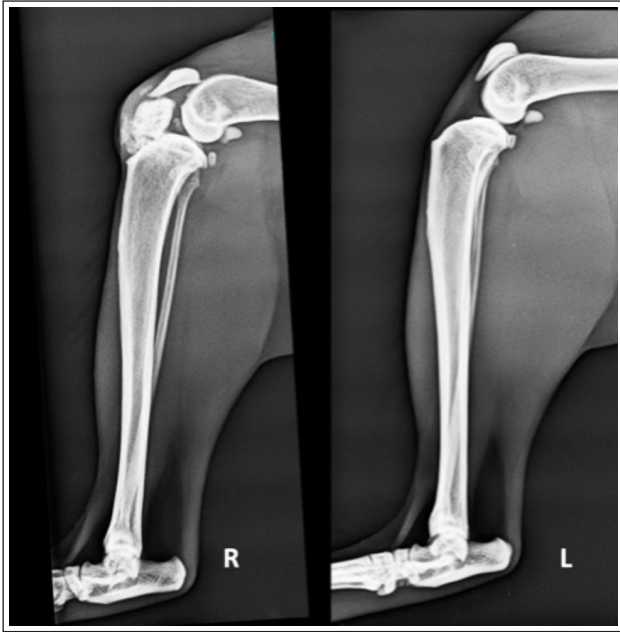

Figure 1 Mediolateral radiographs of both stifle joints taken by the first-opinion veterinarian

displacement of the patella. Additionally, the right stifle joint was moderately distended with fluid-attenuating material and the joint capsule was mild-to-moderately thickened. Furthermore, the scan revealed additional multifocal periosteal osteophyte and enthesophyte formations surrounding the stifle joint. The left stifle joint was unremarkable.

Surgical resection was elected by the owner and performed under general anaesthesia. The cat was administered midazolam (0.2 mg/kg [5 mg/ml] IV) and methadone (0.1 mg/kg [10 mg/ml] IV) for premedication, propofol (3 mg/kg [10 mg/ml] IV) for induction and isoflurane in oxygen for maintenance. To access the whole stifle joint, an osteotomy of the tibial tuberosity was performed in addition to a medial parapatellar arthrotomy. The patella, embedded in the patellar tendon, was also lifted and displaced laterally. The mass was located inside the joint capsule and without apparent adhesions to the joint capsule or cartilage. After in toto resection of the mass (approximately 2 × 3 × 2 cm; Figure 4a,b), the tibial tuberosity was re-fixed with 2 × 0.8 mm Kirschner wires (Aesculap; B Braun) and tension band fixation (orthopaedic wire). Intraoperatively, there were no macroscopic or biomechanical changes to the menisci, cruciate ligaments or the patellar mechanism. The joint capsule was closed using absorbable suture (3-0 Polydioxanone [MonoPlus; B Braun]) and the remaining layers were closed routinely.

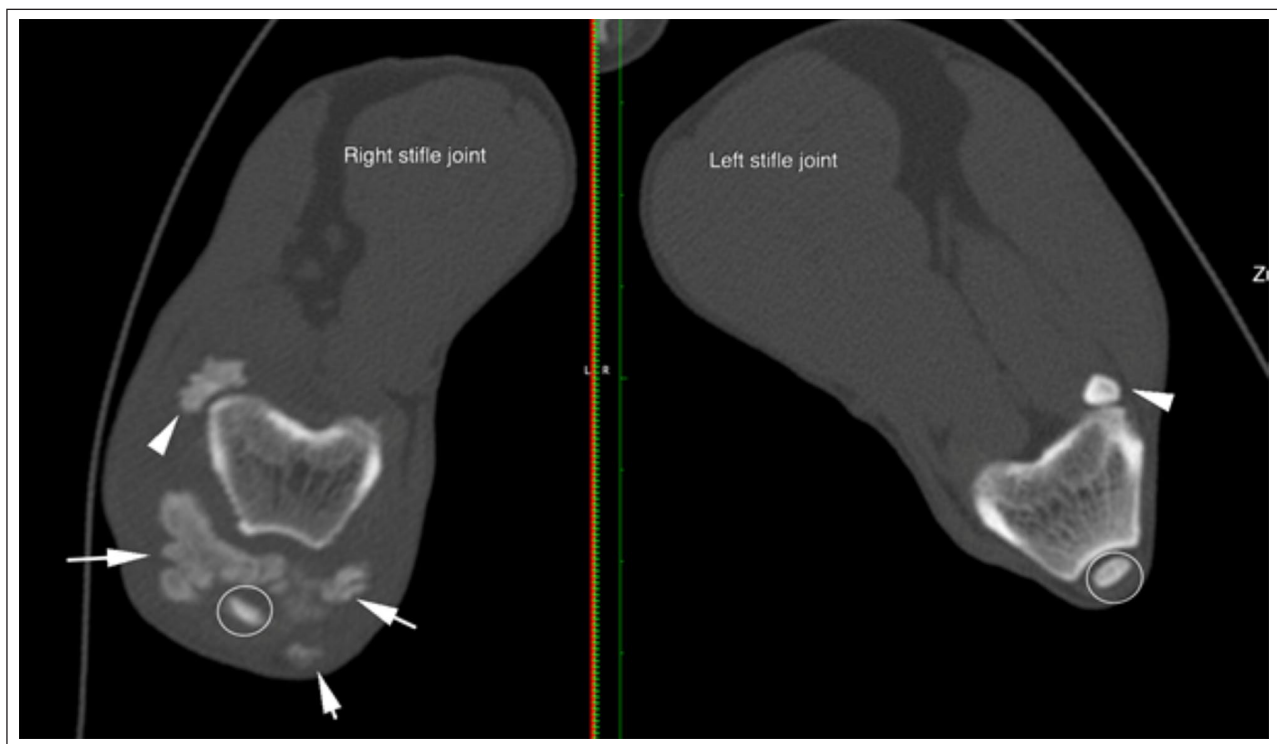


Figure 2 Transverse images of the right and left stifle joint with marked right-sided muscular atrophy. The white arrows mark mineralisations with secondary displacement of the patella (white circle). The white arrowheads show both lateral fabellae

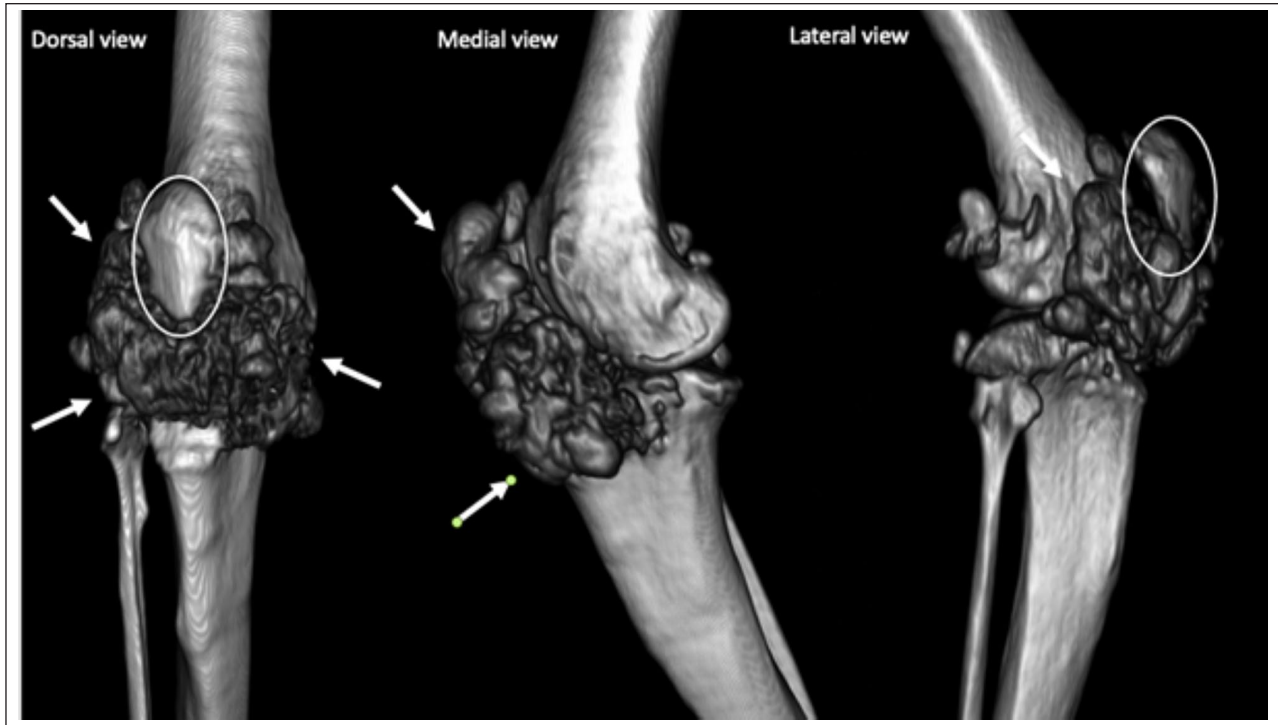
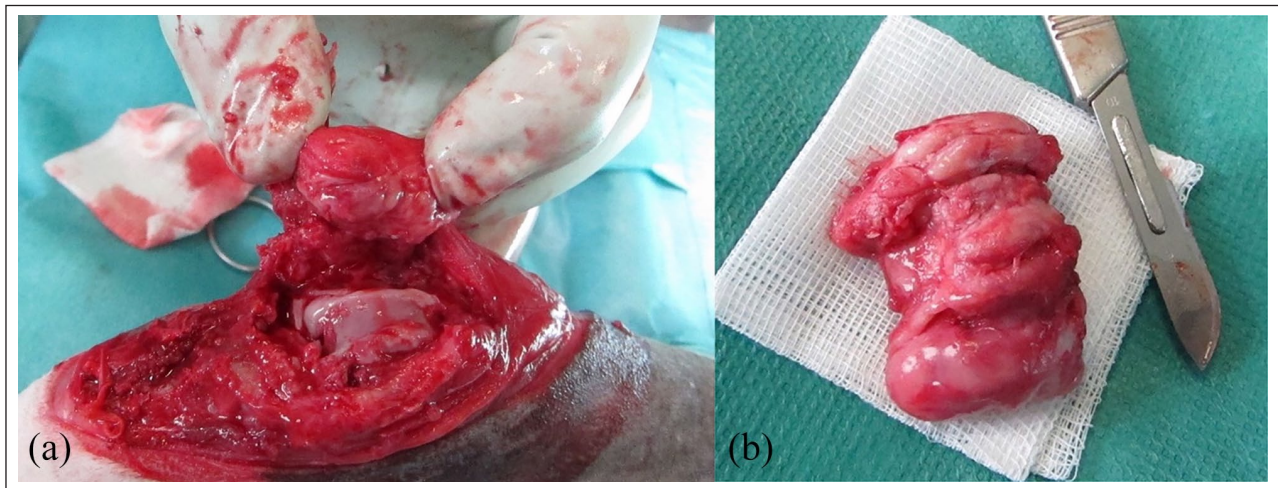


Figure 3 Three-dimensional reconstruction of the right stifle joint. Arrows mark the cauliflower-like mineralisations; the white oval marks the patella



Figures 4 (a) Intraoperative view before excision, with the distal part of the hindlimb pictured on the left, and (b) the excised mass

Histopathological findings (Figure 5) revealed a homogeneous appearance of bony trabeculae with embedded osteocytes surrounded by uniform osteoblasts and few osteoclasts, which were connected by fibrocytes. This benign new bone formation was diagnosed as an osteoma.

At 8 weeks postoperatively, the patient was presented for a follow-up examination and radiographs were taken. The orthopaedic examination showed physiological gait, physiological range of motion of the stifle joint and absence of pain during palpation. The owner described the cat's full recovery to normal activity

without limitations in movement. Radiographs (Figure 6) confirmed the absence of the osteoma. The implants within the tibia showed no signs of failure. The few residual periarticular periosteal osteophyte and enthesophyte bone formations and the previously described intra-articular mineralisations that were left in the stifle joint were unchanged from the preoperative imaging.

Discussion

Osteoma of the cat is a rare finding and long-term studies are lacking. Few case reports have been published and

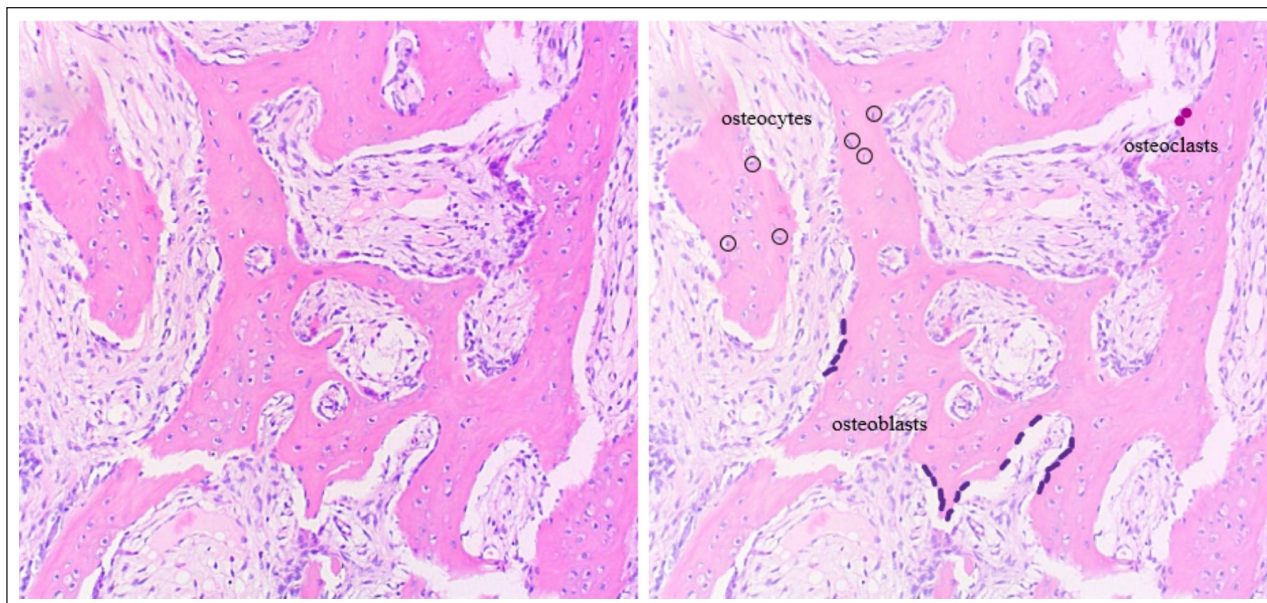


Figure 5 Osteoma (haematoxylin and eosin stain, $\times 10$) native overview (a) and with annotations (b). Bone trabeculae with embedded osteocytes (black circles) surrounded by uniform osteoblasts (purple) and few osteoclasts (pink), connected by fibrocytes (light-pink islands)

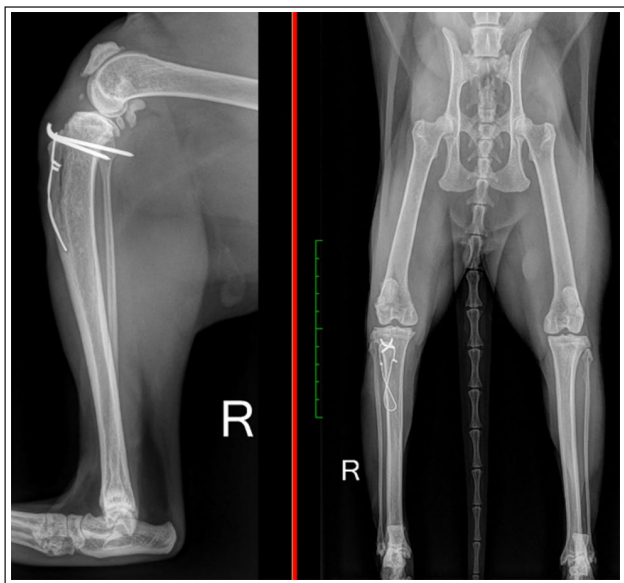


Figure 6 Mediolateral view of the right stifle joint and orthogonal view of the hindlimbs. Green scale is equivalent to 10 cm

the aetiology remains disputed.^{2,4-6} While some authors consider osteoma to be a true neoplasm, others suggest it is an acquired mass triggered by trauma or infection.^{2,7,8} The only case series of osteomas in cats to date, conducted by Fiani et al,² did not show a connection between osteoma development and prior traumatic or infection events. In the present case, the owner was not aware of any obvious traumatic injury or infection to the cat's stifle in the years prior to the onset of lameness.

Diagnosis of osteoma is made through physical examinations, diagnostic imaging and histopathological findings. Orthogonal radiographs are often the first diagnostic modality for any proliferative bony lesions. However, for a better understanding of the biological behaviour of the lesion and preoperative planning, both for biopsy sampling and mass resection, cross-sectional imaging, preferably CT, is recommended.⁹ In this case, the CT scans were considered vital to assessing the overall prognosis and surgical treatment options.

To the best of our knowledge, this is the first report of an intra-articular osteoma in a veterinary patient. In older felines with suspected joint degeneration, common diagnoses include osteoarthritis, osteochondroma and synovial osteochondroma. Their radiographic appearance can be very similar to an osteoma, especially regarding proliferative periarticular bony lesions.¹⁰⁻¹² However, in this case, the lesions did not match osteoarthritis. In addition, the absence of chondrocytes and no histological connection to synovial membrane excluded osteochondroma and synovial osteochondroma as diagnoses. Furthermore, dystrophic calcification could be considered a differential diagnosis for the radiographic lesions found in the stifle joint. Histopathological evaluation is necessary to confirm the suspected diagnosis, which would present as calcium depositions in injured, degenerated or dead soft tissue, while serum calcium and phosphorus are within normal limits.¹³

Similar to veterinary patients, osteomas in humans are usually slow-growing benign tumours that typically occur in the maxilla-facial region.⁷ Although exceedingly rare, there are case reports of osteomas in the long bones of humans, including the stifle joint.^{14,15} In

contrast to veterinary medicine, osteomas in humans are further classified according to their growth behaviour, as central (endosteum), peripheral (periosteum) or extraskeletal (soft tissues).^{2,7,16,17}

While there is limited information on osteomas in cats, it seems remarkable that most of the reported cases occurred in male patients.² In humans, a male-to-female ratio of 1.9:1 in patients with osteoma has been described.⁷ Additionally, similar to human medicine, osteomas in cats have been reported in a variety of ages. Fiani et al² described seven cases of osteomas in cats, with the age at diagnosis ranging from 1 to 23 years (median 9). However, more data are needed to test the validity of the suggested connections.

In the absence of long-term studies, prognosis and recurrence rates of osteoma are not well described. As osteomas are benign primary tumours, it can be assumed that a complete surgical resection is curative. Nevertheless, early intervention is desirable, albeit unlikely, owing to the late onset of obvious clinical signs. Regular follow-ups of the patients would be ideal but could be difficult to implement if patients are free of clinical signs in the eyes of their owners.

The general prognosis for many patients with osteoma is good. The individual prognosis depends heavily on tumour location and progression, secondary lesions and subsequent surgical treatment options.

Conclusions

Primary benign bone tumours are a rare finding in cats, but a thorough diagnostic work-up of these cases is worthwhile, as the prognosis is generally good. If the mass is surgically resectable in toto, the prognosis is presumed to be excellent. Osteoma in the stifle joint of a cat has not been described previously. CT proved to be the modality of choice for surgical planning and histopathological examination is essential to confirm diagnosis.

Acknowledgements The authors thank Dr Wolf von Bomhard (Dipl ECVP) and team for providing microscopic photography.

Conflict of interest The authors declared no potential conflicts of interest with respect to the research, authorship, and/or publication of this article.

Funding The authors received no financial support for the research, authorship, and/or publication of this article.

Ethical approval The work described in this manuscript involved the use of non-experimental (owned or unowned) animals. Established internationally recognised high standards ('best practice') of veterinary clinical care for the individual patient were always followed and/or this work involved the use of cadavers. Ethical approval from a committee was therefore not specifically required for publication in *JFMS Open Reports*. Although not required, where ethical approval was still obtained, it is stated in the manuscript.

Informed consent statement Informed consent (either verbal or written) was obtained from the owner or legal custodian of all animal(s) described in this work (either experimental or non-experimental animals, including cadavers) for all procedure(s) undertaken (either prospective or retrospective studies). No animals or people are identifiable within this publication, and therefore additional informed consent for publication was not required.

ORCID iD Sebastian Jaenich  <https://orcid.org/0000-0002-9183-6051>

References

- Liu SK, Dorfman HD and Patnaik AK. **Primary and secondary bone tumours in the cat.** *J Small Anim Pract* 1974; 15: 141–156.
- Fiani N, Arzi B, Johnson EG, et al. **Osteoma of the oral and maxillofacial regions in cats: 7 cases (1999–2009).** *J Am Vet Med Assoc* 2011; 238: 1470–1475.
- Alexopoulou A, Kouki ML, Papadopoulou PL, et al. **Osteoma of the mandible in a cat.** *Hell J Comp Anim Med* 2017; 6: 50–62.
- Jabara AG and Paton JS. **Extraskeletal osteoma in a cat.** *Aust Vet J* 1984; 61: 405–407.
- Knecht CD and Greene JA. **Osteoma of the zygomatic arch in a cat.** *J Am Vet Med Assoc* 1977; 171: 1077–1078.
- Gassel AD and Huber ML. **What is your diagnosis? A 2.0 × 1.75-cm well-circumscribed ovoid mineralized opacity over the left mandible.** *J Am Vet Med Assoc* 2002; 220: 1151–1152.
- Sayan NB, Ucoc C, Karasu HK, et al. **Peripheral osteoma of the oral and maxillofacial region: a study of 35 new cases.** *J Oral Maxillofac Surg* 2002; 60: 1299–1301.
- Woldenberg Y, Nash M and Bodner L. **Peripheral osteoma of the maxillofacial region. Diagnosis and management: a study of 14 cases.** *Med Oral Patol Oral Cir Bucal* 2005; 10 Suppl 2: E139–E142.
- Towle Millard HA and Breur GJ. **Miscellaneous orthopaedic conditions.** In: Johnston SA and Tobias KM (eds). *Veterinary surgery. small animal.* 2nd ed. St Louis, MO: Elsevier, 2018, pp 1299–1315
- Hubler M, Johnson KA, Burling RT, et al. **Lesions resembling osteochondromatosis in two cats.** *J Small Anim Pract* 1986; 27: 181–187.
- Langley-Hobbs SJ. **Humeral osteochondromas in cats [abstract].** *Vet Surg* 2001; 30: 296.
- Tan C, Allan GS, Barfield D, et al. **Synovial osteochondroma involving the elbow of a cat.** *J Feline Med Surg* 2010; 12: 412–417.
- Lefbom BK, Adams WH and Weddle DL. **Mineralized arteriosclerosis in a cat.** *Vet Radiol Ultrasound* 1996; 37: 420–423.
- Ayas MS, Gül O and Dada ME. **Extracranial location of the osteoma: patella, case report and literature review.** *Ekleml Hastalik Cerrahisi* 2018; 29: 189–192.
- Peyser AB, Makley JT, Callewart CC, et al. **Osteoma of the long bones and the spine. A study of eleven patients and a review of the literature.** *J Bone Joint Surg Am* 1996; 78: 1172–1180.
- Kaplan I, Calderon S and Buchner A. **Peripheral osteoma of the mandible.** *J Oral Maxillofac Surg* 1994; 52: 467–470.
- Bodner L, Gatot A, Sion-Vardy N, et al. **Peripheral osteoma of the mandibular ascending ramus.** *J Oral Maxillofac Surg* 1998; 56: 1446–1449.