



ELSEVIER

Contents lists available at ScienceDirect

JSES International

journal homepage: www.jseinternational.org

Clinical outcomes after refixation of subacute repaired distal biceps tendon ruptures



Kathi Thiele, MD^{a,*}, Laura König, MD^a, Maximilian Kerschbaum, MD^{a,b},
Jon Hedgecock, MD^c, Alp Paksoy^a, Markus Scheibel, MD^{a,d}, Christian Gerhardt, MD^{a,e}

^aCenter for Musculoskeletal Surgery, Charité – University of Berlin, Berlin, Germany

^bDepartment of traumatology, University Hospital Regensburg, Regensburg, Germany

^cOrthopedic Health of Kansas City, North Kansas City, MO, USA

^dDepartment of Shoulder and Elbow Surgery, Schulthess Klinik, Zürich, Switzerland

^eDepartment of hand- and traumatology, ViDia Christliche Kliniken Karlsruhe, Karlsruhe, Germany

ARTICLE INFO

Keywords:

Distal biceps tendon rupture
Refixation
Delayed treatment
Outcome
Strength
Function

Level of evidence: Level III; Retrospective
Cohort Comparison; Prognosis Study

Background: The aim of this study was to evaluate the clinical outcome and complication spectrum after delayed repair surgery of distal biceps tendon ruptures, postulating that satisfactory results are possible contrary to previous literature.

Methods: Forty-three of 92 patients with a full workup (= OPT in) undergoing primary distal biceps tendon repair were included in this study. The mean age of participants was 49.5 years (range = 22–66 years). This cohort was divided into two groups: patients undergoing acute repair (<21 days = AR group) and a group with delayed intervention (>21 days = SR group). Beside clinical evaluation, functional scores and detection of heterotopic ossification were documented. Strength of flexion and supination were measured using a BIODEX multipoint system. In addition, thirty-one patients were included only in the evaluation of complications in the absence of consent for clinical examination (= OPT out).

Results: Concerning the OPT-in group, twenty-eight patients (\bar{x} age = 48.9 years; 22–63 years) received acute repair after an average of 9.2 ± 3.7 days. On the contrary, 15 patients (\bar{x} age = 50.5 years; 32–66 years) were treated with a delay after an average of 31.4 ± 10.4 days. Regarding patient-reported outcome measures, conflicting results emerge (AR/SR: Subjective Elbow Value = 87/80%, $P > .05$; Mayo score = 96/93 pts, $P > .05$; the Disabilities of the Arm, Shoulder and Hand score = 6/13 pts, $P < .05$; and Oxford Elbow Score = 44/39 pts, $P < .05$). The main complication is the paresthesia of the lateral antebrachial cutaneous nerve, which occurs more in the group of delayed repair (AR: 21.0%, SR 31.8%). Forty-one percentage of patients in the SR group described pain in the elbow with exertion in contrast to 17.3% in the AR group. In terms of elbow strength, no significant difference in the AR or SR group compared with the contralateral side could be observed.

Conclusion: The data suggest that delayed repair of distal biceps ruptures beyond 3 weeks may result in satisfactory clinical outcomes. However, exertional pain and paresthesia of the lateral antebrachial cutaneous nerve may diminish results.

© 2022 The Authors. Published by Elsevier Inc. on behalf of American Shoulder and Elbow Surgeons. This is an open access article under the CC BY-NC-ND license (<http://creativecommons.org/licenses/by-nc-nd/4.0/>).

All procedures performed in studies involving human participants were in accordance with the ethical standards of the institutional research committee and with the 1964 Helsinki declaration and its later amendments or comparable ethical standards. The study is registered in the German Clinical Trials Register (No. DRKS00009696). Local ethics committee approval was obtained (registration number: EA1/248/14). All patients gave consent to be included in this study.

*Corresponding author: Kathi Thiele, MD, Center for Musculoskeletal Surgery, Campus Virchow, Charité-Universitätsmedizin Berlin, Augustenburger Platz 1 13353 Berlin, Germany.

E-mail address: Kathi.Thiele@charite.de (K. Thiele).

<https://doi.org/10.1016/j.jseint.2021.12.004>

2666-6383/© 2022 The Authors. Published by Elsevier Inc. on behalf of American Shoulder and Elbow Surgeons. This is an open access article under the CC BY-NC-ND license (<http://creativecommons.org/licenses/by-nc-nd/4.0/>).

Lesions of the distal biceps tendon represent only a small portion of injuries of the biceps brachii (3%–12%).^{12,19} Avulsions mostly are due to an eccentric load against the contracted muscle and are often found in middle-aged men. Unrepaired distal biceps tendon ruptures are often associated with a permanent loss of flexion and supination strength of 30%–50%.³ By contrast, surgical reinsertion leads to highly satisfying results.^{8,23}

Nevertheless, the rate of complications can vary between 8% and 40%.^{5,6,8,9,10,13} Common perioperative complications after surgical

refixation include neurological injuries (10%-15%), heterotopic ossifications (HO) (0%-50%), re-ruptures (1%-5%), hardware failures (0%-20%), chronic regional pain syndrome (2%), wound problems (2%-30%), stiffness (4%), and weakness (15-50%).¹² Operative complications, as mentioned previously, depend on the surgeon's experience and the performed surgical technique. Anatomic tendon fixation to the radial tuberosity is the preferred technique of most elbow surgeons. This fixation technique is either performed via a single-incision technique,¹⁶ using suture anchors, cortical buttons, or interference screws, or through a double-incision technique, giving the opportunity to reconstruct without the use of implants.

Widely agreed on is the effect of a delay in reconstructive surgery. Kelly et al stated in 2000 that morbidity after a surgical refixation of the distal biceps tendon can be attributed to a delay in repairing the injured tendon.¹⁷ The surgical outcome showed significant differences between a repair within the first three weeks after injury and a repair after the first three weeks. This assumption led to a hesitation in repair of subacute distal biceps tendon ruptures, which occurred more than 3 weeks after injury. Recent publications by Haverstock et al confirm the increase in complication spectrum with delayed intervention, but difference in the value of complications.¹⁵ There is also an increase in overall complications due to intervention after 21 days from 29% to 63%, but 90% of the complications affect irritation of the lateral antebrachial cutaneous nerve (LACN) alone. Major complications such as re-rupture, HO, or infection could not be demonstrated.

Although findings of Kelly et al have been widely agreed on, the aim of the present study is to determine whether the clinical outcome and complication rate differ between patients with a delayed repaired distal biceps tendon rupture (>21 days) and patients with an acute repair (<21 days). We hypothesize that even when a delayed refixation of the distal biceps tendon is associated with a generally higher complication rate, there will be no significant inferior clinical results and negligible adverse events.

Material and methods

The study protocol was approved by the local ethics committee (registration number: EA1/248/14).

Over a period of ten years (2005-2015), a total of 92 distal biceps tendon ruptures were operatively repaired at our institution. Patients who showed signs of arthrosis of the elbow and elbow stiffness and instability of the joint were excluded from the study. Furthermore, patients were excluded in the case of previously performed surgery of either the ipsilateral or contralateral elbow. Forty-three patients agreed to participate in the study with appropriate clinical follow-up (OPT in). In 31 patients, only an incomplete re-evaluation was possible, as a clinical presentation was not agreed to. Data were collected on the basis of existing file entries and after telephone inquiries (OPT out). For the remaining 18 patients, no contact could be established, and the documentation was insufficient.

Considering the time of repair, patients were divided into two groups. The first was defined as "acutely repaired" and included all patients who were operated up to 21 days after the initial trauma (AR group). The second group consisted of all patients who were operated at a later time (subacutely repaired [SR] group).

Next, a clinical examination, range of motion, elbow strength, postoperative complications, the presence of HO, and the overall satisfaction were evaluated in patients with complete clinical follow-up (OPT in). Patients with missing clinical follow-up as per the study protocol but with the complete record and telephone contact (OPT out) were also grouped to list at least complications. [Figure 1](#) shows the detailed patient inclusion ([Fig. 1](#)).

Operative fixation was performed through a single-incision technique. Different fixation methods were used. The first and most often used technique was a hybrid fixation, where the tendon's refixation is secured via a Bio-Tenodesis screw and an Endobutton. The incision was performed vertically about 3 cm distal to the elbow's flexion crease. Via cautious and atraumatic dissection, the distal biceps tendon was identified and then retrieved, and a heavy baseball-like whipstitch was placed in the tendon substance. In the next step, the forearm was supinated to its maximal extent, which provides a better display of the radial tuberosity. Before drilling the radial cortex, a guide pin was placed at the center of the tuberosity. The tendon was repaired using a cortical button with the addition of an interference screw (Bio-Composite, Arthrex, Naples, FL, USA). To tighten the knots, an endoscopic knot pusher was used. The other prevalent surgical technique in our study was the suture anchor technique (BioPlug, Karl Storz, Tuttlingen, Germany), where two anchors were inserted directly into the radial tuberosity. The anchors' sutures were used to draw the muscle toward the radial tuberosity and secure the tendon firmly onto it, again using a knot pusher to secure the knots. The arm was immobilized for 7 days using a splint angled at 90 degrees.

All patients were treated with indomethacin (75 mg; twice daily for a duration of 14 days). Afterward, a motion splint was applied for 6 weeks. During the first 3 weeks after the procedure, patients were advised to only passively flex and supinate the forearm with the assistance of physical therapists. Limitations were set at an extension block at 30 degrees. After 3 weeks, the extension limitation was reduced to 15 degree, and isometric tension exercises were applied. Patients were instructed that active flexion and supination should be avoided for about 6 weeks. Active flexion exercises were started in the seventh postoperative week. A return to full-load, as well as athletic activities, was only started after consulting the surgeon and not earlier than 6 months after the operative reinsertion. Patients were examined at postoperative follow-up intervals of 6, 12, and 24 months after the procedure.

Elbow flexion/extension and forearm supination/pronation strength measurement was performed on both sides using the Biodex Multipoint System in patients with complete clinical follow-up (OPT in) ([Fig. 2](#)). An isometric measurement program was selected to determine elbow strength and to compare the operated arm with the healthy arm in each possible direction of movement. A percentage comparing both of the patient's elbows was then calculated.

In the OPT-in group, all patients underwent radiographic analysis via x-rays to detect the presence of HO. In addition, elbow function as well as the patient's satisfaction was determined using the Disabilities of the Arm, Shoulder, and Hand (DASH) score, the Oxford Elbow Score, the Mayo score, and the Subjective Elbow Value (SEV).

Statistical analysis was carried out using SPSS software (IBM, Armonk, NY, USA). The exact chi-square independence test was performed to compare categorical variables. The independent t-test was used to compare continuous variables after determining the distribution was appropriate for parametric testing. *P* values <.05 were considered significant.

Results

Forty-three patients, all men, were included in our study with a complete workup (OPT in). Twenty-eight patients formed the group of the acutely repaired ruptures (AR group). The mean age in this group was 48.9 years (22-63 years) with a mean follow-up of 45 months (6-120 months). Fifteen men formed the SR group. The

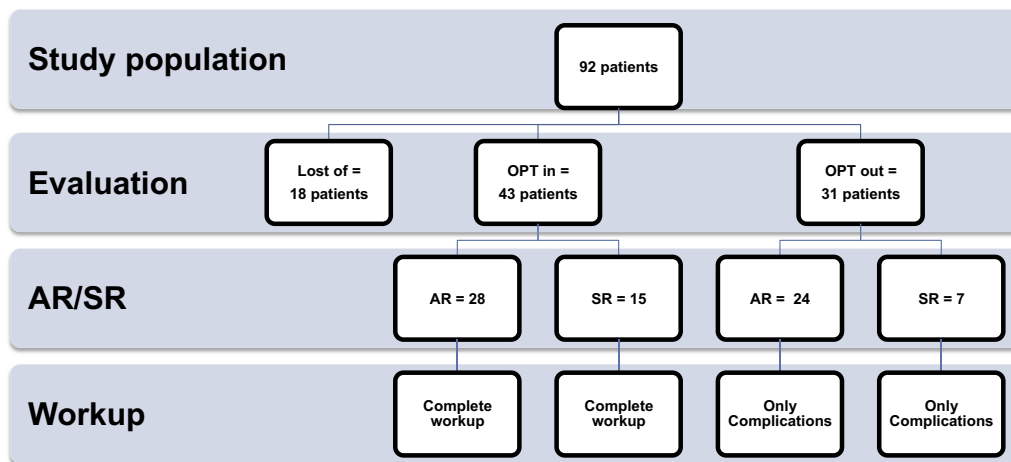


Figure 1 The flow chart of patients' inclusion.




Figure 2 Strength measurements with the BIODEX multipoint system for (A) flexion and for (B) rotation.

mean age was 50.5 years (32–66 years), and the follow-up averaged 35 months (9–68 months). The AR group received acute reconstructive treatment after an average of 9.2 ± 3.7 days, and the SR group was treated with a delay after an average of 31.4 ± 10.4 days ($P < .001$). The hybrid technique was used 25 times, 14 times in patients of the AR group (<21 days) and 11 times for the SR group (>21 days). The suture anchor technique was used in 18 patients, of which 14 were part of the AR group, and the remaining four were part of the SR group.

Thirty-one patients (24 patients = AR; 7 patients = SR) could not be reached for a clinical examination and were therefore only included for the evaluation of complications (OPT out). The complete demographic data of both patient collectives (OPT in and OPT out) are shown in Table I.

In the following, primarily the results of the OPT-in group are presented as only here a complete workup could take place. Concerning the range of motion, no significant differences between the operated and the nonoperated side in both groups (<21 days, >21 days) could be detected (Table II). No significant differences

concerning the elbow strength between the two groups (AR group and SR group) or between the operated and nonoperated side could be noticed. The elbow flexion strength of the operated side was 91.7% (± 33.3) for the AR group and 87.8% (± 19.1) for the SR group compared with the contralateral side. The supination strength of the AR group was 78.0% (± 18.2) compared with the healthy elbow, whereas the SR group reached 90.4% (± 24.1) (Fig. 3).

In the OPT-out group, 13% described a subjective loss of strength. Objective strength measurement could not be performed owing to the lack of clinical presentation.

In the group where follow-up examinations were performed, an allograft (1/43) was used in one case. In the group of patients where only record entries and telephone follow-ups are available, a total of 1 autograft and 2 allografts were used (3/31). The augmentation technique was only performed in the delayed treatment group because direct repair was no longer possible owing to the short tendon stump.

No significant differences in the SEV between the AR group and the SR group could be detected (AR group: 87.3% [± 16.3] vs. SR

Table I
Demographic data for acutely treated and delayed treated group (AR vs. SR group).

Item	OPT in (mean, range)	OPT out (mean, range)
Patient	43	31
AR	28	24
SR	15	7
Age		
AR	49 (22-63)	46 (25-60)
SR	51 (32-66)	41 (32-51)
Gender		
AR	100% male	100% male
SR	100% male	100% male
Operated side		
AR	Left 16/right 12	Left 11/right 13
SR	Left 9/right 6	Left 2/right 5
Surgical technique		
AR	Tension slide 14/suture anchor 14	Tension slide 11/suture anchor 13
SR	Tension slide 11/suture anchor 4	Tension slide 2/suture anchor 5

Table II
Range of motion after refixation of the distal biceps tendon for the acutely and subacutely treated group.

ROM	Operated extremity (degrees)	Healthy extremity (degrees)	P value
Acutely treated group (min-max)			
Flexion	142 (100-150)	144 (120-150)	.05
Extension	2 (0-10)	4 (0-10)	.05
Global range (E/F)	139 (80-150)	140 (105-150)	.05
Supination	85 (50-90)	87 (70-90)	.05
Pronation	82 (50-90)	85 (60-90)	.05
Global range (S/P)	166 (100-180)	172 (140-180)	.05
Subacutely treated group (min-max)			
Flexion	142 (100-150)	149 (140-150)	.05
Extension	5 (0-10)	6 (0-10)	.05
Global range (E/F)	138 (80-150)	142 (140-150)	.05
Supination	86 (60-90)	87 (70-90)	.05
Pronation	81 (50-90)	82 (60-90)	.05
Global range (S/P)	164 (100-180)	171 (140-180)	.05

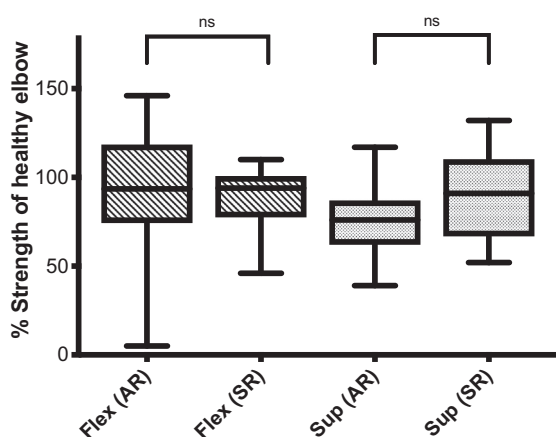


Figure 3 Results of the measurements of strength via the Biodex multijoint system in acutely and subacutely treated groups after distal biceps tendon rupture. Flex (AR), strength flexion in the acutely treated group; Flex (SR), strength flexion in the subacutely treated group; Sup (AR), strength supination in the acutely treated group; Sup (SR), strength supination in the subacutely treated group.

group: 79.7% [± 20.0] [n.s.]). In addition, the Mayo score showed no significant differences between the AR and SR group (AR group: 96.1 points [± 10.2] vs. SR group: 92.7 points [± 13.2] [n.s.]). In comparison, significant differences between the two groups (AR and SR groups) could be detected for the DASH score and the

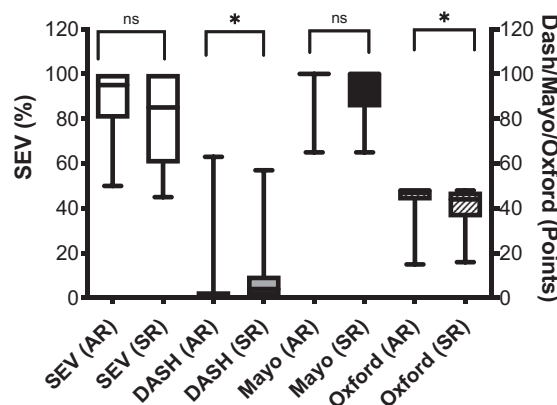


Figure 4 Postoperative score results in the acutely and delayed treated group after distal biceps tendon rupture (AR vs. SR group). AR, acutely treated group; SR, subacutely treated group.

Oxford Elbow Score. Patients of the AR group reached a DASH score of 6.1 (± 14.1), whereas the SR group showed a mean value of 12.7 (± 19.5) (P = .01). The Oxford Elbow Score for the AR group was 44.4 points (± 7.9), and it was 39.3 points (± 10.7) for the SR group (P = .02) (Fig. 4).

The results of the OPT-in and OPT-out groups are included in the evaluation of complications, except for the occurrence of ossifications because standardized fluoroscopy could not be performed for

Table III
Descriptive analysis of postoperative complications after refixation of the distal biceps tendon in acutely and delayed treated group (AR vs. SR group).

Item	OPT in (N = 43) (AR = 28, SR = 15)	P value	OPT out (N = 31) (AR = 24, SR = 7)	P value
Heterotopic ossification				
AR	N = 8	.72	-	
SR	N = 3	.72	-	
LACN palsy				
AR	Temporary N = 3	.28	N = 4	.55
	Persistent N = 4			
SR	Temporary N = 3	.28	N = 0	.55
	Persistent N = 4			
Motoric palsy				
AR	N = 0		N = 0	.23
SR	N = 0		N = 1	.23
Re-rupture				
AR	N = 0		N = 0	
SR	N = 0		N = 0	
Subjective power loss				
AR	-		N = 3	1.00
SR	-		N = 1	1.00
Impaired wound healing				
AR	N = 0	.35	N = 0	
SR	N = 1	.35	N = 0	
Pain				
AR	N = 9 (activity)	.26	N = 0	.23
SR	N = 6 (activity) 2 (rest)	.26	N = 1 (activity)	.23

the OPT-out group. The main complication is the affection of the LACN, which occurs more in the group of delayed (32%) than in case of an acute repair (21%). Regarding major complications, one radial nerve palsy showed up in the delayed treated group (4.6%). In both groups (SR + AR), no re-rupture could be detected. Forty-one percentage of patients in the delayed treated group described some pain in the elbow, especially with exertion, whereas only 17.3% of patients with prompt repair reported this.

Mild ossifications were more common in the acute treated group (AR = 28.6%, SR = 20.0%) related to the patients with complete follow-up (OPT in). The complete analysis of complications is shown in Table III.

Discussion

The most important results of the present study suggest that delayed repair of distal biceps ruptures beyond 3 weeks may result in satisfactory clinical outcomes. However, exertional pain and paresthesia of the LACN may diminish results.

The surgical approach and fixation technique have been continuously modified. Next to these surgical details (single-incision vs. double-incision, anatomical vs. nonanatomical repair, repair techniques), the time of operation seems to influence the postoperative outcome of the patients. Kelly et al postulated that most of the morbidity could be primarily attributed to the time of repair and recommended an early refixation. They described an increased complication rate from 24% (0-9 days after acute trauma) to over 38% (10-21 days after subacute trauma) and 41% in cases of delayed refixation (22-1918 days after delayed trauma).¹⁷ Kelly et al also observed in case of a delayed repair an increase for infections from the tenth day, for re-ruptures from the 20th day, and for loss of motion as well as HO from the 30th day after trauma.¹⁷ This statement has been accepted in this particular field of research.^{5,6} Bisson et al noted a 40% complication rate in patients with distal biceps tendon rupture operated more than 2 weeks after trauma,

compared with 20% after acute intervention.⁵ Cain et al reported on 198 patients with a 46% rate of adverse events correlated with a delayed treatment of 4 weeks out of injury.⁶

The increase of complications after delayed treatment is undisputed according to the literature, but recent literature sources including the present study show that minor complications are the most important ones.^{4,15}

Following the results of the multivariate analysis by Beks et al, 22% of 373 surgical repairs had an adverse event.⁴ In the subsequent multivariate analysis, it emerged that the single-incision anterior approach and obesity are significantly associated with an increased risk of complications, whereby the time of intervention did not affect the results. Most of the complications were due to a dysfunction of the LACN as a minor complication.⁴ Haverstock et al also showed that complications occurred in 63% of patients in the delayed cohort vs. 29% in the acute cohort. However, 90% of the delayed cohort’s complications consisted of transient paresthesia.¹⁵ Dunphy et al showed in an analysis of 784 surgical repairs of distal biceps tendon ruptures an overall complication rate of 37%, regardless of approach or technique.⁸ At 26.6%, nerve injuries represent the largest share of complications, with 20.6% alone attributed to a lesion of the LACN. In conclusion, a detailed differentiation in major and minor criteria allows one to see the higher complication rate in delayed surgery from another perspective.

Major complications include posterior interosseous nerve palsy, massive HO with consecutive restriction of motion, and re-ruptures of a biceps tendon after repair, whereas minor complications are defined by superficial infection, wound separation, and lateral antebrachial cutaneous neuropathy.¹²

Like Haverstock et al, the main complication in our study population is an paresthesia of the LACN with more frequent occurrence in the delayed treatment patient group (AR vs. SR = 21.0% vs. 31.8%). Most injuries to the LACN are transient neuropraxia and typically result in temporary numbness along the lateral forearm. For this reason, especially with an anterior approach, the visualization of the nerve with detachment from the adhesions is

recommended, and the use of retractors should be avoided.¹² However, one radial nerve palsy was also evident in our patient population in the setting of delayed therapy.

Other major complications such as re-ruptures or revisions due to massive HO could not be demonstrated in this retrospective evaluation, regardless of the time of intervention. In one case, the patient demonstrated a persistent positive hook test after surgery, but without radiographic evidence of a partial or complete re-rupture. Overall, re-ruptures are reported to be a rare complication in the literature with 0%–5.6% incidence.^{8,9}

Even though we did not observe motion-restricting HO, mild HO occurred in the acute and subacute treated group (OPT in), but did not require intervention. An interesting result was that patients with a delayed operation showed less HO than those in which an acute distal biceps tendon repair was performed. One possible reason could be differences in the method of fixation between the two groups.⁸ An influence by the choice of the surgical approach can be excluded as the single-incision approach is used as a standard in our institution. All patients were treated with indomethacin (75 mg, 1–0–1). Although a number of studies show statistically significant effects of this prophylaxis, its actual clinical value has not been definitively clarified.^{1,3,7}

In addition to the complication spectrum, the aim of this study was also to examine the impact of a delayed distal biceps tendon repair on patient-related outcome scores and strength measurements. The strength measurement during the follow-up workup showed no significant differences for flexion or for supination related to the time of treatment (OPT-in group). Nevertheless, a total of 13% in the OPT-out group complained of a subjective loss of strength regardless of the time of treatment after the injury. In addition, the high proportion of exertional pain in patients with delayed treatment (31.8%) in contrast to 17.3% in the group with an acute repair is striking. Owing to this, the assessment of the resulting strength appears to be subject to various influences and must be judged critically. Askew et al found that the dominant arm was stronger by 3% in flexion and 8% in supination than the nondominant arm in isometric examinations.² El–Hawary et al showed the influence of the postoperative time interval by a continual increase of power and stamina of up to 6–12 months in isometric and isokinetic tests depending on incision technique.⁹ Suda et al showed that the noninjured extremity was on average 7.7% better than the injured extremity after repair in dependency of handedness.²² A functional biceps muscle is a prerequisite for supination strength through a full arc of rotation.^{20,21} The assessment of the supination force is influenced by the hand position. The true loss of power manifests itself when the patient has to supinate away from his or her body (eg, changing a light bulb). The force measurement in the neutral position may not be sensitive enough to detect differences in strength after distal biceps repair.¹⁸ However, some authors postulate that the magnitude of the power delivery is likely to be more a matter of measurement method, handedness, and tendon reattachment location than a matter of delayed intervention time.^{14,18}

The results of the patient-reported outcome measures revealed a contradictory picture. The assessment of functionality using the DASH score as an objective functional score showed a significant difference between the two treatment groups in this study and may therefore signal a correlation between delayed repair and the outcome. However, in accordance with the results of Freemann and Schmidt et al, the validity of the findings should be looked at critically.^{11,21} In a retrospective study looking at nonoperative treatment, the average reported DASH score was 14. The normative score for the US population is 10.¹ However, 50% of the patients reported a relevant weakness. In summary, it appears that the DASH score could be not sensitive enough to capture the limitation

in general and may not be the most appropriate parameter for differentiating both care groups retrospectively. Nevertheless, there is a highly significant difference in the Oxford Score between the groups with different surgery time points as an indication of a negative influence of a delay. In contrast, there was no significant difference in the Mayo score or in the subjective assessment of the functionality of the affected arm (SEV).

Limitations

Some weaknesses of this study have already been mentioned. The most notable limitation is the retrospective study design. No preoperative scores or elbow strength data were collected, so it was not possible to quantify the amount of improvement that patients experienced. The difficulty of measuring the supination strength as well as the forearm-rotation measurement may itself be a possible shortcoming. No intraoperative information about grade of retraction, tendon quality, or the quality of myotendinous junction was reported. Third, there was a relevant loss to follow-up. We have tried to compensate for this by including at least telephone information in a separate evaluation regarding complications (OPT-out group).

Conclusion

The data suggest that a delayed repair of distal biceps ruptures beyond 3 weeks may result in satisfactory clinical outcomes even if with some deductions. Probably, it is not just the time since injury that is crucial for the functional outcome, but more important may be the quality of the tendon/myotendinous junction, amount of proximal retraction, and the length of the residual tendon.

Disclaimers:

Funding: No funding was disclosed by the authors.
Conflicts of interest: The authors, their immediate families, and any research foundation with which they are affiliated have not received any financial payments or other benefits from any commercial entity related to the subject of this article.

References

1. Agarwal S, Loder S, Levi B. Heterotopic ossification following upper extremity injury. *Hand Clin* 2017;33:363–73. <https://doi.org/10.1016/j.hcl.2016.12.013>.
2. Askew LJ, An KN, Morrey BF, Chao EY. Isometric elbow strength in normal individuals. *Clinical Orthopaedics Relat Res* 1987;222:261–6.
3. Baratz M, King GJW, Steinmann S. Repair of distal biceps ruptures. *J Hand Surg* 2012;37:1462–6. <https://doi.org/10.1016/j.jhsa.2012.02.008>.
4. Beks RB, Claessen FMAP, Oh LS, Ring D, Chen NC. Factors associated with adverse events after distal biceps tendon repair or reconstruction. *J Shoulder Elbow Surg* 2016;25:1229–34. <https://doi.org/10.1016/j.jse.2016.02.032>.
5. Bisson L, Moyer M, Lanigan K, Marzo J. Complications associated with repair of a distal biceps rupture using the modified two-incision technique. *J Shoulder Elbow Surg* 2008;17(1 Suppl):67S–71S. <https://doi.org/10.1016/j.jse.2007.04.008>.
6. Cain RA, Nydick JA, Stein MI, Williams BD, Polikandriotis JA, Hess AV. Complications following distal biceps repair. *J Hand Surg* 2012;37:2112–7. <https://doi.org/10.1016/j.jhsa.2012.06.022>.
7. Casavant AM, Hastings H. Heterotopic ossification about the elbow: a therapist's guide to evaluation and management. *J Hand Ther* 2006;19:255–66. <https://doi.org/10.1197/j.jht.2006.02.009>.
8. Dunphy TR, Hudson J, Batech M, Acevedo DC, Mirzayan R. Surgical treatment of distal biceps tendon ruptures: an analysis of complications in 784 surgical repairs. *Am J Sports Med* 2017;45:3020–9. <https://doi.org/10.1177/0363546517720200>.
9. El-Hawary R, Macdermid JC, Faber KJ, Patterson SD, King GJW. Distal biceps tendon repair: comparison of surgical techniques. *J Hand Surg* 2003;28:496–502. <https://doi.org/10.1053/jhsu.2003.50081>.
10. Ford SE, Andersen JS, Macknet DM, Connor PM, Loeffler BJ, Gaston RG. Major complications after distal biceps tendon repairs: retrospective cohort analysis of 970 cases. *J Shoulder Elbow Surg* 2018;27:1898–906. <https://doi.org/10.1016/j.jse.2018.06.028>.

11. Freeman CR, McCormick KR, Mahoney D, Baratz M, Lubahn JD. Nonoperative treatment of distal biceps tendon ruptures compared with a historical control group. *J Bone Joint Surg Am* 2009;91:2329–34. <https://doi.org/10.2106/JBJS.H.011150>.
12. Garon MT, Greenberg JA. Complications of distal biceps repair. *Orthop Clinics North Am* 2016;47:435–44. <https://doi.org/10.1016/j.ocl.2015.10.003>.
13. Grewal R, Athwal GS, Macdermid JC, Faber KJ, Drosdowech DS, El-Hawary R, et al. Single versus double-incision technique for the repair of acute distal biceps tendon ruptures: a randomized clinical trial. *J Bone Joint Surg Am* 2012;94:1166–74. <https://doi.org/10.2106/JBJS.K.00436>.
14. Hansen G, Smith A, Pollock JW, Werier J, Nairn R, Rakhra KS, et al. Anatomic repair of the distal biceps tendon cannot be consistently performed through a classic single-incision suture anchor technique. *J Shoulder Elbow Surg* 2014;23:1898–904. <https://doi.org/10.1016/j.jse.2014.06.051>.
15. Haverstock J, Grewal R, King GJW, Athwal GS. Delayed repair of distal biceps tendon ruptures is successful: a case-control study. *J Shoulder Elbow Surg* 2017;26:1031–6. <https://doi.org/10.1016/j.jse.2017.02.025>.
16. John CK, Field LD, Weiss KS, Savoie FH. Single-incision repair of acute distal biceps ruptures by use of suture anchors. *J Shoulder Elbow Surg* 2007;16:78–83. <https://doi.org/10.1016/j.jse.2006.03.002>.
17. Kelly EW, Morrey BF, O'Driscoll SW. Complications of repair of the distal biceps tendon with the modified two-incision technique. *J Bone Joint Surg* 2000;82:1575–81.
18. Nesterenko S, Domire ZJ, Morrey BF, Sanchez-Sotelo J. Elbow strength and endurance in patients with a ruptured distal biceps tendon. *J Shoulder Elbow Surg* 2010;19:184–9. <https://doi.org/10.1016/j.jse.2009.06.001>.
19. Safran MR, Graham SM. Distal biceps tendon ruptures: incidence, demographics, and the effect of smoking. *Clin orthop Relat Res* 2002;404:275–83.
20. Schmidt CC, Jarrett CD, Brown BT. The distal biceps tendon. *J Hand Surg Am* 2013;38:811–21. quiz 21. <https://doi.org/10.1016/j.jhssa.2013.01.042>.
21. Schmidt CC, Savoie FH, Steinmann SP, Hausman M, Voloshin I, Morrey BF, et al. Distal biceps tendon history, updates, and controversies: from the closed American Shoulder and Elbow Surgeons meeting-2015. *J Shoulder Elbow Surg* 2016;25:1717–30. <https://doi.org/10.1016/j.jse.2016.05.025>.
22. Suda AJ, Prajitno J, Grützner PA, Tinelli M. Good isometric and isokinetic power restoration after distal biceps tendon repair with anchors. *Arch Orthop Trauma Surg* 2017;137:939–44. <https://doi.org/10.1007/s00402-017-2724-9>.
23. Wang D, Joshi NB, Petrigliano FA, Cohen JR, Lord EL, Wang JC, et al. Trends associated with distal biceps tendon repair in the United States, 2007 to 2011. *J Shoulder Elbow Surg* 2016;25:676–80. <https://doi.org/10.1016/j.jse.2015.11.012>.