



Omalizumab in three children with severe vernal keratoconjunctivitis

Siri Rossberg · Uwe Pleyer · Susanne Lau

Received: 15 April 2020 / Accepted: 27 April 2020 / Published online: 26 May 2020
 © The Author(s) 2020

Summary

Background Vernal keratoconjunctivitis (VKC) is a rare, recurrent form of ocular allergy that can be refractory to topical and systemic treatment. It typically presents as acute and chronic keratoconjunctival inflammation that may lead to visual impairment due to corneal ulcers and scarring. Patients often suffer from atopic IgE-driven comorbidities, especially atopic eczema. Children are frequently affected and often do not tolerate topical treatment well, especially if photophobia and pain impair therapy adherence. We present three children with severe VKC who were not controlled by first- and second-line topical and systemic therapy and finally responded to treatment with the monoclonal anti-IgE antibody omalizumab as third-line treatment.

Methods and results We retrospectively analyzed three patients with VKC having failed response to first- and second-line treatment. All three boys had very early allergic rhinoconjunctivitis from age 1–3 with polysensitization: birch, grass pollen, house dust mite, and/or pets. All received subcutaneous or sublingual immunotherapy (SCIT/SLIT) for birch and/or grass pollen without major success. Two patients had comorbidities: allergic asthma and severe atopic dermatitis (AD). For at least 6 months after the first administration, monoclonal anti-IgE antibody omalizumab (150 or 300 mg) was administered subcutaneously every 2–6 weeks in all patients achieving

improvement of the clinical grading scale from VKC grade 3–4 to grade 1–2. One patient had a relapse mainly of his AD and achieved complete control of AD and VKC by introduction of dupilumab.

Conclusion Although the clinical benefit of omalizumab in asthma and chronic spontaneous urticaria (CSU) has been established in several clinical trials, there are very little data about its effect on severe VKC. In addition to few previously reported cases we can report the rapid effectiveness of omalizumab in VKC clinically and in terms of quality of life. Randomized trials are needed to include omalizumab in third-line treatment of VKC for prevention of visual impairment and further sequelae such as corneal damage.

Keywords Allergic conjunctivitis · Atopic dermatitis · IgE · Allergic asthma · Therapy

Abbreviations

AD	Atopic dermatitis
AKC	Atopic keratoconjunctivitis
CACC	Comprehensive Allergy Center Charité
CsA	Cyclosporine A
CSU	Chronic spontaneous urticaria
DSCG	Disodium cromoglycate (e.g. cromolyn)
ECP	Eosinophil cationic protein
MMP	Matrix metalloproteases
SCIT	Subcutaneous immunotherapy
SLIT	Sublingual immunotherapy
Th2	T helper-2
VKC	Vernal keratoconjunctivitis

Introduction

Vernal keratoconjunctivitis (VKC) can present as a severe eye condition extensively impairing patient's quality of life due to photophobia, foreign body sensation, itching, pain, visual impairment, and limited

S. Rossberg · Prof. Dr. S. Lau (✉)
 Department of Pediatric Pulmonology, Immunology and Intensive Care Medicine, Charité Universitätsmedizin Berlin, Augustenburger Platz 1, 13353 Berlin, Germany
susanne.lau@charite.de

U. Pleyer
 Department of Ophthalmology, Charité Universitätsmedizin Berlin, Berlin, Germany

social activity [1]. The distinction to other ocular allergies can be challenging. Early stages of VKC might be difficult to discriminate from atopic keratoconjunctivitis (AKC), often presenting together with atopic dermatitis as comorbidity. VKC usually occurs within the first decade of life, predominantly in young males without eyelid involvement in contrast to AKC showing additional blepharoconjunctivitis [2]. An Italian prospective study (patients 3–100 years of age) estimated a VKC prevalence of 6.5%; 64.5% of these patients were under 14 years of age [3].

VKC occurs with three main presentations: the most frequent limbal form (54%) shows the characteristic Trantas dots at the limbus due to eosinophilic infiltration, the tarsal form with the disease's hallmark giant papillae, cobblestoning, hypersecretion and the third form presents as a combination of both [4]. Severe photophobia can be an indicator of further complications such as keratitis and severe corneal ulceration/erosions leading to corneal residual scarring and thus visual impairment. In its tarsal presentation, allergic sensitization seems to be more causative [5].

VKC shows differences in its pathophysiology comparing nonatopic (absence of sensitization and atopic comorbidities) and the atopic condition. In atopic individuals, the presence of specific IgE in serum and in tears is observed. The high concentration of tissue mast cells and IgE dependent high affinity Fcε-receptor activation inducing histamine release seem to be the key reaction for the proinflammatory cascade in the atopic background of VKC [5]. In addition to an increased number of conjunctival mast cells, eosinophilic inflammation, CD4+ Th2 (T helper-2) lymphocytes and proinflammatory cytokines like interleukin (IL) 4 and 5 but also matrix metalloproteases (MMP) have been identified in tears of VKC patients [6]. Eosinophil-derived mediators, MMP, and collagenases damage the corneal epithelium and the basement membrane. IL-5, eotaxin, and ECP (eosinophil cationic protein) in tears were found to correlate with disease severity [7]. In nonatopic forms, a direct T cell response, enzyme activation, altered expression of neurotransmitters and receptors leading to hyperreactivity and tissue remodeling are considered underlying conditions [4]. Disease exacerbation can be triggered either by allergen re-exposure (if allergy plays a role) or, more frequently, by nonspecific stimuli such as sunlight, wind, and dust. Many patients with VKC therefore have less symptoms during winter months, although latent persistent clinical activity occurs [4].

Bonini et al. [8] introduced a clinical grading scale to improve distinction from other ocular allergies as well as to define five disease stages for unification and international studies. Grade 0 is absence of symptoms (quiescent), grade 1 mild and occasional symptoms, grade 2A mild to moderate intermittent and grade 2B mild to moderate persistent symptoms, grade 3 moderate to severe persistent symptoms, grade 4 severe

and persistent symptoms and finally grade 5 (evolution) with remission and fibrosis with absent or mild occasional symptoms.

The therapeutic concepts in treating VKC comprise topical and systemic approaches. Major aims are to stop inflammation and remodeling in order to prevent long-term damage of the cornea and visual impairment. Furthermore, quality of life and prevention of social distancing is a main goal especially in children. Recently, biologicals targeting immunological pathways have also been used as off-label treatment. Patients with severe ocular symptoms and photophobia not responding to antiallergic treatment need to be referred to an experienced center. Alongside reduction in allergen exposure and avoidance of wind and sun, patients need to be educated to reduce additional physical damage by itching. A cold compress on the eyelid may reduce itching; furthermore, rinsing of the eye with cool physiological saline solution may remove cellular debris and toxic substances [5].

Medical treatment according to disease stages implies antiallergic eye drops like ketotifen, other topical mast cell stabilizers like cromolyn (DSCG) and systemic non-sedating antihistamines as first-line treatment. From disease grade 3, additionally dual acting antiallergic agents, i.e., mast cell stabilizer in a combination of DSCG and lodoxamide, having inhibitory effects on eosinophil and neutrophil migration [9] and, thus, downregulating ICAM-1 expression [10] can be applied. More frequently, short-term topical steroids (dexamethasone/prednisolone) are used as first- and second-line treatment. However, given their well-known adverse effects such as glaucoma or cataract the use is limited to short-term application. In recent years, topical cyclosporine A (CsA 1–2% in oil bases) or other calcineurin inhibitors are commonly applied as second-line treatment. Topical CsA has been found to be effective and safe in VKC and recently became certified in some parts of Europe [11]. Systemic administration of the leukotriene receptor antagonist montelukast has been used in severely affected VKC patients as third-line treatment, however, without controlled trials. Furthermore, systemic treatment with CsA is used in some patients with severe atopic dermatitis and comorbid VKC or AKC as third-line treatment. Omalizumab as a monoclonal anti-IgE antibody blocking the IgE high-affinity receptor on mast cells and basophils and, thus, mediator release was used in the treatment of several patients with severe AKC and VKC [12–15] with variable outcome. In case of seasonal and even perennial VKC with associated sensitizations the causative approach of subcutaneous immunotherapy should be introduced despite limited evidence in VKC [2, 4, 8, 16]. In summary, a significant proportion of patients with serious VKC under topical treatment suffer from recurrent insufficiently controlled symptoms, which may result in fibrotic remodelling of the eye, followed by visual impairment. Especially children are often

Table 1 Patient characteristics, duration and dose of omalizumab and response to treatment

	Age at manifestation of VKC	Atopic comorbidity	Sensitization	Therapy before omalizumab was started	Age at omalizumab introduction	Duration and dosage of omalizumab treatment subcutaneously	VKC grade and visual acuity (VA) before omalizumab was started	VKC grade and visual acuity (VA) after omalizumab treatment
Patient A (male)	4 years	Allergic rhinoconjunctivitis, asthma	Birch grass mugwort cat dog guinea pig house dust mite	Systemic and topical antihistamines <i>cetirizine/levocabastine</i> topical corticosteroid <i>dexamethasone</i> topical cyclosporine A	10 years	11 months 300 mg/14 days	Grade 3-4 no visual impairment	Grade 1 no visual impairment
Patient B (male)	6 months	Allergic rhinoconjunctivitis	Birch grass mugwort house dust mite	Systemic and topical antihistamines <i>cetirizine/levocabastine</i> leukotriene receptor antagonist <i>montelukast</i> topical corticosteroid <i>dexamethasone</i> topical cyclosporine A	6 years	<i>Age 6 years:</i> 8 weeks 300 mg/4 weeks <i>Age 7 years:</i> 4 months 150 mg/6 weeks <i>Age 8 years:</i> 1 × 150 mg in April	Grade 4 VA right 0.6/ left 0.8	Grade 1 VA: right 1.0/ left 1.0
Patient C (male)	5 years	Allergic rhinoconjunctivitis, atopic dermatitis, asthma	Birch grass mugwort cat dog horse house dust mite	Systemic and topical antihistamines <i>cetirizine/levocabastine</i> leukotriene receptor antagonist <i>montelukast</i> topical corticosteroid <i>dexamethasone</i> topical and systemic cyclosporine A	7 years	6 months 300 mg/14 days	Grade 4 VA: right 0.5/ left 0.4	Grade 2 VA: right 1.0/ left 0.8

reluctant towards topical treatment with eye drops which need to be applied several times a day. At the Comprehensive Allergy Center Charité (CACC), we interdisciplinary treat children with severe VKC and report our experience of systemic treatment with the biological omalizumab as third-line treatment and off-label use in children not responding to first- and second-line treatment, being a pilot for a potential randomized trial in the near future.

Methods

We retrospectively analyzed three VKC patients who failed to respond to first- and second-line treatment. Patients were recruited in the outpatient clinic of Charité Medical University, Department of Pediatric Allergy and Pulmonology and Department of Ophthalmology. Medical insurance companies were approached to cover costs of an off-label treatment with monoclonal anti-IgE antibody omalizumab (Xolair®). The dose of omalizumab was calculated corresponding to the allergic asthma treatment by weight and total IgE serum levels. The time interval between injections depended on the absolute dose per month.

VKC grading according to Bonini [8] as well as visual impairment was assessed during the treatment phase. For visual acuity Snellen charts were used; all children were able to pass the test. Sodium fluorescein staining, used to detect corneal epithelial defects, allowed grading of superficial corneal alterations. Specific sensitization was either measured by skin prick test or in serum samples with Thermo Fisher ImmunoCAP sys-

tem (Phadia AB, Uppsala, Sweden). Parents and patients agreed to off-label use and to this publication.

Results

Three male patients suffered from early allergic rhinoconjunctivitis already at age 1–3 years. All presented with polysensitization primarily to pollen allergens and over time additionally to house dust mite and/or pets (Table 1). They had received allergen immunotherapy as subcutaneous or sublingual treatment (SCIT/SLIT) for birch and/or grass pollen. Additional comorbidities were allergic asthma and atopic dermatitis (patient C was severely affected). Follow-up time during and after omalizumab treatment was 11 months–3.5 years. Omalizumab treatment was well tolerated by all patients and no side effects were observed.

Patient A

At age 4, seasonal VKC was diagnosed with severe complaints from February to October. Treatment with systemic/topical antihistamines, followed by topical corticosteroid and CsA did not reach complete symptom control. Comorbid asthma triggered by pets and pollen allergens was treated with inhaled corticosteroids. Three years of subcutaneous allergen immunotherapy with birch and grass pollen extract did not achieve amelioration of eye symptoms. Sensitization (specific serum IgE) to birch, grass (CAP 6), mugwort pollen (CAP 4), cat, dog, horse and guinea pig

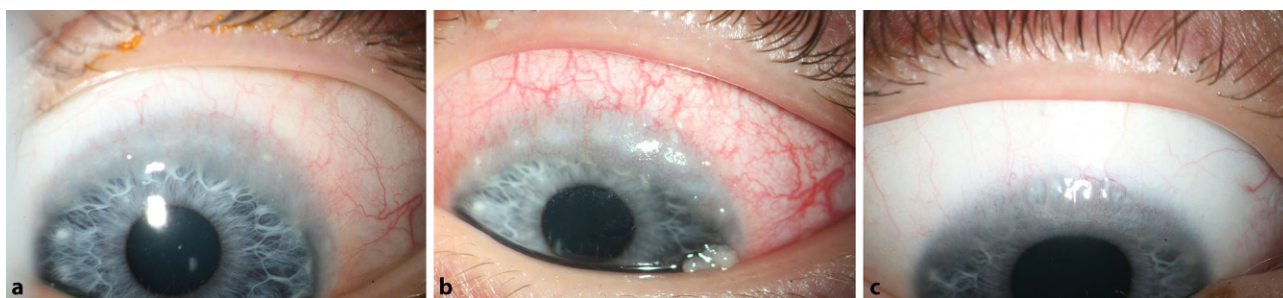

Fig. 1 Patient A: **a** vernal keratoconjunctivitis (VKC) grade 3, presenting with Trantas dots as sign of eosinophilic infiltration at 10 years of age; **b** corneal pannus with neovascularization and mucus discharge 10 months later (VKC grade 3–4);

c 9 months after treatment with omalizumab every 2 weeks 300 mg subcutaneously, neovascularization regressed (VKC grade 1)

(CAP 3), and house dust mite (CAP 2). At age 10, total IgE was 766 kU/l. Seasonal VKC grade 3–4 (conjunctival papillae, Trantas dots, corneal pannus with neovascularization and mucus secretion 10 months later) with visual impairment was observed without adequate response to topical treatment. Omalizumab was administered for 11 months every 2 weeks at a dose of 300 mg subcutaneously, which resulted in improvement to VKC grade 1 (Fig. 1). Further follow-up over 3.5 years showed no relapse of VKC.

Patient B

As an infant at age 6 months, seasonal VKC grade 3 (severe photophobia with keratitis, conjunctival papillae, limbal irritation) due to birch pollen was observed with recurrent symptoms from April–September in the years thereafter. During spring and summer time systemic/topical antihistamines and leukotriene receptor antagonist montelukast were given with incomplete remission, followed by topical corticosteroid and CsA. From age 5–7 years, sublingual immunotherapy with a birch pollen extract (droplets) was applied without major improvement. At age 6, VKC grade 2b was diagnosed in spring time (April), but with no response to topical treatment with dexamethasone and CsA. Monoclonal anti-IgE antibody omalizumab (2 × 150 mg) was started during summer (August) with a quick response within days. After 4 weeks, treatment with omalizumab was repeated due to a slight relapse (mild conjunctivitis). Again complete remission of symptoms occurred and no complaints during winter time were reported. At age 7, seasonal VKC grade 4 with visual impairment right eye 0.4 and left eye 0.7 was observed in April with a total IgE of 1753 kU/l. Omalizumab treatment was given for 4 months every 6 weeks at a dose of 150 mg subcutaneously. Improvement to VKC grade 1 was observed after one week. No further treatment was needed during that year. At age 8, again one injection 150 mg omalizumab was administered during spring with rapid response. No further treatment was needed.

Patient C

Since infancy, patient C has had severe atopic dermatitis without remission and later perennial rhinitis and intermittent asthma. At age 5, perennial VKC grade 4 (giant papillae, severe corneal erosions) was diagnosed. Treatment with systemic and topical antihistamines, topical corticosteroid, and topical CsA was insufficient. The patient experienced extreme photophobia and social distancing. School attendance was not possible during spring and summer time. Ultimately, amnion membrane transplantation was performed in another clinic in May 2017 at the age of 7 because of corneal damage (shield ulcer). Systemic CsA was started due to VKC and worsened atopic dermatitis, but VKC did not improve. Sensitization to pollen (birch, grass, mugwort), pet and house dust mite allergen was observed with a total IgE of 1295 kU/l. Due to a lack of response to systemic and topical immunosuppressive treatment and the increasing corneal damage (shield ulcer), omalizumab treatment was administered every 2 weeks with 300 mg subcutaneously for 6 months. After the first administration of omalizumab, a clear improvement of VKC from grade 4 to 2 was observed (Fig. 2). Systemic CsA was stopped, but the patient deteriorated again regarding the skin and eye condition. After reintroduction of systemic CsA (dose 3 mg/kg body weight) improvement to VKC stage 2 was observed. Complete remission of atopic dermatitis and VKC was achieved by the introduction of monoclonal anti-IL4/IL13 receptor antibody dupilumab (150 mg subcutaneously every 14 days).

Discussion

Omalizumab is a recombinant humanized monoclonal anti-IgE antibody used for the treatment of asthma and CSU [17, 18]. In this case series that included patients with atopic comorbidities and polysensitization, anti-IgE treatment seemed a plausible approach. Two of three patients suffered from visual impairment. Extreme photophobia hampered a normal social life, like school visits and sports.

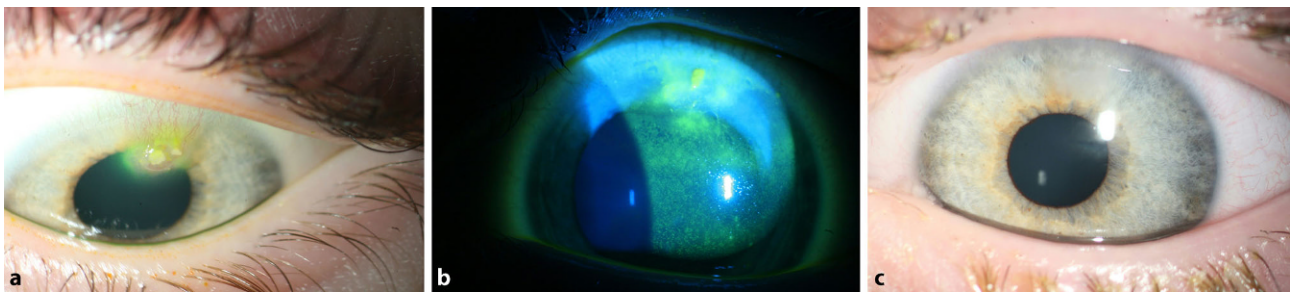


Fig. 2 Patient C: **a, b** corneal erosions at 7 years of age (sodium fluorescein staining), VKC grade 4; **c** 4 weeks after a single administration of 300 mg omalizumab subcutaneously with completely re-epithelialized cornea (VKC grade 2)

Omalizumab was administered for 1–11 months in different seasons and a remarkable improvement in clinical findings and quality of life was achieved, e.g., school attendance and sports activities. Two patients were treated with omalizumab only during one season or for less than a year, respectively, whereas one patient was treated over three seasons. The acceptance of subcutaneous injections was excellent; no side effects were reported during the treatment phase. This is in accordance with the observations from asthma and CSU treatment [19]. Successful treatment with omalizumab and reduction of eosinophil levels in conjunctival smears as a possible proof of concept was reported previously in two VKC patients [13]. Similar to our observation, four patients with VKC in another case series responded very well following a 6-month omalizumab treatment cycle. Interestingly, after cessation of treatment no relapse occurred [14]. Doan et al. reported three out of four patients with VKC improving during omalizumab therapy [15]. In addition, single case reports underline our experience. A 12-year-old boy with VKC, asthma, allergic rhinitis, and atopic dermatitis was successfully treated over 18 months every 4 weeks with 300 mg omalizumab [20]. Another 15-year-old female patient with VKC was treated over 2 years with omalizumab gaining full remission; however, treatment had to be reinitiated after 4 months of discontinuation when symptoms relapsed [21].

VKC often requires a multidisciplinary approach regarding diagnosis of concomitant atopic conditions and treatment options. In our case series, a more severe baseline grade, younger age at disease onset, and a higher grade of ocular inflammation were associated with the highest risk of poor visual outcome, demanding a more intense treatment approach. Onset of VKC before 3.5 years of life was the strongest factor associated with a severe course of the disease and visual impairment [22]. Within a disease classification and regression tree model to identify risk factors aiming at standardized treatment, photophobia was the key symptom to identify corneal involvement [21]. But even in patient B who showed a very early start of VKC at less than one year of age, disease remission to stage 1 was achieved after administering omalizumab for 6 months. Patient C needed additional treatment

with systemic CsA mainly due to severe atopic dermatitis and reached complete control with the biological dupilumab.

Due to the often reported self-limiting course of the disease, probably no long-term use of anti-IgE is to be expected in patients with severe VKC. Therefore, Simpson and Lee suggest the single use of anti-IgE by reporting a 54-year-old patient with VKC to be successfully treated with a single application of 300 mg omalizumab [23]. Our experience in children indicates that at least 2 months of treatment are necessary to achieve long-lasting control in the particular season, at least in the first year of treatment. One patient needed omalizumab in several seasons; however, the natural course of the disease showed less disease activity and complete remission in the third year of treatment only after one injection (patient B). If first- and second-line treatment fail, omalizumab as a biological treatment might have the potential to prevent progression. In particular, individuals at risk with corneal involvement are possible candidates since visual impairment may persist or take months for often incomplete functional recovery.

Conclusion

We report the rapid clinical effectiveness of monoclonal anti-IgE antibody omalizumab in VKC and improved quality of life, especially in severe cases not responding to other therapeutic approaches. Treatment was safe and well tolerated. Randomized trials are needed to include omalizumab in third-line treatment of VKC.

Acknowledgements This work has been facilitated through collaboration within the Comprehensive Allergy Center Charité (CACC).

Author Contribution All three authors were involved in the treatment of patients and in writing of the manuscript. They agree to the publication.

Funding Open Access funding provided by Projekt DEAL.

Compliance with ethical guidelines

Conflict of interest S. Rossberg, U. Pleyer and S. Lau have no direct conflict of interest regarding this article. However,

outside this publication, the following conflict of interest statement can be made: S. Lau has received honoraria from Boehringer, ALK, Sanofi-Genzyme, Allergopharma, Nutricia, DBV and ALK and participated as PI and deputy in studies funded by Allergopharma, Boehringer, Aimmune and DBV. U. Pleyer has served as principal investigator or consultant for the following: Abbvie, Alcon, Allergan, Alimera, Bayer, Dompé, Lilly, Novartis, Santen, Shire, Thea, Ursapharm, Winzer.

Ethical standards The off-label use was announced to the ethics committee and was approved as individual treatment decision.

Open Access This article is licensed under a Creative Commons Attribution 4.0 International License, which permits use, sharing, adaptation, distribution and reproduction in any medium or format, as long as you give appropriate credit to the original author(s) and the source, provide a link to the Creative Commons licence, and indicate if changes were made. The images or other third party material in this article are included in the article's Creative Commons licence, unless indicated otherwise in a credit line to the material. If material is not included in the article's Creative Commons licence and your intended use is not permitted by statutory regulation or exceeds the permitted use, you will need to obtain permission directly from the copyright holder. To view a copy of this licence, visit <http://creativecommons.org/licenses/by/4.0/>.

References

- Sacchetti M, Baiardini I, Lambiase A, Aronni S, Fassio O, Gramiccioni C. Development and testing of the quality of life in children with vernal keratoconjunctivitis questionnaire. *Am J Ophthalmol*. 2007;144:557–63.
- Pleyer U, Leonardi A. Keratoconjunctivitis vernalis. *Ophthalmologie*. 2015;112:177–92.
- Lambiase A, Minchiotti S, Leonardi A, Secchi AG, Rolando M, Calabria G, et al. Prospective, multicenter demographic and epidemiological study on vernal keratoconjunctivitis: a glimpse of ocular surface in Italian population. *Ophthalmic Epidemiol*. 2009;16:38–41.
- Leonardi A, Bogacka E, Fauquert JL, Kowalski ML, Groblewska A, Jedrzejczak-Czechowicz M, et al. Ocular allergy: recognizing and diagnosing hypersensitivity disorders of the ocular surface. *Allergy*. 2012;67:1327–37.
- Vichyanond P, Pacharn P, Pleyer U, Leonardi A. Vernal keratoconjunctivitis: a severe allergic eye disease with remodeling changes. *Pediatr Allergy Immunol*. 2014;25:314–22.
- Leonardi A, Sarthe S, Bortolotti M, Beaton A, Sack R. Cytokines, matrix metalloproteases, angiogenic and growth factors in tears of normal subjects and vernal keratoconjunctivitis patients. *Allergy*. 2009;64:710–7.
- Leonardi A, Jose PJ, Zhan H, Calder VL. Tear and mucus eotaxin-1 and eotaxin-2 in allergic keratoconjunctivitis. *Ophthalmology*. 2003;110:487–92.
- Bonini S, Sacchetti M, Mantelli F, Lambiase A. Clinical grading of vernal keratoconjunctivitis. *Curr Opin Allergy Clin Immunol*. 2007;7:436–41.
- Bonini S, Schiavone M, Bonini S, Magrini L, Lischetti P, Lambiase A, et al. Efficacy of lodoxamide eye drops on mast cells and eosinophils after allergen challenge in allergic conjunctivitis. *Ophthalmology*. 1997;104:849–53.
- Ciprandi G, Buscaglia S, Catrullo A, Paolieri F, Riccio AM, Fiorino N, et al. Antiallergic activity of topical lodoxamide on in vivo and in vitro models. *Allergy*. 1996;51:946–51.
- Bremond-Gignac D, Doan S, Amrane M, Ismail D, Montero J, Nemeth J, et al. Twelve-month results of cyclosporine A cationic emulsion in a randomized study in patients with pediatric vernal keratoconjunctivitis. *Am J Ophthalmol*. 2020;212:116–26.
- Williams PB, Sheppard JD. Omalizumab: a future innovation for treatment of severe ocular allergy? *Expert Opin Biol Ther*. 2005;12:1603–9.
- Heffler E, Picardi G, Liuzzo MT, Pistorio MP, Crimi N. Omalizumab treatment of vernal keratoconjunctivitis. *JAMA Ophthalmol*. 2016;134:461–3.
- Occasi F, Duse M, Nebbioso M, De Castro G, Di Fraia M, Capata G, et al. Vernal keratoconjunctivitis treated with omalizumab: a case series. *Pediatr Allergy Immunol*. 2017;28:503–5.
- Doan S, Amat F, Gabison E, Saf S, Cochereau I, Just J. Omalizumab in severe refractory vernal keratoconjunctivitis in children: case series and review of the literature. *Ophthalmol Ther*. 2017;6:195–206.
- Sacchetti M, Lambiase A, Deligianni V, Mantelli F, Leonardi A, Bonini S. A new clinical grading of vernal keratoconjunctivitis: a classification-regression tree (cart®) analysis. *Invest Ophthalmol Vis Sci*. 2010;51:1932.
- Maurer M, Rosen K, Hsieh HJ, Saini S, Grattan C, Giménez-Arnauet A, et al. Omalizumab for the treatment of chronic idiopathic or spontaneous urticaria. *N Engl J Med*. 2013;368:924–35.
- Humbert M, Beasley R, Ayres J, Slavin R, Hébert J, Bousquet J, et al. Benefits of omalizumab as add-on therapy in patients with severe persistent asthma who are inadequately controlled despite best available therapy (GINA 2002 step 4 treatment): INNOVATE. *Allergy*. 2005;60:309–16.
- Corren J, Kavati A, Ortiz B, Colby JA, Ruiz K, Maiese BA, et al. Efficacy and safety of omalizumab in children and adolescents with moderate-to-severe asthma: a systematic literature review. *Allergy Asthma Proc*. 2017;38:250–63.
- de Klerk TA, Sharma V, Arkwright PD, Biswas S. Severe vernal keratoconjunctivitis successfully treated with subcutaneous omalizumab. *JAAPOS*. 2013;17:305–6.
- Santamaria L, Sanchez J. Long-term efficacy of omalizumab in patients with conventional treatment-resistant vernal keratoconjunctivitis. *Rev Alerg Mex*. 2018;65:192–6.
- Sacchetti M, Lambiase A, Mantelli F, Deligianni V, Leonardi A, Bonini S. Tailored approach to the treatment of vernal keratoconjunctivitis. *Ophthalmology*. 2010;117:1294–9.
- Simpson RS, Lee JK. Omalizumab as single-dose therapy for vernal keratoconjunctivitis. *Ann Allergy Asthma Immunol*. 2019;122:119–20.