


Practical recognition tools of immunoglobulin G serum antibodies against the myelin oligodendrocyte glycoprotein-positive optic neuritis and its clinical implications

Itay Lotan^{1,2}  | Frederike C. Oertel^{3,4,5} | Claudia Chien^{3,4,5,6} | Susanna Assejer^{3,4,5} | Friedemann Paul^{3,4,5,7} | Hadas Stiebel-Kalish^{2,8}

¹Department of Neurology and Neuro-Immunology Service, Rabin Medical Center, Petah Tikva, Israel

²Sackler School of Medicine, Tel Aviv University, Tel Aviv, Israel

³Experimental and Clinical Research Center, Max-Delbrück Center for Molecular Medicine and Charité – Universitätsmedizin Berlin, corporate member of Freie Universität Berlin, Humboldt-Universität zu Berlin, Berlin, Germany

⁴Berlin Institute of Health, Berlin, Germany

⁵NeuroCure Clinical Research Center, Charité – Universitätsmedizin Berlin, corporate member of Freie Universität Berlin, Humboldt-Universität zu Berlin, Berlin, Germany

⁶Department of Psychiatry and Psychotherapy, Charité – Universitätsmedizin Berlin, corporate member of Freie Universität Berlin, Humboldt-Universität zu Berlin, Berlin, Germany

⁷Department of Neurology, Charité – Universitätsmedizin Berlin, corporate member of Freie Universität Berlin, Humboldt-Universität zu Berlin, Berlin, Germany

⁸Department of Ophthalmology and Neuro-Ophthalmology Unit, Rabin Medical Center, Petah Tikva, Israel

Correspondence

Friedemann Paul, Experimental and Clinical Research Center, Max Delbrueck Center for Molecular Medicine and Charité – Universitätsmedizin Berlin, Lindenberger Weg 80, 13125 Berlin, Germany.
Email: friedemann.paul@charite.de

Funding information

Charite Universitätsmedizin Berlin

Abstract

Myelin oligodendrocyte glycoprotein (MOG)-associated disease is an autoimmune disease of the central nervous system, associated with the presence of immunoglobulin G serum antibodies against MOG. Recent data have allowed characterization of the clinical spectrum of MOG-associated disease, which is now considered a new disease entity, distinct from multiple sclerosis and neuromyelitis optica spectrum disorders. Optic neuritis is the most common clinical presentation of MOG-associated disease in adults, both at disease onset and during the disease course, and has several distinct clinical and paraclinical features. Immunoglobulin G serum antibodies against MOG-positive optic neuritis is often bilateral and associated with optic disc swelling and a longitudinally extensive abnormal magnetic resonance imaging signal involving the retrobulbar portion of the optic nerve. The visual acuity during the acute attack is severely decreased, and the response to corticosteroids is often rapid and prominent. However, early relapses after steroid cessation are common, and a subset of patients is left with a permanent visual disability. In this review, we discuss the clinical and paraclinical features of immunoglobulin G serum antibodies against MOG-positive optic neuritis in adults, and focus on the distinctive features that can enable its early diagnosis. Therapeutical considerations at the acute stage and for relapse prevention are further deliberated.

KEYWORDS

multiple sclerosis, myelin oligodendrocyte glycoprotein, neuromyelitis optica spectrum disorders, optic neuritis

This is an open access article under the terms of the Creative Commons Attribution-NonCommercial License, which permits use, distribution and reproduction in any medium, provided the original work is properly cited and is not used for commercial purposes.

© 2020 The Authors. *Clinical and Experimental Neuroimmunology* published by John Wiley & Sons Australia, Ltd on behalf of Japanese Society for Neuroimmunology.

1 | INTRODUCTION

Myelin oligodendrocyte glycoprotein antibody disease (MOGAD) is an autoimmune disease of the central nervous system (CNS) that targets the MOG antigen present on the extracellular surface of the myelin sheath and oligodendrocytes.¹ The exact physiological role of MOG has not been fully delineated. The fact that MOG is expressed relatively late during neural development suggests it might have a physiological role as a surface marker of oligodendrocyte maturation, as well as in myelin integrity, adhesion and cell surface interactions.^{1,2} MOG antibodies (Abs) were initially described in patients with multiple sclerosis (MS). Recently improved antibody detection methods using cell-based assays (CBAs) of MOG in its full native confirmation form have allowed the identification of a subgroup of immunoglobulin G serum antibodies against MOG (MOG-IgG)-positive patients with a distinct, non-MS demyelinating CNS disorder.³⁻⁷

MOGAD shares several clinical similarities with aquaporin-4 (AQP4)-IgG-positive neuromyelitis optica spectrum disorders (NMOSD), including predilection to involve the optic nerves, the spinal cord and the brainstem.^{2,8} Indeed, up to 42% of patients with the clinical NMOSD phenotype who are seronegative for AQP4 Abs test positive for MOG-IgG.^{9,10} However, MOG-IgG-positive patients might have more limited forms of the NMO spectrum (i.e. isolated recurrent optic neuritis [ON] or transverse myelitis¹¹⁻¹⁴), as well as other atypical NMOSD manifestations (i.e. seizures and encephalopathy, brainstem encephalitis, cranial neuropathies, and aseptic meningitis^{12,15-21}).

Being a relatively new disease entity, the epidemiology of MOGAD has not been fully characterized. In a nationwide epidemiological study from the Netherlands, the mean incidence of MOGAD between 2014 and 2017 was 0.16/100 000 persons/year, with higher incidence rates in children than in adults (0.31/100 000/year vs 0.13/100 000/year, respectively).²² In a recent epidemiological study from the UK, the prevalence and incidence rates of MOGAD were nearly twice as common as AQP4-IgG-positive NMOSD.²³

Several sociodemographic features also differ in MOGAD compared with AQP4-IgG positive NMOSD, including younger age of onset, a higher proportion of Caucasian ethnicity and less pronounced female predominance in MOGAD.^{1,23-30} These immunobiological and clinical distinctions have led many experts to consider MOGAD as a distinct clinical entity, separate from NMOSD.^{27,31-35}

With the accumulation of data from several retrospective studies that describe the clinical spectrum of MOGAD, it is now evident that ON represents the most common clinical manifestation of the disease in adults.^{8,22,26,28,29,33,36} Although some authors report a monophasic disease course in up to 50%²⁸ and better long-term outcomes in MOGAD,^{24,36,37} others have reported a relapsing course in 70-93% of patients,^{8,38} which might be associated with permanent neurological disability.^{8,13,28,38,39} Therefore, the early distinction of

MOGAD from other demyelinating diseases is an important goal in the management of this disorder and in avoiding potentially harmful pharmaceutical choices.^{8,40,41}

This review focuses on the clinical and paraclinical characteristics of MOG-IgG-positive ON in adults. We discuss the distinguishing clinical and radiological features of MOG-IgG, as well as fundamental therapeutic considerations. Our goal is to provide clinicians with a useful tool that will enable them to formulate early diagnostic suspicion of MOG-IgG ON and a timely therapeutical approach.

2 | THE COURSE OF OPTIC NEURITIS (ISOLATED, RECURRENT, CHRONIC AND ASSOCIATED WITH NMOSD-LIKE SYNDROMES)

ON is the most common clinical manifestation of adult MOGAD.^{8,26,28,29,36} Possible disease courses include a single episode of isolated ON, recurrent ON, chronic relapsing inflammatory optic neuropathy (CRION)-like ON and ON associated with other neurological symptoms, such as transverse myelitis, brainstem syndromes, and cerebral pathology with seizures and encephalopathy.^{2,3,8,14,28,42-46} A large retrospective study of immune-mediated optic neuropathies carried out in the UK identified MOG-IgG antibodies in 9% of patients with isolated ON, 20% of patients with relapsing ON and 27% of patients with CRION.⁴⁷ Jitprapaikulsa et al carried out a retrospective study of 246 patients with at least two episodes of ON, of whom 186 had isolated recurrent ON and 60 had a subsequent neurological involvement. A total of 27 of the 186 (15%) patients with isolated relapsing ON and four of 60 patients (6.6%) with subsequent neurological involvement (i.e. transverse myelitis or brainstem or other cerebral syndromes) were MOG-IgG-positive. Among 14 patients in this study who presented with CRION, four (29%) were MOG-IgG-positive.⁴⁸ In other series, the percentage of MOG-IgG ON ranges between 6.3% in adults with inflammatory demyelinating disease of the CNS,⁵ to 27.5-66.7% in selected cohorts of patients with isolated ON and CRION.^{40,42,49} In a population-based prospective study of ON in Denmark, MOG-IgG was detected in two out of 51 patients (4%).⁵⁰

Several retrospective studies have described the various clinical manifestations of MOGAD during the past few years.^{8,13,22,28,36,38,51,52} The respective distribution of MOG-IgG ON and its clinical characteristics are summarized in Table 1.

Recent data suggest that ON as the initial symptom of MOGAD might be more frequent in the Asian versus the white population. A retrospective study that compared the clinical features of MOG-IgG ON between Asian and white races found it was present in 99% of Asian patients and 82% of white patients.⁵³ In a Chinese study, 75% of MOGAD patients presented with isolated ON at disease onset, and 83.3% experienced at least one episode of ON during the disease course.⁵⁴ However, in another study from Japan, the site of the first attack was the optic nerve in 17 out of 42 patients (40.5%).⁴¹

TABLE 1 Clinical course and characteristics of MOG-IgG optic neuritis in adults

	Study (reference)						
	Jarius et al ^{9,53}	Coco-Calvo et al ³⁷	Sepúlveda et al ⁵²	Jurynczyk et al ²⁹	Ramanathan et al ⁸⁹	De Mol et al ²³	Chen et al ¹⁴
Epidemiology							
Patient population	Adults and children with MOGAD	Adults with MOGAD	Adults with MOGAD	Adults and children with MOGAD	Adults and children with MOGAD	Adults and children with MOGAD	MOG-IgG ON
No. patients with MOG-IgG Abs/total no. patients (%)	50	197	56	252 (230 adults, 22 children)	59 (26 adults) *Numbers below refer to adults only	92 (27 adults) *Numbers below refer to adults only	87
% females	37 (74%)	97 (49.2%)	37 (66%)	143 (57%)	18 (69%)	12 (44%)	50 (57%)
Ethnicity	49 Caucasian (98%)	183 white (93%)	54 Caucasian (96.5%)	19 Caucasian (73%)	22 Caucasian (81%)	73 white (84%)	
Duration of observation	Median 26 months in monophasic disease course and 53 months in relapsing course	Median 15.77 months (range 1–556.64 months)	Median 43 months (range 4–554 months)	Median 39 months (range 12–288 months)	Median 20.2 months (IQR 11.3–43.0)	Median 2.9 years (range 0.6–24 years)	
Course of ON							
No. patients with ON (%)	44 (88%)	120 (60.9%)	39 (69.6%)	138 (55.5%)	19 (73%)	17 (63%)	71 (82%)
ON at disease onset	37 (74%)	72 (36.5%)	6 (10.7%)	153 of unilateral ON (53%) and 108 of bilateral ON (43%)	10 (12%)	26 (30%)	
Monophasic ON (%)	9 (20.5%)	34 (17.2%)	27 (48.2%)	22 at disease onset (9%)			
Recurrent isolated ON (%)	13 (29.5%)	16 at disease onset (8%)	5 at disease onset (9%)				
CRION (%)	5 (10%) at disease onset, 22 (44%) during disease course		3 (5%)				14 (16%)
ON associated with other neurological manifestations (%)							
Clinical characteristics of ON							
Optic disc swelling (%)					18 (69%)		36/42 at presentation (86%)
Bilateral ON (%)	15 (40.5%) at disease onset, 22 (44%) during disease course	50 at disease onset (41.6%)	10 patients with isolated ON (37%)	60 at disease onset (24%)	11 at disease onset (42%)	7 at disease onset (58%)	33 (46%)

Abbreviations: MOG, myelin oligodendrocyte glycoprotein; MOGAD, myelin oligodendrocyte glycoprotein associated disease; ON, optic neuritis.

A recent meta-analysis of the prevalence of AQP4-IgG and MOG-IgG ON reports a prevalence of AQP4-IgG of 27% in the Asian population and 4% in non-Asian adult patients with isolated ON, whereas MOG-IgG seroprevalence was 20% in Asians and 8% in non-Asians.⁵⁵

3 | FREQUENCY OF BILATERAL ON

Simultaneous involvement of both optic nerves is characteristic of MOG-IgG ON and occurs more frequently than in other inflammatory optic neuropathies, including MS, NMOSD and idiopathic ON.^{37,46} In the study by Jitrapaikulsa et al, simultaneous bilateral ON was reported in 14 of 27 (52%) of MOG-IgG ON, in comparison with three of 24 (13%) of AQP4-IgG positive ON, two of 25 (8%) of MS and 23 of 110 (21%) of double-seronegative patients.⁴⁸ Jarius et al reported bilateral ON in 15 of 50 patients (30%) at disease onset, and in 51.2% during the disease course.⁸ De Mol et al reported bilateral ON in 58% of adult MOGAD patients who presented with ON at disease onset.²² Juryncyk et al reported bilateral ON in 24% of MOGAD at disease onset.²⁸ In the series by Sepúlveda et al, simultaneous bilateral ON was observed in 37% of the patients with isolated ON.⁵¹ Coco-Calvo et al reported bilateral ON in 50 of 120 (41.7%) of MOGAD who presented with ON at disease onset.³⁶ Zhao et al reported bilateral involvement at the initial presentation in 45% of MOG-IgG and 37.8% of the AQP4-IgG groups.⁵⁶ Ramanathan et al reported bilateral ON in nine of 13 (69.2%) AQP4-IgG-negative patients. In one patient, bilateral ON was followed by transverse myelitis, whereas in the other eight patients, the ON was isolated.¹⁴ In another series by Ramanathan et al, bilateral ON was reported in 42% of patients at disease onset.³⁸ Similar findings were reported in a French retrospective multicenter study of MOGAD patients who experienced at least one episode of ON, in which 19 of 47 patients (40.4%) presented with bilateral simultaneous ON.⁵⁷ Chen et al reported bilateral simultaneous ON during at least one of the attacks of ON in 32 of 86 patients (37%).¹³

4 | ANTERIOR ON: NEURITIS ASSOCIATED WITH OPTIC DISC SWELLING

The presence of optic disc swelling is another salient characteristic of MOG-IgG ON (Fig. 1). Liu et al reported optic disc swelling in 21 of 31 (67.7%) of MOG-IgG ON versus 22 of 67 (32.8%) of AQP4-IgG ON.⁵⁸ Zhao et al reported optic disc swelling in 80% of MOG-IgG ON and 20% of AQP4-IgG ON,⁵⁹ and Zhou et al found optic disc swelling in all 10 MOGAD patients who had attacks of ON during the disease course.⁵⁴ Ramanathan et al reported prominent optic disc swelling at the presentation of ON.¹⁴ Of 19 adult patients with ON who had available fundoscopic examination, optic disc swelling was observed in 18 (95%).³⁸ Chen et al noted disc edema in 36 of 42 patients (86%) with available fundoscopic examination. In 52% of the cases, the disc edema was rated as moderate or severe.¹³ Biotti et al reported optic nerve head swelling in 70.2% of the events. In four cases in this series, peripapillary hemorrhages accompanied the presence of optic disc swelling.⁵⁷

5 | PAIN CHARACTERISTICS AT PRESENTATION ARE TYPICAL OF MOG-IgG ON

Periorbital pain in the affected eye aggravated by eye movements is a common symptom in many types of inflammatory demyelinating ON. The rate of associated pain in MOG-IgG ranges between 80% and 90%,^{13,54,57} which is comparable to the frequency of pain in MS and AQP4-IgG-positive ON.^{60,61} However, MOGAD patients typically describe a more severe pain⁵⁰ and a diffuse headache or facial pain, as well as other types of pain. In a recent study that compared pain characteristics in MOGAD and AQP4-IgG-positive NMOSD, 50% of patients with MOGAD suffered mainly from headache or neck pain, including tension-type headache (in association with recurrent ON), occipital neuralgia, cervicogenic-like headache and migraine that was aggravated in the context of MOGAD. In contrast, AQP4-IgG-positive NMOSD patients

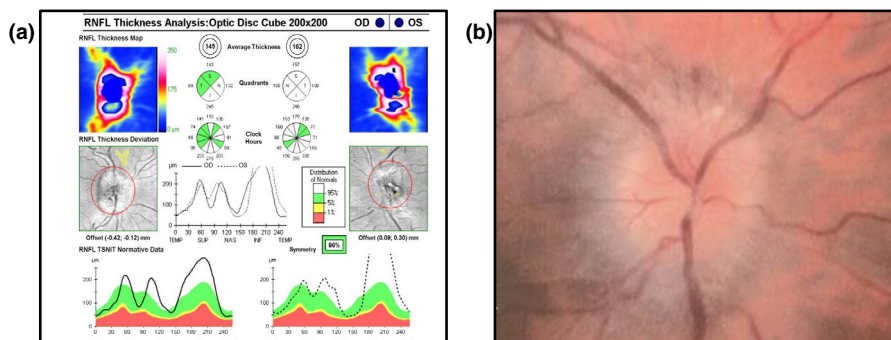


FIGURE 1 (A) Retinal nerve fiber layer thickness and (B) color photograph of optic disc swelling in acute immunoglobulin G serum antibodies against myelin oligodendrocyte glycoprotein (MOG-IgG) optic neuritis. (A) A spectral domain (SD-HD) Cirrus OCT 4000-2713 (Cirrus HD; Carl Zeiss Meditec, Jena, Germany) of the optic nerve reveals bilateral swelling of the retinal nerve fiber layer. (B) A color photograph of the optic disc revealing 360° disc edema. OD, oculus dexter (right eye); OS, oculus sinister (left eye); RNFL, retinal nerve fiber layer

suffered mainly from myelitis-related neuropathic pain (82.6%), whereas headache and neck pain were reported less frequently (21.7%).⁶² In another study that evaluated the frequency and characteristics of headaches in MOG-IgG ON, 64 of 129 (49.6%) of the patients had at least one episode of ON associated with headaches. MOG-IgG-related ON is often associated with a florid intraorbital and periopic inflammation of the anterior portion of the optic nerve, likely to involve meninges and nociceptive fibers around the optic nerve.^{8,63} The severity of the inflammation and the extent of the edema might explain the frequent and often severe headache that precedes the visual deficit in MOGAD, sometimes misdiagnosed as migraine.⁶⁴ This clinical constellation might be a differentiating feature compared with other forms of ON and should therefore trigger MOG-IgG testing.

6 | ASSOCIATED AUTOIMMUNE DISORDERS ARE UNCOMMON IN MOGAD

Autoimmune comorbidities and seropositivity for other autoantibodies that are relatively common in AQP4-IgG-positive NMOSD are less frequent in MOGAD.^{30,65,66} Concomitant circulating autoantibodies are usually not detected in the context of MOGAD.^{8,40,47,59} Elevated serum autoantibodies have been occasionally reported, including anti-thyroid peroxidase and anti-thyroglobulin, anti-nuclear antibody, anti-LGI1, and anti-NMDA.^{38,54,58,67,68}

7 | CEREBROSPINAL FLUID AND BLOOD TESTS IN MOGAD

MOG is a glycoprotein that is selectively expressed on oligodendrocytes and is one of the constituents of the myelin sheath. Its presence on the myelin sheath's surface makes it a target for antibody production and autoimmune responses in the CNS.³³ Previous antibody-detecting assays were targeted to linear or denatured forms of the glycoprotein and identified non-pathogenic antibodies that were erroneously associated with MS. The current CBAs use the full-length conformationally intact MOG construct and a secondary class 1 IgG-binding antibody. The current CBAs include live CBAs, in-house fixed CBAs and commercial fixed CBAs. All CBAs have been shown to have high sensitivity and specificity in patients with a non-MS demyelinating CNS phenotype.^{4,69}

The simultaneous occurrence of MOG-IgG and AQP4-IgG in the same patients is extremely uncommon. In most studies, double seropositivity was not observed.³⁶ Nakajima et al reported a patient with gastric cancer who tested positive for both antibodies,⁴⁰ and Zhao et al reported two patients with double seropositivity at the initial stage, who became MOG-IgG negative after 3 months.⁵⁶ In a large retrospective cohort study that examined serum samples of 15 598 patients, just 10 (0.06%) had dual seropositivity. In all cases, the titers of AQP-IgG were higher than the MOG-IgG titers.⁷⁰

Lumbar puncture might show a pleocytic cerebrospinal fluid (CSF; >5 cells/ μ L) and elevated protein count. CSF pleocytosis in MOG-IgG ON is reported in 5–47% of the cases, and is usually mild in isolated ON cases.^{38,54,57,59} When MOG-IgG ON occurs in combination with other neurological manifestations, the CSF white blood cell count might reach higher levels of >50 cells/ μ L^{13,51} or even >100 cells/ μ L.^{8,28} Elevated protein count is reported in 37–54.5% of patients.^{13,38,54} Intrathecal synthesis of oligoclonal bands and elevated IgG index, typically observed in MS, are much less frequent in MOGAD (and AQP4-IgG-positive NMOSD), where their occurrence has been reported in 0–28%.^{8,13,22,30,36,38,48,54,57,59} A recent study investigating the CSF profile in 100 adult MOGAD patients confirmed these observations.⁷¹ In addition, the measles–rubella–varicella zoster antibody index (MRZ reaction) in the CSF, considered a specific laboratory marker of MS, was absent in all MOGAD patients with available data.⁷¹

A few case series have reported elevated CSF opening pressure during MOG-IgG ON.^{54,72} As MOG-IgG is often bilateral and associated with prominent disc swelling, it might be initially misdiagnosed as idiopathic increased intracranial hypertension.⁷²

8 | RADIOLOGICAL CHARACTERISTICS

Several orbital magnetic resonance imaging (MRI) features have been shown to characterize MOG-IgG ON and help differentiate it from other forms of ON. Abnormal signal of the affected optic nerve during the acute attack is observed in most patients, with variable proportions ranging between 58.3% and 93.3% reported in different series.^{8,40,59,73} Typical findings include T2-hyperintense lesions with swelling of the optic nerve and contrast enhancement.^{8,13,33,57}

Although longitudinally extensive involvement of the optic nerve is typical for AQP4-IgG-positive NMOSD, it has been reported in comparable proportions in MOGAD.¹³ Ramanathan et al compared the radiological characteristics of MOG-IgG-, AQP4-IgG- and MS-related ON patients during the first clinical presentation. Longitudinal ON, defined as the involvement of at least two contiguous optic nerve segments, was observed in 18 of 19 (95%) of MOG-IgG ON and 11 of 11 (100%) AQP4-IgG ON.⁶³

Although both MOG-IgG and AQP4-IgG ON might present with longitudinally extensive ON, the segment of the optic nerve involved varies between these two conditions. Zhao et al reported the involvement of the retrobulbar portion of the optic nerve in the majority (80%) of MOG-IgG patients, whereas in AQP4-IgG ON, the canalicular part of the optic nerve was more common (57.8%).⁵⁹ In the series by Ramanathan et al, a retrobulbar involvement was observed in 53% of MOG-IgG ON versus 27% of AQP4-IgG ON and 23% of MS-ON, whereas the involvement of the intracranial portion of the optic nerve was observed more frequently in AQP4-IgG-positive ON.⁶³ The involvement of the anterior part of the visual pathway in MOG-IgG ON that is often associated with the clinical finding of optic disc swelling might have a radiological correlate. Such findings of radiological swelling

of the optic nerve head were observed in 10 of 19 (53%) MOG-IgG-positive patients.⁶³ In the French series reported by Biotti et al, the retrobulbar segment of the optic nerve was involved in 93.3% of the cases.⁵⁷

Perineural enhancement of the soft tissue around the optic nerve is another characteristic of MOG-IgG ON. In the series by Kim et al, such findings were reported in 33% of the cases⁵; Jarius et al reported a similar finding in 39.3% of the patients⁸; in the series by Akaishi et al, an extension of the inflammation with contrast enhancement of the intraorbital tissue was observed in 47.1% of patients.⁷⁴ Chen et al observed perineural enhancement during at least one ON attack in 50% of the cases,¹³ whereas in the series by Zhou et al and by Lee et al, perineural enhancement was observed in 75% and 91.6% of the cases, respectively.^{42,54} Other intracranial anatomical parts of the visual pathway, that is, the optic chiasm and optic radiation, are involved more typically in AQP4-IgG-positive NMOSD, but might be involved in MOGAD as well. While Ramanathan et al reported these findings to be very uncommon in MOGAD patients (5% of MOGAD had chiasmatic lesions and 0% had bilateral involvement of the optic tracts, in comparison with 64% and 45% of AQP4-IgG positive NMOSD, respectively),⁶³ Chen et al reported involvement of the optic chiasm in 12% and optic tract involvement in 2%,¹³ and Akaishi et al reported sparing of the optic chiasm in MOG-IgG ON,⁷⁴ Their occurrence was higher in other series: Etemadifar et al reported chiasmatic lesions in 25%, and post-chiasmatic lesions of the visual pathway in 16.6% of MOG-IgG ON during the first event;⁷³ Zhao et al reported chiasmatic lesions in 15% and optic radiation lesions in 5% of MOG-IgG ON.⁵⁹

Other than the visual pathway, brain abnormalities have been reported in patients with MOG-IgG ON as well. In the series by Zhou et al, brain lesions were present in eight of 12 (66.7%) MOGAD patients.⁵⁴ Similar abnormalities were less frequent in other series, ranging between 12.4% and 37%.^{5,36,40,48,57,63} When present, the brain abnormalities in MOGAD are usually described as non-specific or non-typical for MS.^{75,76} In some cases, large lesions that involve the white matter and internal capsule, multiple cortical and subcortical lesions, and thalamic and pontine lesions might be observed.^{5,36,63} Active lesions have been shown to often present as gadolinium-enhancing, poorly delineated with a "cloud-like" morphology.⁷⁷ Some authors described several imaging features that might help to distinguish between MOGAD- and AQP4-positive NMOSD. These include the presence of cortical lesions and juxtacortical brain lesions that are more frequently observed in MOGAD, whereas the involvement of the area postrema, which is typical for NMOSD, is rare in MOGAD.^{78,79} In contrast, others found an overlapping pattern of brain lesions in the two conditions.⁸⁰

9 | ADVANCED MAGNETIC RESONANCE IMAGING CHARACTERISTICS

Due to the difference in cellular targets between AQP4-IgG and MOG-IgG, it would be expected that conventional MRI

characteristics would differ between the two disease entities. However, there has yet to be a clear distinction found.^{35,81}

Evaluation of advanced MRI metrics in NMOSD and MOGAD could offer more discriminatory power, and elucidate microstructural differences in the CNS between patients with NMOSD and MOGAD. Recently, Schmidt et al showed that despite no differences in the whole brain and deep grey matter volumes of the brain between MOG-IgG-seropositive patients from healthy controls, a decreased parallel diffusivity in the whole brain diffusion tensor analysis was found.⁸² Meanwhile, no differences in diffusion-weighted MRI metrics were found between AQP4-IgG-seropositive NMOSD patients and healthy controls, indicating that white matter tracts are more affected in MOGAD than in AQP4-IgG-positive patients.

Another study found that optic chiasm height and area measured from standard 3-D T1-weighted brain MRIs were significantly decreased in AQP4-IgG-positive patients with and without previous ON compared with healthy controls.⁸³

Aside from localized damage, Chien et al found that in AQP4-IgG-positive patients, deep grey matter volumes are decreased with an increased history of combined NMOSD-related attack counts and disease duration.⁸⁴ There are still discrepancies in findings regarding deep grey matter volume differences in AQP4-IgG-seropositive NMOSD patients and healthy controls, where some studies find no significant differences,⁸⁵ whereas other studies have found some decreases in volumes.^{82,84} There is evidence that deep grey matter involvement does occur, especially in children with MOG-IgG-seropositive autoimmune encephalitis.⁸⁶ These findings increase the likelihood that deep grey matter regions of the brain are affected in adult MOGAD as well and should be further studied.

The discussed recent methods of evaluating advanced MRI metrics are yet to be studied in large adult MOGAD cohorts, and it remains to be seen if advanced MRI metrics can detect microstructural changes due to ON in these patients.

10 | OPTICAL COHERENCE TOMOGRAPHY CHARACTERISTICS

Optical coherence tomography (OCT) is an interferometric technique using low-coherent light to produce cross-sectional images of the retina. It thereby allows us to qualitatively and quantitatively analyze the three anterior neurons of the afferent visual system, as well as their degeneration; for example, in MOG-IgG-associated ON. In particular, the peripapillary retinal nerve fiber layer thickness (pRNFL)—consisting of unmyelinated axons of retinal ganglion cells—and the macular ganglion cell layer itself (mostly measured in combination with the adjacent inner plexiform layer as ganglion cell/inner plexiform) have become reliable OCT markers for retinal neurodegeneration dependent and independent of ON.⁸⁷

During the acute stage of MOG-ON, typical disc swelling is accompanied by corresponding pRNFL swelling seen on OCT (Fig. 1). After the acute stage of ON, retinal neurodegeneration ensues (measured by pRNFL and ganglion cell/inner plexiform). MOG-IgG-seropositive

patients are suggested to suffer from less severe retinal neurodegeneration per ON attack than AQP4-IgG-positive patients.^{74,86,88} However, as MOGAD typically manifests with frequent ON attacks, accumulated thinning might ensue. Some patients reach pRNFL values <30 μm , after which further neurodegeneration is hard to detect due to flooring effects.^{89,90} Furthermore, one publication suggests that MOG-IgG-associated ON—as MS-associated ON—commonly leads to a temporal preponderance of retinal neurodegeneration.⁹¹ The outer retinal layers were only sparsely investigated, but seemed unaffected by MOG-IgG ON.⁹² OCT studies in acute ON or with longitudinal analyses are also sparse in MOGAD. One study in a combined cohort of eyes with and without a history of ON found a progressive pRNFL, but not ganglion cell/inner plexiform thinning in MOG-IgG-seropositive patients,⁹³ suggesting a potential additional ON-unrelated retinal pathology in MOGAD.

OCT technology is under constant development; acquisition, as well as postprocessing, is undergoing fast advancements. Novel OCT technologies allow, for example, the incorporation of volumetric angiography images called OCT angiography (OCTA). Only one study applying OCTA in MOG-IgG ON so far showed a decrease in retinal vessel density.⁹⁴

11 | SEVERITY OF VISUAL LOSS AT NADIR

The decrease in visual acuity during the acute stage of MOG-IgG ON is usually severe. In most series where this information is available, the visual loss at nadir was reported between counting finger and hand movements.^{5,13,48,54,58,95} This finding is comparable to that observed in AQP4-IgG positive ON and is significantly worse than that observed in MS.

12 | MOG-IGG ON HAS A UNIQUELY RAPID RESPONSE TO IV METHYLPREDNISOLONE

Acute therapy for all types of ON consists of intravenous methylprednisolone administered at a daily dosage of 500–1000 mg for 3–7 days, followed by oral prednisone.³³ The response to corticosteroid therapy is, in most cases of MOG-IgG ON, very fast and prominent. Zhou et al reported improvement of visual acuity to 0.8–1.0 after high-dose intravenous methylprednisolone in seven of 10 patients (70%)⁵⁴; Nakajima et al reported a complete response to steroids in seven of eight patients (87.5%)⁴⁰; Biotti et al observed rapid and dramatic response to steroids in most cases.⁵⁷

13 | STEROID-CESSATION RELAPSES ARE TYPICAL OF MOG-IGG ON

Although the response to steroids is usually rapid, MOG-IgG ON might show a CRION-like clinical course characterized by

steroid-dependency; that is, a tendency to recur after steroid cessation or during tapering of oral steroids. In the series by Sepúlveda et al, three of 21 patients (14%) with recurrent ON presented CRION features.⁵¹ Liu et al reported that 11 of 31 patients (35.5%) with MOG-IgG ON relapsed when the steroid dose was reduced.⁵⁸ Zhou et al reported a relapse during the reduction process of oral steroids or shortly (<1 month) after steroid cessation in five of six patients (83.3%).⁵⁴ Ramanathan et al documented 103 relapses following 146 episodes treated with a short course of oral prednisolone taper. In 41 episodes, the relapse occurred toward the end of the taper, and in 63 episodes, relapse occurred after a mean duration of 2 months from treatment cessation.³⁸

14 | PREVENTIVE IMMUNOTHERAPY

The topic of preventive immunotherapy in MOGAD is still a matter of debate. This is primarily driven by several observations that reported a relatively low relapse risk in MOGAD, therefore suggesting that chronic immunotherapy might not be required.^{24,37} However, other studies report similar relapse rates in MOGAD as in NMOSD,⁴⁸ as well as a significant risk of disability accumulation.^{5,8} Some studies have shown a correlation between persistent MOG-IgG seropositivity and the risk of relapse. Jurynczyk et al reported that 41 of 57 patients (72%) with repeated MOG Abs testing at least 6 months apart remained seropositive. A total of 24 of the 41 patients (59%) who remained seropositive had a clinical relapse, whereas all those who became seronegative over time (14 of 57; 25%) were relapse-free.²⁸ Hyun et al obtained longitudinal serum samples from 10 MOGAD patients treated with maintenance immunotherapy. Two of five patients (40%) in whom MOG-IgG Abs remained positive had clinical relapses, whereas none of those who became seronegative had further relapses.⁹⁶ López-Chiriboga et al evaluated the risk of relapse in patients with an initial diagnosis of ADEM. Among 20 adult patients, eight showed persistent MOG-IgG seropositivity, and four had transient MOG-IgG seropositivity. Seven of eight patients (87.5%) with persistent MOG-IgG seropositivity and one of four (25%) with transient MOG-IgG seropositivity had further relapses of ON ($n = 7$) or myelitis ($n = 1$).⁹⁷ Coco-Calvo et al evaluated the relationship between MOG-IgG titers at the time of initial disease presentation and disease course. Higher titers were associated with a more severe initial presentation, but were not predictive of higher relapse risk.⁹⁸

Currently, there is no consensus on whether to start immunosuppressive treatment after the first clinical presentation in MOGAD. In an international survey distributed to clinicians who treat MOGAD, 31 of 51 (60%) experts reported they usually start maintenance immunotherapy after the first attack, and 48 of 52 (92%) would start a maintenance therapy after two or more attacks.⁹⁹ Jurynczyk et al recommend continuing low-dose oral corticosteroids for 6 months after the initial attack and tailor the future therapeutic decision based on repeated MOG-IgG testing. In the case the MOG-IgG becomes negative, the patient can be weaned off therapy, whereas in the case of persistent seropositivity, continuation with oral corticosteroids for an additional

6 months and retesting the MOG-IgG serostatus or treatment with a steroid-sparing immunosuppressive agent is recommended.³³ Other authors consider the recovery from the initial attack and suggest to start a maintenance immunosuppressive therapy in the case of significant disability from the onset attack.^{26,100} Hegen and Reindl proposed a combined approach based on an individual risk-benefit evaluation that takes into consideration the severity and recovery from the acute attack, and the persistency of serum MOG-IgG.³⁴

The current therapeutic approach for relapse prevention in MOGAD is largely adopted from NMOSD and focuses on steroid-sparing agents, such as azathioprine, mycophenolate mofetil and rituximab.^{99,101-103} However, in contrast to AQP4-IgG-positive NMOSD, where rituximab is considered highly efficacious, there are several reports of lower efficacy in MOGAD.^{8,104,105} Recent reports suggest intravenous immunoglobulins, which has been proved effective in reducing relapse rate and improving neurological disability in pediatric MOGAD,¹⁰⁶ might be an effective therapeutical option in adult MOGAD as well.^{107,108} Tocilizumab, an anti-interleukin-6 agent that has been shown to reduce the relapse rate in NMOSD, has also shown similar efficacy in a few adult MOGAD patients.^{109,110}

The common disease-modifying therapies used for relapse prevention in MS are ineffective in NMOSD and are therefore not recommended in MOGAD.^{33,100} This concept is supported by several reports of the ineffectiveness of classic disease-modifying therapies (i.e. interferon-beta, fingolimod and natalizumab) in MOGAD.^{8,40,41,105}

15 | RISK OF PERMANENT VISUAL DISABILITY FROM ON IN MOGAD

Although some studies report a more favorable outcome of MOG-IgG ON compared with AQP4-IgG positive ON, others have shown that a subset of patients might have a permanent visual disability.^{24,36,37,111} Jarius et al documented visual impairment in 21 of 38 (55.3%) of MOG-IgG patients with a history of ON and available outcome data. A total of 14 of the 38 patients (36.8%) were either functionally blind at last follow up in at least one eye or had a severe visual impairment (visual acuity [decimal] >0.1 and ≤0.5)⁸; Sepúlveda et al reported severe visual disability in seven of 27 patients (26%) with isolated ON. Recurrent clinical course and bilateral ON were associated with worse visual outcomes⁵¹; Matsuda et al documented a permanent visual field deficit in 14 of 18 patients (77.8%) with MOG-IgG ON¹¹²; Jurynczyk et al reported permanent visual disability (defined as visual acuity of 6/36 or worse in at least one eye at last follow up) in 12 of 75 patients (16%). Interestingly, all patients with permanent visual loss had ON during the onset attack, and in nine of them, the visual disability resulted from the onset attack.²⁸ In the series by Kim et al, severe visual disability resulted from the first attack in three of four patients with severe sequelae.⁵

Some data suggest that early initiation of corticosteroid treatment in MOG-IgG ON is associated with a better long-term visual outcome,¹¹³ as well as better preservation of the retinal nerve fiber layer observed in OCT.¹¹⁴

16 | DISCUSSION

The growing data accumulated during the past years support the notion that MOGAD is a clinical entity distinct from MS and NMOSD. ON is the most common clinical manifestation of MOGAD. In this review, we delineate the distinctive clinical and radiological characteristics of MOG-IgG ON. The information provided should enable clinicians who face a patient with ON to raise an early diagnostic suspicion of MOG-IgG.

The early recognition of MOG-IgG ON might have important therapeutic and prognostic implications. Although some studies suggest that MOG-IgG ON might have a better clinical recovery and more favorable visual outcomes than AQP4-IgG positive ON, sustained visual impairment has been reported in MOGAD.^{8,14,51} These differences in visual outcomes after the acute event might evolve from lack of data on the timing of intravenous methylprednisolone from attack onset. The fact that early initiation of corticosteroid treatment has been shown to correlate with a better long-term visual outcome suggests that the permanent visual disability in MOG-IgG ON might result from delayed recognition and lack of tailored management aimed at offering hyperacute treatment and preventing the typical relapse of visual loss after steroid cessation. Similar observations have been previously reported in another cohort of patients with relapsing isolated ON and CRION, in which a hyperacute corticosteroid treatment was associated with better visual outcomes.¹¹⁵ Although the MOG-IgG status of the patients in this cohort is not available, it seems plausible to assume that at least some of them were MOG-IgG positive. In animal models, it has been shown that the inflammatory process precedes the axonal degeneration by 2 days,¹¹⁶ and that the irreversible axonal damage starts as early as 5–7 days from the inflammatory attack.¹¹⁷ Taken together, these notions highlight the importance of early recognition and prompt initiation of treatment in MOG-IgG ON to prevent permanent axonal loss and visual disability. The short course of oral steroids prescribed to MS-related ON patients should not be given to MOGAD-ON patients, in whom undertreated relapses might jeopardize the visual outcome. However, the current data supporting this claim are based on retrospective studies and small cohorts. Larger, prospective trials are required to clarify the relationship between the timing of treatment and visual outcome. A large prospective study that will address the possible impact of early corticosteroid therapy on the long-term visual disability in ON is currently being designed.

These unique characteristics of treatment response underscore the importance of early recognition of MOG-IgG ON.

17 | CONCLUSIONS

ON is the most common clinical manifestation of MOGAD. MOG-IgG often presents with simultaneous involvement of both optic nerves, is painful and is associated with prominent disc swelling. Orbital MRI shows an extensive abnormal signal of the anterior portion of the optic nerve and is associated with contrast enhancement of the

surrounding soft tissue. The visual deficit during the acute stage is severe, and although many patients show a good response to corticosteroids, many present with a typical relapse once short-course steroids are stopped, potentially compromising visual outcomes. Prospective trials are warranted to define the role of hyperacute steroids and the optimal duration of treatment in acute MOG-IgG ON. Other urgent research needs to include identifying patients at high risk for relapses who would require maintenance immunotherapy and delineation of the most appropriate immunosuppressive regimen.

CONFLICT OF INTEREST

The authors declare no conflict of interest.

ACKNOWLEDGMENT

Open access funding enabled and organized by Projekt DEAL.

ORCID

Itay Lotan  <https://orcid.org/0000-0002-4015-9783>

REFERENCES

- Narayan R, Simpson A, Fritsche K, Salama S, Pardo S, Mealy M, et al. MOG antibody disease: a review of MOG antibody seropositive neuromyelitis optica spectrum disorder. *Mult Scler Relat Disord*. 2018;25:66–72.
- Ramanathan S, Dale RC, Brilot F. Anti-MOG antibody: the history, clinical phenotype, and pathogenicity of a serum biomarker for demyelination. *Autoimmun Rev*. 2016;15(4):307–24.
- Reindl M, Di Pauli F, Rostasy K, Berger T. The spectrum of MOG autoantibody-associated demyelinating diseases. *Nat Rev Neurol*. 2013;9(8):455–61.
- Waters P, Woodhall M, O'Connor KC, Reindl M, Lang B, Sato DK, et al. MOG cell-based assay detects non-MS patients with inflammatory neurologic disease. *Neurol Neuroimmunol Neuroinflamm*. 2015;2(3):e89.
- Kim SM, Woodhall MR, Kim JS, Kim SJ, Park KS, Vincent A, et al. Antibodies to MOG in adults with inflammatory demyelinating disease of the CNS. *Neurol Neuroimmunol Neuroinflamm*. 2015;2(6):e163.
- Spadaro M, Gerdes LA, Krumbholz M, Ertl-Wagner B, Thaler FS, Schuh E, et al. Autoantibodies to MOG in a distinct subgroup of adult multiple sclerosis. *Neurol Neuroimmunol Neuroinflamm*. 2016;3(5):e257.
- Cobo-Calvo Á, d'Indy H, Ruiz A, Collongues N, Kremer L, Durand-Dubief F, et al. Frequency of myelin oligodendrocyte glycoprotein antibody in multiple sclerosis: a multicenter cross-sectional study. *Neurol Neuroimmunol Neuroinflamm*. 2020;7(2):e649.
- Jarius S, Ruprecht K, Kleiter I, Borisow N, Asgari N, Pitarokoil K, et al. MOG-IgG in NMO and related disorders: a multicenter study of 50 patients. Part 2: epidemiology, clinical presentation, radiological and laboratory features, treatment responses, and long-term outcome. *J Neuroinflammation*. 2016;13(1):280.
- Hamid SHM, Whittam D, Mutch K, Linaker S, Solomon T, Das K, et al. What proportion of AQP4-IgG-negative NMO spectrum disorder patients are MOG-IgG positive? A cross sectional study of 132 patients. *J Neurol*. 2017;264(10):2088–94.
- Jarius S, Paul F, Weinshenker BG, Levy M, Kim HJ, Wildemann B. Neuromyelitis optica. *Nat Rev Dis Primers*. 2020;6(1):85.
- Anis S, Regev K, Pittock SJ, Flanagan EP, Alcalay Y, Gadot A. Isolated recurrent myelitis in a persistent MOG positive patient. *Mult Scler Relat Disord*. 2019;30:163–4.
- Dos Passos GR, Oliveira LM, da Costa BK, Apostolos-Pereira SL, Callegaro D, Fujihara K, et al. MOG-IgG-associated optic neuritis, encephalitis, and myelitis: lessons learned from neuromyelitis optica spectrum disorder. *Front Neurol*. 2018;9:217.
- Chen JJ, Flanagan EP, Jitprapaikulsan J, Lopez-Chiriboga ASS, Fryer JJ, Leavitt JA, et al. Myelin oligodendrocyte glycoprotein antibody-positive optic neuritis: clinical characteristics, radiologic clues, and outcome. *Am J Ophthalmol*. 2018;195:8–15.
- Ramanathan S, Reddel SW, Henderson A, Parratt JD, Barnett M, Gatt PN, et al. Antibodies to myelin oligodendrocyte glycoprotein in bilateral and recurrent optic neuritis. *Neurol Neuroimmunol Neuroinflamm*. 2014;1(4):e40.
- Budhram A, Mirian A, Le C, Hosseini-Moghaddam SM, Sharma M, Nicolle MW. Unilateral cortical FLAIR-hyperintense lesions in anti-MOG-associated encephalitis with seizures (FLAMES): characterization of a distinct clinico-radiographic syndrome. *J Neurol*. 2019;266(10):2481–7.
- Salama S, Khan M, Pardo S, Izbudak I, Levy M. MOG antibody-associated encephalomyelitis/encephalitis. *Mult Scler*. 2019;25(11):1427–33.
- Wang L, Zhang Bao J, Zhou L, Zhang Y, Li H, Li Y, et al. Encephalitis is an important clinical component of myelin oligodendrocyte glycoprotein antibody associated demyelination: a single-center cohort study in Shanghai, China. *Eur J Neurol*. 2019;26(1):168–74.
- Ogawa R, Nakashima I, Takahashi T, Kaneko K, Akaishi T, Takai Y, et al. MOG antibody-positive, benign, unilateral, cerebral cortical encephalitis with epilepsy. *Neurol Neuroimmunol Neuroinflamm*. 2017;4(2):e322.
- Matesanz S, Kotch C, Perrone C, Waanders AJ, Hill B, Narula S. Expanding the MOG phenotype: Brainstem encephalitis with punctate and curvilinear enhancement. *Neurol Neuroimmunol Neuroinflamm*. 2019;6(6):e619.
- Cobo-Calvo A, Ayrignac X, Kerschen P, Horellou P, Cotton F, Labauge P, et al. Cranial nerve involvement in patients with MOG antibody-associated disease. *Neurol Neuroimmunol Neuroinflamm*. 2019;6(2):e543.
- Nagabushana D, Shah R, Pendharkar H, Agrawal A, Kulkarni GB, Rajendran S, et al. MOG antibody seropositive aseptic meningitis: a new clinical phenotype. *J Neuroimmunol*. 2019;333:476960.
- de Mol CL, Wong Y, van Pelt ED, Wokke B, Siepman T, Neuteboom RF, et al. The clinical spectrum and incidence of anti-MOG-associated acquired demyelinating syndromes in children and adults. *Mult Scler*. 2020;26(7):806–14.
- O'Connell K, Hamilton-Shield A, Woodhall M, Messina S, Mariano R, Waters P, et al. Prevalence and incidence of neuromyelitis optica spectrum disorder, aquaporin-4 antibody-positive NMOSD and MOG antibody-positive disease in Oxfordshire, UK. *J Neurol Neurosurg Psychiatry*. 2020;91(10):1126–8.
- Sato DK, Callegaro D, Lana-Peixoto MA, Waters PJ, de Haidar Jorge FM, Takahashi T, et al. Distinction between MOG antibody-positive and AQP4 antibody-positive NMO spectrum disorders. *Neurology*. 2014;82(6):474–81.
- Weber MS, Derfuss T, Metz I, Bruck W. Defining distinct features of anti-MOG antibody associated central nervous system demyelination. *Ther Adv Neurol Disord*. 2018;11:1756286418762083.
- Chen JJ, Bhatti MT. Clinical phenotype, radiological features, and treatment of myelin oligodendrocyte glycoprotein-immunoglobulin G (MOG-IgG) optic neuritis. *Curr Opin Neurol*. 2020;33(1):47–54.
- Borisow N, Mori M, Kuwabara S, Scheel M, Paul F. Diagnosis and treatment of NMO spectrum disorder and MOG-encephalomyelitis. *Front Neurol*. 2018;9:888.
- Jurynczyk M, Messina S, Woodhall MR, Raza N, Everett R, Roca-Fernandez A, et al. Clinical presentation and prognosis in MOG-antibody disease: a UK study. *Brain*. 2017;140(12):3128–38.

29. Reindl M, Waters P. Myelin oligodendrocyte glycoprotein antibodies in neurological disease. *Nat Rev Neurol*. 2018;15(2):89–102.
30. van Pelt ED, Wong YY, Ketelslegers IA, Hamann D, Hintzen RQ. Neuromyelitis optica spectrum disorders: comparison of clinical and magnetic resonance imaging characteristics of AQP4-IgG versus MOG-IgG seropositive cases in the Netherlands. *Eur J Neurol*. 2016;23(3):580–7.
31. Hacoen Y, Palace J. Time to separate MOG-Ab-associated disease from AQP4-Ab-positive neuromyelitis optica spectrum disorder. *Neurology*. 2018;90(21):947–8.
32. Jarius S, Paul F, Aktas O, Asgari N, Dale RC, de Seze J, et al. MOG encephalomyelitis: international recommendations on diagnosis and antibody testing. *J Neuroinflammation*. 2018;15(1):134.
33. Juryńczyk M, Jacob A, Fujihara K, Palace J. Myelin oligodendrocyte glycoprotein (MOG) antibody-associated disease: practical considerations. *Pract Neurol*. 2019;19(3):187–95.
34. Hegen H, Reindl M. Recent developments in MOG-IgG associated neurological disorders. *Ther Adv Neurol Disord*. 2020;13:1–20.
35. Zamvil SS, Slavin AJ. Does MOG Ig-positive AQP4-seronegative optospinal inflammatory disease justify a diagnosis of NMO spectrum disorder? *Neurol Neuroimmunol Neuroinflamm*. 2015;2(1):e62.
36. Cobo-Calvo A, Ruiz A, Maillart E, Audoin B, Zephir H, Bourre B, et al. Clinical spectrum and prognostic value of CNS MOG autoimmunity in adults: the MOGADOR study. *Neurology*. 2018;90(21):e1858–69.
37. Kitley J, Waters P, Woodhall M, Leite MI, Murchison A, George J, et al. Neuromyelitis optica spectrum disorders with aquaporin-4 and myelin-oligodendrocyte glycoprotein antibodies: a comparative study. *JAMA Neurol*. 2014;71(3):276–83.
38. Ramanathan S, Mohammad S, Tantsis E, Nguyen TK, Merheb V, Fung VSC, et al. Clinical course, therapeutic responses and outcomes in relapsing MOG antibody-associated demyelination. *J Neurol Neurosurg Psychiatry*. 2018;89(2):127–37.
39. Jelcic I, Hanson JVM, Lukas S, Weber KP, Landau K, Pless M, et al. Unfavorable structural and functional outcomes in myelin oligodendrocyte glycoprotein antibody-associated optic neuritis. *J Neuroophthalmol*. 2019;39(1):3–7.
40. Nakajima H, Motomura M, Tanaka K, Fujikawa A, Nakata R, Maeda Y, et al. Antibodies to myelin oligodendrocyte glycoprotein in idiopathic optic neuritis. *BMJ Open*. 2015;5(4):e007766.
41. Pandit L, Mustafa S, Nakashima I, Takahashi T, Kaneko K. MOG-IgG-associated disease has a stereotypical clinical course, asymptomatic visual impairment and good treatment response. *Mult Scler J Exp Transl Clin*. 2018;4(3):1–9.
42. Lee HJ, Kim B, Waters P, Woodhall M, Irani S, Ahn S, et al. Chronic relapsing inflammatory optic neuropathy (CRION): a manifestation of myelin oligodendrocyte glycoprotein antibodies. *J Neuroinflammation*. 2018;15(1):302.
43. Chalmoukou K, Alexopoulos H, Akrivou S, Stathopoulos P, Reindl M, Dalakas MC. Anti-MOG antibodies are frequently associated with steroid-sensitive recurrent optic neuritis. *Neurol Neuroimmunol Neuroinflamm*. 2015;2(4):e131.
44. Levy M. Expanding the spectrum of MOG antibody disease. *Mult Scler J*. 2020;26(4):515–6.
45. Willis MD, Robertson NP. Myelin oligodendrocyte glycoprotein antibody-associated disease: characterising clinical disease. *J Neurol*. 2018;265(8):1950–2.
46. Akaishi T, Sato DK, Takahashi T, Nakashima I. Clinical spectrum of inflammatory central nervous system demyelinating disorders associated with antibodies against myelin oligodendrocyte glycoprotein. *Neurochem Int*. 2019;130:104319.
47. Petzold A, Woodhall M, Khaleeli Z, Tobin WO, Pittock SJ, Weinshenker BG, et al. Aquaporin-4 and myelin oligodendrocyte glycoprotein antibodies in immune-mediated optic neuritis at long-term follow-up. *J Neurol Neurosurg Psychiatry*. 2019;90(9):1021.
48. Jitraprakulsan J, Chen JJ, Flanagan EP, Tobin WO, Fryer JP, Weinshenker BG, et al. Aquaporin-4 and myelin oligodendrocyte glycoprotein autoantibody status predict outcome of recurrent optic neuritis. *Ophthalmology*. 2018;125(10):1628–37.
49. Liu H, Zhou H, Wang J, Xu Q, Wei S. Antibodies to myelin oligodendrocyte glycoprotein in chronic relapsing inflammatory optic neuropathy. *Br J Ophthalmol*. 2019;103(10):1423–8.
50. Soelberg K, Jarius S, Skejoe H, Engberg H, Mehlsen JJ, Nilsson AC, et al. A population-based prospective study of optic neuritis. *Mult Scler*. 2017;23(14):1893–901.
51. Sepúlveda M, Armangue T, Martinez-Hernandez E, Arrambide G, Sola-Valls N, Sabater L, et al. Clinical spectrum associated with MOG autoimmunity in adults: significance of sharing rodent MOG epitopes. *J Neurol*. 2016;263(7):1349–60.
52. Jarius S, Ruprecht K, Kleiter I, Borisov N, Asgari N, Pitarokoil K, et al. MOG-IgG in NMO and related disorders: a multicenter study of 50 patients. Part 1: frequency, syndrome specificity, influence of disease activity, long-term course, association with AQP4-IgG, and origin. *J Neuroinflammation*. 2016;13(1):279.
53. Padungkiatsagul T, Chen JJ, Jindahra P, Akaishi T, Takahashi T, Nakashima I, et al. Differences in clinical features of myelin oligodendrocyte glycoprotein antibody-associated optic neuritis in white and Asian race. *Am J Ophthalmol*. 2020;219:332–40.
54. Zhou L, Huang Y, Li H, Fan J, Zhangbao J, Yu H, et al. MOG-antibody associated demyelinating disease of the CNS: a clinical and pathological study in Chinese Han patients. *J Neuroimmunol*. 2017;305:19–28.
55. Filippatou AG, Mukharesh L, Saidha S, Calabresi PA, Sotirchos ES. AQP4-IgG and MOG-IgG related optic neuritis-prevalence, optical coherence tomography findings, and visual outcomes: a systematic review and meta-analysis. *Front Neurol*. 2020;11:540156.
56. Zhao G, Chen Q, Huang Y, Li Z, Sun X, Lu P, et al. Clinical characteristics of myelin oligodendrocyte glycoprotein seropositive optic neuritis: a cohort study in Shanghai, China. *J Neurol*. 2017;265(1):33–40.
57. Biotti D, Bonneville F, Tournaire E, Ayrignac X, Dalliere CC, Mahieu L, et al. Optic neuritis in patients with anti-MOG antibodies spectrum disorder: MRI and clinical features from a large multicentric cohort in France. *J Neurol*. 2017;264(10):2173–5.
58. Liu H, Zhou H, Wang J, Sun M, Teng D, Song H, et al. The prevalence and prognostic value of myelin oligodendrocyte glycoprotein antibody in adult optic neuritis. *J Neurol Sci*. 2019;396:225–31.
59. Zhao Y, Tan S, Chan TCY, Xu Q, Zhao J, Teng D, et al. Clinical features of demyelinating optic neuritis with seropositive myelin oligodendrocyte glycoprotein antibody in Chinese patients. *Br J Ophthalmol*. 2018;102(10):1372.
60. The clinical profile of optic neuritis. Experience of the Optic Neuritis Treatment Trial. Optic Neuritis Study Group. *Arch Ophthalmol*. 1991;109(12):1673–8.
61. Brody J, Hellmann MA, Marignier R, Lotan I, Stiebel-Kalish H. Neuromyelitis optica spectrum disorder: disease course and long-term visual outcome. *J Neuroophthalmol*. 2016;36(4):356–62.
62. Asseyer S, Schmidt F, Chien C, Scheel M, Ruprecht K, Bellmann-Strobl J, et al. Pain in AQP4-IgG-positive and MOG-IgG-positive neuromyelitis optica spectrum disorders. *Mult Scler J Exp Transl Clin*. 2018;4(3):2055217318796684.
63. Ramanathan S, Prelog K, Barnes EH, Tantsis EM, Reddel SW, Henderson AP, et al. Radiological differentiation of optic neuritis with myelin oligodendrocyte glycoprotein antibodies, aquaporin-4 antibodies, and multiple sclerosis. *Mult Scler J*. 2016;22(4):470–82.
64. Asseyer S, Hamblin J, Messina S, Mariano R, Siebert N, Everett R, et al. Prodromal headache in MOG-antibody positive optic neuritis. *Mult Scler Relat Disord*. 2020;40:101965.

65. Jarius S, Ruprecht K, Wildemann B, Kuempfel T, Ringelstein M, Geis C, et al. Contrasting disease patterns in seropositive and seronegative neuromyelitis optica: a multicentre study of 175 patients. *J Neuroinflammation*. 2012;9:14.
66. Gkaniatsou T, Papadopoulou A, Paul F, Brandt AU, Oertel FC. Frequency of autoimmune disorders and autoantibodies in European patients with neuromyelitis optica spectrum disorders. *Acta Neurol Belg*. 2020;120(1):223–5.
67. Zhou L, Zhang Bao J, Li H, Li X, Huang Y, Wang M, et al. Cerebral cortical encephalitis followed by recurrent CNS demyelination in a patient with concomitant anti-MOG and anti-NMDA receptor antibodies. *Mult Scler Relat Disord*. 2017;18:90–2.
68. Kunchok A, Flanagan EP, Krecke KN, Chen JJ, Caceres JA, Dominick J, et al. MOG-IgG1 and co-existence of neuronal autoantibodies. *Mult Scler*. 2020;135245852095104.
69. Reindl M, Schanda K, Woodhall M, Tea F, Ramanathan S, Sagen J, et al. International multicenter examination of MOG antibody assays. *Neurol Neuroimmunol Neuroinflamm*. 2020;7(2):e674.
70. Kunchok A, Chen JJ, McKeon A, Mills JR, Flanagan EP, Pittock SJ. Coexistence of myelin oligodendrocyte glycoprotein and aquaporin-4 antibodies in adult and pediatric patients. *JAMA Neurol*. 2020;77(2):257–9.
71. Jarius S, Pellkofer H, Siebert N, Korporal-Kuhnke M, Hümmert MW, Ringelstein M, et al. Cerebrospinal fluid findings in patients with myelin oligodendrocyte glycoprotein (MOG) antibodies. Part 1: results from 163 lumbar punctures in 100 adult patients. *J Neuroinflammation*. 2020;17(1):261.
72. Lotan I, Brody J, Hellmann MA, Bialer O, Ganelin-Cohen E, Michaeli N, et al. Myelin oligodendrocyte glycoprotein-positive optic neuritis masquerading as pseudotumor cerebri at presentation. *J Neurol*. 2018;265(9):1985–8.
73. Etemadifar M, Abbasi M, Salari M, Etemadifar F, Tavakoli H. Comparing myelin oligodendrocyte glycoprotein antibody (MOG-Ab) and non MOG-Ab associated optic neuritis: clinical course and treatment outcome. *Mult Scler Relat Disord*. 2019;27:127–30.
74. Akaishi T, Sato DK, Nakashima I, Takeshita T, Takahashi T, Doi H, et al. MRI and retinal abnormalities in isolated optic neuritis with myelin oligodendrocyte glycoprotein and aquaporin-4 antibodies: a comparative study. *J Neurol Neurosurg Psychiatry*. 2016;87(4):446–8.
75. Juryńczyk M, Tackley G, Kong Y, Gerales R, Matthews L, Woodhall M, et al. Brain lesion distribution criteria distinguish MS from AQP4-antibody NMOSD and MOG-antibody disease. *J Neurol Neurosurg Psychiatry*. 2017;88(2):132–6.
76. Bensi C, Marrodan M, González A, Chertcoff A, Osa Sanz E, Chaves H, et al. Brain and spinal cord lesion criteria distinguishes AQP4-positive neuromyelitis optica and MOG-positive disease from multiple sclerosis. *Mult Scler Relat Disord*. 2018;25:246–50.
77. Pekcevik Y, Orman G, Lee IH, Mealy MA, Levy M, Izbudak I. What do we know about brain contrast enhancement patterns in neuromyelitis optica? *Clin Imaging*. 2016;40(3):573–80.
78. Salama S, Khan M, Shaneechi A, Levy M, Izbudak I. MRI differences between MOG antibody disease and AQP4 NMOSD. *Mult Scler*. 2020;1352458519893093.
79. Salama S, Khan M, Levy M, Izbudak I. Radiological characteristics of myelin oligodendrocyte glycoprotein antibody disease. *Mult Scler Relat Disord*. 2019;29:15–22.
80. Juryńczyk M, Gerales R, Probert F, Woodhall MR, Waters P, Tackley G, et al. Distinct brain imaging characteristics of autoantibody-mediated CNS conditions and multiple sclerosis. *Brain*. 2017;140(3):617–27.
81. Cai MT, Zheng Y, Shen CH, Yang F, Fang W, Zhang YX, et al. Evaluation of brain and spinal cord lesion distribution criteria at disease onset in distinguishing NMOSD from MS and MOG antibody-associated disorder. *Mult Scler*. 2020;1352458520939008.
82. Schmidt FA, Chien C, Kuchling J, Bellmann-Strobl J, Ruprecht K, Siebert N, et al. Differences in advanced magnetic resonance imaging in MOG-IgG and AQP4-IgG seropositive neuromyelitis optica spectrum disorders: a comparative study. *Front Neurol*. 2020;11:499910.
83. Juenger V, Cooper G, Chien C, Chikermane M, Oertel FC, Zimmermann H, et al. Optic chiasm measurements may be useful markers of anterior optic pathway degeneration in neuromyelitis optica spectrum disorders. *Eur Radiol*. 2020;30(9):5048–58.
84. Chien C, Oertel FC, Siebert N, Zimmermann H, Asseyer S, Kuchling J, et al. Imaging markers of disability in aquaporin-4 immunoglobulin G seropositive neuromyelitis optica: a graph theory study. *Brain Commun*. 2019;1(1):fz026.
85. Finke C, Heine J, Pache F, Lacheta A, Borisow N, Kuchling J, et al. Normal volumes and microstructural integrity of deep gray matter structures in AQP4+ NMOSD. *Neurol Neuroimmunol Neuroinflamm*. 2016;3(3):e229.
86. Wegener-Panzer A, Cleaveland R, Wendel EM, Baumann M, Bertolini A, Häusler M, et al. Clinical and imaging features of children with autoimmune encephalitis and MOG antibodies. *Neurol Neuroimmunol Neuroinflamm*. 2020;7(4):e731.
87. Oertel FC, Zimmermann H, Paul F, Brandt AU. Optical coherence tomography in neuromyelitis optica spectrum disorders: potential advantages for individualized monitoring of progression and therapy. *EPMA J*. 2018;9(1):21–33.
88. Pache F, Zimmermann H, Mikolajczak J, Schumacher S, Lacheta A, Oertel FC, et al. MOG-IgG in NMO and related disorders: a multicenter study of 50 patients. Part 4: afferent visual system damage after optic neuritis in MOG-IgG-seropositive versus AQP4-IgG-seropositive patients. *J Neuroinflammation*. 2016;13(1):282.
89. Costello F. Optical coherence tomography in neuro-ophthalmology. *Neurol Clin*. 2017;35(1):153–63.
90. Oertel FC, Zimmermann H, Mikolajczak J, Weinhold M, Kadas EM, Oberwahrenbrock T, et al. Contribution of blood vessels to retinal nerve fiber layer thickness in NMOSD. *Neurol Neuroimmunol Neuroinflamm*. 2017;4(3):e338.
91. Havla J, Kümpfel T, Schinner R, Spadaro M, Schuh E, Meinl E, et al. Myelin-oligodendrocyte-glycoprotein (MOG) autoantibodies as potential markers of severe optic neuritis and subclinical retinal axonal degeneration. *J Neurol*. 2017;264(1):139–51.
92. Martinez-Lapiscina EH, Sepulveda M, Torres-Torres R, Alba-Arbalaz S, Llufríu S, Blanco Y, et al. Usefulness of optical coherence tomography to distinguish optic neuritis associated with AQP4 or MOG in neuromyelitis optica spectrum disorders. *Ther Adv Neurol Disord*. 2016;9(5):436–40.
93. Oertel FC, Outteryck O, Knier B, Zimmermann H, Borisow N, Bellmann-Strobl J, et al. Optical coherence tomography in myelin-oligodendrocyte-glycoprotein antibody-seropositive patients: a longitudinal study. *J Neuroinflammation*. 2019;16(1):154.
94. Yu J, Huang Y, Quan C, Zhou L, Zhang Bao J, Wu K, et al. Alterations in the retinal vascular network and structure in MOG antibody-associated disease: an optical coherence tomography angiography study. *J Neuroophthalmol*. 2020.
95. Vicini R, Brügger D, Abegg M, Salmen A, Grabe HM. Differences in morphology and visual function of myelin oligodendrocyte glycoprotein antibody and multiple sclerosis associated optic neuritis. *J Neurol*. 2020;1–9.
96. Hyun JW, Woodhall MR, Kim SH, Jeong IH, Kong B, Kim G, et al. Longitudinal analysis of myelin oligodendrocyte glycoprotein antibodies in CNS inflammatory diseases. *J Neurol Neurosurg Psychiatry*. 2017;88(10):811–7.
97. López-Chiriboga AS, Majed M, Fryer J, Dubey D, McKeon A, Flanagan EP, et al. Association of MOG-IgG serostatus with relapse

- after acute disseminated encephalomyelitis and proposed diagnostic criteria for MOG-IgG-associated disorders. *JAMA Neurol.* 2018;75(11):1355–63.
98. Cobo-Calvo A, Sepúlveda M, d'Indy H, Armangué T, Ruiz A, Maillart E, et al. Usefulness of MOG-antibody titres at first episode to predict the future clinical course in adults. *J Neurol.* 2019;266(4):806–15.
 99. Whittam DH, Karthikeyan V, Gibbons E, Kneen R, Chandratte S, Ciccarelli O, et al. Treatment of MOG antibody associated disorders: results of an international survey. *J Neurol.* 2020;67:3566–7.
 100. Tajfirouz DA, Bhatti MT, Chen JJ. Clinical characteristics and treatment of MOG-IgG-associated optic neuritis. *Curr Neurol Neurosci Rep.* 2019;19(12).
 101. Lu Q, Luo J, Hao H, Liu R, Jin H, Jin Y, et al. Efficacy and safety of long-term immunotherapy in adult patients with MOG antibody disease: a systematic analysis. *J Neurol.* 2020.
 102. Whittam DH, Cobo-Calvo A, Lopez-Chiriboga AS, Pardo S, Gornall M, Cicconi S, et al. Treatment of MOG-IgG-associated disorder with rituximab: an international study of 121 patients. *Mult Scler Relat Disord.* 2020;44:102251.
 103. Li S, Ren H, Xu Y, Xu T, Zhang Y, Yin H, et al. Long-term efficacy of mycophenolate mofetil in myelin oligodendrocyte glycoprotein antibody-associated disorders: a prospective study. *Neurol Neuroimmunol Neuroinflamm.* 2020;7(3).
 104. Durozard P, Rico A, Boutiere C, Maarouf A, Lacroix R, Cointe S, et al. Comparison of the response to rituximab between MOG- and AQP4-antibody diseases. *Ann Neurol.* 2019;87:256–66.
 105. Cobo-Calvo A, Sepulveda M, Rollot F, Armangué T, Ruiz A, Maillart E, et al. Evaluation of treatment response in adults with relapsing MOG-Ab-associated disease. *J Neuroinflammation.* 2019;16(1):134.
 106. Hacoen Y, Wong YY, Lechner C, Jurynczyk M, Wright S, Konuskan B, et al. Disease course and treatment responses in children with relapsing myelin oligodendrocyte glycoprotein antibody-associated disease. *JAMA Neurol.* 2018;75(4):478–87.
 107. Tsantes E, Curti E, Siena E, Granella F. Successful intravenous immunoglobulin treatment in relapsing MOG-antibody-associated disease. *Mult Scler Relat Disord.* 2019;32:27–9.
 108. Chen JJ, Flanagan EP, Bhatti MT, Jitprapaikulsan J, Dubey D, Lopez Chiriboga AS, et al. Steroid-sparing maintenance immunotherapy for MOG-IgG associated disorder. *Neurology.* 2020;95(2):e111–20.
 109. Rigal J, Pagnet G, Ciron J, Lépine Z, Biotti D. Off-label use of tocilizumab in neuromyelitis optica spectrum disorders and MOG-antibody-associated diseases: a case-series. *Mult Scler Relat Disord.* 2020;46:102483.
 110. Lotan I, Charlson RW, Ryerson LZ, Levy M, Kister I. Effectiveness of subcutaneous tocilizumab in neuromyelitis optica spectrum disorders. *Mult Scler Relat Disord.* 2019;39:101920.
 111. Sotirchos ES, Filippatou A, Fitzgerald KC, Salama S, Pardo S, Wang J, et al. Aquaporin-4 IgG seropositivity is associated with worse visual outcomes after optic neuritis than MOG-IgG seropositivity and multiple sclerosis, independent of macular ganglion cell layer thinning. *Mult Scler.* 2020;26(11):1360–71.
 112. Matsuda R, Kezuka T, Umazume A, Okunuki Y, Goto H, Tanaka K. Clinical profile of anti-myelin oligodendrocyte glycoprotein antibody seropositive cases of optic neuritis. *Neuroophthalmology.* 2015;39(5):213–9.
 113. Stiebel-Kalish H, Hellmann MA, Mimouni M, Paul F, Bialer O, Bach M, et al. Does time equal vision in the acute treatment of a cohort of AQP4 and MOG optic neuritis? *Neurol Neuroimmunol Neuroinflamm.* 2019;6(4):e572.
 114. Stiebel-Kalish H, Lotan I, Brody J, Chodick G, Bialer O, Marignier R, et al. Retinal nerve fiber layer may be better preserved in MOG-IgG versus AQP4-IgG optic neuritis: a cohort study. *PLoS ONE.* 2017;12(1):e0170847.
 115. Osinga E, van Oosten B, de Vries-Knoppert W, Petzold A. Time is vision in recurrent optic neuritis. *Brain Res.* 2017;1673:95–101.
 116. Shindler KS, Ventura E, Dutt M, Rostami A. Inflammatory demyelination induces axonal injury and retinal ganglion cell apoptosis in experimental optic neuritis. *Exp Eye Res.* 2008;87(3):208–13.
 117. Zhu B, Moore GR, Zwimpfer TJ, Kastrukoff LF, Dyer JK, Steeves JD, et al. Axonal cytoskeleton changes in experimental optic neuritis. *Brain Res.* 1999;824(2):204–17.

How to cite this article: Lotan I, Oertel FC, Chien C, Asseyer S, Paul F, Stiebel-Kalish H. Practical recognition tools of immunoglobulin G serum antibodies against the myelin oligodendrocyte glycoprotein-positive optic neuritis and its clinical implications. *Clin Exp Neuroimmunol.* 2021;12:42–53. <https://doi.org/10.1111/cen3.12623>