




ORIGINAL ARTICLE

Variable pulmonary manifestations in Chitayat syndrome: Six additional affected individuals

Aude-Annick Suter¹  | Fernando Santos-Simarro²  | Pernille Mathiesen Toerring³ |
 Angela Abad Perez¹ | Rosario Ramos-Mejia⁴ | Karen E. Heath² |
 Victoria Huckstadt⁵ | Manuel Parrón-Pajares⁶ | Martin Atta Mensah^{1,7} |
 Wiebke Hülsemann⁸ | Manuel Holtgrewe⁹ | Stefan Mundlos^{1,10} |
 Uwe Kornak^{1,11} | Oliver Bartsch¹² | Nadja Ehmke^{1,10} 

¹Institute of Medical Genetics and Human Genetics, Charité – Universitätsmedizin Berlin, Berlin, Germany

²Institute of Medical and Molecular Genetics (INGEMM) and Skeletal dysplasia multidisciplinary Unit (UMDE), Hospital Universitario La Paz and CIBERER, ISCIII, Madrid, Spain

³Department of Clinical Genetics, Odense University Hospital, Odense, Denmark

⁴Department of Growth and Development, Garrahan Hospital, Buenos Aires, Argentina

⁵Department of Genetics, Garrahan Hospital, Buenos Aires, Argentina

⁶Department of Radiology and Skeletal dysplasia multidisciplinary Unit (UMDE), Hospital Universitario la Paz, Madrid, Spain

⁷Berlin Institute of Health (BIH), Berlin, Germany

⁸Handchirurgie Kinderkrankenhaus Wilhelmstift, Hamburg, Germany

⁹Core Unit Bioinformatics – CUBI, Berlin Institute of Health (BIH), Berlin, Germany

¹⁰RG Development & Disease, Max Planck Institute for Molecular Genetics, Berlin, Germany

¹¹Institute of Human Genetics, University Medical Center Göttingen, Göttingen, Germany

¹²Institute of Human Genetics, University Medical Centre of the Johannes Gutenberg University Mainz, Mainz, Germany

Correspondence

Nadja Ehmke, Institute of Medical Genetics and Human Genetics, Charité – Universitätsmedizin Berlin, Augustenburger Platz 1, 13353 Berlin, Germany.
 Email: nadja.ehmke@charite.de

Funding information

Charité – Universitätsmedizin Berlin; Berlin Institute of Health

Abstract

Hand hyperphalangism leading to shortened index fingers with ulnar deviation, hallux valgus, mild facial dysmorphism and respiratory compromise requiring assisted ventilation are the key features of Chitayat syndrome. This condition results from the recurrent heterozygous missense variant NM_006494.2:c.266A>G; p.(Tyr89Cys) in *ERF* on chromosome 19q13.2, encoding the ETS2 repressor factor (ERF) protein. The pathomechanism of Chitayat syndrome is unknown. To date, seven individuals with Chitayat syndrome and the recurrent pathogenic *ERF* variant have been reported in the literature. Here, we describe six additional individuals, among them only one presenting with a history of assisted ventilation, and the remaining presenting with variable pulmonary phenotypes, including one individual without any obvious pulmonary manifestations. Our findings widen the phenotype spectrum caused by the recurrent pathogenic variant in *ERF*, underline Chitayat syndrome as a cause of isolated skeletal

This is an open access article under the terms of the Creative Commons Attribution-NonCommercial-NoDerivs License, which permits use and distribution in any medium, provided the original work is properly cited, the use is non-commercial and no modifications or adaptations are made.

© 2020 The Authors. *American Journal of Medical Genetics Part A* published by Wiley Periodicals LLC.

malformations and therefore contribute to the improvement of diagnostic strategies in individuals with hand hyperphalangism.

KEYWORDS

bronchomalacia, Chitayat syndrome, *ERF*, hyperphalangism, respiratory distress, ulnar deviation

1 | INTRODUCTION

Chitayat syndrome (MIM 617180) is characterized by bilateral hand hyperphalangism resulting in shortening and ulnar deviation of the index and sometimes third fingers, hallux valgus, mild facial dysmorphism and respiratory complications presenting from birth (Chitayat et al., 1993). It is caused by the recurrent missense variant NM_006494.2:c.266A>G; p.(Tyr89Cys) in *ERF* on chromosome 19q13.2 (MIM 611888) (Balasubramanian et al., 2017). *ERF* encodes the ETS2 repressor factor (ERF), which is ubiquitously expressed. It binds to the ETS-binding site (EBS) within the *ETS2* promoter and belongs to the ETS family of transcription factors which regulate cellular proliferation and differentiation, embryological development, hematopoiesis, lymphocyte function and apoptosis (Bose et al., 2017; de Castro et al., 1997; Liu, Pavlopoulos, Modi, Moschonas, & Mavrothalassitis, 1997; Sevilla et al., 1999). ETS factors are also involved in bone and cartilage development (Kola et al., 1993). In osteoblasts, *ETS2* was implicated in the regulation of osteopontin (Raouf & Seth, 2000; Vary et al., 2000). Overexpression of *ETS2* in mice inhibits chondrogenesis and ossification with evidence for reduced proteoglycan content in the cartilaginous skeleton (Sumarsono et al., 1996). The recurrent *ERF* aminoacid substitution found in Chitayat syndrome is located in the DNA-binding domain. Pathogenic heterozygous variants in *ERF* leading to haploinsufficiency, including other missense variants in the DNA-binding domain, cause craniosynostosis 4 (MIM 600775) (Twigg et al., 2013). However, it still remains unclear why the p.(Tyr89Cys) variant is associated with a different phenotype (Balasubramanian et al., 2017).

To date, seven individuals with molecularly confirmed Chitayat syndrome have been described in the literature (Balasubramanian et al., 2017; Caro-Contreras, Alcantara-Ortigoza, Ahumada-Perez, & Gonzalez-Del, 2019; Chitayat et al., 1993; Shin, StJoseph, Mannan, & Khan, 2019). Furthermore, two individuals with high clinical suspicion of Chitayat syndrome and one individual with suspected Chitayat syndrome but without hand hyperphalangism have been reported (Tanaka, Matsuo, Nishimura, & Nagai, 1994). It is of interest that all individuals reported so far showed respiratory distress requiring assisted ventilation in the first 8 weeks of life, mostly due to bronchomalacia or interstitial lung disease. Here, we report six additional individuals from four unrelated families with molecularly confirmed Chitayat syndrome. Only one of the individuals reported here had a history of respiratory distress requiring assisted ventilation, and the remaining individuals showed variable pulmonary manifestations, also including one individual lacking obvious pulmonary disease.

2 | MATERIALS AND METHODS

2.1 | Editorial policies and ethical considerations

The study was approved by the ethics committee of the Charité—Universitätsmedizin Berlin (Individuals 1 and 2). Individuals 3, 4, 5 and 6 were included in a research project with IRB approval (MINECO SAF2017-84646-R) in Madrid, Spain. All procedures were in accordance with the ethical standards of the responsible committees on human experimentation (institutional and national) and with the Helsinki Declaration of 1975, as revised in 2000. Informed consent was obtained from all individuals included in the study. Additional informed consent was obtained from all individuals for which identifying information is included in this article.

2.2 | Human material and diagnostic testing

Genomic DNA was extracted from peripheral blood leukocytes using standard protocols. Illumina's All Exon Kit V6 was used for targeted enrichment of DNA of Individuals 1, 2 and their parents. Data processing and variant filtration were applied as previously published (patient 2 in Ehmke et al., 2020). The remaining variants were filtered according to a dominant and recessive mode of inheritance. The de novo *ERF* variants were confirmed with Sanger sequencing in Individuals 1 and 2.

In Individuals 3, 5 and 6, a custom designed skeletal dysplasia panel (Roche Nimblegen, SkeletalSeqV4 or V6) including 327/419 genes was applied in the Hospital Universitario La Paz, Madrid, Spain. Validation in these three individuals and segregation analysis of the *ERF* variant in Individual 4 was performed using Sanger sequencing. The sequencing and variant filtering have been published (Sentchordi-Montane et al., 2018).

3 | RESULTS

3.1 | Clinical description of the cohort

This study included three unrelated affected individuals (Individuals 1–3) as well as a mother (Individual 4) and her two daughters (Individuals 5 and 6, half-siblings) with Chitayat syndrome. The clinical data of the six individuals are shown in Table 1 and Figures 1 and 2.

TABLE 1 (Continued)

Individual	1	2	3	4	5	6	Summary of this cohort	Summary from seven individuals described in literature ^a
Interstitial lung disease HP:0006530	u	-	-	-	u	-	0/6	5/7
Other affections of the airways	-	u	+ ^b	+ ^c	u	+ ^d	3/6	1/7 ^e
<i>Facial dysmorphisms</i>								
HP:0001999							5/6	7/7
Proptosis HP:0000520	-	+	-	+	-	+	3/6	2/7
Hypertelorism HP:0000316	-	-	+	+	-	+	3/6	5/7
Broad nasal bridge HP:0000431	-	+	+	+	-	+	4/6	2/7
Depressed nasal bridge HP:0005280	-	+	-	-	-	-	1/6	4/7
Anteverted nares HP:0000463	-	+	-	-	-	-	1/6	3/7
Low hanging/low inserted columella HP:0009765/HP:0010763	+	-	+	+	+	+	5/6	u
Short philtrum HP:0000322	+	-	+	+	+	+	5/6	u
Full lips HP:0012471	+	+	+	+	-	-	4/6	2/7
Thin upper lip vermillion HP:0000219	-	-	-	-	+	+	2/6	u
Broad chin HP:0011822	+	-	-	+	+	+	4/6	u
Abnormal form/location of the ears HP:0000377/HP:0000357	-	+	+	+	-	+	4/6	1/7
Neurodevelopmental delay HP:0012758	+	-	-	+	-	-	2/6	3/7
Polyhydramnios HP:0001561	-	-	-	u	-	-	0/6	3/7

Abbreviations: f, female; l, individual; u, unknown; +, present; -, absent.

^aBalasubramanian et al., Caro-Contreras et al., Shin et al.^bApnea.^cRestrictive ventilatory insufficiency.^dInterstitial infiltrates.^eSevere tracheomalacia additionally to bronchomalacia in one individual.

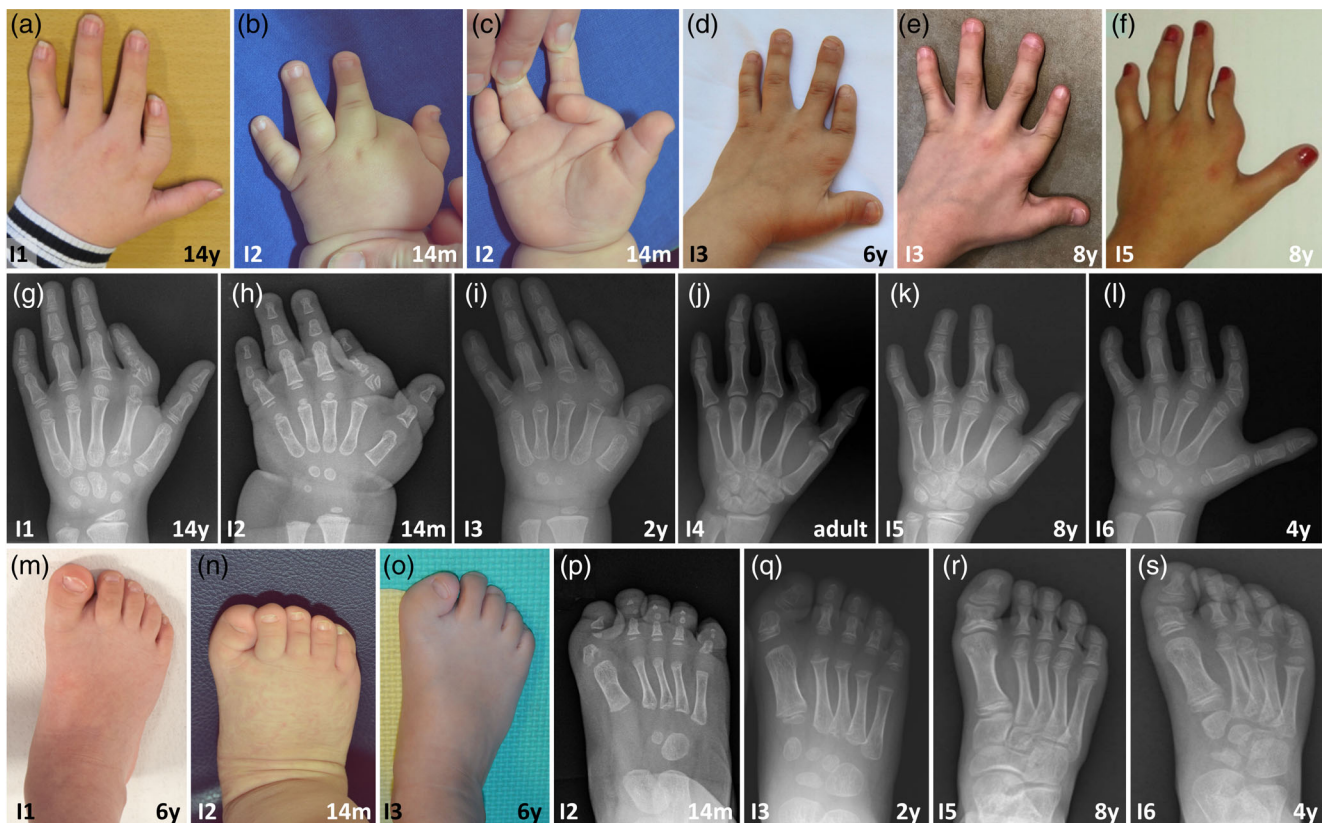


FIGURE 1 Hand/feet photographs and radiographs. (a–f) Photographs of the hands of individuals (I) 1, 2, 3 and 5 at different ages, showing short and small index fingers with ulnar deviation and spontaneously flexed position of the metacarpophalangeal joint, especially in I2. Note that there is also shortening of the other fingers, especially the middle fingers, and ulnar deviation of all fingers. Photographs of the hands of I3 display additional flexed position of the first metacarpophalangeal joint. (g–l) Hand radiographs of I1–6 at different ages, showing triangular shaped bones in the second metacarpophalangeal joints. In I1–3, 5 and 6 the triangular bone has lateral growth plates, whereas in I4, it is fused with the proximal phalanx. In I3, 5 and 6, the third and fourth fingers are also affected. The phalanges of the index finger are small and/or short, and the index fingers are ulnarly deviated. There is also ulnar deviation and shortening of other fingers in all individuals. Clinodactyly of the fifth finger and short middle phalanges can be found in most individuals. In I3, the proximal phalanx of the first finger is ulnarly deviated and has an abnormally shaped growth plate. A detailed description of the radiographs can be found in the Supporting Information. (m–o) Photographs of the feet of I1, 2 and 3 showing short first toes and hallux valgus. (p–s) Radiographs of the feet of I2, 3, 5 and 6, showing short proximal phalanges and hallux valgus [Color figure can be viewed at wileyonlinelibrary.com]

Detailed clinical descriptions of the individuals are provided in the Supporting Information. All individuals had the typical hand malformation observed in Chitayat syndrome, consisting of short index fingers with ulnar deviation in the hands and malformed first toes, also with lateral deviation. The hand malformation was most prominent in Individual 2 who showed crossing under the third fingers and additional shortening of other fingers (Figure 2a–f). Radiographs showed hyperphalangism of the index fingers, consisting of a triangular shaped bone with lateral growth plates in the second metacarpophalangeal joint leading to ulnar deviation in all individuals. In some individuals, the first, third and/or fourth digits were also affected. Hyperphalangism could not always be differentiated from an abnormally shaped growth plate in the individuals included in this report. Furthermore, all affected individuals showed short middle phalanges, in particular of the fourth digit, but affecting all digits in Individuals 4, 5 and 6. The bony changes led to small and slender (except Individual 4) index fingers. We also noted ulnar deviation of the third, fourth and often fifth fingers in most

individuals. There was spontaneously flexed position of the second metacarpophalangeal joint in Individuals 1, 2 and 3, and additionally of the first interphalangeal joint in Individual 3. All individuals had short first toes and hallux valgus of different degree (Figure 1m–s). A detailed description of the hand radiographs can be found in the Supporting Information.

The pulmonary phenotype in this cohort was milder than the phenotype described previously in individuals with Chitayat syndrome. Although five of six individuals in the present cohort had pulmonary problems, none of the individuals received a diagnosis of bronchomalacia, tracheomalacia or interstitial lung disease, and only one had respiratory distress leading to temporary ventilation. One individual (Individual 2) had laryngomalacia, which has not been described before in individuals with Chitayat syndrome. Individuals 3, 4, 5 and 6 had recurrent bronchospasms and pulmonary obstruction, and Individual 3 had recurrent pulmonary infections. Further diagnostic testing of this individual showed unspecific micronodules in the right hemithorax and a distal airway

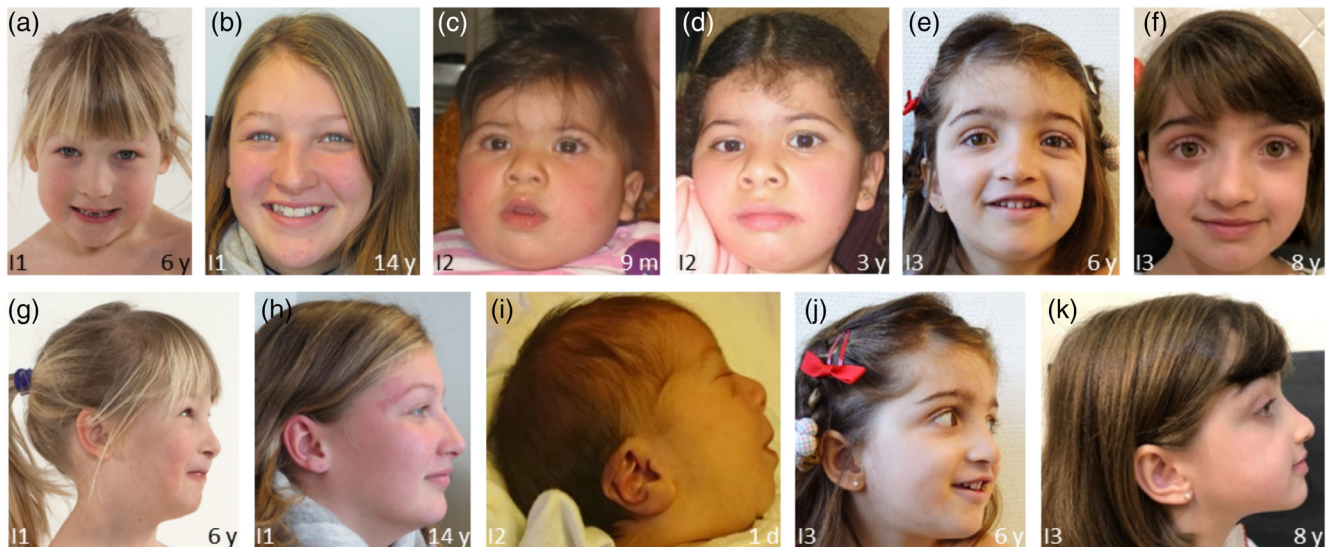


FIGURE 2 Facial photographs of Individuals 1–3. (a, b, g, h) Facial photographs of Individual 1 at the age of 6 years (y) and 14 y, showing fullness of the upper eyelid, a low inserted columella, a short philtrum and a broad chin. (c, d, i) Facial photographs of Individual 2 at the age of 1 day, 9 months and 3 years show mild proptosis, a broad and depressed nasal bridge, anteverted nares, a tented upper lip vermillion, full lips, forward facing ear lobes and overfolded helices. (e, f, j, k) Facial photographs of Individual 3 show synophrys, hypertelorism, a broad nasal bridge, ridge and tip, low hanging columella, short philtrum, full lips and posteriorly rotated ears [Color figure can be viewed at wileyonlinelibrary.com]

pathology in the left posterobasal segment but no signs of interstitial lung disease. Additionally, Individual 4 was diagnosed with restrictive ventilatory insufficiency whereas chest radiographs of Individual 6 noted interstitial infiltrates. In one individual (Individual 1), there was no history of pulmonary disease.

All individuals had variable facial dysmorphisms. The following features were observed in at least two unrelated individuals and had been previously reported in individuals with Chitayat syndrome: proptosis (3/6), hypertelorism (3/6), broad nasal bridge 4/6, full lips (3/6) and abnormal form or location of the ears (4/6). The features depressed nasal bridge and anteverted nares, which were present in at least three previously described individuals, were found in a single individual of the present cohort. In five individuals we observed a low hanging/low inserted columella and short philtrum, which was previously undescribed. Facial photographs of all individuals were available for systematic evaluation and comparison, consent for publication was available from Individuals 1, 2 and 3 (Figure 2a–f).

Polyhydramnios was not observed during pregnancy in any of the individuals described here, in contrast to those described in the literature, where polyhydramnios had been reported in three of the seven cases. Two individuals in this cohort achieved developmental milestones later than expected and one of them later had learning difficulties and attended a school for children with special needs. No data of formal neurological evaluation is available.

3.2 | Genotype

Trio exome sequencing of Individuals 1 and 2, gene panel analysis in Individuals 3, 5 and 6 and Sanger sequencing in Individual 4

identified the recurrent heterozygous variant NM_006494.2: c.266A>G; p.(Tyr89Cys) in *ERF*. The *ERF* pathogenic variant occurred *de novo* in Individuals 1, 2 and 3, whereas Individuals 5 and 6 inherited it from Individual 4.

4 | DISCUSSION

To our knowledge, only seven individuals with molecularly confirmed Chitayat syndrome have been described in the literature so far (Balasubramanian et al., 2017; Caro-Contreras et al., 2019; Shin et al., 2019). With this report, the known phenotypical spectrum of Chitayat syndrome is widened by six additional individuals with variable pulmonary manifestations and one of them presenting without any clinically obvious lung disease.

Individuals with Chitayat syndrome show the characteristic combination of hyperphalangism of the index fingers leading to shortening and ulnar deviation, hallux valgus, facial dysmorphism and lung disease. In some of the individuals reported here, clinical diagnosis was complicated by the absence of severe respiratory impairment, and diagnosis was obtained by NGS-based analyses (exome and panel sequencing). In Individual 2 the respiratory problems, which appeared to be rather mild, were documented only retrospectively. Notably, all of the individuals described in the literature with a molecular diagnosis of Chitayat syndrome had respiratory distress postnatally or in the first 8 weeks of life, requiring assisted ventilation, and recurrent lung infections (Balasubramanian et al., 2017; Caro-Contreras et al., 2019; Shin et al., 2019). Six out of seven individuals had bronchomalacia, five out of seven individuals showed interstitial lung disease. The here reported cohort broadens the variability of phenotypes associated

with Chitayat syndrome with remarkably mild pulmonary manifestations. Most interestingly, Individual 1 of this cohort, a meanwhile 16-year-old girl, does not show any of these complications to date. No respiratory distress or respiratory infections ever occurred. To our knowledge, this is the first individual with molecularly confirmed Chitayat syndrome showing no respiratory involvement, although it should be mentioned that she did not receive any diagnostic test to exclude lung disease and pulmonary manifestation cannot be completely excluded.

The most specific feature of Chitayat syndrome is hyperphalangism with shortening and ulnar deviation of the index fingers. There are only few other conditions presenting with a similar type of hyperphalangism and hand malformation, including Catel-Manzke syndrome (MIM 616145), Desbuquois dysplasia 1 (DBQD1; MIM 251450), Temtamy preaxial brachydactyly syndrome (TBPS; MIM 605282) and chondrodysplasia with joint dislocations (GPAPP deficiency) (MIM 614078). Catel-Manzke syndrome is due to pathogenic variants in *TGDS* (MIM 616146) (Ehmke et al., 2014; Manzke, Lehmann, Klopocki, & Caliebe, 2008). DBQD1 is caused by mutations in *CANT1* (MIM 613165) (Favre et al., 2004; Huber et al., 2009), while TBPS is secondary to pathogenic variants in *CHSY1* (MIM 601882) (Li et al., 2010; Temtamy, Meguid, Ismail, & Ramzy, 1998) and GPAPP deficiency is caused by pathogenic variants in *IMPAD1* (MIM 614010) (Vissers et al., 2011). Furthermore, brachydactyly type C due to certain variants in *GDF5* can be associated with similar hand malformations (Farooq et al., 2013; Gutierrez-Amavizca et al., 2012; Schwabe et al., 2004; Stange et al., 2015). DBQD1, TPBS, GPAPP deficiency and possibly Catel-Manzke syndrome are resulting from defects in proteoglycan metabolism and are characterized by micro-retrognathia and cleft palate, short stature, congenital heart defects and developmental delay, hearing loss and joint dislocations additionally to hyperphalangism. These additional features are not present in Chitayat syndrome, which facilitates differentiation from the above-mentioned conditions. Only in Catel-Manzke syndrome pathognomonic features of the aforementioned proteoglycan-related disorders can be absent or very mild, which makes the differential diagnosis to Chitayat syndrome challenging, especially when no respiratory distress occurs. In this context, an analysis of the hand malformation can be conclusive: Catel-Manzke syndrome is usually associated with radial deviation of the index finger, but ulnar deviation is observed in individuals with Chitayat syndrome.

When comparing individuals with Chitayat syndrome to individuals with *GDF5*-related brachydactyly type C, especially to the individual reported by Schwabe et al. (Schwabe et al., 2004), a striking similarity between the hand malformations is detectable. The molecular mechanism of *ERF*-related hyperphalangy remains unclear, but due to the phenotypic overlap, a misregulation of *GDF5* could be considered. Nevertheless, the reduced proteoglycan content in the cartilaginous skeleton of mice overexpressing *ETS2* (Sumarsono et al., 1996) could present a link to proteoglycan-related skeletal dysplasias.

Facial dysmorphisms were present in all of the individuals reported here, but were variable. The characteristic facial features described before (hypertelorism, depressed nasal bridge, anteverted

nares) were not detectable in all individuals, which is in line with previous reports. In addition, we observed a long hanging/low inserted columella and a short philtrum in all but one individuals.

Interestingly, none of the individuals with Chitayat syndrome displayed signs of craniosynostosis. *ERF*-related craniosynostosis is characterized by sagittal, lambdoid and multisutural synostosis as well as pansynostosis, often with postnatal onset (Glass et al., 2019; Twigg et al., 2013; Wilkie, Johnson, & Wall, 2017). Additionally, individuals diagnosed with *ERF*-associated craniosynostosis appear to have a high risk for pathologically elevated intracranial brain pressure leading to visual impairment, Chiari-1 malformation, language and speech delay, poor fine and/or gross motor skills and behavioral problems/hyperactivity (Glass et al., 2019; Twigg et al., 2013; Wilkie et al., 2017). In many of these individuals, a diagnosis of Crouzon syndrome had been suspected initially. The pathomechanism of *ERF*-related craniosynostosis is predominantly linked to haploinsufficiency and causative missense variants are located in the DNA-binding domain, just like the variant associated with Chitayat syndrome (Glass et al., 2019; Wilkie et al., 2017). Wilkie et al. suggested that the distinct phenotype in Chitayat syndrome might result from altered DNA-binding properties associated with the missense variant NM_006494.2:c.266A>G; p.(Tyr89Cys), but the etiological mechanisms remain unknown (Wilkie et al., 2017).

Individuals with Chitayat syndrome typically have a normal intelligence. According to Caro-Contreras et al., the developmental delay described in 3/7 individuals in the literature improved over time in at least two of them (Caro-Contreras et al., 2019). When last seen, Individual 1 in the present report attended a special needs school due to mild developmental delay, whereas Individual 4 experienced learning difficulties at a regular school. Unfortunately, no data of formal neurological evaluation were available for this study. Nevertheless, these findings could be further evidence that developmental problems are part of the phenotypic spectrum associated with Chitayat syndrome.

In conclusion, we present six further individuals with Chitayat syndrome, at least one of them lacking clinical pulmonary manifestations, and only one presenting with respiratory problems requiring assisted ventilation. This report extends the range of clinical features of individuals with Chitayat syndrome and will help to improve the diagnosis of individuals with hyperphalangism.

ACKNOWLEDGMENTS

We thank Elisa Julia Schäfers for assistance in NGS data analysis and Anja Lekaj for technical assistance. We thank the families for their collaboration and contribution to this project. The authors declare no conflict of interest. M. A. M. is participant in the BIH Charité Junior Clinician Scientist Program funded by the Charité-Universitätsmedizin Berlin and the Berlin Institute of Health. N. E. was supported by the Rahel-Hirsch program (Charité).

AUTHOR CONTRIBUTIONS

Aude-Annick Suter, Angela Abad Perez and Nadja Ehmke: drafted the manuscript. **Fernando Santos-Simarro, Pernille Mathiesen Toerring, Rosario Ramos-Mejia, Karen E. Heath, Victoria Huckstadt,**

Martin Atta Mensah, Wiebke Hülsemann, Stefan Mundlos, Uwe Kornak and Oliver Bartsch: critically revised the manuscript. **Aude-Annick Suter, Fernando Santos-Simarro, Pernille Mathiesen Toerring, Rosario Ramos-Mejia, Karen E. Heath, Victoria Huckstadt, Manuel Parrón-Pajares, Martin Atta Mensah, Wiebke Hülsemann, Stefan Mundlos, Uwe Kornak, Oliver Bartsch and Nadja Ehmke:** collected and/or interpreted clinical, radiological and/or molecular data of the patients. **Fernando Santos-Simarro, Karen E. Heath, Manuel Holtgrewe and Nadja Ehmke:** analyzed and interpreted NGS data. All authors gave final approval of the version to be published. Nadja Ehmke agrees to be accountable for all aspects of the work in ensuring that questions related to the accuracy or integrity of any part of the work are appropriately investigated and resolved.

DATA AVAILABILITY STATEMENT

The data that support the findings of this study are available on request from the corresponding author. The data are not publicly available due to privacy or ethical restrictions.

ORCID

Aude-Annick Suter  <https://orcid.org/0000-0003-2252-3497>

Fernando Santos-Simarro  <https://orcid.org/0000-0002-1201-9118>

Nadja Ehmke  <https://orcid.org/0000-0003-1449-9909>

REFERENCES

- Balasubramanian, M., Lord, H., Levesque, S., Guturu, H., Thuriot, F., Sillon, G., ... Chitayat, D. (2017). Chitayat syndrome: Hyperphalangism, characteristic facies, hallux valgus and bronchomalacia results from a recurrent c.266A>G p.(Tyr89Cys) variant in the ERF gene. *Journal of Medical Genetics*, 54(3), 157–165.
- Bose, R., Karthaus, W. R., Armenia, J., Abida, W., Iaquina, P. J., Zhang, Z., ... Sawyers, C. L. (2017). ERF mutations reveal a balance of ETS factors controlling prostate oncogenesis. *Nature*, 546(7660), 671–675.
- Caro-Contreras, A., Alcantara-Ortigoza, M. A., Ahumada-Perez, J. F., & Gonzalez-Del, A. A. (2019). Molecular analysis provides further evidence that Chitayat syndrome is caused by the recurrent p.(Tyr89Cys) pathogenic variant in the ERF gene. *American Journal of Medical Genetics. Part A*, 179(1), 118–122.
- Chitayat, D., Haj-Chahine, S., Stalker, H. J., Azouz, E. M., Cote, A., & Halal, F. (1993). Hyperphalangism, facial anomalies, hallux valgus, and bronchomalacia: A new syndrome? *American Journal of Medical Genetics*, 45(1), 1–4.
- de Castro, C. M., Rabe, S. M., Langdon, S. D., Fleenor, D. E., Slentz-Kesler, K., Ahmed, M. N., ... Kaufman, R. E. (1997). Genomic structure and chromosomal localization of the novel ETS factor, PE-2 (ERF). *Genomics*, 42(2), 227–235.
- Ehmke, N., Caliebe, A., Koenig, R., Kant, S. G., Stark, Z., Cormier-Daire, V., ... Mundlos, S. (2014). Homozygous and compound-heterozygous mutations in TGDS cause Catel-Manzke syndrome. *American Journal of Human Genetics*, 95(6), 763–770.
- Ehmke, N., Cusmano-Ozog, K., Koenig, R., Holtgrewe, M., Nur, B., Mihci, E., ... Ferreira, C. R. (2020). Biallelic variants in KYN1 cause a multisystemic syndrome with hand hyperphalangism. *Bone*, 133, 115219. <https://doi.org/10.1016/j.bone.2019.115219>.
- Faivre, L., Le Merrer, M., Zerres, K., Ben Hariz, M., Scheffer, D., Young, I. D., ... Cormier-Daire, V. (2004). Clinical and genetic heterogeneity in Desbuquois dysplasia. *American Journal of Medical Genetics. Part A*, 128A(1), 29–32.
- Farooq, M., Nakai, H., Fujimoto, A., Fujikawa, H., Kjaer, K. W., Baig, S. M., & Shimomura, Y. (2013). Characterization of a novel missense mutation in the prodomain of GDF5, which underlies brachydactyly type C and mild Grebe type chondrodysplasia in a large Pakistani family. *Human Genetics*, 132(11), 1253–1264.
- Glass, G. E., O'Hara, J., Canham, N., Cilliers, D., Dunaway, D., Fenwick, A. L., ... Wilson, L. C. (2019). ERF-related craniosynostosis: The phenotypic and developmental profile of a new craniosynostosis syndrome. *American Journal of Medical Genetics. Part A*, 179(4), 615–627.
- Gutierrez-Amavizca, B. E., Brambila-Tapia, A. J., Juarez-Vazquez, C. I., Holder-Espinasse, M., Manouvrier-Hanu, S., Escande, F., & Barros-Nunez, P. (2012). A novel mutation in CDMP1 causes brachydactyly type C with "angel-shaped phalanx". A genotype-phenotype correlation in the mutational spectrum. *European Journal of Medical Genetics*, 55(11), 611–614.
- Huber, C., Oules, B., Bertoli, M., Chami, M., Fradin, M., Alanay, Y., ... Cormier-Daire, V. (2009). Identification of CANT1 mutations in Desbuquois dysplasia. *American Journal of Human Genetics*, 85(5), 706–710.
- Kola, I., Brookes, S., Green, A. R., Garber, R., Tymms, M., Papas, T. S., & Seth, A. (1993). The Ets1 transcription factor is widely expressed during murine embryo development and is associated with mesodermal cells involved in morphogenetic processes such as organ formation. *Proceedings of the National Academy of Sciences of the United States of America*, 90(16), 7588–7592.
- Li, Y., Laue, K., Temtamy, S., Aglan, M., Kotan, L. D., Yigit, G., ... Wollnik, B. (2010). Temtamy preaxial brachydactyly syndrome is caused by loss-of-function mutations in chondroitin synthase 1, a potential target of BMP signaling. *American Journal of Human Genetics*, 87(6), 757–767.
- Liu, D., Pavlopoulos, E., Modi, W., Moschonas, N., & Mavrothalassitis, G. (1997). ERF: Genomic organization, chromosomal localization and promoter analysis of the human and mouse genes. *Oncogene*, 14(12), 1445–1451.
- Manzke, H., Lehmann, K., Klopocki, E., & Caliebe, A. (2008). Catel-Manzke syndrome: Two new patients and a critical review of the literature. *European Journal of Medical Genetics*, 51(5), 452–465.
- Raouf, A., & Seth, A. (2000). Ets transcription factors and targets in osteogenesis. *Oncogene*, 19(55), 6455–6463.
- Schwabe, G. C., Turkmen, S., Leschik, G., Palanduz, S., Stover, B., Goecke TO, & Mundlos, S. (2004). Brachydactyly type C caused by a homozygous missense mutation in the prodomain of CDMP1. *American Journal of Medical Genetics. Part A*, 124A(4), 356–363.
- Sentchordi-Montane, L., Aza-Carmona, M., Benito-Sanz, S., Barreda-Bonis, A. C., Sanchez-Garre, C., Prieto-Matos, P., ... Heath, K. E. (2018). Heterozygous aggrecan variants are associated with short stature and brachydactyly: Description of 16 probands and a review of the literature. *Clinical Endocrinology*, 88(6), 820–829.
- Sevilla, L., Aperlo, C., Dulic, V., Chambard, J. C., Boutonnet, C., Pasquier, O., ... Boulukos, K. E. (1999). The Ets2 transcription factor inhibits apoptosis induced by colony-stimulating factor 1 deprivation of macrophages through a Bcl-xL-dependent mechanism. *Molecular and Cellular Biology*, 19(4), 2624–2634.
- Shin, S. H., StJoseph, E., Mannan, K., & Khan, K. (2019). Radiography of Chitayat syndrome in an infant male. *Radiology Case Reports*, 14(4), 448–451.
- Stange, K., Ott, C. E., Schmidt-von Kegler, M., Gillesen-Kaesbach, G., Mundlos, S., Dathe, K., & Seemann, P. (2015). Brachydactyly Type C patient with compound heterozygosity for p.Gly319Val and p.Ile358Thr variants in the GDF5 proregion: Benign variants or mutations? *Journal of Human Genetics*, 60(8), 419–425.
- Sumarsono, S. H., Wilson, T. J., Tymms, M. J., Venter, D. J., Corrick, C. M., Kola, R., ... Kola, I. (1996). Down's syndrome-like skeletal abnormalities in Ets2 transgenic mice. *Nature*, 379(6565), 534–537.

- Tanaka, Y., Matsuo, N., Nishimura, G., & Nagai, T. (1994). Broad proximal phalanx, facial anomalies, hallux valgus, and bronchomalacia: Additional case. *American Journal of Medical Genetics*, 50(2), 211–212.
- Temtamy, S. A., Meguid, N. A., Ismail, S. I., & Ramzy, M. I. (1998). A new multiple congenital anomaly, mental retardation syndrome with preaxial brachydactyly, hyperphalangism, deafness and orodental anomalies. *Clinical Dysmorphology*, 7(4), 249–255.
- Twigg, S. R., Vorgia, E., McGowan, S. J., Peraki, I., Fenwick, A. L., Sharma, V. P., ... Wilkie, A. O. (2013). Reduced dosage of ERF causes complex craniosynostosis in humans and mice and links ERK1/2 signaling to regulation of osteogenesis. *Nature Genetics*, 45(3), 308–313.
- Vary, C. P., Li, V., Raouf, A., Kitching, R., Kola, I., Franceschi, C., ... Seth, A. (2000). Involvement of Ets transcription factors and targets in osteoblast differentiation and matrix mineralization. *Experimental Cell Research*, 257(1), 213–222.
- Vissers, L. E., Lausch, E., Unger, S., Campos-Xavier, A. B., Gilissen, C., Rossi, A., ... Superti-Furga, A. (2011). Chondrodysplasia and abnormal joint development associated with mutations in IMPAD1, encoding

the Golgi-resident nucleotide phosphatase, gPAPP. *American Journal of Human Genetics*, 88(5), 608–615.

- Wilkie, A. O. M., Johnson, D., & Wall, S. A. (2017). Clinical genetics of craniosynostosis. *Current Opinion in Pediatrics*, 29(6), 622–628.

SUPPORTING INFORMATION

Additional supporting information may be found online in the Supporting Information section at the end of this article.

How to cite this article: Suter A-A, Santos-Simarro F, Toerring PM, et al. Variable pulmonary manifestations in Chitayat syndrome: Six additional affected individuals. *Am J Med Genet Part A*. 2020;182A:2068–2076. <https://doi.org/10.1002/ajmg.a.61735>