

Aus dem CharitéCentrum für Diagnostische und Interventionelle  
Radiologie und Nuklearmedizin  
Direktor: Professor Dr. med. Bernd Hamm

## **Habilitationsschrift**

# **MRT-Diagnostik rheumatischer Erkrankungen der Extremitätengelenke: Klinischer Stellenwert und Vergleich von konventioneller (1,5 Tesla) mit Niederfeld (0,2 Tesla) MRT**

zur Erlangung der Venia legendi  
für das Fach Radiologie

vorgelegt dem Fakultätsrat der Medizinischen Fakultät  
Charité – Universitätsmedizin Berlin

von

Kay-Geert Armin Hermann  
geboren am 25. Januar 1972 in Dresden

Eingereicht: April 2009

Tag des öffentlichen-wissenschaftlichen Vortrages: 8. Februar 2010

Dekanin: Prof. Dr. Annette Grüters-Kieslich

1. Gutachter: Herr Prof. Dr. F. Kainberger / Wien
2. Gutachter: Herr Prof. Dr. J. Freyschmidt / Bremen

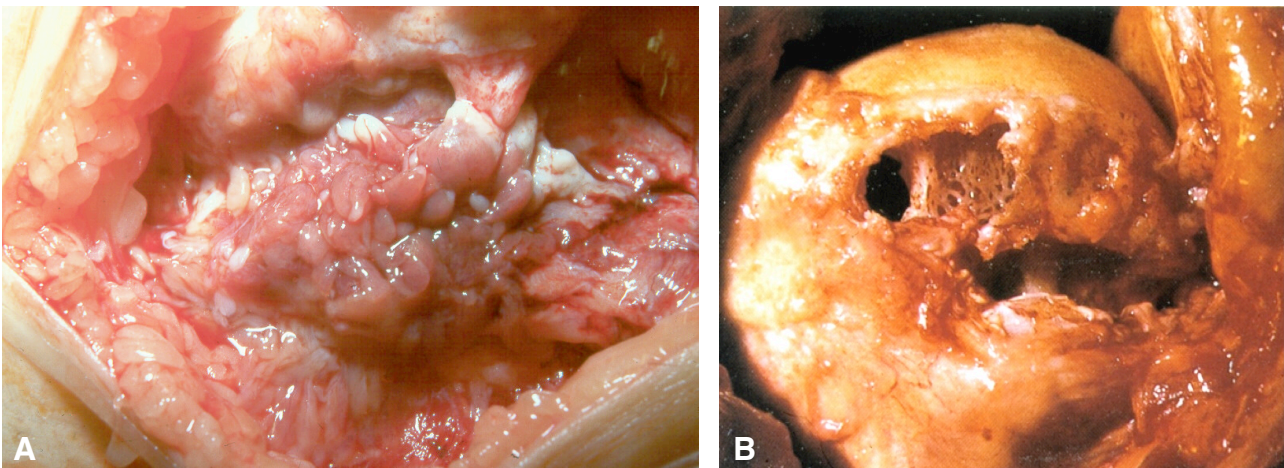
*Für Alice*

**INHALTSVERZEICHNIS**

<b>1. EINLEITUNG UND ZIELSTELLUNG</b>	<b>4</b>
<b>2. METHODIK</b>	<b>7</b>
2.1. Kontrastmitteldosierung bei niedrigen Magnetfeldstärken	7
2.2. MRT einzelner Gelenkregionen und Vergleich der bildgebenden Verfahren	8
2.3. Frühdiagnose und Verlaufsbeurteilung mittels MRT	10
<b>3. EIGENE ORIGINALARBEITEN</b>	<b>11</b>
3.1. Kontrastmitteldosierung bei niedrigen Magnetfeldstärken	12
3.2. MRT einzelner Gelenkregionen und Vergleich der bildgebenden Verfahren	19
3.2.1. Vergleich von konventioneller und Niederfeld-MRT der Hand	19
3.2.2. MRT des Rückfußes	28
3.2.3. MRT des Schultergelenkes	37
3.3. Frühdiagnose und Verlaufsbeurteilung mittels MRT	50
3.3.1. MRT zur Frühdiagnose der rheumatoiden Arthritis	50
3.3.2. MRT zur Langzeitverlaufsbeurteilung	61
<b>4. DISKUSSION UND SCHLUSSFOLGERUNGEN</b>	<b>68</b>
4.1. Klinische Implikationen und Schlussfolgerungen	73
<b>5. ZUSAMMENFASSUNG</b>	<b>75</b>
<b>6. LITERATURVERZEICHNIS</b>	<b>77</b>
<b>ERKLÄRUNG</b>	<b>85</b>
<b>DANKSAGUNG</b>	<b>86</b>

## 1. EINLEITUNG UND ZIELSTELLUNG

Die rheumatoide Arthritis (RA) ist eine Autoimmunerkrankung mit Hauptmanifestationsort an den Händen und Füßen. Die Prävalenz wird mit 1,0 % angegeben. Hauptmanifestationsort der entzündlichen Prozesse ist die Synovialmembran, welche neben dem höherliegenden Gelenkknorpel den Hauptanteil der Gelenkinnenfläche ausmacht. Durch die Entzündungsprozesse in der Synovialmembran kommt es zu Pannusbildung (*Abbildung 1A*), welche im weiteren Verlauf zu aggressiver Knochendestruktion führt (*Abbildung 1B*) und damit bereits einen irreparablen Gelenkschaden verursacht hat, der unbehandelt zu Mutilationen (Verstümmelungen) und Ankylosen führt (1). Daraus ergeben sich erhebliche Funktionseinschränkungen und ein Verlust an Lebensqualität für die Patienten und ökonomisch und volkswirtschaftliche Probleme, da voll im Arbeitsprozess stehende Menschen nur noch eingeschränkt tätig sein können und längere Zeiten der Arbeitslosigkeit und Frühberentungen resultieren (2).



**Abbildung 1: Destruierende Gelenkveränderungen bei rheumatoider Arthritis.** A – Pannusbildung im Kniegelenk [aus (11)]. B – Marginale Erosionen des Metacarpaleköpfchens.

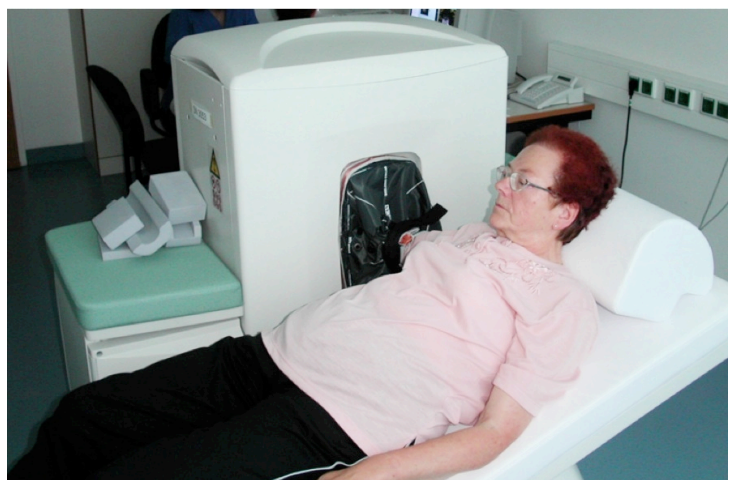Die RA wird aktuell neben klinischen und Laborkriterien durch den Nachweis erosiver Röntgenveränderungen diagnostiziert (3). Die röntgenologische Erosion ist jedoch bereits ein Indiz für die irreversible Destruktion des Gelenkes – die Entzündung der Synovialmembran muss entsprechend noch früher detektiert werden. Hierfür sind sowohl die Arthrosonographie als auch die Magnetresonanztomographie geeignet (4).

Entzündlich-rheumatische Erkrankungen des Achsenskeletts werden unter dem Begriff der Spondyloarthritiden zusammengefasst und kommen bei bis zu 1,9 % der Bevölkerung vor (5). Neben dem charakteristischen klinischen Merkmal des entzündlichen Rückenschmer-

zes, der insbesondere in der zweiten Nachthälfte auftritt, sich bei Bewegung bessert und mit wechselndem Gesäßschmerz und Morgensteifigkeit von mehr als 30 Minuten Dauer einhergeht (6), kommt es zur Manifestation entzündlicher Prozesse an den peripheren Gelenken und Enthesen (7,8). Dies kann zu diagnostischen Problemen führen, die sich mittels klinischer Untersuchung oder Röntgendiagnostik allein nicht auflösen lassen, sondern mittels Kernspintomographie weiter abgeklärt werden sollten.

Neben den peripheren Gelenken befällt die RA auch die Halswirbelsäule als sogenannte „fünfte Extremität“ des RA-Patienten sowie große, stammnahe Gelenke wie beispielsweise das Schultergelenk. Der röntgenologische Nachweis von Erosionen an den großen Gelenken wird dadurch erschwert, dass relativ viel Knochensubstanz destruiert sein muss, bevor erosive Befunde röntgenologisch nachweisbar sind. Hier bieten sich moderne Schnittbildverfahren, wie Gelenkulterschall und Magnetresonanztomographie an, um die Befunde früher und sensitiver zu detektieren (9). Dies wurde im Rahmen dieser Habilitation am Beispiel des Schultergelenkes geprüft.

Die MRT ist ein Verfahren, welches vergleichsweise hohe Kosten verursacht. Diese müssen dem Nutzen einer früheren Diagnosestellung und Therapieentscheidung gegenüber gestellt werden, wobei dem Gesundheitssystem Grenzen gesetzt sind. Des Weiteren handelt es sich bei den entzündlich-rheumatischen Gelenkerkrankungen häufig um ein polyartikuläres Geschehen, was deutliche Probleme bereits bei der Lagerung dieser Patienten in konventionellen, geschlossenen MRT-Systemen hervorruft (10). In der Regel liefert nämlich die Lagerung des Patienten in Bauchlage mit ausgestrecktem Arm (sogenannte „Superman-Position“) die besten Resultate (11). Die sogenannten Niederfeld-Magnetresonanztomographie-Geräte oder dedizierten MRTs bieten für beide Probleme Lösungskonzepte. Zum einen schonen sie durch geringe Beschaffungs-, Installations- und Betriebskosten das Budget (12), zum anderen ermöglichen sie die bequeme Lagerung der Patienten bei der Untersuchung der Hände oder Füße (*Abbildung 2*). Nachteile wie höhere Feldinhomogenitäten, fehlende Mög-



**Abbildung 2: Niederfeld-MRT.** Patientenlagerung zur Darstellung der Hand.

lichkeiten der Fettsättigung und lange Untersuchungszeiten sind zu berücksichtigen (10,12). Im Rahmen mehrerer Studien sollte in dieser Habilitation untersucht werden, ob ein nennenswerter diagnostischer Verlust beim Einsatz der Niederfeld-MRT-Geräte (0,2 Tesla) im Vergleich zu den konventionellen MRT-Geräten (1,5 Tesla) zu verzeichnen ist, und ob diese Geräte im langfristigen Einsatz und in der Frühdiagnose eingesetzt werden können.

## **1.1. Zielstellung**

Die gemeinsame Zielstellung der Habilitation war die vertiefende Evaluierung der Möglichkeiten und Herausforderungen verschiedener MRT-Geräteklassen für die Diagnostik und Verlaufsbeurteilung entzündlich-rheumatischer Gelenkerkrankungen.

Am Beispiel des Schultergelenkes sollte die diagnostische Wertigkeit der konventionellen MRT (1,5 Tesla) in der Diagnostik von Arthritiden großer Gelenke im Vergleich zur Röntgendiagnostik und Arthrosonographie evaluiert werden. Der Nutzen von Niederfeld-MRT-Geräten (0,2 Tesla) sollte bei Patienten mit rheumatoider Arthritis an den Händen und bei Patienten mit Spondyloarthritiden am Rückfuß im Vergleich mit der konventionellen MRT bewertet werden. Um die Methode bestmöglich zu standardisieren, sollte untersucht werden, welchen Einfluss die Dosierung eines paramagnetischen Kontrastmittels auf Auswerteverfahren im Rahmen klinischer Studien nimmt.

Die Bedeutung der MRT für die frühe Diagnose und die Langzeitverlaufsbeurteilung von Patienten mit rheumatoider Arthritis sollte im Rahmen dieser Habilitation ebenfalls herausgearbeitet werden.

## 2. METHODIK

### 2.1. Kontrastmitteldosierung bei niedrigen Magnetfeldstärken

Beim Einsatz neuer bildgebender Verfahren wie der Niederfeld-MRT muss zunächst geklärt werden, ob die diagnostische Aussage gleichwertig im Vergleich zu den herkömmlichen Verfahren ist und welche sonstigen Rahmenbedingungen ggf. zu berücksichtigen sind. Insbesondere ergab sich die Frage, ob die in der konventionellen MRT bei 1,5 Tesla übliche Kontrastmitteldosis von 0,1 mmol/kg Körpergewicht (einfache Dosierung) auch in der Niederfeld-MRT anwendbar ist oder ob diese Dosierung justiert werden muss (13). Diesen Zusammenhang untersuchten wir in einer methodischen Vorarbeit am Beispiel des Kontrastmittels Gadolinium-Diaminessäure (gadopentetate dimeglumine – Gd-DTPA) und verwendeten dabei sowohl Signal-zu-Rausch- als auch Kontrast-zu-Rausch-Analysen als objektive Qualitätskriterien von MR-Aufnahmen und wandten die unterschiedlichen Kontrastmitteldosierungen auch auf ein semiquantitatives Scoringverfahren an, in dessen Bewertung auch der subjektive Bildeindruck einght und das dem Ablauf in der klinischen Routine näher kommt (s. **Publikation 1**). Dabei wurde die einfache Kontrastmitteldosierung mit der doppelten Kontrastmitteldosis (0,2 mmol/kg Körpergewicht) verglichen und ein kumulatives Injektionsschema der Kontrastmittellösung angewandt. Alle übrigen Rahmenbedingungen der Studie waren konstant, darunter die verwendete Spule (dedizierte, doppelt-phasierte Radiofrequenz-Spule) und Lagerung der Hand in vertikaler Position, maschinelle Injektion des Kontrastmittels über Injektor mit einer Injektionsrate von 2 ml/s sowie die akquirierte 3D-Gradientenechosequenz mit nahezu isotropen Voxeln (0,83 mm x 0,83 mm x 0,86 mm) (14). Die gewonnenen MRT-Aufnahmen wurden verblindet im Hinblick auf Dosis des Kontrastmittels, Patientenidentifikation und Zeitpunkt der Untersuchung zwei erfahrenen Auswertern getrennt voneinander vorgelegt und beurteilt.

Ein häufiger Kritikpunkt von Studien zu bildgebenden Verfahren sind Unschärfen in der Beschreibung der zu beurteilenden Befunde (15). In allen in dieser Habilitation zusammengefassten Studien wurden klare Kriterien der einzelnen Läsionen definiert, wobei für Synovitiden und Erosionen die Definitionen der OMERACT-MRT-Arbeitsgruppe (16) übernommen und für Tenosynovitiden eine eigene Definition erstellt wurden. Letztere sind in unserer Studie erstmals einem bildgebenden Vergleich verschiedener MRT-Geräte unterzogen worden (17).

Bei der Auswertung von bildgebenden Verfahren sollte immer auch die Frage der Validität des verwendeten Auswertesystems dargelegt werden. Die Validität semiquantitativer Skalen wie der von der OMERACT-Gruppe anerkannte RAMRIS-Score (16) kann diese Validität mittels Intraklassenkorrelationskoeffizienten (Intraclass correlation coefficient – ICC) sowohl im Intra-Reader-Vergleich, also der Auswertung der Aufnahmen durch den gleichen Auswerter zu zwei Zeitpunkten mit ausreichendem Abstand dazwischen als auch dem Inter-Reader-Vergleich, also der Beurteilung der bildmorphologischen Veränderungen durch verschiedene geschulte Auswerter. Im Allgemeinen werden ICC-Werte  $> 0,8$  als sehr gut und  $> 0,9$  als exzellent eingestuft.

Auf die diagnostische Qualität der Niederfeld-MRT als eingangs erwähnte weitere wichtige Prämisse für die Verwendung dieses bildgebenden Verfahrens in wissenschaftlichen Studien wird im folgenden Abschnitt eingegangen.

## **2.2. MRT einzelner Gelenkregionen und Vergleich der bildgebenden Verfahren**

Magnetresonanztomographische Standardgeräte sind als Tunnelsystem konstruiert, innerhalb dessen die Magnetfeldstärke über einen relativ großen Bereich homogen ist, das durch einen supraleitenden Elektromagneten erzeugt wird und die in der Regel bei einer Feldstärke von 1,5 Tesla operieren. Gegen diese Geräteklasse müssen neue diagnostische Verfahren wie die Niederfeld-MRT ihre diagnostischen Fähigkeiten unter Beweis stellen. Vergleiche der beiden MRT-Geräteklassen sind sowohl durch einen intraindividuellen Vergleich als auch durch einen Gruppenvergleich von zwei in ihren Rahmenparametern homogenen Patientengruppen möglich, wobei mit der erstgenannten Methode härtere wissenschaftliche Daten zu erzielen sind. Im intraindividuellen Vergleich wurde die Wertigkeit der beiden MRT-Geräte für die Diagnostik von Arthritiden der kleinen Gelenke der Finger- und Handwurzel bei Patienten mit RA untersucht (s. **Publikation 2**). Im Gegensatz zu bisher publizierten Studien (18-20) legten wir den besonderen Schwerpunkt auf das semiquantitative Scoring der MR-tomographischen Veränderungen (17). Dieser Ansatz wird im Rahmen klinischer Studien verwendet und ist damit relevanter, als ein dichotomes Auswertesystem (Ja/Nein-Entscheidung). Ein weiteres wichtiges Merkmal unserer Studie besteht darin, dass keine der beiden Methoden zum „Goldstandard“ erklärt wurde, sondern dass die Befunde gelenkweise in Form von Kontingenztafeln, mittels  $\kappa$ -Statistik (Kappa-Statistik)



tik) und dem McNemar-Test auf Übereinstimmungen bzw. Unterschiede untersucht wurden. Die Definition eines „Goldstandards“ gestattet zwar in der Folge die Berechnung von Sensitivität, Spezifität, positivem und negativem prädiktivem Wert, hat Schwächen jedoch dann, wenn das neue Verfahren eine bessere Sensitivität aufweist, da rechnerisch 100 % nicht überstiegen werden können. Mit dem gewichteten  $\kappa$ -Wert werden Unterschiede bzw. Übereinstimmungen zweier Skalen beschrieben und das Maß der Abweichung vom Optimalfall mit einberechnet (21).  $\kappa$ -Werte  $< 0,4$  werden als schlecht, Werte zwischen  $0,4$  und  $0,75$  als moderat bis gut und Werte über  $0,75$  als exzellent eingestuft (22,23).

Zur Evaluation der diagnostischen Möglichkeiten der MRT am Rückfußskelett bei Patienten mit Spondyloarthritis wurden konsekutive Patienten randomisiert in die Studie eingeschlossen und entweder am konventionellen MR-Tomographen oder mit dem Niederfeld-MRT-Gerät untersucht (s. **Publikation 3**). Mit Hilfe des Fisher-Tests wurden die Häufigkeiten der Läsionen in beiden Gruppen auf signifikante Unterschiede geprüft. Es wurden weitgehend ähnliche, geräteadaptierte Sequenzprotokolle angewendet, welche sowohl native, inversionspräparierte T2-gewichtete als auch kontrastverstärkte Sequenzen nach Injektion eines paramagnetischen Kontrastmittels beinhalteten (24).

Die MR-tomographische Darstellung großer Gelenke birgt andere diagnostische Herausforderungen als die Darstellung kleiner Gelenke. Insbesondere kommt es nicht zum Problem, dass die Patienten eine unbequeme, schmerzhaft und verkrampfte Haltung in Bauchlage einnehmen müssen. Deshalb haben wir die konventionelle MRT angewandt und die diagnostischen Möglichkeiten großer Gelenke am Beispiel des Schultergelenkes untersucht und den Methoden konventioneller Radiographie und Arthrosonographie gegenüber gestellt (s. **Publikation 4**). In dieser prospektiven Vergleichsstudie wurden alle drei bildgebenden Verfahren und die klinische Untersuchung von jeweils anderen Untersuchern durchgeführt bzw. ausgewertet, die alle untereinander verblindet in Bezug auf die Ergebnisse der anderen Verfahren waren (25). Es wurde ein standardisiertes Ultraschall-Untersuchungsprotokoll (26) sowie State-of-the-art-MRT-Sequenzen (27) angewandt.

Die dynamische kontrastmittelverstärkte Magnetresonanztomographie erwies sich als vielversprechendes Zusatzinstrument für die Diagnostik entzündlicher Gelenkveränderungen der Kniegelenke (28,29) und Sakroiliakgelenke (30,31). Folglich prüften wir auch deren Einsetzbarkeit für die MRT der Schultergelenke. Mit der dynamischen KM-verstärkten MRT werden schnelle Akquisitionssequenzen während der Kontrastmittelinjektion über ei-

nen längeren Zeitraum (in der Regel fünf bis 10 Minuten) wiederholt, im Anschluss regions of interest im Gelenk und im Kontrollgewebe definiert und daraus die Anstiegssteilheit (Slope) und die prozentuale Zunahme der Signalintensität berechnet. Diese Ergebnisse können dann für Verlaufsbeurteilungen, Risikoabschätzungen und die Korrelation mit klinischen Daten verwendet werden.

### 2.3. Frühdiagnose und Verlaufsbeurteilung mittels MRT

Der Wert der MRT für die Frühdiagnose und Prognoseabschätzung der RA wird vielfach diskutiert (4). Prognostisch hilfreiche Aussagen können durch Bestimmung des positiven und negativen prädiktiven Wertes, durch Bestimmung des relativen Risikos und der Odds Ratio oder durch schrittweise logistische Regressionsanalyse bestimmt werden (32,33). An einem Kollektiv von 99 Patienten mit zum Zeitpunkt der MRT-Untersuchung unbekannter Diagnose und ohne Nachweis von Erosionen in Röntgenaufnahmen der Hände und Füße führten wir eine solche schrittweise logistische Regressionsanalyse durch (33). Dabei gingen Synovitiden der Handgelenke, MCP-Gelenke und PIP-Gelenke, Erosionen der Handgelenke, MCP-Gelenke und PIP-Gelenke und Tenosynovitiden der Beugesehnen und Strecksehnen (insgesamt acht MRT-Parameter), die Klassifikationskriterien des American College of Rheumatology (ACR) und Laborparameter (Rheumafaktoren, Anti-CCP-Antikörper, antiknukleäre Antikörper, C-reaktives Protein) in die Analyse ein (s. **Publikation 5**). Der „Goldstandard“ war die klinische Diagnose (RA versus keine RA), welche durch einen rheumatologischen Experten nach Wiedervorstellung des Patienten unter Zuhilfenahme aller klinischer und paraklinischer Informationen gestellt wurde (34).

Die longitudinale Analyse entzündlicher Gelenkbefunde bei Patienten mit RA trägt wesentlich zum Verständnis der Pathogenese der Erkrankung bei und hilft, verschiedene bildgebende Verfahren hinsichtlich deren diagnostischer Aussage einzugruppiieren. In einer Studie über eine Gesamtlaufzeit von sieben Jahren adressierten wir diese Fragestellung (s. **Publikation 6**). Drei bildgebende Verfahren – konventionelle Röntgendiagnostik, Ultraschall und Niederfeld-MRT – wurden unabhängig voneinander evaluiert. In dieser Studie wurden die Befunde der PIP- und MCP-Gelenke verglichen und mit einem dichotomen Verfahren ausgewertet (35).

### 3. EIGENE ORIGINALARBEITEN ALS BESTANDTEIL DER HABILITATIONSSCHRIFT

#### Kontrastmitteldosierung bei niedrigen Magnetfeldstärken

1. Eshed I, Althoff CE, Schink T, Scheel AK, Schirmer C, Backhaus M, Lembcke A, Bollow M, Hamm B, **Hermann KG**. Low-field MRI for assessing synovitis in patients with rheumatoid arthritis. Impact of Gd-DTPA dose on synovitis scoring. Scand J Rheumatol 2006; 35(4):277-82.

#### MRT einzelner Gelenkregionen und Vergleich der bildgebenden Verfahren

2. Schirmer C, Scheel AK, Althoff CE, Schink T, Eshed I, Lembcke A, Burmester GR, Backhaus M, Hamm B, **Hermann KG**. Diagnostic quality and scoring of synovitis, tenosynovitis and erosions in low-field MRI of patients with rheumatoid arthritis: A comparison with conventional MRI. Ann Rheum Dis 2007; 66(4):522-9.
3. Eshed I, Althoff CE, Feist E, Minden K, Schink T, Hamm B, **Hermann KG**. Magnetic resonance imaging of hindfoot involvement in patients with spondyloarthritides: Comparison of low-field and high-field strength units. Eur J Radiol. 2008; 65(1):140-7.
4. **Hermann KG**, Backhaus M, Schneider U, Labs K, Loreck D, Zühlendorf S, Schink T, Fischer T, Hamm B, Bollow M. Rheumatoid arthritis of the shoulder joint: Comparison of conventional radiography, ultrasound, and dynamic contrast-enhanced magnetic resonance imaging. Arthritis Rheum. 2003 Dec;48(12):3338-49.

#### Frühd Diagnose und Verlaufsbeurteilung mittels MRT

5. Eshed I, Feist E, Althoff CE, Hamm B, Konen E, Burmester GR, Backhaus M, **Hermann KG**. Tenosynovitis of the flexor tendons of the hand detected by MRI: An early indicator of rheumatoid arthritis. Rheumatology 2009 – in press.
6. Scheel AK\*, **Hermann KG\***, Ohrndorf S, Werner C, Schirmer C, Detert J, Bollow M, Hamm B, Müller GA, Burmester GR, Backhaus M. Prospective long term follow-up imaging study comparing radiography, ultrasonography and magnetic resonance imaging in rheumatoid arthritis finger joints. Ann Rheum Dis 2006;65:595–600.

\* Gleichwertiger Beitrag beider Autoren zur Studie.

### 3.1. Kontrastmitteldosierung bei niedrigen Magnetfeldstärken

#### Publikation 1

Eshed I, Althoff CE, Schink T, Scheel AK, Schirmer C, Backhaus M, Lembcke A, Bollow M, Hamm B, **Hermann KG**.

Low-field MRI for assessing synovitis in patients with rheumatoid arthritis. Impact of Gd-DTPA dose on synovitis scoring.

Scand J Rheumatol 2006; 35(4):277-82.

ISSN: 0300-9742, DOI 10.1080/03009740600709873

Die Kontrastmitteldosierung hat Einfluss auf semiquantitative Scoringergebnisse in der Niederfeld-MRT. Bei 38 Patienten mit rheumatoider Arthritis zeigten sich signifikant erhöhte Kontrast-zu-Rausch-Verhältnisse ( $p = 0,00002$ ). Die Scoring-Ergebnisse differierten ebenfalls signifikant: Auswerter A beurteilte bei einfacher Kontrastmitteldosierung durchschnittlich  $1,7 \pm 0,93$  und bei doppelter Dosierung des Kontrastmittels  $1,9 \pm 0,96$  ( $p = 0,0034$ ); Auswerter B beurteilte bei einfacher Dosierung durchschnittlich  $1,6 \pm 1,0$  und bei doppelter Dosierung  $2,0 \pm 0,91$  ( $p = 0,00001$ ). Die höhere Kontrastmitteldosis führt also nicht nur zu einem besseren Bildeindruck (höheres Kontrast-zu-Rausch-Verhältnis), sondern dieser bessere Kontrast schlägt sich auch in den Scoring-Ergebnissen nieder.

Die semiquantitative Scoring-Methode als solche erwies sich als sehr robust – der Intraklassenkorrelationskoeffizient für die Inter-Reader-Übereinstimmung betrug für die einfache Kontrastmitteldosierung 0,75 (Konfidenzintervall: 0,65 - 0,82) und für die doppelte Kontrastmitteldosierung 0,83 (Konfidenzintervall: 0,76 - 0,88).

## Low-field MRI for assessing synovitis in patients with rheumatoid arthritis. Impact of Gd-DTPA dose on synovitis scoring

I Eshed<sup>1</sup>, CE Althoff<sup>1</sup>, T Schink<sup>2</sup>, AK Scheel<sup>3</sup>, C Schirmer<sup>1</sup>, M Backhaus<sup>4</sup>, A Lembcke<sup>1</sup>, M Bollow<sup>5</sup>, B Hamm<sup>1</sup>, K-GA Hermann<sup>1</sup>

Departments of <sup>1</sup>Radiology, <sup>2</sup>Medical Biometry and <sup>4</sup>Rheumatology and Clinical Immunology, Charité Medical School, Berlin, <sup>3</sup>Department of Medicine, Division of Nephrology and Rheumatology, Georg-August University, Göttingen, and <sup>5</sup>Department of Radiology, Augusta Hospital, Bochum, Germany

**Objective:** To investigate the impact of a double dose compared to a single dose of contrast material in low-field magnetic resonance imaging (MRI) on semi-quantitative scoring of synovitis in patients with rheumatoid arthritis (RA).

**Methods:** This prospective study included 38 RA patients (23 women and 15 men, mean age 51 years). All patients underwent low-field MRI of the hand before administration of contrast medium, after intravenous injection of 0.1 mmol/kg gadolinium diethylenetriaminepentaacetic acid (Gd-DTPA), and after another dose of 0.1 mmol/kg Gd-DTPA. Two readers (A and B) blinded to dosage independently scored the single dose and double dose image sets for synovitis according to outcome measures in rheumatology (OMERACT) recommendations. Contrast-to-noise ratio (CNR) and signal-to-noise ratio (SNR) were also calculated for each set.

**Results:** 149 metacarpophalangeal (MCP) joints were evaluated. There was good inter-reader agreement for each of the two sets (intra-class correlation coefficient of 0.75 for the single dose set and 0.83 for the double dose). Median CNR and SNR values were 5.4 and 15.9, respectively, for the single dose set and 8.5 and 16.6, respectively, for the double dose set ( $p < 0.0001$ ). Single dose set mean synovitis scores were 1.7 and 1.6 for readers A and B, respectively. Double dose set scores were 1.9 and 2.0, respectively. Thus, higher synovitis scores were recorded for the double dose sets than the single dose sets ( $p < 0.005$ ).

**Conclusion:** In low-field MRI, when evaluating RA, the dose of the contrast material influences synovitis scoring. Therefore, dosage of contrast material should be taken into consideration when using extremity dedicated low-field MRI.

Dedicated low-field magnetic resonance imaging (MRI)

Contrast enhancement of a tissue depends, up to a

### Copyright-Hinweis

Aus lizenzrechtlichen Gründen kann der gesamte Artikel nicht online zur Verfügung gestellt werden. Bitte bemühen Sie die papiergebundene Version oder prüfen Sie online, ob Sie Zugriff auf den Volltext des Artikels haben:

<http://informahealthcare.com/doi/pdf/10.1080/03009740600709873>

DOI: 10.1080/03009740600709873

**Copyright-Hinweis**

Aus lizenzrechtlichen Gründen kann der gesamte Artikel nicht online zur Verfügung gestellt werden. Bitte bemühen Sie die papiergebundene Version oder prüfen Sie online, ob Sie Zugriff auf den Volltext des Artikels haben:

<http://informahealthcare.com/doi/pdf/10.1080/03009740600709873>

DOI: 10.1080/03009740600709873

**Copyright-Hinweis**

Aus lizenzrechtlichen Gründen kann der gesamte Artikel nicht online zur Verfügung gestellt werden. Bitte bemühen Sie die papiergebundene Version oder prüfen Sie online, ob Sie Zugriff auf den Volltext des Artikels haben:

<http://informahealthcare.com/doi/pdf/10.1080/03009740600709873>

DOI: 10.1080/03009740600709873

**Copyright-Hinweis**

Aus lizenzrechtlichen Gründen kann der gesamte Artikel nicht online zur Verfügung gestellt werden. Bitte bemühen Sie die papiergebundene Version oder prüfen Sie online, ob Sie Zugriff auf den Volltext des Artikels haben:

<http://informahealthcare.com/doi/pdf/10.1080/03009740600709873>

DOI: 10.1080/03009740600709873



**Copyright-Hinweis**

Aus lizenzrechtlichen Gründen kann der gesamte Artikel nicht online zur Verfügung gestellt werden. Bitte bemühen Sie die papiergebundene Version oder prüfen Sie online, ob Sie Zugriff auf den Volltext des Artikels haben:

<http://informahealthcare.com/doi/pdf/10.1080/03009740600709873>

DOI: 10.1080/03009740600709873

**Copyright-Hinweis**

Aus lizenzrechtlichen Gründen kann der gesamte Artikel nicht online zur Verfügung gestellt werden. Bitte bemühen Sie die papiergebundene Version oder prüfen Sie online, ob Sie Zugriff auf den Volltext des Artikels haben:

<http://informahealthcare.com/doi/pdf/10.1080/03009740600709873>

DOI: 10.1080/03009740600709873

## 3.2. MRT einzelner Gelenkregionen und Vergleich der bildgebenden Verfahren

### 3.2.1. Vergleich von konventioneller und Niederfeld-MRT der Hand

#### Publikation 2

Schirmer C, Scheel AK, Althoff CE, Schink T, Eshed I, Lembcke A, Burmester GR, Backhaus M, Hamm B, **Hermann KG**.

Diagnostic quality and scoring of synovitis, tenosynovitis and erosions in low-field MRI of patients with rheumatoid arthritis: A comparison with conventional MRI.

Ann Rheum Dis 2007; 66(4):522-9.

<http://ard.bmj.com/cgi/reprint/66/4/522.pdf> – ISSN: 0003-4967, DOI 10.1136/ard.2006.056366

In dieser Studie musste sich die Niederfeld-MRT im intraindividuellen Vergleich mit der konventionellen MRT in der Diagnostik der rheumatoiden Arthritis an den kleinen Fingergelenken unter Beweis stellen. 17 Patienten unterzogen sich einer doppelten MRT-Untersuchung am gleichen Tag in einem Mindestabstand von sieben Stunden.

Die Hände wurden mit den jeweiligen klinischen Standardprotokollen unter Ausschöpfung der technischen Möglichkeiten in der MRT untersucht. Insbesondere wurde darauf geachtet, dass die Schichtdicke und die Schichtauflösung möglichst nahe beieinander sind. Da die Fettsättigung nur in der konventionellen MRT verfügbar war, konnte sie nur dort angewandt werden.

Im Ergebnis zeigten sich sehr gute Übereinstimmungen zwischen beiden Geräten sowohl für die Diagnostik der Synovitis ( $\kappa$ -Werte zwischen 0,69 – 0,94) als auch von Erosionen ( $\kappa$ -Werte 0,65 – 1,0). Signifikante Unterschiede der Scoring-Ergebnisse fanden sich bei der Darstellung der Gelenke des kleinen Fingers. Das Scoring der Tenosynovitis der Beuge-sehnen resultierte in moderater Übereinstimmung beider Geräte mit  $\kappa$ -Werten zwischen 0,51 und 0,65.

Auch in dieser Studie konnte die Robustheit der Scoring-Methode belegt werden durch hohe Intraklassenkorrelationskoeffizienten für die semiquantitative Beurteilung von Erosionen und Synovitiden (ICC-Werte 0,81 – 0,88) sowie gute Übereinstimmung für die Beurteilung der Tenosynovitis (ICC-Werte 0,74 – 0,76).

## EXTENDED REPORT

# Diagnostic quality and scoring of synovitis, tenosynovitis and erosions in low-field MRI of patients with rheumatoid arthritis: a comparison with conventional MRI

Claudia Schirmer, Alexander K Scheel, Christian E Althoff, Tania Schink, Iris Eshed, Alexander Lembcke, Gerd-Rüdiger Burmester, Marina Backhaus, Bernd Hamm, Kay-Geert A Hermann

*Ann Rheum Dis* 2007;66:522–529. doi: 10.1136/ard.2006.056366

**Objective:** To compare dedicated low-field MRI (lfMRI) with conventional MRI (cMRI) in the detection and scoring of synovitis, tenosynovitis and erosions in patients with rheumatoid arthritis.

**Patients and methods:** The wrist and finger joints of 17 patients with rheumatoid arthritis (median (range) disease duration 8 years (7–12); Disease Activity Score 3.3 (2.6–4.5)) were examined by 0.2 T lfMRI and 1.5 T cMRI. The protocols comprised coronal spin-echo and three-dimensional gradient-echo sequences before and after contrast medium administration. Synovitis of the metacarpophalangeal and proximal interphalangeal joints 2–5 and the wrist joints was scored according to Outcome Measures in Rheumatology recommendations. Tenosynovitis and erosions were scored using 4-point and 6-point scales, respectively. The results were analysed by calculating  $\kappa$  values and performing McNemar's test intra-individually on a joint-by-joint basis.

**Results:** Agreement between the two MRI techniques was good to excellent for synovitis and erosions, and moderate for tenosynovitis. Of the 306 joints evaluated, 245 and 200 joints showed synovitis in lfMRI and cMRI, respectively. Scoring of synovitis of the finger joints yielded  $\kappa$  values from 0.69 to 0.94. Of the 68 flexor tendons evaluated, tenosynovitis was diagnosed by lfMRI in 24 and by cMRI in 33 instances. Of the 391 bones evaluated, 154 and 139 showed erosions in lfMRI and cMRI, respectively.  $\kappa$  values for erosion scores were between 0.65 and 1.

**Conclusion:** Dedicated, lfMRI shows high agreement with cMRI in diagnosing and scoring synovitis, tenosynovitis and erosions in rheumatoid arthritis when using standardised scoring systems.

See end of article for authors' affiliations

Correspondence to:  
Dr K-G A Hermann,  
Department of Radiology,  
Charité Medical School,  
Campus Mitte, Charitéplatz  
1, 10117 Berlin, Germany;  
kgh@charite.de

Accepted 16 October 2006  
Published Online First  
19 October 2006

Rheumatoid arthritis is an inflammatory systemic autoimmune disease of unknown aetiology that predominantly affects the synovial membrane of joints. It is characterised by polyarticular manifestation, typically with a symmetrical pattern of involvement. In most cases, the finger and toe joints and the wrist are affected.<sup>1</sup> The earliest lesion visible on conventional radiographs is juxta-articular osteoporosis.<sup>2,3</sup> Conventional radiography is the most widely used imaging modality for the diagnosis of rheumatoid arthritis. Its advantages are its wide availability, good standardisation and validated evaluation scales.<sup>4</sup>

Synovitis is among the earliest abnormalities in early arthritis, but is identified on radiographs only indirectly or not at all. Other processes such as tenosynovitis and bone marrow oedema are also not detected by conventional x ray.<sup>5–7</sup> Destructive lesions such as erosions become visible on radiographs only at later stages of the disease.<sup>2,8–10</sup>

Studies have shown that MRI demonstrates synovitis and minute erosive lesions shortly after initial clinical manifestation.<sup>11–13</sup> Moreover, MRI is also able to identify cartilaginous defects<sup>14,15</sup> and bone marrow oedema.<sup>9,16</sup>

Dedicated low-field MRI (lfMRI) systems with a field strength of 0.2 T belong to a new generation of magnetic resonance scanners with new imaging options. These scanners provide excellent patient comfort, which makes the examination much more acceptable.<sup>17</sup> Cost effectiveness is another point that must be considered. Not much data are available regarding direct comparison of conventional MRI (cMRI) and extremity MRI in patients with rheumatoid arthritis. Only a few studies have investigated whether lfMRI and cMRI are comparable with regard to the detection of erosions and synovitis.<sup>17–19</sup> Only

one of them attempted to compare pathology scoring results between the two units.<sup>18</sup> Although low-field scanners have not been available for long, the limited data obtained so far suggest that they are equal or only slightly inferior to conventional magnetic resonance scanners in terms of image quality in the evaluation of patients with rheumatoid arthritis, and that there is no loss of diagnostic information.<sup>20</sup>

We present a cross-sectional study comparing 1.5 T cMRI and 0.2 T low-field extremity MRI in terms of their ability to detect and score synovitis, tenosynovitis, and erosions of the wrist and finger joints in patients with rheumatoid arthritis.

## PATIENTS AND METHODS

### Patients

Seventeen patients (7 men and 10 women with a mean age of 58 years (range 26–75 years)) with rheumatoid arthritis according to the criteria of the American College of Rheumatology<sup>21</sup> were enrolled in the study by a university-based rheumatological outpatient service. Median disease duration was 8 years (range 5–41 years). Rheumatoid factor, antinuclear antibodies, antibodies against cyclic citrullinated peptides and the Disease Activity Score of 28 joints<sup>22</sup> were determined in all patients. The study was approved by the local ethics committee and all patients gave written informed consent.

**Abbreviations:** cMRI, conventional magnetic resonance imaging; Gd-DTPA, gadolinium diethylenetriaminepentaacetic acid; lfMRI, low-field magnetic resonance imaging; MCP, metacarpophalangeal; OMERACT, Outcome Measures in Rheumatology; PIP, proximal interphalangeal; RAMRIS, Rheumatoid Arthritis Magnetic Resonance Imaging Score

**Table 1** Parameters of the MRI sequences used

	TR (ms)	TE (ms)/TI (ms)	Flip angle (deg)	In-plane resolution (mm <sup>2</sup> )	Slice thickness/gap (mm)	FOV (mm)	Matrix size	Time (min:s)
Low-field MRI (0.2 T)								
GE-STIR	700	16/75	90	1.13×0.54	3/0.3	180	192×256	5:19
T1 SE	520	26	90	0.56×0.56	3.5/0.3	180	320×512	5:35
T1 GRE	35	16	65	0.83×0.83	0.86/0	160	256×256	8:00
Conventional MRI (1.5 T)								
STIR	5000	65/150	90	0.70×0.70	3/0.3	180	256×256	1:57
T1 SE	500	21	90	0.35×0.35	3.0/0.3	180	512×512	4:21
T1 GRE	8.8	3.5	8	0.47×0.47	1.0/0	180	384×384	3:43

FOV, field of view; GE-STIR, gradient recalled echo STIR; STIR, short-tau inversion-recovery; T1 SE, T1-weighted spin-echo sequence; T1 GRE, T1-weighted gradient recalled echo sequence; TE, echo time; TI, inversion time; TR, repetition time.

### Magnetic resonance imaging

All patients underwent cMRI and lfMRI on the same day. Both MRI examinations were performed with the administration of the paramagnetic contrast medium, gadolinium diethylenetriaminepentaacetic acid (Gd-DTPA; Magnevist, Schering, Berlin, Germany), which was administered at a dose of 0.2 mmol/kg body weight for lfMRI<sup>23</sup> and 0.1 mmol/kg body weight for cMRI. Both MRI examinations were performed with a minimum delay of 7 h.

### MRI protocols

#### Low-field MRI

The patients were examined on a 0.2 T, dedicated low-field magnetic resonance scanner (C-scan, Esaote Biomedica, Genoa, Italy) using a dedicated hand coil. The patients were examined in a semi-sitting position with the arm abducted and the hand in the coil.

The imaging protocol was chosen in accordance with the guidelines of the MRI in rheumatoid arthritis study group of the Outcome Measures in Rheumatology (OMERACT) initiative.<sup>24–26</sup>

The following sequences were acquired: gradient-echo short-tau inversion-recovery sequence in coronal orientation, T1-weighted spin-echo sequence in axial and coronal orientations and T1-weighted three-dimensional gradient-echo sequence in coronal orientation before and after bolus administration of contrast medium. Table 1 summarises the sequence parameters.

The dataset acquired with the T1-weighted three-dimensional gradient-echo sequence was used for reconstruction of axial views.

#### Conventional MRI

The high-field examination was performed on a 1.5-T, whole-body magnetic resonance scanner (Sonata, Siemens Medical Solutions, Erlangen, Germany) using a large flexible surface coil. The patient was positioned prone with the hand extended over the head.

The following sequences were acquired: short-tau inversion-recovery sequence in coronal orientation, T1-weighted spin-echo sequence in axial and coronal orientations, three-dimensional gradient recalled echo sequences in coronal orientation before and after bolus administration of the contrast medium, and T1-weighted, fat-saturated spin-echo sequence. Table 1 summarises the sequence parameters. The three-dimensional dataset was reconstructed in axial orientation.

#### Image analysis

The magnetic resonance images were evaluated by KGH and CS who were blinded to the clinical data. Discrepant results were solved by consensus. The images of the lfMRI and cMRI examinations were reviewed with an interval of 3 months in between. Images were evaluated for synovitis of the metacarpophalangeal (MCP) and proximal interphalangeal (PIP) joints 2–5, the radiocarpal joint, the distal radioulnar joint, the styloid process of ulna, the proximal and distal intercarpal joints, and carpometacarpal joints 1–5 and for tenosynovitis of the flexor tendons of fingers 2–5. The presence of erosions was evaluated at the MCP and PIP joints 2–5 of the fingers, all carpal bones, including the distal radius and ulna, and the base of the metacarpal bones 1–5. The presence of bone marrow oedema was not included in the analysis because the gradient-echo short-tau inversion-recovery sequence of the lfMRI system

**Table 2** Detection and scoring of synovitis at metacarpophalangeal and proximal interphalangeal joints (n = 136)

Joint	Synovitis		κ†	CI†	p Value‡ (McNemar)
	Low-field MRI (n)*	Conventional MRI (n)*			
2nd MCP	17	16	0.94	0.88 to 0.99	0.359
3rd MCP	15	13	0.93	0.87 to 0.99	1.000
4th MCP	12	10	0.81	0.62 to 0.99	1.000
5th MCP	15	12	0.89	0.80 to 0.98	0.007
2nd PIP	12	10	0.90	0.82 to 0.98	0.726
3rd PIP	14	10	0.94	0.87 to 0.99	0.062
4th PIP	16	13	0.92	0.86 to 0.97	0.179
5th PIP	14	8	0.74	0.53 to 0.94	0.005
Total	115	92			

MCP, metacarpophalangeal joint; PIP, proximal interphalangeal joint.

\*Number of affected joints.

†Based on scoring results of individual joints.

**Table 3** Detection and scoring of synovitis at wrist joints (n = 170)

Joint	Synovitis		$\kappa$ †	CI†	p Value† (McNemar)
	Low-field MRI (n)*	Conventional MRI (n)*			
Radiocarpal	11	8	0.77	0.56 to 0.98	0.187
Distal radioulnar	12	10	0.72	0.58 to 0.86	0.007
Styloid process	13	12	0.83	0.71 to 0.95	0.031
Proximal intercarpal	16	13	0.89	0.79 to 0.98	0.015
Distal intercarpal	16	12	0.90	0.81 to 0.99	0.031
CMC 1	16	14	0.92	0.87 to 0.98	0.453
CMC 2	13	9	0.69	0.40 to 0.98	0.062
CMC 3	11	9	0.73	0.58 to 0.87	0.035
CMC 4	11	10	0.77	0.62 to 0.92	0.109
CMC 5	11	11	0.83	0.68 to 0.98	0.312
Total	130	108			

CMC, carpometacarpal joint.

\*Number of affected joints.

†Based on scoring results of individual joints.

did not yield artefact-free images in all cases, which might have biased the results.

### Definition of lesions

Erosions and synovitis were defined as suggested by the OMERACT group.<sup>26</sup> According to these definitions, synovitis is an area in the synovial compartment that shows above-normal enhancement after Gd-DTPA administration of a thickness greater than the width of the normal synovium. A published and validated definition for tenosynovitis does not exist. On the basis of the description of synovitis, we defined tenosynovitis as follows: an area adjacent to a tendon with an above-normal enhancement and an abnormal thickening of the tendon sheath. An erosion is defined by the OMERACT group as a sharply margined bone lesion with correct juxta-articular localisation. T1-weighted magnetic resonance images depict an erosion as a lesion with low signal intensity in at least two planes, with cortical disruption seen in at least one plane.

### Scoring

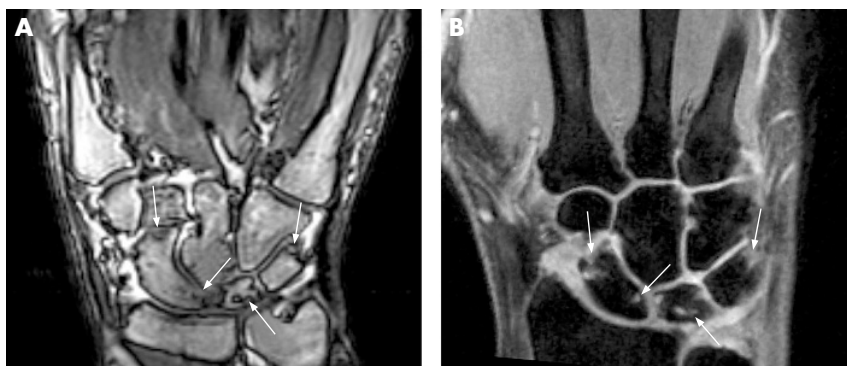Images were analysed using the semiquantitative synovitis scale recommended by the OMERACT group (Rheumatoid Arthritis Magnetic Resonance Imaging Score, RAMRIS)<sup>26</sup> and a system based on the OMERACT scale for evaluation of tenosynovitis.

The synovitis scale assigns one of four scores: 0 for no synovitis, 1 for mild synovitis, 2 for moderate synovitis and 3 for severe synovitis. Tenosynovitis was evaluated in the same fashion (0, no; 1, mild; 2, moderate; and 3, severe tenosynovitis). Only the flexor tendons of digits 2–5 were evaluated. The extensor tendons were deemed too small for semiquantitative scoring.

Erosions were assessed using a semiquantitative scoring system based on the radiographic scoring system according to Larsen *et al*<sup>27</sup> modified for analysis of magnetic resonance images. Points are assigned as follows: 0, no erosions; 1, no erosions but narrowing of the joint cleft or contour irregularities; 2, erosions involving up to 25% of the joint area; 3, erosions of up to 50% of the area; 4, erosions of up to 75% of the area; 5, >75% of the joint area damaged by erosions or mutilation. The joint area is defined as the sum of the joint surfaces of the metacarpal head and the base of the proximal phalanx for the MCP joint and as the sum of the head of the proximal phalanx and the base of the middle phalanx for the PIP joint.

### Inter-reader agreement

A subset of 20 MRI examinations (10 lfMRI, 10 cMRI) was selected to test for inter-reader agreement as a separate analysis 8 months after the original image analysis. Here, both the readers scored the MRI images separately.



**Figure 1** Comparison of erosions at the carpal bones in a 60-year-old patient with rheumatoid arthritis since 5 years. Gradient-echo sequence after contrast injection acquired by low-field MRI (A) and contrast-enhanced gradient-echo sequence with fat suppression (B) of the wrist show the same erosions at the scaphoid, lunate and triquetrum bones (arrows). In addition, mild synovitis is seen in both examinations, partly also within the erosions.

**Table 4** Detection and scoring of tenosynovitis of flexor tendons (n = 68)

Flexor tendon	Tenosynovitis		$\kappa$ †	CI†	p Value† (McNemar)
	Low-field MRI (n)*	Conventional MRI (n)*			
2nd finger	6	8	0.60	0.25 to 0.95	0.109
3rd finger	8	10	0.51	0.21 to 0.80	0.492
4th finger	5	8	0.59	0.36 to 0.82	0.687
5th finger	5	7	0.65	0.26 to 1.00	0.226
Total	24	33			

\*Number of affected tendons.

†Based on scoring results of individual tendons.

### Statistical analysis

Neither of the imaging techniques evaluated in this study was regarded as the gold standard. Therefore, the  $\kappa$  coefficient was used to describe agreement between the two techniques. A poor agreement was assumed at  $\kappa < 0.4$ , moderate to good agreement at values 0.4–0.75 and excellent agreement at values  $> 0.75$ .<sup>28</sup> Systematical differences between both methods were tested by applying McNemar's test as a significance test on a joint-by-joint or bone-by-bone basis. Significance was assumed at  $p < 0.05$ . The scores of the individual joints assigned with both MRI techniques were represented in contingency tables. StatXact with Cytel Studio, V.6.1 (Cytel, Cambridge, Massachusetts, USA; software for exact non-parametric inference) was used to calculate weighted  $\kappa$  coefficients and to perform the McNemar tests and SPSS for Windows, V.11.0, to establish the contingency tables. Inter-reader agreement was calculated using both weighted  $\kappa$  values as well as intraclass correlation coefficients.

### RESULTS

Seventeen patients were evaluated for synovitis, tenosynovitis and erosions of the clinically dominant hand (13 right and 4 left); 12 of the patients (71%) had a positive rheumatoid factor. Disease activity was moderate (median disease Activity Score of 28 joints was 3.3 (quartiles 2.6; 4.5)). The antinuclear antibody test was positive in 13 patients (76%) and antibodies against cyclic citrullinated peptides were identified in 10 patients (59%).

A total of 306 joints were evaluated for synovitis. Overall agreement between both magnetic resonance techniques was good to excellent. Table 2 summarises the findings with regard to synovitis at the finger joints. There was excellent agreement of synovitis scoring ( $\kappa = 0.81$ – $0.94$ ) for all joints except for PIP joint 5, for which agreement was good (0.74). The contingency tables for the joints evaluated show that higher scores are assigned with lfMRI. Significantly different scores were

identified for MCP joint 5 and PIP joint 5. Table 3 summarises the  $\kappa$  values and results of McNemar's test for the wrist joints. Agreement was good to excellent ( $\kappa = 0.69$ – $0.93$ ), as fig 1 shows. Significant differences were seen for the distal radio-ulnar joint, the proximal and distal rows of intercarpal joints, the styloid process and carpometacarpal joint 3, with higher scores being assigned with lfMRI.

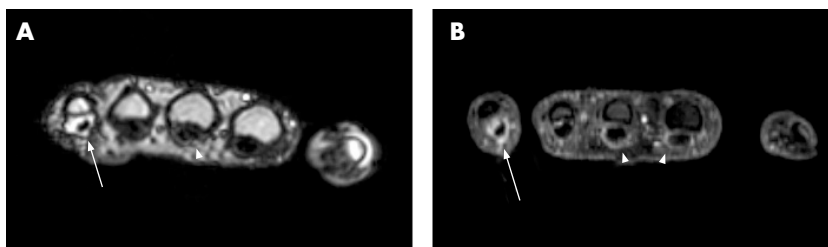
A total of 68 flexor tendons were evaluated. Tenosynovitis was diagnosed by lfMRI in 24 instances and by cMRI in 33 instances (table 4). There was moderate to good agreement of the tenosynovitis scores ( $\kappa = 0.51$ – $0.65$ ) without any significant differences. In general, more tendons were detected positive for tenosynovitis in cMRI (fig 2).

A total of 391 regions (finger joints, bases of metacarpal bones, carpal bones, radius and ulna) were scored for the presence of erosions. There was good to excellent agreement for the finger joints ( $\kappa = 0.65$ – $0.95$ ) and there were no significant differences (table 5, fig 3). Altogether, erosions affected the MCP joints more frequently than the PIP joints. Agreement in the detection of erosions was slightly poorer for the PIP joints.  $\kappa$  values for the wrist joints showed wide variation from good agreement (lowest  $\kappa$  of 0.65) to full agreement of both magnetic resonance systems ( $\kappa = 1.0$ ; table 6). McNemar's test did not identify any bone of the wrist, with significantly higher erosion scores.

Inter-reader agreement was excellent both for lfMRI and for cMRI for scoring synovitis and erosions, and good for scoring tenosynovitis (table 7).

### DISCUSSION

The aim of our study was to compare the diagnosis and scoring of pathologies between cMRI and lfMRI in a group of patients with rheumatoid arthritis using semiquantitative scoring systems. To date, not many studies compared lfMRI with cMRI for the diagnosis and monitoring of treatment.



**Figure 2** Comparison of tenosynovitis of the flexor tendons in a 26-year-old patient with rheumatoid arthritis since 7 years. Transverse reconstructions of the 0.2 T three-dimensional gradient-echo sequence after contrast injection (A) and the 1.5 T fat-suppressed three-dimensional gradient-echo sequence after contrast injection (B) both show severe flexor tenosynovitis at the fifth finger (arrow) and mild tenosynovitis at the third finger (arrowhead). Tenosynovitis at the second finger (second arrowhead in B) is only seen in the 1.5 T examination.



**Table 5** Detection and scoring of erosions at metacarpophalangeal and proximal interphalangeal joints (n = 136)

Joint	Erosions		$\kappa$ †	CI†	p value† (McNemar)
	Low-field MRI (n)*	Conventional MRI (n)*			
2nd MCP	11	12	0.96	0.90 to 1.01	1.000
3rd MCP	10	8	0.89	0.78 to 1.00	0.125
4th MCP	6	6	0.92	0.80 to 1.00	1.000
5th MCP	9	8	0.77	0.59 to 0.95	0.812
2nd PIP	2	1	0.65	0.35 to 0.96	0.500
3rd PIP	3	2	0.73	0.50 to 0.97	0.500
4th PIP	1	1	0.79	0.78 to 0.80	1.000
5th PIP	1	1	0.79	0.78 to 0.80	1.000
Total	43	39			

MCP, metacarpophalangeal joint; PIP, proximal interphalangeal joint.

\*Number of affected joints.

†Based on scoring results of individual joints.

Savnik *et al*<sup>17</sup> were the first to compare the detection of synovitis by lfmMRI and cMRI, showing good agreement between both modalities. They used both a dichotomic evaluation system and volume analysis of the inflammatory synovial membrane. Similar results were reported in a study with 18 patients, although limited by the fact that MRI was performed without contrast medium administration.<sup>18</sup> Recently, Ejbjerg *et al*<sup>19</sup> reported a high sensitivity of contrast-enhanced lfmMRI in diagnosing synovitis in 37 patients with rheumatoid arthritis, using cMRI as the gold standard. This approach is to be questioned. Despite increasing data on the role of MRI in patients with arthritis,<sup>6</sup> there is still no consensus statement regarding the recognition of MRI as the sole gold standard. As a superior diagnostic accuracy of lfmMRI cannot be shown in comparison to another method, if that is regarded the gold standard (as sensitivity cannot be calculated >100%), we did not apply this approach in our study. We therefore calculated  $\kappa$  values that confirm a good agreement between both MRI techniques in evaluating synovitis. In most joints, equal scores were determined, whereas only few joints show significantly higher synovitis scores for lfmMRI. More joints detected with synovitis for lfmMRI were also found by Savnik *et al*,<sup>17</sup> whereas Ejbjerg *et al*<sup>19</sup> reported slightly more joints with synovitis for cMRI. Comparison of the two units for synovitis scoring was performed only by Taouli *et al*.<sup>18</sup> They also used a scoring scale of 0–3 and found no significant differences between both units. However, Taouli *et al* did not use contrast material in their study and hence the evaluation of synovitis lacks the ability to differentiate between inflamed synovium and fluid.

MRI visualises soft-tissue lesions in rheumatoid arthritis such as tenosynovitis,<sup>29</sup> but only few studies have investigated the evaluation of tenosynovitis by MRI<sup>30–32</sup> and there is no study that compares cMRI with lfmMRI in that respect in rheumatoid arthritis.

Conventional MRI identified more instances of tenosynovitis than lfmMRI, however, without statistical significance. We found moderate to good agreement in the scoring of tenosynovitis between both imaging devices. Reference images from the OMERACT group are available only for synovitis, bone marrow oedema and erosions.<sup>24–25</sup> An accepted scoring system for evaluating inflammatory tendon processes of the finger and wrist joints in rheumatoid arthritis similar to the RAMRIS does not yet exist. We therefore evaluated tenosynovitis using a modified version of the RAMRIS for synovitis. The relatively lower agreement rate between the two units found for tenosynovitis could result from the lack of a standardised

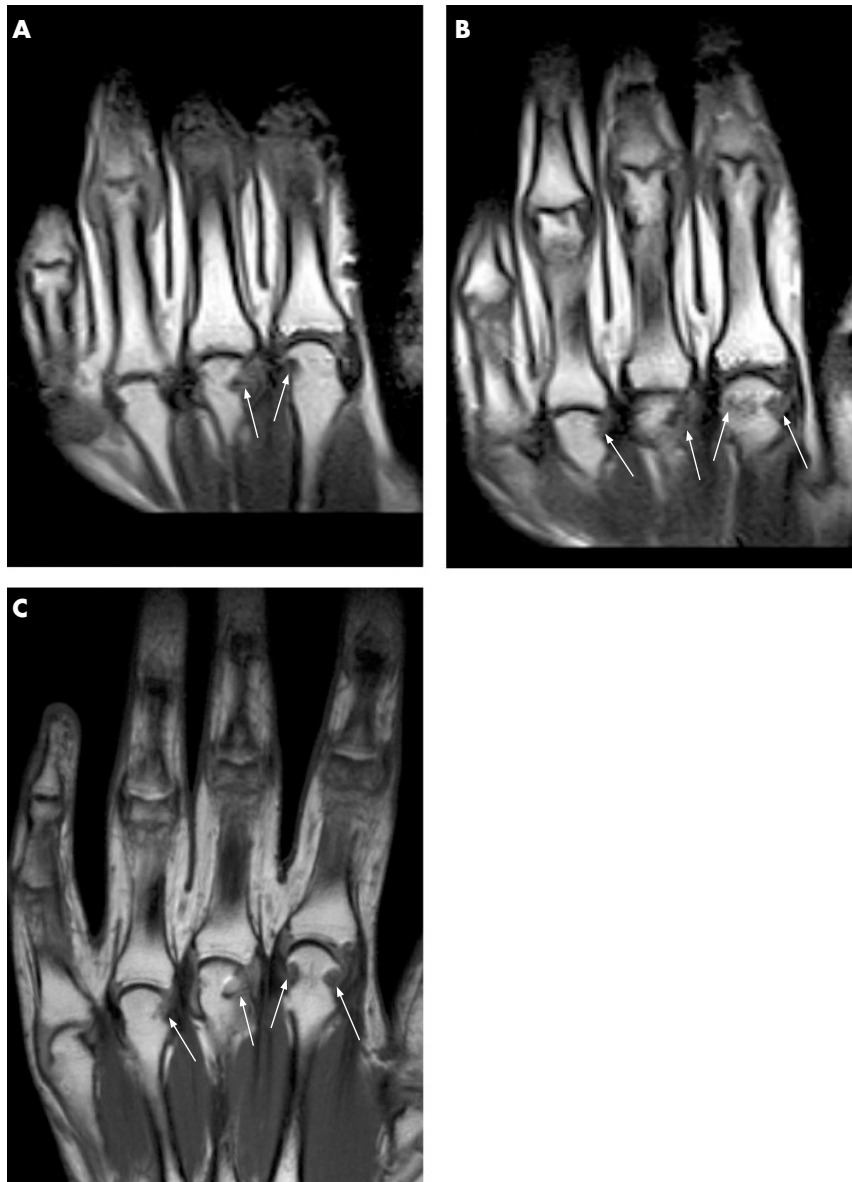
scoring system and of a reference atlas. Also, further studies are necessary to investigate the clinical role of inflammatory tendon processes and their possible effect on therapeutic decision making in the course of rheumatoid arthritis, as recently outlined in the research agenda of the OMERACT MRI in rheumatoid arthritis working group.<sup>33</sup>

Early identification of erosions by means of sensitive imaging modalities has a decisive effect on therapeutic decisions and further disease course.<sup>12–34</sup> We found excellent agreement between both MRI techniques in detecting erosions. Both the scoring results of individual joints and the total number of affected joints showed that more erosions were detected by lfmMRI than with cMRI (154 vs 139 eroded joints). Savnik *et al*<sup>17</sup> also reported a good overall agreement between both types of scanners. They also identified more erosions with lfmMRI (n = 496) than with cMRI (n = 379). Dichotomic evaluation of erosions in the study by Ejbjerg *et al*<sup>19</sup> showed a sensitivity of 94% for lfmMRI, which identified a total of 370 joints with erosions. cMRI served as the reference method and detected a total of 318 eroded joints. Like in our study, Taouli *et al*<sup>18</sup> did not find a statistically significant difference between the scores assigned with both MRI techniques (mean score of 28.8 vs 27.5). However, they do not present data on individual bones and joints.

Why do lfmMRI scanners detect more erosions than conventional scanners throughout all studies? Patients with rheumatoid arthritis may have problems when positioned in a whole-body scanner owing to pain in the shoulder and neck area, and may therefore benefit from comfortable positioning outside the magnet. As a result, fewer motion artefacts occur, which is a possible reason for the higher detection rates of erosions and synovitis shown for lfmMRI.

The OMERACT RAMRIS for erosions<sup>26</sup> was not used in our study, for two reasons: this score is defined for MCP joints only, making a distinction between the metacarpal bone and the base of the proximal phalanx. Each of these two joint segments in the RAMRIS is evaluated separately on a scale of 0–10 (with 1 point corresponding to an erosion of 10% of the total bone volume). This scale allows a very detailed description of even minute changes in erosion size. However, modification of this scoring system for evaluation of the PIP joints in our study was considered unsuitable because of the small size of the PIP joints. Therefore, a modified Larsen score was used in the current study. Although this scoring system is systematic, it differs from the RAMRIS Scoring System for erosions and is not standardised. Evaluation of inter-reader agreement showed excellent  $\kappa$  and intraclass correlation coefficient values,





**Figure 3** Comparison of erosions at metacarpophalangeal (MCP) joints 2–4 (same patient as in fig 2). Spin-echo sequence (two adjacent slices) (A, B) acquired by low-field MRI and fast spin-echo sequence (C) of the MCP joints acquired by conventional MRI show the same marginal erosions at the metacarpal heads (arrows).

underlining the ease of use of our newly developed scoring system. Further studies for the evaluation of the differences between the two imaging systems investigated here using the OMERACT Scoring System for erosions are advisable.

An obvious limitation of our study is the small number of patients. Minimal slice thickness was different in both devices. However, this does not seem to influence the results as the device with thicker slices (lfMRI) overall detected more erosions. Another drawback is the coil selection. Although lfMRI was performed with a dedicated double-phased hand coil, a comparable coil (eg, four-channel hand coil) was not available for cMRI, and a standard flexible surface coil was used. On the other hand, our results reflect the true clinical situation, where only the standard equipment is available in many instances.

Bone marrow oedema, which has a high predictive value for the development of bone erosions,<sup>9</sup> was not evaluated in our study owing to the rather low image quality of the 0.2 T imaging device in this regard. Different studies investigating this pathology on lfMRI showed only a low sensitivity in the detection of bone marrow oedema.<sup>19</sup>

Our study does not include a dedicated, age-matched control group of healthy subjects. Such a group has been investigated by Ejbjerg *et al.*<sup>35</sup> Here, only in a few individuals, mild changes consistent with synovitis were detected. It is important to exclude any possibility to score normal joints as mild synovitis. Although no control group exists, our data of inter-reader agreement suggest a high level of confidence separating low-grade inflammatory changes from normal joints and hence adds to the validity of our study results.

**Table 6** Detection and scoring of erosions at wrist bones (n = 255)

Bone	Erosions		$\kappa$ †	CI†	p Value† (McNemar)
	Low-field MRI (n)*	Conventional MRI (n)*			
Radius	4	4	1.00	1.00 to 1.00	NA
Ulna	10	7	0.88	0.74 to 1.00	0.250
Pisiform	2	3	0.73	0.49 to 0.97	1.000
Triquetrum	11	10	0.92	0.82 to 1.00	1.000
Lunate	11	9	0.85	0.71 to 0.99	0.375
Scaphoid	8	8	0.84	0.68 to 1.00	0.562
Hamate	12	11	0.78	0.68 to 0.89	0.062
Capitate	11	10	0.94	0.88 to 1.00	0.500
Trapezoid	5	3	0.68	0.49 to 0.87	0.125
Trapezium	8	8	0.65	0.51 to 0.79	0.531
1st MC base	5	5	0.95	0.87 to 1.00	1.000
2nd MC base	8	7	0.83	0.65 to 1.00	0.625
3rd MC base	7	7	0.97	0.93 to 1.00	1.000
4th MC base	5	4	0.87	0.62 to 1.00	1.000
5th MC base	4	4	1.00	1.00 to 1.00	NA
Total	111	100			

MC, metacarpal; NA, not applicable (no discordant pairs).

\*Number of affected bones.

†Based on scoring results of individual bones.

**Table 7** Inter-reader agreement

	ICC	CI	Weighted $\kappa$	SE
Low-field MRI				
Erosions	0.84	0.80 to 0.87	0.78	0.05
Synovitis	0.86	0.79 to 0.90	0.78	0.07
Tenosynovitis	0.76	0.60 to 0.86	0.65	0.12
Conventional MRI				
Erosions	0.81	0.76 to 0.85	0.78	0.05
Synovitis	0.88	0.81 to 0.92	0.77	0.08
Tenosynovitis	0.74	0.56 to 0.86	0.74	0.12

ICC, intraclass correlation coefficient.

In summary, the results presented here confirm the clinical usefulness of dedicated low-field magnetic resonance scanners for evaluating patients with rheumatoid arthritis. High agreement rates were found between lMRI and cMRI not only in the detection of erosions and synovitis, as already shown by other studies, but also when scoring those lesions. The performance of the two devices in the detection and grading of tenosynovitis was investigated for the first time. Dedicated magnetic resonance scanners have a role wherever a universal whole-body magnetic resonance scanner cannot be purchased for reasons of cost or for sparsely populated areas, but still a timely and sensitive diagnosis of rheumatoid arthritis and other inflammatory joint diseases is sought.

#### ACKNOWLEDGEMENTS

The use of the MRI device was possible owing to a research contract between Charité medical school and Esaote Biomedica SA, Genoa, Italy.

#### Authors' affiliations

Claudia Schirmer, Christian E Althoff, Iris Eshed, Alexander Lembcke, Bernd Hamm, Kay-Geert A Hermann, Department of Radiology, Charité Medical School, Berlin, Germany

Alexander K Scheel, Department of Medicine, Division for Nephrology and Rheumatology, Georg-August University, Göttingen, Germany  
Tania Schink, Department of Medical Biometry, Charité Medical School, Berlin, Germany

Gerd-Rüdiger Burmester, Marina Backhaus, Department of Rheumatology and Clinical Immunology, Charité Medical School, Berlin, Germany

Competing interests: None.

#### REFERENCES

- Lee DM, Weinblatt ME. Rheumatoid arthritis. *Lancet* 2001;**358**:903–11.
- McGonagle D, Conaghan PG, Wakefield R, Emery P. Imaging the joints in early rheumatoid arthritis. *Baillieres Best Pract Res Clin Rheumatol* 2001;**15**:91–104.
- Kainberger F, Peloschek P, Langs G, Boegl K, Bischof H. Differential diagnosis of rheumatic diseases using conventional radiography. *Best Pract Res Clin Rheumatol* 2004;**18**:783–811.
- van der Heijde D. Quantification of radiological damage in inflammatory arthritis: rheumatoid arthritis, psoriatic arthritis and ankylosing spondylitis. *Best Pract Res Clin Rheumatol* 2004;**18**:847–60.
- Taylor PC. The value of sensitive imaging modalities in rheumatoid arthritis. *Arthritis Res Ther* 2003;**5**:210–13.
- Ostergaard M, Szkudlarek M. Imaging in rheumatoid arthritis—why MRI and ultrasonography can no longer be ignored. *Scand J Rheumatol* 2003;**32**:63–73.
- Ostergaard M, Ejlertsen B. Magnetic resonance imaging of the synovium in rheumatoid arthritis. *Semin Musculoskelet Radiol* 2004;**8**:287–99.
- Backhaus M, Kamradt T, Sandrock D, Loreck D, Fritz J, Wolf KJ, et al. Arthritis of the finger joints: a comprehensive approach comparing conventional radiography, scintigraphy, ultrasound, and contrast-enhanced magnetic resonance imaging. *Arthritis Rheum* 1999;**42**:1232–45.
- McQueen FM, Benton N, Perry D, Crabbe J, Robinson E, Yeoman S, et al. Bone edema scored on magnetic resonance imaging scans of the dominant carpus at presentation predicts radiographic joint damage of the hands and feet six years later in patients with rheumatoid arthritis. *Arthritis Rheum* 2003;**48**:1814–27.
- Guermazi A, Taouli B, Lynch JA, Peterfy CG. Imaging of bone erosion in rheumatoid arthritis. *Semin Musculoskelet Radiol* 2004;**8**:269–85.
- McQueen FM, Stewart N, Crabbe J, Robinson E, Yeoman S, Tan PL, et al. Magnetic resonance imaging of the wrist in early rheumatoid arthritis reveals a high prevalence of erosions at four months after symptom onset. *Ann Rheum Dis* 1998;**57**:350–6.
- Ostergaard M, Hansen M, Stoltenberg M, Jensen KE, Szkudlarek M, Pedersen-Zbinden B, et al. New radiographic bone erosions in the wrists of patients with rheumatoid arthritis are detectable with magnetic resonance imaging a median of two years earlier. *Arthritis Rheum* 2003;**48**:2128–31.
- Benton N, Stewart N, Crabbe J, Robinson E, Yeoman S, McQueen FM. MRI of the wrist in early rheumatoid arthritis can be used to predict functional outcome at 6 years. *Ann Rheum Dis* 2004;**63**:555–61.

- 14 **Peterfy CG**, van Dijke CF, Lu Y, Nguyen A, Connick TJ, Kneeland JB, *et al.* Quantification of the volume of articular cartilage in the metacarpophalangeal joints of the hand: accuracy and precision of three-dimensional MR imaging. *Am J Roentgenol* 1995;**165**:371–5.
- 15 **Gandy SJ**, Brett AD, Dieppe PA, Keen MC, Maciewicz RA, Taylor CJ, *et al.* Measurement of cartilage volumes in rheumatoid arthritis using MRI. *Br J Radiol* 2005;**78**:39–45.
- 16 **Savnik A**, Malmkov H, Thomsen HS, Graff LB, Nielsen H, Danneskiold-Samsøe B, *et al.* Magnetic resonance imaging of the wrist and finger joints in patients with inflammatory joint diseases. *J Rheumatol* 2001;**28**:2193–200.
- 17 **Savnik A**, Malmkov H, Thomsen HS, Bretlau T, Graff LB, Nielsen H, *et al.* MRI of the arthritic small joints: comparison of extremity MRI (0.2 T) vs high-field MRI (1.5 T). *Eur Radiol* 2001;**11**:1030–8.
- 18 **Taouli B**, Zaim S, Peterfy CG, Lynch JA, Stork A, Guermazi A, *et al.* Rheumatoid arthritis of the hand and wrist: comparison of three imaging techniques. *Am J Roentgenol* 2004;**182**:937–43.
- 19 **Ejbjerg BJ**, Narvestad E, Jacobsen S, Thomsen HS, Ostergaard M. Optimised, low cost, low field dedicated extremity MRI is highly specific and sensitive for synovitis and bone erosions in rheumatoid arthritis wrist and finger joints: comparison with conventional high field MRI and radiography. *Ann Rheum Dis* 2005;**64**:1280–7.
- 20 **Ostergaard M**, Ejbjerg B, Szkudlarek M. Imaging in early rheumatoid arthritis: roles of magnetic resonance imaging, ultrasonography, conventional radiography and computed tomography. *Best Pract Res Clin Rheumatol* 2005;**19**:91–116.
- 21 **Arnett FC**, Edworthy SM, Bloch DA, McShane DJ, Fries JF, Cooper NS, *et al.* The American Rheumatism Association 1987 revised criteria for the classification of rheumatoid arthritis. *Arthritis Rheum* 1988;**31**:315–24.
- 22 **Prevo ML**, van't Hof MA, Kuper HH, van Leeuwen MA, van de Putte LB, van Riel PL. Modified disease activity scores that include twenty-eight-joint counts. Development and validation in a prospective longitudinal study of patients with rheumatoid arthritis. *Arthritis Rheum* 1995;**38**:44–8.
- 23 **Eshed I**, Althoff CE, Schink T, Scheel AK, Schirmer C, Backhaus M, *et al.* Low-field MRI for assessing synovitis in patients with rheumatoid arthritis. Impact of Gd-DTPA dose on synovitis scoring. *Scand J Rheumatol* 2006;**35**:277–82.
- 24 **Ejbjerg B**, McQueen F, Lassere M, Haavardsholm E, Conaghan P, O'Connor P, *et al.* The EULAR-OMERACT rheumatoid arthritis MRI reference image atlas: the wrist joint. *Ann Rheum Dis* 2005;**64**(Suppl 1):i23–47.
- 25 **Conaghan P**, Bird P, Ejbjerg B, O'Connor P, Peterfy C, McQueen F, *et al.* The EULAR-OMERACT rheumatoid arthritis MRI reference image atlas: the metacarpophalangeal joints. *Ann Rheum Dis* 2005;**64**(Suppl 1):i11–21.
- 26 **Ostergaard M**, Peterfy C, Conaghan P, McQueen F, Bird P, Ejbjerg B, *et al.* OMERACT rheumatoid arthritis magnetic resonance imaging studies. Core set of MRI acquisitions, joint pathology definitions, and the OMERACT RA-MRI scoring system. *J Rheumatol* 2003;**30**:1385–6.
- 27 **Larsen A**, Dale K, Eek M. Radiographic evaluation of rheumatoid arthritis and related conditions by standard reference films. *Acta Radiol Diagn (Stockh)*, 1977;**18**:481–91.
- 28 **Cicchetti DV**, Feinstein AR. High agreement but low kappa: II. Resolving the paradoxes. *J Clin Epidemiol* 1990;**43**:551–8.
- 29 **Ostergaard M**, Szkudlarek M. Magnetic resonance imaging of soft tissue changes in rheumatoid arthritis wrist joints. *Semin Musculoskelet Radiol* 2001;**5**:257–74.
- 30 **Klarlund M**, Ostergaard M, Jensen KE, Madsen JL, Skjodt H, Lorenzen I. Magnetic resonance imaging, radiography, and scintigraphy of the finger joints: one year follow up of patients with early arthritis. The TIRA Group. *Ann Rheum Dis* 2000;**59**:521–8.
- 31 **Swen WA**, Jacobs JW, Hubach PC, Klasens JH, Algra PR, Bijlsma JW. Comparison of sonography and magnetic resonance imaging for the diagnosis of partial tears of finger extensor tendons in rheumatoid arthritis. *Rheumatology (Oxford)* 2000;**39**:55–62.
- 32 **Backhaus M**, Burmester GR, Sandrock D, Loreck D, Hess D, Scholz A, *et al.* Prospective two year follow up study comparing novel and conventional imaging procedures in patients with arthritic finger joints. *Ann Rheum Dis* 2002;**61**:895–904.
- 33 **Ostergaard M**, McQueen FM, Bird P, Ejbjerg B, Lassere MN, Peterfy CG, *et al.* Magnetic resonance imaging in rheumatoid arthritis advances and research priorities. *J Rheumatol* 2005;**32**:2462–4.
- 34 **Peterfy CG**. Magnetic resonance imaging in rheumatoid arthritis: current status and future directions. *J Rheumatol* 2001;**28**:1134–42.
- 35 **Ejbjerg B**, Narvestad E, Rostrop E, Szkudlarek M, Jacobsen S, Thomsen HS, *et al.* Magnetic resonance imaging of wrist and finger joints in healthy subjects occasionally shows changes resembling erosions and synovitis as seen in rheumatoid arthritis. *Arthritis Rheum* 2004;**50**:1097–106.

#### BNF for Children 2006, second annual edition

In a single resource:

- guidance on drug management of common childhood conditions
- hands-on information on prescribing, monitoring and administering medicines to children
- comprehensive guidance covering neonates to adolescents

For more information please go to [bnfc.org](http://bnfc.org)

### 3.2.2. MRT des Rückfußes

#### Publikation 3

Eshed I, Althoff CE, Feist E, Minden K, Schink T, Hamm B, **Hermann KG.**

Magnetic resonance imaging of hindfoot involvement in patients with spondyloarthritides: Comparison of low-field and high-field strength units.

Eur J Radiol. 2008; 65(1):140-7.

ISSN: 0720-048X, DOI 10.1016/j.ejrad.2007.03.009

Die diagnostische Wertigkeit der Niederfeld-MRT im Vergleich zur konventionellen MRT wurde durch Gruppenvergleich von 27 Patienten mit Spondyloarthritiden durchgeführt. Es zeigten sich vergleichbare Häufigkeiten von Erosionen, Gelenkergüssen, Synovitiden, Knochenmarködemen, Tenosynovitiden oder Tendinosen ohne statistisch signifikante Unterschiede.

Häufigste Befunde waren dabei die retrokalkaneale Bursitis, welche in 86 % mit der Niederfeld-MRT und in 70 % mit der konventionellen MRT detektiert wurde, die plantare Fasziitis, die in 66 % bzw. 70 % der Fälle auftrat, und die Tenosynovitis der Tibialis-Posterior-Sehne, die sich in 53 % bzw. 40 % der Patienten darstellen ließ.



## Magnetic resonance imaging of hindfoot involvement in patients with spondyloarthritis: Comparison of low-field and high-field strength units

Iris Eshed<sup>a</sup>, Christian E. Althoff<sup>a</sup>, Eugen Feist<sup>b</sup>, Kirsten Minden<sup>c,d</sup>,  
Tania Schink<sup>e</sup>, Bernd Hamm<sup>a</sup>, Kay-Geert A. Hermann<sup>a,\*</sup>

<sup>a</sup> Department of Radiology, Charité Medical School, Berlin, Germany

<sup>b</sup> Department of Rheumatology and Clinical Immunology, Charité Medical School, Berlin, Germany

<sup>c</sup> Helios Clinics, 2nd Children's Hospital Berlin-Buch, Rheumatology Unit, Berlin, Germany

<sup>d</sup> German Rheumatology Research Center, Berlin, Germany

<sup>e</sup> Department of Medical Biometry, Charité Medical School, Berlin, Germany

Received 10 September 2006; received in revised form 1 March 2007; accepted 9 March 2007

### Abstract

**Objective:** To compare MRI evaluation of a painful hindfoot of patients with spondyloarthritis (SpA) on low-field (0.2 T) versus high-field (1.5 T) MRI.

**Materials and methods:** Patients with SpA and hindfoot pain were randomly referred to either high-field or low-field MRI. Twenty-seven patients were evaluated (male/female: 17/10; mean age:  $39 \pm 1.4$  years). Fifteen patients were examined by low-field and 12 by high-field MRI. Two patients (evaluated by high-field MRI) were excluded. Images were separately read by two radiologists who later reached a consensus. In each patient the prevalence of erosions, fluid, synovitis or bone marrow edema of the hindfoot joints, tendinosis or tenosynovitis of tendons, enthesitis of the plantar fascia and Achilles tendon and retrocalcaneal bursitis were recorded. Clinical and demographic parameters were comparable between both groups.

**Results:** MRI evaluation of joints and tendons of the hindfoot revealed no significant differences in patients with SpA groups for all parameters. Analyzing all joints or tendons together, there was no statistically significant difference between the two groups.

**Conclusion:** Low-field and high-field MRI provide comparable information for evaluation of inflammatory hindfoot involvement. Thus, low-field MRI can be considered as a reliable diagnostic tool for the detection of hindfoot abnormalities in SpA patients.

© 2007 Elsevier Ireland Ltd. All rights reserved.

**Keywords:** Magnetic resonance imaging; Ankle; Spondyloarthritis; Spondyloarthropathy; Low-field MRI; Arthritis

### 1. Introduction

The spondyloarthritis (SpA) are a group of related conditions that includes ankylosing spondylitis (AS), psoriatic arthritis (PsA), reactive arthritis (Reiter's disease), undifferentiated spondyloarthritis (uSpA) and inflammatory bowel-disease-associated arthritis. This group is characterized by the absence of rheumatoid factor and the presence of synovitis and enthesopathy which lead to axial and peripheral inflammatory joint disease [1].

The hindfoot is one of the more commonly affected sites in SpA and may cause considerable morbidity. However, the numerous structures of the feet and ankle make both clinical evaluation of the ankle and diagnosis difficult [2–4]. Magnetic resonance imaging (MRI) is particularly advantageous for assessing the ankle and its soft tissue structures such as tendons, ligaments and fascia [5–7].

In recent years, MRI has been shown to be a sensitive tool for early changes of the arthritic disease [8–11] and few descriptive studies have shown its advantages in imaging hindfoot involvement in inflammatory joint diseases [12,13].

There has been a trend towards the use of low-field equipment in recent years. Compared to a high-field MRI, dedicated low-field MRI offers greater patient comfort, eliminates the problem of claustrophobia and is less expensive, although issues as

\* Corresponding author at: Department of Radiology, Charité University Hospital, Campus Mitte, Schumannstr. 20/21, 10117 Berlin, Germany.  
Tel.: +49 30 450 527082; fax: +49 30 450 527905.

E-mail address: kgh@charite.de (K.-G.A. Hermann).

Table 1  
Parameters of the 0.2 T MRI sequences used

	TR (ms)	TE (ms)/ TI (ms)	Flip angle (°)	In-plane resolution (mm <sup>2</sup> )	Slice thickness/ gap (mm)	FOV (mm)	Matrix size	Time (min:s)
GE-STIR (sag; native)	700	16/75	90	1.13 × 0.54	3/0.3	180	256 × 192	5:19
T1 SE (sag; native and post CM)	520	26/	90	0.56 × 0.56	3.5/0.3	180	320 × 512	5:35
T1 GRE (sag; native and post CM)	35	16/	65	0.83 × 0.83	0.86/0	160	192 × 256	8:00

Sag, sagittal; GE-STIR, gradient recalled echo short tau inversion recovery sequence; T1 SE, T1-weighted spin echo sequence; CM, contrast material; T1 GRE, T1-weighted gradient recalled echo sequence; TR, repetition time; TE, echo time; TI, inversion time; FOV, field of view.

limited field of view, unavailability of spectral fat suppression, and non-reimbursement in some countries do still exist.

Low-field MRI has been proved to be a sensitive, reliable tool for evaluating the peripheral joints of patients with inflammatory diseases [8,14–16].

The purpose of the current study was to compare high-field and low-field strength MRI in the evaluation of the hindfoot in SpA.

## 2. Materials and methods

### 2.1. Study design and patients

This study was a prospective trial using a standardised protocol. Patients with SpA who met the ESSG criteria [17] and suffered from heel or ankle pain were enrolled consecutively. Randomly, patients were referred to either high-field or low-field MRI for the evaluation of their ankle.

In each patient a thorough physical examination, laboratory tests and MRI of the hindfoot were performed. Informed consent was obtained from all patients and the study protocol was approved by the local ethics committee.

A total of 27 patients underwent MRI of the hindfoot (male/female ratio 17:10) with a mean age of  $37 \pm 2.9$  years. Fifteen patients were evaluated by low-field MRI and 12 by high-field MRI.

### 2.2. MRI protocol

The MRIs used were a closed bore unit with a field strength of 1.5 T (Magnetom Sonata, Siemens Medical Solutions, Erlangen, Germany) and a dedicated extremity unit with a field strength of 0.2 T (C-scan, Esaote, Genoa, Italy). In both units, phased-array extremity coils were used. Examination was performed with the patient in the supine position and the foot in about 20° plantar flexion.

Table 2  
Parameters of the 1.5 T MRI sequences used

	TR (ms)	TE (ms)/ TI (ms)	Flip angle (°)	In-plane resolution (mm <sup>2</sup> )	Slice thickness/ gap (mm)	FOV (mm)	Matrix size	Time (min:s)
STIR (sag; native)	5760	42/150	180	1.3 × 0.9	4/0.4	300	192 × 320	4:32
T1 SE (sag; native)	630	21	90	0.4 × 0.4	4/0.4	200	512 × 512	5:27
T1 SE (sag and ax; fatsat; post CM)	981	21	90	0.4 × 0.4	4/0.8	200	512 × 512	8:27
T1 GRE (sag; fatsat; post CM)	9.02	3.72	8	0.5 × 0.5	1.0/0	200	384 × 384	3:43

STIR, short tau inversion recovery sequence; T1 SE, T1-weighted spin echo sequence; CM, contrast material; T1 GRE, T1-weighted gradient recalled echo sequence; TR, repetition time; TE, echo time; TI, inversion time; FOV, field of view. sag, sagittal; ax, axial; fatsat, fat saturated.

The sequence protocols of the two units are summarized in Tables 1 and 2. Gadolinium diethylenetriaminepentaacetic acid (Gd-DTPA) (Magnevist, Schering AG, Berlin, Germany) was applied by an automatic injector with a rate of 1 ml/s in all MRI examinations (0.1 mmol/kg Gd-DTPA for the high-field unit and 0.2 mmol/kg Gd-DTPA [18] for the low-field unit). Based on the sagittal 3D gradient echo sequences additional axial images were reconstructed. MRI evaluation was based on both the sagittal and the reconstructed axial planes.

### 2.3. MRI evaluation

MR images were separately read by two radiologists. In cases of disagreement a consensus was reached in second reading session. The prevalence of pathologic findings of each hindfoot was recorded. Structures evaluated were:

- joints (ankle joint, including tibio-talar and fibulo-talar compartments, talo-calcaneal, talo-navicular and calcaneo-cuboidal) for erosions, effusion, synovitis and adjacent bone-marrow edema (BME);
- tendons (tibialis anterior, extensor hallucis longus, tibialis posterior, flexor hallucis longus, flexor digitorum longus, peroneus longus, peroneus brevis, and Achilles tendon) for tendinosis and tenosynovitis;
- entheses (Achilles tendon and plantar fascia) for enthesitis;
- bursae (retrocalcaneal bursa) for bursitis;
- soft tissues of the heel for edema.

### 2.4. Definition of pathology

Bone erosions were defined as a focal signal loss or contour irregularities of the cortical bone on T1-weighted sequences. Joint effusion was defined as high signal intensity on STIR sequences and low signal intensity on T1-weighted sequences that does not enhance after contrast injection. Synovitis was



defined as high signal intensity of the synovium on STIR sequence and low signal intensity on the T1-weighted sequences that enhances after contrast injection. BME was defined as areas of increased signal intensity with ill-defined margins in the STIR sequences. Tendinitis or tenosynovitis was characterized as a considerable amount of surrounding fluid which demonstrates high signal intensity on STIR sequences and low signal intensity on T1-weighted sequences and enhances after contrast injection. Tendinosis was defined as increased tendon thickness and/or increased signal intensity in all sequences. Enthesitis (plantar fasciitis or Achilles tendonitis) was defined as an increased thickness of the plantar fascia or Achilles tendon at their insertion sites and/or increased signal intensity on all sequences and/or the existence of adjacent fluid and/or the demonstration of adjacent soft tissue enhancement after contrast injection and/or the demonstration of adjacent BME at their insertion sites. Retrocalcaneal bursitis was defined as bursal fluid collection with high signal intensity on STIR sequence and low signal intensity on T1-weighted sequences that enhances after contrast injection. Soft tissue edema of the heel was defined as increased signal intensity on STIR images and/or the demonstration of soft tissue enhancement after contrast injection.

### 2.5. Statistical analysis

The independent sample *t*-test was used to compare the two groups' demographic and clinical data. Nonparametric factorial analysis for repeated measurements was applied to compare the overall differences, accounting for clustering of joints and tendons.

Fisher's exact test was used to analyze and compare the prevalence of findings in the two groups at the joint and tendon levels. Analyses were performed using SAS version 8 (SAS Institute, Cary, NC) and SPSS version 11.5 (SPSS Inc., Chicago, IL). *p*-Values lower than 0.05 were considered statistically significant.

Table 3

Disease characteristics and clinical data of patients included in analysis

	Low-field MRI	High-field MRI	<i>p</i> value
Male:female	10:5	6:4	0.504
Average age (S.D.)	39 (18.6)	40 (19.5)	0.584
Average disease duration (S.D.)	2.2 years (2.9)	2.4 years (2.5)	0.323
Average serum CRP level (S.D.)	9 mg/l (10)	11 mg/l (8)	0.842
HLA B27 (percent of positive patients)	50%	60%	0.265
Patients' disease distribution	1 AS 3 PsA 3 ReA 5 JSA 3 uSA	1 AS 1 PsA 4 ReA 2 JSA 2 uSA	0.791

CRP, C reactive protein; AS, ankylosing spondylitis; PsA, psoriatic arthritis; ReA, reactive arthritis; JSpA, juvenile spondyloarthritis; uSpA, undifferentiated spondyloarthritis; S.D., standard deviation.

### 3. Results

A total of 25 out of 27 MRI examinations of the hindfoot were evaluated. Two patients from the high-field group were excluded from the study. One refused contrast injection and in the other examination quality was low because of patient movement. No significant differences were found between the two group's demographic data, disease duration, and laboratory parameters (Table 3).

Analyzing all joints together (i.e., all four joints evaluated), no statistical significant difference was found between the low-field to the high-field groups relative to erosions, effusion, synovitis, and BME ( $p = 0.620, 0.849, 0.352, \text{ and } 0.300$ , respectively). There were also no significant difference in the prevalence of tendinosis, tenosynovitis, and enthesitis between groups analyzing all tendons (i.e., all eight tendons evaluated) together ( $p = 0.755, 0.115, \text{ and } 0.706$ , respectively).

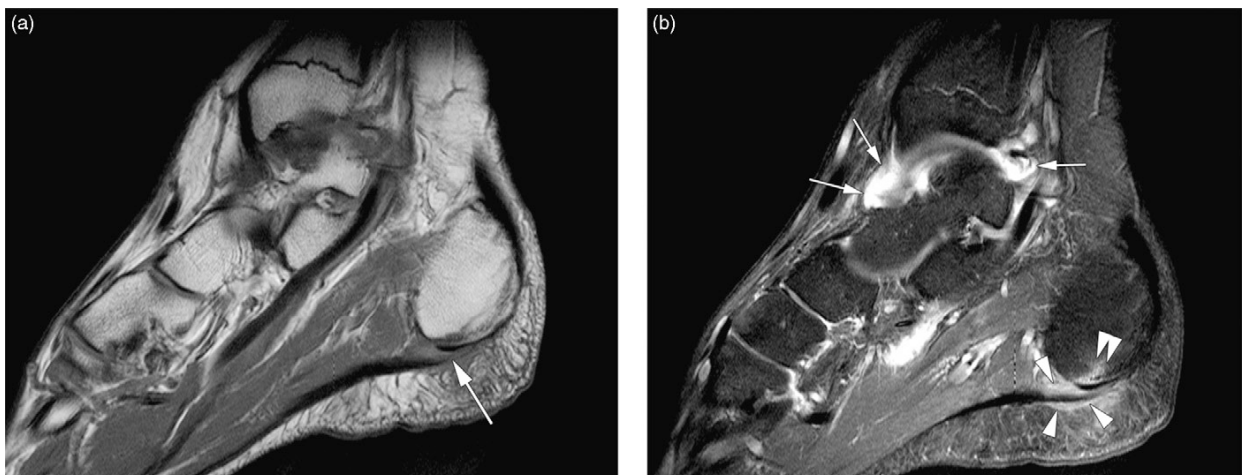


Fig. 1. 1.5T MRI of the ankle in a 15-year-old boy with juvenile SpA. Unenhanced sagittal T1-weighted turbo spin-echo (a) and fat-suppressed T1-weighted turbo spin-echo after contrast injection (b) sequences show plantar fasciitis (arrow) with soft tissue edema (arrow heads) accompanied by calcaneal bone marrow edema (double arrowhead). Synovitis is also seen in the tibio-talar joint (small arrows).

Table 4  
Prevalence of MRI findings

Parameter evaluated	Both MRIs (n = 25)	Low-field MRI (n = 15)	High-field MRI (n = 10)	p value (Fisher's exact test)
<b>Ankle joint</b>				
Erosions	2 (8%)	1 (7%)	1 (10%)	1.000
Effusion	8 (32%)	6 (40%)	2 (20%)	0.402
Synovitis	10 (40%)	4 (27%)	6 (60%)	0.092
Bone marrow edema	0	0	0	N/A
<b>Talo-calcaneal joint</b>				
Erosions	1 (4%)	0	1 (10%)	0.400
Effusion	11 (44%)	8 (53%)	3 (30%)	0.414
Synovitis	9 (36%)	4 (27%)	5 (50%)	0.212
Bone marrow edema	2 (8%)	0	2 (20%)	0.150
<b>Talo-navicular joint</b>				
Erosions	6 (24%)	6 (40%)	0	0.051
Effusion	8 (32%)	3 (20%)	5 (50%)	0.194
Synovitis	7 (28%)	5 (33%)	2 (20%)	0.669
Bone marrow edema	4 (16%)	2 (13%)	2 (20%)	1.000
<b>Calcaneo-cuboidal joint</b>				
Erosions	1 (4%)	0	1 (10%)	0.400
Effusion	4 (16%)	1 (7%)	3 (30%)	0.267
Synovitis	5 (20%)	3 (20%)	2 (20%)	1.000
Bone marrow edema	3 (12%)	1 (7%)	2 (20%)	0.543
<b>Tibialis anterior</b>				
Tenosynovitis	4 (16%)	4 (27%)	0	0.259
Tendinosis	0	0	0	N/A
<b>Extensor hallucis longus</b>				
Tenosynovitis	2 (8%)	2 (13%)	0	0.500
Tendinosis	0	0	0	N/A
<b>Peroneus longus</b>				
Tenosynovitis	8 (32%)	6 (40%)	2 (20%)	0.657
Tendinosis	0	0	0	N/A
<b>Peroneus brevis</b>				
Tenosynovitis	6 (24%)	4 (27%)	2 (20%)	1.000
Tendinosis	0	0	0	N/A
<b>Tibialis posterior</b>				
Tenosynovitis	12 (48%)	8 (53%)	4 (40%)	1.000
Tendinosis	0	0	0	N/A
<b>Flexor hallucis longus</b>				
Tenosynovitis	11 (44%)	9 (60%)	2 (20%)	0.089
Tendinosis	0	0	0	N/A
<b>Flexor digitorum longus</b>				
Tenosynovitis	12 (48%)	9 (60%)	3 (30%)	0.089
Tendinosis	0	0	0	N/A
<b>Achilles tendon</b>				
Tendinitis	12 (48%)	9 (60%)	3 (30%)	0.400
Tendinosis	10 (40%)	6 (40%)	4 (40%)	1.000
Bone marrow edema at insertion site	6 (24%)	4 (27%)	2 (20%)	1.000
<b>Plantar fascia</b>				
Fasciitis	17 (68%)	10 (66%)	7 (70%)	1.000
Bone marrow edema at insertion site	5 (20%)	3 (20%)	2 (20%)	1.000
<b>Retrocalcaneal bursitis</b>	20 (80%)	13 (86%)	7 (70%)	0.358
<b>Heel soft tissue edema</b>	8 (32%)	6 (40%)	2 (20%)	0.388

N/A, not applicable.

Table 4 shows the distribution of findings in the hindfoot on the joint and tendon level and the results of Fisher's exact tests. The most common pathologies found in both groups were retrocalcaneal bursitis and plantar fasciitis (Figs. 1 and 2). Erosions

were found most commonly in the talo-navicular joint, effusion was found most commonly in the talo-calcaneal joint, synovitis was found most commonly in the tibio-talar joint (Figs. 3 and 4) and bone marrow edema was found most commonly in the talus



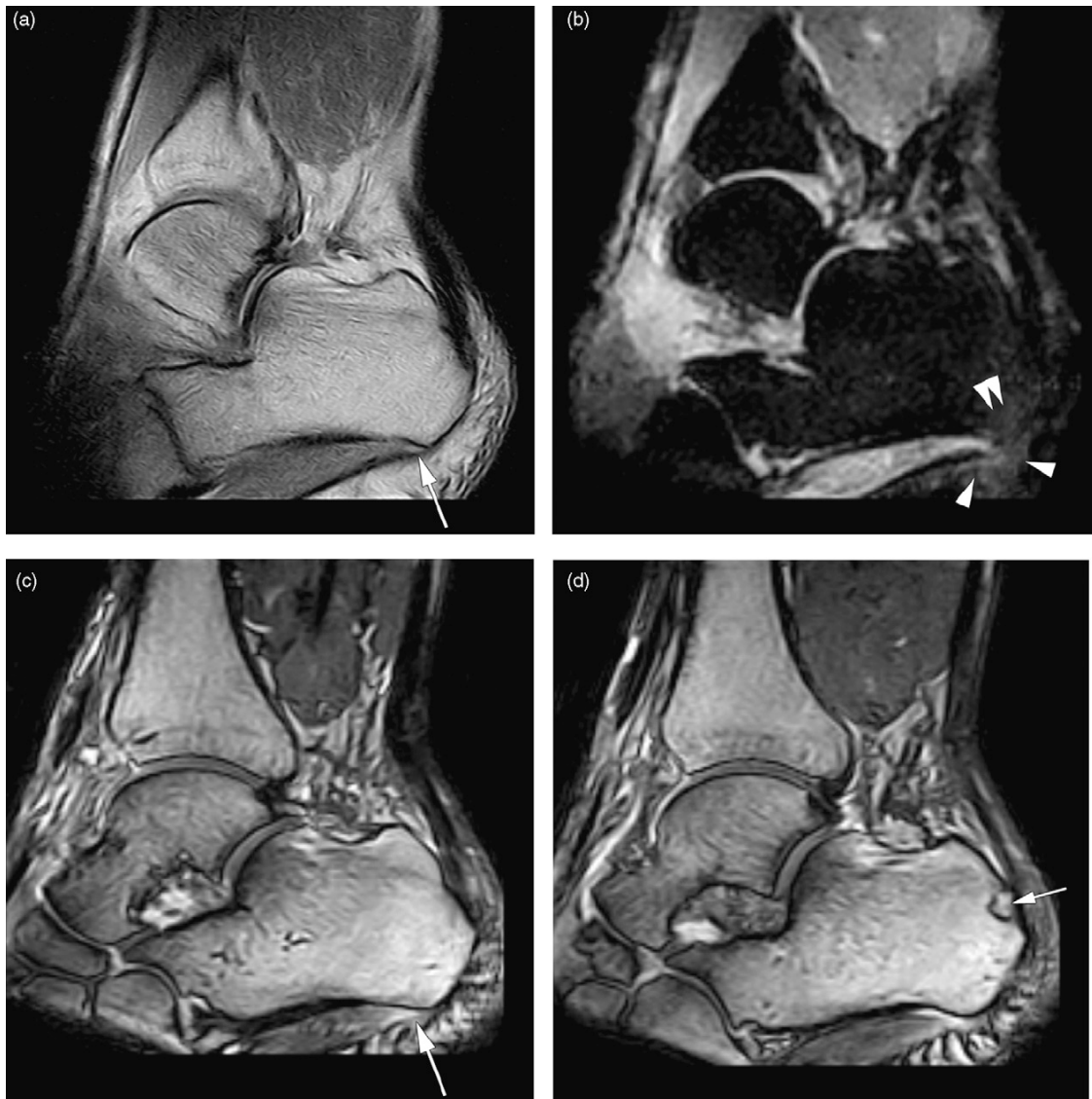

Fig. 2. 0.2T MRI of the ankle in a 55-year-old patient with PsA. Sagittal T1-weighted spin-echo (a) and STIR sequences (b) as well as a T1-weighted 3D GRE sequence after contrast injection (c) show plantar fasciitis (large arrow) and soft tissue edema (arrow heads) associated with minimal calcaneal bone marrow edema (double arrowheads). A T1-weighted 3D GRE sequence after contrast injection (d) at a different slice position shows a calcaneal erosion (small arrow) due to bursitis.

and the navicular bone. Tendinitis or tenosynovitis was found most commonly in the tibialis posterior, the flexor digitorum and the Achilles tendons. Tendinosis was found most commonly in the Achilles tendon, while in the other tendons it was not seen at all. The findings of the two groups were not significantly different in all parameters evaluated (Table 4).

#### 4. Discussion

SpA is a progressive, debilitating group of diseases that affects mostly the axial skeleton and lower extremities. Inflammatory processes are evident as synovitis, tenosynovitis, and enthesitis. Early diagnosis and treatment are important for improved outcome [1].

Low-field MRI has been shown to be a cost effective, reliable alternative modality for evaluation of the peripheral joints of patients with inflammatory rheumatic diseases [8,14–16]. Hottya et al. have evaluated the findings of 169 ankles on low-field MRI among those also of patients with inflammatory arthritis [19] and concluded that low-field MRI is a feasible alternative to high-field MRI. In another study, Munding et al. have compared the image quality of low- and high-field units in the assessment of inflammatory and traumatic diseases of the knee and ankle [20]. They concluded that both units had acceptable diagnostic quality but that the high-field unit was superior in that respect. The better signal-to-noise ratio and larger field of view of high-field MRI units as well as some advantageous sequences over the ones available for low-field strength units can explain

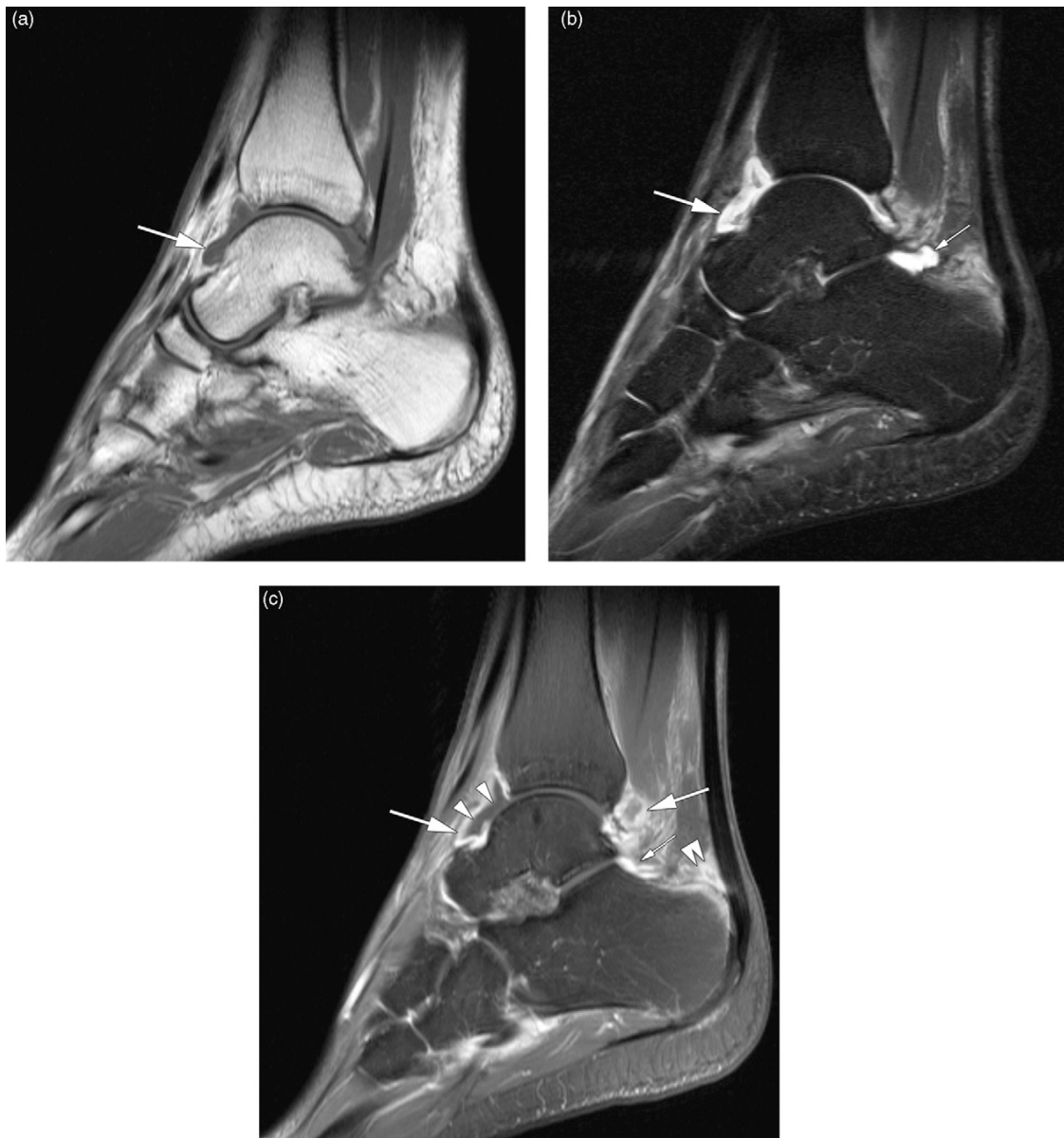


Fig. 3. 1.5T MRI of the ankle in a 33-year-old patient with reactive arthritis. Unenhanced sagittal T1-weighted turbo spin-echo (a), and STIR sequences (b) as well as fat-suppressed T1-weighted turbo spin-echo sequence after contrast injection (c) show tibio-talar synovitis (large arrows) and talo-calcaneal synovitis (small arrow). Contrast injection allows for the differentiation between synovitis and effusion (arrowheads). In addition, retrocalcaneal bursitis (double arrowheads) and discrete calcaneal bone marrow edema are seen.

Mundinger et al.'s conclusion. Even so, this study was performed many years ago and both MRI hardware and software have since then greatly improved. Evaluating the image quality of the two units was not in the scope of our study, however in only one patient (studied with the high-field unit) the readers decided the diagnostic quality was low due to motion artifacts and the patient was excluded from the study group.

Up to date, the diagnostic value of low-field MRI of the hindfoot in patients with SpA was never compared to that of high-field MRI. In the current study no statistical significant difference was found between the low-field to the high-field

groups. This is in concordance with studies directly comparing high-field and low-field MRI units in other body parts such as the finger and wrist joints [11,21–23]. In these studies, the detection of erosions, synovitis, tenosynovitis and joint effusions was similar in both units with no significant statistical differences. Interestingly, two of these studies found low-field MRI slightly better than high-field MRI for the detection of synovitis and erosions [21,22].

Retrocalcaneal bursitis and plantar fasciitis were the two most common findings in our cohort. Erdem et al. evaluated imaging features of ankle involvement in patients with AS on high-field

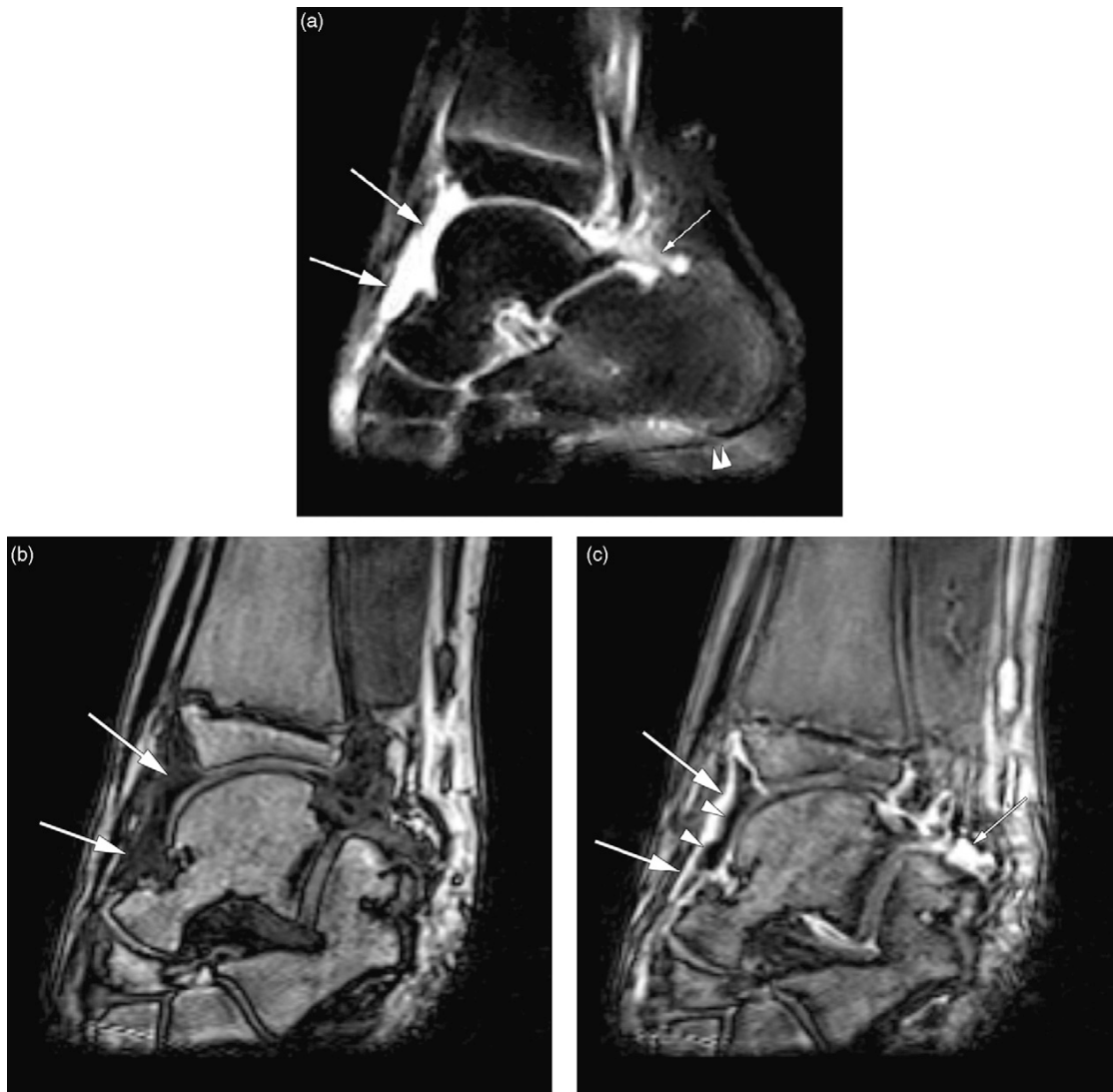

Fig. 4. 0.2 T MRI of the ankle in a 16 year old boy with juvenile SpA. A sagittal STIR sequence (a), unenhanced T1-weighted 3D GRE sequence (b) and 3D GRE sequence after contrast injection (c) show tibiotalar synovitis (large arrows) and talocalcaneal synovitis (small arrow). Contrast injection allows for the differentiation between synovitis and effusion (arrowheads). In addition, plantar fasciitis (double arrowheads), bone marrow and soft tissue edema are seen.

MRI and found plantar fasciitis to be among the most common findings [12]. However, in their study retrocalcaneal bursitis was not as abundant as in our study. This could result from the fact that in Erdem et al.'s study no contrast material was injected and therefore some mild cases with retrocalcaneal bursitis were missed.

Enthesitis of the plantar fascia is the most common cause of heel pain [24]. In accordance to our study, it was shown that in patients with SpA, plantar fasciitis is often associated with Achilles tendinitis and retrocalcaneal bursitis [7,25,26].

Moreover, in our study we found synovitis most commonly in the ankle joint. Such findings were also evident in patients with juvenile SpA [4] and other inflammatory arthritides [2].

BME was not a frequent finding in our group of patients. Among the joints evaluated, it was found most commonly in the

talo-navicular joint. Indeed, in inflammatory arthritis subchondral BME is reported to be located mostly in the talo-navicular and the talo-calcaneal joints [27]. No statistical differences between the two MRI units were found in our study for BME. However, the low sensitivity of low-field MRI for the detection of BME needs to be taken into account [15].

Tenosynovitis was found most commonly in the tibialis posterior and the flexor digitorum longus tendons. These tendons were shown to be characteristically involved in reactive arthritis [13]. Maillfert et al. also showed a high frequency of flexor digitorum longus tenosynovitis in a group of patients with inflammatory polyarthritis [2]. However, in their group, tenosynovitis of the tibialis posterior tendon was not as common as in our group. This could result from the different patient selection since they used wider inclusion criteria for their study.

The Achilles tendon was commonly affected in our study group. This was also shown in the group of AS patients studied by Erdem et al. [12]. Enthesitis is an important feature in SpA patients [28]. In our group of patients it was seen in 24% of the Achilles tendon enthesitis and in 20% of the plantar fascia enthesitis. This is in concordance with the reported prevalence of enthesitis in SpA patients which is 33–58.3% [12,29,30].

An obvious limitation of our study must be considered: We compared two different groups of patients and did not study the same group of patients on both MRI units used. However, by randomizing as described, two comparable groups of SpA patients were formed as demonstrated by similar demographic and clinical data.

One should also acknowledge the fact that our group size is relatively small. Therefore, the fact that the abnormalities found by MRI of the two groups did not differ statistically does not necessarily imply that the diagnostic ability of the two devices is the same. However, our results suggest that differences, if existent, are minimal. As in all studies without an accepted gold standard, the problem of false positive findings exists. The strict definitions of the pathologies were used to minimize false positives.

To summarize, the prevalence of the different pathologies described in the current study of the hindfoot in SpA patients is comparable with that reported in the literature. No statistically significant differences were found between low-field strength and high-field strength MRI units in our study. Even though high-field strength MRI seems to have better image quality, low-field strength MRI offers better patient comfort (e.g., in patients with claustrophobia or polyarticular joint diseases) and is cost efficient and therefore can serve as an alternative diagnostic tool to detect abnormalities of the hindfoot in SpA patients.

## References

- [1] Arnett FC. Seronegative spondylarthropathies. *Bull Rheum Dis* 1987; 37(1):1–12.
- [2] Maillief JF, Dardel P, Cherasse A, Mistrih R, Krause D, Tavernier C. Magnetic resonance imaging in the assessment of synovial inflammation of the hindfoot in patients with rheumatoid arthritis and other polyarthritis. *Eur J Radiol* 2003;47(1):1–5.
- [3] Button G, Pinney S. A meta-analysis of outcome rating scales in foot and ankle surgery: is there a valid, reliable, and responsive system? *Foot Ankle Int* 2004;25(8):521–5.
- [4] Remedios D, Martin K, Kaplan G, Mitchell R, Woo P, Rooney M. Juvenile chronic arthritis: diagnosis and management of tibio-talar and sub-talar disease. *Br J Rheumatol* 1997;36(11):1214–7.
- [5] Rosenberg ZS, Beltran J, Bencardino JT, From the RSNA Refresher Courses. Radiological Society of North America. MR imaging of the ankle and foot. *Radiographics* 2000;20. Spec No.: S153–79.
- [6] Tuite MJ. MR imaging of the tendons of the foot and ankle. *Semin Musculoskelet Radiol* 2002;6(2):119–31.
- [7] Narvaez JA, Narvaez J, Ortega R, Aguilera C, Sanchez A, Andia E. Painful heel: MR imaging findings. *Radiographics* 2000;20(2):333–52.
- [8] Bonel HM, Schneider P, Seemann MD, et al. MR imaging of the wrist in rheumatoid arthritis using gadobenate dimeglumine. *Skelet Radiol* 2001;30(1):15–24.
- [9] Ostergaard M, Duer A, Moller U, Ejlberg B. Magnetic resonance imaging of peripheral joints in rheumatic diseases. *Best Pract Res Clin Rheumatol* 2004;18(6):861–79.
- [10] Ostergaard M, Ejlberg B, Szkudlarek M. Imaging in early rheumatoid arthritis: roles of magnetic resonance imaging, ultrasonography, conventional radiography and computed tomography. *Best Pract Res Clin Rheumatol* 2005;19(1):91–116.
- [11] Savnik A, Malmskov H, Thomsen HS, et al. MRI of the arthritic small joints: comparison of extremity MRI (0.2 T) vs high-field MRI (1.5 T). *Eur Radiol* 2001;11(6):1030–8.
- [12] Erdem CZ, Sarikaya S, Erdem LO, Ozdolap S, Gundogdu S. MR imaging features of foot involvement in ankylosing spondylitis. *Eur J Radiol* 2005;53(1):110–9.
- [13] Weishaupt D, Schweitzer ME, Alam F, Karasick D, Wapner K. MR imaging of inflammatory joint diseases of the foot and ankle. *Skelet Radiol* 1999;28(12):663–9.
- [14] Cimmino MA, Innocenti S, Livrone F, Magnaguagno F, Silvestri E, Garlaschi G. Dynamic gadolinium-enhanced magnetic resonance imaging of the wrist in patients with rheumatoid arthritis can discriminate active from inactive disease. *Arthritis Rheum* 2003;48(5):1207–13.
- [15] Ejlberg B, Narvestad E, Jacobsen S, Thomsen HS, Ostergaard M. Optimised, low cost, low field dedicated extremity MRI is highly specific and sensitive for synovitis and bone erosions in rheumatoid arthritis wrist and finger joints: a comparison with conventional high-field MRI and radiography. *Ann Rheum Dis* 2005.
- [16] Lindegaard H, Vallo J, Horslev-Petersen K, Junker P, Ostergaard M. Low field dedicated magnetic resonance imaging in untreated rheumatoid arthritis of recent onset. *Ann Rheum Dis* 2001;60(8):770–6.
- [17] Dougados M, van der Linden S, Juhlin R, et al. The European Spondylarthropathy Study Group preliminary criteria for the classification of spondylarthropathy. *Arthritis Rheum* 1991;34(10):1218–27.
- [18] Eshed I, Althoff CE, Schink T, et al. Low-field MRI for assessing synovitis in patients with rheumatoid arthritis. Impact of Gd-DTPA dose on synovitis scoring. *Scand J Rheumatol* 2006;35(4):277–82.
- [19] Hottya GA, Peterfy CG, Uffmann M, et al. Dedicated extremity MR imaging of the foot and ankle. *Eur Radiol* 2000;10(3):467–75.
- [20] Mundinger A, Ioannidou M, Dinkel E, Beck A, Friedburg H, Sigmund G. Inflammatory and traumatic lesions of the knee and ankle: comparison of 0.23 T and 2 T MRI. *Radiat Med* 1990;8(6):211–4.
- [21] Ejlberg BJ, Narvestad E, Jacobsen S, Thomsen HS, Ostergaard M. Optimised, low cost, low field dedicated extremity MRI is highly specific and sensitive for synovitis and bone erosions in rheumatoid arthritis wrist and finger joints: comparison with conventional high field MRI and radiography. *Ann Rheum Dis* 2005;64(9):1280–7.
- [22] Schirmer C, Scheel AK, Althoff CE, et al. Diagnostic quality and scoring of synovitis, tenosynovitis and erosions in low-field MRI of patients with rheumatoid arthritis: a comparison with conventional MRI. *Ann Rheum Dis* 2007;66:522–9.
- [23] Taouli B, Zaim S, Peterfy CG, et al. Rheumatoid arthritis of the hand and wrist: comparison of three imaging techniques. *AJR* 2004;182(4):937–43.
- [24] Karr SD. Subcalcaneal heel pain. *Orthop Clin North Am* 1994;25(1):161–75.
- [25] Kier R. Magnetic resonance imaging of plantar fasciitis and other causes of heel pain. *Magn Reson Imaging Clin N Am* 1994;2(1):97–107.
- [26] Gerster JC, Vischer TL, Bennani A, Fallet GH. The painful heel. Comparative study in rheumatoid arthritis, ankylosing spondylitis, Reiter's syndrome, and generalized osteoarthritis. *Ann Rheum Dis* 1977;36(4):343–8.
- [27] Weishaupt D, Schweitzer ME. MR imaging of the foot and ankle: patterns of bone marrow signal abnormalities. *Eur Radiol* 2002;12(2):416–26.
- [28] Hermann KG, Eshed I, Bollow M. Imaging of enthesitis: a new field for the radiologist? *Rofo* 2006;178(6):578–89.
- [29] Kumar R, Madewell JE. Rheumatoid and seronegative arthropathies of the foot. *Radiol Clin North Am* 1987;25(6):1263–88.
- [30] Resnick D. Patterns of peripheral joint disease in ankylosing spondylitis. *Radiology* 1974;110(3):523–32.



### 3.2.3. MRT des Schultergelenkes

#### Publikation 4

**Hermann KG**, Backhaus M, Schneider U, Labs K, Loreck D, Zühlsdorf S, Schink T, Fischer T, Hamm B, Bollow M.

Rheumatoid arthritis of the shoulder joint: Comparison of conventional radiography, ultrasound, and dynamic contrast-enhanced magnetic resonance imaging.

Arthritis Rheum. 2003 Dec;48(12):3338-49.

<http://www3.interscience.wiley.com/cgi-bin/fulltext/106570257> – ISSN: 0004-3591, DOI 10.1002/art.11349

43 Patienten unterzogen sich einem prospektiven Vergleich der bildgebenden Verfahren konventionelle Radiographie, Gelenkulterschall (US) und kontrastmittelverstärkte dynamische Magnetresonanztomographie. Sowohl US als auch MRT detektieren mehr erosive Läsionen am Humeruskopf als die konventionelle Radiographie. Von den 13 Patienten ohne Erosionen im US zeigte die MRT dagegen bei 10 Patienten Erosionen, acht davon mit isolierten Erosionen, zwei mit konfluierenden Erosionen.

Entzündliche Weichteilveränderungen bei rheumatoider Arthritis wurden mittels MRT häufiger als mittels US detektiert: Synovitis 28 % (US) versus 63 % (MRT), Tenosynovitis 35 % versus 65 % sowie Bursitis 30 % versus 42 %.

Die Gabe von Kontrastmittel hatte keinen Einfluss auf die Detektierbarkeit von Erosionen ( $\kappa$ -Wert 0,83) beim Vergleich der Nativsequenzen mit dem kompletten MRT-Datensatz, der auch die kontrastmittelverstärkten Sequenzen enthält. Dagegen wurden Weichteilveränderungen wie Synovitiden, Tenosynovitiden und Bursitiden allein mittels T1-gewichteten Sequenzen und STIR-Sequenzen nur mit geringer Sensitivität erkannt. Die Detektion dieser Läsionen gelingt erst mit kontrastmittelverstärkten Sequenzen suffizient. Konsekutiv war eine geringe Übereinstimmung zwischen den Nativsequenzen und dem kompletten MR-Datensatz nachzuweisen mit  $\kappa$ -Werten von 0,35 (Synovitis), 0,39 (Tenosynovitis) und 0,38 (Bursitis).

Die dynamische kontrastverstärkte MRT erwies sich hilfreich für die Differenzierung verschiedener Patientengruppen: signifikant höhere „Enhancement-Slopes“ wurden gefunden bei Patienten mit Erosionen in der konventionellen Radiographie im Vergleich zu Patienten ohne Erosionen ( $p < 0,05$ ) sowie bei Patienten mit Erosionen in der MRT im Vergleich zu Patienten ohne MR-tomographisch detektierte Erosionen ( $p < 0,05$ ). Die dynamische MRT spielte jedoch keine Rolle bei der Differenzierung von Patienten mit hoher klinischer bzw. laborchemischer Aktivität von solchen mit niedriger Aktivität.

## Rheumatoid Arthritis of the Shoulder Joint

### Comparison of Conventional Radiography, Ultrasound, and Dynamic Contrast-Enhanced Magnetic Resonance Imaging

Kay-Geert A. Hermann,<sup>1</sup> Marina Backhaus,<sup>2</sup> Udo Schneider,<sup>2</sup> Karsten Labs,<sup>3</sup> Dieter Loreck,<sup>1</sup> Svenda Zühlsdorf,<sup>2</sup> Tania Schink,<sup>4</sup> Thomas Fischer,<sup>1</sup> Bernd Hamm,<sup>1</sup> and Matthias Bollow<sup>5</sup>

**Objective.** To determine the role of ultrasound and magnetic resonance imaging (MRI) compared with conventional radiography in the detection of chronic and acute inflammatory manifestations of rheumatoid arthritis (RA) of the shoulder joint.

**Methods.** Forty-three consecutive patients with known RA prospectively underwent clinical examination, radiography, ultrasound, and MRI of the shoulder joints. Each patient was assigned a clinical/laboratory score consisting of 7 parameters, including measurements of shoulder mobility, the erythrocyte sedimentation rate, and C-reactive protein level. Conventional radiography was standardized and performed in 2 planes. Ultrasound was performed in 10 predefined planes using a 7.5-MHz linear transducer. MRI at 1.5T comprised transverse and oblique coronal T1- and T2\*-weighted fast spin-echo, gradient-echo (GRE), and inversion-recovery sequences with a matrix size of up to 512 pixels. A dynamic T1-weighted GRE sequence was acquired with intravenous administration of contrast medium. Erosions were assessed using all 3 imaging techniques on a 4-point scale. Soft-tissue involvement was evaluated according to the presence of synovitis, tenosynovitis, and bursitis on ultrasound and MRI. The

results in the study group were compared with those obtained in a control group of 10 patients with shoulder pain.

**Results.** In the study group, erosions of the humeroscapular joint were detected by conventional radiography in 26 patients, by ultrasound in 30 patients, and by MRI in 39 patients; the differences were statistically significant for the comparisons of conventional radiography with MRI and for ultrasound versus MRI ( $P < 0.0001$ ). Conventional radiography detected 12 erosions of the scapula and MRI detected 15. Synovitis was demonstrated in 12 patients by ultrasound and in 27 patients by MRI ( $P = 0.0003$ ). Tenosynovitis was observed in 15 patients by ultrasound and in 28 patients by MRI ( $P = 0.0064$ ). Bursitis was detected in 13 patients by ultrasound and in 18 patients by MRI. The findings on dynamic contrast-enhanced MRI correlated significantly with the detection of synovitis by ultrasound and erosions by static MRI ( $P < 0.05$ ).

**Conclusion.** Ultrasound and MRI supplement conventional radiography in assessing the shoulder joint. Although conventional radiography can be used as the sole method of following up known joint destruction in RA, ultrasound and, preferably, MRI are recommended as additional techniques in the initial diagnostic evaluation when radiography yields negative results.

Radiography is currently regarded as the standard of reference for documenting the extent of joint destruction and its course in rheumatoid arthritis (RA) (1). The radiographic demonstration of erosions and narrowing of the joint space is one of the American College of Rheumatology (formerly, the American Rheumatism Association) criteria for RA (2). The

<sup>1</sup>Kay-Geert A. Hermann, MD, Dieter Loreck, MD, Thomas Fischer, MD, Bernd Hamm, MD: Department of Radiology, Charité, Berlin, Germany; <sup>2</sup>Marina Backhaus, MD, Udo Schneider, MD, Svenda Zühlsdorf: Department of Rheumatology and Clinical Immunology, Charité, Berlin, Germany; <sup>3</sup>Karsten Labs, MD: Department of Orthopedics, Charité, Berlin, Germany; <sup>4</sup>Tania Schink: Department of Medical Statistics, Charité, Berlin, Germany; <sup>5</sup>Matthias Bollow, MD: Augusta-Kranken-Anstalt, Bochum, Germany.

Address correspondence and reprint requests to Kay-Geert A. Hermann, MD, Institut für Radiologie, Charité Campus Mitte, Humboldt-Universität zu Berlin, Schumannstrasse 20/21, 10117 Berlin, Germany. E-mail: kgh@charite.de.

Submitted for publication October 14, 2002; accepted in revised form August 20, 2003.

guidelines of the World Health Organization/International League of Associations for Rheumatology include radiographic parameters among the examinations requested for the followup of RA patients in clinical long-term studies (3). Ultrasound and magnetic resonance (MR) imaging have already been compared with conventional radiography for the assessment of the peripheral joints of RA patients in several studies, and both have been found to have a higher sensitivity than radiography in detecting erosions (4–7). Little attention has so far been paid to the proximal joints of the arms, although the shoulder joints tend to show abnormal changes in a high percentage of patients when RA first becomes manifest (8,9). Clinical symptoms, such as pain and restriction of movement, may not occur before the destructive changes of the joints can be demonstrated.

In this open, prospective study, we determined the value of conventional radiography, ultrasound, and MR imaging as techniques for visualizing and detecting chronic and acute inflammatory changes of the humero-scapular joint in patients with RA.

#### PATIENTS AND METHODS

**Patients.** Forty-five consecutive patients with known RA and symptoms of shoulder pain were recruited for the study by a rheumatologist (US) from a rheumatology outpatient service. Two of the 45 patients had to be excluded because they reported having claustrophobia. The remaining group of 43 patients comprised 10 men (23%) and 33 women (77%) with a mean age of 56 years (range 23–89 years). Rheumatoid factor was positive in 28 patients (65%) and negative in 15 (35%). The mean duration of disease was 6.8 years, ranging from 6 months to 26 years. The shoulder symptoms had persisted for a mean of 2.1 years with a range of 4 months to 6.5 years. Erosions of the hands and feet were present at the time of examination in 65% of the study patients.

In addition, a control group of 10 patients (3 men and 7 women with a mean age of 43.3 years, range 22–71 years) from an orthopedic outpatient service was recruited by an orthopedist (KL). These control subjects were patients with shoulder pain. Exclusion criteria for the control group were a history of rheumatic disease, a history of trauma during the preceding 6 months, an elevated C-reactive protein (CRP) level, and the presence of rheumatoid factor. The controls had the following clinical features: 3 had impingement due to arthritis of the acromioclavicular joint, 2 had partial tear of the supraspinous tendon, 2 had labrum lesions, and 3 had normal shoulder findings.

**Clinical examination.** The clinical examination was performed by the same physician (US) in all patients of the study group. Disease activity in each patient was determined by calculating an activity index, consisting of the following clinical and laboratory parameters: apron maneuver, neck maneuver, inhibited abduction, pain at rest, pain on movement, abnormal

erythrocyte sedimentation rate (>20 mm/hour) during the first hour, and elevated level of CRP (>5 mg/dl). Each of these parameters was assigned 1 point, resulting in a maximum disease activity score of 7 points per patient. Active disease was defined as a score of 3 or above. This was the case in 25 patients (58.1%) of the study group.

**Conventional radiography.** Radiographic evaluation of both shoulders was performed by an experienced technician using 2 standard projections (anteroposterior and axial), after the clinical examination. The following exposure parameters were used: 52 kVp, 9–11 mAs depending on the requirements in the individual patient, nominal focal-spot size of 0.6 mm, and a focus–film distance of 1.15 meters. The radiographs were evaluated for the presence of erosions by 2 radiologists (DL and K-GAH) who were in consensus and had no knowledge of the clinical findings and the results of the other imaging techniques. The presence of erosions was determined using a modification of the Larsen scale (10), with the following stages: score 0–1 = no erosions, 2 = isolated erosions, 3–4 = confluent erosions, and 5 = generalized erosions. The presence of soft-tissue calcifications was recorded as well, and their rate of occurrence was 13%. However, no statistical analysis was performed, since the focus of the study was on inflammatory changes.

**Ultrasound.** The ultrasound examination was performed using a linear 7.5-MHz transducer (Ultramark 4; ATL, Bothel, WA). Ten standardized sections through both shoulder joints were documented on hard copies, as follows: 1) ventral transverse section and 2) ventral longitudinal section over the intertubercular sulcus, for visualization of the long biceps tendon and detection of minute fluid accumulations and detection of tenosynovitis; 3) ventral transverse section in the coracoacromial window in neutral position; 4) ventral transverse section during maximal external rotation and 5) ventral transverse section during maximal internal rotation (apron grip), for assessments of the rotator cuff and bursitis, effusion, synovial proliferation, and erosion; 6) ventral longitudinal section at a 90° angle to the coracoacromial section during maximal internal rotation of the arm (apron grip), for visualization of the target structures in a different plane; 7) ventrolateral longitudinal section from the ventral lateral acromion to the greater tubercle, for assessment of the supraspinatus muscle; 8) dorsal transverse section through the infraspinous fossa laterally below the scapular spine and 9) axillary longitudinal section, for detection of synovitis, synovial proliferation, and erosion of the humeral head; and 10) ventral transverse section over the acromioclavicular joint. The examination was performed by a rheumatologist (MBa) experienced in ultrasound examinations, who had no knowledge of the clinical, radiographic, and MR imaging findings.

Steplike deformations and other irregularities of the joint contours in the humeral head were classified as erosions when they were visualized in 2 planes perpendicular to each other. The extent of erosions was graded as follows: no erosions, isolated erosions (1–3), confluent erosions (4–6), and generalized erosions (>6).

Synovitis is characterized on ultrasound by an anechoic or hypoechoic area with elevation of the capsule on the axillary longitudinal section and/or dorsal transverse section and/or ventral transverse and longitudinal sections. Presence of tenosynovitis of the long biceps tendon was assumed when the

**Table 1.** Comparison of conventional radiography with ultrasound and magnetic resonance imaging in assessing erosions of the shoulder joint\*

Conventional radiography	Ultrasound					Magnetic resonance imaging				
	None	Isolated	Confluent	Generalized	Total	None	Isolated	Confluent	Generalized	Total
None	9	8	0	0	17	4	11	2	0	17
Isolated	2	9	1	1	13	0	7	5	1	13
Confluent	2	3	3	1	9	0	3	4	2	9
Generalized	0	0	2	2	4	0	0	1	3	4
Total	13	20	6	4	43	4	21	12	6	43

\* Values are the number of shoulders graded for erosions. See Patients and Methods for definitions of grading scales.

echogenic tendon was surrounded by a hypoechoic band on the transverse and longitudinal sections. Bursitis was characterized by a widened anechoic or hypoechoic margin in the area of the subacromial/subdeltoid bursa or subcoracoid bursa, with or without villus formation.

**MR imaging.** Assessment of the shoulder joint by MR imaging was performed on a 1.5T imager (Magnetom Vision; Siemens, Erlangen, Germany) using a flexible wrap-around coil. The patients underwent MR imaging within 2–4 weeks of the clinical examination, and their medication remained unchanged during this time. The shoulder joint that was clinically determined to be most severely affected was imaged, with the patient placed in the supine position and the adducted arm in neutral position. The following sequences were used: T1-weighted spin-echo sequence (repetition time [TR] of 559 mseconds, echo time [TE] of 20 mseconds, slice thickness of 3 mm, matrix size of  $192 \times 512$  pixels, and field of view [FOV] of 290 mm) in a transverse and oblique coronal slice orientation parallel to the course of the tendon of the supraspinous muscle; T2\*-weighted opposed-phase gradient-echo (GRE) sequence (TR of 450 mseconds, TE of 12 mseconds, flip angle of  $30^\circ$ , slice thickness of 4 mm, matrix size of  $224 \times 256$  pixels, and FOV of 250 mm) in a transverse section orientation; and short tau inversion recovery (STIR) sequence (TR of 4,890 mseconds, TE of 60 mseconds, slice thickness of 4 mm, matrix size of  $242 \times 256$  pixels, and FOV of 280 mm) in an oblique coronal orientation as described above.

After selection of a suitable slice on which abnormal changes were visualized, a dynamic contrast-enhanced study was performed using a T1-weighted opposed-phase GRE sequence (TR of 50 mseconds, TE of 5 mseconds, flip angle of  $70^\circ$ , slice thickness of 5 mm, matrix size of  $224 \times 265$  pixels, and FOV of 240 mm) in the single-slice mode in transverse orientation. Five repetitions, each of 45 seconds in duration, were performed, with bolus administration of gadolinium diethylenetriaminepentaacetic acid (Gd-DTPA) (Magnevist; Schering, Berlin, Germany) at a dose of 0.01 mmoles/kg body weight between the first and the second repetition. The dynamic study was followed by acquisition of a T1-weighted spin-echo sequence with fat saturation (TR of 720 mseconds, TE of 20 mseconds, slice thickness of 3 mm, matrix size of  $192 \times 512$  pixels, and FOV of 290 mm) in transverse orientation. The same MR imaging protocol was used in the control group. The results on dynamic contrast-enhanced MR imaging with regard to synovitis were used to calculate an enhancement factor, which was expressed as the percentage increase in signal intensity (SI) (calculated as  $SI_{\max} \times 100$ , divided by  $SI_{\text{pre}}$ ), and an enhancement slope, expressed as the percentage increase in SI per minute (calculated as  $[SI_{\max} - SI_{\text{pre}}] \times 100$ , divided by  $SI_{\text{pre}} \times T_{\max}$ ), where the  $SI_{\max}$  is the maximum postcontrast

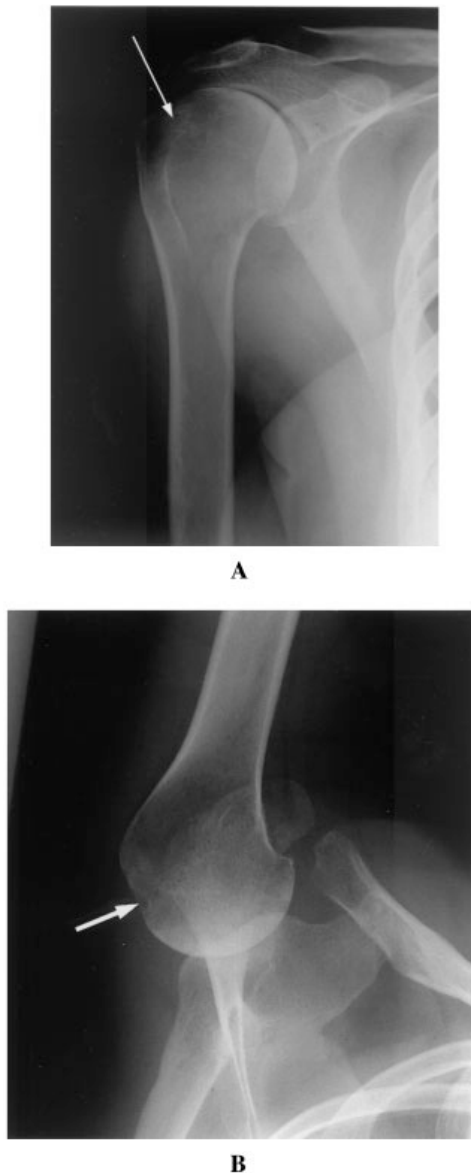
signal intensity before a plateau is reached, the  $SI_{\text{pre}}$  is the precontrast signal intensity, and the  $T_{\max}$  is the time (in seconds) between the contrast medium bolus and the  $SI_{\max}$  (see Figure 4B).

The MR images were evaluated by 2 readers (MBo and SZ) who were in consensus and had no knowledge of the clinical findings and the results of the other imaging techniques. The MR images were analyzed for the presence of synovitis, tenosynovitis of the long biceps tendon, and bursitis, as well as the extent of erosions in the dorsal, ventral, and lateral part of the humeral head and additionally in the glenoid fossa of the scapula. The extent of erosions was graded using the following scale: no erosions, isolated erosions (1–3 isolated erosions), confluent (4–6 isolated erosions or 1–6 beaded erosions), and generalized erosions (>6 erosions).

An erosion was defined as a joint-related cortical defect with a hypointense signal on T1-weighted spin-echo or GRE images showing contrast enhancement after Gd-DTPA administration and hyperintensity on the STIR sequence. Nonenhancing hypointense joint-related substrates were counted as smoothed erosions only if they were at least 2 mm in size. Tenosynovitis was diagnosed when an increased signal was seen along the courses of tendons on the T2\*-weighted sequences, the STIR sequence, or the fat-saturated T1-weighted turbo spin-echo sequence after administration of contrast medium. Bursitis was assumed to be present when these sequences showed hyperintensities in the areas of the subacromial/subdeltoid bursa or of the subcoracoid bursa. All unenhanced MR images were assessed for the presence of erosions, synovitis, tenosynovitis, and bursitis in a second blinded reading after 4 months, to determine whether contrast medium is necessary for visualization.

**Statistical analysis.** None of the imaging techniques evaluated in this study was regarded as the gold standard. Therefore, the kappa coefficient was used to describe agreement between each technique. Poor agreement was assumed at kappa values <0.40, moderate to good agreement at values of 0.40–0.75, and excellent agreement at values >0.75 (11). McNemar's test was used to examine whether any one technique identified significantly more abnormal findings than the other techniques (12). Comparisons between patients and controls were done with Fisher's exact test. Continuous variables (the enhancement factor and enhancement slope as measures of dynamic MR imaging) were compared using the nonparametric Mann-Whitney U test. Statistical significance was assumed at a *P* value of less than 0.05. Statistical analysis was performed using the standard software packages





**Figure 1.** Conventional radiographic images of the shoulder joint of a 23-year-old patient with a 3-year history of rheumatoid arthritis and 6 months of shoulder pain on the right. **A**, Anteroposterior projection, showing smooth joint contours and areas of cyst-like lesions in the greater tubercle of the humeral head (**arrow**). **B**, Axial projection, showing slightly wavy configuration of the greater tubercle (**arrow**).

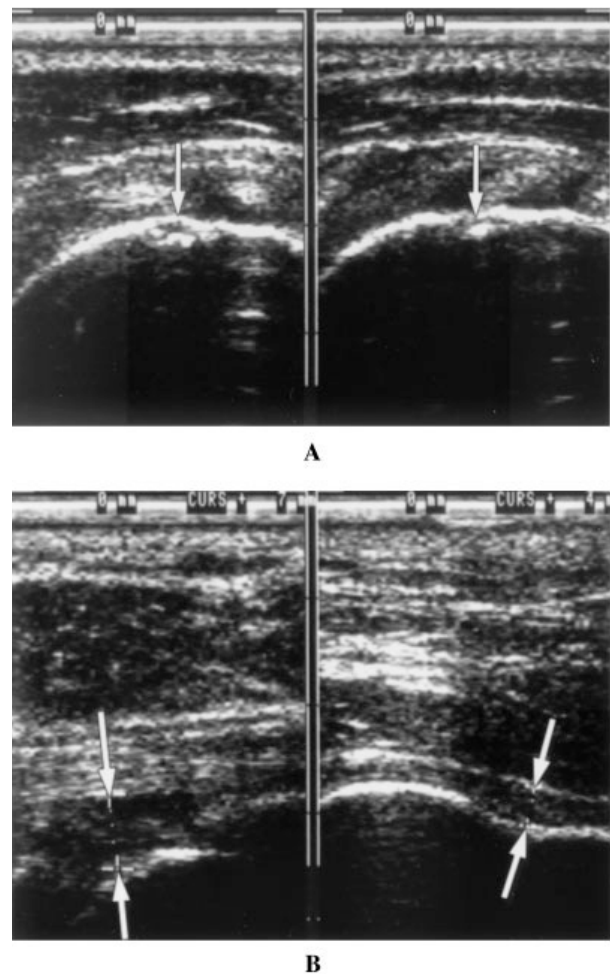
SPSS 10 for Macintosh (SPSS, Chicago, IL), StatXact 5.0.3 (Cytel Software, Cambridge, MA), and MedCalc 6.12 for Windows (MedCalc, Brussels, Belgium).

## RESULTS

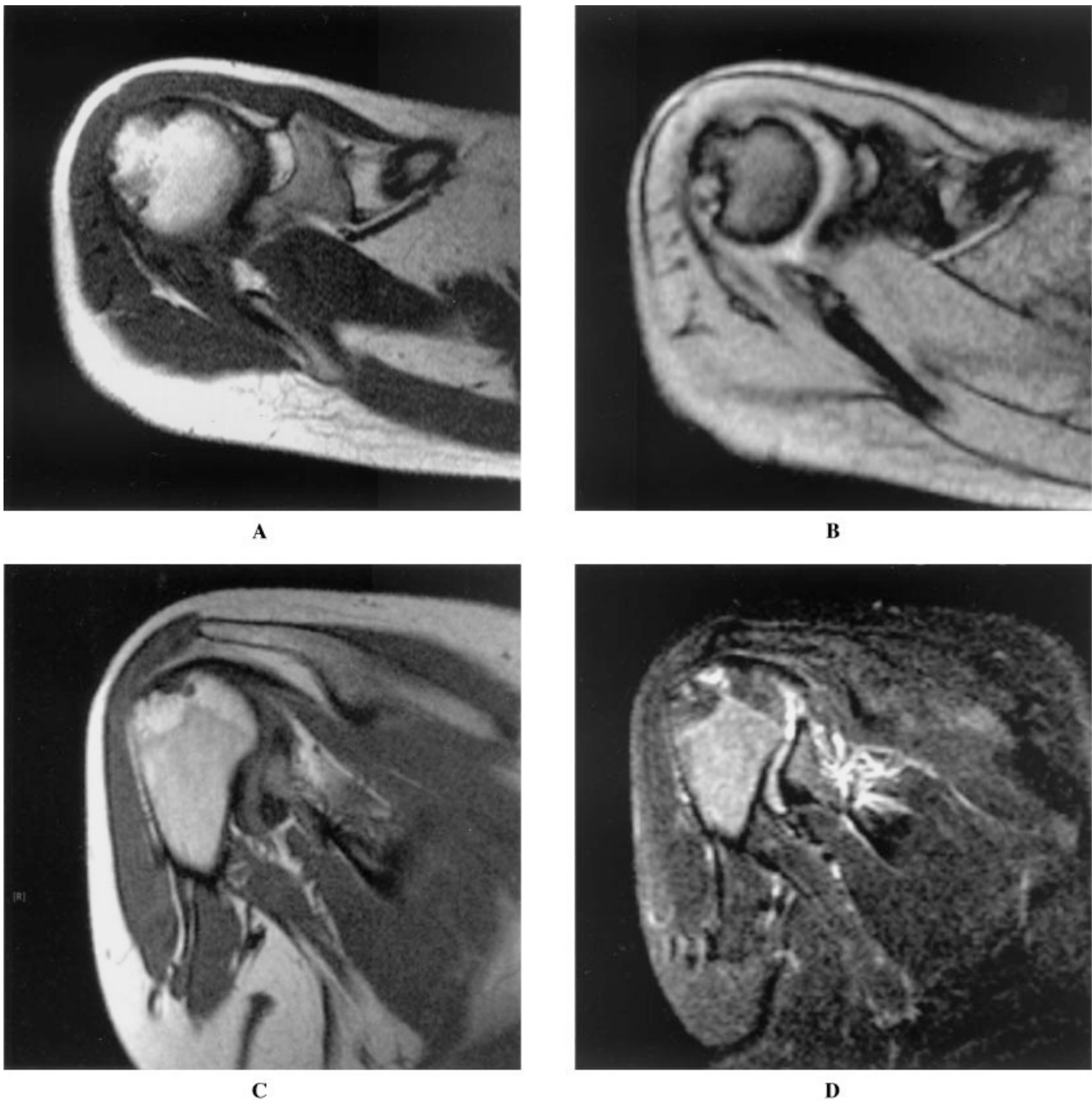
**Frequency of erosions in the study group.** The imaging studies of all 43 patients were complete and could

be entirely evaluated, and the results have been summarized. Conventional radiography detected erosions in 26 (60%) of the shoulders examined. The erosions were isolated in 13 patients, confluent in 9, and generalized in 4. Seventeen (40%) of the humeral heads examined were found to be free of erosions by conventional radiography (Table 1, Figures 1A and B). Twelve patients were found to have erosions in the glenoid fossa.

Ultrasound examination demonstrated erosions in 30 (70%) of the glenohumeral joints. Twenty joints showed isolated erosions (Table 1 and Figure 2A), 6



**Figure 2.** Ultrasound images of the shoulder joint of the same patient as in Figure 1. **A**, Longitudinal (**left**) and transverse (**right**) views of the anterolateral region of the humerus, showing erosion of the anterior portion of the head of the humerus (**arrows**). **B**, Posterior portion (**left**) and axillary recess (**right**) of the shoulder joint, with hypoechoic indications of synovitis as shown by widening of the synovial space to 7 mm and 4 mm, respectively (**arrows**).



**Figure 3.** Magnetic resonance imaging of the shoulder joint of the same patient as in Figure 1. In the T1-weighted spin-echo sequence (A) and T2\*-weighted gradient-echo sequence (B) in transverse orientation, and in the oblique coronal T1-weighted sequence (C), confluent erosions are evident in the area of the greater tubercle and the adjoining anterior and dorsal portions of the head of the humerus. In the oblique coronal short tau inversion recovery sequence (D), the hyperintense signal of the erosions is an indication of synovitis or effusion.

showed confluent erosions, and 4 showed generalized erosions. Thirteen joints (30%) showed no erosions on ultrasound. No results were available on the glenoid fossa, which is not assessable by ultrasound.

MR imaging detected erosions in 39 (91%) of the

glenohumeral joints. These were isolated in 21 joints, confluent in 12 (Figures 3A–C), and generalized in 6 (Table 1). Four shoulders (9%) showed no erosions. Erosions of the scapula were found in 15 patients. Cyst-like lesions unrelated to the cortex were seen in 15

**Table 2.** Comparison of ultrasound with magnetic resonance imaging in assessing erosions of the shoulder joints\*

Ultrasound	Magnetic resonance imaging				Total
	None	Isolated	Confluent	Generalized	
None	3	8	2	0	13
Isolated	1	12	5	2	20
Confluent	0	1	4	1	6
Generalized	0	0	1	3	4
Total	4	21	12	6	43

\* Values are the number of shoulders graded for erosions. See Patients and Methods for grading scales.

patients (34.9%). There was excellent agreement in the assessment of erosions between the full MR imaging study and the reading of unenhanced images alone ( $\kappa = 0.83$ , 95% confidence interval [95% CI] 0.74–0.91,  $P < 0.0001$ ).

**Comparison of methods to detect erosions in the study group.** *Negative findings on conventional radiography versus ultrasound and MR imaging.* In the 17 patients without detectable erosions on conventional radiography, the ultrasound examination demonstrated isolated erosions in 8 patients and MR imaging identified erosions in 13 patients (11 isolated and 2 confluent) (Table 1). Of the 8 shoulders with erosions detected by ultrasound, 7 of these could be confirmed by MR imaging.

*Isolated erosions on conventional radiography versus MR imaging and ultrasound.* In the group of 13 patients diagnosed as having isolated erosions on the basis of radiography, MR imaging identified confluent erosions in 5 of these patients and even generalized erosions in 1 patient. Ultrasound examination demonstrated 1 patient as having confluent erosions or 1 as having generalized erosions, but failed to identify erosions in 2 patients of this group (Table 1).

*Negative findings on ultrasound versus conventional radiography and MR imaging.* In the group of 13 patients not showing any erosions on ultrasound, 2 patients had isolated erosions and 2 had confluent erosions on conventional radiography. MR imaging depicted 8 joints with isolated erosions and 2 joints with confluent erosions in this group (Table 2).

**Table 3.** Results of ultrasound and magnetic resonance imaging in detecting erosions of the humeral head, in a region-by-region approach\*

	Localization of erosions		
	Ventral	Lateral	Dorsal
Ultrasound	21	12	11
Magnetic resonance imaging	27	34	12

\* Values are the number of shoulders with erosions of the humeral head.

**Table 4.** Combined results of conventional radiography and ultrasound compared with magnetic resonance imaging in assessing erosions of the shoulder joint\*

Conventional radiography + ultrasound	Magnetic resonance imaging				
	None	Isolated	Confluent	Generalized	Total
None	3	6	0	0	9
Isolated	1	12	5	1	19
Confluent	0	3	5	1	9
Generalized	0	0	2	4	6
Total	4	21	12	6	43

\* Values are the number of shoulders graded for erosions. See Patients and Methods for grading scales.

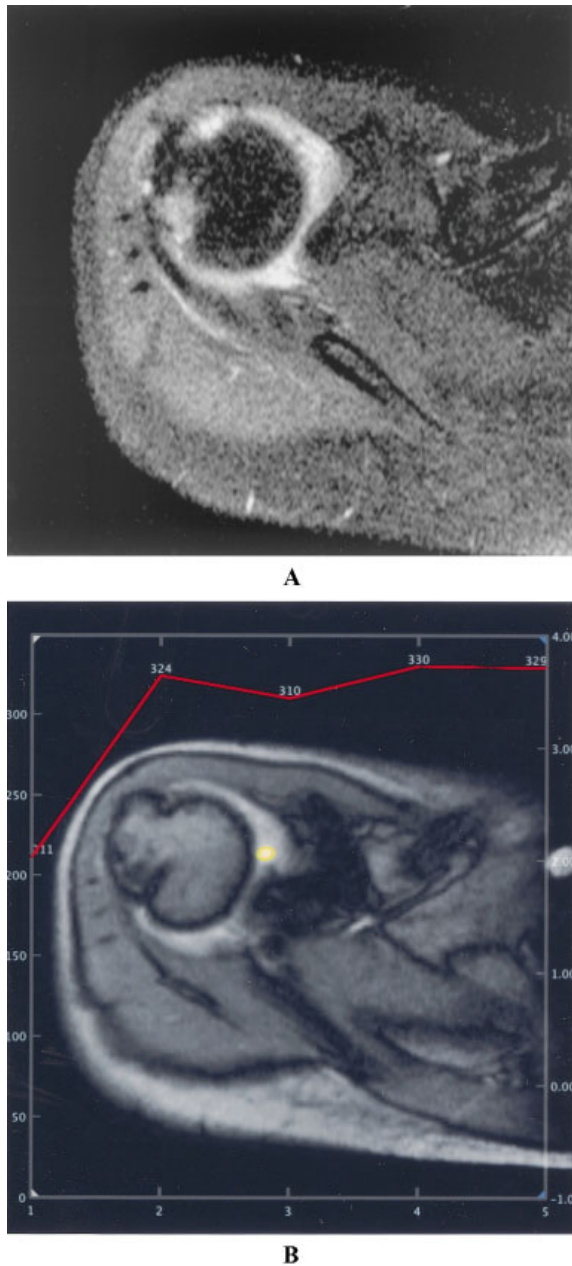
*Negative findings on MR imaging versus conventional radiography and ultrasound.* The glenohumeral joints negative for erosions on MR imaging were also negative on conventional radiography. Ultrasound demonstrated no erosions in 3 of these patients, but isolated erosions were visualized in 1 instance (Table 2).

*Positive findings on ultrasound and MR imaging, in a region-by-region approach.* Ventral, lateral, and dorsal erosions of the humeral head were demonstrated by ultrasound in 21, 12, and 11 shoulders, respectively, as compared with 27, 34, and 12 shoulders by MR imaging (Table 3).

*Scapula erosions on conventional radiography and MR imaging.* All erosions of the scapula detected by conventional radiography were also demonstrated by MR imaging. MR imaging also identified erosions of the glenoid fossa of the scapula in 3 patients, while erosions at this site escaped detection by conventional radiography.

*Concurrence among the techniques.* Statistical analysis of these results showed moderate to good agreement between the techniques in the detection of erosions. Comparison of ultrasound with conventional radiography (Table 1) yielded a weighted kappa value of 0.62 (95% CI 0.43–0.82,  $P < 0.0001$ ). Ultrasound identified more higher-grade erosions than did conventional radiography in 11 patients, while 9 cases of erosion were classified as more severe by conventional radiography than by ultrasound. This difference in the assessment of severity was not significant ( $P = 1.0$  by McNemar’s test).

A different picture emerged in the comparison of conventional radiography with MR imaging, and of ultrasound with MR imaging. In the former comparison (Table 1), a weighted kappa of 0.59 was calculated (95% CI 0.41–0.76,  $P < 0.0001$ ). MR imaging identified a higher rate of more severe erosions than did conventional radiography in 21 patients (compared with 4 patients by radiography). This difference was significant



**Figure 4.** Dynamic contrast-enhanced magnetic resonance imaging of the shoulder joint of the same patient as in Figure 1. **A**, The transverse T1-weighted spin-echo sequence with fat saturation, after intravenous administration of gadolinium diethylenetriaminepentaacetic acid, reveals pronounced enhancement of erosions and the entire joint space, suggesting hypervascularized synovitis. **B**, The T1-weighted gradient-echo sequence with superimposed signal intensity–time curve shows in a circular region of interest (yellow area) a rapid increase in signal and an early transition to a plateau phase.

( $P < 0.0006$  by McNemar's test). The comparison of ultrasound and MR imaging (Table 2) yielded a weighted kappa of 0.55 (95% CI 0.36–0.75,  $P < 0.0001$ ). Similar to the results described above, MR imaging identified a higher number of more severe erosions compared with ultrasound (18 patients versus 3 patients) ( $P < 0.0009$  by McNemar's test).

The comparison of the combined results of conventional radiography and ultrasound (taking into account the higher-grade result) with those of MR imaging showed moderate agreement, with a kappa of 0.69 (95% CI 0.54–0.84,  $P < 0.0001$ ) (Table 4). There were fewer discrepancies in the degree of severity than that found in the comparison of MR imaging and ultrasound alone (13 shoulders in which MR imaging identified more severe lesions versus 6 shoulders identified by conventional radiography combined with ultrasound) ( $P = 0.1344$  by McNemar's test).

**Detection of synovitis and paraarticular soft-tissue involvement in the study group.** The presence of synovitis, tenosynovitis, and bursitis was assessed qualitatively by ultrasound and MR imaging supplemented by the information derived from calculation of the enhancement factor and enhancement slope (Figure 4B).

Ultrasound demonstrated synovitis of the humero-scapular joint in 12 joints (28%) (Figure 2B), tenosynovitis of the long biceps tendon in 15 joints (35%), and bursitis in 13 joints (30%). In comparison, MR imaging demonstrated a higher frequency of all 3 types of soft-tissue lesions analyzed: 27 joints with synovitis (63%) (Figures 3D and 4A), 28 with tenosynovitis of the long biceps tendon (65%), and 18 with bursitis (42%).

Synovitis was additionally assessed quantitatively by calculation of the enhancement factor and enhancement slope (Figure 4B). The quantitative analysis revealed a significantly higher enhancement slope in patients with erosions demonstrated by conventional radiography and MR imaging and with sonographically detected synovitis ( $P < 0.05$  by Mann-Whitney U test). Results were similar using the enhancement factor. No significant differences in enhancement slopes and enhancement factors were seen between patients with and without erosions on ultrasound and between patients with and without abnormal clinical and laboratory activity indices. The second reading, which did not include the contrast-enhanced MR image sets, showed poor agreement in the detection of synovitis, tenosynovitis, and bursitis as reflected by kappa values of 0.35, 0.39, and 0.38, respectively.

The results of the statistical comparison of ultrasound and MR imaging in the detection of synovitis and inflammatory changes of the periarticular soft tissue are

**Table 5.** Comparison of ultrasound with magnetic resonance imaging in detecting synovitis of the shoulder joints\*

Ultrasound	Magnetic resonance imaging		Total
	No	Yes	
No	15	16	31
Yes	1	11	12
Total	16	27	43

\* Values are the number of shoulders showing the presence (Yes) or absence (No) of synovitis.

presented in Tables 5–7. Among the 31 patients with normal ultrasound findings in the glenohumeral joints, contrast-enhanced MR imaging identified 16 instances of synovitis (52%) (Table 5). The kappa value of 0.29 (95% CI 0.08–0.50,  $P = 0.0318$ ) suggests a poor agreement between these 2 imaging techniques in the detection of synovitis. MR imaging detected synovitis in a total of 27 shoulders, whereas ultrasound identified synovitis in only 12 shoulders. Sixteen cases of synovitis on MR imaging escaped detection by ultrasound, as opposed to only 1 case being undetected by MR imaging. This difference was significant ( $P = 0.0003$  by McNemar's test).

The situation was similar for the detection of tenosynovitis of the long biceps tendon (Table 6). Fourteen of the 28 patients without any abnormality of the biceps tendon on ultrasound showed tenosynovitis on MR imaging (50%). The kappa value was 0.36 (95% CI 0.14–0.58,  $P = 0.0064$ ), indicating poor agreement between the 2 techniques. MR imaging demonstrated 28 instances of tenosynovitis, of which 14 escaped detection by ultrasound ( $P = 0.001$  by McNemar's test).

The agreement between both of these techniques for the detection of bursitis was poor, similar to the above comparison, and this was reflected by a kappa value of 0.35 (95% CI 0.07–0.63;  $P = 0.0225$ ) (Table 7). Among the 30 patients without demonstration of bursitis on ultrasound, MR imaging identified bursitis in 9 (30%). Of the 13 shoulders with bursitis demonstrated

**Table 6.** Comparison of ultrasound with magnetic resonance imaging in detecting tenosynovitis of the shoulder joints\*

Ultrasound	Magnetic resonance imaging		Total
	No	Yes	
No	14	14	28
Yes	1	14	15
Total	15	28	43

\* Values are the number of shoulders showing the presence (Yes) or absence (No) of tenosynovitis.

**Table 7.** Comparison of ultrasound with magnetic resonance imaging in detecting bursitis of the shoulder joints\*

Ultrasound	Magnetic resonance imaging		Total
	No	Yes	
No	21	9	30
Yes	4	9	13
Total	25	18	43

\* Values are the number of shoulders showing the presence (Yes) or absence (No) of bursitis.

by ultrasound, 4 (31%) escaped detection by MR imaging ( $P = 0.2668$  by McNemar's test).

**Comparisons with control group.** MR imaging demonstrated changes consistent with the presence of erosions in 2 patients in the control group (20%). This incidence of erosions was significantly lower than in the study group ( $P < 0.0001$  by Fisher's exact test). Patients with RA and erosions on MR imaging had significantly higher enhancement slopes than did the controls ( $P < 0.05$  by Mann-Whitney U test). Cyst-like subcortical lesions of the humeral head were detected in 5 patients (50%) of the control group, which was not statistically different from the incidence in the RA patients ( $P = 0.475$  by Fisher's exact test). However, the enhancement factors differed significantly between RA patients with cysts and control patients with cysts ( $P < 0.05$  by Mann-Whitney U test).

## DISCUSSION

The early and definitive diagnosis of a chronic inflammatory joint disease is crucial for initiating optimal treatment. Conventional radiography is currently a widely used approach for the detection and followup of joint destruction of the shoulder in patients with RA. However, conventional radiography only detects late changes, such as narrowing of the joint space, erosions, and joint destruction, but fails to visualize inflammation of the synovial membrane.

In the present study, we compared conventional radiography, ultrasound, and MR imaging as techniques for the detection of inflammatory processes of the shoulder joint. The key question to be answered by this investigation was whether there is an imaging technique that detects both bone lesions (erosions) and acute inflammatory changes (synovitis, tenosynovitis, and bursitis) earlier than conventional radiography. Moreover, we hoped to use our results to make recommendations for clinical practice.

A study by Babini et al that investigated the shoulder by conventional radiography demonstrated

erosions in the superolateral area of the glenohumeral joint in 20% of 56 patients with RA (13). In contrast, we identified erosions in 60% of our study patients. This discrepancy may be due to the fact that we evaluated the entire head of the humerus and also classified very small cortical defects as erosions.

Our results show that the detection rate of ultrasound is even higher than that of conventional radiography, but the difference is not statistically significant. Significantly more erosions were detected by MR imaging compared with conventional radiography. These findings are consistent with the results reported by other authors (14–19). The differences in the detection rate are due to the fact that ultrasound and MR imaging are sectional imaging techniques. Radiography has a higher spatial resolution and depicts cortical structures in great detail. However, as a projection technique, radiography is methodologically limited because cortical defects are visualized as typical erosions only if the beam hits them tangentially. Otherwise, an erosion will appear as a cyst-like lesion or completely escape detection. The significantly better detection rate of MR imaging is the result of its high soft-tissue contrast, which allows for the visualization of abnormal bone marrow changes such as edema that are associated with cortical destruction. The diagnostic accuracy of MR imaging is further improved by administration of a contrast medium, since florid erosions are characterized by a steep contrast enhancement (20).

Several investigators have emphasized the role of ultrasound in detecting erosions of the joints of the hands (4,7,21–23). In the area of the shoulder girdle, lesions of the rotator cuff have been investigated by ultrasound (24–26). Few studies assessing the detection of erosions in rheumatic diseases have focused on the humeroscapular joint for the comparison with conventional radiography. The data published in the literature show ultrasound to have a higher sensitivity than radiography (16,17,27).

The markedly higher detection rate for identifying erosions of the shoulder joint on MR imaging in comparison with conventional radiography confirms the results of former studies (17,27,28). MR imaging consistently detects more erosions than conventional radiography. However, the key question of our study is how MR imaging performs in direct comparison with ultrasound. This issue has not yet been clarified in depth.

The agreement between ultrasound and MR imaging in the detection of erosions, as reflected by the kappa value, was moderate to good in our study. MR imaging was more sensitive than ultrasound. This result

is consistent with the observations of Alasaarela and coworkers, who, in a study of 26 patients, showed that, on the whole, MR imaging identified more lesions than ultrasound (17). However, the situation was different for the greater tubercle, where ultrasound demonstrated a higher number of erosions. In a second study by the same group, which involved 30 patients, the kappa values showed poor agreement between both techniques for the region of the greater tubercle, but moderate to good agreement for the other areas of the humeral head (29). The poor agreement was due to the fact that ultrasound identified more erosions of the greater tubercle than did MR imaging. The latter result has not been confirmed by us, but rather, the opposite was true in our study. Our experience suggests that the greater tubercle of the humerus is effectively visualized by MR imaging when transverse and oblique coronal sections are used. The lower detection rate of MR imaging in the study by Alasaarela et al may have been due to the fact that a lower field strength of 1.0T and no high-resolution sequences with a matrix size of 512 pixels were used. Differences in defining the regions of the humeral head may also play a role (“ventral” versus “greater tubercle”).

In a study of 23 patients, Hodler et al found the percentage of erosions in the glenohumeral joint detected by MR imaging to be similar to that identified by ultrasound (27). To our knowledge, there are no studies in which ultrasound identified more erosions of the shoulder joint as a whole in comparison with MR imaging, whereas slightly different results are reported when using a region-by-region approach (17,29). The fact that the combined results of conventional radiography and ultrasound demonstrated detection of fewer erosions of the shoulder also underlines the higher detection rate of MR imaging.

In addition to the detection of osseous changes, we also directly compared ultrasound and MR imaging in the evaluation of soft-tissue involvement of the shoulder in RA. The ability of MR imaging and ultrasound to identify soft-tissue involvement was assessed by analyzing the detection of synovitis, tenosynovitis of the long biceps tendon, and bursitis. All 3 conditions were detected more frequently by MR imaging than by ultrasound, with the difference being significant for the demonstration of synovitis and tenosynovitis.

The above-quoted study by Alasaarela et al also deals at length with the involvement of paraarticular soft tissue in the shoulder area in RA (29). The authors found a level of agreement between MR imaging and ultrasound in the detection of synovitis similar to that

found in our study, with MR imaging having a higher detection rate. The detection of synovitis by ultrasound is limited by the poor differentiation of joint effusion and proliferative synovitis, which may be improved in the future by the use of power Doppler ultrasound or contrast-enhanced Doppler ultrasound (30,31).

In our clinical experience, dynamic contrast-enhanced MR imaging is an effective approach for assessing the shoulder joint. The time course of enhancement after administration of contrast medium allows for assessing the floridity of arthritis, even when only minor morphologic changes are present (20,32–34). Enhancement parameters provide useful additional information for differentiating erosions from contour irregularities caused by degenerative processes. This assumption is corroborated by the significant difference in enhancement seen between patients with erosions and those without erosions on MR imaging. Moreover, RA patients with erosions on MR imaging show a higher enhancement than do controls. The first study, by Munk et al, that investigated dynamic contrast-enhanced MR imaging of the shoulder included 12 patients (34). To our knowledge, the present study is the first that evaluates dynamic contrast-enhanced MR imaging of the shoulder joint in comparison with 2 other imaging techniques in a larger patient series.

It is often difficult to differentiate subcortical cysts in healthy elderly individuals or in patients with rotator cuff lesions from inflammatory cystic lesions in patients with RA of the shoulder (35,36). In this case, again, dynamic MR imaging may be helpful. Our study demonstrates a pronounced difference in enhancement slopes between RA patients with cysts and control patients with cysts. However, there is a wide range of conditions that similarly show enhancement in the presence of reactive synovitis. Only the patient's history, clinical findings, laboratory results, and MR imaging findings, taken together, allow one to arrive at the diagnosis. These results require further investigation in larger patient populations.

Tenosynovitis of the long biceps tendon was significantly more frequently detected by MR imaging than by ultrasound, which is in agreement with the results of the study of Alasaarela et al (29). It is again likely that the results of ultrasound can be improved in this respect by using the power Doppler technique and contrast-enhanced ultrasound. Bursitis was also more frequently detected by MR imaging, but the difference was not significant. Both techniques seem to be able to detect minute abnormal fluid accumulations in the

subacromial/subdeltoid bursa and the subcoracoid bursa.

Does the administration of a contrast medium provide additional information as compared with unenhanced STIR and T2-weighted sequences? Erosions are primarily identified on the basis of morphologic criteria and were detected in the present study using the unenhanced MR image sets alone. All inflammatory soft-tissue processes (synovitis, tenosynovitis, and bursitis), on the other hand, are inadequately visualized on unenhanced images. These results show the usefulness of contrast medium in MR imaging of patients with RA.

The investigations by Drossaers-Bakker et al (37) have shown that there is a close association between the destruction of small and large joints. All patients included in this study who had abnormal changes of the large joints also showed changes of the small joints. Many clinical studies therefore do not assess the large joints in the followup of RA. Patients presenting with initial manifestations in the hands and feet already have symptoms in the shoulder joint in 67% of the cases (8). However, not all cases of RA present with primary symptoms in the hands and feet. A large epidemiologic study showed that 8% of patients had initial symptoms in the shoulder (38). In a large population of 105 RA patients with a mean duration of RA of 17 years, 91 patients reported shoulder symptoms (9).

In terms of costs and benefits, conventional radiography is an inexpensive procedure that is available everywhere, but fails to detect very early changes. Ultrasound can be used as a bedside technique. It is relatively inexpensive, but is limited by being examiner-dependent. MR imaging is more sensitive than conventional radiography and ultrasound in several respects, depicts intraosseous processes, and provides a clear picture of the extent of granulation tissue, erosions, joint effusion, and similar changes. MR imaging is less widely available, and is time-consuming and expensive.

Although the prospective study described herein was carefully planned, it has some limitations. One is the time interval between the clinical examination and ultrasound, on the one hand, and MR imaging, on the other. The study patients were recruited from the outpatient service, which made their rapid enrollment in the study necessary in order to ensure their compliance. Not all patients could undergo the MR imaging examination on the same day as the ultrasound and conventional radiography examinations, because of the limited MR imaging capacities available.

A further limitation of our study may be the fact

that the dynamic MR imaging studies were performed in the single-slice mode. The transverse slice for the dynamic study was chosen by the radiologist on the basis of the precontrast examination. Florid pannus tissue in slice orientations other than the one chosen, therefore, could not be studied dynamically and could not be included in the calculation of the parameters characterizing the time course of contrast enhancement. This limitation had no effect on the qualitative evaluation of the images, since the dynamic series was followed by a fat-saturated T1-weighted spin-echo sequence that visualized enhancing pannus tissue in all slice positions. The acquisition of 12–15 slices per sequence did not allow complete coverage of the acromioclavicular joint in 2 planes in all patients, so that no generalizations about the visualization of inflammatory changes of the acromioclavicular joint by MR imaging can be made. Whether the high percentage (34.9%) of rheumatoid factor–negative patients in our study had any effects on the results remains to be determined in investigations of larger patient populations.

In conclusion, our results suggest that both ultrasound and MR imaging are important additional techniques that supplement conventional radiography of the shoulder joint in RA. Although conventional radiography may be sufficient in following up known joint processes in RA, the initial diagnostic examination should include ultrasound in cases of negative radiographic findings, and contrast-enhanced MR imaging should be used as a problem-solving approach.

#### ACKNOWLEDGMENTS

The authors thank Mrs. Angelika Bock for expertly performing the radiographic examinations, and Mrs. Bettina Herwig for translating the manuscript.

#### REFERENCES

- McGonagle D, Conaghan PG, Wakefield R, Emery P. Imaging the joints in early rheumatoid arthritis. *Baillieres Best Pract Res Clin Rheumatol* 2001;15:91–104.
- Arnett FC, Edworthy SM, Bloch DA, McShane DJ, Fries JF, Cooper NS, et al. The American Rheumatism Association 1987 revised criteria for the classification of rheumatoid arthritis. *Arthritis Rheum* 1988;31:315–24.
- Tugwell P, Boers M. OMERACT conference on outcome measures in rheumatoid arthritis clinical trials: introduction. *J Rheumatol* 1993;20:528–30.
- Backhaus M, Kamradt T, Sandrock D, Loreck D, Fritz J, Wolf KJ, et al. Arthritis of the finger joints: a comprehensive approach comparing conventional radiography, scintigraphy, ultrasound, and contrast-enhanced magnetic resonance imaging. *Arthritis Rheum* 1999;42:1232–45.
- Klarlund M, Ostergaard M, Gideon P, Sorensen K, Jensen KE, Lorenzen I. Wrist and finger joint MR imaging in rheumatoid arthritis. *Acta Radiol* 1999;40:400–9.
- Klarlund M, Ostergaard M, Rostrup E, Skjodt H, Lorenzen I. Dynamic magnetic resonance imaging of the metacarpophalangeal joints in rheumatoid arthritis, early unclassified polyarthritis, and healthy controls. *Scand J Rheumatol* 2000;29:108–15.
- Wakefield RJ, Gibbon WW, Conaghan PG, O'Connor P, McGonagle D, Pease C, et al. The value of sonography in the detection of bone erosions in patients with rheumatoid arthritis: a comparison with conventional radiography. *Arthritis Rheum* 2000;43:2762–70.
- Bjelle A. Epidemiology of shoulder problems. *Baillieres Clin Rheumatol* 1989;3:437–51.
- Petersson CJ. Painful shoulders in patients with rheumatoid arthritis: prevalence, clinical and radiological features. *Scand J Rheumatol* 1986;15:275–9.
- Larsen A, Dale K, Eek M. Radiographic evaluation of rheumatoid arthritis and related conditions by standard reference films. *Acta Radiol Diagn (Stockh)* 1977;18:481–91.
- Cicchetti DV, Feinstein AR. High agreement but low kappa. II. Resolving the paradoxes. *J Clin Epidemiol* 1990;43:551–8.
- Krummenauer F, Kalden P, Kreitner KF. Cohen's kappa or McNemar's test? A comparison of binary repeated measurements. *Rofo Fortschr Geb Rontgenstr Neuen Bildgeb Verfahr* 1999;171:226–31.
- Babini JC, Gusic SE, Babini SM, Cocco JA. Superolateral erosions of the humeral head in chronic inflammatory arthropathies. *Skeletal Radiol* 1992;21:515–7.
- Burk DL Jr, Karasick D, Mitchell DG, Rifkin MD. MR imaging of the shoulder: correlation with plain radiography. *Am J Roentgenol* 1990;154:549–53.
- Harty MP, Mahboubi S, Meyer JS, Hubbard AM. MRI of the pediatric shoulder: nontraumatic lesions. *Eur Radiol* 1997;7:352–60.
- Jantsch S, Zenz P, Schwagerl W. Radiologic and sonographic screening study of shoulder joints of patients with rheumatoid arthritis. *Z Gesamte Inn Med* 1991;46:512–7.
- Alasaarela E, Suramo I, Tervonen O, Lahde S, Takalo R, Hakala M. Evaluation of humeral head erosions in rheumatoid arthritis: a comparison of ultrasonography, magnetic resonance imaging, computed tomography and plain radiography. *Br J Rheumatol* 1998;37:1152–6.
- Bouffard JA, Lee SM, Dhanju J. Ultrasonography of the shoulder. *Semin Ultrasound CT MR* 2000;21:164–91.
- Van der Heijden GJ. Shoulder disorders: a state-of-the-art review. *Baillieres Best Pract Res Clin Rheumatol* 1999;13:287–309.
- Ostergaard M, Lorenzen I, Henriksen O. Dynamic gadolinium-enhanced MR imaging in active and inactive immunoinflammatory gonarthrosis. *Acta Radiol* 1994;35:275–81.
- Grassi W, Tittarelli E, Pirani O, Avaltroni D, Cervini C. Ultrasound examination of metacarpophalangeal joints in rheumatoid arthritis. *Scand J Rheumatol* 1993;22:243–7.
- Lund PJ, Heikal A, Maricic MJ, Krupinski EA, Williams CS. Ultrasonographic imaging of the hand and wrist in rheumatoid arthritis. *Skeletal Radiol* 1995;24:591–6.
- Klarlund M, Ostergaard M, Jensen KE, Madsen JL, Skjodt H, Lorenzen I, for the TIRA Group. Magnetic resonance imaging, radiography, and scintigraphy of the finger joints: one year follow up of patients with early arthritis. *Ann Rheum Dis* 2000;59:521–8.
- Middleton WD, Edelstein G, Reinus WR, Melson GL, Totty WG, Murphy WA. Sonographic detection of rotator cuff tears. *Am J Roentgenol* 1985;144:349–53.
- Wiener SN, Seitz WH Jr. Sonography of the shoulder in patients with tears of the rotator cuff: accuracy and value for selecting surgical options [see also discussion p. 109–10]. *Am J Roentgenol* 1993;160:103–7.
- Van Holsbeeck MT, Kolowich PA, Eyler WR, Craig JG, Shirazi



- KK, Habra GK, et al. US depiction of partial-thickness tear of the rotator cuff. *Radiology* 1995;197:443–6.
27. Hodler J, Terrier B, von Schulthess GK, Fuchs WA. MRI and sonography of the shoulder. *Clin Radiol* 1991;43:323–7.
  28. Kieft GJ, Dijkmans BA, Bloem JL, Kroon HM. Magnetic resonance imaging of the shoulder in patients with rheumatoid arthritis. *Ann Rheum Dis* 1990;49:7–11.
  29. Alasaarela E, Takalo R, Tervonen O, Hakala M, Suramo I. Sonography and MRI in the evaluation of painful arthritic shoulder. *Br J Rheumatol* 1997;36:996–1000.
  30. Magarelli N, Guglielmi G, Di Matteo L, Tartaro A, Mattei PA, Bonomo L. Diagnostic utility of an echo-contrast agent in patients with synovitis using power Doppler ultrasound: a preliminary study with comparison to contrast-enhanced MRI. *Eur Radiol* 2001;11:1039–46.
  31. Szkudlarek M, Court-Payen M, Strandberg C, Klarlund M, Klausen T, Ostergaard M. Power Doppler ultrasonography for assessment of synovitis in the metacarpophalangeal joints of patients with rheumatoid arthritis: a comparison with dynamic magnetic resonance imaging. *Arthritis Rheum* 2001;44:2018–23.
  32. Bollow M, Braun J, Hamm B, Eggens U, Schilling A, Konig H, et al. Early sacroiliitis in patients with spondyloarthropathy: evaluation with dynamic gadolinium-enhanced MR imaging. *Radiology* 1995;194:529–36.
  33. Bollow M, Fischer T, Reissbauer H, Backhaus M, Sieper J, Hamm B, et al. Quantitative analyses of sacroiliac biopsies in spondyloarthropathies: T cells and macrophages predominate in early and active sacroiliitis. Cellularity correlates with the degree of enhancement detected by magnetic resonance imaging. *Ann Rheum Dis* 2000;59:135–40.
  34. Munk PL, Vellet AD, Levin MF, Bell DA, Harth MM, McCain GA. Intravenous administration of gadolinium in the evaluation of rheumatoid arthritis of the shoulder. *Can Assoc Radiol J* 1993;44:99–106.
  35. Sano A, Itoi E, Konno N, Kido T, Urayama M, Sato K. Cystic changes of the humeral head on MR imaging: relation to age and cuff-tears. *Acta Orthop Scand* 1998;69:397–400.
  36. Needell SD, Zlatkin MB, Sher JS, Murphy BJ, Uribe JW. MR imaging of the rotator cuff: peritendinous and bone abnormalities in an asymptomatic population. *Am J Roentgenol* 1996;166:863–7.
  37. Drossaers-Bakker KW, Kroon HM, Zwinderman AH, Breedveld FC, Hazes JM. Radiographic damage of large joints in long-term rheumatoid arthritis and its relation to function. *Rheumatology (Oxford)* 2000;39:998–1003.
  38. Vojtsek O. Clinical and laboratory findings with regard to early diagnosis of primary chronic polyarthritis. *Beitr Rheum* 1968;13:21–8.

### 3.3. Frühdiagnose und Verlaufsbeurteilung mittels MRT

#### 3.3.1. MRT zur Frühdiagnose der rheumatoiden Arthritis

##### Publikation 5

Eshed I, Feist E, Althoff CE, Hamm B, Konen E, Burmester GR, Backhaus M, **Hermann KG**. Tenosynovitis of the flexor tendons of the hand detected by MRI: An early indicator of rheumatoid arthritis.

Rheumatology 2009 - im Druck.

ISSN: 1462-0324.

99 Patienten mit einer maximalen Beschwerdedauer von 24 Monaten ohne röntgenologische Erosionen an Händen und Füßen wurden mit der Niederfeld-MRT untersucht, um Einflussfaktoren für die Frühdiagnose einer rheumatoiden Arthritis zu detektieren. Neben acht MR-tomographischen Parametern gingen die sieben ACR-Klassifikationskriterien sowie laborchemische Parameter wie Rheumafaktor, Anti-CCP-Antikörper, antinukleäre Antikörper und C-reactives Protein in die Analyse ein. Bei 58 der untersuchten Patienten konnte im weiteren Verlauf die Diagnose einer rheumatoiden Arthritis gestellt werden und bei 41 ausgeschlossen werden. Häufigster MR-tomographischer Befund waren Synovitiden der MCP-Gelenke, welche bei 83 % der RA-Patienten nachweisbar waren. Synovitiden der MCP-Gelenke waren jedoch auch bei 61 % der Nicht-RA-Patienten detektierbar. In 43 % der Patienten mit RA wurden MR-tomographisch Erosionen der MCP-Gelenke nachgewiesen, in 22 % an den Handwurzelgelenken und nur in 3 % an den PIP-Gelenken. Tenosynovitiden der Beugesehnen fanden sich bei 60 % der RA-Patienten, jedoch nur bei 27 % der Nicht-RA-Patienten ( $p = 0,001$ ). Die Ergebnisse wurden mittels schrittweiser logistischer Regressionsanalyse weiter untersucht. Es zeigte sich, dass nur der Nachweis von Tenosynovitiden der Beugesehnen ein starker Prädiktor für die Frühdiagnose einer RA war (Odds Ratio = 4,15). Die Analyse der MR-Parameter zusammen mit den ACR-Kriterien ermittelte die Kombination eines positiven Rheumafaktors (Odds Ratio = 8,72) und von Tenosynovitiden der Beugesehnen im MRT (Odds Ratio = 4,77) als Prädiktoren für die rheumatoide Arthritis. Durch die Kombination dieser beiden Befunde kann die Diagnose einer rheumatoiden Arthritis mit einer Sensitivität von 83 % und einer Spezifität von 63 % in dieser frühen Erkrankungsphase gestellt werden. Die Spezifität dieser diagnostischen Kombination lässt sich durch den Austausch des Rheumafaktors durch Anti-CCP-Antikörper weiter erhöhen, die Spezifität beträgt dann 73 %, die Sensitivität 79 %.

**Rheumatology 2009 – Article in press**

## **Tenosynovitis of the Flexor Tendons of the Hand Detected by MRI: An Indicator of Early Rheumatoid Arthritis.**

Iris Eshed<sup>1</sup>, Eugen Feist<sup>2</sup>, Christian E. Althoff<sup>3</sup>, Bernd Hamm<sup>3</sup>, Eli Konen<sup>1</sup>, Gerd-R. Burmester<sup>2</sup>, Marina Backhaus<sup>2</sup> and Kay-Geert A. Hermann<sup>3</sup>

1 Department of Radiology, Sheba Hospital, Tel Hashomer, Israel

2 Department of Rheumatology and Clinical Immunology, Charité Medical School, Berlin, Germany

3 Department of Radiology, Charité Medical School, Berlin, Germany

### **Corresponding Author / Address for Reprint Requests:**

Kay-Geert A. Hermann, MD

Department of Radiology, Charité University Hospital, Campus Mitte

Charitéplatz 1, 10117 Berlin, Germany

Phone: +49 30 450 627288, Fax: + 49 30 450 527968, Email: kgh@charite.de

### **Keywords:**

rheumatoid arthritis, diagnostic criteria, magnetic resonance imaging, tenosynovitis, early diagnosis

The authors declare no conflict of interest.

### **Abstract**

**OBJECTIVE:** To evaluate the potential of magnetic resonance imaging (MRI) of finger and wrist joints for diagnosing early rheumatoid arthritis (RA). MRI was evaluated as a stand-alone tool and in combination with American College of Rheumatology (ACR) criteria and serum markers such as rheumatoid factor (RF).

**MATERIAL/METHODS:** Ninety-nine patients (31 men, 68 women, median age 46 years) with unspecified arthritis or suspected RA and negative X-ray findings were included. MR images of the hand and wrist of these patients were retrospectively evaluated for the presence of synovitis, erosions and tenosynovitis. The clinical diagnosis (early RA or non-RA) was made by a rheumatologist after clinical follow-up for 6 to 41 months. Clinical and laboratory data were collected from all patients.

**RESULTS:** Fifty-eight patients had a clinical diagnosis of RA and 41 were diagnosed as non-RA. Stepwise logistic regression of all MR parameters evaluated identified tenosynovitis of the flexor tendons to be the most powerful predictor of early RA (sensitivity=60%, specificity=73%). Including ACR criteria in the analysis, positive serum RF and tenosynovitis were the strongest predictors of early RA (sensitivity=83%, specificity=63%). When serum anti-CCP, ANA and CRP were included as additional parameters, anti-CCP and flexor tenosynovitis were the strongest predictors of early RA (sensitivity=79%, specificity=73%).

**CONCLUSIONS:** Flexor tenosynovitis diagnosed by MRI of the hand is a strong predictor of early RA. Combining flexor tenosynovitis on MRI with positive serum anti-CCP or positive RF is an even stronger predictor of early RA.

Rheumatoid arthritis (RA) is a chronic inflammatory disease causing irreversible joint damage and systemic complications. There is growing evidence that therapeutic intervention early in the disease course of RA leads to earlier disease control and less joint damage, thus emphasizing the importance of early diagnosis (1).

The diagnosis of rheumatoid arthritis (RA) is based primarily on clinical findings, and differentiation of early RA from other joint diseases poses a challenge. The joints of the hands are among the first to be affected in RA (2, 3), and therefore conventional radiographs of finger and wrist joints play a significant role in the assessment and diagnosis of patients with RA (4). However, as many as 70 percent of the patients with early RA have no apparent changes on X-rays of the hands (5, 6).

Magnetic resonance imaging (MRI) detects bone erosions and active synovitis long before they become visible on conventional radiographs (7, 8). Some MRI characteristics of RA (9, 10) and differences in MRI appearance between RA and other inflammatory diseases have been published (11, 12). However, the value of MRI findings in diagnosing early RA has been scarcely studied to date (13, 14).

RA has no unique disease-specific clinical, radiological or immunological features; thus no independent gold standard for RA exists. The American College of Rheumatology (ACR) has published revised criteria for RA (4), which are widely used as a gold standard for studies.

The ACR classification criteria have been presented in both a traditional list format and a tree format (4). The traditional list format comprises seven equally valid criteria: morning stiffness, arthritis of three or more joints, arthritis of the hand joints, symmetric arthritis, serum rheumatoid factor, rheumatoid nodules, and conventional radiology findings compatible with RA. At least four criteria from this list must be present to diagnose RA.

The ACR criteria were originally derived from patients with established disease, thus their relevance and predictive power have been doubted for patients with recent onset inflammatory arthritis (15, 16).

While radiographic changes lag behind the disease process, MRI is highly sensitive to early inflammatory and destructive changes in RA (17). Low-field MRI has been shown to be as sensitive and diagnostic as high-field MRI in imaging the extremities of patients with rheumatoid diseases (18-20).

It was shown in a small cohort that the inclusion of MRI in the ACR criteria for RA may contribute to a more accurate diagnosis in patients with suspected RA (21).

In the current study we evaluated the potential of MRI of the finger and wrist joints for the diagnosis of early RA. We searched for specific characteristics of MRI findings that would help in diagnosing early RA in patients with negative X-ray findings. Subsequently, we evaluated the significance of these criteria in combination with the conventional ACR criteria and with serum indicators.

## Materials and Methods

Patients were referred to our institution in a consecutive manner by a university-based rheumatology outpatient department between July 2002 and March 2005. A total of 320 patients agreed to undergo low-field MRI of the fingers and wrist and gave informed consent. The clinical files of these patients as well as their hand anterior-posterior and oblique conventional radiographs were then evaluated retrospectively.

Patients with undifferentiated arthritis or patients with clinically suspected RA at the time of presentation who had no typical findings of RA on conventional radiographs (i.e. no signs of erosions, juxta-articular osteoporosis, etc.) with a maximum disease duration of 24 months were included in this analysis.

Patients with a known clinical diagnosis of RA or a known clinical diagnosis of another form of arthritis were excluded. Also excluded were patients with typical findings for RA on their conventional radiographs and patients with disease duration longer than 24 months.

Ninety-nine patients fulfilled the inclusion criteria (31 men, 68 women; median age 46 years) and their clinical files and MRI examinations were further evaluated. Clinical diagnoses (RA or non-RA) were made by an experienced rheumatologist based on clinical, serological, and radiological data after follow-up of 6 to 41 months. This clinical diagnosis was regarded as the gold standard.

The local ethics committee of the Charité university hospital approved this study and patients' written consent was obtained according to the declaration of Helsinki.

*Data Collection*

Data collected from the patients' files included: demographic information such as age and sex, blood test results at presentation (rheumatoid factor [IgM, measured by ELISA, cut-off 20 IU, ORGENTEC Diagnostika, Mainz, Germany], anticyclic citrullinated peptide antibodies (anti-CCP Ab [second generation ELISA, cut-off 25 IU, EURO-DIAGNOSTICA, Malmoe, Sweden]), antinuclear antibodies (ANA [determined by indirect immunofluorescence on HEp2 cells]), C-reactive protein (CRP), disease duration until presentation, and follow-up period.

*Imaging Procedure*

All examinations were performed with the same low-field-strength dedicated extremity 0.2-Tesla MRI unit (C-scan, Esaote, Genoa, Italy) and the same dedicated, dual phased-array coil as described earlier (22). The more severely affected hand was examined. In patients with symmetric involvement, the right hand was examined.

Briefly, the imaging protocol comprised a coronal short tau inversion recovery (STIR) sequence, a coronal T1-weighted spin echo (SE) sequence, and a coronal three-dimensional T1-weighted gradient-recalled echo (GRE) sequence. Following unenhanced imaging, intravenous injection of 0.2 mmol/kg gadolinium diethylenetriaminepentaacetic acid (Gd-DTPA; Magnevist, Bayer Schering Pharma AG, Berlin, Germany) by an automatic injector (2 ml/sec) was performed. Axial reconstructions of the GRE sequences were then generated. The wrist joints were additionally imaged after contrast injection.

*MRI Evaluation*

MRI examinations of all patients included in the study were evaluated for erosions, synovitis and tenosynovitis by two experienced musculoskeletal radiologists who finally reached an agreement (consensus decision). Images were evaluated for the presence of synovitis and/or erosions of the wrist joints (including the intercarpal joints, the radiocarpal joint, the distal radioulnar joint and the styloid process of ulna), and of the metacarpophalangeal (MCP) and proximal interphalangeal (PIP) joints 2 – 5 as well as for tenosynovitis of the flexor and/or the extensor tendons.

Bone marrow edema was not evaluated as it is known to have low sensitivity using low-field-strength magnets (18).

Since our aim was to determine presence versus absence of pathology without attempting to quantify its severity, scoring for synovitis and erosions according to the OMERACT RAMRIS system (23) or to the recently published scoring system for tenosynovitis (24) was not performed.

*MRI Pathology Definition*

Erosions and synovitis were defined as suggested by the OMERACT group (23). According to these definitions, synovitis is an area in the synovial compartment that shows above-normal enhancement after Gd-DTPA administration of a thickness greater than the width of the normal synovium.

Erosion is defined by the OMERACT group as a sharply marginated bone lesion with correct juxta-articular localization. T1-weighted MR images depict erosion as a low-signal-intensity lesion in at least two planes with cortical disruption seen in at least one plane.

A published and validated definition for tenosynovitis does not exist. Based on the definition of synovitis, we previously defined tenosynovitis as follows: an area adjacent to a tendon with an above-normal Gd-DTPA enhancement and abnormal thickening of the tendon sheath (20).

*ACR Criteria Definitions*

Morning stiffness: Documented self-reported morning stiffness lasting one hour or more.

Arthritis of three or more joint areas: Documented physical examination of the presence of soft tissue swelling in three or more of the following joint areas: right or left proximal interphalangeal joints (PIP), MCP, wrist, elbow, knee and MTP joints.

Arthritis in the joints of the hand: Documented physical examination of the presence of soft tissue swelling in at least one right or left PIP, MCP or wrist joint areas.

Presence of symmetric arthritis: Documented physical examination of the simultaneous presence of soft tissue swelling of the same joint areas on both sides of the body, which need not be exactly symmetric.

Presence of rheumatoid nodules: Documented physical examination of the presence of subcutaneous nodules.

Positive rheumatoid factor: Documented blood sample results using a standardized ELISA with a cut-off of 20 IU for the purpose of this study.

Conventional radiographs compatible with RA: Antero-posterior and lateral-oblique radiographs of both hands and wrists in which erosions or signs of juxta-articular decalcification were detected. Since the study inclusion criteria specified conventional radiographs free of such signs, our study population in general was negative for this criterion.

#### *Statistical Analysis*

Univariate analysis: Fisher's exact test was used to analyze the correlation between the gold standard of the final clinical diagnosis against MR findings of synovitis, erosions and tenosynovitis and ACR criteria for RA.

Multivariate analysis: A stepwise logistic regression analysis of the MR findings alone (synovitis and erosions in the carpal joints, MCP joint and PIP joints as well as tenosynovitis of the flexor or extensor tendons – a total of 8 parameters) of the MR findings in combination with the ACR criteria (all seven criteria and also as a binary fulfilled/not fulfilled ACR criterion), and of the MR findings, ACR criteria and serological results (RF, anti-CCP Ab., ANA, CRP) (covariates) was performed to determine the strength of each finding in predicting diagnosis of early RA. The dependent variable was the gold standard of clinically established RA.

Analyses were performed using SPSS version 11.5 (SPSS INC., Chicago, IL). P-values lower than 0.05 were considered statistically significant.

#### **Results**

Fifty-eight patients had a clinical diagnosis of RA and 41 were diagnosed as non-RA. The final clinical diagnoses for the non-RA patients were: arthritis related to other rheumatic diseases (n=8), osteoarthritis (n=12), arthritis related to viral infection (n=5), reactive arthritis, (n=4), and unclassified self-limiting arthritis (n=12). The patient characteristics are presented in table 1.

In 59 patients the right hand was imaged and in 40 the left hand. Median time between conventional radiography and MRI was  $34 \pm 59$  days (range 8 days – 4 months). MRI findings are summarized in table 2.

Descriptive statistics for the ACR criteria together and separately and for the MRI findings are summarized in table 3.

#### *Logistic Regression Analysis*

Stepwise logistic regression of all MR parameters evaluated showed tenosynovitis of the flexor tendons to be the most powerful early predictor of RA (odds ratio (OR)=4.15,  $p=0.001$ , confidence interval (CI): 1.742–9.890). Sensitivity is 60.3% and specificity 73.2%. This MRI finding of rheumatoid arthritis is illustrated in figure 1. The only other MR finding that was close to statistical significance was synovitis of the MCP joints ( $p=0.077$ ).

The strongest early predictors of RA determined by stepwise logistic regression for ACR criteria and MRI findings in our cohort were positive serum rheumatoid factor (OR=8.72,  $p<0.001$ , CI: 2.811–27.057) and tenosynovitis of the flexor tendons (OR=4.774,  $p=0.001$ , CI: 1.823–12.505). Sensitivity with these factors is 82.8% and specificity 63.4%. No other MRI findings and/or ACR criteria were identified to be predictive markers for RA.

The stepwise logistic regression results of ACR criteria, MRI findings and serum laboratory values of anti-CCP antibodies, anti-nuclear antibodies and CRP revealed the two strongest early predictors of RA to be antibodies against CCP (OR=13.786,  $p=0.001$ , CI: 2.873–66.149) and tenosynovitis of the flexor tendons (OR=4.990,  $p=0.002$ , CI: 1.837–13.555). Sensitivity with these factors is 78.9% and specificity 73%.

The remaining parameters evaluated were not statistically significant.

## Discussion

The ACR criteria for the classification of RA were originally derived from patients with established disease; thus, their relevance and predictive power in patients with recent-onset inflammatory arthritis have been doubted (15, 16). Our cohort included both patients with undifferentiated arthritis and patients with clinically suspected RA. Forty-two percent of this study cohort fulfilled the ACR criteria at presentation. However 27% of patients who fulfilled the ACR criteria were finally diagnosed as non-RA patients, resulting in quite low sensitivity and specificity (52% and 73% respectively) in our cohort of early RA patients. These values are similar to those reported in other studies (15, 16), emphasizing the need for different criteria in patients with early RA. Indeed, a recent meta-analysis of a total of 7438 patients, among them 3883 patients diagnosed as RA based on expert opinion, including 546 patients with early RA, revealed low sensitivity and specificity (both 77%) for the ACR criteria in list format in patients with disease duration of less than one year, while sensitivity and specificity were better (79% and 90%, respectively) in established disease (25).

MRI is an excellent modality for imaging both the anatomy and pathology of the hand joints with a proven higher sensitivity than conventional radiographs (7, 8). Its potential in assisting the diagnosis of early RA is promising but its value as a stand-alone diagnostic tool for this indication remains to be established.

In the current study we analyzed the predictive value of different MRI and clinical parameters for RA established at presentation by comparison with the gold standard diagnosis obtained after a clinical follow-up period. A notable result of our study is the importance of tenosynovitis of the flexor tendons in the early stages of disease for the diagnosis of RA. This parameter was found to be statistically significant in all lines of logistic regression performed. It was the strongest early predictor of RA compared to all other parameters evaluated by MRI. When ACR criteria were added to the logistic regression analysis, only the presence of rheumatoid factor was stronger than tenosynovitis of the flexor tendons for the prediction of RA.

Recently, Wakefield et al. in a cohort of patients with early untreated RA have demonstrated a better sensitivity of MRI compared to ultrasound of the hand for the detection of tenosynovitis (26), underlining the superiority of this method for evaluation of patients with early RA.

Many studies reported flexor tenosynovitis to be a common finding in patients with early RA (9, 27-29); however, to the best of our knowledge, the importance of this finding for diagnosing RA in its early stages has never been reported.

Tenosynovitis, like synovitis of the joints, is thought to result from inflammatory reactions within the tendon's synovial sheath. Apparently, in early arthritis, tenosynovitis of the flexor tendons is more specific for RA than for other disease entities. In a one-year follow-up study of patients with early RA, Lindegaard et al. have also shown that tenosynovitis was present at baseline in the majority of patients with early RA (60%) but was much less common at 6 months (28%). Dactylitis resulting from flexor tenosynovitis is known to occur in psoriatic arthritis and can be of help in diagnosing psoriatic arthritis (30). Schoellnast et al. compared wrist MRI findings of patients with established psoriatic arthritis and patients with established RA (28). These patients differed only by the presence of erosions, while no statistically significant difference was found between the two groups in the frequency of tenosynovitis.

Possibly, adequate treatment of RA has a stronger impact on tenosynovitis than on other arthritic pathologies such as erosions and synovitis. Still, the reason why tenosynovitis of the flexor tendons appears in early RA and then decreases in frequency needs further investigation. A further interesting point for investigation would be the impact of tenosynovitis of the flexor tendon on the diagnosis of RA in the entire group of patients with early arthritis including RA and other diagnoses, with or without changes on conventional radiographs of the hand.

When we added the serum results for anti-CCP Ab, ANA and CRP to the logistic regression analysis, only anti-CCP Ab and flexor tenosynovitis were identified as strong early predictors of RA. The importance of anti-CCP Ab for diagnosing early RA has been extensively reported (31-33). The fact that in our cohort anti-CCP Ab was also the strongest predictor of RA validates our cohort as a representative sample of early RA.

Determination of the odds ratios of the three strongest predictors of RA (tenosynovitis of the flexor tendons, RF and anti-CCP Ab), anti-CCP Ab was identified as the strongest predictor (OR=13.786). Tenosynovitis of the flexor tendons was the weakest of the three (OR=4.990), but its additive value in diagnosing RA was substantial.

A recent study prospectively evaluated the diagnostic performance of hand MRI compared to anti-CCP values in seronegative early RA patients (34). The authors' MRI criterion for RA was the presence of either synovitis with bone erosions or bone marrow edema. The MRI criterion was better than anti-CCP Ab for the diagnosis of early RA with negative RF. These findings again underline a strong correlation between these two serum parameters.

Few studies tried to determine the value of wrist MRI for the diagnosis of early RA. The study populations examined in these studies were similar to ours in that the patients had no findings characteristic of RA on conventional hand radiographs. In a study performed with a low-field magnet (0.5 Tesla), like in the current study, criteria indicative of RA were either erosions or synovitis of the joints in a distribution pattern typical of RA (35). MRI findings in combination with whole-body scintigraphy were found to have quite low sensitivity (45%) and very high specificity (100%) for diagnosing RA.

Other studies used mid-field MRI (1.0-1.5 Tesla), which allows simultaneous examination of both hands. In these studies, a parameter of symmetric synovitis was chosen for the diagnosis of RA (14, 21, 36). Sugimoto et al. used this parameter alone to diagnose early RA in 48 patients. Sensitivity of this parameter for diagnosing RA was 96% and specificity was 86%, much higher than in our study. However, this cohort also had remarkably high sensitivity and specificity for the traditional ACR criteria (69% and 96% respectively). This might imply a different cohort selection. To the best of our knowledge, these results were not reproduced by another study group and the diagnostic value of symmetric synovitis on MR as the only criterion needs further verification.

Tamai et al. presented a brief report of a study that evaluated the impact of MRI findings in combination with serum anti-CCP level (14). The report provides no data on the predictive value of either of the two MRI criteria alone. We therefore assume that, similar to our results, the criteria had lower sensitivities and specificities when used alone. Sensitivity for the combined criteria was 82.5% and specificity 84.8%, which is slightly better than in our study. The role of tenosynovitis for diagnosing early RA was not evaluated by this group.

Our study has some limitations. The retrospective design may have introduced some bias.

The statistical analysis is limited by the small number of patients investigated and the relatively large number of potential predictors analyzed. We tried to overcome these limitations to some extent by using stepwise logistic regression analysis, which eliminates statistically weak variables at the beginning of the analysis and retains only stronger variables. Nevertheless, a larger cohort and a prospective setting are warranted to verify our results.

Bone marrow edema may be an important feature of RA but cannot be evaluated at low field strength (37). The value of bone marrow edema in low-field MRI is an important research question raised by the OMERACT MRI in RA working group (38) A recent multicenter study performed using both low-field and high-field MRI units found bone marrow edema to be the strongest predictor of subsequent radiographic progression in early RA (39). The cohort investigated in this study was different from ours and included only patients who fulfilled the ACR criteria. The authors do not address the low sensitivity of weaker MR units in the detection of bone marrow edema. However, the rather inexpensive low-field extremity MRI units, which are particularly patient friendly, are becoming more and more popular. Evaluation of bone marrow edema will be limited in general in all patients examined on low-field extremity MRI scanners. Another limitation of low-field MRI units is that they do not allow simultaneous imaging of both hands.

Flexor tenosynovitis is a strong early predictor of RA in MRI of the hand. Combining this finding with positive serum anti-CCP values or alternatively with positive RF values yields even stronger early predictors of RA. These results need further prospective investigation in a larger group of patients.

### Key messages

- This is the first study describing the importance of tenosynovitis of flexor tendons as a strong predictor of early rheumatoid arthritis.
- Magnetic resonance imaging findings of the hands in combination with laboratory findings facilitate early diagnosis and treatment in patients with suspected rheumatoid arthritis.
- The use of magnetic resonance imaging as sole diagnostic test irrespective of clinical and laboratory results could not be established.



## References

1. Lard LR, Visser H, Speyer I, vander Horst-Bruinsma IE, Zwinderman AH, Breedveld FC, et al. Early versus delayed treatment in patients with recent-onset rheumatoid arthritis: comparison of two cohorts who received different treatment strategies. *Am J Med* 2001;111(6):446-51.
2. Brook A, Corbett M. Radiographic changes in early rheumatoid disease. *Ann Rheum Dis* 1977;36(1):71-3.
3. Fuchs HA, Kaye JJ, Callahan LF, Nance EP, Pincus T. Evidence of significant radiographic damage in rheumatoid arthritis within the first 2 years of disease. *J Rheumatol* 1989;16(5):585-91.
4. Arnett FC, Edworthy SM, Bloch DA, McShane DJ, Fries JF, Cooper NS, et al. The American Rheumatism Association 1987 revised criteria for the classification of rheumatoid arthritis. *Arthritis Rheum* 1988;31(3):315-24.
5. Klarlund M, Ostergaard M, Jensen KE, Madsen JL, Skjodt H, Lorenzen I. Magnetic resonance imaging, radiography, and scintigraphy of the finger joints: one year follow up of patients with early arthritis. The TIRA Group. *Ann Rheum Dis* 2000;59(7):521-8.
6. van der Heijde DM, van Leeuwen MA, van Riel PL, van de Putte LB. Radiographic progression on radiographs of hands and feet during the first 3 years of rheumatoid arthritis measured according to Sharp's method (van der Heijde modification). *J Rheumatol* 1995;22(9):1792-6.
7. Backhaus M, Burmester GR, Sandrock D, Loreck D, Hess D, Scholz A, et al. Prospective two year follow up study comparing novel and conventional imaging procedures in patients with arthritic finger joints. *Ann Rheum Dis* 2002;61(10):895-904.
8. Backhaus M, Kamradt T, Sandrock D, Loreck D, Fritz J, Wolf KJ, et al. Arthritis of the finger joints: a comprehensive approach comparing conventional radiography, scintigraphy, ultrasound, and contrast-enhanced magnetic resonance imaging. *Arthritis Rheum* 1999;42(6):1232-45.
9. Boutry N, Larde A, Lapegue F, Solau-Gervais E, Flipo RM, Cotten A. Magnetic resonance imaging appearance of the hands and feet in patients with early rheumatoid arthritis. *J Rheumatol* 2003;30(4):671-9.
10. McQueen F, Beckley V, Crabbe J, Robinson E, Yeoman S, Stewart N. Magnetic resonance imaging evidence of tendinopathy in early rheumatoid arthritis predicts tendon rupture at six years. *Arthritis Rheum* 2005;52(3):744-51.
11. Boutry N, Hachulla E, Flipo RM, Cortet B, Cotten A. MR imaging findings in hands in early rheumatoid arthritis: comparison with those in systemic lupus erythematosus and primary Sjogren syndrome. *Radiology* 2005;236(2):593-600.
12. Jevtic V, Watt I, Rozman B, Kos-Golja M, Demsar F, Jarh O. Distinctive radiological features of small hand joints in rheumatoid arthritis and seronegative spondyloarthritis demonstrated by contrast-enhanced (Gd-DTPA) magnetic resonance imaging. *Skeletal Radiol* 1995;24(5):351-5.
13. Ostergaard M, Duer A, Horslev-Petersen K. Can magnetic resonance imaging differentiate undifferentiated arthritis? *Arthritis Res Ther* 2005;7(6):243-5.
14. Tamai M, Kawakami A, Uetani M, Takao S, Rashid H, Tanaka F, et al. Early prediction of rheumatoid arthritis by serological variables and magnetic resonance imaging of the wrists and finger joints: results from prospective clinical examination. *Ann Rheum Dis* 2006;65(1):134-5.
15. Harrison BJ, Symmons DP, Barrett EM, Silman AJ. The performance of the 1987 ARA classification criteria for rheumatoid arthritis in a population based cohort of patients with early inflammatory polyarthritis. American Rheumatism Association. *J Rheumatol* 1998;25(12):2324-30.
16. Saraux A, Berthelot JM, Chales G, Le Henaff C, Thorel JB, Hoang S, et al. Ability of the American College of Rheumatology 1987 criteria to predict rheumatoid arthritis in patients with early arthritis and classification of these patients two years later. *Arthritis Rheum* 2001;44(11):2485-91.
17. Ostergaard M, Ejbjerg B, Szkudlarek M. Imaging in early rheumatoid arthritis: roles of magnetic resonance imaging, ultrasonography, conventional radiography and computed tomography. *Best Pract Res Clin Rheumatol* 2005;19(1):91-116.

18. Ejbjerg BJ, Narvestad E, Jacobsen S, Thomsen HS, Ostergaard M. Optimised, low cost, low field dedicated extremity MRI is highly specific and sensitive for synovitis and bone erosions in rheumatoid arthritis wrist and finger joints: comparison with conventional high field MRI and radiography. *Ann Rheum Dis* 2005;64(9):1280-7.
19. Savnik A, Malmskov H, Thomsen HS, Bretlau T, Graff LB, Nielsen H, et al. MRI of the arthritic small joints: comparison of extremity MRI (0.2 T) vs high-field MRI (1.5 T). *Eur Radiol* 2001;11(6):1030-8.
20. Schirmer C, Scheel AK, Althoff CE, Schink T, Eshed I, Lembcke A, et al. Diagnostic quality and scoring of synovitis, tenosynovitis and erosions in low-field MRI of patients with rheumatoid arthritis: a comparison with conventional MRI. *Ann Rheum Dis* 2007;66(4):522-9.
21. Sugimoto H, Takeda A, Hyodoh K. Early-stage rheumatoid arthritis: prospective study of the effectiveness of MR imaging for diagnosis. *Radiology* 2000;216(2):569-75.
22. Eshed I, Althoff CE, Schink T, Scheel AK, Schirmer C, Backhaus M, et al. Low-field MRI for assessing synovitis in patients with rheumatoid arthritis. Impact of Gd-DTPA dose on synovitis scoring. *Scand J Rheumatol* 2006;35(4):277-82.
23. Ostergaard M, Peterfy C, Conaghan P, McQueen F, Bird P, Ejbjerg B, et al. OMERACT Rheumatoid Arthritis Magnetic Resonance Imaging Studies. Core set of MRI acquisitions, joint pathology definitions, and the OMERACT RA-MRI scoring system. *J Rheumatol* 2003;30(6):1385-6.
24. Haavardsholm EA, Ostergaard M, Ejbjerg BJ, Kvan NP, Kvien TK. Introduction of a novel magnetic resonance imaging tenosynovitis score for rheumatoid arthritis: reliability in a multireader longitudinal study. *Ann Rheum Dis* 2007;66(9):1216-20.
25. Banal F, Dougados M, Combescure C, Gossec L. Sensitivity and specificity of the American College of Rheumatology 1987 criteria for the diagnosis of rheumatoid arthritis according to disease duration: a systematic literature review and meta-analysis. *Ann Rheum Dis* 2008.
26. Wakefield RJ, O'Connor PJ, Conaghan PG, McGonagle D, Hensor EM, Gibbon WW, et al. Finger tendon disease in untreated early rheumatoid arthritis: a comparison of ultrasound and magnetic resonance imaging. *Arthritis Rheum* 2007;57(7):1158-64.
27. Lindegaard HM, Vallo J, Horslev-Petersen K, Junker P, Ostergaard M. Low-cost, low-field dedicated extremity magnetic resonance imaging in early rheumatoid arthritis: a 1-year follow-up study. *Ann Rheum Dis* 2006;65(9):1208-12.
28. Schoellnast H, Deutschmann HA, Hermann J, Schaffler GJ, Reittner P, Kammerhuber F, et al. Psoriatic arthritis and rheumatoid arthritis: findings in contrast-enhanced MRI. *AJR Am J Roentgenol* 2006;187(2):351-7.
29. Treitl M, Panteleon A, Korner M, Becker-Gaab C, Reiser M, Wirth S. [Soft tissue manifestations of early rheumatic disease: imaging with MRI]. *Radiologe* 2006;46(8):677-80, 682-8.
30. Olivieri I, Padula A, Scarano E, Scarpa R. Dactylitis or "sausage-shaped" digit. *J Rheumatol* 2007;34(6):1217-22.
31. Meyer O, Nicaise-Roland P, Santos MD, Labarre C, Dougados M, Goupille P, et al. Serial determination of cyclic citrullinated peptide autoantibodies predicted five-year radiological outcomes in a prospective cohort of patients with early rheumatoid arthritis. *Arthritis Res Ther* 2006;8(2):R40.
32. Quinn MA, Gough AK, Green MJ, Devlin J, Hensor EM, Greenstein A, et al. Anti-CCP antibodies measured at disease onset help identify seronegative rheumatoid arthritis and predict radiological and functional outcome. *Rheumatology (Oxford)* 2006;45(4):478-80.
33. Tamai M, Kawakami A, Uetani M, Takao S, Tanaka F, Nakamura H, et al. The presence of anti-cyclic citrullinated peptide antibody is associated with magnetic resonance imaging detection of bone marrow oedema in early stage rheumatoid arthritis. *Ann Rheum Dis* 2006;65(1):133-4.
34. Narvaez J, Sirvent E, Antonio Narvaez J, Bas J, Gomez-Vaquero C, Reina D, et al. Usefulness of Magnetic Resonance Imaging of the Hand versus Anticyclic Citrullinated Peptide Antibody Testing to Confirm the Diagnosis of Clinically Suspected Early Rheumatoid Arthritis in the Absence of Rheumatoid Factor and Radiographic Erosions. *Semin Arthritis Rheum* 2008.
35. Duer A, Ostergaard M, Horslev-Petersen K, Vallo J. Magnetic resonance imaging and bone scintigraphy in the differential diagnosis of unclassified arthritis. *Ann Rheum Dis* 2008;67(1):48-51.

36. Sugimoto H, Takeda A, Masuyama J, Furuse M. Early-stage rheumatoid arthritis: diagnostic accuracy of MR imaging. *Radiology* 1996;198(1):185-92.
37. McQueen FM. A vital clue to deciphering bone pathology: MRI bone oedema in rheumatoid arthritis and osteoarthritis. *Ann Rheum Dis* 2007;66(12):1549-52.
38. Ostergaard M, McQueen FM, Bird P, Ejbjerg B, Lassere MN, Peterfy CG, et al. Magnetic resonance imaging in rheumatoid arthritis advances and research priorities. *J Rheumatol* 2005;32(12):2462-4.
39. Hetland ML, Ejbjerg BJ, Horslev-Petersen K, Jacobsen S, Vestergaard A, Jurik AG, et al. MRI bone oedema is the strongest predictor of subsequent radiographic progression in early rheumatoid arthritis. Results from a 2 year randomized controlled trial (CIMESTRA). *Ann Rheum Dis* 2008.

## Tables

**Table 1:** Cohort characteristics

	Total (n=99)	RA (n=58)	Non-RA (n=41)
Sex [female/male]	68 / 31	15/43	15/26
Median age (range) [years]	46 (17-65)	48 (17-65)	47 (17-65)
Median disease duration (range) [months]	6 (1-24)	6 (1-24)	6 (1-24)
Median follow-up period (range) [months]	8 (6-41)	8 (6-41)	9 (6-41)
Fulfilling ACR criteria	42%	50%	27%
Positive RF	35%	50%	12%
Positive anti-CCP	26%	41%	5%
Median CRP (range) [mg/dl]	1 (0-27)	1 (0-27)	1 (0-27)
Median ANA titer (range)	80 (0-5120)	80 (0-5120)	80 (0-5120)

**Table 2:** Distribution of MRI findings (n=99)

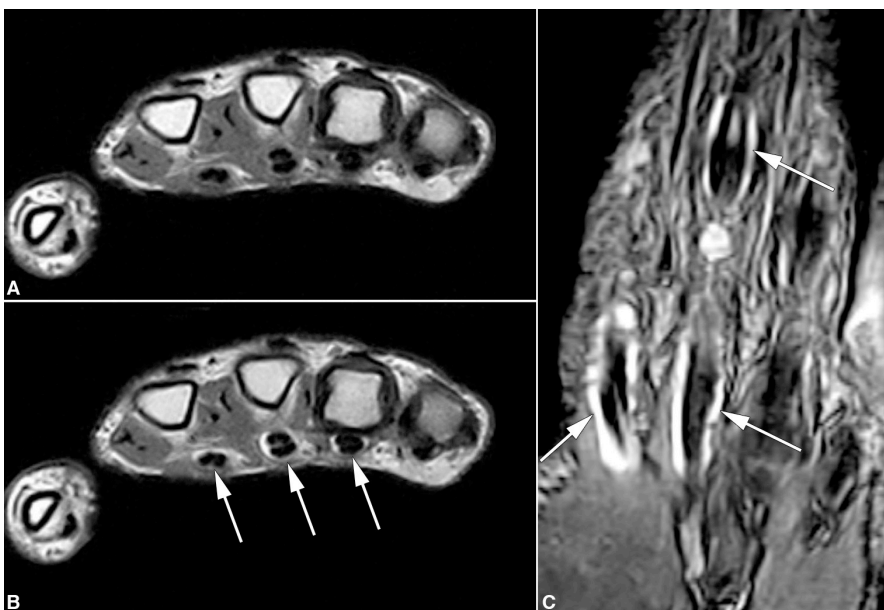
	Total	RA (n=58)	Non-RA (n=41)	p-value*
<b>Synovitis</b>				
Carpal joints	33	21 (36%)	12 (29%)	0.522
MCP joints	83	48 (83%)	25 (61%)	0.021*
PIP joints	55	37 (64%)	18 (44%)	0.065
<b>Erosions</b>				
Carpal joints	19	13 (22%)	6 (14%)	0.439
MCP joints	36	25 (43%)	11 (27%)	0.137
PIP joints	3	2 (3%)	1 (2%)	1.0
<b>Tenosynovitis</b>				
Flexor tendons	46	35 (60%)	11 (27%)	0.001*
Extensor tendons	15	14 (24%)	5 (12%)	0.196

\* p values were calculated using Fisher's exact test

**Table 3:** Descriptive statistics

	Sensitivity	Specificity	PPV	NPV	Accuracy
<b>ACR Criteria</b>	52%	73%	73%	52%	61%
Morning stiffness	52%	56%	62%	45%	53%
Arthritis $\geq$ 3 joints	78%	41%	65%	57%	62%
Arthritis of hand joints	95%	17%	62%	70%	62%
Symmetric arthritis	60%	58%	67%	51%	60%
Serum RF	52%	88%	86%	56%	67%
Rheumatoid nodule	3%	100%	100%	42%	43%
<b>MRI Synovitis</b>					
Carpal joints	36%	71%	63%	44%	50%
MCP joints	83%	39%	66%	61%	64%
PIP joints	64%	56%	67%	52%	61%
<b>MRI Erosions</b>					
Carpal joints	22%	85%	68%	44%	48%
MCP joints	43%	73%	69%	48%	55%
PIP joints	3%	98%	67%	42%	42%
<b>MRI Tenosynovitis</b>					
Flexor tendons	60%	73%	76%	57%	66%
Extensor tendons	24%	88%	74%	54%	38%

\* 7<sup>th</sup> ACR criterion (presence of x-ray changes) not included since all patients studied had no x-ray changes by definition.

**Figure 1**

MRI examination of a 38-year-old woman (finger swelling for 6 months, C-reactive protein 0.3 mg/dl). Unenhanced (A) and gadolinium-enhanced (B) transverse spin echo images as well as gadolinium-enhanced coronal gradient echo image (C) showing severe tenosynovitis of the 2nd to 4th rays at the level of the metacarpophalangeal joints and proximal interphalangeal joints (arrows).

### 3.3.2. MRT zur Langzeitverlaufsbeurteilung

#### Publikation 6

Scheel AK\*, **Hermann KG\***, Ohrndorf S, Werner C, Schirmer C, Detert J, Bollow M, Hamm B, Müller GA, Burmester GR, Backhaus M.

Prospective long term follow-up imaging study comparing radiography, ultrasonography and magnetic resonance imaging in rheumatoid arthritis finger joints.

Ann Rheum Dis 2006;65:595–600.

<http://ard.bmj.com/cgi/reprint/65/5/595.pdf> – ISSN: 0003-4967, DOI 10.1136/ard.2005.041814

16 Patienten (11 Frauen und 5 Männer mit einem Durchschnittsalter von 58,6 Jahren, Altersspanne 27 – 75 Jahre), welche zu diesem Zeitpunkt oder in der Vergangenheit mit langsamwirkenden Antirheumatika (Disease-modifying antirheumatic drugs – DMARDs) behandelt worden sind, wurden in eine Verlaufsbeobachtung der RA-Progression über sieben Jahre eingeschlossen worden. Die mittlere Erkrankungsdauer betrug 14,7 Jahre. 1996 erfolgte die erste Untersuchung und unter ähnlichen Bedingungen fand im Jahr 2003 die Verlaufskontrolle statt.

Die Ergebnisse zeigten eine statistisch signifikante Reduktion der Synovitis von 63 % (80 Gelenke Baseline) auf 41 % (53 Gelenke Follow-up) nach sieben Jahren.

Die Anzahl der Erosionen an den Fingergelenken nahm zu, jedoch ohne statistische Signifikanz ( $p = 0,2$ ). Von 34 (27 %) betroffenen Gelenken bei der Erstuntersuchung stieg die Zahl der Erosionen auf 41 (32 %) bei der Folgeuntersuchung sieben Jahre später.

\* Gleichwertiger Beitrag beider Autoren zur Studie.

## EXTENDED REPORT

# Prospective 7 year follow up imaging study comparing radiography, ultrasonography, and magnetic resonance imaging in rheumatoid arthritis finger joints

A K Scheel\*, K-G A Hermann\*, S Ohrndorf, C Werner, C Schirmer, J Detert, M Bollow, B Hamm, G A Müller, G R Burmester, M Backhaus



*Ann Rheum Dis* 2006;**65**:595–600. doi: 10.1136/ard.2005.041814

See end of article for authors' affiliations

Correspondence to:  
Dr A K Scheel, Department of Medicine, Nephrology and Rheumatology, Robert-Koch-Strasse 40, D-37075 Göttingen, Germany; ascheel@gwdg.de

Accepted  
26 September 2005  
Published Online First  
28 September 2005

**Objective:** To perform a prospective long term follow up study comparing conventional radiography (CR), ultrasonography (US), and magnetic resonance imaging (MRI) in the detection of bone erosions and synovitis in rheumatoid arthritis (RA) finger joints.

**Methods:** The metacarpophalangeal and proximal interphalangeal joints II–V (128 joints) of the clinically dominant hand of 16 patients with RA were included. Follow up joint by joint comparisons for erosions and synovitis were made.

**Results:** At baseline, CR detected erosions in 5/128 (4%) of all joints, US in 12/128 (9%), and MRI in 34/128 (27%). Seven years later, an increase of joints with erosions was found with CR (26%), US (49%) ( $p < 0.001$  each), and MRI (32%, NS). In contrast, joint swelling and tenderness assessed by clinical examination were decreased at follow up ( $p = 0.2$ ,  $p < 0.001$ ). A significant reduction in synovitis with US and MRI ( $p < 0.001$  each) was seen. In CR, 12 patients did not have any erosions at baseline, while in 10/12 patients erosions were detected in 25/96 (26%) joints after 7 years. US initially detected erosions in 9 joints, of which two of these joints with erosions were seen by CR at follow up. MRI initially found 34 erosions, of which 14 (41%) were then detected by CR.

**Conclusion:** After 7 years, an increase of bone erosions was detected by all imaging modalities. In contrast, clinical improvement and regression of synovitis were seen only with US and MRI. More than one third of erosions previously detected by MRI were seen by CR 7 years later.

Accurate assessment of disease activity and joint damage in rheumatoid arthritis (RA) is important for monitoring treatment efficiency and for predicting outcome of the disease. This requires sensitive imaging methods for detection and monitoring of the disease process.

Of all imaging modalities, conventional radiography (CR) has the best established role in identifying progressive joint damage in RA. However, it has long been recognised that CR is insensitive in detecting soft tissue lesions—for example, synovitis, and usually does not detect early erosive lesions.<sup>1–3</sup> Magnetic resonance imaging (MRI) has shown strength in detecting early inflammatory changes.<sup>4–6</sup> However, MRI is expensive and the need for contrast agents to detect active synovitis has meant that MRI has become not a general imaging modality but a problem solving tool in the diagnostic management of RA.<sup>7</sup> Recent technological advances have made musculoskeletal ultrasonography (US) a promising tool for the assessment of patients with rheumatic diseases, with strengths in visualising soft tissue inflammatory processes<sup>8–11</sup> and early bone erosions<sup>1–3, 12</sup> in different joints; however, validation studies to assess reader dependability are still needed.<sup>13</sup>

Validity measures for US in RA have recently been summarised. They concluded that further determination of its discriminant validity and reproducibility is still needed.<sup>13</sup> In particular, further longitudinal data on musculoskeletal US are needed.<sup>13</sup> Up to now, the course of US bone erosions have been followed systematically only by Backhaus *et al.*<sup>2</sup> In 49 patients with various arthritides, MRI, US, and CR

\* Both authors contributed equally to this study.

findings for the clinically dominant hand were analysed at baseline and after 2 years. MRI and US signs of synovitis decreased, whereas the number of bone erosions detected by MRI and US increased. More patients showed erosive progression with US than with CR, suggesting that US has a higher sensitivity to change. To contribute to validity studies for the evaluation of longitudinal imaging data in musculoskeletal US we decided to re-examine patients with RA who were available after 7 years with all imaging techniques previously used.

We present the first long term data comparing clinical examination (CE), CR, US, and MRI in the detection of bone erosions and synovitis in finger joints of a small cohort of patients, including 16 patients with RA. An additional aim was to monitor erosions by different imaging modalities during treatment with disease modifying antirheumatic drugs (DMARDs) and to determine whether radiographically occult finger joint erosions—previously detected by US and MRI—would be seen by CR 7 years later.

## PATIENTS AND METHODS

Sixteen patients with RA (11 women, 5 men, mean age 58.6 years, range 27–75) according to the American College of Rheumatology criteria<sup>14</sup> were included in the study. All

**Abbreviations:** CE, clinical examination; CR, conventional radiography; CRP, C reactive protein; DMARDs, disease modifying antirheumatic drugs; ESR, erythrocyte sedimentation rate; MCP, metacarpophalangeal; MRI, magnetic resonance imaging; OMERACT, Outcome Measures in Rheumatology (working group); PIP, proximal interphalangeal; RA, rheumatoid arthritis; US, ultrasonography

patients were recruited from the Rheumatological Outpatient Clinic, Department of Rheumatology and Clinical Immunology, Charité University Hospital Berlin. Their mean disease duration was 14.7 years. All patients had been or were being treated with DMARDs (methotrexate: all patients, additionally sulfasalazine one patient, leflunomide one patient). Serum measures of inflammation (erythrocyte sedimentation rate (ESR), and C reactive protein (CRP)) were assessed in all patients.

All patients underwent follow up assessment in the same way as 7 years ago (in 1996), as described by Backhaus *et al.*<sup>1</sup> CE, US, CR, and MRI were performed of the clinically dominant hand (right hand = 10, left hand = 6) and included in the analysis. Proximal interphalangeal (PIP) and metacarpophalangeal (MCP) joints II–V were selected for evaluation (eight joints; total 128 joints). Follow up comparisons for the presence of erosions and synovitis were performed joint by joint. All evaluations were performed blinded to baseline results and to the other imaging result. Owing to the technical progress over 7 years, it was not possible to perform the examinations with the same imaging devices. Both CE and imaging studies were performed on the same day at follow up.

For CE, special care was taken in the clinical examination of the PIP and MCP joints. A binary scoring system was used to assess each joint as normal (0) or abnormal (1) for joint tenderness and soft tissue swelling. CE was performed by two experienced examiners (JD, AKS).

The study was approved by the local ethics committee. All patients gave their written informed consent before investigation.

### Imaging methods

#### Conventional radiography

CR of the hands was obtained in two planes. The presence of erosions was recorded for each joint and graded as normal (0) or abnormal (1), as described by Backhaus *et al.*<sup>1</sup>

#### Ultrasonography

US was performed at baseline (in 1996) and follow up (in 2003) with two different imaging devices owing to technical progress.

At baseline, a 7.5 MHz linear array transducer in combination with an acoustic standoff (silicone) was used for better focusing (Ultramark 4, ATL, Bothell, USA), as described in detail by Backhaus *et al.*<sup>1</sup> At follow up, a 10–5 MHz hockey-stick linear array transducer without acoustic standoff was used (ATL, HDI 3500, Bothell, USA).

PIP and MCP finger joints II–V were examined in longitudinal and transverse planes from dorsal and palmar views with the hand in a neutral position. Radial and ulnar views were not carried out at baseline. These views were used at follow up, but not taken into account for direct joint by joint comparisons. Erosions were defined as an interruption of the bone surface visible in two planes. In US, two criteria of inflammation were evaluated: joint effusion was visible as a black, anechoic area, and thickening of the synovial membrane (synovial proliferation) was visualised by US as hypo- or hyperechoic structures within the region affected by effusion. In the following, both phenomena are described as “synovitis”. All findings were also graded as normal (0) or abnormal (1).

US images were evaluated by one experienced examiner at baseline (MB), while at follow up two experienced examiners (AKS, MB) reached consensus for the erosion and synovitis evaluation. In a former study, both examiners reached high interreader agreement with a  $\kappa$  value of 0.88 and 0.93.<sup>15</sup> The investigators were unaware of the clinical findings. Readers were blinded to baseline results.

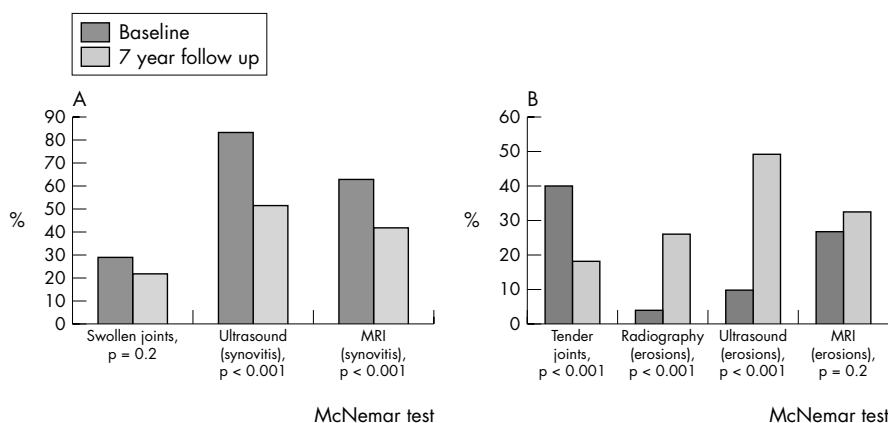
#### Magnetic resonance imaging

MRI of the clinically dominant hand was performed at baseline (in 1996) and follow up (in 2003) with two different imaging devices:

The baseline examination was performed with a 0.2 Tesla imaging device (Magnetom Open, Siemens, Erlangen, Germany) with the patients in sitting position and using a small flex coil. Three dimensional (3D) T<sub>1</sub> weighted gradient echo sequences were obtained before and after intravenous injection of gadodiamide (Gd-DTPA (Omniscan; Nycomed, Oslo, Norway) at a dose of 0.3 mmol/kg of body weight. At follow up MRI was performed with a 0.2 Tesla Esaote unit (Esaote C-Scan, Genoa, Italy). The protocol called for a T<sub>1</sub> weighted 3D gradient echo sequence in coronal slice orientation before and after administration of gadolinium diethylenetriamine pentaacetic acid (Magnevist; Schering AG, Berlin, Germany) at a dose of 0.2 mmol/kg body weight. Reconstructions in transverse section orientation were made.

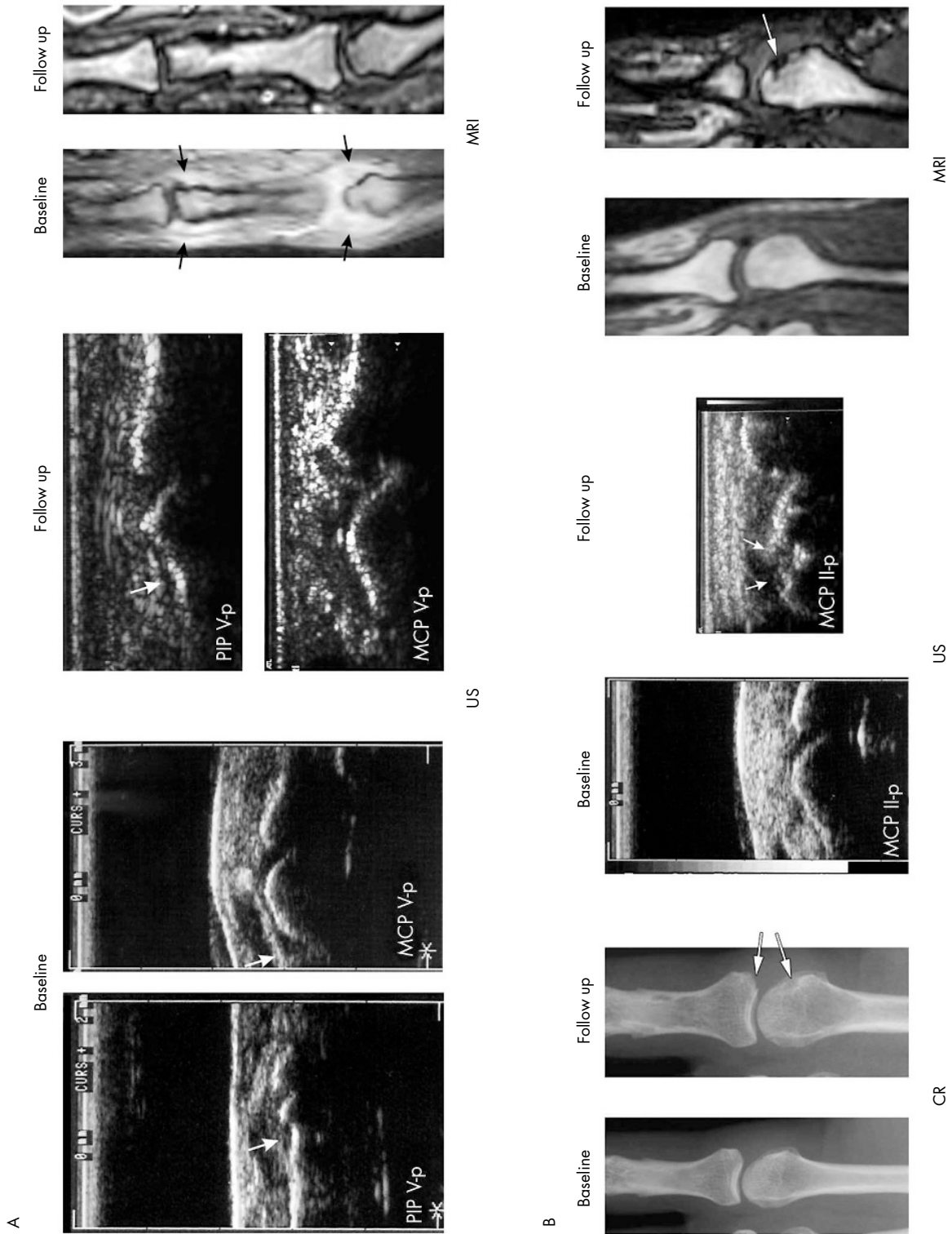
An erosive joint lesion was defined as a joint related cortical defect with or without a decrease in the signal intensity of the adjacent subchondral bone marrow on precontrast T<sub>1</sub> weighted images. To determine synovitis, MR images were evaluated using the definition as recommended by the OMERACT MRI in RA working group.<sup>6, 16</sup>

For further evaluation, the number of erosions and the presence of synovitis were determined for each joint and



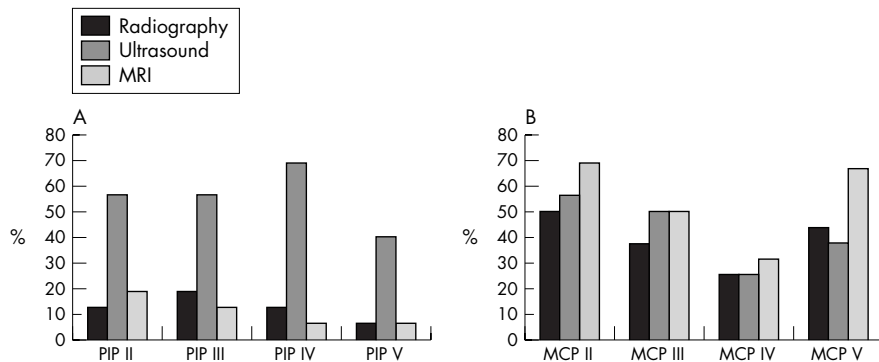
**Figure 1** (A) Detection of soft tissue lesions (synovitis/effusion) by CE, US, and MRI in 128 finger joints. (B) Detection of development in bone erosions by US, CR, and MRI in 128 finger joints.





**Figure 2** (A) MRI and US show marked synovitis at MCP and PIP joints V at baseline (arrows). At follow up after 7 years no synovitis is present at MCP and PIP joints V with MRI, whereas minimal synovitis can be seen at PIP joint V with US. (B) Images of the same MCP II joint at baseline and follow up visit with three different imaging techniques. In radiography, there is no erosion at baseline, while there is an irregularity at the 7 year follow up (arrows). In US and MRI there are no erosions detectable at baseline, while there are clear erosions at the follow up visit.





**Figure 3** Distribution of the detection of erosions (in %) by the different imaging modalities at follow up examination in (A) PIP joints, (B) MCP joints.

graded as either normal (0) or abnormal (1), as described in our previous study.<sup>2</sup>

Two experienced investigators analysed CR (K-GAH, MBo) and MRI (K-GAH, MBo) and reached consensus for erosion and synovitis. The investigators were unaware of the clinical findings and results of the respective other imaging modalities. Readers were blinded to baseline results. There were at least 3 months between the readings for CR and MRI.

#### Statistical analysis

The data were analysed by non-parametric methods. The McNemar test was used to analyse differences between the imaging modalities. All analyses were calculated with the standard software package Statistica (Tulsa, Oklahoma (USA)).

### RESULTS

#### Clinical examination

A reduction in swollen joints was seen by CE (from 37 to 28 joints), however it was not significant ( $p = 0.2$ ) (fig 1A). CE tenderness showed a significant decrease from 51 (40%) tender joints at baseline to 23 (18%) at follow up ( $p < 0.001$ ) (fig 1B).

Comparing baseline and follow up visit, we saw a reduction of serum measures of inflammation: mean (SD) ESR decreased from 27.7 (15.7) mm/1st h (baseline) to 23.8 (15.4) mm/1st h (follow up), CRP decreased from 26.8 (26.8) mg/l to 0.65 (0.66) mg/l ( $p < 0.001$ ), indicating a more active disease at the baseline visit.

#### Imaging techniques

##### Synovitis

We saw a significant reduction in synovitis with US with a decrease in synovitis from 106 joints (83%, baseline) to 66 joints (52%, follow up examination;  $p < 0.001$ ). In agreement with US, a significant reduction in synovitis evaluation could also be detected by MRI (baseline 80 joints = 63%, follow up 53 joints = 41%,  $p < 0.001$ ).

##### Erosions

An increase in the detection of erosions was seen by all imaging techniques (CR, US, and MRI). At baseline, 5/128 (4%) joints with erosions were detected by CR; 7 years later, a significant increase of joints with erosions was found with radiography (33 joints = 26%;  $p < 0.001$ ). At baseline, 12 (9%) of all finger joints with erosions were detected by US with a significant increase to 62 affected joints (49%) at follow up examination ( $p < 0.001$ ) (fig 1B). Thirty four (27%) finger joints had erosions at baseline when examined by MRI (fig 1B). An increase was also detected by MRI to 41 (32%) joints, which was, however, not significant compared with

baseline visit ( $p = 0.2$ ). There were no significant differences of imaging data between the patients receiving methotrexate alone as compared with the patients who additionally received sulfasalazine or leflunomide.

Figures 2A and B show images of the course of synovitis and erosions with the different imaging techniques.

In a next step, we evaluated whether radiographically occult finger joint erosions, previously detected by US and MRI, would be seen by CR 7 years later: At baseline, erosions were not visible in 12/16 patients by CR. After 7 years, in 10/12 (83%) patients erosions were detected by CR in 25/96 (26%) joints. US initially detected erosions in 9/96 (9%) joints, of which two (22%) erosions were seen in CR at follow up. MRI found 34 erosions at baseline, of which 14 (41%) erosions were then detected in CR at follow up.

#### Distribution in the PIP and MCP joints

US was sensitive for the detection of very small fluid accumulations and proved better than MRI, especially in the PIP joints. Figures 3A and B show the distribution of erosions for the PIP and MCP joints II–V visualised by the three different imaging techniques. Interestingly, US detected far more erosions in PIP joints than MRI and even CR. For MCP joints, most erosions were detected by MRI, while US and CR detected fewer erosions. The distribution of finger joints affected shows that MCP IV was less often affected than MCP II, III, and V.

### DISCUSSION

MRI is an established imaging technique for the detection of early inflammatory changes in RA joints.<sup>17</sup> Musculoskeletal US is a rapidly emerging technique, especially for the detection of soft tissue lesions in inflammatory rheumatoid diseases.<sup>13–18</sup> Several studies have proved the ability of US and MRI in the sensitive detection of synovitis and early erosive lesions,<sup>12–19–21</sup> which is of major importance in the early treatment of RA. However, with the exception of a 2 year follow up study involving mainly RA and psoriatic arthritis finger joints<sup>2</sup> there are no longitudinal long term data for US, while MRI has been proved to be sensitive for the follow up analysis of bone damage.<sup>22–23</sup> No data on the importance of US findings for later radiographic or functional status are available (that is, the prognostic value of US in RA is unknown).<sup>13</sup> Some indirect support for a predictive value of US is provided by the high agreement with MRI findings.<sup>1–2–11–24</sup>

In this study we collected the first long term data comparing CR, US, and MRI for the detection of bone erosions and synovitis in RA finger joints. During long term DMARD treatment we saw a significant reduction of synovitis with both US and MRI, but the reduction was

more evident with US. In CE a reduction of finger joint swelling was also assessed, although CE seemed clearly to underestimate the presence of synovitis in RA joints, which was also shown in previous studies.<sup>1 24 25</sup> US was sensitive for the detection of very small fluid accumulations and proved better than MRI, especially in the PIP joints, which might explain the slightly higher percentage of joints affected by synovitis which were detected by US.

Follow up analysis of finger joint synovitis is an important task in controlling the effectiveness of treatment. However, for long term outcome, a precise analysis of erosions is essential. Although we saw a decrease in synovitis during long term DMARD treatment, we found an increase of finger joints with erosions with all imaging techniques. The difference between baseline and 7 year follow up was highly significant as detected by CR and US, but there was no significant difference with MRI between both time points.

A possible reason for the small number of erosions detected by US at baseline is the distinct difference in the quality of the US devices (fig 2). With a significantly lower resolution and the need to use an acoustic standoff pad it is likely that US missed a number of erosions at baseline. Also, it should be mentioned that neither ulnar nor radial aspects of the joints were evaluated by US, raising the possibility that some erosions might have been missed. A high number of erosions were already detected at baseline visit by MRI<sup>1</sup> and owing to our binary evaluation system no statistically significant further progression of MRI erosions was shown because of a ceiling effect (truncation of data because a score of 1 could not progress further as it is already the highest possible score),<sup>26</sup> which may help to explain our current results. Although it could be shown that low field MRI (0.2 Tesla) has similar sensitivities for bone erosions to those obtained with 1.5 Tesla MRI devices,<sup>27</sup> a better detection of bone erosions might have been achieved by using higher field MRI (>0.2 Tesla) devices.

The selection of patients with established disease (mean disease duration 14.7 years) might have had an impact on the study outcome. Our data are in agreement with the 2 year follow up study,<sup>2</sup> which recorded an increase of erosions with clinical improvement and regression of synovitis, but now more pronounced with MRI than with US. An increase in erosions in the wrist as detected by MRI despite clinical improvement was also described by McQueen *et al.*<sup>23</sup>

Another aim of our study was to determine whether radiographically occult finger joint erosions, previously detected by US and MRI, would be detected by CR 7 years later. Nearly every second erosion previously detected by MRI presented on CR 7 years later, showing that erosions could actually be predicted by MRI. The reason why not all formerly detected erosions were seen later in the disease course by CR might be explained by healing processes, reader error, and technical limitations of x ray procedures.<sup>28</sup> US initially detected erosions in nine joints, of which two erosions were seen in radiography at follow up. Again, we explain this rather low percentage of erosions at baseline by the low quality of the US images 7 years ago. However, another explanation lies in the fundamental difference in the way in which CR and MRI generate image contrast. This is outlined by Peterfy,<sup>29</sup> but basically, the lucency associated with erosions on radiographs is due to the loss of cortical bone, not trabecular bone. CR is quite insensitive to trabecular bone loss. Consequently, the often larger intramedullary component of an erosion is typically not visible on radiographs. MRI, however, provides excellent delineation of abnormalities in the marrow space, and therefore can detect even large intramedullary erosions that are radiographically occult. Many of these erosions may not become detectable on radiographs even after many years.

For MCP joints, more erosions were detected by MRI than by US and CR. The distribution of finger joint erosions shows that MCP IV is less often affected than MCP II, III, and V, as also described by Wakefield *et al.*<sup>3</sup> Interestingly, we saw a more frequent and distinct affection of PIP compared with MCP joints by US than by CR and MRI, which is in agreement with recently presented data.<sup>30 31</sup> This underlines the importance of potentially including PIP joints in common scoring systems both for US and MRI—for example, the RA-MRI scoring system developed by the OMERACT MRI in an RA working group.<sup>32</sup>

US has some advantages over MRI, because it is easier to perform examinations of all finger joints with US, although documentation is time consuming. In MRI examinations, especially in the dedicated systems which we used in this study, the region to be examined has to be defined before the examination is performed (for example, focus on PIP and MCP joints or wrist and MCP joints) owing to field of view and coil limitations. However, when limited to a field of view, it would probably be more useful to include the wrist and MCP joints rather than solely the PIP and MCP joints. On the other hand, with MRI, images can be obtained by a technician, whereas with US, several readers are needed to interpret and score both synovitis and erosions at a later time point.

For each method, two experienced readers reached consensus about synovitis and erosion findings, except for US which was evaluated by one experienced examiner at baseline. Although this might have had an influence on the interpretation of the pathological findings, we have recently shown that US performed by experienced examiners giving good interreader agreement results.<sup>15 33</sup>

## CONCLUSIONS

US and MRI are valuable imaging techniques for the visualisation and follow up analysis of synovitis and bone erosions in small finger joints of patients with RA. MRI seems to be better than US for the detection of early erosions because more erosions formerly detected by MRI were seen by CR at follow up. However, technical limitations of the US device at baseline have to be taken into account. MRI seems to be better for evaluation of erosions of MCP joints rather than PIP joints, while US was better than MRI for evaluation of PIP joints. Both techniques have their advantages and disadvantages. However, because US is an easy handling and low cost imaging technique, whereas MRI (as imaging “gold standard”) is rather expensive, we recommend US for quick evaluation of follow up analysis.

## ACKNOWLEDGEMENTS

The use of the MRI device was possible owing to a research contract between Charité Medical School and Esaote Biomedica SA, Genoa, Italy. Dr Scheel received grants from the “Rheumatology Competence Network” and the “Georg-August-University funding” to perform the clinical study.

.....

### Authors' affiliations

**A K Scheel, S Ohrndorf, G A Müller**, Department of Medicine, Nephrology and Rheumatology, Georg-August-University Göttingen, Robert-Koch-Strasse 40, D-37075 Göttingen, Germany  
**K-G A Hermann, C Schirmer, B Hamm**, Department of Radiology, Charité University Hospital, Schumannstrasse 20/21, D-10098 Berlin, Germany  
**C Werner**, Department of Medical Statistics, Georg-August-University Göttingen, Humboldtallee 32, D-37073 Göttingen, Germany  
**J Detert, G R Burmester, M Backhaus**, Department of Medicine, Rheumatology and Clinical Immunology, Charité University Hospital, Schumannstrasse 20/21, D-10098 Berlin, Germany  
**M Bollow**, Department of Radiology, Augusta Hospital, Bergstrasse 26, D-44791 Bochum, Germany

Competing interests: None.

## REFERENCES

- 1 **Backhaus M**, Kamradt T, Sandrock D, Loreck D, Fritz J, Wolf KJ, et al. Arthritis of the finger joints: a comprehensive approach comparing conventional radiography, scintigraphy, ultrasound, and contrast-enhanced magnetic resonance imaging. *Arthritis Rheum* 1999;**42**:1232–45.
- 2 **Backhaus M**, Burmester GR, Sandrock D, Loreck D, Hess D, Scholz A, et al. Prospective two year follow up study comparing novel and conventional imaging procedures in patients with arthritic finger joints. *Ann Rheum Dis* 2002;**61**:895–904.
- 3 **Wakefield RJ**, Gibbon WW, Conaghan PG, O'Connor P, McGonagle D, Pease C, et al. The value of sonography in the detection of bone erosions in patients with rheumatoid arthritis: a comparison with conventional radiography. *Arthritis Rheum* 2000;**43**:2762–70.
- 4 **Peterfy CG**. Magnetic resonance imaging of rheumatoid arthritis: the evolution of clinical applications through clinical trials. *Semin Arthritis Rheum* 2001;**30**:375–96.
- 5 **Bird P**, Eijbjerg B, McQueen F, Ostergaard M, Lassere M, Edmonds J. OMERACT Rheumatoid Arthritis Magnetic Resonance Imaging Studies. Exercise 5: an international multicenter reliability study using computerized MRI erosion volume measurements. *J Rheumatol* 2003;**30**:1380–4.
- 6 **Lassere M**, McQueen F, Ostergaard M, Conaghan P, Shnier R, Peterfy C, et al. OMERACT Rheumatoid Arthritis Magnetic Resonance Imaging Studies. Exercise 3: an international multicenter reliability study using the RA-MRI Score. *J Rheumatol* 2003;**30**:1366–75.
- 7 **Scheel AK**, Krause A, Rheinbaben IM, Metzger G, Rost H, Tresp V, et al. Assessment of proximal finger joint inflammation in patients with rheumatoid arthritis, using a novel laser-based imaging technique. *Arthritis Rheum* 2002;**46**:1177–84.
- 8 **Schmidt WA**, Volker L, Zacher J, Schlafke M, Ruhnke M, Gromnica-Ihle E. Colour Doppler ultrasonography to detect pannus in knee joint synovitis. *Clin Exp Rheumatol* 2000;**18**:439–44.
- 9 **Szkudlarek M**, Court-Payen M, Strandberg C, Klarlund M, Klausen T, Ostergaard M. Contrast-enhanced power Doppler ultrasonography of the metacarpophalangeal joints in rheumatoid arthritis. *Eur Radiol* 2003;**13**:163–8.
- 10 **Grassi W**, Lamanna G, Farina A, Cervini C. Synovitis of small joints: sonographic guided diagnostic and therapeutic approach. *Ann Rheum Dis* 1999;**58**:595–7.
- 11 **Terslev L**, Torp-Pedersen S, Savnik A, von der Recke P, Qvistgaard E, Danneskiold-Samsøe B, et al. Doppler ultrasound and magnetic resonance imaging of synovial inflammation of the hand in rheumatoid arthritis: a comparative study. *Arthritis Rheum* 2003;**48**:2434–41.
- 12 **Szkudlarek M**, Court-Payen M, Jacobsen S, Klarlund M, Thomsen HS, Ostergaard M. Interobserver agreement in ultrasonography of the finger and toe joints in rheumatoid arthritis. *Arthritis Rheum* 2003;**48**:955–62.
- 13 **Ostergaard M**, Wiell C. Ultrasonography in rheumatoid arthritis: a very promising method still needing more validation. *Curr Opin Rheumatol* 2004;**16**:223–30.
- 14 **Arnett FC**, Edworthy SM, Bloch DA, McShane DJ, Fries JF, Cooper NS, et al. The American Rheumatism Association 1987 revised criteria for the classification of rheumatoid arthritis. *Arthritis Rheum* 1988;**31**:315–24.
- 15 **Scheel AK**, Hermann KG, Kahler E, Pasewaldt D, Fritz J, Hamm B, et al. A novel ultrasonographic synovitis scoring system suitable for analyzing finger joint inflammation in rheumatoid arthritis. *Arthritis Rheum* 2005;**52**:733–43.
- 16 **Conaghan P**, Lassere M, Ostergaard M, Peterfy C, McQueen F, O'Connor P, et al. OMERACT Rheumatoid Arthritis Magnetic Resonance Imaging Studies. Exercise 4: an international multicenter longitudinal study using the RA-MRI Score. *J Rheumatol* 2003;**30**:1376–9.
- 17 **Peterfy CG**. New developments in imaging in rheumatoid arthritis. *Curr Opin Rheumatol* 2003;**15**:288–95.
- 18 **Grassi W**, Cervini C. Ultrasonography in rheumatology: an evolving technique. *Ann Rheum Dis* 1998;**57**:268–71.
- 19 **Wakefield RJ**, Kong KO, Conaghan PG, Brown AK, O'Connor PJ, Emery P. The role of ultrasonography and magnetic resonance imaging in early rheumatoid arthritis. *Clin Exp Rheumatol* 2003;**21**(suppl 31):S42–9.
- 20 **Conaghan PG**, Ostergaard M, McGonagle D, O'Connor P, Emery P. The validity and predictive value of magnetic resonance imaging erosions in rheumatoid arthritis: comment on the article by Goldbach-Mansky, et al. *Arthritis Rheum* 2004;**50**:1009–11.
- 21 **McGonagle D**, Conaghan PG, Wakefield R, Emery P. Imaging the joints in early rheumatoid arthritis. *Best Pract Res Clin Rheumatol* 2001;**15**:91–104.
- 22 **Ostergaard M**, Hansen M, Stoltenberg M, Gideon P, Klarlund M, Jensen KE, et al. Magnetic resonance imaging-determined synovial membrane volume as a marker of disease activity and a predictor of progressive joint destruction in the wrists of patients with rheumatoid arthritis. *Arthritis Rheum* 1999;**42**:918–29.
- 23 **McQueen FM**, Stewart N, Crabbe J, Robinson E, Yeoman S, Tan PL, et al. Magnetic resonance imaging of the wrist in early rheumatoid arthritis reveals progression of erosions despite clinical improvement. *Ann Rheum Dis* 1999;**58**:156–63.
- 24 **Szkudlarek M**, Court-Payen M, Strandberg C, Klarlund M, Klausen T, Ostergaard M. Power Doppler ultrasonography for assessment of synovitis in the metacarpophalangeal joints of patients with rheumatoid arthritis: a comparison with dynamic magnetic resonance imaging. *Arthritis Rheum* 2001;**44**:2018–23.
- 25 **Kane D**, Balint PV, Sturrock RD. Ultrasonography is superior to clinical examination in the detection and localization of knee joint effusion in rheumatoid arthritis. *J Rheumatol* 2003;**30**:966–71.
- 26 **Kuper IH**, van Leeuwen MA, van Riel PL, Sluiter WJ, Houtman NM, Cats HA, et al. Influence of a ceiling effect on the assessment of radiographic progression in rheumatoid arthritis during the first 6 years of disease. *J Rheumatol* 1999;**26**:268–76.
- 27 **Taouli B**, Zaim S, Peterfy CG, Lynch JA, Stork A, Guermazi A, et al. Rheumatoid arthritis of the hand and wrist: comparison of three imaging techniques. *AJR Am J Roentgenol* 2004;**182**:937–43.
- 28 **McQueen FM**, Benton N, Crabbe J, Robinson E, Yeoman S, McLean L, et al. What is the fate of erosions in early rheumatoid arthritis? Tracking individual lesions using x rays and magnetic resonance imaging over the first two years of disease. *Ann Rheum Dis* 2001;**60**:859–68.
- 29 **Peterfy CG**. MRI of the wrist in early rheumatoid arthritis. *Ann Rheum Dis* 2004;**63**:473–7.
- 30 **Szkudlarek MKM**, Narvestad E, Court-Payen M, Strandberg C, Ostergaard M. Ultrasonography of the RA finger joints is more sensitive than conventional radiography for the detection of erosions without loss of specificity, with MRI as a reference method. *Ann Rheum Dis* 2004;**63**(suppl 1):82–3.
- 31 **Szkudlarek M**. Ultrasonography of the finger and toe joints in rheumatoid arthritis University of Copenhagen, 2003. [PhD thesis.].
- 32 **Ostergaard M**, Peterfy C, Conaghan P, McQueen F, Bird P, Eijbjerg B, et al. OMERACT Rheumatoid Arthritis Magnetic Resonance Imaging Studies. Core set of MRI acquisitions, joint pathology definitions, and the OMERACT RA-MRI scoring system. *J Rheumatol* 2003;**30**:1385–6.
- 33 **Scheel AK**, Schmidt WA, Hermann KG, Bruyn GA, D'Agostino MA, Grassi W, et al. Interobserver reliability of rheumatologists performing musculoskeletal ultrasonography: results from a EULAR "Train the trainers" course. *Ann Rheum Dis* 2005;**64**:1043–9.

## 4. DISKUSSION UND SCHLUSSFOLGERUNGEN

Aufgrund der Unumkehrbarkeit der erosiven Knochendestruktion entsteht die Notwendigkeit, Arthritiden aggressiv zu therapieren, die sich in Form von Synovitiden und Tenosynovitiden manifestieren (36). Die klinische Untersuchung ist dabei zu ungenau und unspezifisch, die konventionelle Röntgendiagnostik kann Vorgänge in den Weichteilen nur mit geringer Sensitivität und nur indirekt darstellen (37). Moderne bildgebende Verfahren wie US und MRT sind deshalb zur Objektivierung der Gelenkveränderungen erforderlich (4). Weiterhin spielen die genannten Verfahren eine Rolle bei der Verlaufsbeurteilung von Synovitiden und Tenosynovitiden (38).

Neben dem exzellenten Weichteilkontrast und der fehlenden Anwendung von ionisierenden Strahlen als Vorteil der MRT bestehen Limitationen wie vergleichsweise hohe Kosten, Probleme und Schmerzen bei der Lagerung der Patienten in „Superman-Position“ (11) und Klaustrophobie. Klaustrophobe Reaktionen werden zwar häufig ins Feld geführt (39), treten bei sachlicher Analyse der Situation jedoch nur in 1 % – 2 % der MRT-Untersuchungen auf und führen nur in 1,2 % zum kompletten Abbruch der MRT-Untersuchung (40,41). Die Probleme der Kosten und unbequemen Patientenlagerung wurde durch die Entwicklung der Niederfeld-MRT-Geräte Anfang der 1990er-Jahre adressiert. Diese Geräte wurden zunächst für orthopädische Indikationen großer Gelenke vermarktet und evaluiert (42,43). Aufgrund der Entwicklung hochwirksamer Medikamente wie TNF- $\alpha$ -Inhibitoren bestand der Bedarf, Therapieeffekte nicht nur mittels Röntgenaufnahmen nach 12 bzw. 24 Monaten detektieren zu können, sondern bereits nach drei bis vier Monaten (44). Konsekutiv fanden Niederfeld-MRT-Geräte auch ihre Verbreitung in der Rheumatologie und wurden einem Evaluationsprozess unterzogen (20,45-48). An diesem Prozess haben wir uns aus radiologischer Perspektive beteiligt.

Die inflammatorische Aktivität der Synovialmembran kann auf verschiedene Art und Weise abgeschätzt werden: mittels quantitativer Volumenmessung, semiquantitativem Scoring und mit Hilfe qualitativer Messmethoden (49). Wir verwendeten die von der OMERACT-Arbeitsgruppe empfohlene semiquantitative Methode RAMRIS (Rheumatoid arthritis magnetic resonance imaging score) (16). Diese Methode erwies sich auch innerhalb unserer Arbeitsgruppe als robust, was an sehr guten Intraklassenkorrelationskoeffizienten der

Übereinstimmung zwischen den Bewertern gemessen werden kann (Publikationen 1 und 2).

Die relativ niedrigere Empfindlichkeit von MRT-Kontrastmitteln bei niedriger Feldstärke hat folgende Hintergründe: Die T1-Relaxationszeit von Gewebe und die Relaxivität von Gadolinium hängen auf verschiedene Art und Weise von der Feldstärke ab. Die Relaxationszeit eines Gewebes mit Gadolinium erfolgt nichtlinear zur Feldstärke und hat einen größeren Effekt bei hohen als bei niedrigen Feldstärken (50). Das Signal-zu-Rausch-Verhältnis (SNR) ist eine der Schlüsselkomponenten für die Beurteilung der Qualität von MRT-Aufnahmen. Bei einer höheren Kontrastmitteldosis wird zum einen eine Verbesserung der Anreicherung im Gewebe erwartet und zum anderen verbessert sich das SNR dieses Gewebes (13,51). In bisherigen Studien zur Diagnostik von Synovitiden mittels Niederfeld-MRT wurden paramagnetische Kontrastmittel und verschiedene Dosierungen verwendet: Neben der einfachen (52) Dosierung von Gd-DTPA (gadolinium-diethylenetriaminepentaacetic acid) wurde auch die doppelte Dosierung dieses Kontrastmittels berichtet (53,54), desweiteren der Einsatz von Gd-DTPA-BMA (gadodiamide) in einfacher (18,20,45) und dreifacher (37,55) Dosierung. Die Vergleichbarkeit zwischen diesen Studien ist dadurch eingeschränkt. Wir konnten zeigen, dass die Kontrastmitteldosis signifikanten Einfluss auf die Wahrnehmung der Synovitis auf Niederfeld-MRT-Aufnahmen hat (Publikation 1). Dies erfolgt unabhängig von der Erfahrung des Auswerters (14).

Diese Ergebnisse sind anhand der Überlegungen zum Signal-Rausch-Verhältnis zu erwarten gewesen, nicht jedoch vor dem Hintergrund unserer klinischen Erfahrung. Beim Scoring der Synovitis geht vor allen Dingen die Dicke der Synovialmembran und somit der gesamten Gelenkkapsel in die Wertung ein, wobei die Synovialmembran ein Enhancement nach KM-Gabe aufweisen muss (16). Die Erwartungen, dass sich die Dicke der Synovialmembran durch die Menge des injizierten Kontrastmittels nicht ändert und somit das Scoring-Ergebnis nicht beeinflusst wird, wurden nicht bestätigt. Die Empfehlung lautet entsprechend, beim Einsatz der Niederfeld-MRT immer mit doppelter Kontrastmitteldosis zu arbeiten, um frühe und diskrete Veränderungen nicht zu übersehen. Einschränkungen beim höher dosierten Einsatz von Kontrastmitteln wie z. B. systemische nephrogene Fibrose sind jedoch zu berücksichtigen und vorher abzuklären (56). Im Rahmen von Verlaufsstudien sollte die Kontrastmitteldosis konstant bleiben.

Neben der reinen Betrachtung von Signalintensitäten und Kontrast-zu-Rausch-Verhältnissen muss die Niederfeld-MRT auch ihre diagnostische Fähigkeit im Vergleich mit der konventionellen MRT bei 1,5 Tesla unter Beweis stellen. In unserer intraindividuellen Vergleichsstudie der kleinen Gelenke der Hände (Publikation 2) zeigten sich in der überwiegenden Mehrzahl der untersuchten Knochen und Gelenke hohe Übereinstimmung beider bildgebender Verfahren (17). Ähnliche Studien mit unterschiedlichem Design wurden bereits durchgeführt: Savnik et al. führten erstmalig einen direkten Vergleich von Niederfeld- und konventioneller MRT bei Patienten mit rheumatoider Arthritis durch (18). Bei der Detektion der Synovitis konnten gute Übereinstimmungen der beiden Geräte nachgewiesen werden. Ähnliche Ergebnisse wurden in einer Studie mit 18 Patienten erzielt, obwohl in diesem Fall ohne Kontrastmittelapplikation gearbeitet wurde (19).

Auch Ejbjerg et al. zeigten an einer Gruppe von 37 RA-Patienten eine hohe Sensitivität des Niederfeld-MRT bei der kontrastmittelgestützten Diagnostik der Synovitis (20). Die konventionelle MRT wurde in der letztgenannten Studie als Referenzmethode bzw. als der sogenannte „Goldstandard“ betrachtet. Ferner wurde nur das Vorhandensein oder Fehlen der Synovitis an einem Gelenk beurteilt (dichotomes Beurteilungssystem). Da diese Ansätze methodische Schwächen haben (17), führten wir ein semiquantitatives Scoring der Veränderungen durch und verwendeten  $\kappa$ -Statistiken und den McNemar-Test. Im Ergebnis fanden wir eine gute Übereinstimmung der beiden MRT-Geräte für die Detektion der Synovitis. In den meisten Fällen erzielten Niederfeld-MRT und konventionelle MRT ähnliche Score-Werte. Nur bei einigen Gelenken wurden signifikant höhere Score-Werte durch das Niederfeld-MRT erzielt. Auch Savnik et al. detektierten mehr von Synovitis betroffene Gelenke mittels Niederfeld-MRT (18). Im Unterschied dazu stehen die Ergebnisse der Ejbjerg-Studie, in der mit der konventionellen MRT mehr Gelenke als positiv für Synovitis charakterisiert wurden (20).

Die MRT ist in der Lage, RA-typische Weichteilläsionen wie Tenosynovitis oder Synovitis zu visualisieren (57,58). Nur wenige Studien haben bisher die Bildgebung der Tenosynovitis mittels MRT untersucht (58,59), wobei ein Vergleich von Niederfeld-MRT mit konventioneller MRT bisher noch nicht erfolgte. Die Daten unserer Studie für die Detektion der Tenosynovitis sind noch nicht zufriedenstellend, da nur eine mäßige Übereinstimmung zwischen den Beurteilern besteht und Scorewerte pro Sehne voneinander abweichen.

Spondyloarthritiden sind im Gegensatz zur rheumatoiden Arthritis, welche ihren Hauptmanifestationsort in der Synovialmembran der Gelenke findet, Erkrankungen der Enthesen (60). Enthesen sind die Übergänge zwischen Bändern, Sehnen und Gelenkkapseln zum Knochen und bestehen in der Mehrzahl der Enthesen aus Faserknorpel (61). Aufgrund der Affektion dieser Enthesen kommt es bei Spondyloarthritiden häufiger zu extraartikulären entzündlichen Weichteilmanifestationen als bei der rheumatoiden Arthritis. Die Darstellung dieser Enthesen der kleinen Fingergelenke erfordert besondere technische Vorkehrungen, um Auflösungen bis zu 100  $\mu\text{m}$  in Schichtebene zu erzielen (62,63). Versuche, Enthesitiden am Beispiel der Psoriasisarthritis mittels Niederfeld-MRT und dynamischen kontrastverstärkten Sequenzen darzustellen, existieren, zeigten jedoch keine Unterschiede zu Veränderungen bei rheumatoider Arthritis (54). Die Darstellung von Enthesitiden großer Gelenke, wie beispielsweise den Sprunggelenken und den Ansätzen der Achillessehne und Plantarfaszie am Kalkaneus erscheint dagegen aussichtsreicher. Wir führten für diese Indikation einen prospektiven Gruppenvergleich von Patienten mit Spondyloarthritiden und Fersenschmerzen durch (Publikation 3) und fanden ähnliche Häufigkeiten der Befunde in der konventionellen MRT und der Niederfeld-MRT (24). Häufigste Manifestationen waren dabei die retrokalkaneale Bursitis (Bursitis subachillea) und die plantare Fasziitis. Untersuchungen zum Wert der MRT am Rückfußskelett sind insgesamt sehr selten. Erdem et al. analysierten diese Veränderungen mittels konventioneller MRT und wiesen plantare Fasziitiden ebenfalls als einen der häufigsten Befunde nach (64).

Die Entwicklung der Destruktion großer Gelenke geht prinzipiell mit der Destruktion kleiner Gelenke einher (65). Die RA manifestiert sich jedoch bei einem Teil der Patienten zuerst am Schultergelenk und erst später an den Händen und Füßen (66). Arthritiden der Schultergelenke führen rasch zu deutlichen funktionellen Beeinträchtigungen des täglichen Lebens (67). Es besteht deshalb berechtigtes Interesse, die Wertigkeit der bildgebenden Verfahren für die Diagnostik der Arthritiden der großen Gelenke zu untersuchen. Am Schultergelenk fanden wir in unserer Studie bei 43 Patienten (Publikation 4) eine sehr hohe Sensitivität der konventionellen MRT bei 1,5 Tesla im Vergleich zur Röntgendiagnostik und Arthrosonographie (25). Im Vergleich mit US wurden mittels MRT mehr entzündliche Weichteilläsionen detektiert in Übereinstimmung mit früheren Untersuchungen an kleineren Patientengruppen (68). Erosive Knochenläsionen wurden in unserer Studie zahlreicher mittels MRT als durch US detektiert. Teile des Schultergelenkes, insbesondere die Region des Tuberculum majus humeri, liegen so oberflächlich, dass sie gut durch US zugänglich sind



und eine Studie zeigte für diese Region höhere Detektionsraten von Erosionen durch US im Vergleich zur MRT (9). Aufgrund der widersprüchlichen Ergebnisse wurden entsprechende wissenschaftliche Diskussionen geführt (69,70) und die Notwendigkeit des systematischen Trainings und der weiteren Standardisierung der Arthrosonographie erkannt (71-73).

Den Wert der Detektion von Tenosynovitiden mittels MRT als frühen Indikator der RA stellen wir erstmals heraus (Publikation 5). Insbesondere in Kombination mit Laborparametern, wie dem Nachweis von Rheumafaktoren oder von Anti-CCP-Antikörpern, gelang die Diagnosestellung mit hoher Sensitivität und Spezifität (34). Dagegen brachte unsere statistische Analyse keine Hinweise, dass MR-tomographische Parameter allein ohne Zuhilfenahme des klinischen Befundes oder laborchemischer Kriterien in der Lage ist, die RA zu diagnostizieren. Dies unterstreicht die Wichtigkeit der engen Kooperation zwischen Radiologen und Rheumatologen. Versuche anderer Arbeitsgruppen scheiterten ebenfalls, die MRT als alleinigen diagnostischen Test für die Diagnose einer frühen RA zu etablieren und konnten akzeptable Sensitivitäten und Spezifitäten nur in Kombination mit Laborparametern erzielen (74). Eine bilaterale MR-Untersuchung der Hände trägt offenbar in höherem Maße zur Diagnose einer RA bei, da das Kriterium des symmetrischen Gelenkbefalls hier beurteilt werden kann (75). Dieser Ansatz ist aus technischer Hinsicht jedoch für viele Einrichtungen schwierig umzusetzen.

In Kooperation mit der Klinik für klinische Immunologie und Rheumatologie gewannen wir die ersten Sieben-Jahres-Langzeitdaten der Niederfeld-MRT für die Detektion von Erosionen und Synovitis der Fingergelenke von RA-Patienten (Publikation 6). Unter Langzeittherapie mit DMARDs konnten wir mittels MRT eine Reduktion der Synovitis dokumentieren (35). Die Verlaufskontrolle von Synovitis und Erosionen der Fingergelenke über längere Zeit sind wichtige Parameter zur Beurteilung der Effizienz der medikamentösen Behandlung. Obwohl während der Behandlung mit DMARDs ein Rückgang der Synovitis zu verzeichnen war, wurden mittels MRT progrediente Erosionen in den Fingergelenken festgestellt. Im Verlauf progrediente Erosionen bei klinischer Verbesserung der Beschwerden wurden ebenfalls in einer MRT-Studie von Handgelenken mit RA von McQueen et al. beschrieben (76). Dies unterstreicht den Wert hochsensitiver bildgebender Verfahren, da offenbar „subklinische“ Synovitiden die Ursache für progrediente Fehlstellungen, Funktionsbehinderungen und Einschränkungen der Lebensqualität von RA-Patienten sind (77).



Insgesamt ergibt sich also ein positives Bild für den Einsatz der Niederfeld-MRT bei rheumatologischen Indikationen. Zu beachten ist aber, dass diese Ergebnisse nicht für alle Niederfeld-MRT-Geräte verallgemeinerbar sind. Unsere Ergebnisse (14,17,24,35) sowie die überwiegende Mehrzahl anderer publizierter Studien (18-20,48,78,79) beziehen sich auf das Gerät „C-Scan“ bzw. dessen Vorläufer „ArtoScan“ der Firma Esaote Biomedica (Genua, Italien). Diese Geräte mit einem „Field-of-View“ von 12 cm sind in der Lage, das ganze Handgelenk oder alle Finger in einem Arbeitsschritt darzustellen. Sie wurden deshalb auch als „Extended-field-of-view“-Geräte bezeichnet. Diesen werden sogenannte „reduced Field-of-View“-Geräte gegenüber gestellt (80). Letztere erzeugen Bilder mit deutlich höherem Rauschanteil und können nur zwei MCP-Gelenke in koronarer Orientierung darstellen. In einer vergleichenden Studie lag die Sensitivität für die Detektion erosiver Veränderungen sogar unterhalb der Sensitivität der konventionellen Röntgendiagnostik und deutlich unter der Sensitivität für Niedrigfeld-MRT-Geräte mit „extended Field-of-View“ (81).

Die durchgeführten und hier zusammengefassten Studien wurden alle sorgfältig geplant. Dennoch müssen einige Limitationen berücksichtigt werden. Beim intraindividuellen Vergleich der beiden MRT-Geräteklassen (Publikation 2) und bei der Beurteilung des Langzeitverlaufs (Publikation 6) wurden nur sehr kleine Patientengruppen in die Studie eingeschlossen. Im ersten Fall ist dies darin begründet, dass es prinzipiell sehr schwierig ist, Patienten für zwei MRT-Untersuchungen am gleichen Tag zu motivieren, im letzten Fall standen einige Patienten der ursprünglich untersuchten Kohorte für die Verlaufskontrolle nicht mehr zur Verfügung bzw. wollten wir uns auf Patienten mit RA konzentrieren. Aufgrund des Fortschreitens der Gerätetechnologie konnte die Sieben-Jahres-Verlaufsbeurteilung nicht am gleichen MRT-Gerät durchgeführt werden – Feldstärke, „Field-of-View“ und Bildqualität waren aber vergleichbar.

#### **4.1. Klinische Implikationen und Schlussfolgerungen**

Insgesamt konnten wir durch die in dieser Habilitationsschrift zusammengefassten Studien zeigen, dass die MRT eine exzellente Methode für die Diagnostik entzündlich-rheumatischer Gelenkerkrankungen ist. Sie sollte dann zum Einsatz kommen, wenn eine deutliche Befunddiskrepanz zwischen konventioneller Röntgendiagnostik und der Klinik besteht und eine adäquate Arthrosonographie nicht möglich ist. Für die Diagnostik am Schultergelenk

stellt dabei die konventionelle MRT bei 1,5 Tesla das sensitivste Verfahren dar, welches alle Gelenkkompartimente vollständig erfasst. In der Diagnostik peripherer Arthritiden und Enthesitiden stellt die Niederfeld-MRT eine ernst zu nehmende Alternative dar. Dabei müssen die MRT-Aufnahmen jedoch mit entsprechender Sorgfalt angefertigt, Einflussfaktoren auf die Bildqualität wie beispielsweise die Anwendung von Kontrastmittel in feldstärkeadaptierter Dosierung beachtet und international validierte Auswertescores berücksichtigt werden. Pluspunkte erzielt die Niederfeld-MRT insbesondere durch die hohe Akzeptanz durch die Patienten, da das Gerätedesign nicht den Eindruck eines medizinischen Großgerätes vermittelt, sondern die Dimensionen überschaubar erscheinen und Patienten nur die betroffene Extremität innerhalb des Magnetfeldes platzieren müssen. Die von uns durchgeführten Studien stellen nicht das Ende der wissenschaftlichen Evaluation dieser Geräte dar. Neuere, noch mobilere Geräte erobern derzeit den Markt, welche aufgrund einer nochmals deutlich reduzierten Bildqualität einer gründlichen Prüfung unterzogen werden müssen. Ferner existieren bereits Extremitäten-MRT-Geräte mit Feldstärken von 1,0 Tesla und 1,5 Tesla, welche alle Optionen der konventionellen MRT bieten und gleichzeitig einer bequemen Lagerung der Patienten ermöglichen. Die Anwendbarkeit der Niederfeld-MRT für die Diagnostik enthesenassoziierter Erkrankungen, beispielsweise der reaktiven Arthritis und Psoriasisarthritis, muss weiter untersucht werden. Empfehlenswert ist es, diesen Prozess mit radiologischem Knowhow voranzubringen und mit rheumatologischer Fachkompetenz zu bündeln. Aufgrund der Komplexität der technischen und klinischen Aspekte sollten Alleingänge der beteiligten Fachdisziplinen vermieden werden, um die verfügbare Technologie zum Wohle der Patienten mit fundierter Datenlage einsetzen zu können.

## 5. ZUSAMMENFASSUNG

Die rheumatoide Arthritis (RA) und Spondyloarthritiden (SpA) sind die häufigsten entzündlich-rheumatischen Gelenkerkrankungen und stellen durch Langzeitarbeitsunfähigkeit und Frühberentungen ein volkswirtschaftliches Problem dar. Die geringe Sensitivität der konventionellen Röntgendiagnostik für die Diagnostik früher Formen von Arthritiden ist im Allgemeinen anerkannt. Moderne Schnittbildverfahren wie die Ultraschalldiagnostik (US) und die Magnetresonanztomographie (MRT) haben sich als sensitiver für die Diagnostik von Erosionen erwiesen und können zusätzlich Synovitiden, Tenosynovitiden und Knochenmarködeme darstellen. Beide Verfahren, insbesondere jedoch die MRT, sind mit vergleichsweise hohen Kosten behaftet. Niederfeld-MRT-Geräte verfügen über das Potential, eine sensitive Diagnostik zu vergleichsweise geringen Kosten anbieten zu können.

Im Rahmen der vorliegenden Habilitationsarbeit wurden folgende Fragestellungen bearbeitet: 1. Welche Rahmenbedingungen sind für den Einsatz von Niederfeld-MRT-Geräten erforderlich? 2. Ist die diagnostische Qualität der Niederfeld-MRTs im Vergleich zur konventionellen MRT gleichwertig? 3. Welchen Stellenwert hat die MRT in der Diagnostik von Arthritiden an großen Gelenken? 4. Welche Rolle spielt die MRT in der Prognoseabschätzung bei früher RA und in der Langzeitverlaufsbeurteilung?

Insgesamt analysierten wir 240 Patienten im Rahmen von sechs Studien. Dabei zeigten wir, dass insbesondere bei niedriger Feldstärke (0,2 Tesla) die Dosis des Kontrastmittels einen erheblichen Einfluss sowohl auf Signal-zu-Rausch- und Kontrast-zu-Rausch-Verhältnisse hat als auch die Ergebnisse des semiquantitativen Scorings positiv beeinflusst – bis zu 65 (44%) der 149 untersuchten MCP-Gelenke werden bei Verdoppelung der Kontrastmitteldosis mit höheren Scoringergebnissen eingeschätzt (Publikation 1).

Sowohl im intraindividuellen Vergleich bei Patienten mit RA als auch im Gruppenvergleich bei Patienten mit SpA erwies sich die Niederfeld-MRT gleichwertig im Vergleich zur konventionellen MRT in Bezug auf deren diagnostische Aussage. Für die Diagnostik von Synovitiden fanden sich  $\kappa$ -Werte zwischen 0,69 – 0,94 und für die Diagnostik von Erosionen errechneten sich  $\kappa$ -Werte von 0,65 – 1,0 (Publikation 2). Bei der Darstellung pathologischer Veränderungen des Rückfußskeletts waren beide MRT-Geräteklassen etwa gleichwertig – es wurden keine signifikanten Unterschiede der Häufigkeiten der verschiedenen Pathologien gefunden (Publikation 3).

Am Schultergelenk erwies sich die MRT bei 1,5 Tesla als sensitivstes Verfahren im Vergleich zur konventionellen Röntgendiagnostik und der US-Diagnostik. Erosive Läsionen wurden zahlreicher mittels US und MRT detektiert, wobei MRT auch bei 10 von 13 Patienten ohne Erosionen im US noch weitere Erosionen nachweisen konnte. Auch Weichteilveränderungen lassen sich mit der MRT deutlich sensitiver darstellen als mittels US, insbesondere bei Einsatz von paramagnetischem Kontrastmittel. Mit Hilfe der dynamischen kontrastverstärkten MRT konnte die diagnostische Sicherheit für die MR-tomographische Detektion von Erosionen signifikant erhöht ( $p < 0,005$ ) und Patienten mit und ohne röntgenologische Erosionen voneinander differenziert ( $p < 0,005$ ) werden (Publikation 4).

Die MRT ist ein wertvolles Hilfsmittel für die Frühdiagnose der RA. Unsere Studie unterstrich erstmals den Wert der Detektion von Tenosynovitiden für die Diagnose einer frühen RA (Publikation 5). Die diagnostische Aussage des Nachweises von Tenosynovitiden war in Kombination mit dem positivem Nachweis von Rheumafaktoren bzw. Antikörpern gegen citrullinierte Peptid-Antigene noch spezifischer. Eine weitere Studie stellte erstmals den MR-tomographischen Verlauf der rheumatoiden Arthritis in einem Zeitraum von sieben Jahren unter Therapie mit erkrankungsmodifizierenden Antirheumatika (DMARDs) dar. Trotz der deutlichen Reduktion von Synovitiden der PIP- und MCP-Gelenke war eine Progression der erosiven Läsionen in allen verwendeten bildgebenden Verfahren (Röntgendiagnostik, Ultraschall, MRT) zu verzeichnen (Publikation 6). Daraus lassen sich Rückschlüsse auf Synovitiden ziehen, die vom Patienten nicht wahrgenommen werden und welche Ursache für die langfristige Zerstörung der Gelenke auch bei adäquater antiinflammatorischer Therapie sein können.

Insgesamt konnten wir zeigen, dass die Niederfeld-MRT bei adäquatem Einsatz, unter Zuhilfenahme einer feldstärkeadaptierten Kontrastmitteldosis und unter Anwendung von international standardisierten Auswerteverfahren ein hilfreiches diagnostisches Instrument ist. Bei akzeptabler Bildqualität waren keine diagnostischen Einbußen bei den hier untersuchten Indikationen zu verzeichnen.

## 6. LITERATURVERZEICHNIS

1. Lee DM, Weinblatt ME. Rheumatoid arthritis. *Lancet* 2001;358:903-911
2. Mau W, Beyer W, Ehlebracht-König I, Engel M, Genth E, Greitemann B, Jackel WH, Zink A. Krankheitslast. Erste Routineberichterstattung zu sozialmedizinischen Folgen entzündlich-rheumatischer Erkrankungen in Deutschland. *Z Rheumatol* 2008;67:157-164
3. Arnett FC, Edworthy SM, Bloch DA, McShane DJ, Fries JF, Cooper NS, Healey LA, Kaplan SR, Liang MH, Luthra HS, et al. The American Rheumatism Association 1987 revised criteria for the classification of rheumatoid arthritis. *Arthritis Rheum* 1988;31:315-324.
4. Ostergaard M, Ejbjerg B, Szkudlarek M. Imaging in early rheumatoid arthritis: roles of magnetic resonance imaging, ultrasonography, conventional radiography and computed tomography. *Best Pract Res Clin Rheumatol* 2005;19:91-116
5. Braun J, Bollow M, Remlinger G, Eggens U, Rudwaleit M, Distler A, Sieper J. Prevalence of spondylarthropathies in HLA-B27 positive and negative blood donors. *Arthritis Rheum* 1998;41:58-67
6. Rudwaleit M, Metter A, Listing J, Sieper J, Braun J. Inflammatory back pain in ankylosing spondylitis: A reassessment of the clinical history for application as classification and diagnostic criteria. *Arthritis Rheum* 2006;54:569-578
7. Ginsburg WW, Cohen MD. Peripheral arthritis in ankylosing spondylitis. A review of 209 patients followed up for more than 20 years. *Mayo Clin Proc* 1983;58:593-596
8. Liao HT, Chen HA, Chen CH, Wang HP, Tsai CY, Chang HN, Chou CT. Undifferentiated spondyloarthropathy in chinese patients. *Arch Med Res* 2006;37:384-387
9. Alasaarela E, Suramo I, Tervonen O, Lahde S, Takalo R, Hakala M. Evaluation of humeral head erosions in rheumatoid arthritis: a comparison of ultrasonography, magnetic resonance imaging, computed tomography and plain radiography. *Br J Rheumatol* 1998;37:1152-1156.
10. Peterfy CG. Is there a role for extremity magnetic resonance imaging in routine clinical management of rheumatoid arthritis? *J Rheumatol* 2004;31:640-644
11. Hermann KG. Magnetresonanztomographie der Hand bei rheumatoider Arthritis. Wissenschaftliche Ergebnisse und praktische Anwendung. *Radiologe* 2006;46:384-393

12. Ghazinoor S, Crues JV, 3rd, Crowley C. Low-field musculoskeletal MRI. *J Magn Reson Imaging* 2007;25:234-244
13. Elster AD. How much contrast is enough? Dependence of enhancement on field strength and MR pulse sequence. *Eur Radiol* 1997;7 Suppl 5:276-280
14. Eshed I, Althoff CE, Schink T, Scheel AK, Schirmer C, Backhaus M, Lembcke A, Bollow M, Hamm B, Hermann KG. Low-field MRI for assessing synovitis in patients with rheumatoid arthritis. Impact of Gd-DTPA dose on synovitis scoring. *Scand J Rheumatol* 2006;35:277-282
15. Conaghan P, Edmonds J, Emery P, Genant H, Gibbon W, Klarlund M, Lassere M, McGonagle D, McQueen F, O'Connor P, Peterfy C, Shnier R, Stewart N, Ostergaard M. Magnetic resonance imaging in rheumatoid arthritis: summary of OMERACT activities, current status, and plans. *J Rheumatol* 2001;28:1158-1162
16. Ostergaard M, Peterfy C, Conaghan P, McQueen F, Bird P, Ejbjerg B, Shnier R, O'Connor P, Klarlund M, Emery P, Genant H, Lassere M, Edmonds J. OMERACT Rheumatoid Arthritis Magnetic Resonance Imaging Studies. Core set of MRI acquisitions, joint pathology definitions, and the OMERACT RA-MRI scoring system. *J Rheumatol* 2003;30:1385-1386
17. Schirmer C, Scheel AK, Althoff CE, Schink T, Eshed I, Lembcke A, Burmester GR, Backhaus M, Hamm B, Hermann KG. Diagnostic quality and scoring of synovitis, tenosynovitis and erosions in low-field MRI of patients with rheumatoid arthritis: A comparison with conventional MRI. *Ann Rheum Dis* 2007;66:522-529
18. Savnik A, Malmskov H, Thomsen HS, Bretlau T, Graff LB, Nielsen H, Danneskiold-Samsoe B, Boesen J, Bliddal H. MRI of the arthritic small joints: comparison of extremity MRI (0.2 T) vs high-field MRI (1.5 T). *Eur Radiol* 2001;11:1030-1038
19. Taouli B, Zaim S, Peterfy CG, Lynch JA, Stork A, Guermazi A, Fan B, Fye KH, Genant HK. Rheumatoid arthritis of the hand and wrist: comparison of three imaging techniques. *AJR Am J Roentgenol* 2004;182:937-943
20. Ejbjerg BJ, Narvestad E, Jacobsen S, Thomsen HS, Ostergaard M. Optimised, low cost, low field dedicated extremity MRI is highly specific and sensitive for synovitis and bone erosions in rheumatoid arthritis wrist and finger joints: comparison with conventional high field MRI and radiography. *Ann Rheum Dis* 2005;64:1280-1287
21. Jakobsson U, Westergren A. Statistical methods for assessing agreement for ordinal data. *Scand J Caring Sci* 2005;19:427-431

22. Cicchetti DV, Feinstein AR. High agreement but low kappa: II. Resolving the paradoxes. *J Clin Epidemiol* 1990;43:551-558
23. Greve W, Wentura D. *Wissenschaftliche Beobachtung: Eine Einführung*. Weinheim: PVU/Beltz; 1997
24. Eshed I, Althoff CE, Feist E, Minden K, Schink T, Hamm B, Hermann KG. Magnetic resonance imaging of hindfoot involvement in patients with spondyloarthritides: comparison of low-field and high-field strength units. *Eur J Radiol* 2008;65:140-147
25. Hermann KG, Backhaus M, Schneider U, Labs K, Loreck D, Zuhlsdorf S, Schink T, Fischer T, Hamm B, Bollow M. Rheumatoid arthritis of the shoulder joint: comparison of conventional radiography, ultrasound, and dynamic contrast-enhanced magnetic resonance imaging. *Arthritis Rheum* 2003;48:3338-3349
26. Mellerowicz H, Hauer RW, Schmidt WA, Bohl-Buhler M, Banzer D, Sattler H, Braun J, Backhaus M. Technik und Stellenwert der Arthrosonographie in der rheumatologischen Diagnostik - Teil 5: Sonographie des Schultergürtels. *Z Rheumatol* 2002;61:577-589
27. Vahlensieck M. MRI of the shoulder. *Eur Radiol* 2000;10:242-249
28. König H, Sieper J, Wolf KJ. Rheumatoid arthritis: evaluation of hypervascular and fibrous pannus with dynamic MR imaging enhanced with Gd-DTPA. *Radiology* 1990;176:473-477
29. Ostergaard M, Lorenzen I, Henriksen O. Dynamic gadolinium-enhanced MR imaging in active and inactive immunoinflammatory gonarthrosis. *Acta Radiol* 1994;35:275-281
30. Bollow M, Braun J, Hamm B, Eggens U, Schilling A, König H, Wolf KJ. Early sacroiliitis in patients with spondyloarthropathy: evaluation with dynamic gadolinium-enhanced MR imaging. *Radiology* 1995;194:529-536
31. Bollow M, König H, Hoffmann C, Schilling A, Wolf KJ. Initial findings using dynamic magnetic resonance tomography in the diagnosis of inflammatory diseases of the sacroiliac joint. *Rofo Fortschr Geb Rontgenstr Neuen Bildgeb Verfahr* 1993;159:315-324
32. Siström CL, Garvan CW. Proportions, Odds, and Risk. *Radiology* 2004;230:12-19
33. Gareen IF, Gatsonis C. Primer on Multiple Regression Models for Diagnostic Imaging Research. *Radiology* 2003;229:305-310

34. Eshed I, Feist E, Althoff CE, Hamm B, Konen E, Burmester GR, Backhaus M, Hermann KG. Tenosynovitis of the flexor tendons of the hand detected by MRI: An early indicator of rheumatoid arthritis. *Rheumatology* 2009;48:(in press)
35. Scheel AK, Hermann KG, Ohrndorf S, Werner C, Schirmer C, Detert J, Bollow M, Hamm B, Muller GA, Burmester GR, Backhaus M. Prospective 7 year follow up imaging study comparing radiography, ultrasonography, and magnetic resonance imaging in rheumatoid arthritis finger joints. *Ann Rheum Dis* 2006;65:595-600
36. Sokka T, Mäkinen H. Drug management of early rheumatoid arthritis - 2008. *Best Pract Res Clin Rheumatol* 2009;23:93-102
37. Backhaus M, Kamradt T, Sandrock D, Loreck D, Fritz J, Wolf KJ, Raber H, Hamm B, Burmester GR, Bollow M. Arthritis of the finger joints: a comprehensive approach comparing conventional radiography, scintigraphy, ultrasound, and contrast-enhanced magnetic resonance imaging. *Arthritis Rheum* 1999;42:1232-1245
38. Haavardsholm EA, Ostergaard M, Hammer HB, Boyesen P, Boonen A, van der Heijde D, Kvien TK. Monitoring anti-TNF{alpha} treatment in RA: Responsiveness of magnetic resonance imaging and ultrasonography of the dominant wrist compared to conventional measures of disease activity and structural damage. *Ann Rheum Dis* 2008:ard.2008.091801
39. Katznelson R, Djajani GN, Minkovich L, Fedorko L, Carroll J, Borger MA, Cusimano RJ, Karski J. Prevalence of claustrophobia and magnetic resonance imaging after coronary artery bypass graft surgery. *Neuropsychiatr Dis Treat* 2008;4:487-493
40. Dewey M, Schink T, Dewey CF. Claustrophobia during magnetic resonance imaging: cohort study in over 55,000 patients. *J Magn Reson Imaging* 2007;26:1322-1327
41. Eshed I, Althoff CE, Hamm B, Hermann KG. Claustrophobia and premature termination of magnetic resonance imaging examinations. *J Magn Reson Imaging* 2007;26:401-404
42. Riel KA, Kersting-Sommerhoff B, Reinisch M, Ottl G, Golder W, Lenz M, Hof N, Gerhardt P, Hipp E. Prospektiver Vergleich von ARTOSCAN-MRT und Arthroskopie bei Kniegelenkverletzungen. *Z Orthop Ihre Grenzgeb* 1996;134:430-434
43. Riel KA, Reinisch M, Kersting-Sommerhoff B, Hof N, Merl T. 0.2-Tesla magnetic resonance imaging of internal lesions of the knee joint: a prospective arthroscopically controlled clinical study. *Knee Surg Sports Traumatol Arthrosc* 1999;7:37-41



44. Ostergaard M, Szkudlarek M. Imaging in rheumatoid arthritis – why MRI and ultrasonography can no longer be ignored. *Scand J Rheumatol* 2003;32:63-73
45. Lindegaard H, Vallo J, Horslev-Petersen K, Junker P, Ostergaard M. Low field dedicated magnetic resonance imaging in untreated rheumatoid arthritis of recent onset. *Ann Rheum Dis* 2001;60:770-776
46. Ostergaard M, Duer A, Nielsen H, Johansen JS, Narvestad E, Ejbjerg BJ, Baslund B, Moller JM, Thomsen HS, Petersen J. Magnetic resonance imaging for accelerated assessment of drug effect and prediction of subsequent radiographic progression in rheumatoid arthritis: a study of patients receiving combined anakinra and methotrexate treatment. *Ann Rheum Dis* 2005;64:1503-1506
47. Lindegaard HM, Vallo J, Horslev-Petersen K, Junker P, Ostergaard M. Low-cost, low-field dedicated extremity magnetic resonance imaging in early rheumatoid arthritis: a 1-year follow-up study. *Ann Rheum Dis* 2006;65:1208-1212
48. Bird P, Ejbjerg B, Lassere M, Ostergaard M, McQueen F, Peterfy C, Haavardsholm E, O'Connor P, Genant H, Edmonds J, Emery P, Conaghan PG. A multireader reliability study comparing conventional high-field magnetic resonance imaging with extremity low-field MRI in rheumatoid arthritis. *J Rheumatol* 2007;34:854-856
49. Hodgson RJ, O'Connor P, Moots R. MRI of rheumatoid arthritis image quantitation for the assessment of disease activity, progression and response to therapy. *Rheumatology (Oxford)* 2008;47:13-21
50. Strijkers GJ, Mulder WJ, van Tilborg GA, Nicolay K. MRI contrast agents: current status and future perspectives. *Anticancer Agents Med Chem* 2007;7:291-305
51. Desai NK, Runge VM. Contrast use at low field: a review. *Top Magn Reson Imaging* 2003;14:360-364
52. Huegeli RW, Tirman PF, Bonel HM, Staedele H, Zaim S, Grigorian M, Genant HK. Use of the modified three-point Dixon technique in obtaining T1-weighted contrast-enhanced fat-saturated images on an open magnet. *Eur Radiol* 2004;14:1781-1786
53. Cimmino MA, Innocenti S, Livrone F, Magnaguagno F, Silvestri E, Garlaschi G. Dynamic gadolinium-enhanced magnetic resonance imaging of the wrist in patients with rheumatoid arthritis can discriminate active from inactive disease. *Arthritis Rheum* 2003;48:1207-1213

54. Cimmino MA, Parodi M, Innocenti S, Succio G, Banderali S, Silvestri E, Garlaschi G. Dynamic magnetic resonance of the wrist in psoriatic arthritis reveals imaging patterns similar to those of rheumatoid arthritis. *Arthritis Res Ther* 2005;7:R725-731
55. Backhaus M, Burmester GR, Sandrock D, Loreck D, Hess D, Scholz A, Blind S, Hamm B, Bollow M. Prospective two year follow up study comparing novel and conventional imaging procedures in patients with arthritic finger joints. *Ann Rheum Dis* 2002;61:895-904
56. Sadowski EA, Bennett LK, Chan MR, Wentland AL, Garrett AL, Garrett RW, Djamali A. Nephrogenic systemic fibrosis: risk factors and incidence estimation. *Radiology* 2007;243:148-157
57. Ostergaard M, Szkudlarek M. Magnetic resonance imaging of soft tissue changes in rheumatoid arthritis wrist joints. *Semin Musculoskelet Radiol* 2001;5:257-274
58. Tehranzadeh J, Ashikyan O, Anavim A, Tramma S. Enhanced MR imaging of tenosynovitis of hand and wrist in inflammatory arthritis. *Skeletal Radiol* 2006;35:814-822
59. McQueen F, Beckley V, Crabbe J, Robinson E, Yeoman S, Stewart N. Magnetic resonance imaging evidence of tendinopathy in early rheumatoid arthritis predicts tendon rupture at six years. *Arthritis Rheum* 2005;52:744-751
60. McGonagle D, Emery P. Enthesitis, osteitis, microbes, biomechanics, and immune reactivity in ankylosing spondylitis. *J Rheumatol* 2000;27:2302-2304.
61. Benjamin M, McGonagle D. The anatomical basis for disease localisation in seronegative spondyloarthropathy at entheses and related sites. *J Anat* 2001;199:503-526
62. Tan AL, Benjamin M, Toumi H, Grainger AJ, Tanner SF, Emery P, McGonagle D. The relationship between the extensor tendon enthesis and the nail in distal interphalangeal joint disease in psoriatic arthritis--a high-resolution MRI and histological study. *Rheumatology (Oxford)* 2007;46:253-256
63. Tan AL, Grainger AJ, Tanner SF, Emery P, McGonagle D. A high-resolution magnetic resonance imaging study of distal interphalangeal joint arthropathy in psoriatic arthritis and osteoarthritis: are they the same? *Arthritis Rheum* 2006;54:1328-1333
64. Erdem CZ, Sarikaya S, Erdem LO, Ozdolap S, Gundogdu S. MR imaging features of foot involvement in ankylosing spondylitis. *Eur J Radiol* 2005;53:110-119

65. Drossaers-Bakker KW, Kroon HM, Zwinderman AH, Breedveld FC, Hazes JMW. Radiographic damage of large joints in long-term rheumatoid arthritis and its relation to function. *Rheumatology* 2000;39:998-1003
66. Petersson CJ. Painful shoulders in patients with rheumatoid arthritis. Prevalence, clinical and radiological features. *Scand J Rheumatol* 1986;15:275-279
67. Bjelle A. Epidemiology of shoulder problems. *Baillieres Clin Rheumatol* 1989;3:437-451
68. Alasaarela E, Takalo R, Tervonen O, Hakala M, Suramo I. Sonography and MRI in the evaluation of painful arthritic shoulder. *Br J Rheumatol* 1997;36:996-1000.
69. Bruyn GA, Iagnocco A, Naredo E, Wakefield RJ, Schmidt WA. Ultrasonography of the shoulder in patients with rheumatoid arthritis: comment on the article by Hermann et al. *Arthritis Rheum* 2004;50:3054
70. Hermann KG, Backhaus M, Schink T, Hamm B, Bollow M. Ultrasonography of the shoulder in patients with rheumatoid arthritis: Author reply. *Arthritis Rheum* 2004;50:3055-3056
71. Scheel AK, Schmidt WA, Hermann KG, Bruyn GA, D'Agostino MA, Grassi W, Iagnocco A, Koski JM, Machold KP, Naredo E, Sattler H, Swen N, Szkudlarek M, Wakefield RJ, Ziswiler HR, Pasewaldt D, Werner C, Backhaus M. Interobserver reliability of rheumatologists performing musculoskeletal ultrasonography: results from a EULAR "Train the trainers" course. *Ann Rheum Dis* 2005;64:1043-1049
72. Wakefield RJ, Balint PV, Szkudlarek M, Filippucci E, Backhaus M, D'Agostino MA, Sanchez EN, Iagnocco A, Schmidt WA, Bruyn GA, Kane D, O'Connor PJ, Manger B, Joshua F, Koski J, Grassi W, Lassere MN, Swen N, Kainberger F, Klauser A, Ostergaard M, Brown AK, Machold KP, Conaghan PG. Musculoskeletal ultrasound including definitions for ultrasonographic pathology. *J Rheumatol* 2005;32:2485-2487
73. Wakefield RJ, D'Agostino MA, Iagnocco A, Filippucci E, Backhaus M, Scheel AK, Joshua F, Naredo E, Schmidt WA, Grassi W, Moller I, Pineda C, Klauser A, Szkudlarek M, Terslev L, Balint P, Bruyn GA, Swen WA, Jousse-Joulin S, Kane D, Koski JM, O'Connor P, Milutinovic S, Conaghan PG, Group OU. The OMERACT Ultrasound Group: status of current activities and research directions. *J Rheumatol* 2007;34:848-851
74. Tamai M, Kawakami A, Uetani M, Takao S, Rashid H, Tanaka F, Fujikawa K, Aramaki T, Nakamura H, Iwanaga N, Izumi Y, Arima K, Aratake K, Kamachi M, Huang

- M, Origuchi T, Ida H, Aoyagi K, Eguchi K. Early prediction of rheumatoid arthritis by serological variables and magnetic resonance imaging of the wrists and finger joints: results from prospective clinical examination. *Ann Rheum Dis* 2006;65:134-135
75. Sugimoto H, Takeda A, Hyodoh K. Early-stage rheumatoid arthritis: prospective study of the effectiveness of MR imaging for diagnosis. *Radiology* 2000;216:569-575
76. McQueen FM, Stewart N, Crabbe J, Robinson E, Yeoman S, Tan PL, McLean L. Magnetic resonance imaging of the wrist in early rheumatoid arthritis reveals progression of erosions despite clinical improvement. *Ann Rheum Dis* 1999;58:156-163
77. Bresnihan B, Kane D. Sonography and subclinical synovitis. *Ann Rheum Dis* 2004;63:333-334
78. Savnik A, Malmskov H, Thomsen HS, Graff LB, Nielsen H, Danneskiold-Samsøe B, Boesen J, Bliddal H. MRI of the wrist and finger joints in inflammatory joint diseases at 1-year interval: MRI features to predict bone erosions. *Eur Radiol* 2002;12:1203-1210
79. Ejbjerg B, Narvestad E, Rostrup E, Szkudlarek M, Jacobsen S, Thomsen HS, Ostergaard M. Magnetic resonance imaging of wrist and finger joints in healthy subjects occasionally shows changes resembling erosions and synovitis as seen in rheumatoid arthritis. *Arthritis Rheum* 2004;50:1097-1106
80. Freeston JE, Olech E, Yocum D, Hensor EM, Emery P, Conaghan PG. A modification of the Omeract RA MRI score for erosions for use with an extremity MRI system with reduced field of view. *Ann Rheum Dis* 2007;66:1669-1671
81. Duer-Jensen A, Ejbjerg B, Albrecht-Beste E, Vestergaard A, Møller Dohn U, Lund Hetland M, Ostergaard M. Does low-field dedicated extremity MRI (E-MRI) reliably detect RA bone erosions? A comparison of two different E-MRI units and conventional radiography with high resolution CT. *Ann Rheum Dis* 2008

## ERKLÄRUNG

§ 4 Abs. 3 (k) der HabOMed der Charité

Hiermit erkläre ich, dass

- weder früher noch gleichzeitig ein Habilitationsverfahren durchgeführt oder angemeldet wurde.
- die vorgelegte Habilitationsschrift ohne fremde Hilfe verfasst, die beschriebenen Ergebnisse selbst gewonnen sowie die verwendeten Hilfsmittel, die Zusammenarbeit mit anderen Wissenschaftlern / Wissenschaftlerinnen und mit technischen Hilfskräften sowie die verwendete Literatur vollständig in der Habilitationsschrift angegeben wurde.
- mir die geltende Habilitationsordnung bekannt ist.

20. April 2009

---

## DANKSAGUNG

Besonders bedanken möchte ich mich bei meiner Mutter, meinem Vater und meiner lieben Frau Sandra, die mein Studium und die anschließende wissenschaftliche Laufbahn auf vielfältige Weise unterstützt und gefördert haben.

Herrn Prof. Dr. Bernd Hamm danke ich für den kontinuierlichen Support meiner Ausbildung und wissenschaftlichen Studien, die nur durch die gute Ausstattung des Instituts für Radiologie der Charité möglich waren.

Mein Interesse für die muskuloskelettale Bildgebung weckten insbesondere PD Dr. Dieter Loreck, der leider viel zu früh verstorben ist, und Prof. Dr. Matthias Bollow. Insbesondere Matthias' Selbstlosigkeit war eine große Hilfe für mich und meine Familie. In besonderem Maße förderlich für die verschiedenen Studien war die Tätigkeit von Dr. Iris Eshed als Research Fellow und die Mitarbeit von Dr. Christian Althoff. Diesen vier Menschen war bzw. bin ich auch privat in tiefer Freundschaft verbunden.

Die Forschungstätigkeit von PD Dr. Alexander Scheel an der Charité legte den wesentlichen Grundstein für diverse Studien zur Niederfeld-MRT. Wir konnten beide viel voneinander profitieren und ich bin dafür sehr dankbar.

Die sehr enge, langjährige Kooperation mit der Medizinischen Klinik für klinische Immunologie und Rheumatologie ist die Basis für unsere Forschungstätigkeit auf dem Gebiet der Arthritis-Bildgebung. Mein Dank gilt insbesondere Frau PD Dr. Marina Backhaus, Herrn PD Dr. Eugen Feist, Herrn Dr. Udo Schneider und Herrn Prof. Dr. Gerd-Rüdiger Burmester.

Frau Dr. rer. medic Tania Schink, MPH, vom Institut für Biometrie und klinische Epidemiologie der Charité danke ich für die fundierte und fruchtbare Zusammenarbeit in statistischen Fragen, die leider viel zu kurz war.

Meinen ehemaligen Doktorandinnen Dr. Svenda Zühlsdorf und Dr. Claudia Schirmer danke ich für die Erhebung wertvoller wissenschaftlicher Daten und die unkomplizierte Zusammenarbeit.

Allen Mitarbeitern des Instituts für Radiologie der Charité danke ich für Ihre Unterstützung und Kollegialität. Insbesondere gebührt mein Dank meinen Kollegen Dr. Alexander

Lembcke, Dr. Matthias Mühler und Prof. Dr. Matthias Taupitz sowie meinem ehemaligen Kollegen PD Dr. Dietmar Kivelitz. Bedanken möchte ich mich nicht zuletzt auch bei Frau Heike Giese und Frau Gabriele Förster für das Schreiben von Manuskripten und der Habilitationsschrift sowie die allgemeine exzellente Unterstützung meiner Tätigkeit, bei Frau Bettina Herwig für ihre exzellenten Dienste bei der Übersetzung der Manuskripte und Abstracts und den medizinisch-technischen Assistentinnen Frau Anne Kathrin Gellert, Frau Ute Tenner, Frau Annette Teßmann und Frau Elke Smid für Ihren Einsatz am Niederfeld-MRT.