

# Epidemiological study of congenital malformations of the vertebral column in French bulldogs, English bulldogs and pugs

Felix Lackmann<sup>1</sup>  | Franck Forterre<sup>2</sup> | Leo Brunberg<sup>1</sup> | Shenja Loderstedt<sup>3</sup> 

<sup>1</sup> Small Animal Clinic, Department of Veterinary Medicine, Freie Universität Berlin, Berlin, Germany

<sup>2</sup> Small Animal Clinic, Department of Clinical Veterinary Medicine, Vetsuisse-Faculty, University Bern, Bern, Switzerland

<sup>3</sup> Department for Small Animal, Faculty of Veterinary Medicine, Leipzig University, Leipzig, Germany

## Correspondence

Felix Lackmann, Small Animal Clinic, Department of Veterinary Medicine, Freie Universität Berlin, 14163 Berlin, Germany.  
Email: [Felix.Lackmann@fu-berlin.de](mailto:Felix.Lackmann@fu-berlin.de)

## Abstract

**Background:** Congenital vertebral body malformations (CVBMs) have retrospectively been investigated in British and American canine populations. This study prospectively evaluates occurrence, localization, type and characteristic of CVBM along the entire vertebral column in a cohort of French Bulldogs, English Bulldogs and Pug dogs from Germany.

**Methods:** Prospective clinical and radiological screenings for CVBM were performed in brachycephalic dogs presented for reasons unrelated to neurological problems. Neurological and orthopaedic examinations as well as radiographs in two orthogonal planes of the entire vertebral column including the tail were performed in all dogs. Cobb angle and vertebral step were determined. Associations between CVBM, tail malformation, neurological deficits and occurrence of concurrent orthopaedic diseases were investigated.

**Results:** A total of 707 VBMs were identified in the whole vertebral column of 169 of 265 brachycephalic dogs. The most common types of CVBMs were ventral wedge shape (48%), dorsal wedge shape (14%) and shortened vertebral body (14%). A new type of malformation was investigated: dorsal wedge shape vertebrae. There was significant association between severe tail malformations with CVBM. Neurological deficits were significantly associated with ventrolateral wedge shape, dorso lateral hemivertebrae, Cobb angle > 30% and vertebral step  $\geq 1.75$  mm. Orthopaedic conditions were not significantly associated with CVBM.

**Conclusion:** Kyphotic Cobb angle and vertebral step are radiological findings associated with neurological deficits. We propose severe tail malformation as an easy and accurate selection factor for determining breeding dogs.

## KEYWORDS

neurology, neuroradiology, radiography

## INTRODUCTION

Congenital vertebral body malformations (CVBMs) are commonly diagnosed conditions in brachycephalic canine breeds that have been retrospectively investigated, especially in British and American canine populations.<sup>1–14</sup> Vertebral body malformations' origin is classified as either defects of segmentation (block vertebra) or defects of formation, which can be differentiated in aplastic (hemivertebrae) and hypoplastic malformations (wedge shape vertebrae, butterfly

vertebrae), transitional vertebrae and neural tube defects.<sup>4,12,15</sup> They often are incidental findings during diagnostic imaging investigation regarding clinical issues unrelated to the vertebral column.<sup>4,7,9,12,15–19</sup> Dogs can show radiological signs like deviation of normal vertebral axis (kyphosis, lordosis, scoliosis) or vertebral step formation.<sup>2,4,6,9,12,17,19–23</sup> If neurological deficits are present, myelopathic signs are thought to be associated with both number and type of thoracolumbar vertebral malformations.<sup>6,24</sup> More recent literature findings consider the rising cobb angle and

This is an open access article under the terms of the [Creative Commons Attribution-NonCommercial](https://creativecommons.org/licenses/by-nc/4.0/) License, which permits use, distribution and reproduction in any medium, provided the original work is properly cited and is not used for commercial purposes.

© 2021 The Authors. *Veterinary Record* published by John Wiley & Sons Ltd on behalf of British Veterinary Association

vertebral step both caused by vertebral malformations to be associated with neurological deficits.<sup>2,6,9,21,23</sup> CVBM are present in the whole vertebral column and its extension, the tail.<sup>5,10</sup> The curve of a short and curled tail in brachycephalic dogs is caused by CVBM.<sup>10</sup> Breeding towards a corkscrew curled tail is a suspected cause why CVBMs are indirectly bred into the whole vertebral column of brachycephalic dogs.<sup>5,25</sup>

Orthopaedic diseases such as hip dysplasia (HD) and patellar luxation are rarely described in brachycephalic dogs.<sup>7,11,26–29</sup> A possible relationship between CVBM and orthopaedic diseases in dogs has not previously been reported. In human medicine recent studies have shown a close relationship between spine and hip motion during movement<sup>30</sup> and how normal and abnormal spinal axis influences femoral-hip articulation.<sup>31,32</sup> If the vertebral column and hind limbs are a functional unity and if the stiffness of the vertebral column can decrease the tilt of the pelvis,<sup>30</sup> could there be a possible correlation between CVBM and HD or patellar luxation in dogs?

Almost all studies investigating CVBM are retrospective, describing a defined segment of the vertebral column and commonly include a low number of patients.<sup>2–5,8,9,15,17,19,21</sup> The aim of the study was to prospectively evaluate the associations between CVBM along the entire vertebral column and tail malformation, neurological deficits, as well as occurrence of accompanying orthopaedic diseases, specifically HD and patellar luxation in a cohort of brachycephalic dogs from Germany. The hypotheses of the study were: (i) Distribution and types of CVBM in a German brachycephalic dog population do not differ from reported results in literature. (ii) The degree of tail malformation is associated with vertebral malformation of the thoracolumbar vertebral column. (iii) Accompanying orthopaedic diseases, specifically HD and patellar luxation are associated with CVBM.

## MATERIAL AND METHODS

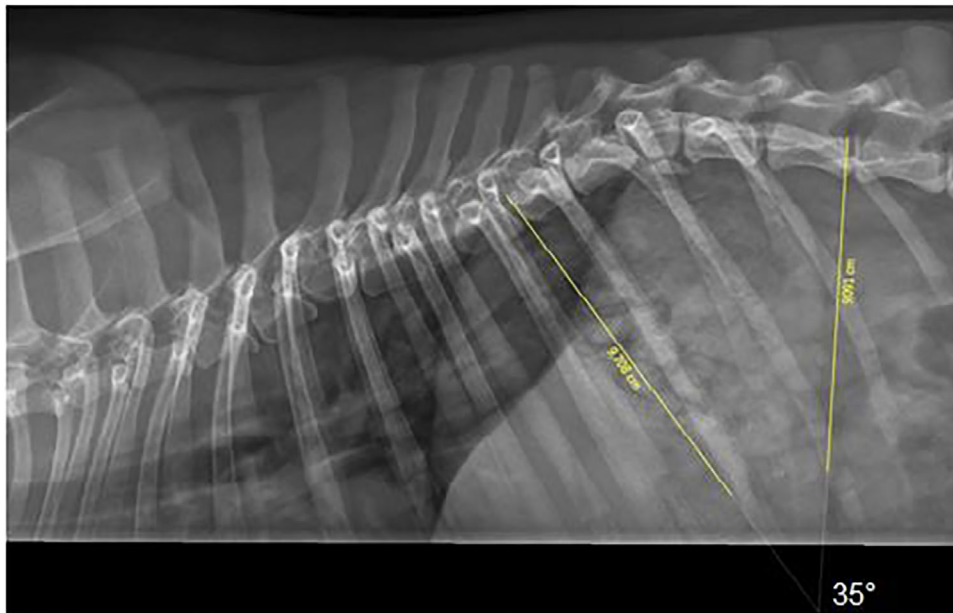
In this prospective clinical cross-sectional study, we investigated a total of 265 brachycephalic dogs including French Bulldogs, English Bulldogs and Pugs. A power analysis was performed in preparation of this study to investigate the minimum numbers of dogs required for the investigation (significance level 0.05). All dogs were presented to Small Animal Clinic, Department of Veterinary Medicine, Freie Universität Berlin between 2014 and 2016, and their owners gave written consent to participate in the survey. The study was approved by the State Office for Health and Social Affairs Berlin (Reg. 0151/15). Dogs were included regardless of presence of neurological deficits if their owners considered them neurologically normal or had no concerns regarding the neurological status. A total of 81 of 265 dogs were presented with problems and diseases of eyes, ears, skin, airways or gastrointestinal tract. The other 184 of 265 dogs were privately owned pets that volunteered in cooperation with kennel

**TABLE 1** Categorization of tail malformations

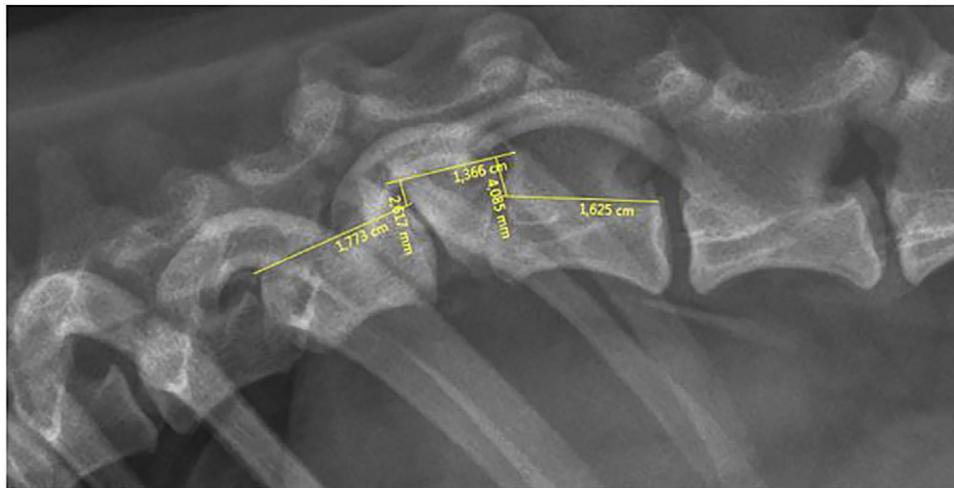
Severity of tail malformations	Number of nonmalformed caudal vertebra
Nonmalformed	No malformed caudal vertebra
Minimal malformations	>4 nonmalformed caudal vertebra
Moderate malformations	2–3 nonmalformed caudal vertebra
Severe malformations	0–1 nonmalformed caudal vertebra

clubs and presented exclusively to participate in the study. All dogs underwent complete clinical, neurological, orthopaedic and radiographic examinations. All examinations were performed by the first author under supervision of an orthopaedic and neurology specialist (Leo Brunnberg, Shenja Loderstedt). Signs of myelopathy were scored regardless of the neuroanatomical localisation of the spinal cord deficits orientating on the modified Frankel score (0 = unremarkable, 1 = pain without neurological deficits, 2 = ambulatory paresis, 3 = non ambulatory paresis, 4 = plegia with deep pain perception, 5 = without deep pain perception). All dogs were radiographed under unsedated conditions restrained and positioned by the first author and a technical assistant. Three times two orthogonal radiographs of the vertebral column in laterolateral and ventrodorsal planes were performed of the following spinal sections: Occiput – T1/2, C6/7 – L1-2, T12/13 – end of the tail. The quality of the images was assessed by the authors (Felix Lackmann, Leo Brunnberg, Shenja Loderstedt) and if necessary a radiograph was repeated. Radiographs were evaluated by the authors (Felix Lackmann, Leo Brunnberg, Shenja Loderstedt) which were blinded to the patients data. Number, localization and type of malformation, based on the proposed classification scheme by Gutierrez-Quintana et al<sup>4</sup> and evidence of other types of malformations were documented. The Cobb angle of the most deviated area of affected vertebral column was measured as described by Guevar et al<sup>22</sup> (Figure 1), and the cut off for clinically relevant spinal deviation of 30° was used.<sup>22</sup> In case a vertebral step was evident on radiographs, the height of the step was measured as described by Moissonnier et al<sup>6</sup> (Figure 2). A cut-off for clinical relevant vertebral step of 1.75 mm was used.<sup>6</sup> For assessment of the tail malformations, the number of nonmalformed caudal vertebrae was evaluated, and the severity of tail malformation was categorized based on the number of radiologically nonmalformed caudal vertebra (Table 1). During orthopaedic examination abnormal findings were recorded, and particular attention was paid to signs of patella luxation (PL) and HD. The radiographs were evaluated by the first author and a radiologic specialist, with regard to structural changes of the acetabulum and femoral head that indicate HD.

Statistical analysis was carried out under support of the Institute of Veterinary Epidemiology and Biometry for statistical support and all dogs and dog owners for participating in this study. And chi-square test, odd-ratio test and descriptive statistic were used (IBM SPSS Statistics 24).



**FIGURE 1** Radiograph of the spine of a French Bulldog, female, 2.5 years, laterolateral projection, measurement of the Cobb-angle (–,–)



**FIGURE 2** Radiograph of the thoracolumbar junction of the spine of a French Bulldog, female, 3 years, laterolateral projection (–,–)

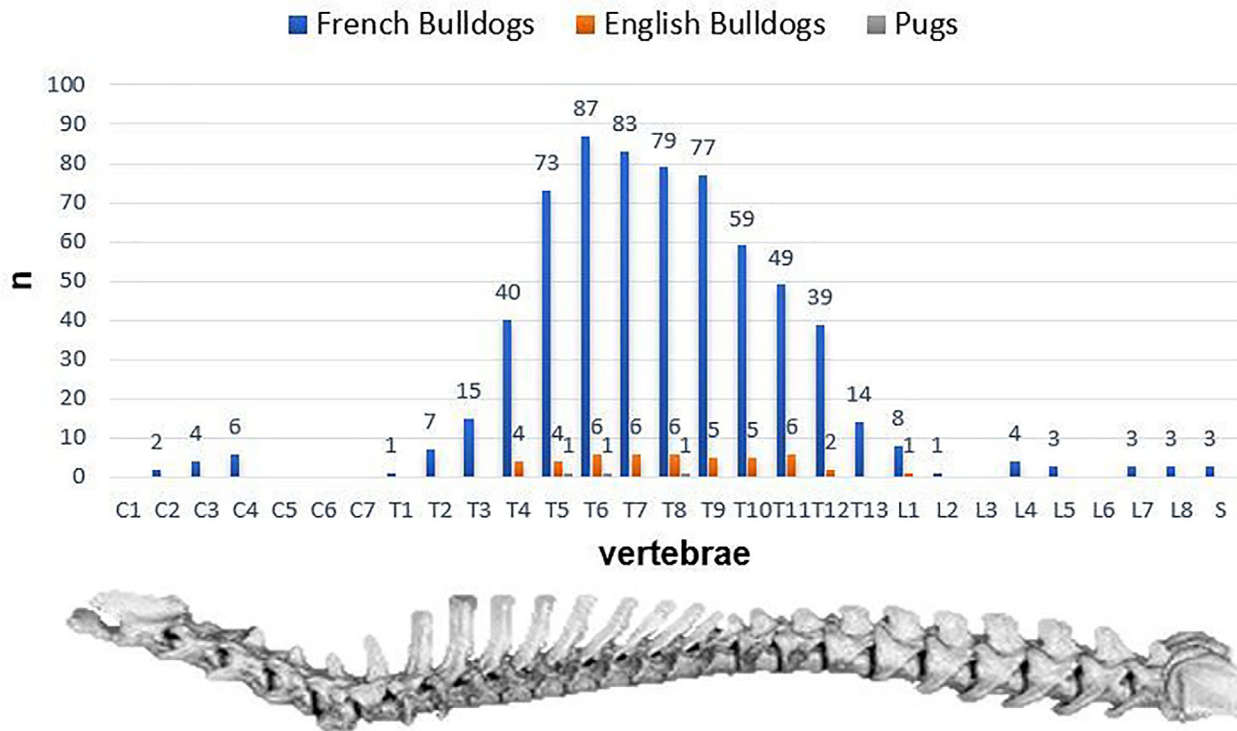
## RESULTS

In this study, a total of 268 brachycephalic dogs were examined. Three dogs had to be excluded, since they did not tolerate positioning for radiographs. Therefore, 265 dogs of the following breeds were included in the study: 199 French Bulldogs, 54 Pugs and 12 English Bulldogs. The median age was 3.6 years (1–13 years). Eighty were intact male, 55 male castrated, 76 were intact female and 54 female castrated. The median body weight was 12.4 kg for French Bulldogs (7.4–18.0 kg), 8.6 kg for Pugs (5.0–11.5 kg) and 29.2 kg for English Bulldogs (10–39.4 kg).

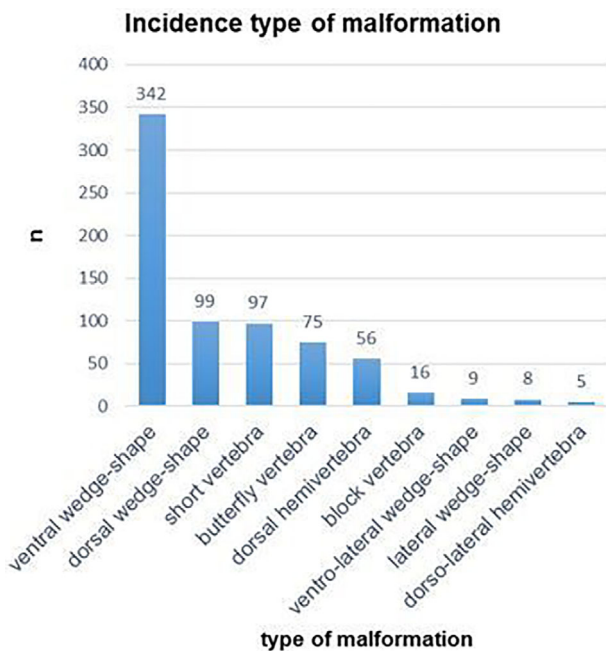
Neurological deficits were present in 55% (145/265) of all the examined dogs. All affected dogs revealed symptoms related to a T3–L3 myelopathy. Of those, 82.6% (120/145) were Frankel score 2, 7.7% (11/145) Frankel score 1, 6.2% (9/145) Frankel score 3, 2.0% (3/145) Frankel score 4 and 1.5% (2/145) Frankel score 5.

In total 707 vertebral malformations were diagnosed in 63.8% of all dogs (169/265). One or more vertebral malformations were diagnosed in 157 of 199 (78.9%) French Bulldogs, 10 of 12 (83.4%) English Bulldogs and 2 of 54 (3.7%) Pugs. There was no association between malformation and gender ( $p > 0.05$ ). The most common localization for vertebral malformations was the region between the fourth to ninth thoracic vertebral bodies in all breeds (Figure 3). Cervical (11/707) and lumbar (22/707) vertebral anomalies were only rarely observed. The types of malformation were distributed as follows: ventral wedge shape 48% (342/707), dorsal wedge shape 14% (99/707), shortened vertebral body 14% (97/707), butterfly 11% (75/707), dorsal hemivertebra 7.9% (56/707), block vertebra 2.3% (16/707), ventrolateral wedge shape 1.3% (9/707), lateral wedge shape 1.1% (8/707) and dorsolateral hemivertebra 0.7% (5/707) (Figure 4). Considering specific types of vertebral malformations only ventrolateral wedge shape and dorsolateral hemivertebra were positively

### Amount and localisation of congenital vertebral body malformations of each breed



**FIGURE 3** Distribution of vertebral malformation along the entire spine in total numbers and of each breed. Overall 707 vertebral malformation were identified



**FIGURE 4** Bar chart of the incidence of type of malformation

correlated with neurological deficits ( $p$  0.009). However, 98% of all vertebral malformations were not associated with neurological deficits. A significant statistical association between neurological deficits and the appearance of vertebral malformations at the thoracolumbar junction (T11-L2) could not be shown ( $p$  0.239).

A Cobb angle and vertebral step were detected in 64% (170/265) of all dogs, of which 39% (67/170) were neurologically normal, and 61% (103/170) had myelopathic signs. The Cobb angle was  $>30^\circ$  in 3% (2/67) of all neurologically normal dogs. Dogs with spinal cord deficits had a Cobb angle of  $>30^\circ$  in 23% (24/103) and  $<30^\circ$  in 77% (79/103) of the cases. A Cobb angle  $> 30^\circ$  increased the risk of neurological deficits by factor 9.87 (OR) and was positively correlated with neurological deficits ( $p < 0.001$ ).

A vertebral step of  $<1.75$  mm was seen in 84% (56/67) and  $\geq 1.75$  mm in 16% (11/67) of all neurologically normal dogs. In dogs with neurological deficits, 69% (71/103) had a vertebral step  $< 1.75$  mm and 31% (32/103)  $\geq 1.75$  mm. Thus, a vertebral step  $\geq 1.75$  mm was positively correlated with the presence of neurological deficits ( $p$  0.032) and increased their risk by factor 2.29 (OR).

Malformations of the caudal vertebrae were found in 80% of all cases: 99% (197/199) in French Bulldogs, 100% (12/12) in English Bulldogs and 6% (3/54) in Pugs. Only severe malformation of the tail was significantly associated with vertebral malformations located cranial to the tail ( $p < 0.001$ ). These severe malformations were present in 59% (125/212) of all cases. Compared to dogs with no minimal or moderate tail malformations, the risk of one or more vertebral malformations in the cervical, thoracic or lumbar vertebral column was increased by a factor 16 (OR) in dogs with severe tail malformations.

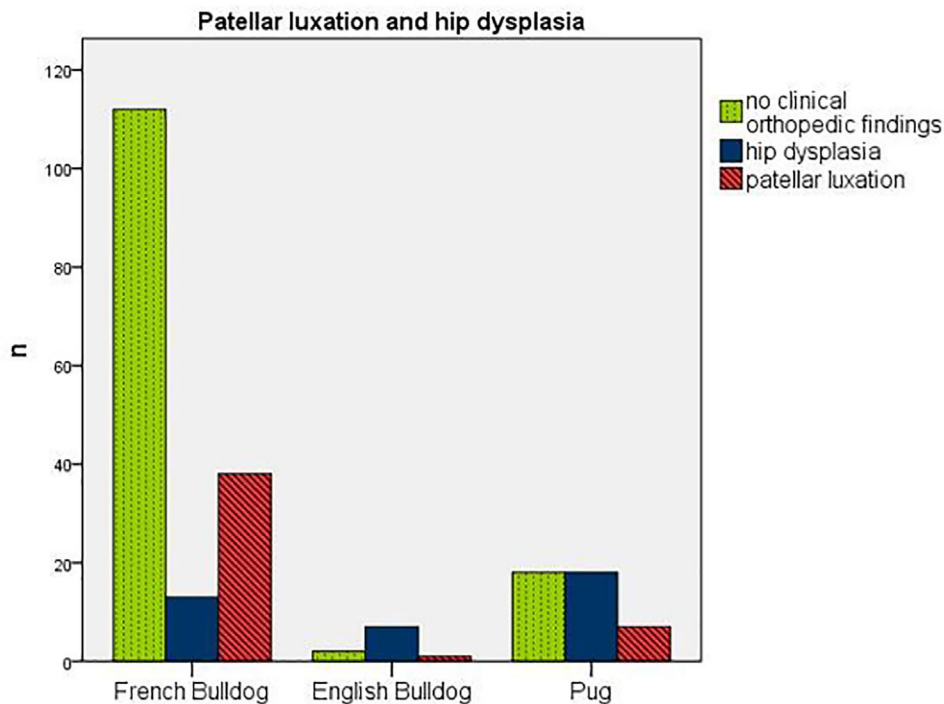


FIGURE 5 Bar chart of dogs with no clinical orthopaedic findings or patellar luxation and/or hip dysplasia

In 82% (216/265) of all dogs, a full orthopaedic examination and radiological assessment of HD was possible (Figure 5). The orthopaedic examinations resulted in abnormal findings in 32% (52/163) of French Bulldogs, 80% (8/10) of English Bulldogs and 58% of Pugs. Clinical diagnoses of PL (Grade I-IV) were established in 23% (38/163) of French Bulldogs, 10% (1/10) of English Bulldogs and 16% (7/43) of Pugs. Radiological diagnosis of HD was made in 8% (13/163) of French Bulldogs, 70% (7/10) of English Bulldogs and 42% (18/43) of Pugs. One or more vertebral malformations were diagnosed in 50% of all dogs with HD (19/38) and 67% of dogs with patellar luxation (31/46). No significant association between HD, PL and CVBM could be detected ( $p > 0.05$ ).

## DISCUSSION

CVBMs often are diagnosed in brachycephalic breeds.<sup>1-14,33</sup> Here, we present a prospective study investigating CVBM in brachycephalic dog breeds (French Bulldog, English Bulldog, Pug) confirming that radiographic assessment of vertebral step and angulation in the region of malformations is of clinical relevance with regard to neurological deficits.

To compare our results regarding the types of vertebral malformation with relevant veterinary literature,<sup>2,4,8,9,15,18,25</sup> we used the classification proposed by Gutierrez-Quintana et al.<sup>4</sup> In addition to the used classification we investigate two types of vertebral malformations not described in the used classification: dorsal wedge shape vertebra and ventrolateral wedge shape vertebra. During the writing process of this paper, the research group who published the first classification of vertebral malformation

completed their scheme with the ventro lateral wedge shape vertebra.<sup>9</sup> In our study the ventrolateral wedge shape vertebra appeared very rarely in only 1.3% (9/707) of cases. A graduation of the wedge shape vertebra as a percentage of the dorsal and ventral vertebral length as described by Meyer<sup>18</sup> and Schlenker and Distl<sup>25</sup> was not found clinically applicable in our study.

In this study, CVBMs were found in 83% of English Bulldogs, 79% of French Bulldogs and 3.7% of Pugs. These results are comparable with the results in veterinary literature where CVBMs are reported in 46.2%–93.5% of cases in French Bulldogs,<sup>7,18,19,29</sup> in 73.2%–97.3% of cases in English Bulldogs<sup>7,19,34</sup> and in 17.6% of cases in Pugs.<sup>3,13,19</sup> The most common localization for CVBM in this dog population was the fourth to ninth thoracic vertebra, which also is consistent with the published literature.<sup>3,6,7</sup> There was no correlation ( $p > 0.05$ ) between vertebral malformation in the thoracolumbar junction and neurological deficits. However, several German Breeding Clubs (e.g., Norddeutscher Bulldog Club [2019], Verband Deutscher Rassehunde e.V. [2019]) consider vertebral malformations at the thoracolumbar junction as disqualifying criteria for breeding. Considering the results of this study, this regulation appears rather questionable and adaptation of breeding regulations to include the T4-9 vertebrae may be warranted.

Ventrolateral wedge shape vertebra (1.3% (9/707)) and dorsolateral hemivertebra (0.7% (5/707)) were rarely observed in the dog population examined in this study, but were significantly associated with neurological deficits ( $p 0.009$ ). The risk for neurological deficits with one or both of these two malformations was 9.7 (OR) times higher than for dogs without those. Both types of malformation will lead to kyphoscoliosis.

Faller et al<sup>21</sup> described a higher prevalence of intervertebral disc degeneration in dogs with kyphoscoliosis. Intervertebral disc degeneration itself is known to increase the risk for compressive intervertebral disc disease and therefore neurological deficits.<sup>8,35,36</sup> Further, a significant association between intervertebral disc extrusion and kyphosis has been described for French Bulldogs and Pugs.<sup>9,23</sup> So, despite the low number of the two discussed vertebral malformations (14/707) associated with neurological deficits in this study, our findings can be interpreted in agreement with recent literature.

There are different methods of Cobb angle measurements veterinary literature, that all describe measurements of the vertebral angulation in brachycephalic dogs as a reliable procedure to assess the degree of kyphosis and scoliosis and to specify the clinical relevance of vertebral malformations.<sup>6,22,23</sup> All studies that investigate Cobb angles in dogs are more or less in accord with the results presented by Moissonnier et al<sup>6</sup> who described a mean angle of 133° in brachycephalic dogs with neurological deficits. Moreover, the study reports that in 32 dogs without neurological deficits and with vertebral malformations, the mean angle was 170°. The present study used the Cobb angle measurement described by Guevar et al.<sup>22</sup> The significant correlation of a Cobb angle > 30° and neurological deficits ( $p < 0.001$ ) found in our study only slightly differs from the results of other studies. There, the authors considered a Cobb angle > 35° very likely to cause present or future neurological problems<sup>19</sup> or of 34.5° to differentiate between dogs with and without neurological signs.<sup>17</sup>

Beside the Cobb angle, the vertebral step has also been described as a risk factor for neurological deficits in brachycephalic dogs with vertebral malformations.<sup>6</sup> Moissonnier et al<sup>6</sup> showed that dogs with wedge shape vertebra and no neurological deficits had no vertebral step, whereas dogs with neurological deficits had a mean step of 1.75 mm right at the location of the respective malformation. The authors concluded that the neurological abnormalities are not caused primarily by the vertebral malformations, but by the angulation and the step between malformed vertebral bodies. This is supported in the present study, in which dogs with neurological deficits had a significantly higher vertebral step ( $p$  0.032), and a step of  $\geq 1.75$  mm increased the risk by a factor of 2.29 (OR).

Projection radiography was chosen in this prospective study to evaluate for vertebral malformation due to comprehensive availability in veterinary general practices, comparatively low cost since general anaesthesia is not necessarily mandatory and ability to identify VBMs clinically sufficient and to be able to compare them to radiographic classifications. A recent study shows that identifying brachycephalic dogs as being spinal malformation free was not statistically different when comparing orthogonal radiography and computer tomography.<sup>20</sup> The same authors also describe the agreement between both modalities as fair to good on the presence or absence of CVBM but as poor to slight on the type of CVBM. Advanced diagnos-

tic imaging, such as CT, CT-myelography or magnetic resonance imaging was not used in this study. Due to the radiographic technique, measurement inaccuracies are possible when evaluating angulation or vertebral step.

The present study included more dogs with neurological deficits (55% [145/265]) compared to other studies.<sup>4,6,15,19,22</sup> The most likely explanation for this difference is the prospective design of the investigation, different inclusion criteria and neurological examination under supervision of a neurologist of all participating dogs which might have resulted in the higher sensitivity to detect subtle paresis.

It is well accepted that dogs with malformed screw tails are predisposed for other vertebral malformations.<sup>1-4,6,8,10,12,14,37</sup> In recent literature, a frame shift mutation in DISHEVELLED 2 gene was reported, which segregates with thoracic and caudal vertebral column malformations in screw tailed dogs.<sup>37</sup> The relationship between severe caudal vertebral malformation and malformation of other parts of the vertebral column could also be confirmed in the data presented. In accordance with our findings, Schlensker and Distl<sup>25</sup> showed an association between the number of abnormal caudal vertebral body and the degree and number of wedge shape vertebra in the more cranial vertebral column. Another study investigated 149 CT scans of the lumbar, sacral and caudal vertebral column and found similar results and a correlation between tail malformation and vertebral malformation of L7 and S1.<sup>15</sup> That leads to the assumption that, if the degree of tail malformation assessed by clinical examination is coherent with the degree of malformation observed during radiological evaluation, the tail phenotype may be an easy and accurate selection factor to determine breeding dogs. Further studies are necessary to confirm this hypothesis. Considering the different length of the dogs' tails and the radiologically often indistinguishable malformed caudal vertebrae, an objective count of malformed vertebral bodies was not possible in most cases in our study. In contrast, the identification of radiologically nonmalformed vertebrae was objectively possible. Further, only a low number of dogs belonging to the breeds investigated in this study carried a longer tail. The absence of a 'normal' tail length itself has to be interpreted as malformation. Under consideration of the aforementioned, the tail malformation classification proposed here was based on the number of nonmalformed caudal vertebrae.

The Canine Health Information Center (2018) published incidences of HD and PL.<sup>38</sup> Their data for HD in English Bulldog (71.6%) are comparable with the results presented in this study. On the other hand, the incidences in French Bulldogs (30.4%) and Pugs (71%) are higher than our results. The data published for PL in an American and English population were overall lower (Pugs 3.5%–5.4%, English Bulldogs 2.9%–4.5%, French Bulldogs 4.0%–5.5%) compared to our results.<sup>29,38</sup> The occurrence of PL in English Bulldogs in Finland (33%) is higher than ours.<sup>7</sup> One possible explanation for this discrepancy could be the different

genetic pool of brachycephalic dogs from different regions worldwide or the difference is caused by the small sample size. However, no statistically significant association between CBVM and the aforementioned orthopaedic diseases was identified.

This study has several limitations. The dogs have not been under general anaesthesia for projection radiography. This could have had an influence on the radiographic quality and may have affected the accuracy of measurements for the Cobb angle and vertebral step. An intermodality and interobserver assessment is needed to clarify this question. The number of dogs of different breeds diverged; therefore no comparison was made among the groups, and the statements about the English Bulldogs alone have no power. Finally, other myelopathic disease processes that could have accompanied the vertebral malformations have not been ruled out, and the relationship of vertebral malformations and neurological deficits as described in this study has to be interpreted in light of this.

## CONCLUSION

The radiographic assessment of vertebral step and angulation (Cobb angle) in the region of malformations are of clinical relevance with regard to neurological deficits. Vertebral step, angulation (Cobb angle), vertebral malformation causing kyphoscoliosis and high severity of caudal vertebral malformation could be objective criteria for clinical assessment of individual dogs and for breeding selection.

## ACKNOWLEDGEMENTS

The authors want to thank Nadia Shihab and Emma Davies for language editing and proofreading, the Institute of Veterinary Epidemiology and Biometry for statistical support and all dogs and dog owners for participating in this study. Open Access Funding Enabled and Organized by Projekt DEAL.

## AUTHOR CONTRIBUTIONS

Felix Lackmann was spear-heading the practical realization of this study and drafted and edited the manuscript. Franck Forterre was involved in writing and editing of the manuscript. Leo Brunnberg supervised and designed the practical parts of this study and edited the manuscript. Shenja Loderstedt designed and supervised the study and was involved in writing and editing of the manuscript.


## CONFLICT OF INTEREST

The authors declare that there is no conflict of interest that could be perceived as prejudicing the impartiality of the research reported.

## ETHICS APPROVAL

The study was approved by the State Office for Health and Social Affairs Berlin (Reg. 0151/15).

## ORCID

Felix Lackmann  <https://orcid.org/0000-0002-4381-3226>

Shenja Loderstedt  <https://orcid.org/0000-0001-9987-5349>

## REFERENCES

1. Aikawa T, Shibata M, Asano M, Hara Y, Tagawa M, Orima H. A comparison of thoracolumbar intervertebral disc extrusion in French Bulldogs and Dachshunds and association with congenital vertebral anomalies. *Vet Surg.* 2014;43(3):301–7.
2. Dewey CW, Davies E, Bouma JL. Kyphosis and kyphoscoliosis associated with congenital malformations of the thoracic vertebral bodies in dogs. *Vet Clin N Am Small.* 2016;46(2):295–306.
3. Done SH, Drew RA, Robins GM, Lane JG. Hemivertebra in dog - clinical and pathological observations. *Vet Rec.* 1975;96(14):313–7.
4. Gutierrez-Quintana R, Guevar J, Stalin C, Faller K, Yeaman C, Penderis J. A proposed radiographic classification scheme for congenital thoracic vertebral malformations in brachycephalic “screw-tailed” dog breeds. *Vet Radiol Ultrasound.* 2014;55(6):585–91.
5. Kramer JW, Sande RD, Rantanen NW, Whitener EK. Characterization of heritable thoracic hemivertebra of the German Short-haired Pointer. *J Am Vet Med Assoc.* 1982;181(8):814–5.
6. Moissonnier P, Gossot P, Scotti S. Thoracic kyphosis associated with hemivertebra. *Vet Surg.* 2011;40(8):1029–32.
7. Mölsä SH, Hyytiäinen HK, Morelius KM, Palmu MK, Pesonen TS, Lappalainen AK. Radiographic findings have an association with weight bearing and locomotion in English bulldogs. *Acta Vet Scand.* 2020;62(1). <https://doi.org/10.1186/s13028-020-00517-3>.
8. Morgan JP. Congenital anomalies of vertebral column of dog - a study of incidence and significance based on a radiographic and morphologic study. *J Am Vet Radiol Soc.* 1968;9:21–9.
9. Ryan R, Gutierrez-Quintana R, ter Haar G, De Decker S. Relationship between breed, hemivertebra subtype, and kyphosis in apparently neurologically normal French Bulldogs, English Bulldogs, and Pugs. *Am J Vet Res.* 2019;80(2):189–94.
10. Schlensker E, Distl O. Appearance and heredity of hemivertebra in dogs. *Prakt Tierarzt.* 2012;93(1):14–23.
11. Volta A, Gnudi G, Morgan JP, Bonazzi M, Manfredi S, Bottarelli E, et al. Radiographic features of pelvis and hip joint development of English Bulldogs. *Vet Comp Orthop Traumatol.* 2010;23(1):19–27.
12. Westworth DR, Sturges BK. Congenital spinal malformations in small animals. *Vet Clin N Am-Small.* 2010;40(5):951–81.
13. White D. Screening for hemivertebra in pugs. *Vet Rec.* 2013;173(1):24.
14. Wright JA. Congenital and developmental abnormalities of the vertebrae .15. radiological refresher. *J Small Anim Pract.* 1979;20(10):625–34.
15. Bertram S, Ter Haar G, De Decker S. Congenital malformations of the lumbosacral vertebral column are common in neurologically normal French Bulldogs, English Bulldogs, and Pugs, with breed-specific differences. *Vet Radiol Ultrasound.* 2019;60(4):400–8.
16. Chan G, Dormans JP. Update on congenital spinal deformities preoperative evaluation. *Spine.* 2009;34(17):1766–74.
17. De Decker S, Packer RMA, Cappello R, Harcourt-Brown TR, Rohdin C, Gomes SA, et al. Comparison of signalment and computed tomography findings in French Bulldogs, Pugs, and English Bulldogs with and without clinical signs associated with thoracic hemivertebra. *J Vet Intern Med.* 2019;33(5):2151–9.
18. Meyer S. Röntgenologische wirbelsäulenuntersuchungen bei gesunden Französischen Bulldoggen. Berlin: FU, vetreinärmed. Fak., Diss.; 2011.
19. Ryan R, Gutierrez-Quintana R, Ter Haar G, De Decker S. Prevalence of thoracic vertebral malformations in French bulldogs, Pugs and English bulldogs with and without associated neurological deficits. *Vet J.* 2017;221:25–9.

20. Brocal J, De Decker S, Jose-Lopez R, Guevar J, Ortega M, Parkin T, et al. Evaluation of radiography as a screening method for detection and characterisation of congenital vertebral malformations in dogs. *Vet Rec.* 2018;182(20):573.
21. Faller K, Penderis J, Stalin C, Guevar J, Yeaman C, Gutierrez-Quintana R. The effect of kyphoscoliosis on intervertebral disc degeneration in dogs. *Vet J.* 2014;200(3):449–51.
22. Guevar J, Penderis J, Faller K, Yeaman C, Stalin C, Gutierrez-Quintana R. Computer-assisted radiographic calculation of spinal curvature in brachycephalic “screw-tailed” dog breeds with congenital thoracic vertebral malformations: reliability and clinical evaluation. *PLoS One.* 2014;9(9):e106957.
23. Inglez de Souza M, Ryan R, Ter Haar G, Packer RMA, Volk HA, De Decker S. Evaluation of the influence of kyphosis and scoliosis on intervertebral disc extrusion in French bulldogs. *BMC Vet Res.* 2018;14(1):5.
24. Bollini G, Docquier PL, Viehweger E, Launay F, Jouve JL. Thoracolumbar hemivertebrae resection by double approach in a single procedure - long-term follow-up. *Spine.* 2006;31(15):1745–57.
25. Schlensker E, Distl O. Heritability of hemivertebrae in the French bulldog using an animal threshold model. *Vet J.* 2016;207:188–9.
26. Fries CL, Remedios AM. The pathogenesis and diagnosis of canine hip dysplasia: a review. *Can Vet J.* 1995;36(8):494–502.
27. Aristizabal Escobar AS, de Souza ANA, de Campos Fonseca Pinto ACB, Matera JM. Kinetic gait analysis in English Bulldogs. *Acta Vet Scand.* 2017;59(1):77.
28. King MD. Etiopathogenesis of canine hip dysplasia, prevalence, and genetics. *Vet Clin North Am Small Anim Pract.* 2017;47(4):753–67.
29. O'Neill DG, Meeson RL, Sheridan A, Church DB, Brodbelt DC. The epidemiology of patellar luxation in dogs attending primary-care veterinary practices in England. *Canine Genet Epidemiol.* 2016;3:4.
30. Ike H, Dorr LD, Trasolini N, Stefl M, McKnight B, Heckmann N. Spine-pelvis-hip relationship in the functioning of a total hip replacement. *J Bone Joint Surg Am.* 2018;100(18):1606–15.
31. Morimoto T, Sonohata M, Mawatari M. Ipsilateral hip dysplasia in patients with sacral hemigenesis: a report of two cases. *Case Rep Orthop.* 2015;2015:854151.
32. Yeganeh A, Moghtadaei M, Motalebi M. A challenge on orthopedic sciences: the influence of spinal disease and deformities on total hip arthroplasty: a review on literature. *Arch Bone Jt Surg.* 2018;6(5):346–52.
33. Dennis R. Radiographic examination of the canine spine. *Vet Rec.* 1987;121(2):31–5.
34. Grebe J. Hemivertebrae. *French Bullytin.* 1984;3(3):11–5.
35. Jensen VF, Beck S, Christensen KA, Arnbjerg J. Quantification of the association between intervertebral disk calcification and disk herniation in Dachshunds. *Javma-J Am Vet Med A.* 2008;233(7):1090–5.
36. Stigen O, Ciasca T, Kolbjornsen O. Calcification of extruded intervertebral discs in dachshunds: a radiographic, computed tomographic and histopathological study of 25 cases. *Acta Vet Scand.* 2019;61(1):13.
37. Mansour TA, Lucot K, Konopelski SE, Dickinson PJ, Sturges BK, Vernau KL, et al. Whole genome variant association across 100 dogs identifies a frame shift mutation in DISHEVELLED 2 which contributes to Robinow-like syndrome in Bulldogs and related screw tail dog breeds. *PLoS Genet.* 2018;14(12):e1007850.
38. Center CHI. Breed statistic. [www.ofa.org](http://www.ofa.org). 2018. Accessed September 2018.

**How to cite this article:** Lackmann F, Forterre F, Brunnberg L, Loderstedt S. Epidemiological study of congenital malformations of the vertebral column in French bulldogs, English bulldogs and pugs. *Vet Rec.* 2021;e509. <https://doi.org/10.1002/vetr.509>