

Evaluation of short-term safety of ultrasound-guided foetal fluid sampling in the dog (*Canis lupus familiaris*)

Smadar Tal¹  | Gila Kahila Bar-Gal¹ | Sebastian Patrick Arlt² 

¹ Koret School of Veterinary Medicine, The Hebrew University of Jerusalem, Rehovot, Israel

² Clinic for Animal Reproduction, Faculty of Veterinary Medicine, Freie Universität Berlin, Berlin, Germany

Correspondence

Smadar Tal, Koret School of Veterinary Medicine, The Hebrew University of Jerusalem, P.O. Box 12, Rehovot 761001, Israel.
Email: Smadar.tal@mail.huji.ac.il

Funding information

Freie Universität Berlin and The Hebrew University of Jerusalem; Joint Seed Money Funding Scheme, Grant/Award Numbers: HUJI 0366216, 2016

Abstract

Background: In humans, analysis of amniotic fluid is widely used for diagnostic and prognostic purposes. Amniocentesis has scarcely been used in veterinary medicine to date, despite a tremendous potential for clinical and research applications in dogs. Our study aimed to establish a safe method for foetal fluid sampling in female dogs.

Methods: Two transabdominal ultrasound-guided methods were assessed: the “free hand” and the needle-guided bracket sampling. In addition, through a subsequent routinely scheduled ovariohysterectomy, fluid was directly collected. Samples from 98 conceptuses were collected at day 46.7 ± 7.5 of pregnancy.

Results: The amount of fluid retrieved varied between 0.5 and 5.0 ml per collection. Macroscopic examination of the uterus and conceptuses identified 53% of the puncture sites. Neither fluid leakage nor foetal injury was detected, and six hematomas (5.8%) were visible. Ultrasound-guided foetal fluid collection was found to be potentially safe, and it can be performed by using either transabdominal method.

Conclusion: Foetal fluid collection is possible with relative ease and low short-term risk, and may open paths for diagnostic, therapeutic and research purposes in dogs. The procedure can provide new insights into prenatal clinical medicine, including diagnostics of foetal deaths, early identification of heritable diseases and so on.

KEYWORDS

allantoic fluid, amniocentesis, amniotic fluid, dog, foetal fluid centesis, pregnancy

INTRODUCTION

The foetal membranes of the canine species are the allantois, amnion, chorion and yolk sac.¹ The amniotic cavity provides mechanical protection of the fetus and its development in a liquid medium.² Amniotic fluid is a complex biofluid which provides both mechanical and antimicrobial protection to the fetus as well as lubrication, nutrition and growth factors, which are important for foetal development.³ Amniotic fluid is formed with contributions from oral, nasopharyngeal, tracheal, pulmonary secretions and urine excretion from the conceptus.⁴

Amniocentesis is a technique for collecting amniotic fluid from the amniotic sac. The technique is performed using a needle via transabdominal centesis

and under continuous ultrasound guidance.⁵ In humans and other primates, the allantois regresses very early in development to remain at term as a diverticulum enclosed into the wall of the umbilical cord.² Therefore, during amniocentesis it is possible to collect amniotic fluid solely. The main purposes for performing amniocentesis are for ante-partum assessment of foetal viability and detection of diseases.^{6–8} Analysis of amniotic biofluid is used extensively in human clinical medicine for diagnosis of chromosomal abnormalities or single gene disorders, as well as the evaluation of foetal lung maturity, microbial invasion of the amniotic cavity, intra-amniotic inflammation, foetal infections and gender determination.^{9–11}

In carnivores and ungulates, the allantoic sack grows to line the chorionic sack almost entirely and

This is an open access article under the terms of the [Creative Commons Attribution](https://creativecommons.org/licenses/by/4.0/) License, which permits use, distribution and reproduction in any medium, provided the original work is properly cited.

© 2021 British Veterinary Association

persist until parturition. It communicates with the urinary apparatus of the fetus and acts as waste reservoir of foetal metabolism.² As a result, foetal fluid is potentially available for collection from both amniotic and allantoic cavities. It can be assumed that an amniocentesis is feasible in the female dog in a time frame beginning at the second half of pregnancy and onwards, as there is sufficient foetal fluid and the amniotic and allantoic membranes are discernable. Few studies on foetal fluid analysis in cattle and horses have indicated their use for diagnosis of infectious diseases,^{12,13} gender determination,¹⁴ as well as assisted reproductive techniques such as production of cloned offspring.¹⁵ In dogs, one study analyzed the amniotic fluid for determining pulmonary maturity in the last days of pregnancy,¹⁶ and another case study showed the feasibility of performing sex analysis from amniotic cells of a singleton canine pregnancy.¹⁷ In addition, puncture of amniotic or allantoic cavities have been used in the canine species to inject agents for research purposes,^{18,19} gene therapy and induction of abortion.²⁰

In human medicine, well-established standard procedures for amniocentesis have been developed in the past decades.^{7,21} Amniocentesis is commonly performed in the second trimester, which is from 16 weeks of pregnancy onwards.²¹ It carries a risk of foetal loss of approximately 0.5% (range, 0.06–1%) when performed in the second trimester. In addition, a risk of amniotic fluid leakage in approximately 0.3% of cases and other rare complications such as placental haemorrhage, intra-amniotic infection, abdominal wall hematoma and foetal lesion have been described.⁹ Guidelines for the procedure include the positioning of the woman, the skin preparation prior to puncture, the preceding ultrasound evaluation, the position of the ultrasound probe, needle insertion, uterine puncture, amniotic fluid aspiration and post procedure recommendations.⁹

As of today, the procedures for fluid collection^{16,17} or injection of substances into foetal cavities in dogs^{18–20} were not described in abundant detail, especially in regard to the potential complications and side effects. Therefore, no routine method has been developed, and no safety studies have been performed to date.

The aim of our study was to establish a method of foetal fluid sampling in the female dog, as well as to assess safety aspects of the methodology.

MATERIALS AND METHODS

Animals

Foetal fluid collection was performed on a cohort of 21 healthy pregnant female dogs representing five breeds (Bull Terrier, Asian Shepherd, Golden Retriever, Labrador Retriever and Cavalier King Charles Spaniel; one female dog per breed) and 16 mongrel female dogs. All were pregnant stray dogs that were brought

to the Hebrew University Veterinary Teaching Hospital (HUVTH) for preterm ovariohysterectomy. Estimated ages were provided by the authority that held them for most but not all of the dogs (Table 1). This information was based on rabies vaccine federal records. Ovariohysterectomy is a routine procedure in pregnant stray animals advocated by the Society for Prevention of Cruelty to Animals (SPCA) in Israel, aiming to prevent overpopulation in the country (<https://spca.co.il/spaying-neutering/>). The procedure was conducted by board-certified theriogenologist and anaesthetists from the HUVTH. Furthermore, this study was approved by the HUVTH Committee of Animal Handling and Experimentation (permit KSVM-VTH/08_2015).

Determination of cycle stage and ovulation timing was performed on none of the dogs prior to conception. In addition, no information on the reproductive history of the animals was available.

Examination of female dogs

Prior to foetal fluid sampling, each female dog underwent a complete general and gynaecological examination including vaginoscopy, vaginal cytology and abdominal ultrasound. As a part of routine pre-surgical tests, blood samples were collected in potassium-EDTA tubes used for complete blood count (CBC; Advia 120; Siemens Medical Solutions Diagnostics, Erfurt, Germany), and in plain tubes, for serum creatinine measurements using an autoanalyzer (Cobas-Integra 400 Plus, Roche, Mannheim, Germany, at 37°C). Only female dogs showing no signs of disease were enrolled into the study. All female dogs in the study were considered healthy based on their clinical and gynaecological exams, and based on their laboratory test results.

Gestational age was assessed by measuring biparietal head diameters (BPD) of at least three fetuses (with the exception of one female dog that carried only two fetuses) using ultrasonography (Mindray M9, Shenzhen Mindray Bio-medical Electronics, Co., Shenzhen, China, with an C11-3s micro convex 3–11 MHz transducer). Average BPDs were measured and days to parturition were calculated using the following formulas: $(\text{BPD in mm} - 29.18)/0.7$ for medium (10–20 kg) and large (over 20 kg) size female dogs and $(\text{BPD in mm} - 25.11)/0.61$ for small (2–10 kg) female dogs.²² Based on this calculation, all foetal fluid collection procedures aimed to be performed between day 35 and on post ovulation.

Anaesthesia

All female dogs were premedicated with methadone (Physeptone; Martinadale pharmaceuticals, Brentwood, UK) 0.5 mg/kg IM 30 min prior to the procedure. Acepromazine (acepromazine 0.1%; Medimarket, Netanya, Israel) 0.01–0.03 mg/kg IM and atropine (atropine sulphate; Teva Pharmaceutical

TABLE 1 Data on pregnant female dogs subjected to ultrasound-guided foetal fluid sampling

Dog No.	Age*	Breed	Body weight (kg)	Estimated day of pregnancy at time of foetal fluid collection	Number of foetuses in the pregnancy	Total number of foetuses sampled (sampling method)	Location of sample collections (number of foetuses sampled and suspected** horn)
1	3	Bull Terrier	20	S	6	3 (3FH)	1L + 2R
2	2.5	Mixed breed	25	40	5	5 (2FH; 3G)	2L + 3R
3	2	Mixed breed	8	56	3	1 (1FH)	1B
4	2	Mixed breed	22.4	S	6	6 (2FH; 4G)	2L + 3R + 1B
5	4	Mixed breed	22.6	50	5	3 (1FH; 2G)	2R + 1B
6	Young	Mixed breed	8,4	53	2	2 (2G)	1L + 1R
7	Mature	Mixed breed	S	45	4	3 (2FH; 1G)	1L + 1R + 1B
8	2	Mixed breed	22.5	52	4	2 (2FH)	1R + 1B
9	Mature	Mixed breed	20	50	5	3 (3G)	1L + 1R + 1B/L
10	Young mature	Mixed breed	6.6	38-40	6	6 (3FH; 3G)	3L + 2R + 1B
11	1.5	Mixed breed	30	49	9	6 (1FH; 5G)	4L + 2R
12	1.2	Asian Shepherd	46	43	8	4 (2FH; 2G)	3L + 1R
13	1	Mixed breed	20.7	44	7	7 (2FH; 5G)	2L + 3R + 2B
14	5.2	Mixed breed	18.2	45	7	5 (3FH; 2G)	1L + 2R + 2B
15	2.25	Mixed breed	23	42	8	6 (3FH; 3G)	2L + 1R + 3UN
16	Mature	Mixed breed	30	47	10	7 (2FH; 5G)	2L + 5R
17	5.6	Mixed breed	12	35	7	7 (3FH; 4G)	3L + 4R
18	5.8	Golden Retriever	41.6	62	4	2 (2G)	1L + 1R
19	2	Labrador Retriever	15	50	8	8 (3FH; 5G)	4L + 4R
20	2.8	Mixed breed	42	35	7	7 (4FH; 3G)	3L + 4R
21	8.2	Cavalier King Charles Spaniel	10	50	6	5 (1FH; 4G)	1L + 3R + 1B

Ultrasound-guided fluid collection performed on 98 canine foetuses to assess short-term safety of the procedure at day 46.7 ± 7.5 (range 35–62 days) of pregnancy. *Estimated age in years; S = missing data; FH = using free hand technique; G = using needle guide; L = left horn; R = right horn; B = body of the uterus; UN = unknown area of collection.

**The location was determined using ultrasonography and therefore not confirmed.

Industries Ltd, Debrecen, Hungary) 0.02 mg/kg IM were administered as needed, based on temperament and baseline heart rate of the female dog. Female dogs were induced with propofol (Lipuro 1%; B. Braun Melsungen AG, Melsungen, Germany) IV to effect (0.5–1.5 mg/kg) and diazepam (Assival; Teva Pharmaceutical Industries, Netanya, Israel) 0.5 mg/kg IV. Anaesthesia was maintained with isoflurane (Terrell Isoflurane USP; Piramal Critical Care Inc., Bethlehem, PA) in 100% oxygen. During anaesthesia patients were monitored for heart rate and respiratory rate using lead II electrocardiogram and pulse oximetry. Additional monitoring during anaesthesia included oesophageal temperature measurements, end tidal CO₂ monitoring (S/5 monitor; Datex Ohmeda, Helsinki, Finland) and noninvasive blood pressure measurements using a Doppler technique (811-BTS; Parks Medical Electronics, Beaverton, OR) or oscillometry (Cardell 9601; Midmark Corp., Miamisburg, OH). A forced-air warming device (Thermacare; Gaymar Industries Inc., Orchard Park, NY) was applied to minimize heat loss.

Once the patient was fully anesthetized and monitored, the abdomen was clipped and disinfected

using povidone iodine surgical scrub solution and 70% ethanol solution.

Percutaneous foetal fluid sampling

Two methods were performed using a disposable spinal needle (18 G x 3½ inch or 21 G x 3½ inch, KDL, London, UK):

1. “Free hand technique” – without a needle guide. Prior to insertion of the spinal needle the abdomen was disinfected once more, using 70% ethanol. The uterine and gestational cavities, as well as the fetus, were examined via ultrasonography, and an optimal collection position that appeared promising for fluid collection without harming the fetus or the foetal membranes was selected. At the same time, the localization of the fetus in the left or right uterine horn and the collection site (allantois or amnion) were estimated, even if this method may not be completely reliable. Then, the spinal needle was inserted into the abdominal wall in an almost 90° angle and advanced into the uterine

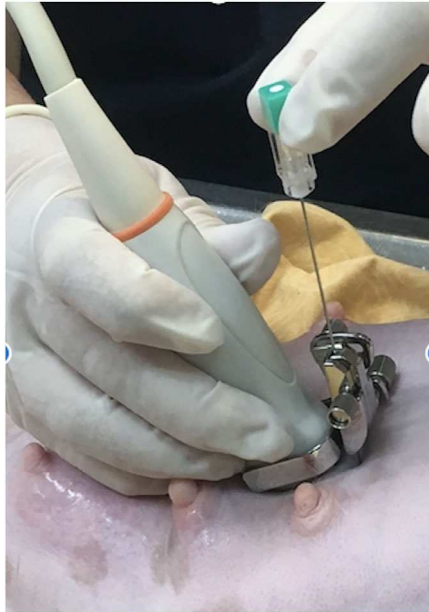

FIGURE 1 Transabdominal fetal fluid collection using an ultrasonography needle-guided brackets

cavity and the gestational sac (amnion or allantois). Both amniotic and allantoic membranes were often visible but a definite positioning of the tip of the needle was not always possible. When the needle was positioned, fluid was aspirated using a 5-ml syringe. The collected fluid was immediately transferred to a sterile 1.5-ml Eppendorf tube and frozen at -80°C .

2. *Using an ultrasonography needle-guided brackets* (model BGB-018; Shenzen Mindray Bio- Medical Electronics, Co., Shenzen, China), i.e. a needle guiding device, which can be attached to the C11-3s curved array transducer. Prior to each procedure, the guide underwent sterilization in an autoclave. After sampling of each gestational sac, it was disinfected using 70% ethanol. The guide was placed on the probe according to the manufacturer's instructions, and the spinal needle inserted into a small hole in a preset position on the guide, as shown in Figure 1. Penetration of the foetal membranes, fluid collection and its processing followed the same procedures described for the "free hand technique".

Both techniques were used on 15 female dogs (Table 1). For each female dog, fluid was collected from a minimum of one foetus from the left horn, one from the right horn and one from the uterine body, if this was possible within a few minutes, i.e. if there were more than two foetuses in a pregnancy, and if the position of the foetus allowed for safe fluid collection (Table 1).

Foetal fluid sampling during surgery

After the percutaneous sampling, the abdomen was scrubbed again with povidone iodine scrub solution and 70% ethanol solution in preparation for surgery.

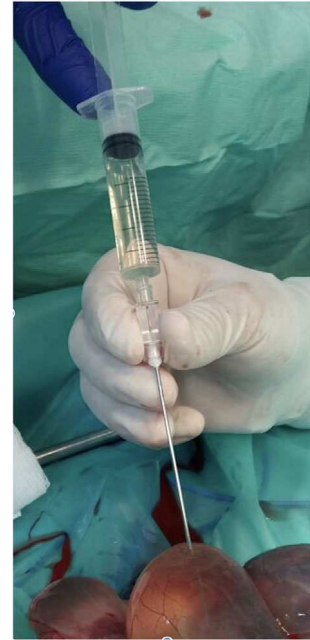

FIGURE 2 Collection of fetal fluids during surgery using a spinal needle

Laparotomy was then performed commencing with an incision in the linea alba. The uterine wall was inspected for lesions and puncture holes from the percutaneous samplings. The uterus was then incised near the cranial or caudal end of each gestational sac, with care taken not to incise over a placenta. The allantoic and amniotic membranes were inspected thoroughly for lesions and puncture signs from percutaneous sampling. An 18-gauge hypodermic needle used for female dogs weighing up to 25 kg, or a 21-gauge needle for female dogs weighing more than 25 kg, respectively, was then inserted through the membrane and fluid was collected for analysis using a 3- or 5-ml syringe (Figure 2). Using both methods, percutaneous and surgical foetal fluid collection, care was taken not to injure the conceptus itself.

Following termination of foetal fluid samplings from the different conceptuses, routine ovariohysterectomy was performed, and the foetuses euthanized individually immediately after removal of the uterus with an intracardiac injection of pentobarbital sodium solution, 150 mg/kg IP (Pental Veterinary Injection 200 mg/ml; CTS Chemical Industries Ltd., Israel). After termination of the surgery and routine abdominal closure, 25 mg/kg dipyrone (Optalgin, Teva Pharmaceutical Industries, Israel) was administered SQ for pain management.

Evaluation of foetal fluid was performed macroscopically and specific gravity was determined using a refractometer (Headed Reinforcement Corp., Fountain Valley, CA).

Statistical analyses of the results were performed by IBM SPSS Statistics software (version 24 for Windows). Frequency analysis, cross tables, Pearson chi-squared test and Pearson correlation test were used to determine differences between the expected and observed frequencies of total number and sampled foetuses for

the age, body weight and day of pregnancy. The significance level was set as $\alpha = 0.05$.

RESULTS

The duration of the foetal fluid collection procedure prior to ovariohysterectomy took up to 15 min, and the whole surgery time did not exceed 60 min.

Foetal fluid was successfully collected from 98 fetuses of all 21 female dogs (Table 1). Detailed information on the dogs, their estimated age, day of pregnancy, number and localization of sampled amniotic fluid can be found in Table 1. The mean age of female dogs for which the age could be estimated ($n = 16$) was 3.19 ± 2.39 years (range 1–8.2 years). The age of five female dogs could not be determined. The mean body weight ($n = 20$) was 22.2 ± 10.8 kg (range 6.6–46.0 kg) excluding the weight of one female dog due to recording errors.

Fluid collection was conducted from 98 fetuses on day 46.7 ± 7.5 of pregnancy (range 35–62 days). The mean number of conceptuses sampled per female dog ($n = 21$) was 4.7 ± 2.1 (range 1–8 conceptuses). Foetal fluid from 40 fetuses was collected using the free hand technique, and from 58 fetuses it was collected using the needle-guided method. Foetuses sampled were located on both the left ($n = 37$) and right ($n = 46$) uterine horns, and in the uterine body ($n = 11$). The location of three of the foetuses was not determined precisely by ultrasonography.

The amount of fluid retrieved from each conceptus ranged between 0.5 and 5.0 ml. During most collections, however, sampling was stopped as soon as a volume of 3.0 ml was reached to avoid harming the foetuses. The colour of the foetal fluid retrieved was mostly transparent, or yellowish transparent. Two samples were yellowish, one was reddish and one was greyish in colour, and 23 of the samples were cloudy. The viscosity was low in all cases, and the specific gravity ranged between 1.002 and 1.016 in all samples (mean 1.009 ± 0.009).

In total, 55 out of the 98 puncture sites were identified macroscopically on the uterine serosal surface (Figure 3). In two female dogs, hematomas measuring approximately 2 and 3 ml in diameter were found at one puncture site, respectively (Figure 4). Spontaneous fluid leakage was not observed from any of the puncture sites. This was ascertained by using gentle digital pressure on the uterine wall around the puncture sites. Careful examination of the membranes of every fetus immediately after its exposition revealed that in 30 out of 98 a small puncture site could be detected macroscopically. The diameter of all puncture sites, as measured by a caliper, was less than 0.5 mm. In six out of the identified 30 puncture sites, a small external hematoma of less than 0.5 cm was present on the foetal membrane surfaces.

During the surgical procedure, foetal membranes of three conceptuses ruptured spontaneously due to handling. Finally, the skin of each of the 98 fetuses

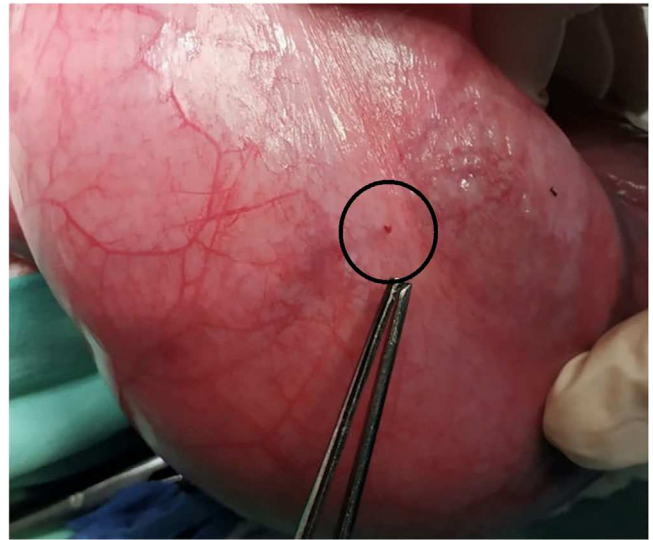


FIGURE 3 Puncture site on the serosal surface of the uterus after transabdominal fetal fluid sampling. No fluid leakage was noticed. The puncture site is demarcated by a black circle

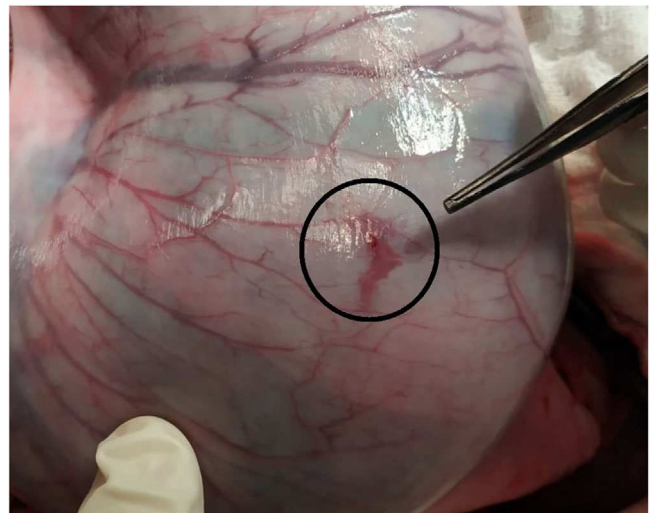


FIGURE 4 Hematoma on a puncture site on the serosal surface of the uterus after transabdominal fetal fluid sampling. No fluid leakage was noticed. The hematoma is demarcated by a black circle

was examined immediately after removal from the foetal membranes. Not a single puncture site or signs of injury were identified.

Only one percutaneously collected sample was of red colour, presumably blood. However, the corresponding area of the uterus, the foetal membranes and the fetus did not show any signs of injury.

Statistical analysis revealed that there was no significant influence of the dam's body weight on the total number of fetuses ($p = 0.13$) or on the number of fetuses sampled ($p = 0.80$). Also, the age of the dam had no influence on these numbers ($p = 0.43$ and $p = 0.71$). Furthermore, the bodyweight and the day of pregnancy at the time of sampling had no influence on the proportion of fetuses (number of sampled fetuses/total number of fetuses) sampled ($p = 0.6$ and $p = 0.15$, respectively).

DISCUSSION

The main conclusion from this study is that percutaneous foetal fluid collection between days 35 and 62 from ovulation via centesis causes only little visible damage to the uterus, the extraembryonic membranes and the fetus. Pending future studies on long-term safety, the procedure may be considered as a routine method, with minimal injury. In accordance with our hypothesis, we can confirm that in less than 10% of sampling punctures in the uteri and conceptuses, clinically relevant signs of injury were detected. Even when macroscopically puncture sites in the uterus could be seen in half of the samples and in around one-third of foetal membranes, no fluid leakage and no lesions in the skin of the foetuses were detected. The feasibility and safety of the procedure has also been shown by Bonte et al.¹⁶ Spinal needle puncture sites were visible in 30% of the foetal membranes but most seemed not to be of clinical relevance. While several studies in humans showed the rate of fluid leakage due to amniocentesis procedure to be 1.4–1.6%,^{23,24} in our study we observed no fluid leakage from any puncture site. Furthermore, small hematomas on the foetal membranes were found at only six puncture sites (5.8%) with no injury noted on the skin of any foetus sampled. These findings are based on a cohort of 98 samples and for the detection of side effects with low incidences, a higher number of samples may have been helpful to calculate more robust percentages of fluid leakages and hematomas.

Potential complications of amniocentesis in human medicine include infection of the amniotic sac, preterm labour, respiratory distress, foetal deformities, trauma, alloimmunisation and failure of the puncture wound to heal properly.²⁵ Although very uncommon in human medicine, foetal injury can occur secondary to trauma from the needle. Foetal trauma case reports have commonly reported disfigurements on the skin; nonetheless, cases have been reported inciting direct trauma to central nervous system causing bleeding, ocular disturbances and injury to internal organs.^{26–28} In our study, exploratory laparotomy and observation of tissues and foetuses were all performed within 60 min after the amniocentesis procedure. Although no foetal injury was detected macroscopically following needle puncture, it is possible that microscopic injuries did occur. It is possible that some microscopic puncture sites in the uterus, foetal membranes or foetuses may have not been identified. For these cases, it can be assumed that they would not have been of clinical relevance. Further studies, with a larger cohort and a follow-up to an examination of newborn puppies postpartum are required in order to evaluate the possible long-term effects of foetal fluid centesis procedure on the canine pregnancy, and on the sampled offspring.

Foetal fluids were collected from all pregnant female dogs enrolled in this study. However, using the trans-abdominal fluid collection methods, it was not possible to take samples from all gestational sacs of each pregnant female dog. In some cases, especially when a

high number of conceptuses was present in the uterus, a definitive determination of the different gestational sacs was not always possible ultrasonographically. In addition, the gravid uterine horns were convoluted in many female dogs, and parts of them crossed over from left to right and vice versa in the abdominal cavity, which added a challenge in locating the exact position of each conceptus.

When interpreting the results of the statistical analysis, one has to take into account that the sample size and the high variations among the female dogs do not allow concise conclusions. The volume of foetal fluid that can be collected may have depended on the size of the dam, the stage of the pregnancy, the number of conceptuses in the uterus, and their position in the abdomen, as well as on the level of proficiency of the person collecting the samples. However, in this study we did not assess these influencing factors since we stopped fluid collection in most cases when 3.0 ml was aspirated. A volume of 1.0 ml is suitable for one or more diagnostic tests¹⁶ and collecting more fluid than necessary might increase the risk of injury.

Between 35 and 62 days post ovulation there is sufficient fluid in the gestational sac, and the foetus does not impede the collection procedure. Based on the statistical analysis, the day of sampling had no influence on the proportion of foetuses that could be sampled. In the time period we chose, the space in the gestational sac is sufficient for safe insertion of the tip of a spinal needle without injuring the conceptus. We hypothesize that prior to day 35 post ovulation, the amount of foetal fluids is not abundant, and it can be assumed that the potential risk for injuring the conceptus is higher. It is expected that foetal fluid collection via needle puncture from this time on to the end of the pregnancy is safe to the conceptus. This is in accordance with another study that showed no complications to either the dam or the conceptuses following the collection of amniotic fluids 1 day prepartum.¹⁶

Two methods were used in the current study to collect amniotic fluids: with and without needle-guided brackets. It was concluded subjectively that the use of a needle guiding device facilitated the visualization of the needle and puncture of the gestational sac cavity. The free hand method, however, enabled a more flexible handling of the needle and adjustment of the path of needle insertion. Initially, it was significantly easier to perform the procedure using the ultrasonography needle-guided brackets. As experience was gained during this study, after performing numerous foetal fluid collections, the ability to use both methods interchangeably was achieved. The same outcomes were gained for amounts of foetal fluid retrieval. The incidence of injuries was low for both procedures. In order to prove one method safer than the other, a larger set of observations is necessary. It is likely that the needle bracket guide may be easier and safer in the hands of beginner and less experienced operators for foetal fluid collection from pregnant dogs. These observations are in accordance with human literature and practice. In human medicine, most operators prefer

the “freehand technique”, i.e., without the aid of a needle guiding device. However, beginner operators often use needle guides until they are comfortable with the procedure.^{29,30} The drawback of using the ultrasound needle-guided brackets in this study is the need for sterilization of the apparatus between multiple foetal fluid samplings of different conceptuses in one female dog during one procedure. Bathing the apparatus in 70% ethanol solution between sampling procedures is not optimal, as it potentially carries a higher risk of contamination of conceptuses, despite the use of a new sterile spinal needle. Hence, it would be optimal to have several guides to be able to use a sterile guide for each fluid collection.

Prenatal cell-free DNA screening from maternal blood samples, or non-invasive prenatal DNA testing (NIPT), is an important addition to the range of screening tests for foetal chromosomal abnormalities in humans,³⁰ and can also be used for sex determination in bovines.³¹ Prenatal screening in the dog using NIPD has not been established to date, as, unlike the human and cattle, it is a polytocous species.³²

Foetal fluid sampling may be used in the future in dogs for screening for hereditary diseases, metabolic, toxic and various other conditions or in terms of genetic, genomic and epigenetic foetal tissue and cellular manipulations, or for sex determination. In addition, in utero injections of therapeutic agents may be a potential clinical tool in canine medicine. In the research context, also the safety of medications given to the dam for the conceptus may be examined by foetal fluid sampling.

Collection of foetal fluids from dogs can also be valuable as a source of stem cells with therapeutic potential in the field of regenerative medicine. Stem cells from the amniotic fluid can be isolated and expanded easily,³³ and have the ability to differentiate into a various cell types without the risk of tumorigenesis. These cells can successfully engraft in multiple organs, and emerging evidence from experimental models of disease has generated great interest in potential clinical applications for human tissue repair and regeneration. The latter, in combination with the lack of ethical concerns associated with other stem cell sources, such as ovine^{34,35} and leporine,³⁶ makes stem cells derived from the foetal fluids prime candidates for the development of novel therapies for a wide range of congenital and acquired human and animal disorders.³⁷

The collection of foetal fluid may provide valuable possibilities for veterinary research in the canine species, as well as for clinical practice, including identification of heritable diseases, especially those that are lethal, identification of sex related diseases and so on. To date, the literature on foetal fluid analysis in the female dog is scarce and focuses on sample collection close to term. One example is the study on foetal pulmonary maturity in dogs using amniotic fluid collected in the last days of pregnancy.¹⁶ Another study characterized progenitor stem cells from allantois and amniotic fluids at the third trimester of gestation in the female dog.³⁸ A third example is a case report

reported foetal in a singleton pregnancy in a dog.¹⁷ All three studies used percutaneous collection of fluids. In other studies, at which foetal fluid was collected, the latter was performed post surgically (for example, cesarean section or ovariohysterectomy of pregnant female dogs at term).^{39,40}

CONCLUSION

Ultrasound-guided foetal fluid collection is a potentially safe procedure, and in the hands of the trained operator can be executed with relative ease by using either the “freehand technique” or needle-guided methodology. The option to collect canine foetal fluids with relative ease and a low risk of immediate side effects opens up a path to use them for diagnostic, therapeutic and research purposes, similar to the way it is performed in humans. Further research is warranted to assess long-term safety of the procedure.

FUNDING INFORMATION

Freie Universität Berlin and The Hebrew University of Jerusalem: Joint Seed Money Funding Scheme; Grant Number: HUJI 0366216, 2016.


ACKNOWLEDGEMENTS

The authors wish to thank the Koret School Veterinary Teaching Hospital for their technical support, as well as Dr. Yehonatan Even Tsur and the staff of the Rishon LeZion municipal veterinary service for their cooperation and participation in this study.

CONFLICT OF INTEREST

The authors declare that there is no conflict of interest.

ORCID

Smadar Tal  <https://orcid.org/0000-0003-1243-5004>
Sebastian Patrick Arlt  <https://orcid.org/0000-0003-1869-4226>

REFERENCES

1. Carter AM. IFPA senior award lecture: mammalian fetal membranes. *Placenta* 2016;48(Suppl 1):S21-30.
2. Chavatte-Palmer P, Tarrade A. Placentation in different mammalian species. *Ann Endocrinol (Paris)*. 2016;77:67-74.
3. Underwood MA, Gilbert WM, Sherman MP. Amniotic fluid: not just fetal urine anymore. *J Perinatol*. 2005;25:341-8.
4. Brace RA. Physiology of amniotic fluid volume regulation. *Clin Obstet Gynecol*. 1997;40:280-9.
5. Nizard J. Amniocentesis: technique and education. *Curr Opin Obstet Gynecol*. 2010;22:152-4.
6. Shulman LP, Elias S. Amniocentesis and chorionic villus sampling. *West J Med*. 1993;159:260-8.
7. Tseng JJ, Chou MM, Lo FC, Lai HY, Chen MH, Ho ES. Detection of chromosome aberrations in the second trimester using genetic amniocentesis: experience during 1995-2004. *Taiwan J Obstet Gynecol*. 2006;45:39-41.
8. Connolly KA, Eddleman K. A. Amniocentesis: a contemporary review. *World J Obstet Gynecol*. 2016;5:58-65.
9. Cruz-Lemini M, Parra-Saavedra M, Borobio V, Bennasar M, Goncá A, Martínez JM, et al. How to perform an amniocentesis. *Ultrasound Obstet Gynecol*. 2014;44:727-31.
10. Musilova I, Bestvina T, Stranik J, Stepan M, Jacobsson B, Kacerovsky M. Transabdominal amniocentesis is a feasible and

- safe procedure in preterm prelabor rupture of membranes. *Fetal Diagn Ther.* 2017;42:257–61.
11. Wood PL, Ball BA, Scoggin K, Troedsson MH, Squires EL. Lipidomics of equine amniotic fluid: identification of amphiphilic (O-acyl)-omega-hydroxy-fatty acids. *Theriogenology* 2018;105:120–5.
 12. Callan RJ, Schnackel JA, Van Campen H, Mortimer RG, Cavanaugh JA, Williams ES. Percutaneous collection of fetal fluids for detection of bovine viral diarrhoea virus infection in cattle. *J Am Vet Med Assoc.* 2002;220:1348–52.
 13. Smith KC, McGladdery AJ, Binns MM, Mumford JA. Use of transabdominal ultrasound-guided amniocentesis for detection of equid herpesvirus 1-induced fetal infection in utero. *Am J Vet Res.* 1997;58:997–1002.
 14. Leibo SP, Rall WF. Prenatal diagnosis of sex in bovine fetuses by amniocentesis. *Theriogenology* 1990;33:531–52.
 15. da Silva CG, Martins CF, Cardoso TC, da Cunha ER, Bessler HC, et al. Production of bovine embryos and calves cloned by nuclear transfer using mesenchymal stem cells from amniotic fluid and adipose tissue. *Cell Reprogram.* 2016;18:127–36.
 16. Bonte P, Del Carro A, Paquette J, Charlot Valdieu A, Buff S, Rosset E. Foetal pulmonary maturity in dogs: estimated from bubble tests in amniotic fluid obtained via amniocentesis. *Reprod Domest Anim.* 2017;52:1025–9.
 17. Laysol DPAC-MS. Fetal sex determination by amniocentesis in the canine species: a case report. *Proceedings of 21st EVSSAR Congress, June 22–23 2018, Venice, Italy.* 2018.
 18. Lutzko C, Omori F, Abrams-Ogg AC, Shull R, Li L, Lau K, et al. Gene therapy for canine alpha-L-iduronidase deficiency: in utero adoptive transfer of genetically corrected hematopoietic progenitors results in engraftment but not amelioration of disease. *Hum Gene Ther.* 1999;10:1521–32.
 19. Hayashita-Kinoh H, Yugeta N, Okada H, Nitahara-Kasahara Y, Chiyo T, Okada T, et al. Intra-amniotic rAAV-mediated microdystrophin gene transfer improves canine X-linked muscular dystrophy and may induce immune tolerance. *Mol Ther.* 2015;23:627–37.
 20. Manca R, Rizzo A, Trisolini C, Minoia G, Mutinati M, Spedicato M, et al. Intra-vesicle administration of D-cloprostenol for induction of abortion in mid-gestation bitches. *Anim Reprod Sci.* 2008;106:133–42.
 21. Verp MS and Gerbie AB. Amniocentesis for prenatal diagnosis. *Clin Obstet Gynecol.* 1981;24:1007–21.
 22. Luvoni GC and Grioni A. Determination of gestational age in medium and small size bitches using ultrasonographic fetal measurements. *J Small Anim Pract.* 2000;41:292–4.
 23. Tara F, Lotfalizadeh M, Moeindarbari S. The effect of diagnostic amniocentesis and its complications on early spontaneous abortion. *Electron Physician.* 2016;8:2787–92.
 24. Gold RB, Goyert GL, Schwartz DB, Evans MI, Seabolt LA. Conservative management of second-trimester post-amniocentesis fluid leakage. *Obstet Gynecol.* 1989;74:745–7.
 25. Hayat M, Hill M, Kelly D, Tubbs RS, Loukas M. A very unusual complication of amniocentesis. *Clin Case Rep.* 2015;3:345–8.
 26. Papi L, Farusi F, Teti G, Dini V, Romanelli M. Cutaneous foetal injuries related to amniocentesis. *J Wound Care.* 2013;22:S23–5.
 27. Sant-Cassia LJ, MacPherson MB, Tyack AJ. Midtrimester amniocentesis: is it safe? A single centre controlled prospective study of 517 consecutive amniocenteses. *Br J Obstet Gynaecol.* 1984;91:736–44.
 28. Admoni MM, BenEzra D. Ocular trauma following amniocentesis as the cause of leukocoria. *J Pediatr Ophthalmol Strabismus.* 1988;25:196–7.
 29. Ghidini A. Diagnostic amniocentesis. *UpToDate.* 2019.
 30. Harraway J. Non-invasive prenatal testing. *Aust Fam Physician.* 2017;46:735–9.
 31. Davoudi A, Tarang A, Aleyasin SA, Salehi A, Seighalani R, Tahmouresi F. Evaluation of two DNA extraction methods from maternal plasma for using in non-invasive bovine fetus gender determination. *Iran J Reprod Med.* 2012;10:523–30.
 32. Ahn H, Kim KW, Kim HJ, Cho S, Kim H. Differential evolution between Monotocous and Polytocous species. *Asian-Australas J Anim Sci.* 2014;27:464–70.
 33. Loukogeorgakis SP, De Coppi P. Concise review: amniotic fluid stem cells: the known, the unknown, and potential regenerative medicine applications. *Stem Cells.* 2017;35:1663–73.
 34. Fuchs JR, Kaviani A, Oh JT, LaVan D, Udagawa T, Jennings RW, et al. Diaphragmatic reconstruction with autologous tendon engineered from mesenchymal amniocytes. *J Pediatr Surg.* 2004;39:834–8; discussion 834–38.
 35. Kunisaki SM, Freedman DA, Fauza DO. Fetal tracheal reconstruction with cartilaginous grafts engineered from mesenchymal amniocytes. *J Pediatr Surg.* 2006;41:675–82; discussion 675–82.
 36. Steigman SA, Ahmed A, Shanti RM, Tuan RS, Valim C, Fauza DO. Sternal repair with bone grafts engineered from amniotic mesenchymal stem cells. *J Pediatr Surg.* 2009;44:1120–6; discussion 1126.
 37. Loukogeorgakis SP, De Coppi P. Stem cells from amniotic fluid—Potential for regenerative medicine. *Best Pract Res Clin Obstet Gynaecol.* 2016;31:45–57.
 38. Fernandes RA, Wenceslau CV, Reginato AL, Kerkis I, Miglino MA. Derivation and characterization of progenitor stem cells from canine allantois and amniotic fluids at the third trimester of gestation. *Placenta* 2012;33:640–4.
 39. Groppetti D, Martino PA, Ravasio G, Bronzo V, Pecile A. Prognostic potential of amniotic fluid analysis at birth on canine neonatal outcomes. *Vet J.* 2015;206:423–5.
 40. Bolis B, Prandi A, Rota A, Faustini M, Veronesi MC. Cortisol fetal fluid concentrations in term pregnancy of small-sized purebred dogs and its preliminary relation to first 24 hours survival of newborns. *Theriogenology* 2017;88:264–9.

How to cite this article: Tal S, Kahila Bar-Gal G, Arlt SP. Evaluation of short-term safety of ultrasound-guided foetal fluid sampling in the dog (*Canis lupus familiaris*). *Vet Rec.* 2021;e31. <https://doi.org/10.1002/vetr.31>