

Aus der Klinik für Gefäß-, endovaskuläre, Allgemein- und Viszeralchirurgie,
Franziskus-Krankenhaus, Akademisches Lehrkrankenhaus der
Charité – Universitätsmedizin Berlin

DISSERTATION

Total endovascular therapy of aortoiliac aneurysms with preservation of internal
iliac artery patency using Iliac Branch Device (Zenith® Branch, COOK MEDICAL
INCORPORATED)

zur Erlangung des akademischen Grades
Doctor medicinae (Dr. med.)

vorgelegt der Medizinischen Fakultät
Charité – Universitätsmedizin Berlin

von

Fakhri Abdo
aus Afrin, Syrien

Datum der Promotion: 06.03.2020

Table of Contents

Abstract	9
I. Introduction	10
I.1 Historical Background	10
I.2 Significance of the subject	11
<i>IIA anatomy and function</i>	11
<i>Aneurysm location</i>	11
I.3 Problem and Subject of the Dissertation	12
II. Material and methods	14
II.1 Literature Review	14
II.2 Patients and methods	14
<i>Our IBD procedure</i>	15
<i>Follow-up protocol</i>	16
<i>Study end points and definitions</i>	16
III. Results	17
III.1 Results reported in the literature	17
III.2 Results of series presented in this study (Franziskus Krankenhaus)	27
<i>Perioperative results</i>	31
<i>Occurrence of endoleak</i>	31
<i>Reinterventions</i>	32
<i>Long-term follow-up</i>	33
<i>Comparison of the presented series with the results of the published research</i>	35
IV. Discussion	36
IV.1 Sacrificing the Internal Iliac Artery: Consequences and Complications	36
<i>Coil and coverage</i>	38
<i>Unilateral or bilateral?</i>	39
IV.2 Indications, feasibility and morphological criteria for using Iliac Branch Device	40
<i>Indications for using IBD</i>	40
<i>Feasibility and morphologic criteria for the use of IBDs</i>	41
<i>Patient selection</i>	44
<i>Bilateral IBD</i>	45

IV.3 Methods of IIA Preservation Following EVAR (other than IBD)	46
<i>Open repair</i>	47
<i>Hybrid open and endovascular procedures</i>	47
<i>Banding of the Common Iliac Artery</i>	49
<i>Bell-bottomed configuration (BBT)</i>	49
<i>Trifurcated endograft technique</i>	50
<i>The Apollo® Iliac Branched Device</i>	51
<i>Sandwich/chimney technique</i>	51
<i>Crossover chimney technique</i>	54
<i>Banana technique</i>	54
<i>Sac-Sealing Endograft / Endovascular aneurysm sealing (EVAS)</i>	54
<i>Parallel graft (PG-EVAR)</i>	56
IV.4 Considerations regarding IBD use	57
<i>Description of Iliac Branch Devices</i>	57
<i>Cook Zenith Iliac Branch Device</i>	58
<i>Helical IBD</i>	58
<i>Straight IBD (ZBIS)</i>	59
<i>Bifurcated-bifurcated IBD</i>	61
<i>The novel-designed iliac branch stent graft (IBSG)</i>	62
<i>Self-made (surgeon-modified) devices</i>	63
<i>The GORE® EXCLUDER® iliac branch endoprosthesis (IBE)</i>	64
<i>JOTEC E-liac Stent Graft</i>	67
<i>IBD vs Coil</i>	67
<i>Self-expanding endografts vs. balloon expandable covered stents (BECS)</i>	68
<i>IBD-Technique</i>	68
<i>IBD advantages</i>	77
<i>Availability of IBD</i>	77
<i>Cost Efficiency</i>	78
<i>Perspectives for the future</i>	78
V. Conclusion	80
VI. Summary	81
VII. Appendix	83
VII.1 List of Abbreviations	83
VIII. References	85

Tables and Figures

Tables

Table 1 (p. 17)

Review of published literature: Outcomes in patients with IBD

Table 2 (p. 19)

Review of published literature: Complications and secondary interventions

Table 3 (p. 28)

Characteristics of 39 patients with endovascular repair with Iliac Branch Device

Table 4 (p. 29)

Aneurysm extension in 39 patients

Table 5 (p. 31)

Post-operative local wound conditions

Table 6 (p. 31)

Perioperative results (30 days)

Table 7 (p. 32)

Endoleak at discharge and at most recent control

Table 8 (p. 32)

Details of reinterventions

Table 9 (p. 33)

Patients with IBD occlusion

Table 10 (p. 35)

Comparison of our results with published research

Table 11 (p. 44)

Therapy options for each aneurysm type according to Peters et al.

Figures

Figure 1 (p. 16)

Angiography confirms satisfactory position and patency of the internal iliac side branch

Figure 2 (p. 29)

Three-dimensional reconstruction in a patient with iliac side-branch repair for right iliac aneurysm in combination with EVAR with AAA

Figure 3 (p. 34)

Kaplan-Meier estimate of the probability of IBD side branch patency

Figure 4 (p. 42)

The narrow, distal common iliac artery (arrow) precludes use of an iliac bifurcation device. Figure and explanation taken from Huilgol et al. (87)

Figure 5 (p. 43)

Morphology of isolated iliac aneurysms type I-IV according to Reber et al. Illustration taken from Reber et al. (182)

Figure 6 (p. 48)

(a) Relocation of origin of internal iliac arteries; (b) The Reverse-U stent-graft; (c) Bifurcated stent-graft. Illustration taken from Ghosh et al. (65)

Figure 7 (p. 50)

Trifurcated endograft technique. Figure taken from Minion et al. (144)

Figure 8 (p. 51)

Apollo branched graft. Figure taken from Massière et al. (133)

Figure 9 (p. 52)

Stages of deployment during ST. Figure taken from Lobato et al. (124)

Figure 10 (p. 53)

Illustration shows the adjacent Powerlink and Viabahn grafts. Illustration taken from Friedman et al. (63)

Figure 11 (p. 55)

“Treatment of 6.3 cm AAA with short, funnel neck and 3.7 cm right common iliac aneurysm. (a) Pre-op 3D-CT reconstruction and (b) Post-op angiogram. (c) Post-op angiogram showing exclusion of the iliac aneurysm with preservation of internal iliac artery flow and (d) 3D-CT reconstruction of the common iliac aneurysm after treatment with complete exclusion of the aortic and iliac aneurysms.”. Figure and explanation taken from Krievins et al. (109)

Figure 12 (p. 56)

Schematic drawing of parallel graft endovascular repair procedure, showing bilateral common iliac artery aneurysms (BCIAA) extending to both iliac bifurcations treated with iliac leg endografts to both external iliac arteries, covered stent-graft to one IIA and Amplatzer vascular plug to the contralateral IIA. Illustration taken from Lepidi et al. (119)

Figure 13 (p. 58)

Evolution of the Zenith Iliac Branch Device: (A) first generation; (B) second generation; (C) straight (Australian) version. Figure modified from Ziegler et al. (235)

Figure 14 (p. 59)

The helical device (A), involving a preloaded catheter and guide-wire which transcends the delivery system (B). Figure and explanation taken from Haulon et al. (76)

Figure 15 (p. 60)

The preloaded through-lumen catheter is threaded from the delivery catheter into the internal iliac side branch, exiting out of the proximal end of the Iliac Branch Device to assist with cannulation of the internal iliac limb. Figure with explanations taken from Lee (118)

Figure 16 (p. 61)

Zenith Connection Endovascular Covered Stent. Figure taken from Lee (118)

Figure 17 (p. 62)

The bifurcated-bifurcated IBD (BB-IBD). Figure taken from Oderich et al. (158)

Figure 18 (p. 63)

(A) Two types of novel-designed iliac branch stent grafts (IBSGs) with different length of common iliac trunks. (B) Schematic drawing of the IBSG proposed in this study. Figure, illustration and explanations taken from Zhang et al. (233)

Figure 19 (p. 63)

Device modification and placement of a preloaded wire and catheter. Figure and explanations taken from Riesenman et al. (187)

Figure 20 (p. 66)

GORE EXCLUDER IBE features and anatomic requirements. (A) Iliac branch component; (B) internal iliac component; (C) anatomic requirements. Figure, illustration and explanation quoted from Millon et al. (143)

Figure 21 (p. 67)

Photograph of the unsheathed E-liac stent graft system. The nitinol skeleton is covered by woven polyester, which is sutured with braided polyester. The asymmetric tip-to-tip spring configuration allows good conformability to the vessel's shape, which minimizes the risk of kinking in angulated anatomies while maintaining appropriate longitudinal stiffness. (Courtesy Jotec GmbH, Hechingen, Germany.) Figure and explanations taken from Mylonas et al. (151)

Figure 22 (p. 70)

Left: Body and side branch of iliac branched device deployed. The ANL sheath is introduced inside the Balkin sheath (crossover "trombone" technique)

Right: Indwelling wire removed. This opens up the iliac branch limb (black arrow). The ANL I sheath is advanced inside the internal iliac artery. Illustration and explanation quoted from Tielliu et al. (208)

Figure 23 (p. 70)

Left: Iliac branched device retracted (black arrows) over two rails (the ANL sheath and the main introduction device)

Right: Ipsilateral limb of the iliac branched device deployed and the bridging stent-graft introduced and deployed. Illustration and explanation quoted from Tielliu et al. (208)

Figure 24 (p. 71)

Illustration of the technical variations. A, The main device tip is shown inside the iliac artery while the exchanged Amplatz wire is snared from the contralateral approach. B, The 12F sheath is in place with the Amplatz wire still in place. C, The Fluency and the Zilver stent are both in place. The uncovered stent is implanted 1 cm forward into the IIA, compared with the first, to avoid kinking. Illustration and explanation taken from Ferreira et al. (60)

Figure 25 (p. 74)

Sketch showing the technique of endovascular repair of aneurysmal internal iliac arteries using iliac branch devices. Illustration and explanation quoted from Austerman et al. (7)

Abstract

Deutsch

Die vorgelegte Studie leistet einen Beitrag zur Bewertung endovaskulärer Therapie (EVAR) von simultan auftretenden Aneurysmata der Aorta abdominalis (AAA) und der A. iliaca communis (AAIC) mit Ausdehnung bis zur Iliaka-Bifurkation oder der A. iliaca interna (AAII) unter Verwendung iliakaler Stentprothesen mit Seitenarmen (Zenith bifurcated iliac side-branch ZBIS, COOK). In solchen Fällen galt bisher die Indikation zur endovaskulären Therapie als begrenzt. Die vorgelegte Studie belegt, dass bei Verwendung iliakaler Stentprothesen mit Seitenarmen die Indikation zur EVAR erweitert werden kann.

Die Studie präsentiert eine retrospektive Analyse prospektiv gesammelter Daten aus einer single-center Serie von 39 konsekutiven Patienten, die zwischen Oktober 2007 und Juli 2014 am Franziskus-Krankenhaus Berlin mit total endovaskulärer Therapie zur Ausschaltung der genannten Aneurysmen unter Verwendung von ZBIS behandelt wurden.

Zweitens wird eine systematische Auswertung publizierter Studien (bis Januar 2016) zu den Ergebnissen endovaskulärer Behandlung von aorto-iliakalen Aneurysmen durch iliakale Stentprothesen mit Seitenarmen (Iliac side-branch ZBIS oder Helical Graft, COOK) durchgeführt.

Die Auswertung der untersuchten Serie zeigt, dass bei EVAR einschließlich effektiver und sicherer Ausschaltung von AAIC und AAII durch Verwendung des ZBIS Systems die antegrade Perfusion der Beckenarterien fast immer erhalten werden kann. Dies stimmt überein mit den Ergebnissen in der ausgewerteten Literatur.

English

The present study contributes to the evaluation of endovascular therapy (EVAR) of simultaneous aneurysms of the abdominal artery and the common iliac artery, which extend until the iliac bifurcation or the internal iliac artery. Until recently, the indication for endovascular treatment of aortoiliac aneurysms was considered to be limited. This study shows that the indication for endovascular therapy (EVAR) of aortoiliac aneurysms (AIA) is broadened by using iliac side-branch device (Zenith bifurcated iliac side-branch ZBIS, COOK).

The study presents a retrospective analysis of prospectively collected data from a single-center series reviewing 39 consecutive patients who were treated at Franziskus-Krankenhaus, Berlin, between October 2007 and July 2014, with pure endovascular therapy of aortoiliac aneurysms by using the ZBIS systems. Additionally, it offers a systematic literature review of studies published in English until January 2016 analysing the results of endovascular treatment of aortoiliac aneurysms with iliac stent-grafts with side branches (Iliac side-branch ZBIS or Helical Graft, COOK) to compare with the presented series.

The results indicate that the antegrade flow of pelvic arteries can almost always be preserved with EVAR including efficient therapy of common iliac artery aneurysms and internal iliac artery aneurysms by using the ZBIS system. This agrees with the findings in the reviewed literature.

I. Introduction

I.1 Historical Background

The present study investigates possibilities for total endovascular therapy of aortoiliac aneurysms (AIA) with preservation of internal iliac artery (IIA) patency using Iliac Branch Device™ (Cook, Bloomington). The management of aortic aneurysms has fundamentally changed in recent years with the development of endovascular devices offering reduced perioperative mortality and faster recovery times in comparison to open surgical repair. A review of the historical trajectory of surgical therapy of aortic aneurysms underlines the importance of this recent development.

Surgical therapy of iliac artery aneurysm (IAA) was first performed in 1817, when Sir Astley Paston Cooper of Guy's Hospital, London, operated on a 37-year-old male patient who suffered from a traumatic aneurysm of the external iliac artery (EIA). Cooper ligated the aorta above the aneurysm. The patient died 40 hours after the operation (112).

In 1827, Cooper's student Valentine Mott (New York) conducted the first successful operation for a common iliac artery aneurysm (CIAA) by ligating the proximal iliac artery (52). Ligation remained the only treatment option for IAAs until the 1950s (202).

However, for infrarenal abdominal aortic aneurysms, endovascular therapy was introduced as early as 1864 with the application of steel wire (wiring) as developed and described by Moore and Murchinson. They had inserted steel wire through a puncture needle into the lumen of the aneurysm. The wire created an internal mantling of the abdominal aortic aneurysm (AAA), but the patients did not survive the first postoperative year (166). In the 1960s, the basic idea to stabilize the internal vascular wall was developed further thanks to technical progress. Percutaneous transluminal angioplasty (PTA) and intraoperative transluminal angioplasty (ITA) were introduced for the therapy of stenosis and short segment vascular obstructions. Intentional ligation of the internal iliac artery (IIA) has been used since the 1960s in young women with pelvic pathology to reduce pelvic circulation and blood loss during gynecological operations (24).

In the 1980s and 1990s, the feasibility of treating AAAs by implantation of stent grafts was demonstrated in animals. In 1987, the Soviet surgeon Nicholas Volodos (Kharkov) performed the first endovascular aneurysm repair (EVAR) (220); in September 1990 Parodi, Palmaz and Barone in Argentina treated for the first time an infrarenal AAA with a diameter of 6.5 cm with a covered stent graft (164). With the improvement of these first devices over time, and commercial development of the technology, the technique has spread worldwide. In 1989, Iliopoulos et al. measured intraluminal IIA pressures and its variations from intermittent clamping of the pelvic branches. Their findings suggested that ascending branches from the ipsilateral external iliac-deep femoral system provide a more significant collateral pathway to the region of the occluded IIA than the contralateral (89).

In 1994, the term transluminal placed endovascular graft (TPEG) was coined by Veith (218).

In 1994 and 1995, the clinical feasibility of repairing complex multisegmental AIAs with the aorto-uni-iliac-femoral stent graft was described by Parodi, May, and Marin (132, 136, 165). The term 'endoleak' was introduced in 1997 by White et al. to describe "persistent blood flow within the aneurysm sac but outside the stent-graft" (222).

In 1999, Parodi described proximal ligation and transection of IIA following direct revascularization of the IIA as a procedure to lengthen the distal anchoring site to a more distant site EIA (163). Occlusion of the IIA with catheter-based technology is an alternative option.

In 2001, vascular surgeons described the use of the occluder for endovascular repair of aortic aneurysms, especially in the implantation of the aorto-uni-iliac (AUI) stent grafts. Initially, the occluder was used mainly by cardiologists in occluding the ventricular septal defect (VSD) and atrial septal defect (ASD) (198).

In the same year, Karch et al. were the first to describe the bell-bottom technique (BBT) (96).

In 2002, the feasibility of percutaneous access also after using sheaths up to 27F. was assessed by Torsello et al. (210) In 2009, Schlösser et al. demonstrated the significance of endoleaks, showing them to be the major source of rupture in 160 of 235 patients (193).

Malina and Dias published the first study of the Iliac Branch Device in 2006 (131).

I.2 Significance of the subject

IIA anatomy and function

The IIAs and the inferior mesenteric artery (IMA), which connect through their hemorrhoidal branches, provide the main supply of pelvic blood flow. The IMA, lumbar arteries, EIAs, and profunda femoral arteries, are linked to the IIA and its branches by manifold anatomic connections (90). Connolly et al. state that “branches of the IIAs anastomose with the lumbar and middle sacral arteries, proximally, and with the circumflex branches of the external iliac and common and deep femoral arteries, distally.” (34). By supplying blood to the penis through the internal pudendal arteries, the IIAs are involved in erectile function. The quality of the contralateral IIA and ipsi- and contralateral deep femoral collateral branches, all adding to the vascularization of the pelvis, are essential for collateral circulation (89). Most of the blood supply to the buttocks is provided through the posterior division of the IIA and to the rectosigmoid and genital areas through its anterior division (73). Internal iliac circulation is also an important mechanism to maintain collateral flow to the spinal cord during endovascular repair of the more proximal aortic segments (69). It is therefore necessary to take pelvic circulation into consideration when evaluating possible options and approaches for treating AAA with CIAA. It must be considered if, in any given case, pelvic artery circulation is hampered by severe arteriosclerosis, or if previous pelvic radiation therapy may have caused some damage to pelvic collateral vessels.

Aneurysm location

Patients with CIAA may have adverse anatomic features, and medical co-morbidities may be present (154): Hobo et al. showed that patients with concomitant CIAA suffered from an increased occurrence of type Ib endoleaks, iliac limb occlusion, reinterventions, and aneurysm rupture (84). Similar results in patients with CIAA stretching to the distal third of the CIA (common iliac artery) were reported by Albertini et al (2).

The majority of aneurysms occur in the CIAs. A much smaller part occurs in the IIAs. The proportion of aneurysms occurring in the EIAs is almost negligible (118). One cannot give a uniform definition of an iliac aneurysm. As Lee states, “the spectrum of normal, ectasia, arteriomegaly, and aneurysm is an anatomic continuum, whose clinical relevance can be defined only in the context of surgical or endovascular terms.” (118). Generally, definitions are based on the vessel diameter and morphology. Vessels with a diameter between 8 and 12 mm are usually classified as normal, vessels with a diameter between 13 and 20 mm are considered as ectasia (tortuous) or arteriomegaly (nontortuous), and vessels with a diameter greater than 20 mm aneurysm. CIAs have an average length of 50-60 mm. This length varies considerably depending

on age, iliac ectasia–arteriomegaly–aneurysm, occlusive disease, and ethnic background: Cheng et al. note that the CIAs of people of Asian-Pacific descent may be relatively short compared with people of Caucasian descent, with average lengths of 25 to 30 mm (29).

Isolated iliac aneurysms are scarce (23). Recent studies quote the prevalence of isolated iliac aneurysms as 1.4 – 11.7 % (15, 120, 152). This considerable variation in size must be understood in terms of geography and mode of examination. Isolated iliac aneurysms occur uni- as well as bilaterally; there is no recognizable preference for either side in the unilateral cases (182). Unilateral CIAA occur in 43%, bilateral CIAA occur in 11 % of patients with intact AAA (82). Generally, concomitant CIAAs are present in 15% to 40% of patients with AAA (104).

It must be noted that not all IAAs are present at the time of initial diagnosis of an AAA. Regarding external iliac artery aneurysms (EIAA), they are extremely rare. It is advisable to always question the diagnosis of an EIAA and to consider alternative etiologies, such as connective tissue disorders, dissections, fibromuscular dysplasia, or iatrogenic acquired causes (118).

I.3 Problem and Subject of the Dissertation

The introduction of endovascular devices has fundamentally changed the management of infrarenal aortic aneurysms. If at the outset of the endovascular era, Krupski et al. stated in 1998 that in isolated iliac aneurysms, “endovascular repair may be less durable and effective than direct surgical repair” (112), endovascular techniques have today become wide-spread, not least in the treatment of IAAs (206). The increasing popularity of endovascular treatment of AAAs with endografts is due to decreased perioperative mortality and faster recovery times in comparison to open surgical repair.

In conventional EVAR, the presence of CIAA hindering an effective seal and distal fixation is a major anatomic difficulty. Two considerable safety challenges are exposed by extensive iliac aneurysm repair, namely “preservation of pelvic circulation to avoid ischaemic complications, and durable effective exclusion of the aneurysm to prevent risk of rupture in the long term” (162, 123).

Another problem is AAA associated with shorter CIAs. This is particularly prevalent in Asian patients, especially on the right side (29). In 20% to 30% of cases, short or aneurysmal CIAs with aortic and CIAAs were encountered (80), posing a challenge to solitary and uneventful EVAR procedures. The difficulty is even greater with the involvement of bilateral CIAA and profound concerns of severe pelvic ischemia (95, 229).

Isolated iliac aneurysms are rare (they occur at a rate of 0.008-0.03%) (23), but up to 40% of AAA have coexisting unilateral or bilateral iliac artery ectasia or aneurysms (5, 84). The most dangerous complication is rupture of the IAA, which is difficult to diagnose because there is typically no tactile pulsative mass. To prevent complications, elective repair has been advised for isolated IAA with a diameter of >3 cm (112, 186).

The complexity of the required endovascular or open repair (OR) is increased when the aneurysmal disease is more extensive and involves the visceral vessels, the CIAs or IIAs. This is associated with heightened morbidity and mortality (26, 36, 192, 203). While the mortality in open repair of an IAA can be compared to elective repair of open AAA, in the case of emergent interventions, mortality rises to 33%. The anatomic proximity of ureters and veins to the iliac arteries in the pelvic area augments the risk of injuring these formations. This factor contributes to the heightened morbidity associated with this procedure (112, 149, 186). The most frequent

complications after complex aortic reconstructions may be considerably reduced if a less invasive approach is available (70).

In cases where no adequate distal landing zone is available, EVAR classically involves the occlusion of one or both IIAs and extension of the stent graft into the EIA. The necessity of this procedure has been estimated at 15% to 30% of cases (37, 95, 114, 116, 205).

When one or both IIAs were sacrificed during AIA repair, the most frequently cited complications included incapacitating hip and buttock claudication (BC), colonic ischemia (CI), erectile dysfunction, perineal or spinal ischemia, and buttock necrosis (21) but also bladder dysfunction, sacral decubitus ulceration, and scrotal skin sloughing. BC has been cited as the most prevalent complication, observed in up to 45 % of cases (228).

Reports suggest that iliac stent prostheses with side branches (iliac side-branch Z-bis or helical graft, COOK) present a valid new endovascular approach. These iliac branch devices (IBD) manage AIAs by effectively maintaining antegrade flow into at least one IIA. In the management of internal iliac aneurysms, IBD's primary purpose is to reinforce the weakened section of the blood vessel, to prevent rupture of the aneurysm and to maintain adequate blood flow. In an additional effect, by expanding like a spring to press securely against the wall of the artery, the frame of the IBD cuts off the blood supply to the aneurysm. By flowing through the IBD, the blood now bypasses the aneurysm.

The objective of this study is to contribute to the evaluation of endovascular therapy (EVAR) of AIAs by using the iliac side-branch device (Zenith bifurcated iliac side-branch ZBIS, Zenith® Branch, COOK MEDICAL INCORPORATED, Bloomington, U.S.A.). The study presents a retrospective analysis of prospectively collected clinical data on a single-center series of 39 consecutive patients (38 male, 1 female) who received pure endovascular therapy of AIAs by using the iliac branch device (IBD) at Franziskus-Krankenhaus, Berlin, between October 2007 and July 2014. In addition, the study presents a systematic review of the literature published in English about the iliac branch device until January 2016. This allows to better situate the results of the series presented, and to relate them to previous findings.

II. Material and methods

II.1 Literature Review

The literature review presented here builds on, and adds new data, to the first systematic review analysis of studies about IBD which was published in 2010 by Karthikesalignam et al. (97). Their comparative review included data from 195 patients (rather than 196 patients, as erroneously stated in the article (97)).

The objective of the literature review is an analysis of the outcomes of endovascular therapy of AIAs with iliac stent prosthesis with side branch (Iliac side-branch Z-bis or Helical graft, COOK). This overview will contribute to evaluating the efficacy and safety of IBD, and it will give the necessary background of studies conducted until January 2016 in order to compare the data presented in this study with previously published evidence.

An electronic search was performed to identify all reports published in English until January 2016 using the PubMed, Medline, Medscape databases as well as Google search engine for an internet search. The search terms “EVAR”, “hypogastric artery”, “internal iliac artery” and “iliac branch graft”, “iliac branch device”, “IBD”, “endovascular repair of iliac artery aneurysm” were used. IBD reports containing fewer than 6 patients were excluded. The study of Pearce et al. (167) analysing the anatomic suitability in 99 patients through usage of the anatomic inclusion and exclusion criteria of the Cook IBD and Gore IBE trials was not included in this evaluation because it did not explain the number of patients treated with IBD and therefore could not contribute to the objective of the present study. The results of the literature review are presented in section III.1.

II.2 Patients and methods

This study presents a single-center series of 39 consecutive patients who were implanted with IBD between October 2007 and July 2014 at Franziskus-Krankenhaus (Berlin, Germany), a tertiary vascular centre. Patients were treated with pure endovascular therapy of AIAs by using the iliac branch device (IBD). In the total number of 39 patients, 48 IBDs were implanted.

Prospectively maintained computed databases were used to obtain patients' characteristics as well as preoperative, intra-operative and follow-up clinical and imaging data. The present study excludes patients treated with other endovascular procedures during the same period, such as simple common iliac endograft, bell-bottom or IIA coiling embolisation/occlusion, as well as pseudo-aneurysms, symptomatic, and ruptured iliac aneurysms as well as iliac aneurysms managed with open repair.

Treatment was indicated by the occurrence of isolated unilateral or bilateral CIAA with a diameter ≥ 30 mm or the presence of CIAA of >21 mm diameter associated with AAA. In some cases the CIA was not aneurysmatic, but the IIA was. Those patients were also treated with IBD, although the diameter of CIA in these cases was < 30 mm. We also treated some cases with IBD preventively when the CIAA was < 30 mm but extended until shortly before the bifurcation. Treatment with IBD was decided according to anatomic characteristics of aorto-iliac vessels and presence of severe co-morbidities. The decision for treatment with IBD was taken when the CIAAs extended distally to preclude an appropriate distal landing zone with conventional endovascular stent graft.

In all cases, treatment was associated with deployment of a bifurcated EVAR graft. Only in one case had EVAR been conducted 9 years previously. The requirement for correct graft expansion was a patent lumen of the CIA of at least 18 mm in diameter, 40 mm in length and a distal landing zone of a length of at least 10 mm on the main IIA trunk. A further condition was an adequate length of EIA for a distal landing of more than 15 mm and EIA diameter <12 mm. In contrast, severe IIA atherosclerosis, small CIA diameter (<18 mm) at the level of bifurcation, severe kinking and calcifications of EIA and wide angle of IIA off-spring were exclusion criteria for IBD.

In all cases, contrast-enhanced computed tomographic (CT) aorto-iliac imaging was obtained and used for preoperative planning, and subsequently deposited in a prospective computed data set. All patients received antiplatelet or anticoagulation therapy. In cases where patients had been taking anticoagulants before the intervention, mostly for cardiac indications, this therapy was continued after the operation. In all other cases, a daily dose of 100 mg of acetylsalicylic acid was prescribed. All patients gave informed consent before the procedure.

Our IBD procedure

Except one patient who received a particular type of second-generation IBD (REINFORCED-ILIAC-SIDE-BRANCH, COOK), all patients received a second-generation IBD, the Zenith straight version of the Zenith iliac branch device (ZENITH® BRANCH GRAFT ZBIS, Cook®). It consists of a bifurcated vessel graft including a main iliac limb with an additional reinforced stump for the IIA side branch, with a fixed proximal diameter of 12 mm and a distal diameter of 10, 12 or 16 mm, a common iliac segment length of 45 or 61 mm and an EIA segment length of 41 or 58 mm. The IBD was fitted within an indwelling catheter preloaded with a 0.035'' guidewire. The IBD was introduced through femoral access, using a small surgical cut down over a stiff guidewire (Lunderquist, Cook Inc., Bloomington, IN, USA). It was oriented under fluoroscopic guidance. Placement was carried out in such a manner that the short leg was located medially 1 cm above the IIA offspring. Subsequently, the delivery sheath was withdrawn and the tip of the preloaded catheter exposed. The preloaded 0.035'' guidewire was subsequently snared from the contralateral side to create a through-and-through access. This was used to guide the introduction of a sheath entering the device's main body, exiting through the IIA side branch. The IIA was catheterised with a hydrophilic guidewire through this sheath. In order to ensure adequate sealing and patency, a bridging covered stent was used to fill the gap between the side branch of the IBD and the IIA. The required length had previously been determined with pigtail catheter using digital subtraction angiography (DSA). Where available, landing of the bridging covered stent of the internal branch was reached on the IIA distal common trunk. The main bifurcated Zenith body was deployed from the contralateral side. Then, the gap in the proximal portion of the IBD was bridged with a Zenith iliac limb. Then, the extension leg of the main bifurcated Zenith body is implanted contralaterally. Treatment of patients with bilateral CIA aneurysms was attempted by IBD implantation in both sides where initially, both iliac stent grafts and subsequently the aortic stent graft's main body delivery system were deployed. All junctions between the stent grafts (top, bottom, and landing zones) were subject to balloon angioplasty. Accuracy of positioning, patency of IBD, exclusion of aneurysms and endoleak presence were assessed by routine performance of completion angiography. Multiple views in double projection were used to monitor the adequacy of external branch landing.

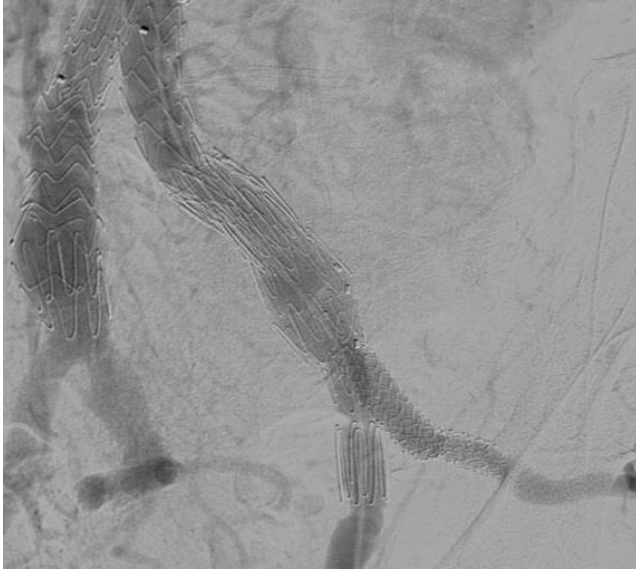


Figure 1. *Angiography confirms satisfactory position and patency of the internal iliac side branch.*

Follow-up protocol

A computed tomography (aorto-iliac CT) scan and a plain X-ray just prior to discharge were used to perform initial post-operative imaging. Further imaging and clinical follow up post-operatively were performed at 6, 12, 18 and 24 months, and at least annually after that with ultrasound and a plain X-ray and CT scan. In one case, due to impaired renal function, follow-up was performed just with ultrasound and plain X-ray. Arterial diameters were measured as the shortest outside transverse diameter of the artery on CT scans by the same observer. AAA and iliac diameter changes exceeding 3 mm were considered significant. Arterial length was measured with centreline of flow from the CT scan. Follow-up data were determined by contacting patients and reviewing the most recent imaging. Follow-up length was defined as the time between the procedure and the most recent check-up of the patient.

Study end points and definitions

Technical success was defined as positioning the device in the intended position, with patency of the IAA and EIA and absence of endoleak type I and III (completion angiogram), as well as survival through 24 hours.

To assess long-term outcomes, Kaplan-Meier reintervention and patency estimates were calculated. With regard to all measurements, a value of $p < 0.05$ was considered statistically significant.

III. Results

III.1 Results reported in the literature

This chapter begins with the results of the literature review and then details the results of the series presented (Franziskus-Krankenhaus).

With regard to the literature evaluated for this study, Table 1 presents a comparative overview of studies about IBD which were published between 2006 and 2015, showing initial technical success, as well as short- to mid-term follow-up. As two pairs of reports (by Dias/ Malina (47, 131) and Greenberg/Haulon (70, 76)) included the same patients, only the most recent data were reviewed. Of the reviewed series, one series (Verzini et al. (219)) contained the first comparative study of IBD with IIA occlusion. All in all, 26 unique case series reporting the use of 909 IBDs in a total of 846 patients were reviewed.

Generally, the rate of technical success per vessel varied between 69% and 100% for all IBD forms currently in use. In detail, technical success per vessel was n=855 (94%) of altogether 909 planned IBD, showing the feasibility of IBD use in a selected group of patients. Initial clinical success (<30 days) per vessel was n=834 (91.7%) of overall 909 planned IBD. Clinical success rates varied between 61% and 100% per vessel within the follow-up range of the 26 studies included in the review.

Overall, 78 IBD occlusions (8.58% of all planned IBD) were observed across 846 patients in all series, 2 of which were restenosis of the IIAs branch (50). These IBD occlusions led to BC in 29 patients (37.1% of occluded IBDs). In 3 of these 29 patients, IBD occlusions were associated with erectile dysfunction (60, 113, 233) and in one case with a subschemic colic episode (135). 2 cases of BC were treated successfully by placing of an additional covered stent (Advanta) in the IIA (50).

Table 1. Review of published literature: Outcomes in patients with IBD.

	Author, year	Number of patients treated with IBD	Number of IBD	Median follow-up (months)	Technical success in % (n of successful IBD / n of planned IBD)	Initial clinical success (<30 days) % (n of successful IBD / n of planned IBD)	Short-term clinical success (30 days-6 months) % ((n of successful IBD / n of planned IBD)	Mid-term clinical Success (6 months-5 years) % (n of successful IBD / n of planned IBD)
1	Dias/Malina et al., 2008/2006 (47, 131)	22	23	20 (8-31)	91% (21/23)	87% (20/23)	83% (19/23)	74% (17/23)
2	Haulon/Greenberg et al., 2007 (76)/2006 (70)	52	53	14.2	92.4% (49/53)	77.3% (41/53)	77.3% (41/53)	77.3% (41/53)
3	Ziegler et al., 2007 (235)	46	51	24 (3-60)	69% (35/51)	69% (35/51)	61% (31/51)	61% (31/51)
4	Serracino-Ingloft et al., 2007 (196)	8	8	6 (1-14)	100% (8/8)	88% (7/8)	88% (7/8)	88% (7/8)
5	Tielliu et al., 2009 (207)	27	30	16 (1-38)	97% (29/30)	87% (26/30)		
6	Verzini et al., 2009 (219)	32	32	9.8 (1-24)	94% (30/32)			

7	Huilgol et al., 2009 (87)	25	25	12 (1–38)	100% (25/25)	100% (25/25)	100% (25/25)	96% (24/25)
8	Karthikesalingam et al., 2010 (99)	8	8	11.3 (2.6–24)	75% (6/8)			75% (6/8)
9	Ferreira et al., 2010 (60)	37	47	11.6 ± 7.5	98% (46/47)			87% (41/47)
10	Laurito et al., 2010 (113)	6	6	-	83.3% (5/6)	66.6% (4/6)	66.6% (4/6)	
11	Pua et al., 2011 (174)	14	16	18.7 (6–35)	87.5% (14/16)	87.5% (14/16)	87.5% (14/16)	87.5% (14/16)
12	Donas et al., 2011 (50)	64	64	30.5 ± 20.9	100% (64/64)	98.4% (63/64)		92.1% (59/64)
13	Huilgol et al., 2011 (88)	6	12	15 (7–34)	100% (12/12)	100% (12/12)	92% (11/12)	92% (11/12)
14	Parlani et al., 2012 (162)	100	100	21 (1–60)	95% (95/100)	95% (95/100)	93% (93/100)	93% (93/100)
15	Wong et al., 2013 (225)	130	138	20.3 (1–72)	94% (129/138)	90.5% (125/138)	88.4% (122/138)	85.5% (118/138)
16	Pratesi et al., 2013 (171)	81	85	20.4 ± 15.4	98.8% (84/85)	97.6% (83/85)	97.6% (83/85)	97.6% (83/85)
17	Fernández-Alonso et al., 2013 (59)	9	9	14.7 (9–29)	100% (9/9)	100% (9/9)	100% (9/9)	100% (9/9)
18	Maurel et al., 2013 (135)	39	39	-	95% (37/39)	92% (36/39)	92% (36/39)	
19	Austermann et al., 2013 (7)	16	21	-	100% (21/21)	100% (21/21)	95.3% (20/21)	95.3% (20/21)
20	Graham et al., 2013 (66)	7	7	3.5 (1–15)	100% (7/7)	100% (7/7)	100% (7/7)	
21	Unno et al., 2014 (214)	6	6	14.2 (5–28)	100% (6/6)	100% (6/6)	100% (6/6)	100% (6/6)
22	Chowdhury et al., 2014 (30)	27	28	11.3 ± 5.3	100% (28/28)			96.4% (27/28)
23	Bisdas et al., 2014 (13)	18	22	15 (4–25)	100% (22/22)	100% (22/22)	100% (22/22)	100% (22/22)
24	Loth et al., 2015 (128)	41	45	32 ± 27.3	87% (39/45)			84.4% (38/45)
25	Noel-Lamy et al., 2015 (156)	14*	19	18.3	100% (19/19)	100% (19/19)	100% (19/19)	
26	Zhang et al., 2015 (233)	11	15**	12 (8–21)	100% (15/15)	100% (15/15)	86.7% (13/15)	100% (15/15)

* One of the initially 15 patients deceased two days after the intervention. The death was caused by mesenteric ischemia due to a complication involving a custom three vessel fenestrated abdominal aortic stent graft. Noel-Lamy et al. did not include the patient in their subsequent analysis.

** All were one of two types of novel-designed iliac branch stent grafts (IBSGs).

In addition to these cases, 7 patients who underwent successful implantation of an IBD experienced BC (171, 219), among them 6 patients who had been treated for bilateral CIA aneurysms and who developed claudication after IIA exclusion in this side (171).

Loth et al. (128) reported one patient who had been treated successfully with a straight-branch iliac bifurcation device (S-IBD) but at 18-month follow-up complained of BC without disruption of flow on Doppler ultrasound; however this resolved without intervention and was therefore not counted as a failure.

67 patients (7.91%) required post-operative re-intervention across all series (Tab. 2). There were 22 EIA occlusions. 5 of these cases were managed with thrombolysis (60, 70, 76, 128), 3 were managed with thrombectomy (13, 219), 4 were managed with thrombectomy and stent

implantation (128, 162), and 4 were reopened with thrombolysis and supplemental stents distally (128, 225). In one case, stenosis of the EIA was managed twice with balloon angioplasty followed by stent implantation (128). In one other patient, stenosis of CIA was managed by angioplasty with stenting (13). In 4 other patients, a cross-over femoro-femoral bypass was performed for an external iliac leg thrombosis (135, 162, 225) and in 1 patient, thrombectomy and ilio-femoral artery bypass were performed due to external endograft limb occlusion contralateral to IBD (171). In 1 case, ischemia with ipsilateral EIA occlusion led to above-knee amputation at 15 months post-surgery (87).

Table 2. Review of published literature: Complications and secondary interventions.

	Author, year	Type I Endoleak (per number of patients)	Type III endoleak (per number of patients)	Post- operative re- intervention s (per number of patients)	Patients with BC or erectile dysfunction following IBD occlusion, as proportion of the total number of patients with post-operative IBD occlusion
1	Dias/ Malina et al., 2008/ 2006 (47, 131)	0/22	1/22	4/22	3/6 BC
2	Haulon/ Greenberg et al., 2007 (76)/ 2006 (70)	0/52	0/52	3/52	6/6 BC
3	Ziegler et al., 2007 (235)	0/46	0/46	0/46	1/4 BC
4	Serracino-Inglott et al., 2007 (196)	0/8	0/8	0/8	0/1
5	Tielliu et al., 2009 (207)	0/27	0/27	0/27	1/3 BC
6	Verzini et al., 2009 (219)	1/32	1/32	5/32	0/2
7	Huilgol et al 2009 (87)	2/25	0/25	2/25	0/1
8	Karthikesalingam et al., 2010 (99)	0/8	0/8	0/8	1/2 BC
9	Ferreira et al., 2010 (60)	0/37	0/37	1/37	1/5 BC and erectile dysfunction
10	Laurito et al., 2010 (113)	0/6	0/6	0/6	1/1 BC and erectile dysfunction
11	Pua et al., 2011 (174)	0/14	1/14	1/14	0
12	Donas et al., 2011 (50)	2/64	2/64	6/64	2/5 BC
13	Huilgol et al., 2011 (88)	0/6	0/6	1/6	0/1
14	Parlani et al., 2012 (162)	2/100	1/100	9/100	4/7 BC
15	Wong et al., 2013 (225)	4/130	0/130	12/130	5/18 BC
16	Pratesi et al., 2013 (171)	3/81	0/81	3/81	1/3
17	Fernández-Alonso et al., 2013 (59)	0/9	0/9	0/9	0
18	Maurel et al., 2013 (135)	0/39	1/39	3/39	1/2 BC and subischemic colic episode
19	Austermann et al., 2013 (7)	0/16	0/16	1/16	0/1

20	Graham et al., 2013 (66)	0/7	0/7	0/7	0
21	Unno et al., 2014 (214)	0/6	0/6	0/6	0
22	Chowdhury et al., 2014 (30)	2/27	0/27	1/27	0/1
23	Bisdas et al., 2014 (13)	0/18	0/18	2/18	0
24	Loth et al., 2015 (128)	2/41	2/41*	7/41**	0
25	Noel-Lamy et al., 2015 (156)	0/14	0/14	2***/14	0
26	Zhang et al., 2015 (233)	1/11	1/11	4****/11	2/2 (2 patients with BC, 1 of whom also suffered from erectile dysfunction)

* In addition, one non-classifiable leak.

** One patient requiring two reinterventions during follow-up.

*** In the one case of type II endoleak which occurred, the anterior division originated from the IIAA. The attempt at embolization was not successful.

**** In the one case of IIA branch occlusion, which was reported to have been found 36 days after the intervention, treatment with catheter-directed thrombolysis was successful.

There were 3 asymptomatic patients. In 2 of them, stenting of EIA for asymptomatic kinking was performed (47, 131, 156). The other patient revealed an asymptomatic pre-occlusive thrombosis of the external IBD segment at the 3-year CT scan, which was successfully treated with thrombolysis and stenting (171).

In 11 cases, post-operative reinterventions were needed due to IBD occlusion. Most IBD occlusions were managed conservatively. In one case, the occluded IBD recanalised spontaneously (235). One case of subtotal IBD occlusion was managed successfully with thrombectomy and subsequent stent placement in the ipsilateral iliac axis due to residual stenosis (50); in one case of IIA branch occlusion, which was reported to have been found 36 days after the intervention, treatment with catheter-directed thrombolysis was successful (233). In another case with bilateral IBSGs, occlusion of the internal IBSGs was reported at 6 months after the surgery due to a kink in the transition between the short limb of the aortic stent graft and the branch of the IBSG. Treatment with a stent graft proved successful (233). In another case of total occlusion of the entire iliac segment 6 months post-surgery involving acute limb ischemia, thrombectomy was successful (7); treatment with femoro-femoral cross-over was successful in three patients with occlusion of the external iliac leg on the side of the IBD (47, 88, 131, 135). Three other reinterventions attempted recanalization of an occluded iliac branch, and stenting of a stenosis at a junction between a crimped limb and a helical iliac side branch device (H-IBD) (225). One case of overstenting of the IIA and placement of endurant limb into the EIA due to a failed recanalization attempt of the dislocated endograft. The dislocation was caused by rupture of a coexisting internal iliac aneurysm of 6 cm diameter 23 months after the IBD placement (50).

22 re-interventions were performed due to endoleaks. 14 of these cases concerned type I endoleaks, six cases concerned type III endoleak. All type II endoleaks were managed conservatively except two cases, in which embolization of a middle sacral artery were performed through feeder vessels of the IBD side (225), and in one case of type II endoleak where anterior division originated from the IIAA, embolization attempt was not successful (156). Regarding the cases of endoleak type I, two cases were managed with coil occlusion of the IBD branch and the IIA (87, 162); five type Ib endoleaks were managed endovascularly with an additional stent graft at distal IBD sealing zone (50, 73, 219). One patient with a type 1b endoleak in the iliac system contralateral to the IBD was treated with an iliac stent graft extension 6 months after the initial intervention (30). In one series (225), there were four cases with IBD-related type I endoleaks

(two helical iliac branch device (H-IBD) and two bifurcated-bifurcated iliac side branch device (BB-IBD), all in patients with IIAs requiring sealing within the IIA posterior trunk. It was reported that all cases were successfully treated, but no information on the manner of management was given.

Five cases of type III endoleak were reported at the junction of the IIA limb of the IBD with its main body (47, 131, 162, 174, 219, 233); all five cases were managed with an interposition endovascular stent graft. One other case of type III endoleak was managed by recanalization of the iliac axis, placement of coils in the IIA and placement of a limb from the CIA to the EIA (50).

The other post-operative re-interventions were: one IIA stent graft extension due to inadequate overlap into the artery (47, 131), one iliac aneurysm growth which led to aorto-bi-iliac stent graft implantation (162), one EIA-to-IIA surgical bypass due to proximal IBD side-branch collapse (171), two femoral artery repair for pseudoaneurysm at access site (162, 219), one surgical repair due to bleeding of common femoral artery (CFA) (50), one conversion to open aneurysm repair due to backflow into IIA which later led to dilatation of CIA in spite of overstenting (overstenting had occurred because of anatomic impossibility to deliver the second-generation S-IBD graft) (128).

Across all patients in all series, two fatalities were aneurysm-related due to stent graft infection detected three months after repair and followed by sudden death (162). One other patient, who was therefore excluded from the subsequent analysis, died of mesenteric ischemia two days post-surgery due to a complication with a custom three vessel fenestrated abdominal aortic stent graft (156).

The study of Dias et al. (47), including the study of Malina et al. (131), comprised 22 patients, one of whom with bilateral IBD. They demonstrated a primary technical success rate of 91% with a median follow-up time of 20 months. This series used primarily ZBIS in 18 cases, the H-IBD in three cases and an 'in-house' custom-made endograft based on the Chuter design in two cases. The overall IBD was 74% due to six branch occlusions, two of them intraoperative and four during follow-up. Three of the six patients with branch occlusion developed claudication, three others were asymptomatic. All patients with patent IBD were reported as asymptomatic. One patient with a type III endoleak at the junction of the IBD and the main aortic endograft was reported three months after surgery. The patient was successfully treated by use of an extension cuff. Four patients overall (18%) required reinterventions: one bilateral stenting of the EIAs for asymptomatic kinking, one extension from AAA graft into EIA for type III endoleak, one internal stent graft extension and one femoro-femoral cross-over bypass after IBD occlusion.

Haulon et al. (76) presented 52 patients with 53 IBD in a multicenter setting, in an update on an earlier report by Greenberg et al (70). All patients were treated with H-IBD. Haulon et al. reported a technical success rate of 94% and mid-term clinical success rate of 79% with a median follow-up of 14.2 months due to three cases of failure to apply IBD; in two of these cases caused by inability to visualize IIA, and in one case caused by inability to cross the aortic bifurcation.

In six other cases (11%), occlusions of internal iliac branches occurred in the first month (30 days); and late branch occlusions (>30 days) were nil. In one case EIA occlusion on the side of the IBD was found. No endoleak type I or III were noted. Long-term mortality was reported at 13.5%. No deaths were related to aneurysms. Reintervention was required in three cases, two of them thrombolysis for occlusion of tortuous EIA contralateral to IBD, one ipsilateral to occluded IBD.

Ziegler et al. (235) presented a single-center study from Germany, reporting on the results of 51 implants attempted in 46 patients. They initially used an unibody design IBD for their first 26 patients which is now discontinued. It was followed by the modular ZBIS in the last 20 patients. Their series showed technical success per patient at 62% (16/26) for the first-generation device and 85% (17 of 20) for the second-generation device. In eight cases of the 13, failures of the first-generation device were due to the inability to catheterize the IIA through the sidebranch (usually associated with ostial stenosis) or, in three cases, intraoperative sidebranch occlusion; in another three cases, device failure was reported. The three failures of the second-generation devices were in two cases secondary to intraoperative occlusion and in one case to sidebranch deployment failure. A Kaplan-Meier estimate of IIA patency among the 35 successful implantations at 60 months was 87.3%. The number of reported endoleaks was nil. Post-operative re-interventions were nil. There was one intraoperative thrombolysis and angioplasty to treat the occluded IBD.

Serracino-Inglott et al. (196) published a single-center experience from Australia about successful CIA treatment with second-generation IBD implantation in 8 patients, 2 of them aorto-bi-iliac aneurysms, 3 aorto-uni-iliac aneurysms, 1 solitary CIA, and 2 IIA. They reported no aneurysm growth or endoleak at a median follow-up of 6 months. One late occlusion of the IBD side branch occurred without significant symptoms.

Tielliu et al. (207) presented a series on IBD insertion (all ZBIS) in 27 patients with 3 bilateral cases. They reported technical success in 96.3% (26 cases) with a mean follow-up of 16 months. In one patient, the procedure was not successful when IIA catheterization proved impossible. Initial clinical success within a month (<30 days) was reported at 86%. 3 cases of IBD occlusion occurred; in one of these cases, BC was reported. Incidence of endoleak type I or III was nil. No mortality within 30 days or long-term with regard to operative technique or device insertion was reported.

Verzini et al. (219) published the first report comparing early and 1-year outcome of coil embolization of IIA with IBD approach in a consecutive series of 74 patients treated for significant (< 24 mm) unilateral or bilateral iliac aneurysms associated or not with aortic aneurysm. There were 32 cases of unilateral ZBIS insertion (group I); 42 patients were treated by coil embolization followed by endograft extension across the iliac bifurcation (group II). Similar immediate technical success rates (94 and 93 %, respectively) were reported with a mean follow-up of 9.8 months. In the IIA embolization group, re-intervention rates were lower (9.5 %) than in the IBD group (16 %). Overall, 5 reinterventions were required in the IBD group. These were in 2 cases thrombectomy for EIA occlusion, in one case femoral artery repair for pseudoaneurysm at access site, one secondary IIA stent for type I endoleak at distal IBD sealing zone and one interposition endograft for type III endoleak at IIA branch/IIA stent interface. They found frequent occurrence of endoleak and BC in patients with iliac aneurysm treated with IIA exclusion, while these were uncommon in the patients with IIA revascularization. They reported 30-day or long-term mortality at 3%. However, no mortality was noted with regard to operative technique or device insertion. It is remarkable that this comparative study did not find a statistically significant difference between the two groups regarding the occurrence of pelvic ischaemia.

Huilgol et al. (87) published a multi-centre series of 25 patients with CIAA repair between 2004 and 2007, using the IBD (all cases were unilateral, ZBIS implantations); twenty-one cases were combined with EVAR. Technical success was reported at 100%, while mid-term clinical success was 96% with a mean follow-up period of 12 months. 30-day mortality was reported at 8%, but no mortality was reported with regard to operative technique or device insertion or as aneurysm-related. There was one case of IBD occlusion and two cases of type I endoleak. Overall, two

post-operative reinterventions were required; in one patient due to a coil occlusion of the IBD branch and the IIA with endoleak type I, in the second case due to ischaemia by ipsilateral EIA occlusion, leading to above-knee amputation at 15 months post-operatively.

Karthikesalingam et al. (99) in 2010 published a series of eight patients, all of them cases of unilateral ZBIS implantation. Technical success was 75% with two IBD occlusions, both of which were managed conservatively, in which one patient developed symptoms of BC. Mean follow-up was 11.3 months. They reported only one patient with type II endoleak at follow-up. Postoperative mortalities were nil. Branch graft patency at the latest radiological follow-up was reported in 6 of 8 cases.

Ferreira et al. (60) in 2010 published a study of 47 IBD insertions in 37 patients. They reported a secondary patency rate of 87.3% and primary patency rate of 85.4% at 22 months. They reported a technical success rate per patient at 97.3% with a mean follow-up period of 11.6 months. In 11 CIAA (23.4%), the H-IBD was used, while the Zenith bifurcated iliac side branch device was used in the remaining 36 (76.6%). Five IBD occlusions were reported overall; in one of these cases with simultaneous contralateral IIA occlusion, BC and sexual dysfunction occurred. One reintervention was necessary, and successfully conducted, in a case of thrombolysis for acute EIA occlusion. They reported no aneurysm-related mortality in 30 days, no type I or III endoleak in follow-up.

Laurito et al. in 2010 (113) reported early results of six patients with bilateral CIA aneurysms involving IIA origin who were treated with just unilateral IBD. Two patients had previously been submitted to aorto-iliac bypass graft implantation for an AAA. Technical success was quoted at 83.3%. In five cases, bifurcated standard endografts were inserted, in one patient, a custom-made device was placed. Intra-op iliac limb and branch graft occlusion occurred in one case. Good recanalization was not possible and a femoro-femoral crossover bypass graft was necessary. In this case, erectile dysfunction and BC were detected at discharge. Postoperative follow-up showed good aneurysm exclusion and internal iliac branch patency in four cases. A type II endoleak, from lumbar arteries was found in one patient; it resolved spontaneously after six months. No type I or III endoleak was found.

Pua et al. (2011) (174) reported on a series of 14 IBDs with a stent-implanted iliac branch patency rate of 100% on follow-up. Follow-up was a maximum of 35 months (mean 18.7 months). Technical success was reported at 86%, mortality at 30 days post procedure was nil. The two cases of failed implantation were related to a tortuous EIA/CIA. In two cases, type II endoleaks occurred. They were treated conservatively. Iliac branch graft IBG-related type III endoleak was reported in one case requiring reintervention.

Donas et al. 2011 (50) presented results of 64 IBD (all ZBIS) with a primary patency rate of 98.4% compared to 54 iliac aneurysms receiving open repair, at a mean follow-up of 30.5 months. Early (30 days) aneurysm-related mortality was nil for the IBD group vs. 5.5% for the open repair group. They reported primary and secondary endoleak rates of 12.5% and 6.3%, respectively, for the IBD group. The secondary patency rate of the IBD group was 92.1% at occlusion of 5 IBD (IBD overstenting in 2 cases, restenosis of IBD in 2 cases, 1 coil in the IIA with endoleak type III). In the IBD group, 6 reinterventions were required overall: surgical repair due to bleeding of CFA; thrombectomy and subsequent stent placement in the ipsilateral iliac axis at acute limb ischemia caused by subtotal thrombotic occlusion of IBD in two cases; overstenting of the IIA and placement of Endurant limb into the EIA due to failed recanalization attempt of the dislocated endograft in the IIA, due to fistula with the rectum caused by rupture of a coexisting internal iliac aneurysm of 6 cm diameter, 23 months after the IBD placement. The covered stent of the IIA was dislocated. Two were reinterventions due to type Ib endoleak, and in one case, reintervention was needed for recanalization of the iliac axis, placement of coils in

the IIA and placement of a limb from the CIA to the EIA due to type III endoleak. BC was reported in 5.9% and colonic ischaemia in 2% of cases of open repair, compared to 3.1% and 0% of IBD group cases.

Huilgol et al., 2011 (88) reported about a group of six patients who had received 12 IBD (all ZBIS). All patients required an EVAR main body device in addition to bilateral IBDs. Technical success was quoted at 100%; mean follow-up was 15 months (7–34). Branch patency at follow-up was reported in 11 of 12 (92%). One IBD occluded at 8 weeks postoperatively due to kinking in the CIA segment. Thrombectomy was attempted. However, a femoro-femoral bypass was required and the patient recovered well without any claudication symptoms. Neither type I nor type III endoleaks were reported; early (30-day) aneurysm-related mortality was reported at 0%.

Parlani et al., 2012 (162) presented a series of 100 IBD, all ZBIS, in 100 patients, reporting on the long-term results of iliac aneurysm repair with iliac branched endograft. Periprocedural technical success rate was quoted as 95%, with five intra-operative IBD occlusions reported, and external iliac occlusion found in two patients in the first month. Three patients experienced iliac endoleak (one type III and two distal type I), four patients experienced BC, among them three patients with IBD occlusions, and one patient with patent IBD on one side and contralateral IIA embolization. Estimated patency rate of internal iliac branch was reported as 91.4% at one and five years. At one year, 90% were free of any reintervention, while this was the case for 81.4% at 5 years. No early aneurysm-related mortality was reported. One death occurred because of stent graft infection detected three months after repair and followed by sudden death. Overall, nine reinterventions were required: in three cases, external iliac occlusion required thrombectomy and stent implantation; in one case, it required a femoro-femoral by-pass; in two patients, a distal type I endoleak was treated by covered stent implantation; in one patient, a type III endoleak due to internal iliac side-branch disconnection was treated with covered stent implantation; in one case, iliac aneurysm growth required an aorto-bi-iliac stent graft; and in one patient, occurrence of a femoral pseudoaneurysm necessitated a femoral patch.

Wong et al., 2013 (225) presented a group of 138 IBD, 98 of them helical IBD, and 40 bifurcated-bifurcated IBD (BB-IBD), which were implanted in 130 patients. Wong et al. reported an estimated patency of 94.6%, 86.4%, 81.8%, 81.8%, and 81.8%, respectively, at 30 days, 12, 24, 48, and 60 months. 35% of branches were inserted into patients suffering from IIAAs (in addition to their proximal disease), 20% into stenotic IIAs, and 46% into iliac systems with narrow (<16 mm) CIAs. Median follow-up was 20.3 months. Technical success was significantly lower in patients with IIA stenosis (81.5 vs. 96.4%; Fisher exact test, $P = .015$) but not affected by the presence of an IIAA or narrow CIA. Overall, 18 occlusions occurred, of which 11 (including 7 technical failures resulting in occlusion) occurred early (<30 days). The seven late occlusions occurred between 1 and 26 months post procedure. 4 endoleak type I (two H-IBD and two BB-IBD) were recorded, all of which were successfully treated. There was no occurrence of type III endoleak. Overall, 12 IBD-related secondary interventions were required. Four involved endoleak type I treatment; one involved embolization of a middle sacral artery through feeder vessels of the IBD side; four patients experienced thrombosed EIA limbs of the IBD (three were reopened with thrombolysis and supplemental self-expanding nitinol stents distally, and one required a femoral-femoral bypass). All were reported as patent through follow-up. Three re-interventions included the completion of a planned staged procedure, attempted recanalization of an occluded iliac branch, and stenting of a stenosis at a junction between a crimped limb and an H-IBD. Of 7 patients with late occlusion, an unresolving hip/BC ipsilateral to the occlusion occurred in five cases. In the 30-day follow-up period, 1 aortic-related death was reported.

Pratesi et al., 2013 (171) reported on a series of 85 IBD (71 ZBIS, 11 Helical-IBD, 3 bifurcated-bifurcated IBD) in 81 patients. 17 cases were associated with contralateral IAA embolization, while 9 patients underwent direct overstenting into the EIA without any embolization. Median follow-up was 20.4 months. The technical success rate, calculated for the total number of planned IBDs, was reported at 98.8%. Failure was due to one proximal IBD side-branch collapse, likely caused by the challenging anatomy of the iliac bifurcation. Only one early (<30 days) IBD occlusion was reported (1.2%). No additional IBD occlusion was observed, with an estimated IBD patency of 98% at 48 months. Seven patients (8.6%) developed BC; six of them had been treated for bilateral CIA aneurysms on the side of IIA exclusion without improvement during follow-up; one case was associated with the early IBD occlusion. Of the three patients (3.7%) who underwent a secondary procedure during follow-up, only one case was IBD-related where the 3-year CT scan showed an asymptomatic pre-occlusive thrombosis of the external IBD segment, treated successfully with thrombolysis and stenting. A distal IBD type I endoleak was detected at the first CT- scan in three cases (3.7%) which were conservatively managed. No type III endoleak, aneurysm related deaths, or aneurysm ruptures occurred.

Fernández-Alonso et al., 2013 (59) reported on nine IBDs, all of them unilateral, in nine patients. They reported a side-branch patency rate of 100%. Mean follow-up period was 14.7 months, with a range from 9 to 29. Indications were AAA with CIA involvement in seven cases, bilateral CIA aneurysm in one case, and AAA with bilateral CIA and unilateral IIA involvement in one case. Mortality at 30 days was 100%. No type I and III endoleaks occurred. During follow-up, all stent-implanted aortic and iliac aneurysms remained stable in size; no aneurysm rupture or death was recorded. On follow-up, all stent-implanted iliac branches remained patent; all patients were asymptomatic.

Maurel et al., 2013 (135) presented a multi-center study of 39 IBDs in 39 patients. 15 cases involved an isolated CIA aneurysm, 24 patients were associated with an abdominal aorta aneurysm. The IBD was systematically connected to a bifurcated aorto-bi-iliac stent graft. A bifurcated stent graft history was present in two patients. 37 patients (95%) showed a patent internal iliac branch at the end of the surgery. Occlusion occurred in two cases (5%), entailing a subischemic colic episode and BC in one case. A proximal extension partially covering a renal artery was implanted during the same surgery as treatment for a type I endoleak. A type III endoleak was diagnosed on the postoperative angio-CT. A cross-over femoro-femoral bypass was performed for an external iliac leg thrombosis in three cases and, in one case, for an internal iliac branch thrombosis. The success rate at 30 days was 90% (three leg stenoses and a type III endoleak). Mortality at 30 days was nil.

Austermann et al., 2013 (7) presented a study reporting the 2-year results of IBD placement in patients with aortoiliac or solitary iliac aneurysms and coexisting internal iliac artery aneurysms (IIAAs). Technical success for the overall 21 internal iliac branches (five patients with bilateral aneurysms) was quoted at 100%; primary patency was quoted at 95.3%; overall assisted patency was 100%. One patient developed acute limb ischemia due to total occlusion of the entire iliac segment, 6 months post-procedure. Urgent thrombectomy of the occluded external branch and restoration of the flow in the EIA and IIA ensued. No evidence of BC or type I/III endoleak during the follow-up of 2 years was reported, while two patients showed type II endoleaks. In one case, mild erectile dysfunction postoperatively occurred which was likely caused by intraoperative coil embolization of a branch of the IIA conducted to avoid type II endoleak. Mortality rate at 30 days was nil.

Graham et al. (66) in 2013 evaluated the feasibility and efficacy of extension of IBD into the superior gluteal artery (SGA) in endovascular repair of complex AIAs in a small series of 7 patients, all men. Average follow-up was 3.5 months (with a range of 1 to 15 months).

Indications were abdominal aneurysm with IIAA (n=5), repair of type III endoleak in a patient initially managed with EVAR and IBD alone (n=1), and expanding IIA in a patient treated with a surgical aortobifemoral graft (n=1). The study demonstrated excellent short-term results with a technical success rate of 100% (7/7). No cases of post-procedural endoleak were reported. All stent-implanted internal iliac aneurysms remained stable in size, aneurysm rupture or death were not recorded. All SGA stent grafts remained patent on follow-up CT angiography. No new symptoms of pelvic ischemia were shown by any of the patients.

In 2014, Unno et al. (214) presented the first study from a Japanese university hospital, where EVAR was performed using an IBD in 6 patients at high risk for open repair of an AAA with bilateral CIAAs. All cases involved the consecutive placement of both an IBD (ZBIS) and a stent graft for the IIA to secure the unilateral IIA antegrade blood flow; the contralateral IIAs or its branches were embolized. 5 patients had concomitant unilateral IIAAs (>20 mm) necessitating coil embolization of the distal branches of the IIAA before IBD placement. Technical success was quoted at 100%. All IBDs were patent at follow-up, with a mean follow-up period of 14.2 months. No endoleak type I or III occurred, while one patient suffered from an endoleak type II. There was no evidence of BC or ischemic colitis.

Chowdhury et al., 2014 (30) presented a study of 28 IBDs which were scheduled for insertion in 27 consecutive patients. All IBD procedures were successfully completed (success rate of 100%). Cumulative IBD patency was reported as 94.1% at 24 months among the successful implantations. One patient showed a type 1b endoleak in the iliac system contralateral to the IBD on completion angiogram which persisted on subsequent CT scans; for this reason, treatment with an iliac stent graft extension 6 months after the initial intervention was instituted. In one other patient, completion angiography revealed a significant thrombus in the iliac bifurcated stent and the IIA, while the flow within the stent and the artery were not compromised. At 6-month follow-up, IBD occlusion was found without any evidence of adverse complications. At 6 months follow-up, one case showed an endoleak type Ia where a dissection in the region of the AAA neck was demonstrated after the aortic stent graft deployment. Due to the tortuous and fragile aorta at this level, a decision against re-intervention was taken, but the endoleak was closely monitored with CT angiograms. On a subsequent surveillance CT scan 6 months later, it resolved spontaneously. Mortality rate at 30 days was 3.7%, no deaths were aneurysm-related.

Presenting a series of 18 patients who were treated for aneurysmal degeneration of 22 distal seal zones after EVAR, Bisdas et al. (13) reported a technical success rate of 100% as their main outcome measure. Over a median follow-up of 15 months, they reported a primary patency rate of 100% while zero cases of type Ib or III endoleak occurred. Two device-related reinterventions were carried out during surveillance, namely thrombectomy of an occluded EIA and angioplasty with stenting to manage stenosis of CIA. One death was reported due to metastatic prostate cancer.

In 2015, Loth et al. (128) published a study about 45 iliac arteries in 41 patients with CIAA at two vascular centers, where CIAA were managed by endovascular route with the second-generation S-IBD stent. The study reported procedural success in 85% of patients (35 of 41) and 87% of vessels (39 of 53). Six technical failures occurred, of which three were caused by unsuccessful placing of straight iliac device or stent; and two were due to endoleaks at the end of the intervention, and one was due to occlusion of the IIA side branch. The mean patient follow-up in this series was 32 months. The IIA patency rate during follow-up was reported at 81%, while freedom from endoleaks was reported at 76% per patient and freedom from reintervention per patient was 75%, there were no cases of pelvic ischemia or permanent BC. 85% of reinterventions became necessary in the first 22 postoperative months. This finding is similar to Parlani et al. (162) according to which 88% (eight of nine patients) of reinterventions occurred

within the first 15 months after the intervention. The authors of the cited series therefore concluded that the necessity for reintervention is likely to become apparent early after the operation but is less likely to occur at a later period for at least the first eight or nine years after the procedure. Loth et al. report as another noteworthy fact that, although three occlusions of IIA occurred during follow-up and 5 closings of IIA became necessary during the initial operation because of technical failure, none of these patients suffered symptoms of pelvic ischemia (128).

Noel-Lamy et al.'s retrospective study from 2015 (156) reported on a series of 20 treated IIAAs in 15 patients with AIAs with concomitant IIAAs who were treated by implantation of an IBG (Cook, Bloomington, IN, USA) with extension of the internal iliac component of the branch stent graft into the SGA. In two cases with a previous history of aorto-bi-iliac bypass, iliac aneurysm repair was carried out only with proximal landing of IBG in a previously placed surgical limb. Viabahn (Gore, Karlsruhe), Fluency (Bard, Flagstaff, Arizona, USA) or iCast (Atrium, Hudson, New Hampshire, USA) were used for stent grafts proximally. The series reported a technical success rate of 100%. Mesenteric ischemia resulting in death occurred in one patient who was treated with simultaneous IBG and three vessel fenestrated EVAR; this patient was excluded from the subsequent analysis. Mean imaging follow-up of this series was 18.3 months. The primary patency rate of SGA was 100%. One case of type II endoleak occurred in a patient where the anterior division originated from the IIAA and measured 6 mm. An attempted embolization failed because it was not possible to select the anterior division. In one case, (5.2%) reintervention with implantation of a balloon expandable stent in the EIA was successfully carried out 6 days after the operation due to stenosis of the EIA component of the graft. In one patient, a non-occlusive coagulation in the IIA branch apparent one day post-intervention was successfully treated with Coumadin over a period of three months resulting in resolution of the clot. two patients with IIA embolization contralateral to the IBG placement reported symptoms of unilateral lower limb monoparesis. No cases of BC during follow up were reported.

Zhang et al., 2015 (233) investigated the usefulness of a novel-designed iliac branch stent grafts (IBSG) in preservation of IIA during EVAR in Chinese patients (significant because, as mentioned above, the branch iliac stent grafts used in Western countries are often not appropriate for many Asian patients due to shorter CIA in these patients). They reported that common iliac aneurysms in 11 patients were successfully managed by endovascular repair with 15 novel-designed IBSG, with an overall primary patency rate of 86.7%. The median follow-up was 12 months (ranging from 8 to 21 months). In two cases, reintervention with additional iliac endografts was needed due to type I endoleak (6 months post operatively) and type III endoleak (3 months post-operatively). No occurrence of type II endoleak was reported. Patency rate of IBSGs during follow-up was 86.7% (13/15). IIA branch occlusion occurred in two patients, one of them 36 days post intervention. This patient was successfully treated with catheter-directed thrombolysis. In the case of the second patient who had received bilateral IBSGs, occlusion of one of the internal IBSGs occurred 6 months post intervention and was managed with success by stent graft. Secondary patency rate of this series was reported at 100%.

III.2 Results of series presented in this study (Franziskus Krankenhaus)

Between October 2007 and July 2014, 39 patients with CIAA were consecutively treated with pure endovascular therapy of AIAs by using the iliac branch device (IBD) at one German vascular centre. 38 of the 39 patients were male (97.43%). Mean age of patients on the date of operation was 67.43 years (range 56-86 years). Mean IBD follow-up was 34.74 months (range,

1-81). See Table 3 for demographics, co-morbidities and morphology characteristics of patients with CIAA and IBD procedure at baseline.

Table 3. *Characteristics of 39 patients with endovascular repair with Iliac Branch Device (ZBIS).*

	<i>N</i>
<i>Number of patients</i>	<i>39 total (38 m, 1 f)</i>
<i>Mean Age at operation (years)</i>	<i>67.43 (56-86)</i>
<i>Mean Body Mass Index (BMI)</i>	<i>26.986</i>
<i>Smokers</i>	
<i>Current</i>	<i>20</i>
<i>Former</i>	<i>4</i>
<i>C2 Abuse</i>	<i>7</i>
<i>Coronary artery disease</i>	<i>19</i>
<i>COPD*</i>	<i>11</i>
<i>renal failure**</i>	<i>9</i>
<i>hypertension</i>	<i>32</i>
<i>hyperlipidemia</i>	<i>20</i>
<i>diabetes mellitus</i>	<i>6</i>
<i>hostile abdomen</i>	<i>3</i>
<i>hernia***</i>	<i>20</i>

* *COPD: dyspnea of exertion, pulmonary function test <65%.*

** *renal failure: heightened creatinin level >1.5 mg/dl*

*** *patient suffered or had suffered from inguinal hernia, sigmoid colon diverticulitis, repair of incisional hernia, diastasis recti, hiatal hernia*

The overall number of CIAA was 49. 10 patients (25.6%) suffered from bilateral CIAA, 9 patients (23%) underwent bilateral repair of CIAAs. In one case, the patient received coil embolization on one side, and IBD on the other side. The coil embolization was effected with Amplatzer (Vascular Plug II, St. Jude Medical, 9-AVP2-10) on the ostium of the larger of the two IIA in the same operation. Baseline median diameter of all treated CIAA was 36.31 mm (range 21-62 mm). 9 patients (23% of all patients with CIAA) suffered from an IIAA aneurysm with a diameter \geq 16 mm. Baseline median diameter of these 9 IIAA was 20.44 mm (range 16-31 mm). No patients had bilateral IIAA. 33 patients (84.6%) had suffered from infrarenal AAA with a diameter >35 mm, and one (2.63 %) from juxtarenal AAA. Baseline median diameter of these 34 AAA was 57.11 mm (range 38-85 mm). In the case of the patient with juxtarenal AAA, the device was associated with a fenestrated aortic stent graft. One patient had previously received EVAR treatment. This single patient was treated with IBD alone in the setting of prior aorto-iliac repairs with distal aneurysm formation (2.63 %). 3 AAA (7.69%) were ectatic (AAA diameter <35 mm), and 1 patient (2.63 %) suffered from an isolated iliac aneurysm. The extensions of aneurysms are detailed in Table 4.

Table 4. Aneurysm extension in 39 patients

	<i>Aneurysm</i>	<i>Ectasis</i>
AAA	34* (87.1%)	3 (7.6%)
CIA right side	21 (53.8%)	5 (12.8%)
CIA left side	8 (20.5%)	7 (17.9%)
CIA both sides	10 (25.6%)	0
IIA right side	5 (12.8%)	0
IIA left side	4 (10.2%)	3 (7.6%)

* of which 1 juxtarenal AAA

The proximal component of the branched graft was connected to an infrarenal graft in 37 (95%) patients and to a fenestrated juxtarenal endograft in one (2.56%) patient. This patient received the (AAA-REINFORCED-FENPROX, COOK) as main body stent graft for aorta. Of the other patients, one received (CMD-TFB-D-4273-060409) as main body stent graft for aorta. In one patient, the aneurysm neck showed more than 90° kinking, so that in this, case a flexible stent graft for aorta (Aorifix, SG-HBB-31-111-80-20-A 12-22) had to be used. All other patients (n = 35) received ZENITH FLEX© TFFB-XX-YY as main body stent graft for aorta. In one case (2.56%), the IBD was docked into a limb of a previous aortic repair.

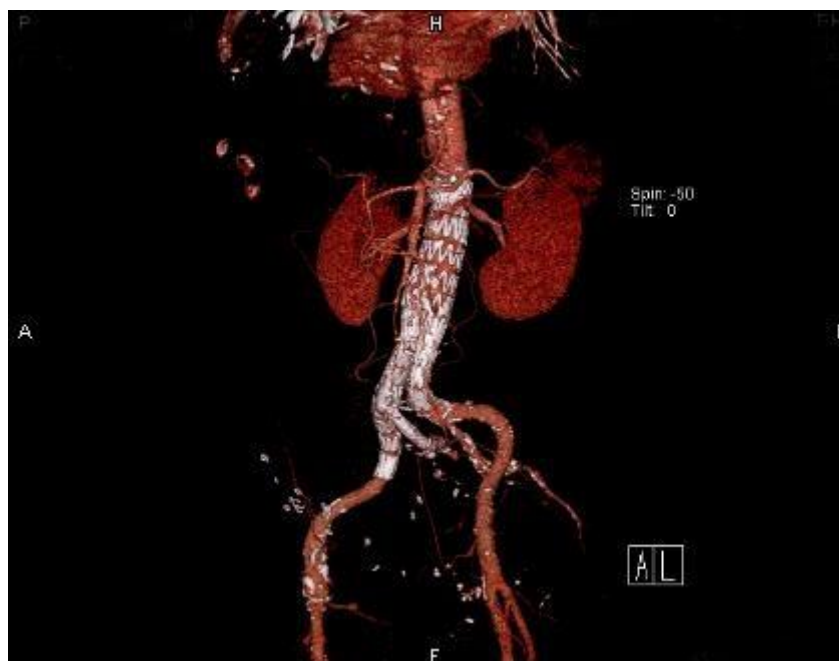

Figure 2. Three-dimensional reconstruction in a patient with iliac side-branch repair for right iliac aneurysm in combination with EVAR with AAA.

47 IBDs of all implanted IBDs (n=48) were second-generation straight IBDs (ZENITH® BRANCH GRAFT - ILIAC BIFURKATION; ZBIS, COOK©); more specifically: ZBIS-10-45-41 (n=7), ZBIS-10-45-58 (n=2), ZBIS-10-61-41 (n=3), ZBIS-10-61-58 (n=3), ZBIS-12-45-41 (n=18), ZBIS-12-45-58 (n=1), ZBIS-12-61-41 (n=11), and ZBIS-12-61-58 (n=2). Only one IBD was another type IBD (REINFORCED-ILIAC-SIDE-BRANCH, COOK©).

Two cases of failed IIA access occurred: In one case, the patient had CIAA in both sides and due to the severe stenosis of the ostium of the IIA the use of a leg extension (ZSLE-16-56-ZT) was required to connect the IBD to the aortic mating device and cover the ostium of the iliac branch. In the second case (which occurred early in the series) it was impossible to insert the Advanta stent graft to seal the IIA trunk due to a previous attempt at perturbation of the IIA resulting in lesions of the wall with thrombus formation in the IIA. In this case, a leg extension (TFLE-12-54) was done to connect the IBD to the aortic mating device without covering the ostium of the iliac branch.

In only one case, we used the balloon-expandable stent graft (9/57 mm, Bentley, InnoMed) to bridge the distance between the side branch and the IIA. In all other patients, we used the balloon-expandable stent graft ADVANTA V12. In 6 patients, we had to extend the Advanta stent graft into the IIA to reach a perfect bridging, therefore requiring 2 stent grafts per patient. Overall, 52 stent grafts ADVANTA V12 were used: 7/38 mm, Atrium (n=2), 7/59 mm, Atrium (n=2), 8/38 mm, Atrium (n=5), 8/39 mm, Atrium (n=1), 8/59 mm, Atrium (n=10), 9/38 mm, Atrium (n=2), 9/59 mm, Atrium (n=15), 10/38 mm, Atrium (n=4), and 10/59 mm, Atrium (n=10).

In one patient, following selective DSA, a primary distal type I endoleak ipsilaterally was observed, making an extension of the stent graft leg into the EIA necessary (TFLE-14-39-ZT). In another patient, concluding DSA showed a relevant stenosis of the EIA on the side of IBD immediately distal to the distal landing zone which was optimally dilated using a PTA balloon (10mm, 4cm).

In one patient, implantation of the extension leg of the main body stent graft for aorta contralaterally (ZENITH FLEX TFLE-18-39-ZT) led to an accidental overstenting which closed the ostium of IIA. In one patient, temporary occlusion of IIA required recanalization which was eventually successfully effected using a Glide Cat and a Terumo wire. Subsequent DSA after IBD bridging showed an excellent result. In another patient, the bridging process (Advanta V12, 10/59 mm, Atrium) was not successful because after inflation of the balloon, the stent graft could not be fully expanded, probably due to a defect in the balloon. A new stent graft was inserted and successfully expanded.

In another patient, due to the heavily elongated and coiled iliac artery, the main body stent graft was inserted through the IBD, and the contralateral graft leg was applied by crossover manoeuvre.

With regard to local inguinal complications, one patient required thrombectomy of the CFA after occlusion, one patient received endarterectomy of the CFA due to stenosis caused by plaque, and one patient with local dissection of CFA received arteriotomy and fixation of the dissection.

One procedure was performed under spinal anaesthesia. All other procedures were performed under general anaesthesia. All procedures were done through femoral access bilaterally except in two patients: in one case, following EVAR with right side CFA and left brachial artery; in the second case, fenestrated EVAR with CFA in both sides and left brachial artery. Post-operative local wound conditions are detailed in Table 5.

Table 5. *Post-operative local wound conditions*

	N
pseudo aneurysm	1
wound dehiscence	0
wound hematoma	11
lymphorrea	4*

*One patient after remained compress

Perioperative results

Perioperative data are detailed in Table 6. Initial technical success for all patients was 92.3 % (36 of 39), initial technical success in all planned IBDs was 93.75% (45 of 48). In one patient, failure was due to a proximal endoleak type I. In one other case, intra-operative insertion of the catheter was not possible due to a high-grade stenosis of the ostium of the IIA in a patient with bilateral CIAA. Consequently, overstenting on the left side was decided. The third was the above-mentioned case where it was impossible to insert the Advanta stent graft to seal the IIA trunk due to a previous attempt at pertubation of the IIA resulting in lesions of the wall with thrombus formation in the IIA. The patient subsequently developed an associated endoleak type III. No intra-operative IBD occlusions, perioperative deaths, myocardial infarctions, strokes, conversions to open surgery, mesenteric or spinal cord infarcts or buttock necrosis occurred. There was no major morbidity or conversions to open surgery.

Table 6. *Perioperative results (30 days)*

	n (of 39 patients total)
Mortality/Rupture	0
Initial technical failure	3 (7.6%)
External iliac limb occlusion	0*
30 postoperative days Revision	3 (7.6%)

* high-grade stenosis distally from the stent graft landing zone of EIA contralaterally from IBD

No external iliac limb occlusions occurred during the first 30 postoperative days in the 39 patients. Three reinterventions were required (7.69%), one a transfemoral endovascular covered stent implantation with proximal endoleak type I; the second one a local revision with removal of a foreign body (compress) right inguinal; the third one a PTA and stent implantation of the contralateral EIA with high-grade stenosis distally from the stent graft landing zone of the EIA.

Occurrence of endoleak

Endoleaks Type I and III were recorded in two patients (5.12%) (Tab. 7): one patient with proximal type I endoleak had been successfully implanted with a covered stent at the proximal part of the main body stent graft of the aorta. After 24 months, this patient developed endoleak type I distally due to dislocated stent graft in the in distal IIAA. This was treated with coil embolization which resulted in ZBIS occlusion. Another patient developed a type III endoleak

during the second month post-operatively, caused by an uncovered short leg of the IBD which could not be bridged to the EIA. It was successfully corrected by implantation of a Hemobahn stent in the EIA. The same patient developed type II endoleak of IMA after 38 months, and received coil embolization of IMA. After 55 months, this patient developed a distal type Ib endoleak contralaterally which was managed by extending the leg of the main body stent graft. Endoleaks type II were recorded in 18 patients (46%) at discharge, and in 8 patients (20.5%) at most recent control. In 5 cases, the endoleak was caused by the lumbar artery, in 3 cases, by the IMA. Most patients with endoleak type II were treated conservatively, with only 5 patients requiring late embolization. One patient showed a paravasal leak in the area of ZBIS without evidence of endoleak.

Table 7. Endoleak at discharge and at most recent check*

	at discharge	at most recent check
Type I	1(2.56%)	0
Type II	18(46%)	8(20.5%)
Type III	1(2.56%)	0

*In one case, computer tomographic control had to be postponed because of weak renal function

Reinterventions

In ten patients (25.64%), reinterventions were performed during the follow-up period for multiple reasons. Only four of these (10.25%) occurred because of problems with the IBD or the ipsilateral iliac artery. Causes and types of reinterventions are detailed in Table 8.

Table 8. Details of reinterventions.

Pat Nr.	Time (months)	Indication	Type of reintervention
1	1	proximal type I endoleak	covered stent implantation
	24	distal type I endoleak of the IBD-side	coilembolisation of IIAA
2	2	type III endoleak	covered stent implantation
	38	type II endoleak of IMA	coilembolisation of IMA
	48	kinking in the contralateral iliac artery	prolongation of contralateral stent graft leg, unsuccessful
	55	distal type Ib endoleak contralateral to IBD	exclusion of endoleak by extension of stent graft leg
3	25	type II endoleak of IMA	unsuccessful CT-based embolisation attempt
	27	type II endoleak of IMA	angiography-based embolisation of proximal IMA
	41	type II endoleak of lumbar artery	iatrogenic bleeding from a sub-costal artery during embolisation; subsequently removal of hematoma
4	17	short distance stenosis of EIA ipsilateral to IBD	PTA with cutting balloon
5	14	occlusion of contralateral stent graft leg	Thrombectomy
6	29	type II endoleak of lumbar artery	CT-based embolisation
7	6	type II endoleak of IMA	coil embolisation
8	1	corpus alienum inguinal	removal of corpus alienum
9	7	type II endoleak of IMA	coil embolization
10	1	high grade stenosis at the distal stent landing zone in contralateral EIA	stent/PTA of EIA

Long-term follow-up

Initial and short-term clinical success (30 days – 6 months) remained stable at 92.3 % for all patients (36 of 39) and at 93.75% for all planned IBDs (45 of 48). No occlusions were noted post-operatively at 6 months. Three IBD occlusions happened later. One internal iliac side-branch occlusion occurred after 24 months due to coil embolization of the IIAA because of distal endoleak type I with dislocated stent graft in the distal IIA. This patient had been implanted bilaterally with IBD. The second IBD remained patent. Another internal iliac side-branch occlusion occurred after 24 months due to coil embolization with distal endoleak type I. The contralateral IIA remained patent. A third IBD occlusion occurred after 41 months. This patient showed an endoleak type II and received a translumbar embolization of the aneurysmal sac. Subsequently iatrogenic bleeding from a sub-costal artery occurred and was treated by emergency suturing of the source of the bleeding. Subsequently occlusion of the IBD occurred. The contralateral IIA remained patent. Overall, 4 occlusions of internal limbs of IBD out of a total of 48 occurred (8.33%), leading to a mid-term clinical success (6 months – 5 years) of 89.74% for all patients (35 of 39). Table 9 describes all patients of this series with occluded IBDs. One of the patients with occluded IBD (25%) and a patent IIA contralaterally presented clinical evidence of light BC ipsilaterally. All other patients with occluded or patent IBD presented no clinical evidence of hip and/or BC, colon ischemia, or spinal cord ischemia during follow-up. No patient experienced deterioration in erectile function.

Table 9. *Patients with IBD occlusion*

Pat Nr.	time of occlusion	cause of occlusion	Symptoms	presence of IIAA	contralateral IIA
1	intra-operatively	impossibility to correctly deploy the covered stent	BC ipsilateral	IIAA (30mm)	patent IIA
2	24 months	coil embolization with distal endoleak type I	No	No	patent IIA
3	24 months	coil embolization with distal endoleak type I at dislocated stent graft in the distal IIA	No	No	patent IBD
4	41 months	iatrogenic	No	No	patent IIA

According to Kaplan-Meier estimates, IBD patency rate was approx. 97% at 12 months and approx. 81% at 80 months per patient, and was 98% at 12 months and 85% at 80 months per vessel (Fig. 3).

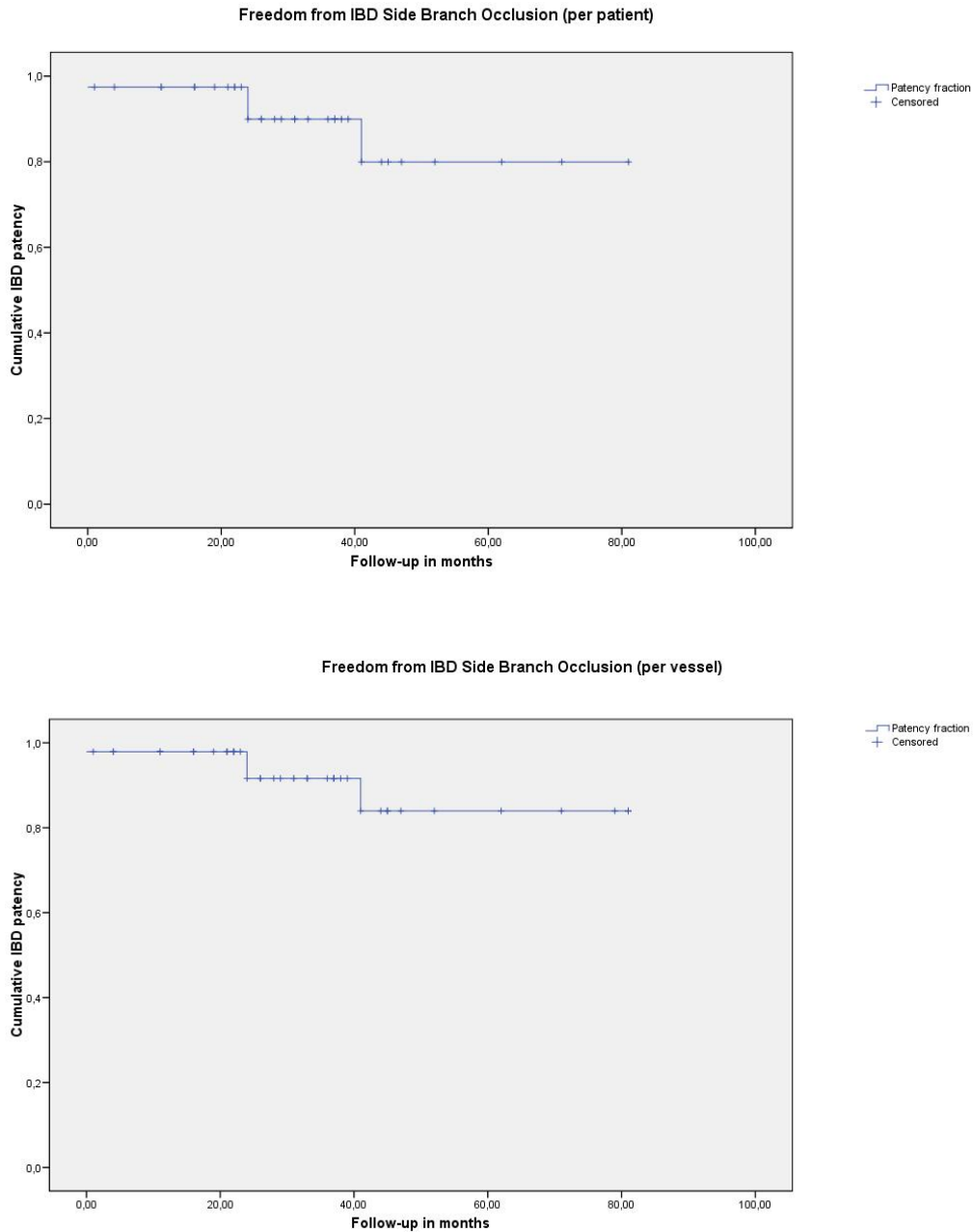


Figure 3. Kaplan-Meier estimate of the probability of iliac bifurcation device (IBD) side branch patency. Analyzed on an intention-to-treat basis, cumulative IBD side branch patency was 97% at 12 months and 81% at 80 months per patient (upper diagram), and 98% at 12 months and 85% at 80 months per vessel (lower diagram).

During follow-up, one occlusion of one external iliac limb contralateral IBD-side was noted. The occlusion occurred 14 months after the procedure and was successfully removed by thrombectomy.

In this series, no aneurysm-related deaths occurred during the follow-up period. Only one patient (2.56%) was lost after 2 years due to sepsis following chemotherapy. No aneurysm rupture occurred.

The present study has a number of limitations which should be taken into consideration when interpreting our results. Among them are the relatively small number of patients (39) and the retrospective nature of the study. Further limitations are due to difficulties in securing accurate data from case notes as well as the sensitivity of some questions such as erectile dysfunction.

Comparison of the presented series with the results of the published research

Our results are similar to, and support, the results published in the literature (as detailed in Table 10). In the published literature, the rate of technical success per vessel varied between 69% and 100% for all IBD forms currently in use. In detail, technical success per vessel was n=855 (94%) of altogether 909 planned IBD, showing the feasibility of IBD use in a selected group of patients. In our series, the rate of technical success per vessel was 93.75% (45 of 48).

In the published literature, initial clinical success (<30 days) per vessel was n=834 (91.7%) of overall 808 planned IBD. Clinical success rates varied between 61% and 100% per vessel within the follow-up range of the 26 studies included in the review.

In our series, initial clinical success per vessel was at 93.75% (45 of 48).

Table 10. *Comparison of our results with published research*

	N of patients treated with IBD	N of IBD	Technical success in % (n of successful IBD / n of planned IBD)	Initial clinical success (<30 days) % (n of successful IBD / n of planned IBD)	N of IBD occlusions (and % in relation to all planned IBD) in last check-up during follow-up	N (and %) of patients with BC across* all cases of IBD occlusion	N (and %) of patients requiring post-operative re-intervention	N (and %) of patients, type I endoleak	N (and %) of patients, type III endoleak
Our series	39	48	93.75% (45 of 48).	93.75% (45 of 48)	4 (8.33 %)	1 (25%)	4** (10.25)	1 (2.5%)	1 (2.5%)
Published Literature	846	909	94% (855 of 909)	91.7% (834 of 909)	78 (8.58%)	29 (37.1%)	67 (7.91%)	19 (2.2%)	10 (1.1%)

* indicates the percentage in relation to the patients with occlusion of IBD only (and not the percentage in relation to all patients)

** due to problems with the IBD or the ipsilateral iliac artery

Like the studies published so far, our series demonstrates the feasibility and usefulness of IBD use for treating complex AAA while preserving the IIA.

IV. Discussion

IV.1 Sacrificing the Internal Iliac Artery: Consequences and Complications

When no adequate distal landing zone is available during EVAR, it is necessary to extend the stent graft beyond the ostium of the IIA, leading to the sacrifice of the IIA. Bilateral interruption antegrade IIA flow is rarely asymptomatic and ischemic complications can result in severe morbidity and mortality (95, 181, 229). The most frequently cited complications are BC (39, 137) and erectile dysfunction (181) but other complications may include bowel or spinal ischemia (57), sloughing of the scrotal skin (122) or ischemic injury to the lumbosacral plexus (54) resulting in weakness and numbness in both lower limbs with bowel and bladder incontinence, non-healing decubitus ulcers, gluteal compartment syndrome (201). This may improve over time, but up to 15% of the patients remain symptomatic (116, 229).

The consequence of intentional IIA occlusion on an individual basis is difficult to predict. While even bilateral IIA occlusion has been reported with limited morbidity (137), unilateral occlusion of the IIA may result in persistent invalidating BC (180). BC following unilateral internal iliac occlusion is often regarded as mild and transient, but in around 50 % of patients, symptoms do not improve (116). Some authors (4) have therefore combined the procedure with EIA-to-IIA bypass to prevent this complication.

The main factors contributing to pelvic ischemic complications following IIA occlusion include stenosis greater than 70% at the origin of the contralateral IIA, absence of filling of three or more named IIA branches, and diseased or absent ascending branches from the ipsilateral CFA (229).

Symptoms of pelvic ischemia are difficult to predict and remain evident for most patients over years, even with active exercise (95, 181, 229, 235). When one or both IIA are sacrificed, severity of symptoms is dependent on the demand of end organs and their collateral supply. Previous literature suggests bilateral IIA interruption, failed collateral anastomotic network, and atherothrombotic microembolization as possible causes of acute pelvic ischemic complications (11, 96, 110, 121, 130, 137). Younger, more active patients with a greater demand for blood supply run a significantly higher risk of BC after IIA occlusion. Another high-risk group is patients with poor supply due to reduced cardiac output (53, 57, 228). Jean-Baptiste et al. state that it is unclear whether this increased risk is due exclusively to age or rather to activity level. They point out that “elderly patients are likely to have occult chronic pelvic ischemia because of sedentary lifestyle and possibly more common comorbid conditions” (94). The contralateral IIA provides collateral blood supply while bilateral blood supply is derived from profunda femoris and external iliac branches (89, 97). The circumflex branches of the CFA and branches of the profunda femoris artery provide greater collateral circulation than the contralateral IIA. This affects the occurrence of adverse effects of IIA occlusion (89, 123). Ischemic complications are reduced when the IIA is interrupted as proximally as possible, likely because more collateral blood supply is preserved (21, 137). Other risk factors are previous open aortic repair and insufficient collateral flow to the IMA (189) and previous pelvic radiation therapy which may cause some damage to pelvic collateral circulation. Outcomes may also be adversely affected by severe perioperative hypotension or in cases with associated splanchnic arterial occlusive disease (53).

Interestingly, a lower rate of BC is observed in patients with diabetes. While the reason for this is unclear, Park et al. hypothesize that this subgroup of patients is also less active and may not have experienced symptoms of claudication (161).

Many vascular specialists assume that unilateral IIA occlusion results in a lower prevalence of ischemic complications than bilateral IIA. Interpretation of available data is not easy due to small numbers within most individual series, subjectivity in patient assessment and heterogeneity in follow up. Aetiology and assessment of sexual dysfunction are difficult to determine due to the common confounding comorbidities of diabetes mellitus, prostate surgery, renal failure and advanced age. As Karthikesalingam et al. observe, it appears likely that the rate of major complications resulting from bilateral IIA occlusion is under-reported owing to a significant publication bias (97). Nevertheless, the published evidence does not support the commonly held belief that more adverse outcomes may be expected with bilateral IIA sacrifice (65).

The sequelae of unilateral and bilateral IIA occlusions with regard to buttock/thigh claudication and erectile dysfunction have been compared in many studies. Rayt et al., who compared 29 patients who had undergone either unilateral or bilateral IIA occlusions with the published literature, have reviewed these data. They found no significant differences in claudication rates following unilateral and bilateral IIA occlusion. 11 series following up 301 patients undergoing unilateral IIA occlusion described 29% developing BC and 18% sexual dysfunction. Eight papers detailing follow-up of 90 patients after bilateral IIA occlusion found a 32% prevalence of post-procedural BC and 18% of sexual dysfunction (180).

In a systematic literature review, Rayt et al. found the development of BC in 31% of patients who had received unilateral IIA embolization before EVAR and in 35% of patients who had undergone bilateral IIA embolization prior to EVAR (180).

Similarly, a series of 39 patients undergoing bilateral IIA embolization prior to EVAR reported post-procedural BC for 31% of patients, falling to 9% after one year. Sexual dysfunction occurred in 5% of patients, spinal ischemia in 3% (21).

In a review of IBD implantations, Karthikesalingam et al. describe that occlusion of the IIA limb of an IBD caused BC in 50% of patients (97). Reduced buttock and pelvic ischaemia was shown in previous research when using the IBD unilaterally compared with IIA embolization (219).

New onset erectile dysfunction was described in 17% of patients undergoing unilateral IIA embolization prior to EVAR and 24% of patients undergoing bilateral IIA embolization prior to EVAR (180).

The rate of CI has been found to rise with bilateral IIA ligation (195). Interruption of IMA and IIAs has been cited as the major cause of CI after AAA repair (234). Other factors have also been implicated, for example micro-embolization, shock, and vasopressive drugs (9, 234). Most of the cases of CI after EVAR have been attributed to cholesterol embolization and IIA thrombosis (83).

Sfyroeras et al. presented the first report of CI after endovascular exclusion of an AIA with the patent IBD and the contralateral IIA. In this case, CI seemed to be caused by IMA thrombosis after exclusion by the endograft and inadequate collaterals from the SMA and the IIAs (197). This case shows that the incidence of postoperative CI after EVAR may not be completely excluded. Postoperative patients with severe abdominal pain, early diarrhea, rectorrhagia, unexplained hemodynamic disturbances, unexplained organ failures, and/or elevated lactate enzymes should be assessed for CI. When the interruption of one or both IIAs is necessary, preoperative angiographic investigation of the splanchnic circulation can help to assess the risk of CI.

Recently, Park et al. have described the ischemic complications after IIA embolization for EVAR in a Korean hospital where BC occurred in 10 (26 %) of 38 patients and sexual dysfunction occurred in 13 of 36 male patients (36 %) (161).

In 2014, Jean-Baptiste et al. published the first study which used the walking impairment questionnaire (WIQ) to assess functional capacity and walking ability in patients with the BC after interventional occlusion of the IIA procedures (94). The series comprised a total of 638 consecutive patients with AIA treated with EVAR. 71 patients required 75 interventional procedures to treat occlusion of the IIA. Complications relating to pelvic ischemia, and their effects regarding the quality of life after interventional occlusion of the IIA procedures in patients undergoing EVAR, were analysed for all patients who lived through the postoperative period. The patients took part in a quality of life survey, the WIQ, which included walking speed, distance, stair climbing, and pain. Acute pelvic ischemic complications after interventional occlusion of the IIA procedures occurred at a rate of 2.8%, whereas there was no occurrence of such complications in the remaining 567 EVAR patients who had not undergone an interventional occlusion of the IIA procedure (94). BC, which had disappeared in 61% of cases during follow-up, was experienced by 25 % of patients. This corresponds to data from previous literature according to which the rates of BC are 16% to 55% and natural regression was found in 13% to 100% of cases (28, 145).

There is no evidence indicating that the sequential sacrifice of bilateral IIA would be more beneficial when compared to the simultaneous sacrifice of bilateral IIA (21).

Coil and coverage

Indications for patients that may benefit from an IIA embolization during EVAR have not been clearly defined in the current literature (108).

A number of studies report EVAR with IIA coverage without coil embolization (57, 141, 160, 228); but there is no clear definition of patient selection for this approach. Papazoglou et al. advise against performing IIA embolization in most cases, because this leads to shorter operation time, decreased use of contrast and radiation time, and fewer catheter manipulations into the aneurysmal iliac arteries that may result in peripheral embolization (160). Comparative studies show that the incidence of BC after IIA coverage is lower than after IIA embolization (57, 228); and it is likely that IIA coverage is better tolerated than IIA embolization (232). Willingendael et al. found that “endovascular treatment of aortoiliac and iliac aneurysms without coil embolisation of the IIA is safe and effective and that preemptive IIA coil embolisation may be redundant.” (199) In a recent study (2014), Rajesparan et al. (179) compared seven IIAs (24%) which were embolized before stent covering (embolization group) with 22 IIAs (76%) which were covered only without embolization (cover group), without observing any endoleaks in all 22 cases of the cover group.

Patency of pelvic collateral vessels may be maintained by coil placement within the main trunk of the IIA with an average length of 4 cm (223); this decreases the risk for developing pelvic ischemia symptoms (39, 89). For this reason, Stokmans et al. argue that simple stent graft coverage of the IIA is preferable because this approach produces the most proximal occlusion possible (199). Moreover, coil embolization entails increased contrast load and radiation exposure and prolongs operating time. Finally, it is a high-cost procedure since frequently multiple coils are required to occlude a single IIA (73, 81, 103, 108). Moreover, in rare cases, coil embolization of IIA can result in localized infection, since the colonization of coils acts as a foreign-body agent (48).

If a decision is made for an approach including coil embolization, the strategy described by Faries et al (58) seems the most promising approach. Faries et al. reported good results by coil embolization of the unilateral IIA 3 to 5 weeks prior to EVAR and EIA-to-IIA bypass, setting an interval of several weeks between IIA coiling and the subsequent procedure, to promote the

development of collateral vessels within the pelvic circulation network (86). Similarly, staged bilateral IIA coil embolization has been proposed to minimize complications, since it allows the development of pelvic collateral circulation (37, 138, 224).

Unilateral or bilateral?

According to general perception, the high risk for development of symptoms of pelvic ischemia suggests avoidance of bilateral IIA occlusion. This is reflected in the Clinical Practical Guidelines for the management of AAA established by the European Society for Vascular Surgery, which include the recommendation to avoid bilateral IIA occlusion, at least in standard-risk patients (145). According to a number of clinical series (181, 194, 224, 229), symptoms of pelvic ischemia developed in 55% to 80% of patients with bilateral IIA occlusion, compared with 17% to 38% of patients with unilateral IIA occlusion. Fahramand et al. found that occlusion of one IIA is generally well tolerated (57). But bilateral IIA occlusion is associated with a higher incidence of BC as well as other manifestations of pelvic ischemia. For this reason, flow to at least one IIA should be preserved, if at all possible (57, 95, 138, 180, 229).

However, there are some indications that risk of symptoms in intentional unilateral IIA occlusion may be similar to that of bilateral IIA occlusion, ranging from 9 to 45%. Rayt et al. found that although bilateral IIA embolization slightly increases the occurrence of BC as well as erectile dysfunction, the increase seems insignificant, although this may be due to the small numbers of patients studied (180). However, data defining the incidence of severe complications following bilateral compared to unilateral IIA occlusion is scarce, and the natural history of these sequelae remains unclear (65). Moreover, although in many patients, unilateral occlusions can be asymptomatic, predicting in which patients buttock ischemia may be clinically significant versus those who will develop colon or spinal cord ischemia is not possible. While bilateral occlusion can be performed without complications, it is rarely asymptomatic (95, 138, 181, 229). Huilgol et al. argue that while the incidence of more serious myocutaneous, spinal, neural or colonic ischaemic complications secondary to IIA occlusion is low, these outcomes may be disastrous when they do occur (88).

Studying the intraoperative penile and gluteal blood flow during EVAR with unilateral IIA occlusion and contralateral IIA revascularization, Unno et al. (213) demonstrated that pelvic blood flow was significantly decreased at interruption of bilateral IIA blood flow. However, after unilateral IIA reconstruction, it recovered to the preoperative level. Therefore, preservation of blood flow to IIA at least unilaterally as well during EVAR in some manner is recommended, while bilateral IIA occlusion should be performed in limited cases (37, 54, 180). According to Faries et al., preservation of the left IIA might be beneficial for increasing collateral flow to the left colon when both IIAs appear equally suitable for revascularization (58). However, Hosaka et al. did not find any difference with regard to the side of the reconstructed IIA (86).

In our series, we always aimed at preserving bilateral IIA patency if at all possible, since inception and duration of the ischemic symptoms are largely unpredictable. Only in one patient with bilateral CIAA, we decided to deploy a unilateral IBD in the smaller of the two common iliac aneurysms in order to achieve a shorter length of covered stent to bridge the side branch of the IBD and the origin of the IIA.

IV.2 Indications, feasibility and morphological criteria for using the Iliac Branch Device

Indications for using IBD

According to Huilgol et al., main indications for using IBD include the following scenarios:

- 1) In cases of AAA which occur with a CIAA IBD can be used in conjunction with an EVAR device.
- 2) IBD can be used for exclusion of an isolated CIAA. (It is possible to use IBD without an EVAR device to repair a solitary CIAA if there is sufficient nondiseased proximal CIA for a secure device fixation).
- 3) IBD can be used for excluding a new or enlarging CIAA distal to an iliac limb of a previously used EVAR device.
- 4) IBD can be used for repairing an IIAA (87).

Indications for using IBD bilaterally are the following situations:

- 1) In conjunction with an EVAR device for repair of an AAA and bilateral CIAA
- 2) For exclusion of bilateral isolated CIAAs
- 3) For exclusion of bilateral IIAAs (88).

In many cases of bilateral isolated CIAAs or bilateral IIAAs, there is insufficient landing zone in one or both proximal CIAs to achieve a reliable fixation. Therefore, it may be necessary to use an additional bifurcated EVAR device to achieve a proximal seal in the aorta.

The usual anatomic considerations when using bilateral IBD apply, including CIA length. But while short CIA length may constrain cannulation of the IBD from the contralateral iliac system, it is often less important due to the frequent use of a brachial approach (88).

In cases of bilateral IIA aneurismal involvement, and in cases where a unilateral IBD placement was decided, Verzini et al. have shown that it is preferable to place the IBD on the side which has the most proximal healthy segment, a richer distal arterial bed, and less or no extensive calcification or tortuosity (as evaluated on the preoperative CT), while the other side can be excluded with coil embolization (219).

Furthermore, IBDs have been used successfully in a number of other scenarios. Naik et al. described two cases with bilateral CIA and IIAAs after previous open AAA surgery. These were managed in an endovascular fashion using the IIA branch device (Cook) to maintain pelvic perfusion (153).

IBDs have been used to treat complex AIAs. A synchronous Zenith fenestrated stent graft and an IBD have been used in the same procedure to exclude an AIA, for example (150).

In a very interesting case, IBD was used for the first time to treat a nonaneurysmal disease to repair an arteriovenous fistula (AVF) between the left IIA and the left EIV (external iliac vein) which had developed very close to the iliac bifurcation 11 years after an abdominal gunshot wound. Queiros et al. described IBD as a feasible option to treat traumatic abdominal or pelvic AVF where surgical exposure can be challenging (178).

Taking the hostile surgical fields and complex common and internal iliac aneurysms into consideration, the IIA branch is particularly attractive (153).

Feasibility and morphologic criteria for the use of IBDs

The feasibility of using IBD is influenced by numerous considerations, such as patient anatomy, the patient's clinical situation (esp. level of physical and sexual activity, accompanying diseases, etc.), the surgeon's preference, availability of appropriate devices, and financial considerations or constraints.

Until today, no standardized morphologic criteria for the use of IBD have been defined. Comparative studies are relatively scarce, so standardization of treatment is lacking (115, 219). The literature lacks an adequate evaluation of the proportion of patients with aneurysms involving the iliac bifurcation where the morphology is suitable for the application of IBD.

According to Tielliu et al. (208), only 52% of patients with aortoiliac or solitary iliac aneurysms were morphologically suitable for IBD. Parlani et al. suggest that a better anatomical criteria selection can prevent increased incidence of complications (162).

According to findings published by Gray et al. (67), reporting on 88 iliac arteries treated in 66 patients with AIAs, 58% of iliac arteries could have been treated with the iliac side branch (ZBIS). The weightiest adverse criterion in this series was an aneurysmal IIA without an adequate landing zone for the stent graft in the main trunk. Gray et al. therefore suggested to expand the usage criteria proposed by the manufacturer. More specifically, they proposed to chose a landing zone in a distal branch of the IIA with a preference for the inferior or SGA. This would, they suggested, have enabled treatment of more than 50% percent of patients with AIAs by using iliac side branch, preserving pelvic blood flow, while an endovascular treatment involving the ZBIS stent graft would not be feasible for over 40% of these aneurysms. They also, however, noted that expansion of the usage criteria implied a greater risk of technical failure which could lead to renewed occlusion of IIA when anatomical causes make cannulation of the IIA impossible. Choice of a landing zone shorter than 10 mm in the more distal branches of IIA in cases where the main branch is aneurysmal could also lead to a higher risk of type Ib endoleak (67).

Conversely, liberalizing the morphological indications may decrease efficacy and durability and lead to higher endoleak/failure rates, as shown by Donas et al. who noted high endoleak rate (12.5%) in 65 IBDs, although all cases could be treated successfully with reintervention (50).

Application of IBD (as any endovascular procedure) faces limitations of anatomic feasibility. Successful deployment of IBD relies on suitable EIA and IIA vessels for distal landing. In general, small or tortuous EIA or the concurrence of large IIA are obstacles for successful outcomes. In a comparative evaluation of literature published until 2010, Karthikesalingam et al. (98) found a low morphological applicability of commercially available IBD, with the majority of patients possessing at least one adverse anatomical feature. Most commonly, this was an aneurysmal IIA. They concluded that it is necessary to develop a validated morphological scoring system derived from registry-type data, with quantification of outcomes in IBD deployment that extends the manufacturers' instructions of use (98).

Some studies mention aneurysmal or heavily stenotic IIA as absolute contraindications for the use of IBDs. A contraindication for using the IBD may be if the IIA diameter exceeds the diameter covered by currently available stent grafts (87). The IIA should ideally be < 11 mm in diameter (127). Tielliu et al. state that one should only treat IIA larger than 10-12 mm with this technique if one is prepared to advance the bridging stent graft into a main tributary of the IIA after coil embolization of the branches arising from the aneurysmal portion. They also question whether preservation of an atherosclerotic IIA is advisable (207). Due to the need to use a balloon or self-expanding stent graft for sealing the gap between the side branch and the distal IIA, the application of an IBD is technically challenging in cases of aneurysms that extend deep

into the IIA (102). Pratesi et al. (171) have suggested that type Ib endoleak development during follow-up may be associated with the presence of an ectatic IIA. All patients had received the same kind of stent, and in all cases endoleaks were located at the distal sealing zone in the ectatic IIA main trunk. This suggests that endoleaks may have resulted from an inappropriate conformability of the stent under the pressure of dislodgement forces that normally develop in the post-operative period as the size of the aneurysm decreases (171). On this basis, Pratesi et al. argue that the coexistence of CIAAs and IIAs may be considered an actual limit to the applicability of IBD technique. Thus, they conclude that both options involving either the landing in one of the two relevant IIA branches or the landing in the main IIA trunk are associated with an increased risk of complications and secondary procedures even if technically feasible (171).

However, recently, some studies have demonstrated successful use of IBD for treatment of IIAA (7, 60, 156). Austerman et al. reported their 2-year-results of IBD technique in patients with aortoiliac or solitary iliac aneurysms and coexisting IIAAs, thus presenting the first study describing an endovascular technique to treat patients with AIAs and coexisting IIAAs by IBD placement (7). Ferreira et al. have gone up to the gluteal artery and have found that angulation was unproblematic. They only reported an initial difficulty in going through the very small and calcified EIAs (60). Noel-Lamy et al. showed that it was feasible and safe to extend the internal iliac component of IBGs into the SGA for distal seal when treating AIAs with simultaneous IIAs endovascularly, based on a retrospective study of 20 IIAAs in 15 consecutive patients (156).

Another anatomical requirement is a sufficient length of landing zone in the IIA or one of its branches so that a seal can be achieved with a stent graft. An IIA length of at least 10 mm is adequate for secure fixation of the IBD (118, 127, 219). A wide angle (> 50%) of the IIA offspring is also cited as a risk factor for implantation failure (91, 235).

Cannulation of the proximal end of the device from the contralateral CIA will be problematic if the CIA is too short for the length of the CIA component of the IBD. In this situation, brachial access may be needed. Preoperatively, calibrated angiography may be needed to accurately measure the CIA length. The IIA limb of the IBD will not have the necessary space to open up if the CIA diameter decreases at the iliac bifurcation. Such a CIAA morphology may contraindicate the use of the IBD (Fig. 4) (87). Naik et al. have described a CIA diameter of greater than 2.0 cm proximal to the IIA origin as a primary anatomical requirement for adequate opening of the IBD (153).

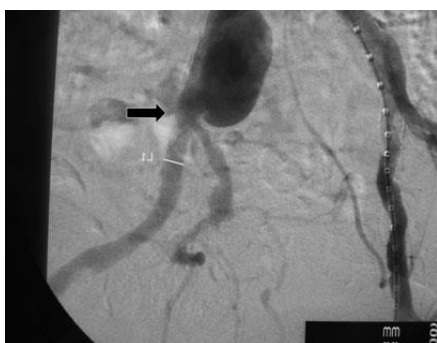

Figure 4. The narrow, distal CIA (arrow) precludes the use of an iliac bifurcation device. Figure and explanation taken from Huilgol et al. (87).

Although it is possible to achieve an iliac limb extension landing in a light-grade CIAA, the landing zone is still located in a diseased segment whose natural history is diameter increase and

subsequent repair failure (type 1b endoleak, distal migration). Therefore, we have preferred to achieve landing in a non-diseased segment.

Symptoms of compression due to aneurysm, or sepsis, are contraindications for an endovascular procedure (111, 129, 200). Another contraindication according to Tiellu et al. is a residual lumen (i.e. without thrombus) of the CIA <1.8 cm which will prevent full opening of the side branch of the IBD and catheterization of the IIA, with a mural thrombus increasing the probability of embolic complications (207).

Severe iliac tortuosity may be considered as another relative contraindication, especially at the origin of the EIA, since it may cause kinking of the device (87, 235) hamper flow beyond the iliac bifurcation and constrain IBD delivery, orientation, rotation and cannulation (65).

Further relative contraindications are the presence of a bifurcated surgical graft, a sharp aortic bifurcation (207), and stenosis at the orifice of IIA and calcification of iliac arteries (97).

It is necessary to describe the morphology of the aneurysm (size, shape, landing zone, wall pathologies) as well as the iliac arteries. The course of the procedure can be significantly altered by the pathological conditions of the vascular walls in the access and target vessels, as well as their development over time. These conditions can even lead to a conversion (42). Given a relevant extent (critical factor), wall pathologies can promote the development of endoleaks and must therefore be taken into consideration in the area of the landing zone (19, 93, 169). An increased incidence of complications is observed especially in association with circular calcifications (>80%) and thrombes (>40%) (42, 72). In procedural planning, it is equally necessary to consider the mural thrombes of the aneurysmal sac, which can cause peripheral embolies, and which may even alter the position of the stent graft (170, 207). The usefulness to preserve an atherosclerotic IIA is also in doubt (207). Insertion and deployment of sheaths is complicated by access vessels with a diameter <7mm, as well as severe calcification and stenosis (28). With decreasing vessel diameter, pathologies and angulations become more significant (170).

Criteria include the presence of an aneurysmal CIA of diameter >24 mm, a sufficient EIA length for distal landing of at least 15 mm (219) or even 20 mm (127).

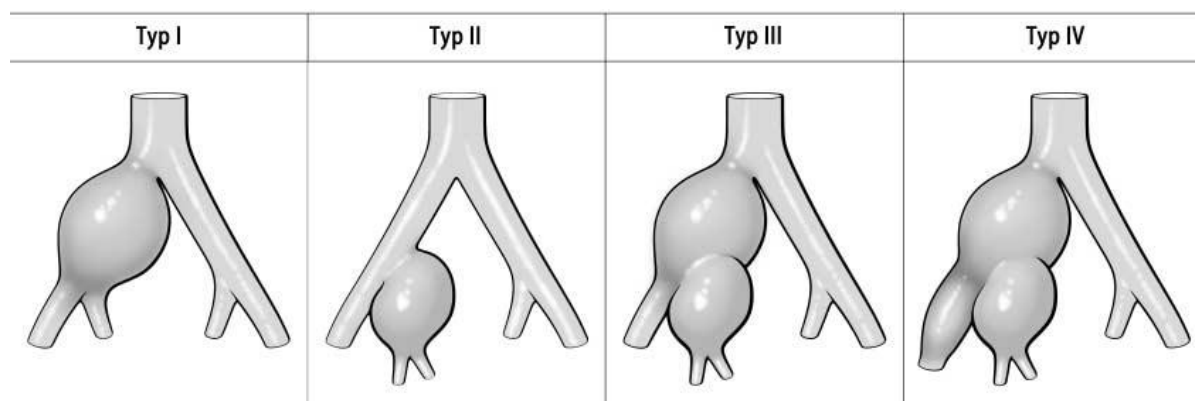


Figure 5. Morphology of isolated iliac aneurysms type I-IV according to Reber et al. Illustration taken from Reber et al. (182).

Reber et al. have suggested a systematic morphological classification of isolated iliac arteries (type I – IV) which can be easily reproduced (182). Accordingly, type II and type III aneurysms are suitable for embolization, as long as contralateral perfusion of IIA is given (15, 55, 189, 200, 211). In contrast, Papazoglu et al. (160) have argued that interna-coiling at overstenting of the

IIA offspring is not necessarily a requirement in type III aneurysms. Type I and type III aneurysms are indications for a hybrid approach (170).

Table 11. Therapy options for each aneurysm type according to Peters et al. (168)

Type 1	Type II	Type III	Type IV
endo-bifurcation	endo-tube + IIA coiling (peripherally)	endo-bifurcation + IIA coiling (peripherally)	“custom-made”
aorto-uni-iliacal endograft + IIA coiling	IBD	IBD	
bell-bottom technique		Periscope	
IBD			
sandwich technique			

Recently, with the development of endovascular techniques, several classifications of aneurysm morphology considering endovascular aspects have been suggested. Parameters of classification are the presence of a proximal and / or distal landing zone, as well as the manifestation of a uni- or bilateral aneurysm. Various classification schemes and manners to define length and width of the aneurysm neck make it difficult to compare the different systems. Added to this, concomitant pathologies of access and target vessels have not been sufficiently considered so far (170).

While the classifications of Fahrni et al. and Uberoi et al. (211), as well as Sakamoto et al. (188), are based on morphological criteria, Stroumpouli et al. (200) have chosen five therapy options as a basis for classification (55). Sandhu et al. (190) and Melas et al. have suggested other schemes (140). All these older classifications largely neglect consideration of maintaining IIA perfusion.

Recently, Pfabe et al. (170) have published a classification for isolated iliac aneurysms based on the scheme suggested by Reber et al., which they extended to include endovascular considerations. The classification suggested by Pfabe et al. considers, first, the affected segment of the vessel; secondly, the neck proximally and distally; and third, the length and width of the landing zone. This is differentiated according to unilateral or bilateral presence of the aneurysm. Pfabe et al. also point out that it is necessary to describe the aneurysm morphology (fusiform, sacciform) as well as presence of thrombi in the aneurysmal sac; furthermore, wall pathologies of the landing zone (calcification, thrombi, conic or bulging morphologies, kinking) must be included.

Patient selection

The decision to branch the IIA must be carefully considered. Should it be done in all suitable patients or only in patients with contralateral IIA occlusion, or in patients in whom one IIA needs to be occluded and the other revascularized?

Listing the main factors to consider when deciding which treatment options to choose, Huilgol et al. named the following seven aspects:

“(1) Patient’s life expectancy

- (2) Patient's level of physical and sexual activity and the impairment from BC or impotence were it to occur
- (3) Perceived risk of serious ischaemic complications from IIA embolization
- (4) Anatomical considerations and tailoring the operative strategy to the aneurysm morphology
- (5) Risks of a potentially longer procedure and associated larger contrast volumes with option (4) (above)
- (6) Financial cost of the procedure
- (7) Technical aspects of the procedure and the endovascular skill requirements." (88).

There are no clear guidelines for the decision to exclude patients with reduced activity level; rather, this decision is usually rooted in the surgeon's individual judgement. Tielliu et al. state that opting to preserve one IIA in most patients is plausible, but that preservation of both IIAs is open to discussion (207). Even occlusion of one single IIA may lead to claudication in a significant number of patients (121). Wong et al. (225) suggested that claudication due to IIA loss is sustained and patients actually "learn" not to walk; however, until now no secure evidence on this point exists. They concluded that clinicians have to balance the risk of complications such as claudication and others with the risks, complexity and expenses of adding an IBD to an aortic repair (225). Ferreira et al. argue that because of the difficulty to accurately predict the consequences of IIA occlusion in each patient, revascularization should be attempted whenever possible (60).

Ferreira et al. treated patients with a thoracoabdominal aortic aneurysm or a juxtarenal aneurysm simultaneously with branched or fenestrated stent grafts. According to their report, a main concern was the risk of paraplegia, since long aortic stent grafts might cover significant medullary arterial circulation. As an added preventive measure, collateral blood flow from IIA branches was preserved. 5% of patients with AAAs will develop a thoracoabdominal aortic aneurysm \leq 5 years, while at the time of diagnosis 20% of thoracoabdominal aortic aneurysms is associated with AAAs. Preservation of IIA blood flow may help to prevent medullar ischemia in patients whose aortic disease extends toward the thoracic or thoracoabdominal segment, and it may present a protection against the known complications of IIA occlusion (60). According to most clinicians, IIA circulation plays a significant role in providing collateral flow to the spinal cord when endovascular repair of the more proximal aortic segments is carried out (69).

In conclusion, case-to-case decisions must still be taken to determine the necessity of preserving IIA flow during endovascular iliac aneurysm repair (87). The consideration of possible complications related to the technique must be included in this decision-making process (207). It is important to note here that most patients are asymptomatic. Just as every person has a differently shaped nose, every patient has a different vascular anatomy. It is the task (and the art) of the surgeon to judge each case on its own, and to find the most appropriate approach for each patient's individual anatomy.

Bilateral IBD

A few cases of endovascular branched aneurysm repair techniques have been presented. Illuminati et al. have described their technique in one case in detail (91). Worldwide, bilateral IBD implantations are relatively rare; due to the anatomical conditions, this technique will be unsuitable in many cases (76, 88, 196, 207). Serracino-Inglott et al. reported that "the increase in need for fluoroscopy time, the increased usage of contrast, the longer anesthetic time, as well as

the additional need for vascular access from the arm to cannulate the second IBD side branch, and IIA” may increase the risk of the procedure and possibly outweigh its benefits as long as experience with this novel device is still limited (196).

Experimental data about the use of bilateral IBDs is scarce; but the advantages of using them can, according to Huilgol et al. (88), be inferred from other information about the advantages of IIA preservation and the negative effects of IIA occlusion. However, they point out that other factors must be taken into account when evaluating the benefits and disadvantages of using bilateral IBDs, such as the longer duration of procedures, screening times, contrast volumes, anatomical conditions, cost, and finally, the experience with branched endograft approaches. Huilgol et al. (88) therefore strongly advocate continued observation of these cases to determine the long-term outcomes. Huilgol et al. (88) are familiar with the straight branch design, but see “no technical reason to choose one design over another when using the IBD bilaterally.”

In each individual case, therefore, the decision will be complex and must take all the mentioned aspects and possibilities into account.

Although bilateral preservation is not always necessary, it is an option when it is technically possible, involving acceptable contrast and fluoroscopy amounts. In our series, we have tended towards bilateral IIA revascularization, since we concur with Ferreira et al. that although the complications associated with exclusion of both IIA are less prevalent with unilateral IIA occlusion, bilateral IIA revascularization is advisable in case of future occlusion. Secondly, it provides protection from present and future ischemic complications of the spine in cases where thoracoabdominal aneurysm repair becomes necessary (60).

In the case of bilateral CIAA, when a decision is taken to use the branch stent in unilateral CIAA, it is more advisable to deploy the branch in the side where the IIA is smaller and shows less thrombus, as described for example by Naik et al (153).

IV.3 Methods of IIA Preservation Following EVAR (other than IBD)

IIA occlusion during endovascular repair in AAA with combined CIA aneurysms may cause a number of complications. Therefore, a range of open, endovascular, and hybrid techniques has been described to maintain pelvic perfusion during EVAR.

Open repair

A less invasive option than open AAA repair is EVAR which has proved to be a feasible alternative (25, 71, 173). Compared with AAA open repair, results of EVAR show lower morbidity and mortality rates at short-term and midterm follow up intervals (71, 173). It Of course regarding both open repair and EVAR, the rates of morbidity and mortality for patients with associated iliac disease are higher than for patients suffering only from AAA (1, 235). Erectile function is affected by blood supply to the penis through the internal pudendal arteries, and thus, the IIAs. However, injury of the autonomic nerves crossing over the aorta during standard, open AAA repair may be even more significant for postoperative sexual dysfunction. This adverse effect is avoided with an endovascular approach.

Until the present day, IMA occlusion during EVAR cannot be avoided, making it advisable to maintain patency of the other vessels as far as possible. The option of mesenteric artery

reimplantation with interruption of other pelvic collateral circulation which is available during open repair is absent in endovascular repair. Note that an IMA with a larger lumen is more significant for pelvic perfusion than one with a smaller lumen.

Compared with EVAR, open repair involves a higher risk of ureteric or iliac vein and collateral vessel injury, especially in patients with previous abdominal operations, obesity (186), or in patients with pathology, radiation, or large iliac aneurysms (118). It seems that endovascular repair may be the better therapy option, especially for young active patients or in patients with contralateral occlusion, since it allows the preservation of the IIA. Notwithstanding the excellent durability of the surgical reconstruction, further advantages of endovascular therapy include the frequency of postoperative incisional wall hernias in 31.4% of the patients, the length of stay in the intensive care unit (ICU), as well as the possibility of graft infection. Furthermore, the effects of different anesthesia techniques on the outcome have not been documented in a comparative way between the two subgroups of patients (50).

Similar results were shown by Donas et al. (50), who were the first to report on the outcome of EVAR by iliac side branch device (IBD) in 64 of 118 patients (54.2 %) compared with open repair for aneurysms involving the iliac bifurcation in 54 of 118 patients (45.8%).

Hybrid open and endovascular procedures

Hybrid procedures combining open surgery and endovascular measures were used in early approaches to preserve IIA.

Parodi and Ferreira first described the relocation of the IIA by deploying a bifurcated endograft into the EIA. This involved covering the ostium of the IIA (163). Isolation and proximal ligation of IIA were performed to avert backflow into the iliac aneurysm, a bridging graft from the common femoral or EIA to the IIA remnant is deployed (65). In a comparison study of coil embolization and IIA bypass, Arko et al. found that a bridging graft is more advantageous, while one should, if possible, avoid coil embolization followed by occlusion of the IIA (4). (Fig. 6, a).

A specially modified covered EIA to IIA stent (cross-stenting technique) was first described by Hoffer et al. to exclude an aneurysm of the iliaca communis, while maintaining a back flow from the femoro-femoral crossover (8, 35, 85, 107, 184). Derom et al. described the use of a HaemobahnTM endograft (W.L. Gore & associates) as an ‘off-the-shelf’ EIA to IIA conduit to treat a bilateral common iliac artery aneurysm (BCIAA) following an open aortic aneurysm repair (45). A similar procedure was described by Clarke et al. using a WallgraftTM (Boston Scientific) device (32). Bergamini et al. described the use of cross-stenting with bilateral CIA aneurysms (12). There are further reports on using this procedure (8, 107, 134, 230). (Fig. 6, b). This approach has a number of disadvantages, including prolonged operating, contrast and X-ray times, as well as reliance on retrograde flow to the contralateral leg and pelvis with an acute graft angle. Dependency on the aorto-uniiliac graft and femoro-femoral cross-over graft as conduits for pelvic and lower limb perfusion is another significant concern; the results of thrombotic or infective complications of either part would be devastating for the patients (65).

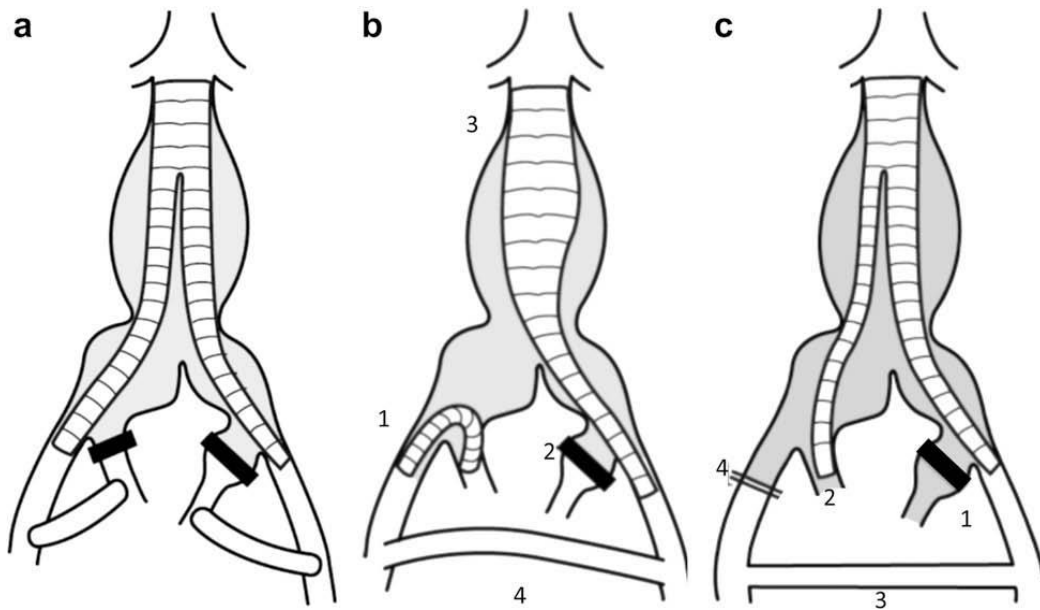


Figure 6. (a) Relocation of origin of IIAs; (b) The Reverse-U stent graft: (1) Stent from EIA to IIA; (2) Embolisation of contralateral IIA; (3) Aorto-uniiliac stent graft; (4) Femoro-femoral crossover graft; (c) Bifurcated stent graft: (1) Embolisation of ipsilateral IIA; (2) bifurcated stent graft with extension into ipsilateral EIA and contralateral IIA; (3) Femorofemoral crossover graft and; (4) ligation of contralateral EIA. Illustration and explanation taken from Ghosh et al. (65).

The use of a bifurcated stent graft following embolization of the ipsilateral IIA as described by Delle et al. (44) is another hybrid open/endovascular procedure. Here, an Excluder™ (WL Gore & Associates, Flagstaff, Ariz) endograft main body is deployed in the EIA from the femoral artery and the patent contralateral IIA cannulated through the brachial artery. Then, a covered stent graft is deployed into the patent IIA to exclude the aneurysm sac. To avert backflow into the aneurysm sac, the unperfused EIA is ligated to. A femoro-femoral crossover graft restores perfusion in both legs. (Fig. 6, c). This approach resembles the natural anatomical situation more closely, since the perfusion to the IIA flows in an antegrade rather than retrograde manner. As in the previously described procedure, the dependency upon the aorto-uniiliac graft and femoro-femoral cross-over graft as conduits for pelvic and lower limb perfusion is a cause for grave concern, since the effects of thrombotic or infective complications of either part would result in devastating outcomes for the patients (65).

Because the Japanese government did not admit the import of commercial endovascular grafts, in 2006, Unno et al. proposed a custom-made aorto-uni-external iliac artery stent graft made from a Gianturco Z-stent (Cook Inc, Bloomington / Ind., USA) and a spiral Z-stent (Medico's Hirata Inc, Osaka, Japan) tapered and sutured to a woven polyester graft (UBE Corp, Ichihara, Japan). They reported performing coil embolization of the contralateral IIA at the main trunk to interrupt retrograde blood flow to the contralateral CIA. A crossover iliaco-femoral bypass was performed in combination with ligating the proximal region of the contralateral CFA. Then, perfusion of the ipsilateral IIA was restored through a bypass between the crossover bypass graft and the ipsilateral IIA. The proximal region of the IIA was ligated (213).

However, all these hybrid techniques technically diminish the benefits of EVAR that are associated with its minimally invasive nature. They necessitate a general anesthesia which makes

these techniques unsuitable for high-risk surgical patients. Recovery times are increased due to the additional incisions and dissections necessary for extra-anatomic bypasses, which may also lead to longer operating times, blood loss, postoperative pain and complications like sexual dysfunction, and an altogether longer stay in hospital (8). The patency rates of the additional small vascular prostheses which are required for all of these techniques vary.

To date, short-term results of hybrid approaches without endoleaks or stent graft thrombosis have been reported only for a few cases (12, 35).

Banding of the Common Iliac Artery

Surgical banding of the CIA is a possible procedure to achieve an effective seal of the iliac limb when ectasias or small iliac aneurysms are present (176). After EVAR, the iliac aneurysm is exposed by employing retroperitoneal exposure. Next, the CIA is tightly banded by a Dacron band or by two thick ligatures until apposition of the artery walls to the underlying endograft limb is achieved (118). According to reports, this technique may be an option for salvaging type I endoleaks at the proximal attachment sites. Although it is technically simple, significant surgical exposure is required, heightening the risk of adjacent venous injury during circumferential dissection of the iliac artery. It is only suitable for small iliac aneurysms. Further studies are needed to determine long-term durability. Moreover, Lee et al. have voiced theoretical concerns regarding late pressure necrosis of the underlying arterial wall (118).

Bell-bottomed configuration (BBT)

The use of a flared cuff, the so-called “bell-bottom” configuration to EVAR iliac extension limbs has first been proposed by Karch et al. as a less invasive method, where the cuff is anchored within the CIA, preserving IIA patency (96). This technique may allow aneurysm sac exclusion even when the iliac anatomy is challenging, and it avoids recourse to open surgery. Originally, a short aortic extension cuff or a reverse-mounted iliac limb stent graft was deployed in the distal CIA attachment zone in order to bring about a complete seal (21, 115).

A comparison study of internal iliac embolization and BBT by Naughton et al. showed that BBT has a lower rate of combined complications and reintervention (154). A disadvantage of these configurations is their limitation to small iliac aneurysms or ectasia (diameters between 18 to 24 mm) due to their maximal 24 mm diameter (65, 96, 209). Generally, for stable anchoring, it is required to oversize the cuff by 15–20% (42, 200). The employed graft diameters should be 2-5 mm larger in the proximal region and 1-2mm larger in the distal landing zone than the relevant vessel diameter (72).

Among the advantages described for BBTs are significantly decreased OR time and catheter procedure time (111). Bell-bottom endograft extensions have been used successfully in some aneurysm morphologies (111), but their use has been limited to small iliac aneurysms or ectasia due to the maximal 24 mm diameter (65, 96, 209). Recently, this technique has been superseded by the introduction of commercially available large-diameter iliac extension limbs of up to 28-mm diameter (215). However, the increased risk of rupture in CIA of more than 30 mm must still be considered (191). Long-term follow-up after BBT had documented further vessel dilatation and/or distal endoleak due to retrograde migration of the stent graft, necessitating secondary intervention (56). The BBT usually involves a landing zone in a diseased segment of CIA. This can give rise to later growth and development of an endoleak type Ib with a 4% reintervention rate (154). In many cases, the length of the attachment zone may be unsuitable for BBT. The main technical consideration is that the actual iliac limb must be deployed sufficiently

proximally, leaving at least 15 mm of distal CIA to allow effective expansion and apposition of the aortic cuff. Kritpracha et al. have defined a minimum attachment zone of 15 mm and a maximum diameter of CIA of 25 mm for BBT.

The additional device cost and potential for a type III junctional leak are the most obvious disadvantages of this technique. BBT can also pose problems in short CIAs, which may require the unstable iliac limb–aortic cuff junction to be near an angulated aortic bifurcation (118). The bell-bottom configuration is also not suitable when internal iliac aneurysms are present. Internal iliac aneurysms must still be excluded by another approach (111).

Trifurcated endograft technique

Minion et al. (144) describe a procedure for preserving IIA patency using what has been termed a trifurcated endograft. Bilateral femoral access with 18 French sheaths (W.L. Gore, Flagstaff, AZ) as well as left brachial or axillary access with a 75 cm, 12 French Hausdorf-Lock introducer sheath (Cook Medical, Bloomington, IN) are needed for this method. The trifurcated configuration is realized by placing a standard bifurcated Gore Excluder device using a PXC 201000 limb on the side of the envisaged IIA extension. Following this, a second main body device with a proximal diameter of 23 mm is deployed inside the PXC 201000 limb. The contralateral gate is oriented toward the target IIA. The Hausdorf-Lock sheath is advanced into this second contralateral gate and an 11 or 13 mm x 5 cm Viabahn is advanced into the IIA. Then the first extension and the contralateral gate of the second main body are bridged with a 13 mm x 5 cm Viabahn (Fig. 7).

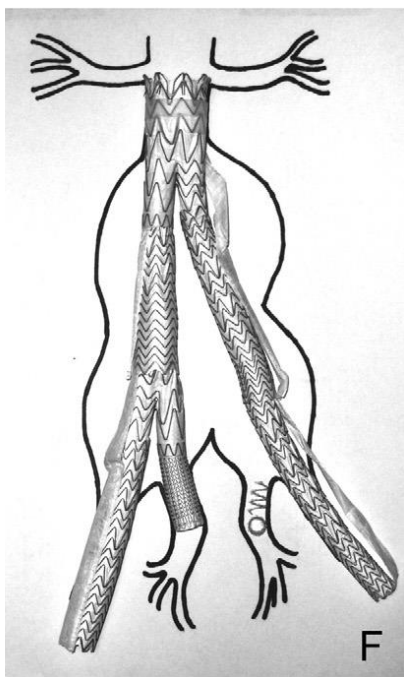


Figure 7. *Trifurcated endograft technique. Figure taken from Minion et al. (144).*

The application of the trifurcated configuration is limited because it requires an aortic diameter big enough to fit the three limbs, and a minimum of 16.5 cm in length from the lowest renal artery to the IIA. Minion et al. regard these limitations as largely unproblematic, since the common iliac aneurysms tend to add significant length, and are often associated with aortic

involvement. They also point out that the use of multiple pieces increases the expenses of the procedure and heightens the risk of late graft disconnects. Furthermore, the axillary exposure which this procedure requires may lead to temporary median nerve dysfunction as well as arterial complications (144).

The Apollo® Iliac Branched Device

Massière et al. (133) proposed an alternative method to preserve IIA patency by using the Apollo® iliac branched device (Nano Endoluminal, Florianópolis, SC, Brazil), a custom-made device which connects to the Apollo AAA device (Fig. 8). Apollo IBD has an extra-flexible structure of superelastic nitinol and expanded polytrafluoroethylene. This was used during endovascular AAA repair for a patient with bilateral CIA aneurysms and bilateral IIAs. The authors used the iliac branched device on one side only, the other IIA had been coil-embolized one month previously. The device was delivered with a 16F delivery system.

The device was deployed after insertion into the ipsilateral femoral artery with adequate fitting to achieve alignment with the IIA. After deploying the contralateral sheath into the origin of the common iliac component, it was advanced into the branch limb and terminated in the distal side. Catheterization of the stent graft branch and of the ipsilateral IIA was performed, followed by insertion and balloon dilation of a 11 × 100 self-expandable stent graft into a 10-mm side branch (Viabahn®; W.L. Gore, Flagstaff, AZ). The contralateral femoral artery served to deploy the main body which was connected to the branched device with an extension (133).



Figure 8. Apollo branched graft. Figure taken from Massière et al. (133).

Sandwich/chimney technique

Another option is the sandwich technique (ST) initially introduced by Armando Lobato (126). In 2008, ST was described for the first time to treat AAA in circumstances of adverse iliac anatomy, such as AIAs and isolated CIAs extending to the IIA, or AAA with bilateral short, non-diseased CIA while preserving pelvic perfusion. The technique is described in a number of easy-to-follow basic steps also termed “the easy 5-step method” (126). First, by an ipsilateral femoral

approach, the main body of a bifurcated aortic stent graft is inserted and deployed. The distal end of the iliac limb is placed 1 cm above the iliac bifurcation (Fig. 9, B).

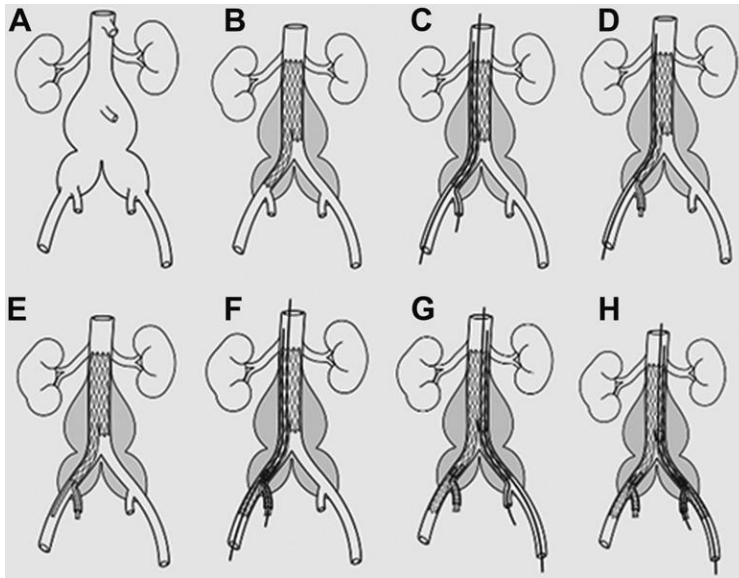


Figure 9. Stages of deployment during ST. Figure taken from Lobato et al. (124).

Next, the ipsilateral IIA is cannulated using a left brachial approach. A self-expandable covered stent (SECS) is placed at least 1 cm inside the non-diseased IIA, with an overlap into the iliac limb extension of at least 5 cm (Fig. 9, C-E). 1 cm below the SECS proximal end, the iliac limb extension is positioned, deployed and accommodated with a latex balloon. Following this, the SECS is deployed (Fig. 9, F). The same procedure can be used for the contralateral CIA and IIA (Fig. 9, G-I) (124).

This technique has been described in a number of variations (63, 64, 79, 147, 231). Frigatti et al. have described a case where a combined ‘chimney-double barrel’ endovascular technique was used to manage bilateral CIA aneurysms extending to both iliac bifurcations while maintaining anterograde circulation to one IIA (64).

Unilateral occlusion of the IIA combined with an endovascular stent graft from the iliac limb of the aortic device into the ipsilateral IIA was used in one case described by Friedman and Wun. After embolization of the contralateral IIA,s a Powerlink device was deployed through a contralateral CFA cutdown. An ipsilateral iliac extension was positioned through a femoral cutdown but not deployed. A Viabahn device was positioned through the contralateral CFA adjacent to the ipsilateral iliac extension device. The distal end was located in the ipsilateral IIA. Then, both devices were simultaneously deployed and postdilated with balloons (see Fig. 10) (63).

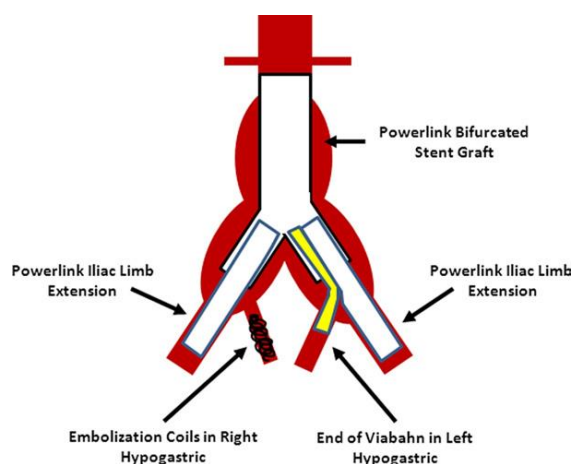


Figure 10. Illustration shows the adjacent Powerlink and Viabahn grafts. Illustration taken from Friedman et al. (63).

In one case described by Heckenkamp et al., a ViaBahn™ graft was deployed into the IIA, combined with standard abdominal aortic stent grafts. Through a transsubclavian access, the chimney graft was deployed and positioned parallel to the iliac limb into the previously deployed standard aortic stent graft (78).

DeRubertis et al. have described a double-barrel technique for IIA preservation using commercially available devices without device modification (46). This technique has been analyzed in a number of small series and case reports. DeRubertis et al. (46) presented a series of 22 patients. Technical success, defined as successful implantation with immediate aneurysm exclusion and no observed endoleak, was reported at 88%. Primary patency for EIA and IIA limbs was 95% and 88% at 6 months, respectively. In a small series of 7 patients treated with the ST, Ricci et al. (185) reported a technical success rate of 100%. There was no stent graft occlusion or endoleak at 1 year follow-up.

Using the ST has a number of benefits. It involves no constraints regarding IIA diameter, diameter or length of CIA (126, 185). It is versatile and flexible enough to manage AIAs with challenging iliac anatomy, among them CIA length <40 mm, CIAA lumen < 18mm; a distal landing zone with a length <10mm on the main internal iliac trunk; isolated CIAA with proximal landing zone (CIA) > 12 mm in diameter; occlusion of EIA; large IIAA; complicated CIA dissection due to CIAA with a true lumen diameter of <18 mm; or earlier AAA open repair with a Dacron graft complicated with CIA anastomotic false aneurysm (124). The deployment of the bridge stent in the IIA through a left brachial access approach makes it easier to catheterize the IIA (56, 124). Thus, the ST is suitable even with very tortuous CIA anatomy. This presents an advantage when compared with the difficulties reported for IBD (219, 235).

This approach permits using shorter stents (106). Lobato et al. describe the ST as straightforward and suitable for use in emergencies, since the “five-step-method” (126) is easy to follow; and since it involves commercially available endografts and stents with which most endovascular surgeons are familiar (175, 124). Waiting for a specific stent graft (126) is not necessary. However, while ST is easier to follow compared to the IBD approach, it is nevertheless a complex procedure (148). Dake has pointed out that the endografts and stents are not exactly used off-the-shelf but must be “cobbled together in an unapproved way” which does not always produce a perfect fit. There is an increased risk of endoleak from the gutters, for instance, when placing two devices within another (40).

Among other disadvantages of the ST, access from a brachial artery which is a requirement for using the ST (in addition to the femoral arteries accesses used in branched iliac stent graft) and a larger introducer (usually 9F) (185) involves certain risks. Brachial puncture may lead to brachial artery thrombosis due to a delay in removing the brachial sheath. Another concern is the risk of stroke (235). Secondly, positioning Viabahn stents requires considerable experience since they are not very radiopaque (185). It has thus been reported that radiopaque marks and tapered design would increase suitability of the covered stent for the ST (124). However, the maximum available diameter of the Viabahn stent graft (with a range of 9-12 mm in diameter) is the major technical limitation of ST (185). Adequate presurgical planning using CT angiography is mandatory, considering that the summed-up areas of the two Viabahn stents should be 10–20 % more than the area of the iliac extension of the bifurcated stent graft, according to the informative technical sheet of Viabahn stents (185).

Due to the relatively recent development of ST, more experience and longer follow-up is necessary before it is possible to fully evaluate this procedure when compared with other techniques that address the same anatomical and device problems (126). However, ST is evidently a promising approach in the EVAR spectrum of options. Finally, while the ST is expensive (185), it is less cost-intensive than the trifurcated endograft technique or the (IBD) (126).

Crossover chimney technique

The crossover chimney technique was recently suggested by Wu et al. (226) as an alternative approach to preserve the IIA in cases of AIAs. This technique presents a number of advantages, since it avoids the complications associated with the brachial access of the ST, is easy to use and avoids the additional cost of an IBD. However, experience with this technique is still limited. Wu et al. presented a small series of 5 patients that was successful until up to 6 months after the operation. The report described insertion of a crossover sheath from the contralateral CFA to the ipsilateral IIA involved in the CIA aneurysm under exposure of bilateral CFA. A Viabahn stent graft was positioned 2 cm inside the IIA. Insertion of the main body abdominal stent graft through the ipsilateral CFA with distal sealing in the EIA followed. Cannulation of the gate and positioning of the limb extension in the contralateral CIA near the IIA orifice were carried out. After the initial deployment of Viabahn, deployment of a second device with a minimum 1-cm overlap inside the first Viabahn and 2 mm distal to the limb extension followed. In cases of bilateral CIA aneurysms, Viabahn and extension landing were effected in the EIA with IIA embolization.

Banana technique

Mosquera Arochena et al. (146) presented the so-called “banana technique”, comprising a hybrid bilateral approach performed with the flexible covered stent (Viabahn® WL Gore), in order to preserve both IIA combined with open repair. This involved implantation of a bilateral retrograde endograft from both EIA to IIA excluding bilateral CIAA followed by open aneurismectomy of AAA with aortobifemoral bypass. Generally, the hybrid approach is a promising approach to IIA preservation in low-risk and young patients with AAA.

Sac-Sealing Endograft / Endovascular aneurysm sealing (EVAS)

In 2011, Donayre et al. (51) first reported a new system: The Nellix device (Endologix Irvine, Calif) which is designed with deployment of EndoBags filled with polymers surrounding

balloon-expandable stents covered with expanded polytetrafluoroethylene. Because the aneurysm sac is stabilized through the complete filling and sealing of the lumen, the system is named EndoVascular Aneurysm Sealing (EVAS) system. As described in (105), citing (51, 109), “rapidly freezing polymer” fill “special polytetrafluoroethylene bags” while blood flow is ensured through two endograft tubes in the aneurysmal sac. Böckler et al. judges that through this design, the risk of type I and type II endoleaks and endograft migration may potentially be reduced, as will the risk of component separation and type III endoleaks, due to the single-piece design for the individual right and left devices (16). According to Brownrigg et al., the EVAS technique is suitable in cases of challenging aortic morphology, while growing procedural experience will probably lead to reduced endoleak rates (22). Böckler et al.’s multicenter postmarket study of infrarenal AAA repair involving the Nellix device in 171 patients reported a technical success in 99 % (169/171 patients) with four type Ib endoleaks in three patients (2%) (16).

Among its disadvantages is the fact that the system is not modular which limits correct and precise placement for sealing in short iliac vessels. Moreover, the endobag inflation may cause hemorrhage and threaten the success of repair, as it may be disruptive and extrude through any aortic deficit (3, 75). Another limitation is that at present, only AAA with a maximum patent lumen diameter < 60 mm can be treated with the Nellix device because each endobag “has a finite capacity for expansion to obliterate the aneurysm sac” (100). Boersen et al. have shown that inflating the endobags to “a pressure of 199 mmHg is associated with a low risk of peri-procedural complications”. This caused lost thrombus volume in some patients, likely due to liquid components squeezed into branch arteries (17).

Donayre et al. showed that, independent of sac diameter, Nellix iliac extender devices, with an available length of 60 mm, enabled treatment of iliac aneurysms with blood lumen diameters of <30 mm (51). They concluded that the Nellix iliac extender devices made treating common iliac aneurysms more simple in that they provided “a normal flow channel to the IIAs and EIAs while obliterating the aneurysm sac” (51) as shown in Fig 11.

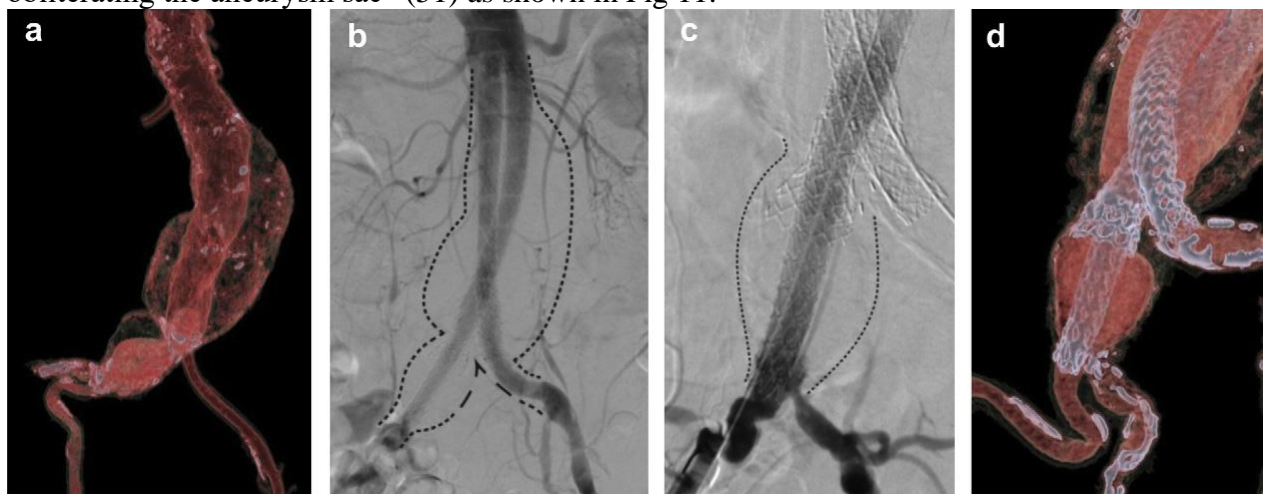


Figure 11. “Treatment of 6.3 cm AAA with short, funnel neck and 3.7 cm right CIAA. (a) Pre-op 3D-CT reconstruction and (b) Post-op angiogram. (c) Post-op angiogram showing exclusion of the iliac aneurysm with preservation of IIA flow and (d) 3D-CT reconstruction of the CIAA after treatment with complete exclusion of the aortic and iliac aneurysms.” Figure and explanation taken from Krievins et al. (109)

According to Krievins et al. (109), the sac-anchoring iliac extender maintains perfusion to the IIAs as well as EIAs because the iliac bifurcation is preserved even while common iliac

aneurysms are obliterated. They moreover suggest that exclusion of a non-aneurysmal aorta or contralateral CIA may not be necessary when using sac-anchoring iliac extenders for the sole treatment of the common iliac aneurysm. Both Krievins et al. and Donayre et al. expressed confidence that future modifications of the Nellix extender designs may enable treatment of internal iliac aneurysms while preserving the flow lumen (51, 109).

Parallel graft (PG-EVAR)

Recently (July 2014), Lepidi et al. (119) have presented the PG-EVAR technique, an original and straightforward “off-label” approach to EVAR at CIAAs derived from the chimney graft technique, first described by Greenberg et al. (68). This approach entails delivering iliac leg endografts (ILE) and covered stent grafts in a parallel fashion from proximal aortic to distal iliac landing zones, while preserving prograde flow to at least one IIA throughout. Lepidi et al. demonstrated that five of eighteen (5/18) patients underwent IIA flow preservation. Here, the covered stent grafts were first delivered, engaging the space between the ILEs which were subsequently released in the proximal landing zone. The in-folding of endografts is consequently distributed between the two ILEs, thereby minimizing the risk of type Ia endoleak from gutters.

In contrast to other off-label approaches which preserve flow to the IIA (126, 144, 226), which normally require a mainbody device delivered in the abdominal aorta, this is not required in parallel graft (PG) EVAR-technique. In their series, Lepidi showed that the median distance between the lower renal artery and the proximal ILE landing zone was 5.3 cm (range 3-6.4 cm), in this way preserving flow to the IMA in four out of five patients with isolated BCIAA.

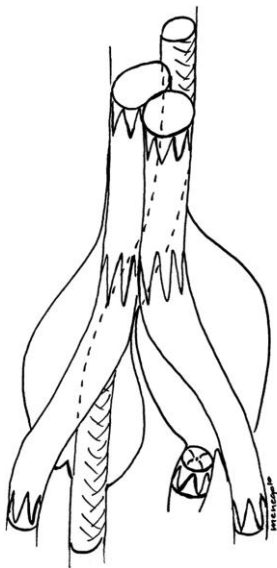


Figure 12. Schematic drawing of parallel graft endovascular repair procedure, showing bilateral common iliac artery aneurysms (BCIAA) extending to both iliac bifurcations treated with ILGs to both EIAs, covered stent graft to one IIA and Amplatzer vascular plug to the contralateral IIA. Illustration taken from Lepidi et al. (119).

As PG-EVAR avoids “the contralateral branch cannulation in the bifurcated graft, retrieval of a guidewire from the contralateral femoral side in the Powerlink/AXF and contralateral iliac plug

occlusion and an extra-anatomical crossover bypass in aorto-uni-iliac AUI” (119), PG-EVAR is considered a quicker and more suitable approach for high-risk patients.

A disadvantage in the PG-EVAR approach is the potential risk of type Ia endoleak along the stent graft gutters, as in all parallel graft approaches. Also, the PG-EVAR technique is not applicable for juxta-renal AAA or AAA with short proximal neck.

IV.4 Considerations regarding IBD use

Description of Iliac Branch Devices

Most IBD devices are off-the-shelf devices which are coupled with devices utilized successfully in the treatment of AAAs (69). The branched iliac stent graft can be combined with regular EVAR or advanced EVAR devices. Another option is bilateral IBD implantation (174). The first unibody IBDs of the early 2000s two-branch stent grafts, were made up of three segments, namely common (12 mm diameter, 45 mm length), external (10 mm diameter, 37 mm length), and internal iliac segments (12 mm distal diameter, 29 mm length). The internal iliac segment served for introduction into the IIA (Fig. 13, A), while a preloaded catheter with a metallic rounded tip was conducted through the external into the common segment. Similar to a shepherd-hook catheter, this catheter curved from the common segment back into the internal segment. The catheter’s tip equalled the tip of the constricted internal branch. The next generation, modular, IBDs were two-branch vessel grafts which were formed of three segments, namely the common (12 mm diameter, 44 mm length), the external (10, 12, or 14 mm diameter, 54 or 71 mm length), and the reinforced stump (8 mm diameter, 12 mm length) for the internal iliac side branch (Fig. 13, B). With proximal and distal fixation, the graft was preloaded onto an introducer sheath. A preloaded catheter crossed through the introducer, outside of the external iliac segment, entering the graft through the distal opening of the side branch and exiting it through the proximal end of the common iliac segment. Proximal and distal attachments were controlled by two trigger strings on the handle (235).

The success of early IBD-designs was limited by kinking or dislocation of the stent graft, which caused thrombosis and endoleaks at the junction of the side branch and bridging stent graft (1). Chuter and colleagues subsequently designed a bifurcated iliac component by amputating the proximal two stents from a Cook Zenith™ AAA endograft main body (1). Contemporary IBD configurations are derived from this design, while the helical branch endograft was designed by Greenberg and colleagues (see below) (65).




Figure 13. Evolution of the Zenith Iliac Branch Device: (A) first generation; (B) second generation; (C) straight (Australian) version. Figure modified from Ziegler et al. (235).

Cook Zenith Iliac Branch Device

The Zenith Iliac Branch Device (IBD) (Cook) is designed for use with the Zenith Flex (Cook) family of endovascular aortic devices. Since its original conception, the device has undergone a number of changes. It exists in two forms: the helical (Greenberg) and the straight (Australian) form (Fig. 13, C). Both types consist of self-expanding stainless steel stents with polyester (Dacron fabric) lining. Branch segments are reinforced with nitinol, while orientation and radiographic visualization are facilitated by gold markers (118). Both forms involve a preloaded indwelling catheter and guide wire through the side branch (60).

Helical IBD

Compared to the straight version IBD, the helical IBD has a longer overlap and can be utilized with self-expanding stent grafts (Fluency or Viabahn) (70, 76). Different from the Zenith bifurcated iliac side branch (ZBIS), the H-IBD has a fixed length; sizing is unnecessary. The H-IBD is designed to maintain rotational ability and the capability to address angulation between the EIA and IIA origins in large CIAAs (65).

The helical internal iliac side branch device (H-IBD) is constructed of a 12-mm tubular common iliac portion to which a 6 or 8 mm helical branch is anastomosed. The anastomosis is fashioned in a beveled way, distal to the proximal edge of the graft, imitating the anastomotic geometry of end-to-side surgical grafts (see Fig. 14). The curved shape of the limb facilitates the creation of a gradual curvature for the branch intended for the IIA, which permits an overlap of 2.5 cm between the internal iliac device and the iliac limb (69).

The internal iliac branch is 29.3 mm long. This is the total helical length from the center of the anastomosis to the outlet branch which is wrapped around the 12-mm tubular graft, terminating 150° from the proximal anastomosis. Fluoroscopic orientation is facilitated by markers which are placed on the branch.

Similar to the Zenith device, the device consists of stainless steel stents and full thickness polyester fabric (Fig. 14, A). The overall joint strength of the device is reinforced by crimps in the fabric within the proximal stent. The device is loaded into a 20F sheath. The delivery system is transcended by a preloaded 4F catheter and a 0.035'' wire (Fig. 14, B, red arrows), which enter the branch in a retrograde manner, exiting it through the proximal device lumen, eventually

passing through a groove within the nose cone of the delivery system. Ready access into the branch ostium is provided when the preloaded wire is snared from the contralateral femoral access site (76).

Initially, two branch sizes were provided, including a right-sided and a left-sided version. More recently, only 8-mm devices have been used, while 6-mm devices have been excluded. In cases where the IIA anatomy is regular, arising from the posterior medial portion of the CIA, the branched device of each respective side is used; in unusual anatomic scenarios, the devices can be reversed so as to deal more adequately with incidences of tortuosity in some iliac vessels (76).

Accuracy of stent graft deployment at the distal IIA landing zone can be more easily achieved with the helical device due to the long overlap, giving flexibility regarding the proximal overlap. Wong et al. report challenges with delivery and deployment accuracy in decidedly tortuous scenarios with respect to the Viabahn (W.L. Gore), while they had better experiences with the Fluency device. They suggest that the high patency rates and absence of any fractures of mating devices even with severe angulation may be due to the fact that the helical design permits smooth accommodation of the inherent angulation between the IIA and CIA, which leads to little angulation within the completed branch (225).

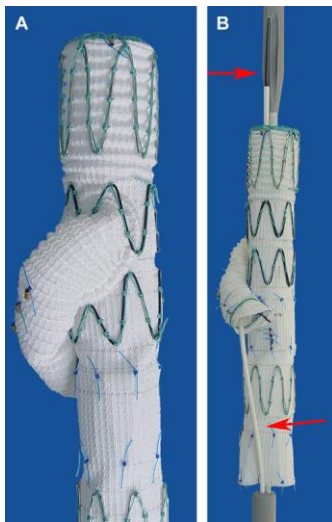


Figure 14. *The helical device (A), involving a preloaded catheter and guide-wire which transcends the delivery system (B). Figure taken from Haulon et al. (76).*

Straight IBD (ZBIS)

The straight IBD (Zenith bifurcated iliac side branch; ZBIS) is a bifurcated endograft intended to be used in conjunction with the Zenith Flex (Cook) iliac limb. It resembles the AAA Zenith modular stent graft main body but is smaller in order to better fit the iliac anatomy. It is possible to use the ZBIS branch model in both sides (60). Customizability is enhanced by availability of eight different sizes. The device's proximal diameter measures 12 mm, and the common iliac segment is available in 45 and 61 mm lengths. The device consists of woven polyester fully supported by stainless steel Z-stent exoskeleton, with the exception of the distal sealing stent (118). Since the overlap zone for the mating stent graft is relatively short, it can be used with a balloon-expandable stent graft (Atrium or Jomed) (235) or a self-expanding endograft.

The diameter of the internal iliac side branch is 8 mm, its length is 14 mm (118). It is attached to the leg at an angle of 30° (207). It is supported with a nitinol ring and Z stent of 6 mm diameter

which can be expanded to 8 mm. This allows a consistent and stable expansion. The orientation of the IIA limb which has a nitinol ring at its distal margin is identified by four gold markers on the medial side of the device. The distal landing zone is provided by the EIA. The distal diameters vary, measuring either 10 or 12 mm with lengths of 41 or 58 mm (118). There are four covered lengths of 86, 102, 103, and 119 mm.

The stiff ZBIS side branch is designed to prevent side branch occlusion by facilitating IIA cannulation and protection against collapse and kinking (65).

The iliac bifurcated endograft is commonly referenced as ZBIS-XX-YY-ZZ, where XX indicates the distal diameter, YY indicates the length of the common iliac segment (measured from the proximal margin of the endo-graft to the tip of the side branch), and ZZ indicates the length of the external iliac segment (measured from the tip of the side branch to the distal margin of the endo-graft) (118).

The H&L-B One-Shot platform (Cook) forms the basis for the delivery system. The device is fixed to the delivery catheter by a series of trigger wires, enabling maximum control during deployment. All of the introducer sheaths have an external diameter of 20F (7.7 mm). A preloaded through-lumen catheter, which eliminates the need to selectively catheterize the internal iliac side branch, represents an important advance in the design of the delivery catheter (Fig. 15) (118). The preloaded wire in the catheter may be exchanged for another wire, such as an exchange length J wire, before the IBD is introduced. This wire can be drawn from the contralateral side. Thus, an up-and-over sheath can be placed, thereby facilitating stent graft placement into the IIA (87).



Figure 15. *The preloaded through-lumen catheter is threaded from the delivery catheter into the internal iliac side branch, exiting out of the proximal end of the IBD to assist with cannulation of the internal iliac limb. Figure taken from Lee (118).*

A new type of balloon-expandable polyurethane-covered stent (Zenith Connection Endovascular Covered Stent, Cook) bridges the distance between the side branch and the IIA. The stent is premounted on a balloon catheter (Fig. 16) (118). Stents are available with diameters of 8, 9, and 10 mm and in lengths of 40 or 60 mm. The catheters are 80 mm in length and are 12F sheath-compatible. The minimum of nonaneurysmal (≤ 10 mm inner wall diameter) IIA required for use as the distal landing zone for the connection stent is 10 mm. However, longer lengths are preferable.




Figure 16. *Zenith Connection Endovascular Covered Stent. Figure taken from Lee (118).*

Overall, results have improved with the use of second-generation IBDs and stent grafts (eg., iCAST stents) compared to first-generation devices, as well as more experience and better understanding regarding the use of these devices (174). This is suggested by Ziegler et al. (235) who report a significantly higher patency rate with the use of later-generation devices.

As Wong et al. have summarized, the straight IBD (S-IBD or ZBIS) and the helical IBD (H-IBD) differ with regard to the length of overlap with the mating internal iliac stent grafts, the mechanism of directing flow into the branch, and (historically) the use of self-expanding rather than balloon-expandable stent grafts within the IIA (225). Deciding on a particular treatment option with respect to the IIA depends on each individual patient's situation.

Ferreira et al. (60) describe several advantages with the ZBIS over the H-IBD: the ZBIS graft is applicable to both sides, whereas the H-IBD has a right or left side choice. Furthermore, they were able to cover all of their 36 cases by using only two from the eight available ZBIS sizes. A second advantage was that the ZBIS is shorter than the H-IBD, making it possible to usually be entirely located inside the aneurysm sac, without compression risk, whereas the longer side branch of the H-IBD could partially be located along the CIA, with risk of compression depending on the aneurysm anatomy.

Third, they found that of 10 implanted H-IBD devices (one was lost due to iliac rupture before deployment), four occluded during follow-up compared with one within the 36 implanted ZBIS devices.

Bifurcated-bifurcated IBD

Neither the helical nor the straight iliac branch device can manage short CIAs unless two or more modular joints within the aneurysm sac are added, which may potentially destabilize the more proximal aortic repair. A third device has been created in response to this problem. It is the bifurcated-bifurcated iliac branch device (BB-IBD) (225).

The bifurcated-bifurcated IBD is the third, and most recent, type of IBD. Here, the helical branch IBD (H-IBD) is combined with the distal bifurcated component of a fenestrated device. The addition of the helical side-arm to the ipsilateral (long) limb of a bifurcated aortic device achieves the elimination of two modular joints from an IBD repair; however, it relegates access into the internal iliac branch to the brachial/axillary circulation.

A self-sealing fenestration immediately cranially to the ostium of the helical branch origin on the medial wall of the iliac limb was designed to counter this disadvantage. It is utilized together with a preloaded wire, which is snared in an identical fashion as with standard IBD devices. After completing the mating of the helical limb and removing the preloaded wire, the sealing segment (a covered Z-stent) that resides over the fenestration functionally excludes the aneurysm

(158). Since this design avoids the necessity for leg extensions to join with an aortic body, it is preferable for patients with shorter CIAs (225).

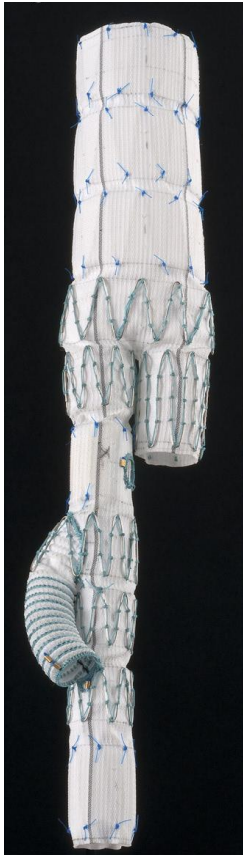

Figure 17. *The bifurcated-bifurcated IBD (BB-IBD). Figure taken from Oderich et al. (158).*

The newly-designed iliac branch stent graft (IBSG)

To counter the disadvantages of hitherto available branch iliac stent grafts used in western countries which are, as stated above, often not suitable for Asian patients because of shorter CIA, a newly-designed IBSG was introduced. In a study conducted to evaluate the usefulness of the IBSG in preserving the IIA during EVAR in Chinese patients, Zhang et al. described the novel device as “made of woven polyester, which is fully supported by a stainless steel Z-stent exoskeleton with gold markers for orientation and radiographic visualization. It includes mainly 2 types with the proximal diameter of 14 mm and 16 mm, respectively. The common iliac segments are 30, 90, or 120 mm in length, whereas the 30 mm one only matches the proximal diameter of 16 mm. The IIA side branch is 8 mm in diameter and 10 mm in length, supported by a Z stent and a nitinol ring that allows a consistent and stable expansion. The EIA serves as the distal landing zone, and the distal diameters vary from 10 to 12 mm with a uniform length of 28 mm. The totally covered length ranges from 58 to 148mm.” (233). In their patients, whose CIAs were usually relatively wide and short without extreme tortuosity, according to Zhang et al. it proved advantageous to “selectively advance the guidewire and sheath into the IIA from the contralateral or brachial approach”, since there was no preloaded catheter passing through the internal iliac segment included in the design of the ISBG. Zhang et al. (233) pointed out that the novel-designed IBSG allowed a “smaller 18F stentintroducer sheath to minimize access vessel traumatic injury and flexible operation” due to the fact that no preloaded catheter was necessary.

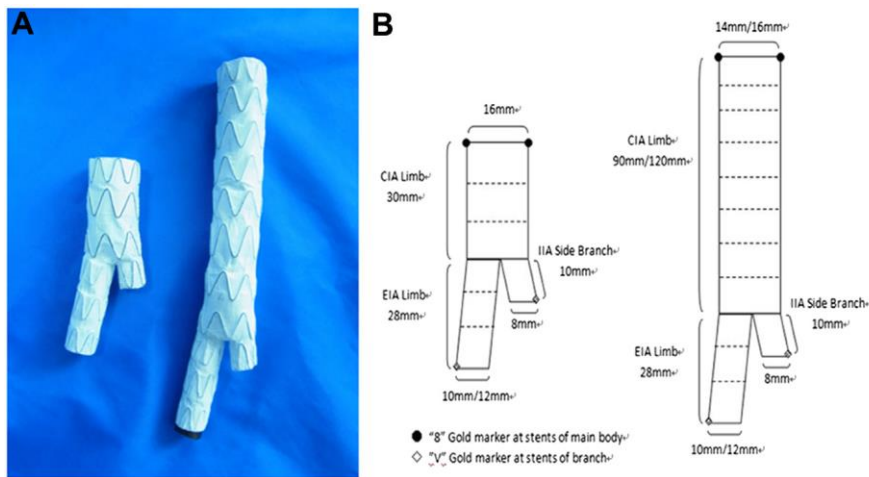


Figure 18. (A) Two types of novel-designed IBSGs with different length of common iliac trunks. (B) Schematic drawing of the IBSG proposed in the present study. Figure, illustration and explanations taken from Zhang et al. (233).

Zhang et al. relied on oversizing region of 10-25% to reduce the likelihood of proximal endoleaks. Having inserted the IBSG from the ipsilateral groin, they partially deployed it “until the side branch was released from the sheath. The wire was inserted from the contralateral femoral or brachial access and advanced, through a selective catheter, into the internal iliac trunk. An introducer sheath was placed anterogradely through the branch of the IBSG into IIA. A balloon-expandable stent graft (Jomed Stent graft; Abbott Vascular Devices, Rangendingen, Germany) was inserted and deployed to bridge the IBSG branch and IIA. Additional balloon-expandable stents or stent grafts were used selectively for reinforcement based on surgeon’s discretion.” (233).

Self-made (surgeon-modified) devices

Besides the devices described previously, a number of surgeon-made or surgeon-modified (intra-operatively) devices have been used.

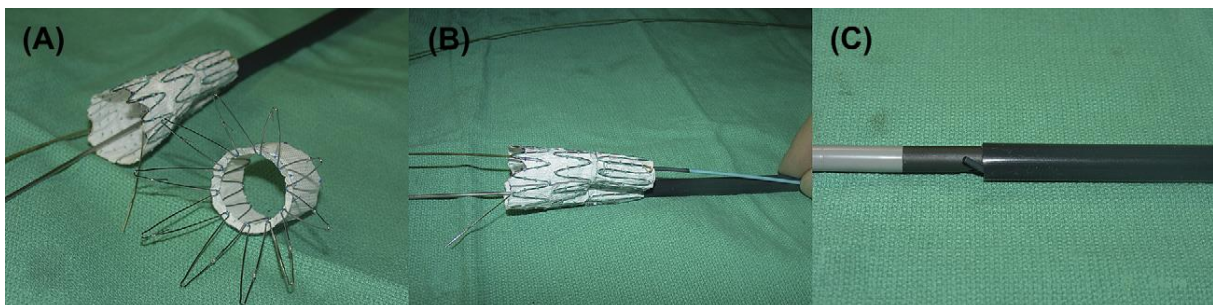


Figure 19. Device modification and placement of a preloaded wire and catheter. (A) Removal of the uncovered and proximal covered stents from the main body component. (B) Placement of a wire and catheter into the contralateral endograft limb. (C) Resheathed device with preloaded catheter and wire into a 22-F sheath. Figure and explanation taken from Riesenman et al. (187).

Riesenman et al. have described the configuration of a 22 x 74-mm bifurcated main body Zenith AAA endovascular graft (Cook) which was partially unsheathed to expose the contralateral limb. A modified bifurcated device of 54 mm length was produced by transecting the uncovered and proximal covered stents from the main body component by ophthalmologic cautery (Fig. 19, A) (187).

Oderich et al described three cases of IIA preservation using back-table modification of a bifurcated endograft. A surgeon-modified IIA branch stent graft was created using a 73 mm iliac stent graft limb with a pre-sewn 6-8 mm polyester side graft (159).

Using a bifurcated main body device obviates the need to construct a branched limb, involving only minimal or no device modification. Disadvantages are (as with any surgeon-modified grafts) the necessity of increased operating room time, fluoroscopy time, and contrast; considerable experience is needed to adequately modify the graft (159, 187). Brachial or axillary approach is often necessary to place bridging stent grafts into the IIA.

A recent new model presents a flexible side branch. Ferreira et al. have suggested that this model might augment overlap force and would be able to adapt better to cases in which the side branch is not precisely deployed in front of the IIA orifice. This is particularly promising, considering the variation of the IIA origin angle as well as the need for awkward fluoroscopy equipment positioning to visualize it (60).

Wu et al. reported on a new surgeon-modified commercial IBD and its flexible use in China: Based on the diameter of the EIA landing zone, they selected a 16 mm³ × 12 mm³ × 120 mm³ MicroPort iliac stent graft limb (MicroPort, Shanghai, China). They performed an elliptical graftotomy (at 45° oblique to the long axis) to the third stent about 30 mm from its proximal end in order to achieve a secure overlap of the limb extender. They then performed end-to-side anastomosis of a 7 mm expanded PTFE-vascular graft (Gore, Flagstaff, Arizona, USA) to the modified limb which had a bevelled cut end. A number of sutures were used to secure the strut of the arm graft helically to the iliac limb. The surgeons tailored the side arm to a length of 30 mm, sewing two metal markers at both ends of the graft arm for purposes of orientation. The device which was modified in this way was reloaded into a 22-F sheath (MicroPort, Shanghai, China) with no guidewire preloaded (227).

The GORE® EXCLUDER® iliac branch endoprosthesis (IBE)

A recently developed new device, the GORE® EXCLUDER® iliac branch endoprosthesis (IBE; W. L. Gore & Associates, Flagstaff, Ariz), was approved with the Conformité Européenne mark in November 2013 (217) and recently also by the US Food and Drug Administration; it is currently available on the market in Europe, Australia, and the USA, as well as through special access in Canada (151). According to van Sterkenburg et al., it combines the Excluder platform, on which it is based, with a dedicated internal iliac component (217). According to Millon et al., “the delivery profile of the loaded catheter allows the use a 16F introducer sheath for the iliac branch component, and a 12F flexible, reinforced introducer sheath for the internal iliac component. Then iliac branch component of the IBE has a proximal diameter of 23 mm, a length of 10 cm, and distal diameters of the external iliac leg of 10, 12, and 14.5 mm. The internal iliac component has a proximal diameter of 16 mm, a length of 7 cm, and distal diameters of 10, 12, and 14.5 mm. (Fig.20)” (143). The system necessitates bilateral femoral access. Positioning of the femorofemoral wire is followed by advancement of the IBE in the introducer sheath. The iliac branch component can be deployed above the aortic bifurcation; it can also be repositioned (143).

The device became commercially available only recently. Therefore, only early results have been reported and no mid-term results of the IBE had been published until the time of the present literature research.

Reporting on a single-institution cohort of 5 patients, Ferrer et al. cited a technical success and branch patency of 100 percent (61). In one of two bilateral cases, it became necessary to conduct “endovascular relining with bare stents ... due to compression of the iliac legs at the level of the aortic bifurcation” (61, 151).

Based on a study of the anatomic eligibility of 99 patients which used the anatomic inclusion and exclusion criteria of the 2 US pivotal trial (Cook IBD trial and Gore IBE trial), Pearce et al. reported that the Cook IBD trial was suitable for 18% (18/99) of patients, while 25% (25/99) of patients were eligible for the Gore IBE trial (143). Regarding Cook, the most frequent (in 68.7%, 68/99 of patients) exclusion factor was an internal iliac diameter measuring less than 6 or more than 9 mm. Exclusion from eligibility for Gore was most frequently (39/99, 39.4% of patients) due to a proximal common iliac diameter of <17 mm and in 37.3% of patients (37/99) by an inadequate IIA diameter smaller than 6.5 or larger than 13.5 mm. When compared across both Cook and Gore, 35.4% (35/99) of patients were anatomically eligible for AIAs treatment (167).

Van Sterkenburg et al. reported on a retrospective cohort analysis from thirteen sites in the Netherland, reviewing 51 common iliac artery aneurysms in 46 patients who were treated by IBE implantation. Primary patency of the internal component of the IBE at 6 months was reported at 94% (217). Millon et al. reported short-term patency at 1 year at 90% (143). Della Schiava et al. showed a success rate of 100% for IBE (43). They published a monocentric retrospective therapy study in which they compared the in vivo anatomical conformability of IBE and ZBIS stent grafts in 13 IBE and 9 ZBIS stent grafts. They reported that the IBE Gore branched iliac stent was more conformable than the ZBIS Cook in cases with severe iliac tortuosity, including iliac arteries with ≥ 1.14 tortuosity; the IBE was therefore better suited to reduce risk of thrombosis (43). Similarly, Ferrer et al. found that even difficult anatomical situations, including diseased EIAs, could be accommodated excellently by the Gore IBE due to its high conformability (61). According to Della Schiava et al., implanting a ZBIS stent graft shortened the total iliac length of 20.56 mm on average versus 9.77 mm for IBE stent grafts. They therefore concluded that using IBE could lead to a reduction in the occurrence of distal endoleaks without a higher danger of limb thrombosis related to the anatomical constraints (43).

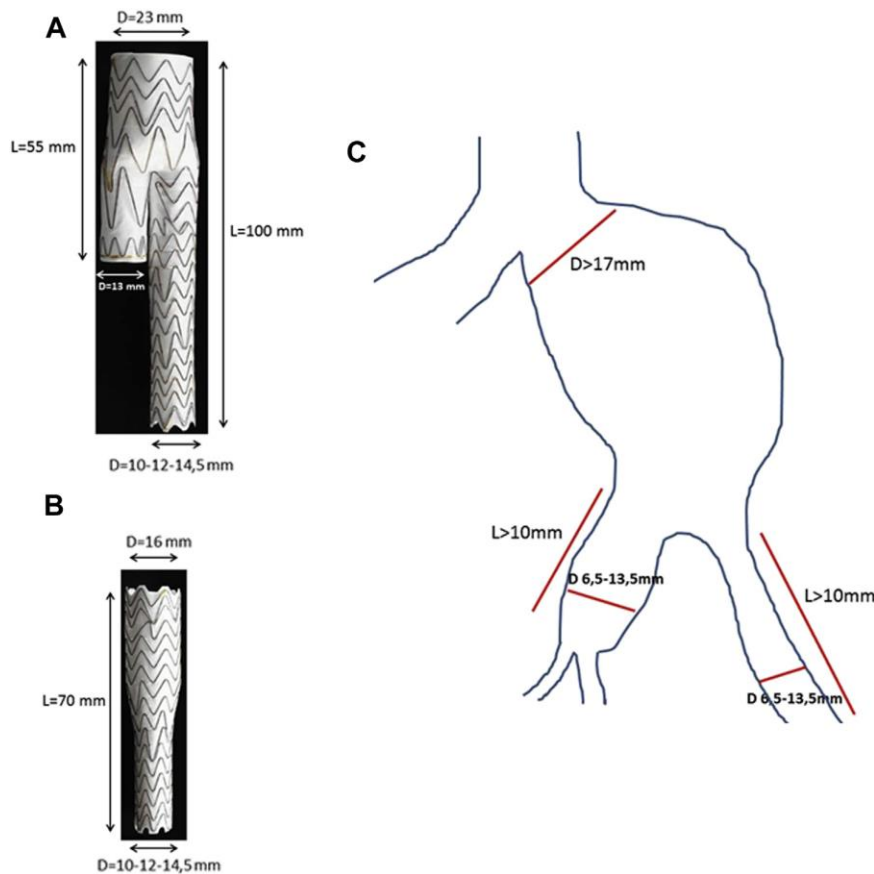


Figure 20. *GORE EXCLUDER IBE features and anatomic requirements. (A) Iliac branch component; (B) internal iliac component; (C) anatomic requirements. Figure, illustration and explanation quoted from Millon et al. (143).*

Explaining the anatomical limitations for using the Gore IBE, Pearce et al. (167) point out that a proximal CIA diameter of at least 17 mm is necessary to facilitate complete opening of the device. The nonaneurysmal distal sealing zone length should be at least 10 mm with a diameter of 6.5 to 13.5 mm (143, 167). According to Ferrer et al. (61), in cases where an extension is used, the diameter can range from 6.5 to 25 mm. In the case of Zenith® IBD, the CIA should be at least 40 mm long in order to allow for appropriate expansion of the device, but this is not a requirement for the Gore IBE. An additional limit of this device according to Millon et al. is the proximal diameter of 23 mm and the iliac branch component's length of 55 mm (from the proximal part to its end) because it does not allow for endovascular treatment of isolated iliac aneurysms with a proximal landing zone in the CIA (143). Due to the flexibility of the iliac branch component, the device can be deployed above the aortic bifurcation without difficulty when the introducer sheath is advanced inside for the internal iliac component, even in cases of short CIAs (61, 143). The length of the catheter of the internal iliac component makes a brachial approach impossible. Therefore, patients with previous aortic stent grafts cannot be treated by the Gore IBE (143). The “distance between the lowest renal artery and the iliac bifurcation” must measure at least 165 mm (217). The scope of the applicability of the device in tortuous arteries may be increased due to the dedicated IBE hypogastric component; but it is a limitation in short of aneurysmal IIA (61).

JOTEC E-liac Stent Graft

Recently, some studies have reported on the JOTEC E-Liac stent graft (JOTEC GmbH, Hechingen, Germany), a new iliac side-branched device (IBD) for revascularization of IIA. According to Mylonas et al., when compared to all other off-the-shelf devices currently available, this device has the widest range of proximal and distal diameters and lengths. They reported that the flexible stent graft design as well as the asymmetric spring configuration accommodate the vessel shape well. This meant that even in angulated anatomies, the risk of kinking was minimized while appropriate longitudinal stiffness was maintained (151). Mylonas et al. also found the 18 F delivery system adapted for crossover maneuvers easy to use. Using the JOTEC E-liac stent graft together with the E-ventus BX balloon-expandable connecting stent graft (JOTEC GmbH) offered, according to Mylonas et al., an advantage over self-expandable stent grafts that connect and seal into the IIA. Another advantage is the squeeze-to-release deployment mechanism which facilitates “stepwise or continuous release of the stent graft” while enabling “precise positioning and safe handling” (151). Assadian reported that it is possible to treat an even wider range of diseases: when CT scans were submitted, according to their experience specially designed, custom-made stent grafts based on the E-liac device were made available usually within 3 weeks of submitting the scans (6).



Figure 21. *Photograph of the unsheathed E-liac stent graft system. The nitinol skeleton is covered by woven polyester, which is sutured with braided polyester. The asymmetric tip-to-tip spring configuration allows good conformability to the vessel's shape, which minimizes the risk of kinking in angulated anatomies while maintaining appropriate longitudinal stiffness. (Courtesy Jotec GmbH, Hechingen, Germany.) Figure and explanations taken from Mylonas et al. (151)*

Evaluating the 1-year safety and efficacy of the JOTEC E-Liac, Mylonas et al. reported on a total of 70 patients who had been implanted with this device at six German vascular centers either as a stand-alone procedure or combined with AAA exclusion. Altogether, 82 IIAs were revascularized, 12 bilaterally. The technical success rate was 100% (82/82) of the revascularized IIAs. When a IIAA was present, an extension of the internal IBSG was successfully applied with an E-liac IBD into a divisional artery, such as the SGA. According to Mylonas et al., this may be an opportunity to gain an adequate distal landing zone (151).

IBD vs Coil

Verzini et al. (219) compared EVAR in patients with aneurysm iliac bifurcations who had received IIA revascularization with IBD and in patients with aneurysm iliac bifurcations treated

by IIA embolization. They found that, while technical success and reintervention rates were similar, endoleak and BC were more frequent in patients with IIA exclusion than in those with IIA revascularization, where they were uncommon (219). Even if side branch occlusion occurs when using IBD, in this case the outcome would be identical to that resulting from IIA embolization. This is an additional benefit of the IBD technique compared with embolization and covering of the origin of the IIA (219).

Self-expanding endografts vs. balloon expandable covered stents (BECS)

There are no systematic evaluations comparing the outcomes of using different types of IBD, such as self-expanding endografts and BECSs, as bridging stent grafts of the IIA. In the majority of the current literature, the use of self-expanding stents is recommended because of better flexibility and conformability (33). However, Donas et al. report that on the contrary, they used the BECS which they found to be characterized by high radial force and excellent fluoroscopic visibility, allowing precise placement. Their series showed an excellent patency rate (50).

One patient from the series of Donas et al., with coexistence of an IAA, presented with a ruptured 6-cm IIA, 2 years after the first placement of IBD (50). The ruptured IIA had been caused by dislocation of the two BECSs, resulting in endoleak type III and consecutive rupture. An enduring limb was placed at the origin of the IIA. A recannulation of the dislocated covered stents was not possible (7). Parlani et al. have also described disconnection of a BECS with a self-expanding covered stent in the IIA (162).

In another report, Donas et al. presented a pooled analysis of 8 single-center studies published between 2006 and 1 March 2012, “designed to determine the performance of self-expanding vs. balloon-expandable bridging stent-grafts used” in IBDs for the repair of IAA (49). Their report showed that it is not possible to draw clear conclusions about the performance of bridging endografts of IBDs from the current literature due to the heterogeneity of the studies. However, the report noted that bridging stent grafts showed a low occlusion rate, especially for balloon-expandable stent grafts compared to self-expanding devices (49). Apparently BECSs have better patency than self-expanding covered stents, particularly in the first 30 days. During follow-up, results between the two subgroups are equal. The largest store of experience in the literature with this covered stent pertains to the use of the flexible Viabahn self-expanding covered stent in the internal branch as bridging covered stent in combination with BECSs. Austermann et al. found a midterm patency of IBD of 100% (7). In contrast, their experience with the less flexible and likely-to-kink Fluency device as the most commonly deployed bridging covered stent in the literature (49) was described as disappointing, recording one occlusion in the one case in which it was used (7). Other authors describe a better outcome with this type of self-expanding covered stent (162, 207).

A further systematic evaluation of benefits and adverse outcomes of self-expanding endografts vs. BECSs is needed in future studies.

IBD-Technique

There are a number of preoperative planning issues to be considered which are specific for IBD. Preoperative planning of the device selection and preparations for the procedure are most important for a successful outcome (214). The use of 3D imaging reconstructions in preoperative planning to identify appropriate iliac artery lengths and diameters has been found to be essential for achieving persisting success of the IBD procedure (162), while the importance of the learning

curve to reach a result plateau for EVAR has been emphasized by several authors (62, 117, 124, 125).

Different techniques have been described for the insertion of the bridging stent graft. The first technique is found in early reports on the use of the IBD. Here, the guiding sheath is advanced only as far as the level of the side branch. With the aim to keep the crossover sheath in position, the indwelling wire is kept in place while a second guide wire is used alongside the first one for catheterization of the IIA and introduction of the bridging stent graft. However, this technique was in earlier cases associated with technical problems such as severe difficulty to advance the bridging stent graft inside the IIA, likely because of friction and/or entangling of the wires. When more force was used, the problem was not solved; rather, in several instances luxation of the crossover sheath even occurred (208).

Another technique, described by Tielliu et al. (208), involves using “tromboned sheaths (ie, a 7F ANL 1 inside a 10F Balkin sheath) for increased cross-over stability”, which “avoids problems associated with the use of parallel wires inside one sheath”. Moreover, they report that reducing the gap between the IBD and the IIA origin may make the position of the device more stable. This technique necessitates standard bilateral femoral artery access. Introduction of the 20F IBD is achieved through the ipsilateral femoral artery. The indwelling wire is snared from the contralateral femoral artery, to achieve a through-and-through crossover access. Following angiography, the body and side branch of the IBD are deployed, while the ipsilateral limb of the IBD is kept constrained inside the sheath (Fig. 22, left), permitting later repositioning if necessary. A 40 cm 10F flexor crossover guiding sheath (Balkin, William Cook Europe, Bjaeverskov, Denmark) is introduced over the aortic bifurcation and into the body of the IBD. Then a 55 cm 7F flexor guiding sheath (ANL 1, William Cook Europe) is advanced through the 10F sheath into the iliac side branch of the IBD. This “trombone” technique leads to a stable position to work with. The indwelling through-and-through wire can now be removed (Fig. 22, right). This technique has three major advantages. First, the iliac limb will naturally open up and face the orifice of the IIA. Second, it is possible to carefully retract the IBD over the two rails, thus reducing the gap and stabilizing the position of the IBD. Third, it is therefore possible to choose a much shorter bridging stent graft. With the graft in such a stable position, an overlap of about 1.5-2 cm and the same length inside the IIA will be sufficient, making it possible to avoid kinking of the balloon expandable and fairly stiff bridging stent graft as well as IIA occlusion. Following catheterization of the IIA, a stiffer wire (Amplatz super stiff, Cook Inc.) is inserted and the ANL 1 guiding sheath advanced inside the IIA. With the purpose of reducing the gap between the side branch and the orifice of the IIA, the IBD can be retracted over the two rails formed by the ANL 1 and the main introduction device (Fig. 23, left). Eventually, the ipsilateral limb of the IBD is deployed and the bridging stent graft introduced (Fig. 23, right). Crossing the gap between the side branch and the ostium of the IIA is achieved by deploying the bridging stent graft.

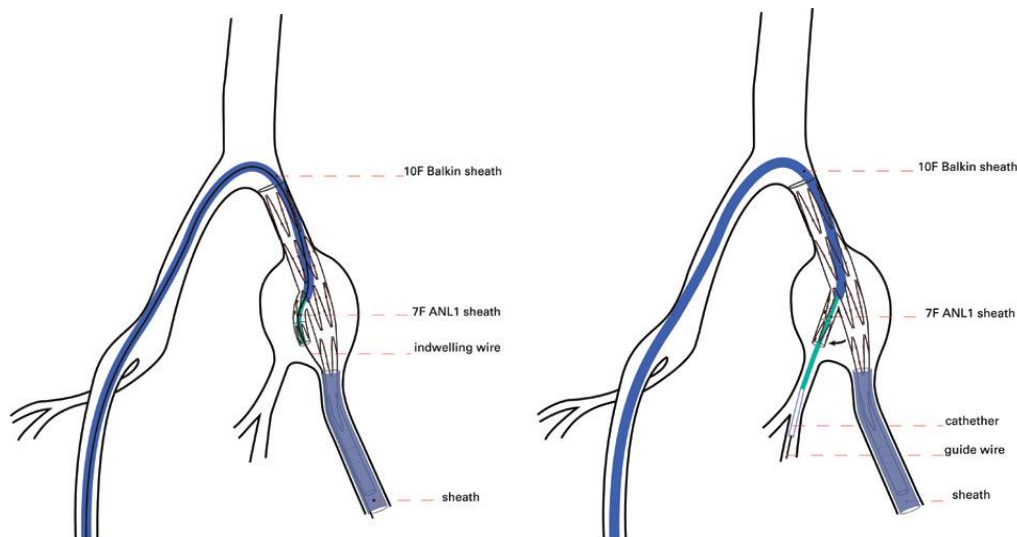


Figure 22. (left). Body and side branch of iliac branched device deployed. The ANL sheath is introduced inside the Balkin sheath (crossover “trombone” technique); (right). Indwelling wire removed. This opens up the iliac branch limb (black arrow). The ANL 1 sheath is advanced inside the IIA. Illustration and explanation quoted from Tielliu et al. (208).

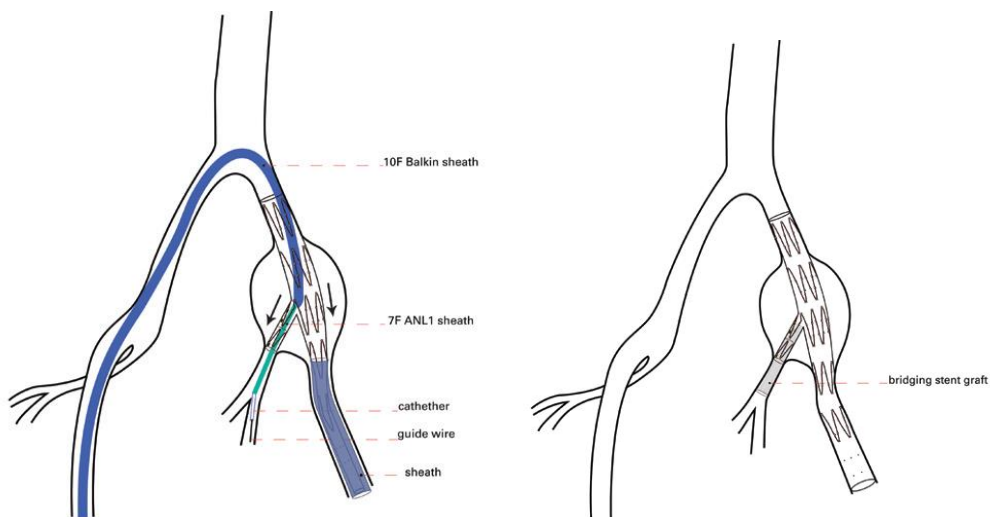


Figure 23. (left). IBD retracted (black arrows) over two rails (the ANL sheath and the main introduction device); (right) Ipsilateral limb of the IBD deployed and the bridging stent graft introduced and deployed. Illustration and explanation quoted from Tielliu et al. (208).

Nice et al. (155) describe a modified insertion technique where the IBG is inserted over prepositioned thoracic aortic and through-and-through iliac arterial guidewires. A 12-F sheath is placed on the side of the planned IBD; through this place, a stiff guidewire is placed in the thoracic aorta and a 260 cm hydrophilic wire and curved catheter combination are placed at the aortic bifurcation. Then, this combination of catheter and hydrophilic guidewire is advanced into the opposite iliac arterial system; the guidewire is directed into the tip of a 7-F sheath placed in the contralateral CFA. A further 6 F sheath and dilator is advanced into the 7 F vascular sheath beyond the flushing side port to act as a valvebreaker. The dilator is removed and the hydrophilic wire is advanced further, then the 6 F sheath is removed, leaving a through-and-through wire crossing the aortic bifurcation. The curved tip of the hydrophilic wire and magnified screening centered on the 7 F sheath tip facilitates this procedure which is usually quickly achieved according to the report. If a surgical cutdown has been performed, the possibilities for sheath

tilting or manipulation are enhanced, which may be helpful. After removal of the pre-loaded 260 cm hydrophilic wire from the IBD for use as the through-and-through wire and after 12 F sheath removal, the IBD is loaded onto both the stiff guidewire (through the nosecone) and the hydrophilic wire (through the pre-loaded catheter tip). Here, a crossing of the guidewires must be avoided. The IBD is then inserted. It may be difficult to avoid intra-arterial guidewire crossing. Careful rotation of the IBD, with screening control to determine the direction of rotation, resolves this difficulty. Deployment of the IBD is performed in accordance with the manufacturer's instructions. Delivery of a 12 F sheath from the opposite side into the IBD is enabled by the pre-positioned through-and-through iliac artery guidewire, facilitating IIA catheterization and sealing stent delivery.

Lee (118) describes a new approach to endovascular management of CIAA in the setting of endovascular aortic aneurysm repair by using an investigational (United States only) IBD.

Duffy et al. (52) describe a technique developed by Ferreira et al. where the preloaded guidewire is exchanged for a 260-cm-long Amplatz guidewire (Cook Inc): Here, the tip of the IBD delivery system is kept in the proximal iliac, positioning only the Amplatz guidewire tip at the aorta. This makes snaring easier, since the Amplatz is stiffer and stays stable at the aorta, facilitating its capture by the snare and, according to Ferreira et al.'s experience, also providing a smoother introduction of the contralateral sheath (Fig. 24).

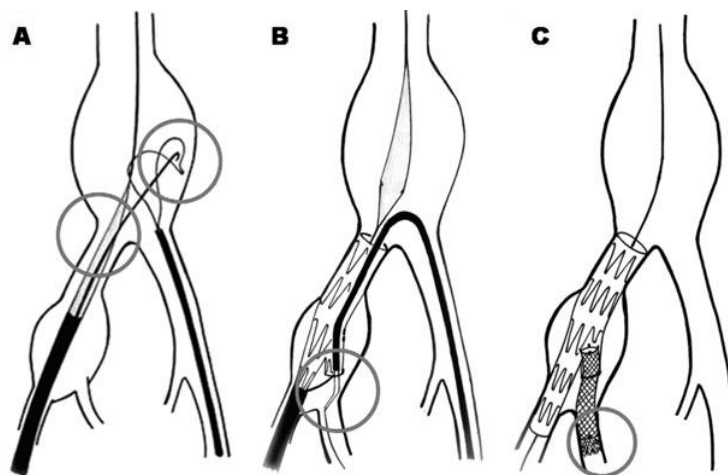


Figure 24. *Illustration of the technical variations. A: The main device tip is shown inside the iliac artery while the exchanged Amplatz wire is snared from the contralateral approach. B: The 12F sheath is in place with the Amplatz wire still in place. This wire will be removed only after the bridging stent is in place. C: The Fluency and the Zilver stent are both in place. The uncovered stent is implanted 1 cm forward into the IIA in relation to the first to avoid kinking. Illustration and explanation taken from Ferreira et al. (60).*

Staying closer to the original technique than Tielliu et al. (208), Ferreira et al. (60) use a technique that involves only retrieving the indwelling Amplatz wire, releasing the contralateral internal iliac branch, after the bridging stent is in place. The bridging stent graft used in all cases has a rather stiff deployment system, causing the sheath to jump out of the side branch during introduction over the aortic bifurcation. The current standard procedure used by Ferreira et al. comprises four procedural steps: First, a 12F Ansel1 Check Flo sheath (Cook Inc) is migrated over the through-and-through Amplatz while simultaneously deploying the IBD, to avoid malpositioning; second, the Check Flo valve is punctured in parallel to the Amplatz; a roadrunner guidewire and a 5F catheter are introduced to catheterize the IIA. To avoid

entangling of the parallel wires, the Amplatz must be maintained under tension during this step. Third, the necessary length for the bridging stent is measured with a centimetered pigtail, and the bridging stent graft is positioned. The curled tip of the pigtail is usually cut to facilitate this measurement from the main body to the first visible IIA branch, at least 2 cm inside the IIA. Fourth, the through-and-through Amplatz is retrieved and the bridging stent graft deployed with the bridging stent in position. An uncovered nitinol stent is deployed inside the bridging stent.

Since none of the available possible bridging stent grafts are resistant to kinking, Ferreira et al. have systematically deployed a self-expanding nitinol stent inside them, creating a high-radial-force, kink-resistant system. This uncovered stent is usually deployed 1 cm longer into the IIA. Chuter et al. (31) initially described this technique to avoid kinking in the visceral branches of the thoraco-abdominal branched stent grafts. In all cases, the Fluency Stent graft (C. R. Bard Inc, Tempe, Ariz) was the bridging stent used, and all patients received a Zilver (Cook Inc) stent inside the Fluency, permitting deployment of a longer bridging stent. While deployment of a short bridging stent could be an alternative option to avoid kinking, this step could raise the risk of a future leak if the IIA is not well sealed.

Bracale et al. (20) describe a modified technique for inserting a bridging stent graft during an IBD placement for an IAA for one patient who had previously received an aorto-bi-iliac surgical graft for a ruptured aneurysm. Ipsilateral access was used to introduce the 20 F IBD. The indwelling wire was snared from the contralateral access to achieve a through-and-through cross-over connection. It was subsequently attempted to advance a 55 cm 7 F Flexor sheath (William Cook Europe) through a 40 cm 10 F Flexor sheath (William Cook Europe), as previously described by Tiellu et al., into the iliac side branch of the IBD from the right access. However, this step was not successful because of the angle at the level of the anastomotic site. Due to this complication, it was decided to catheterize the IIA with a 4 F Cobra glidecath (Terumo Medical Corporation, Somerset, New Jersey, USA) and a soft wire, and then release the entire IBD. A new soft wire was inserted through the 10 F Flexor sheath parallel to the 7 F Flexor sheath and snared from the left access, making a wire-loop over the graft bifurcation. This approach made it possible to advance the 10 F sheath into the IBD with gentle traction on the wire loop. The Cobra catheter was advanced in a side branch of the IIA and the soft wire was exchanged for an extra-stiff Supracore wire (Abbott Vascular, Abbott Park, Illinois, USA). A 9 x 40 mm Fluency stent graft (Bard Peripheral Vascular Inc., Murray Hill, New Jersey, USA) was guided over the stiff wire. It was deployed to close the gap between the side branch of the IBD and the HA.

A similar case was described by Vourliotakis et al. (221) Here, an axillary surgical approach was necessary to create a “body floss” support for a safe implantation of the bridging stent graft in the IBD. Use of an axillary access can likely expand the application of the IBD in patients with tortuous anatomy. On the other hand, among the risks associated with placement of a 10–12 F sheath in this artery are vessel thrombosis or dissection as well as local wound complications. In addition, most device components do not entail available lengths accommodating axillary access (20).

IBD can be used not only as a therapy for CIAAs that develop after EVAR, as well as type Ib endoleak. It enables also contralateral cross-over access via a deflectable steerable guiding sheath (Destino REACH, OSCOR) facilitating antegrade access for a through-and-through wire via the neobifurcation of the main body following EVAR. Oberhuber et al. (157) reported about a patient who “developed a 4-cm iliac aneurysm 3 years after implantation of an Endurant bifurcated stent-graft”. This aneurysm was treated by insertion of IBD “using a steerable sheath which was advanced from the contralateral side over the neobifurcation of the bifurcated stent-graft. A 0.014-inch Roadrunner wire was used as a through-and-through wire to stabilize the curve of the sheath and to get proper push. The bridging stent-graft for the iliac branch was

advanced over this sheath to seal the iliac aneurysm. During the entire procedure, the sheath was stable over the neobifurcation without pulling it down.” (157).

Bellandi et al. (10) reported about IBD placement through a combined femoro-brachial approach three years after successful AAA stent graft placement.

Abraham et al. (1) reported about brachial access to a bifurcated iliac device. Secondary to a tight or calcified iliac bifurcation, or in cases where the common iliac component of the IBD is too long and the device protrudes into the distal aorta, placement of an up-and-over sheath may be impossible. In these cases, axillary or brachial access to the proximal part of the IBD may be used. Another scenario where placement of an up-and-over sheath is not possible is given when the IBD is used as an extension to a previous EVAR device. Brachial access may also be used in settings involving a combined placement of an IBD and coiling or other occlusion of the contralateral IIA. In this situation, proximal access permits access into both iliac systems. Sometimes, brachial access is also used to deploy the IIA stent graft into each IBD in case of bilateral IBD deployment (87).

In settings where the IBD is to be accessed from the arm, Huilgol et al. (88) report that while this site can be either axillary or high brachial, their preference is to use the left arm because in this way, manipulation of wires and devices across the supra-aortic trunk origins is minimized. The required sheath may be up to 10 Fr in diameter, and the size of the access artery must be sufficient to accommodate this sheath. For the brachial or axillary site, Huilgol et al. recommend cut-downs and direct closure. Pua et al. (174) find a high brachial access for deployment of the IBD to be very useful in two settings. First, it allows the sheaths to be sufficiently long to be manipulated into the IIA branch. Second, it is useful in cases of an extremely tortuous contralateral iliac artery, where not only the advancement of the deployment sheath may be hindered, but where the stent graft may be caused to be disconnected from its balloon within the sheath during advancement over the aortic bifurcation.

Serracino-Inglott et al. (196) describe one case of stented IIA occlusion. In this case the patient had had the stent sealing in the largest branch of the IIA after embolization of the other branches at a previous procedure due to an internal iliac aneurysm. According to Serracino-Inglott et al. (196), the combination of the smaller diameter of this vessel, when compared with normal IIA and the longer course of the covered stents to reach this vessel, may well have led to the occlusion, although its cause remains unclear. In order to achieve a seal with a stent graft, an adequate length of the landing zone in the IIA or one of its branches is required. A contraindication to the use of the IBD may be given if the IIA diameter exceeds that covered by currently available stent grafts (87). Karthikesalignam et al. (98) found a coexisting IIAA to be the most common limitation for IBD use. Because of persistent perfusion, placement of bridging stents in IIAA is associated with higher risk for dislocation and rupture of the aneurysm (50). Tielliu et al. (207) conclude that IIA larger than 10-12 mm should not be treated with this technique, except if the surgeon is prepared to advance the bridging stent graft into a main tributary of the IIA after coil embolization of the branches arising from the aneurysmal segment. In such anatomical conditions, they found that use of the rigid BECSs was characterized by a limited conformability. Donas et al. (50) have reported dislocation of the previously deployed BECSs in a huge IIAA (diameter of 6 cm) with consecutive rupture of the aneurysm.

Recently, the use of the IBD is opening new possibilities for treating patients with aorto-iliac or solitary iliac aneurysm with coexisting aneurysmal IIA. Thus, Austermann et al. (7) have recently (2013) presented the 2-year results of a novel technique of endovascular repair in patients with aortoiliac or solitary iliac aneurysms and coexisting IIAAs who had undergone placement of the IBD. The technical success rate was 100%, the primary patency rate was 95.3%. Austermann et al. describe their technique as follows: the initial step is the placement of

the IBD and catheterization of the posterior trunk of the IIA with the 0.035' Terumo wire via a vertebral catheter (Terumo Medical Corporation) (Fig. 25, A). After insertion of the vertebral catheter into the IIA, the Terumo wire is removed and catheterization of the posterior trunk via the atraumatic Rosen wire with the J-tip is attempted. The first used bridging covered stent for the internal branch is the balloon-expandable V12 iCast/ Advanta which will be preloaded in the 7F shuttle sheath extracorporeally and deployed in the internal branch. Stability at the origin of the internal branch is given by the proximal part of the stent graft; the distal part is normally in the middle of the IIAA. The covered stent most used by Austermann et al. is the 8-mm x 59-mm V12 iCast/Advanta covered stent (Fig. 25, B). Next, the 12F flexor sheath is advanced at the distal edge of the V12 bridging covered stent with synchronous deflation of the balloon of the covered stent (Fig. 25, C), permitting a safe advance of the 12F sheath without the risk of dislocation and crushing of the already deployed V12 stent. If other coexisting relevant branches (>6 mm diameter) originated from the IIAA, they were coiled with Tornado coils (Cook) or Amplatzer plug before the intervention (Fig. 25, D). Subsequently, the self-expanding covered stent (Viabahn; Gore, or Fluency; Bard) is advanced and deployed after retraction of the 12F sheath. Here, the 10 mm x 100 mm Viabahn was used in most cases.

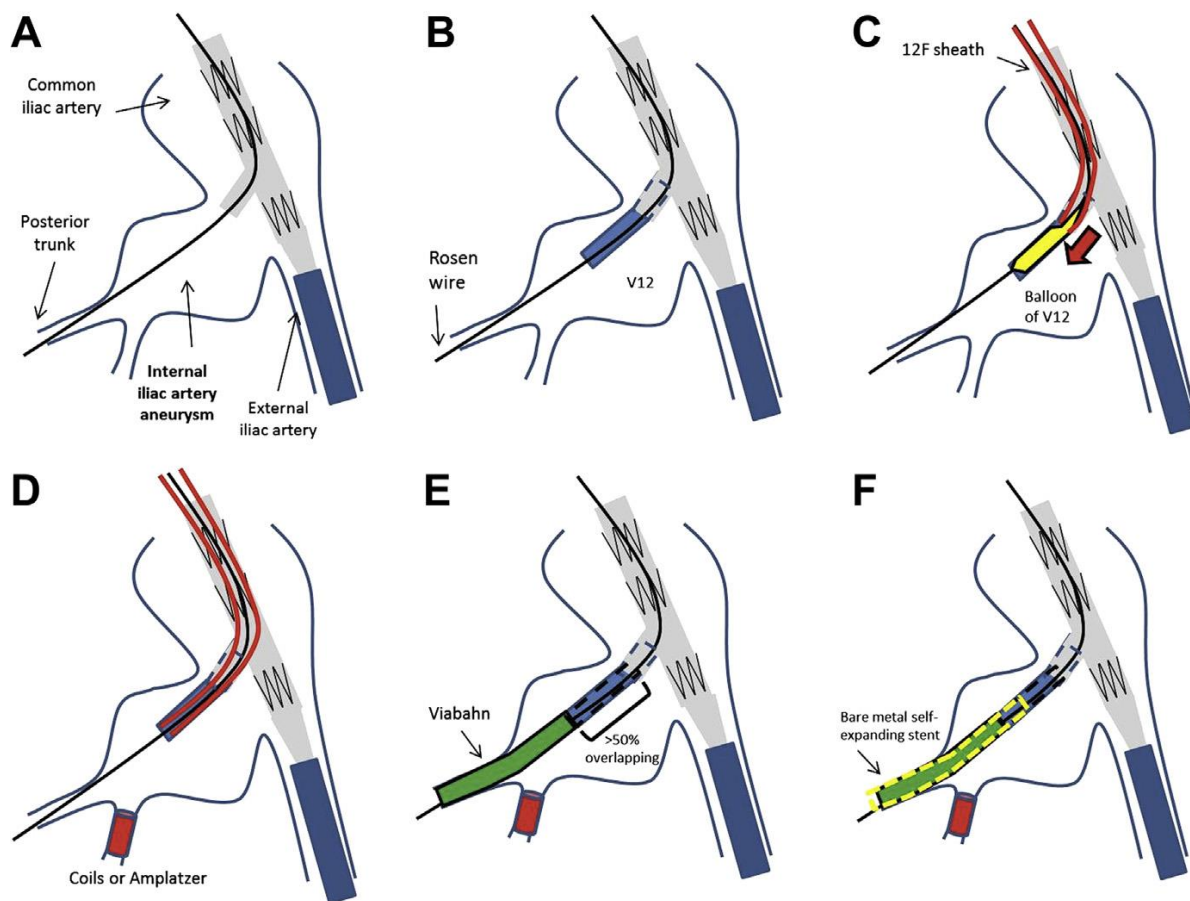


Figure 25. Sketch showing the technique of endovascular repair of aneurysmal IIAs using IBDs. Please note that now the guide wire is the Rosen wire (Cook), which is less traumatic due to the J-tip (Fig. 1-B). Illustration and explanation quoted from Austerman et al. (7).

Here, at least 50% overlapping with the previous deployed V12 covered stent is necessary, while the distal landing zone should be at least 2 cm (Fig. 25, E). In a final step, additional placement of a self-expanding bare metal stent (SMART; Cordis, Bridgewater, NJ, Zilver; Cook, or

Complete; Medtronic, Santa Rosa, Calif) into the covered stents (Fig. 25, F) is carried out with the aim of achieving a smooth transition of the stent grafts to the posterior trunk while simultaneously improving the fixation of the covered stents (7).

This approach offers three advantages. First, the origin of the IIA is stabilized due to the high radial force and precise placement of the BECS. Second, the adaptability and conformability of the covered stents in tortuous and kinked branches of the IIA is improved by the distal placement of the self-expanding covered stent. Third, fixation and smooth transition of the distal end of the covered stent is enhanced by placement of the bare metal self-expanding stent into the covered stents, resulting in successful exclusion of the aneurysms (7). The recent study published by Graham et al. (66) (n= 7) in 2013 also showed excellent short-term results (100%) of feasibility and efficacy of extension of IBD into the SGA.

In a series of 20 IIAAs in 15 patients, Noel-Lamy et al. reviewed their experiences of treating AIAs with concomitant IIAAs with extension of the IIA branch stent graft into the SGA. They described the first steps of implanting the IBG as resembling descriptions in the literature. Coil embolization was applied in cases where the size of the anterior IIA division made a type II endoleak appear likely (> 5 mm). This was followed by selection of the posterior division of the IIA and the SGA. A stent graft - in most cases Viabahn (Gore, Karlsruhe, Germany) for reasons of superior flexibility and easy delivery – was deployed over a stiff wire. Deployment was carried out from the SGA to the limb of the IBG. Oversizing of the stent graft by 10% with regard to the diameter of the SGA (pre-operatively measured on computed tomography angiogram with fluoroscopic confirmation). In cases where length of one stent graft was not suited for reaching the IBG side-branch, initial deployment of the distal stent was effected together with proximal deployment of a second stent graft (Viabahn or iCast). Stent grafts overlapped at least 2-3 cm. Length of the distal landing zone in the SGA was 2 cm or more. Distal deployment beyond the greater sciatic foramen was not carried out. In cases where the fluency stent was used in the SGA, more conformability and reduction of kinking was achieved by lining the graft with a self expanding bare metal stent (156).

It seems probable that in some cases, occlusion of the orifice of the IIA may have been caused by a tortuous ipsilateral CIA which kinked and occluded the orifice of the IIA when straightened by the IBG device, as shown by revisualization of the IIA with the device withdrawn. Therefore, cannulation and stent implantation of the IIA was not possible in these cases.

In ostial IIA lesions, an inability to visualize the IIA after insertion of the device delivery system resulted in initial technical failures. Here, Wong et al. (225) have described a modified implantation technique which involves snaring the preloaded wire from the contralateral groin, with drawing the delivery system caudal to the IIA origin, advancing an up-and-over sheath to allow cannulation and placement of a 6-mm balloon into the IIA origin via a second puncture in the sheath. The delivery system was re-advanced into position with the IIA balloon inflated. Following IBD deployment, removal of the balloon while leaving a wire marking the IIA origin. A third sheath puncture made it possible to introduce a steerable catheter-guidewire combination to cannulate the IIA from within the branch.

Tielliu et al. (207) reported about one case where difficulties were expected in catheterizing the IIA. They first positioned a wire using a cross-over approach in the IIA, with the aim of guiding the access and, if needed, to balloon or stent the orifice of the IIA.

In presence of a sharp bifurcation and iliac artery tortuosity, the crossover technique required for inserting the bridging stent graft between the branch of the IBD and the IIA becomes difficult. Furthermore, if the length of CIA < 5 cm, the IBG will stick out into the aorta, making the crossover technique impossible. In this situation, brachial access may be necessary (87, 207).

The possibility of severe tortuosity of EIA is another morphological feature that must be addressed. Its occurrence is more likely in AAAs with a large CIAA. In such scenarios, insertion of sheaths using a Lunderquist Extra Stiff Guide Wire (Cook Medical Inc., Bloomington, IN, USA) or application of the pullthrough technique to avoid iliac artery injury is needed (214).

Verzini et al. (219) have argued that any graft angulation (especially at the origin of the EIA) may be sufficient to provoke a later occlusion. They respond to this issue by confirming the absence of flow limitation by measuring the pressure gradient immediately above and below the graft curvature, and by liberally placing additional bare stents, if there is any suspicion of graft kink after removal of the guidewire at the end of the procedure.

It must be noted that the relative inflexibility of the distal part of the IBD in the EIA may lead to stenosis or occlusion of the IBD, especially in case of tortuous iliac arteries. To overcome this problem, Unno et al. have in three (3/6) cases used placement of an additional bare stent in the EIA to position the distal edge of the IBD parallel to the EIA wall (214).

With the purpose to increase the system's ability to track kinked anatomies, a new design, the Zenith flex with spiral-z technology iliac leg graft, was developed. With an inner diameter of <22F, this new low-profile device is expected to overcome heavily calcified and stenosed iliac arteries, thus increasing the applicability of the IBD (7).

In patients with solitary CIAA or aneurysms of the proximal IIA, it is possible to use the IBD without an EVAR device as long as there is a suitable sealing zone in the proximal CIA. Where necessary, a straight extension endograft can be used to bridge between CIA and the IBD (87).

It is possible to use the IBD with a main body device with scalloped or fenestrated proximal fixation. In case of fenestrated proximal fixation, the proximal aortic part of the device is deployed first in order to avoid passing access sheaths to the fenestrations through the IBD. Deployment of the IBD is next, followed by the distal aortic component and bridging stents as required (87).

It is possible to join the IBD to a main body EVAR device by a different manufacturer, for instance if faced with a narrow-diameter infrarenal aorta, or in a setting in which suprarenal fixation is either not required or not desirable (88).

Huilgol et al. (88) describe a number of techniques for bilateral IBDs. In the case of bilateral IBDs, where femoral access is the only option, the IBDs must be inserted before the main body EVAR device. Bridging stent grafts between this and the IBDs are inserted as required. Here, the choice of IIA stent graft and EVAR device will be influenced by the necessity to pass multiple sheaths, stents and a main body EVAR device through at least one of the IBDs, leading to an increased risk of crushing the fully deployed IBD.

For bilateral IBDs with proximal access, the main body EVAR device is introduced first. It is positioned and fully deployed with the long ipsilateral limb of the device orientated to the side of the longer CIA. Then, one IBD is inserted, unsheathed and cannulated from above with the wire passing into the IIA through the IIA branch. Huilgol et al. (88) observe that the indwelling wire will usually not be required, often making removal of this catheter and wire possible. The IIA stent graft is deployed; and the procedure is repeated for the other iliac system. Bridging stent grafts are deployed between the EVAR device and the IBDs. There should be no overlap of the CIA component of the IBD and the long limb of the EVAR device during the IBD deployment phase, because this may complicate cannulation of the proximal IBD. Here lies the disadvantage of the technique: according to Huilgol et al., if IBD cannulation is hampered by crowding in the area of the aortic bifurcation, it may become necessary to release the proximal trigger wire and to loosen the pin vise to permit advancement of the nose of the introducer, which will free up room for IBD cannulation (88).

Another option discussed by Huilgol et al. (88) are bilateral IBDs with proximal access and EVAR device introduced last where the first IBD is introduced and partly deployed until opening of the IIA branch. This is followed by cannulation of the IIA branch from above and deployment of the IIA stent graft. Often, the preloaded wire and IBD catheter will not be required and can be removed. The remainder of the IBD is deployed and the introducer retrieved. A similar procedure is carried out for introducing and deploying the second IBD. This is followed by introduction of the main body EVAR device on the most suitable side and bridging stent grafts between the EVAR device and the IBDs are used as required.

When planning this procedure, the CIA component of the IBD may be slightly longer than the CIA, enabling cannulation of the proximal IBD from above if the CIA component protrudes into the aorta. If the cannulation is carried out from the contralateral side, the CIA limb of the IBD cannot be longer than the CIA, because it is impossible to pass an up-and-over sheath into the IBD if its proximal end is positioned above the aortic bifurcation. Since this option requires passage of an EVAR main body through a fully deployed IBD, the choice of IIA stent graft may be influenced accordingly (88).

The passage of large introducers and sheaths through fully deployed IBDs may be required for bilateral IBD placement, thus increasing the chance of crushing the IIA stent graft. However, this risk is lowered by using self-expanding stent grafts for the IIA. It is an option to use a combination of a nitinol stent graft lined with a bare metal self-expanding stent for the IIA (183).

IBD advantages

An advantage of the IBD over other branched endografting techniques is the generous device overlap in an area of relative anatomical fixation. Compared to all other forms of branched EVAR, the IBD thus has the greatest potential of long-term durability (87). As the IBD facilitates the extension of repairs from healthy arteries proximally to healthy arteries distally, in contrast to (potentially) snorkels, sandwiches, or BBTs, it does not compromise the sealing zone within the CIA (76, 77, 162, 225).

Most IBD devices are commercially available off-the-shelf devices which do not need to be customized; they can be mated with devices known as effective in AAA management.

With greater experience regarding IBD implantation, the ability to treat more complex situations increases noticeably. This clear learning curve should be used to advantage to train, through IBD placement, for using more complex branched devices; thus, Wong et al. advise to gather experience with branch endografting techniques from IBD procedures, where occlusion generally results in claudication, and endoleaks are easily treated by branch ostium coverage, and not in other settings where the consequences of failure are much more serious (225).

Overall, the risk of late occlusions because of graft kinkings at the level of iliac tortuosities must be seen as the weak point of all endograft landings into the EIA (219).

Availability of IBD

In the last decade, IBD has been used mainly in Europe (65), Australia, and Latin America. They have been used only in a limited number of patients in Japan and the USA.

In the USA, ZBIS and H-IBD devices are not commercially available in the market since they have so far been approved for investigational use only (clinical trials are ongoing) (27, 38, 174). It has been predicted that the dissemination of these devices may be limited in certain practice

environment, since the costs associated with the research and development of such devices will likely be transferred to the consumer (46).

In Japan, a wider-ranging application of these devices has been limited for cost reasons, since until the time of writing it is not covered by the national insurance program in Japan. In some cases, privately imported IBD have been used (101, 214). However, the number of patients undergoing EVAR has increased considerably since 2007, when the Japanese government approved a commercial device for this use (74).

Cost Efficiency

Cost efficiency regarding EVAR is a pertinent issue. Compared to open AAA repair, EVAR is associated with greater expense (14, 18, 142, 172, 204). At present, extension into the external iliac with ipsilateral IIA embolization is the simplest alternative. Embolization involves sacrificing the IIA, but this technique is relatively low-cost, since it adds approximately 470 US \$ to 500 (ca. 350 to 370 Euro) to the cost of EVAR (185, 216).

The ST using two Viabahn stent grafts will probably cause an additional cost of at least 3,000 to 3,500 US \$ (ca. 2,200-2,600 Euro). It necessitates a bridge cover stent to IIA, an aortic bifurcated stent graft (main body and contralateral iliac limb) and one iliac extension for each IIA endorevascularization. However, it is a more economical option than IBD (124).

The trifurcated endograft technique for IIA preservation (144), requiring two main body stent grafts, and the branched iliac stent graft, requiring an IBD, an aortic bifurcated Zenith stent graft (Cook Inc, Bloomington, Ind), and other subsidiary endovascular devices (124), are expensive options.

IBD is certainly a high-cost technique. The use of Zenith Bifurcated Iliac Side (ZBIS) device (Cook Inc., Bloomington, IN) costs 6000 US \$ in addition to the cost of standard EVAR with the Zenith endograft, excluding the additional cost of the bridging stent (65, 97). Use of ancillary and bridging stents increases the cost (142). IBD has beneficial effects for reducing the consequences of pelvic ischemia, particularly in young patients, but cost-analysis models must be taken into consideration as part of a comprehensive assessment (30).

Perspectives for the future

Future research should enable a clearer identification of patients with high risk of developing complications (such as branch occlusion, occurrence of endoleak) after IBD treatment. Chowdhury et al. (30) have called for the creation of a risk stratification patient selection tool which would be aided by development of international registries and compilation of comparative studies. In addition to this, anatomical assessment of the iliac systems on the one hand will be aided by imaging which will also be a valuable tool for assessing the proportion of patients who would be morphologically suited for treatment with IBD, since not all patients suffering from aortoiliac aneurysmal disease may be well-suited for IBD treatment.

Concerning future research, Chowdhury et al. (30) have called for a definition of complications after IBD insertion which is largely still lacking in the current literature. While the development of endoleak following IIA embolization, for instance, is included in the standardized reporting criteria after EVAR, no reported standard complications were reported following IBD insertion (28). Quantification of a number of complications is therefore difficult. An example is erectile dysfunction, which could be objectively measured using the penile-brachial pressure index (174, 219).

Chowdhury et al. (30) have pointed out that only one study clearly compares patients with EVAR with revascularization of the internal iliac with IBD versus IIA embolization (219). Systematic comparisons of the differences in patency, endoleak, and reintervention rates in the variant configurations of IBD are still lacking in the literature; standardized evaluations regarding the use of Fluency and Atrium stent grafts in conjunction with different types of IBD should also be addressed in further studies to assess the best possible combinations (30).

Since, as Deaton et al. and Mehta et al. (41, 139) showed endoleaks constituted a major challenge, Loth et al. suggested that “a sealing ring filled with polymer between the vessel wall and the prosthesis or deploying endovascular staples to fix the prosthesis to the vessel” might be a useful modification to reduce the risk of endoleaks. They also advocated the development of improved bridging stent grafts, optimized with regard to flexibility and kink resistance, designed with the purpose to be combined with these IBDs in the internal ilial artery. The improved design would accommodate steeper angles of the IIA as well as radial force (128).

A further desideratum for future studies is the inclusion of nontechnical outcomes during longer term follow-up, such as quality of life, cost effectiveness of IBD use, and activities of daily life which have heretofore hardly, if at all, been considered in comparative studies on IBD (30).

Comparing the available data about outcomes of the H-IBD device compared to the ZBIS device, it is difficult to determine clearly which impact, if any, device design (helical vs. a straight IIA branch) might have on the proportional occurrence of branch occlusion (87). To date, it seems that surgeons’ preference is the main distinguishing factor. Future studies should address this issue more systematically.

Difficulties are currently associated with the deployment of IBD in patients with small normal caliber or stenotic CIA bifurcations (diameter < 18 mm) or with iliac tortuosity. Improved design toward more flexible and smaller-profile devices might help to address these problems (174).

It has been suggested that concomitant IIAA with acute enteric fistula caused by the aneurysm’s rupture and dislocation of the covered stent in the IIA might be a contraindication for IBD placement; however, further studies are needed to gather more evidence in this regard (50). The relation between IBD and the dissections which may potentially occur, and the impact of the presence of IBD on the development of these complications, must also be investigated more systematically in future studies (177).

Further directions to be explored include the question if IBD might be effectively applied in isolated IIAA, or if IBD emergency repair will be feasible in the future. Another question is whether sonography with contrast agent might replace CT in follow-up? Another issue is the improvement of the learning curve regarding IBD use.

Further studies are also needed to quantify muscle ischemia, such as CPK level measurements. There is currently no intraoperative monitoring method which helps in assessing pelvic perfusion at IIA sacrifice by embolization during EVAR. Unno et al. have used near-infrared spectroscopy (NIRS), and pulse-volume plethysmography for measuring the penile brachial pressure index (PBI) during EVAR to assess buttock circulation (92, 212). Yet with their monitoring method one cannot identify patients who truly require IIA antegrade flow, since the IBD must be deployed before placement of the aorto-iliac stent graft. Here, an alternative approach is needed and should be developed in the future.

V. Conclusion

The feasibility of EVAR in the presence of unsuitable CIA has been a focus of research published over the past decade. A range of different techniques has been described to preserve IIA perfusion or to occlude IIAs.

In conclusion, the present study shows that the use of IBD is an excellent option for avoiding IIA occlusion. This agrees with the findings on technical feasibility and excellent results of using IBDs published in the current literature.

The technical success rate of IBDs is high, and good medium-term patency of IIA has been demonstrated in selected patients. On the downside, the use of IBD is subject to a range of anatomic restrictions. Its performance requires a highly skilled and trained endovascular team. Furthermore, as a relatively high-cost procedure, it adds to the cost and complexity of aorto-iliac EVAR, which must be weighed against the possible consequences of IIA occlusion. While IBDs are commercially available for general use in the European, Latin American and Australian markets, this is not the case in other regions such as the USA and Japan.

Until the time of writing, there is no sufficient standardization regarding the appropriate management of CIAA; in order to better identify those patients who will likely benefit most from EVAR involving IBD, a more systematic risk stratification as well as more systematic morphological data are a desideratum. To improve our understanding of the role and significance of IBD for treating AIAs and to contribute to improved device designs in the future, more systematic studies about long-term patency and durability are necessary.

VI. Summary

The objective of this study was to contribute to the evaluation of endovascular therapy (EVAR) of aortoiliac aneurysms (AIA) by using iliac side-branch device (Zenith bifurcated iliac side-branch ZBIS, COOK).

Occlusion of the internal iliac artery (IIA) due to embolisation or stent graft extension to the external iliac artery (EIA) may cause complications such as buttock claudication (BC), erectile dysfunction, and more rarely, gluteal necrosis, colon or spinal ischaemia, or other disorders. This has typically limited the indication for endovascular therapy of aortoiliac aneurysms if the antegrade flow of both pelvic arteries is to be preserved. Until recently, the indication for endovascular treatment of aortoiliac aneurysms was considered to be limited. As Karthikesalingam et al. (97) observed, “aortoiliac aneurysms comprise up to 43% of the specialist endovascular caseload. In such cases endovascular aneurysm repair (EVAR) requires distal extension of the aortoiliac endograft beyond the ostium of the internal iliac artery (IIA) and into the EIA, conventionally necessitating the embolisation of one or both IIAs. This has been associated with a wide range of complications, and the use of an iliac branch-graft device (IBD) offers an appealing endovascular solution.” Recently, the use of bifurcated iliac endograft, the iliac side branch device (IBD), presents an alternative to avoid these problems and to broaden the indication for endovascular therapy of aortoiliac aneurysms.

This study presented a retrospective analysis of prospectively collected data from a single-center series reviewing 39 consecutive patients who were treated at Franziskus-Krankenhaus, Berlin, between October 2007 and July 2014, with pure endovascular therapy of aortoiliac aneurysms by using the ZBIS systems (COOK). Additionally, a systematic literature review of studies published in English until January 2016 was conducted with the aim of analyzing the results of endovascular treatment of aortoiliac aneurysms with iliac stent grafts with side branches (Iliac side-branch ZBIS or Helical Graft, COOK) as a basis for comparison with the presented series.

38 of the 39 patients were male (97.43%). Mean age was 67.43 years (range 56-86 years). Baseline median diameter of all treated CIAA was 36.31 mm (range 21-62 mm), a further criterion for inclusion was the morphological suitability of aneurysms for EVAR, including implantation of a ZBIS system, based on a multislice spiral CT. Overall, total endovascular treatment was carried out in 34 abdominal aortic aneurysm (AAA) >35 mm of which 1 was a juxtarenal AAA; 3 aorta ectasias; 1 patient had previously received EVAR; 1 normal aorta without aneurysm; 21 CIAA right side, 8 CIAA left side, 10 CIAA both sides, 5 internal iliac artery aneurysms (IIAA) right side and 4 IIAA left side. All in all, 48 ZBIS systems were implanted. In one case, the patient received coil embolization on one side, and IBD on the other side.

Mean IBD follow-up was 34.74 months (range, 1-81). Patients were reviewed clinically and by CT before discharge, after 6, 12, 18 and 24 months, and at least annually after that.

Initial technical success in our series was 92.3 % (36 of 39) for all patients and 93.75% per vessel (45 of 48), compared to technical success rates per vessel reported in the published literature which varied between 69% and 100% for all IBD forms currently in use.

In our series, one patient failure was due to a proximal endoleak type I. In one other case, the insertion of the catheter was not possible due to a high-grade stenosis of the ostium of the IIA. In the third case, it was impossible to insert the Advanta stent graft to seal the IIA trunk. In only one case, balloon-expandable stent graft systems (Bentley, InnoMed) was used for bridging the distance between the side branch and the IAA. In all other patients, the balloon-expandable stent graft (Advanta V12, Atrium) was used. One endoleak type I and one endoleak type III were

recorded (5.12%) and successfully managed. Besides these two intra-operatively unsuccessful cases, two occlusions of internal limbs of IBD occurred after 24 months and one after 41 months, leading to a mid-term clinical success (6 months – 5 years) of 89.74% for all patients. One of the patients with occluded IBD (20%) and a patent IIA contralaterally showed clinical evidence of light buttock claudication ipsilaterally. Only one patient was lost after 2 years, due to sepsis following chemotherapy. No aneurysm rupture occurred.

The results indicate that the antegrade flow of pelvic arteries can almost always be preserved with EVAR, including effective therapy of common iliac artery aneurysms and internal iliac artery aneurysms by using the ZBIS system (COOK). This is consistent with the findings on technical feasibility and excellent results of using IBDs published in the reviewed literature.

VII. Appendix

VII.1 List of Abbreviations

AAA	abdominal aortic aneurysm
AIA	aorto-iliac aneurysm
ASD	atrial septal defect
AUI	aorto-uni-iliac
AVF	arteriovenous fistula
BB-IBD	bifurcated-bifurcated iliac side branch device
BBT	bell-bottom technique
BC	buttock claudication
BCIAA	bilateral common iliac artery aneurysms
BECS	balloon-expandable covered stent
CFA	common femoral artery
CI	colonic ischemia
CIA	common iliac artery
CIAA	common iliac artery aneurysm
CPK	creatine phosphokinase
CT	computed tomography
DSA	digital subtraction angiography
EIA	external iliac artery
EIAA	external iliac artery aneurysm
EVAR	endovascular aneurysm repair
EVAS	endovascular aneurysm sealing
Fr	French scale or French gauge
H-IBD	helical iliac side branch device
IAA	iliac artery aneurysm
IBD	iliac side branch device
IBE	iliac branch endoprosthesis
IBG	iliac branch graft
IBSG	iliac branch stent graft
ICU	intensive care unit
IIA	internal iliac artery
IIAA	internal iliac artery aneurysm
ILE	iliac leg endograft
IMA	inferior mesenteric artery
ITA	intraoperative transluminal angioplasty
NIRS	near-infrared spectroscopy
OR	open repair
PBI	penile brachial pressure index
PG-EVAR	parallel graft endovascular aneurysm repair
PTA	percutaneous transluminal angioplasty
SE	standard error
SECS	self-expandable covered stent
SGA	superior gluteal artery
S-IBD	straight-branch iliac bifurcation device
ST	sandwich technique

TPEG	transluminal placed endovascular graft
VSD	ventricular septal defect
WIQ	walking impairment questionnaire
ZBIS	Zenith bifurcated iliac side branch

VIII. References

1. Abraham CZ, Reilly LM, Schneider DB, Dwyer S, Sawhney R, Messina LM, Chuter TA. A modular multi-branched system for endovascular repair of bilateral common iliac artery aneurysms. *J Endovasc Ther* 2003;10:203-207.
2. Albertini JN, Favre JP, Bouziane Z, Haase C, Nourissat G, Barral X. Aneurysmal extension to the iliac bifurcation increases the risk of complications and secondary procedures after endovascular repair of abdominal aortic aneurysms. *Ann Vasc Surg* 2010;24:663-669.
3. Antoniou GA, Harrison GJ, Neequaye S, McWilliams RG, Torella F, Fisher RK. Aortic dehiscence during endovascular sealing for ruptured abdominal aortic aneurysms. *J Endovasc Ther*. 2015;22(5):806-809.
4. Arko FR, Lee WA, Hill BB, Fogarty TJ, Zarins CK. Hypogastric artery bypass to preserve pelvic circulation: improved outcome following endovascular abdominal aortic aneurysm repair. *J Vasc Surg* 2004;39:404-408.
5. Armon MP, Wenham PW, Whitaker SC, Gregson RH, Hopkinson BR. Common iliac artery aneurysms in patients with abdominal aortic aneurysm. *Eur J Vasc Endovasc Surg* 1998;15:255-257.
6. Assadian A. Iliac Side Branches for the Treatment of Iliac and Aortoiliac Aneurysms. *Endovascular today europe* 2015;3(7):24-25.
7. Austermann M, Bisdas T, Torsello G, Bosiers MJ, Lazaridis K, Donas KP. Outcomes of a novel technique of endovascular repair of aneurysmal internal iliac arteries using iliac branch devices. *J Vasc Surg* 2013;58:1186-1191.
8. Ayerdi J, McLafferty RB, Solis MM, Teruya T, Danetz JS, Parra JR, Gruneiro LA, Ramsey DE, Hodgson KJ. Retrograde endovascular hypogastric artery preservation (REHAP) and aortouniliac (AUI) endografting in the management of complex aortoiliac aneurysms. *Ann Vasc Surg* 2003;17:329-334.
9. Becquemin JP, Majewski M, Fermani N, Marzelle J, Desgrandes P, Allaire E, Roudot-Thoraval F. Colon ischemia following abdominal aortic aneurysm repair in the era of endovascular abdominal aortic repair. *J Vasc Surg* 2008;47(2):258-263.
10. Bellandi G, Ventoruzzo G. Endovascular Bilateral Evolutive Common Iliac Artery Aneurysm Repair Using a Zenith Branch Graft Through a Combined Femoro-Brachial Approach in a Patient with Previous EVAR. *Eur J Vasc Endovasc Surg* 2010;40:596-598.
11. Berg P, Kaufmann D, van Marrewijk CJ, Buth J. Spinal cord ischaemia after stent-graft treatment for infra-renal abdominal aortic aneurysms. Analysis of the Eurostar database. *Eur J Vasc Endovasc Surg* 2001;22:342-347.
12. Bergamini TM, Rachel ES, Kinney EV, Jung MT, Kaebnick HW, Mitchell RA. External iliac artery-to-internal iliac artery endograft: a novel approach to preserve pelvic inflow in aortoiliac stent grafting. *J Vasc Surg* 2002;35:120-124.
13. Bisdas T, Weiss K, Donas KP, Schwindt A, Torsello G, Austermann M. Use of iliac branch devices for endovascular repair of aneurysmal distal seal zones after EVAR. *J Endovasc Ther* 2014;21(4):579-586.
14. Blackhouse G, Hopkins R, Bowen JM, De Rose G, Novick T, Tarride JE, O'Reilly D, Xie F, Goeree R. A cost-effectiveness model comparing endovascular repair to open surgical repair of abdominal aortic aneurysms in Canada. *Value Health* 2009;12:245-252.

15. Böckler D, Schumacher H, Burger U, Tengg-Kobligk H, Ockert S, Allenberg JR. Chirurgisches Management des isolierten Beckenarterienaneurysmas. *Zentralbl Chir* 2006;131:18-24.
16. Böckler D, Holden A, Thompson M, Hayes P, Krievins D, de Vries JP, Reijnen MM. Multicenter nellix endovascular aneurysm sealing system experience in aneurysm sac sealing. *J Vasc Surg*. *J Vasc Surg* 2015;62:290-298.
17. Boersen JT, Schuurmann RCL, Slump CH, van den Heuvel DAF, Reijnen MMPJ, ter Mors TG, Vahl AC, de Vries JPPM. Changes in aortoiliac anatomy after elective treatment of infrarenal abdominal aortic aneurysms with a sac anchoring endoprosthesis. *Eur J Vasc Endovasc Surg* 2016;51,56-62.
18. Bosch JL, Kaufman JA, Beinfeld MT, Adriaensen ME, Brewster DC, Gazelle GS. Abdominal aortic aneurysms: cost-effectiveness of elective endovascular and open surgical repair. *Radiology* 2002;225:337-344.
19. Bowman JN, Silverberg D, Ellozy S, Teodorescu V, Poblete H, Marin M, Faries P. The role of anatomic factors in predicting success of endovascular repair of thoracic aortic aneurysms. *Vasc Endovascular Surg* 2010;44:101-104.
20. Bracale UM, Narese D, Vitale G, Maglione F, Conti PO, Bajardi G. A wire-loop technique for implantation of an iliac branched device in a patient with previous surgery for a ruptured abdominal aortic aneurysm. *Diagnostic and Interventional Radiology* 2013;19:73-75.
21. Bratby MJ, Munneke GM, Belli AM, Loosemore TM, Loftus I, Thompson MM. How safe is bilateral internal iliac artery embolization prior to EVAR? *Cardiovasc Intervent Radiol* 2008;31:246-253.
22. Brownrigg JRW, de Bruin JL, Rossi L, Karthikesalingam A, Patterson B, Holt PJ, Hinchliffe RH, Morgan R, Loftus IM, Thompson MM. Endovascular Aneurysm Sealing for Infrarenal Abdominal Aortic Aneurysms: 30-Day Outcomes of 105 Patients in a Single Centre. *Eur J Vasc Endovasc Surg* 2015;50,157-164.
23. Brunkwall J, Hauksson H, Bengtsson H, Bergqvist D, Takolander R, Bergentz SE. Solitary aneurysms of the iliac arterial system: an estimate of their frequency of occurrence. *J Vasc Surg* 1989; 10: 381-384.
24. Burchell RC, Mengert WF. Internal iliac artery ligation: a series of 200 patients. *Am J Obstet Gynecol* 1966;94:117-124.
25. Bush RL, Johnson ML, Collins TC, Henderson WG, Khuri SF, Yu HJ, Lin PH, Lumsden AB, Ashton CM. Open versus endovascular abdominal aortic aneurysm repair in VA hospitals. *J Am Coll Surg* 2006;202:577-587.
26. Cambria RP, Clouse WD, Davison JK, Dunn PF, Corey M, Dorer D. Thoracoabdominal aneurysm repair: results with 337 operations performed over a 15-year interval. *Ann Surg* 2002;236:471-479.
27. Casey K, Al-Khatib WK, Zhou W. Hypogastric artery preservation during aortoiliac aneurysm repair. *Ann Vasc Surg* 2011;25:133.e1-8.
28. Chaikof EL, Brewster DC, Dalman RL, Makaroun MS, Illig KA, Sicard GA, Timaran CH, Upchurch GR Jr, Veith FJ. The care of patients with an abdominal aortic aneurysm: the Society for Vascular Surgery practice guidelines. *J Vasc Surg* 2009;50:2-49.
29. Cheng SW, Ting AC, Ho P, Poon JT. Aortic aneurysm morphology in Asians: features affecting stent-graft application and design. *J Endovasc Ther* 2004;11:605-612.

30. Chowdhury MM, Schiro A, Farquharson F, Smyth JV, Serracino-Inglott F, Murray D. Treatment of Aortoiliac Aneurysms With the Iliac Bifurcated Device for Preservation of Internal Iliac Artery Flow. *Vascular and Endovascular Surgery* 2014;48(2):153-158.
31. Chuter TA, Rapp JH, Hiramoto JS, Schneider DB, Howell B, Reilly LM. Endovascular treatment of thoracoabdominal aortic aneurysms. *J Vasc Surg* 2008;47:6-16.
32. Clarke MJ, Pimpalwar S, Wyatt MG, Rose JDG. Endovascular exclusion of bilateral common iliac artery aneurysms with preservation of internal iliac artery perfusion. *Eur J Vasc Endovasc Surg* 2001;22:559-562.
33. Cochenec F, Marzelle J, Allaire E, Desgranges P, Becquemin JP. Open vs endovascular repair of abdominal aneurysm involving the iliac bifurcation. *J Vasc Surg* 2010;51:1360-1366.
34. Connolly JE, Ingegno M, Wilson SE. Preservation of the pelvic circulation during infrarenal aortic surgery. *Cardiovasc Surg* 1996;4:65-70.
35. Coppi G, Tasselli S, Silingardi R, Gennai S, Saitta G, Moratto R. Endovascular Preservation of Full Pelvic Circulation with External Iliac-to-internal Iliac Artery "Cross-stenting" in Patients with Aorto-iliac Aneurysms. *J Vasc Interv Radiol* 2010;21:1579-1582.
36. Cox GS, O'Hara PJ, Hertzner NR, Piedmonte MR, Krajewski LP, Beven EG. Thoracoabdominal aneurysm repair: a representative experience. *J Vasc Surg* 1992;15:780-787.
37. Criado FJ, Wilson EP, Velazquez OC, Carpenter JP, Barker C, Wellons E, Abul-Khoudoud O, Fairman RM. Safety of coil embolization of the internal iliac artery in endovascular grafting of abdominal aortic aneurysms. *J Vasc Surg* 2000;32:684-688.
38. Cuff R, Banegas S, Mansour A, Chambers C, Wong P, Slaikeu J. Endovascular repair of bilateral common iliac artery aneurysms following open abdominal aortic aneurysm repair with preservation of both hypogastric arteries using commercially available stent grafts. *J Vasc Surg* 2014;59:516-519.
39. Cynamon J, Lerer D, Veith FJ, Taragin BH, Wahl SI, Lautin JL, Ohki T, Sprayregen S. Hypogastric artery coil embolization prior to endoluminal repair of aneurysms and fistulas: buttock claudication, a recognized but possibly preventable complication. *J Vasc Interv Radiol* 2000;11(5):573-577.
40. Dake MD. Feasibility and Utility of an Iliac Branch Endoprosthesis. *Supplement to Endovascular Today* 2013:11.
41. Deaton DH, Mehta M, Kasirajan K, Chaikof E, Farber M, Glickman MH, et al. The phase I multicenter trial (STAPLE-1) of the Aptus Endovascular Repair System: results at 6 months and 1 year. *J Vasc Surg* 2009;49:851-858.
42. Debus ES, Carpenter SW, Tsilimparis N, Larena-Avellaneda A, Kölbel T. Therapie des abdominalen Aortenaneurysmas. *Der Internist* 2013;54:543-551.
43. Della Schiava N, Arsicot M, Boudjelit T, Feugier P, Lermusiaux P, Millon A. Conformability of GORE Excluder Iliac Branch Endoprosthesis and COOK Zenith Bifurcated Iliac Side Branched Iliac Stent Grafts. *Ann Vasc Surg* 2016;36:139-144.
44. Delle M, Lönn L, Wingren U, Karlström L, Klingenstierna H, Risberg B, Grahn P, Nyman U. Preserved pelvic circulation after stent-graft treatment of complex aortoiliac artery aneurysms: a new approach. *J Endovasc Ther* 2005;12(2):189-195.
45. Derom A, Vermassen F, Ongena K. Endograft exclusion of residual common iliac artery aneurysms. *J Endovasc Ther* 2000;7:251-254.

46. DeRubertis BG, Quinones-Baldrich WJ, Greenberg JI, Jimenez JC, Lee JT. Results of a double-barrel technique with commercially available devices for hypogastric preservation during aortoiliac endovascular abdominal aortic aneurysm repair. *J Vasc Surg* 2012;56:1252-1260.
47. Dias NV, Resch TA, Sonesson B, Ivancev K, Malina M. EVAR of aortoiliac aneurysms with branched stent-grafts. *Eur J Vasc Endovasc Surg* 2008;35(6):677-684.
48. Domoto S, Tagusari O, Takai H, Nakamura Y, Seike Y, Ito Y. Pelvic abscess following internal iliac artery embolization prior to endovascular aneurysm repair. *J Vasc Surg* 2012;56(6):1734-1736.
49. Donas KP, Bisdas T, Torsello G, Austermann M. Technical considerations and performance of bridging stent-grafts for iliac side branched devices based on a pooled analysis of single-center experiences. *J Endovasc Ther* 2012;19(5):667-671.
50. Donas KP, Torsello G, Pitoulias GA, Austermann M, Papadimitriou DK. Surgical versus endovascular repair by iliac branch device of aneurysms involving the iliac bifurcation. *J Vasc Surg* 2011;53:1223-1229.
51. Donayre CE, Zarins CK, Krievins D, Holden A, Hill A, Calderas C, Velez J, White RA. Initial clinical experience with a sac-anchoring endoprosthesis for aortic aneurysm repair. *J Vasc Surg* 2011;53(3):574-582.
52. Duffy ST, Colgan MP, Sultan S, Moore DJ, Shanik GD. Popliteal aneurysms: a 10-year experience. *Eur J Vasc Endovasc Surg* 1998;16:218-222.
53. Elder K, Lashner BA, Al Solaiman F. Clinical approach to colonic ischemia. *Cleve Clin J Med* 2009;76:401-409.
54. Engelke C, Elford J, Morgan RA, Belli AM. Internal iliac artery embolization with bilateral occlusion before endovascular aortoiliac aneurysm repair-clinical outcome of simultaneous and sequential intervention. *J Vasc Interv Radiol* 2002;13(7):667-676.
55. Fahrni M, Lachat MM, Wildermuth S, Pfannmatter T. Endovascular therapeutic options for isolated iliac aneurysms with a working classification. *Cardiovasc Intervent Radiol* 2003;26:443-447.
56. Falkensammer J, Hakaim AG, Oldenburg WA, Neuhauser B, Paz-Fumagalli R, McKinney JM, Hugl B, Biebl M, Klocker J. Natural history of the iliac arteries after endovascular abdominal aortic aneurysm repair and suitability of ectatic iliac arteries as a distal sealing zone. *J Endovasc Ther* 2007;14:619-624.
57. Farahmand P, Becquemin JP, Desgranges P, Allaire E, Marzelle J, Roudot-Thoraval F. Is hypogastric artery embolization during endovascular aortoiliac aneurysm repair (EVAR) innocuous and useful? *Eur J Vasc Endovasc Surg* 2008;35(4):429-435.
58. Faries PL, Morrissey N, Burks JA, Gravereaux E, Kerstein MD, Teodorescu VJ, Hollier LH, Marin ML. Internal iliac artery revascularization as an adjunct to endovascular repair of aortoiliac aneurysms. *J Vasc Surg* 2001;34: 892-899.
59. Fernández-Alonso L, Fernández-Alonso S, Grijalba FU, Fariña ES, Aguilar EM, Alegret Solé JF, Pascual MA, Centeno R. Endovascular Treatment of Abdominal Aortic Aneurysms Involving Iliac Bifurcation: Role of Iliac Branch Graft Device in Prevention of Buttock Claudication. *Annals of Vascular Surgery* 2013;27(7):851-855.
60. Ferreira M, Monteiro M, Lanzotti L. Technical aspects and midterm patency of iliac branched devices. *J Vasc Surg* 2010;51:545-550.
61. Ferrer C, De Crescenzo F, Coscarella C, Cao P. Early experience with the Excluder iliac branch endoprosthesis. *J Cardiovasc Surg (Torino)* 2014;55:679-683.

62. Forbes TL, DeRose G, Kribs SW, Harris KA. Cumulative sum failure analysis of the learning curve with endovascular abdominal aortic aneurysm repair. *J Vasc Surg* 2004;39:102-108.
63. Friedman SG, Wun H. Hypogastric preservation with Viabahn stent graft during endovascular aneurysm repair. *J Vasc Surg*. 2011;54(2):504-506.
64. Frigatti P, Lepidi S, Piazza M, Maturi C, Menegolo M, Deriu GP, Grego F. A New Endovascular Approach to Exclude Isolated Bilateral Common Iliac Artery Aneurysms. *EJVES Extra* 2010;19(6):e55-e57.
65. Ghosh J, Murray D, Paravastu S, Farquharson F, Walker MG, Serracino-Inglott F. Contemporary Management of Aorto-iliac Aneurysms in the Endovascular Era. *Eur J Vasc Endovasc Surg* 2009;37:182-188.
66. Graham TL, Tan K. Preservation of the superior gluteal artery in patients with internal iliac artery aneurysm using iliac bifurcated device and viabahn stent grafts, a single institution experience. *Journal of Vascular and Interventional Radiology* 2013;24 (4), Supplement,18.
67. Gray D, Shahverdyan R, Jakobs C, Brunkwall J, Gawenda M. Endovascular Aneurysm Repair of Aortoiliac Aneurysms with an Iliac Sidebranched Stent graft: Studying the Morphological Applicability of the Cook Device. *Eur J Vasc Endovasc Surg* 2015;49:283-288.
68. Greenberg RK, Clair D, Srivastava S, Bhandari G, Turc A, Hampton J, Popa M, Green R, Ouriel K. Should patients with challenging anatomy be offered endovascular aneurysm repair? *J Vasc Surg* 2003;38:990-996.
69. Greenberg RK, Lu Q, Roselli EE, Svensson L, Moon M, Dowdall J, Cury M, Francis C, Pfaff K, Clair DG, Ouriel K, Lytle BW. Contemporary analysis of descending thoracic and thoracoabdominal aneurysm repair: a comparison of endovascular and open techniques. *Circulation* 2008;118:808-817.
70. Greenberg RK, West K, Pfaff K, Foster J, Skender D, Haulon S, Sereika J, Geiger L, Lyden SP, Clair D, Svensson L, Lytle B. Beyond the aortic bifurcation: branched endovascular grafts for thoracoabdominal and aortoiliac aneurysms. *J Vasc Surg* 2006;43:879-886.
71. Greenhalgh RM, Brown LC, Kwong GP, Powell JT, Thompson SG, EVAR trial participants. Comparison of endovascular aneurysm repair with open repair in patients with abdominal aortic aneurysm (EVAR trial 1), 30-day operative mortality results: randomised controlled trial. *Lancet* 2004;364:843-848.
72. Gross-Fengels W. Die Interventionelle/endovaskuläre Therapie des infrarenalen abdominalen Aortenaneurysmas. *Radiologe* 2013;53:503-512.
73. Ha CD, Calcagno D. Amplatz vascular plug to occlude the internal iliac arteries in patients undergoing aortoiliac aneurysm repair. *J Vasc Surg* 2005;42:1058-1062.
74. Handa N, Onohara T, Okamoto M, Yamamoto T, Shimoe Y, Okada M, Ishibashi Y, Yamashita M, Takahashi T, Kasashima F, Kishimoto J, Mizuno A, Kei J, Nakai M, Suhara H, Endo M, Nishina T, Furuyama T, Kawasaki M, Mikasa K, Ueno Y. Early outcomes of open abdominal repair versus endovascular repair for abdominal aortic aneurysm: report from national hospital organization network study in Japan. *Ann Vasc Dis* 2012;5:172-179.
75. Harrison GJ, Antoniou GA, Torella F, McWilliams RG, Fisher RK. Endovascular Aneurysm Repair and Sealing (EVARS): A Useful Adjunct in Treating Challenging Morphology. *Cardiovasc Intervent Radiol* 2016;39:616-619.
76. Haulon S, Greenberg RK, Pfaff K, Francis C, Koussa M, West K. Branched grafting for aortoiliac aneurysms. *Eur J Vasc Endovasc Surg* 2007;33:567-574.

77. Haulon S, Lions C, McFadden EP, Koussa M, Gzotote V, Halna P, Beregi JP. Prospective evaluation of magnetic resonance imaging after endovascular treatment of infrarenal aortic aneurysms. *Eur J Vasc Endovasc Surg* 2001;22:62-69.
78. Heckenkamp J, Burnkwall J, Luebke T, Aleksic M, Schöndube F, Stojanovic T. Novel chimney-graft technique for preserving hypogastric flow in complex aortoiliac aneurysms. *J Cardiovasc Surg* 2012;53:773-776.
79. Hennedige T, Chua B, Taneja M. Modification of the sandwich technique to preserve flow in the hypogastric artery after endovascular repair of aortoiliac aneurysmal disease: our initial experience with two cases. *Ann Vasc Surg* 2012;26(7):1011.e1-5.
80. Henretta JP, Karch LA, Hodgson KJ, Mattos MA, Ramsey DE, McLafferty R, Sumner DS. Special iliac artery considerations during aneurysm endografting. *Am J Surg* 1999;178:212-218.
81. Heye S, Nevelsteen A, Maleux G. Internal iliac artery coil embolization in the prevention of potential type 2 endoleak after endovascular repair of abdominal aortoiliac and iliac artery aneurysms: effect of total occlusion versus residual flow. *J Vasc Interv Radiol* 2005;16:235-239.
82. Hinchliffe RJ, Alric P, Rose D, Owen V, Davidson IR, Armon MP, Hopkinson BR. Comparison of morphologic features of intact and ruptured aneurysms of infrarenal abdominal aorta. *J Vasc Surg* 2003;38(1):88-92.
83. Hinchliffe RJ, Armon MP, Tse CC, Wenham PW, Hopkinson BR. Colonic infarction following endovascular AAA repair: a multifactorial complication. *J Endovasc Ther* 2002;9(4):554-558.
84. Hobo R, Sybrandy JEM, Harris P, Buth J. Endovascular repair of abdominal aortic aneurysms with concomitant iliac artery aneurysm. Outcome analysis of the EUROSTAR experience. *J Endovasc Ther* 2008;15:12-22.
85. Hoffer EK, Nicholls SC, Fontaine AB, Glickerman DJ, Borsa JJ, Bloch RD. Internal to external iliac artery stent-graft: a new technique for vessel exclusion. *J Vasc Interv Radiol* 1999;10:1067-1073.
86. Hosaka A, Kato M, Kato I, Isshiki S, Okubo N. Outcome after concomitant unilateral embolization of the internal iliac artery and contralateral external-to-internal iliac artery bypass grafting during endovascular aneurysm repair. *J Vasc Surg* 2011;54:960-964.
87. Huilgol RL, Denton MJ, Cohen T. The iliac bifurcation device for endovascular iliac aneurysm repair: indications, deployment options and results at 1-year follow-up of 25 cases. *ANZ J Surg* 2009;79:844-849.
88. Huilgol RL, Lennox A, Boyne N, Villalba L, Huber D, Goodman M. Using bilateral iliac branch devices for endovascular iliac aneurysm repair. *ANZ J Surg* 2011;81(11):822-826.
89. Iliopoulos JI, Hermreck AS, Thomas JH, Pierce GE. Hemodynamics of the hypogastric arterial circulation. *J Vasc Surg* 1989;9:637-641, discussion 41-42.
90. Iliopoulos JI, Howanits PE, Pierce GE, Kueshkerian SM, Thomas JH, Hermreck AS. The critical hypogastric circulation. *Am J Surg* 1987;154:271-275.
91. Illuminati G, D'Urso A, Ceccanei G, Pacilè MA. Iliac side branch device for bilateral endovascular exclusion of isolated common iliac artery aneurysms without brachial access. *J Vasc Surg* 2009;49(1):225.
92. Inuzuka K, Unno N, Mitsuoka H, Yamamoto N, Ishimaru K, Sagara D, Suzuki M, Konno H. Intraoperative monitoring of penile and buttock blood flow during endovascular abdominal aortic aneurysm repair. *Eur J Vasc Endovasc Surg* 2006;31:359-365.

93. Jayalath RW, Mangan SH, Golledge J. Aortic calcification. *Eur J Vasc Endovasc Surg* 2005;30:476-488.
94. Jean-Baptiste E, Brizzi S, Bartoli MA, Sadaghianloo N, Baqué J, Magnan PE, Hassen-Khodja R. Pelvic ischemia and quality of life scores after interventional occlusion of the hypogastric artery in patients undergoing endovascular aortic aneurysm repair. *J Vasc Surg* 2014;60:40-49.
95. Karch LA, Hodgson KJ, Mattos MA, Bohannon WT, Ramsey DE, McLafferty RB. Adverse consequences of internal iliac artery occlusion during endovascular repair of abdominal aortic aneurysms. *J Vasc Surg* 2000;32:676-683.
96. Karch LA, Hodgson KJ, Mattos MA, Bohannon WT, Ramsey DE, McLafferty RB. Management of ectatic nonaneurysmal iliac arteries during endoluminal aortic aneurysm repair. *J Vasc Surg* 2001;33:33-38.
97. Karthikesalingam A, Hinchliffe RJ, Holt PJ, Boyle JR, Loftus IM, Thompson MM. Endovascular aneurysm repair with preservation of the internal iliac artery using the iliac branch graft device. *Eur J Vasc Endovasc Surg* 2010;39:285-294.
98. Karthikesalingam A, Hinchliffe RJ, Malkawi AH, Holt PJ, Loftus IM, Thompson MM. Morphological suitability of patients with aortoiliac aneurysms for endovascular preservation of the internal iliac artery using commercially available iliac branch graft devices. *J Endovasc Ther* 2010;17:163-171.
99. Karthikesalingam A, Parmar J, Cousins C, Hayes PD, Varty K, Boyle JR. Midterm results from internal iliac artery branched endovascular stent grafts. *Vascular and Endovascular Surgery* 2010;44(3):179-183.
100. Karthikesalingam A, Cobb RJ, Khoury A, Choke EC, Sayers RD, Holt PJ, et al. The morphological applicability of a novel endovascular aneurysm sealing (EVAS) system (Nellix) in patients with abdominal aortic aneurysms. *Eur J Vasc Endovasc. Surg* 2013;46(4):440-445.
101. Kazuno K, Ohtani N, Nakanishi S. Two Cases of Endovascular Abdominal Aortic Aneurysm Repair with Iliac Aneurysm Using a Zenith Iliac Bifurcation Graft. *Ann Vasc Dis* 2012;5(4):469-473.
102. Kemmochi R, Matsumoto M, Kubo Y, Yamasawa T. Hypogastric and lumbar artery bypasses to restore gluteal perfusion after open aortoiliac aneurysm repair. *J Vasc Surg* 2013;58(4):1073-1075.
103. Kickuth R, Dick F, Triller J, Ludwig K, Schmidli J, Do DD. Internal iliac artery embolization before endovascular repair of aortoiliac aneurysms with a nitinol vascular occlusion plug. *J Vasc Interv Radiol* 2007;18:1081-1087.
104. Kirkwood ML, Saunders A, Jackson BM, Wang GJ, Fairman RM, Woo EY. Aneurysmal iliac arteries do not portend future iliac aneurysmal enlargement after endovascular aneurysm repair for abdominal aortic aneurysm. *J Vasc Surg* 2011;53:269-273.
105. Kisis K, Savlovskis J, Dombure P, Gedins M, Ezite N, Zarins K, Krievins D. Treatment of Abdominal Aortic Aneurysms with Accompanied Iliac Artery Aneurysms Using New Sack Sealing Device. *Acta Chirurgica Latviensis* 2013;13:22-27.
106. Kolvenbach RR, Yoshida R, Pinter L, Zhu Y, Lin F. Urgent endovascular treatment of thoraco-abdominal aneurysms using a sandwich technique and chimney grafts—a technical description. *Eur J Vasc Endovasc Surg* 2011;41:54-60.
107. Kotsis T, Tsanis A, Sfyroeras G, Lioupis C, Moulakakis K, Georgakis P. Endovascular exclusion of symptomatic bilateral common iliac artery aneurysms with preservation of an aneurysmal internal iliac artery via a reverse-U stent-graft. *J Endovasc Ther* 2006;13(2):158-163.

- 108.Kouvelos GN, Koutsoumpelis A, Peroulis M, Matsagkas M. In endovascular aneurysm repair cases, when should you consider internal iliac artery embolization when extending a stent into the external iliac artery? *Interactive CardioVascular and Thoracic Surgery* 2014;18:821-824.
- 109.Krievins D, Holden A, Savlovskis J, Calderas C, Donayre CE, Moll FL, Katzen B, Zarins CK. EVAR using the Nellix Sac-anchoring endoprosthesis: treatment of favourable and adverse anatomy. *Eur J Vasc Endovasc Surg* 2011;42(1):38-46.
- 110.Kritpracha B, Pigott JP, Price CI, Russell TE, Corbey MJ, Beebe HG. Distal internal iliac artery embolization: a procedure to avoid. *J Vasc Surg* 2003;37:943-948.
- 111.Kritpracha B, Pigott JP, Russell TE, Corbey MJ, Whalen RC, DiSalle RS, Price CI, Sproat IA, Beebe HG. Bell-bottom aortoiliac endografts: an alternative that preserves pelvic blood flow. *J Vasc Surg* 2002;35:874-881.
- 112.Krupski WC, Selzman CH, Florida R, Strecker PK, Nehler MR, Whitehill TA. Contemporary management of isolated iliac aneurysms. *J Vasc Surg* 1998;28:1-13.
- 113.Laurito A, Faccenna F, Jabbour J, Martinelli O, Giannoni MF, Alunno A, Castiglione A, Felli MMG, Gattuso R, Bresadola L, Venosi S, Irace L. Endovascular treatment of iliac aneurysms with iliac side branch endograft. *Italian Journal of Vascular and Endovascular Surgery* 2010;17(3 Supp 1):95-98.
- 114.Lee CW, Kaufman JA, Fan CM, Geller SC, Brewster DC, Cambria RP, Lamuraglia GM, Gertler JP, Abbott WM, Waltman AC. Clinical outcome of internal iliac artery occlusions during endovascular treatment of aortoiliac aneurysmal diseases. *J Vasc Interv Radiol* 2000;11:567-571.
- 115.Lee WA, Nelson PR, Berceli SA, Seeger JM, Huber TS. Outcome after hypogastric artery bypass and embolization during endovascular aneurysm repair. *J Vasc Surg* 2006;44:1162-1168.
- 116.Lee WA, O'Dorisio J, Wolf YG, Hill BB, Fogarty TJ, Zarins CK. Outcome after unilateral hypogastric artery occlusion during endovascular aneurysm repair. *J Vasc Surg* 2001;33:921-926.
- 117.Lee WA, Wolf YG, Hill BB, Cipriano P, Fogarty TJ, Zarins CK. The first 150 endovascular AAA repairs at a single institution: how steep is the learning curve? *J Endovasc Ther* 2002;9:269-276.
- 118.Lee WA. Branched Endograft for Aortoiliac Artery Aneurysms, Endografts for Aortoiliac Aneurysms 2009;17(3):111-118.
- 119.Lepidi S, Piazza M, Scrivere P, Menegolo M, Antonello M, Grego F, Frigatti P. Parallel Endografts in the Treatment of Distal Aortic and Common Iliac Aneurysms. *European Journal of Vascular and Endovascular Surgery* 2014;48(1):29-37.
- 120.Levi N, Schroter T. Isolated iliac artery aneurysms. *Eur J Vasc Endovasc Surg* 1998;16:342-344.
- 121.Lin PH, Bush RL, Chaikof EL, Chen C, Conklin B, Terramani TT, Brinkman WT, Lumsden AB. A prospective evaluation of hypogastric artery embolization in endovascular aortoiliac aneurysm repair. *J Vasc Surg* 2002;36:500-506.
- 122.Lin PH, Bush RL, Lumsden AB. Sloughing of the scrotal skin and impotence subsequent to bilateral hypogastric artery embolization for endovascular aortoiliac aneurysm repair. *J Vasc Surg* 2001;34(4):748-750.
- 123.Lin PH, Chen AY, Vij A. Hypogastric artery preservation during endovascular aortic aneurysm repair: is it important? *Semin Vasc Surg* 2009;22:193-200.

- 124.Lobato AC, Camacho-Lobato L. The sandwich technique to treat complex aortoiliac or isolated iliac aneurysms: Results of midterm follow-up. *J Vasc Surg* 2013;57:26S-34S.
- 125.Lobato AC, Rodriguez-Lopez J, Diethrich EB. Learning curve for endovascular abdominal aortic aneurysm repair: evaluation of a 277- patient single-center experience. *J Endovasc Ther* 2002;9:262-268.
- 126.Lobato AC. Sandwich technique for aortoiliac aneurysms extending to the internal iliac artery or isolated common/internal iliac artery aneurysms: a new endovascular approach to preserve pelvic circulation. *J Endovasc Ther* 2011;18:106-111.
- 127.Loftus I. Branched Grafts For Hypogastric Revascularisation: Are They Durable? When Are They Feasible And When Not? Presented at the 38th Annual Vascular and Endovascular Issues, Techniques and Horizons (VEITHsymposium), November 16-20, 2011, New York City.
- 128.Loth AG, Rouhani G, MD, Gafoor SA, Sievert H, Stelter WJ. Treatment of iliac artery bifurcation aneurysms with the second-generation straight iliac bifurcated device. *J Vasc Surg* 2015;62:1168-1175.
- 129.Malagari K, Brountzos E, Gougoulakis A, Papathanasiou M, Alexopoulou E, Mastorakou R, Kelekis D. Large diameter limbs for dilated common iliac arteries in endovascular aneurysm repair. Is it safe? *Cardiovasc Intervent Radiol* 2004;27:237-242.
- 130.Maldonado TS, Rockman CB, Riles E, Douglas D, Adelman MA, Jacobowitz GR, Gagne PJ, Nalbandian MN, Cayne NS, Lamparello PJ, Salzberg SS, Riles TS. Ischemic complications after endovascular abdominal aortic aneurysm repair. *J Vasc Surg* 2004;40:703-709; discussion:709-710.
- 131.Malina M, Dirven M, Sonesson B, Resch T, Dias N, Ivancev K. Feasibility of a branched stent-graft in common iliac artery aneurysms. *J Endovasc Ther* 2006;13:496-500.
- 132.Marin ML, Veith FJ, Cynamon J, Sanchez LA, Lyon RT, Levine BA, Bakal CW, SuggsWD, Wengerter KR, Rivers SP. Initial experience with transluminally placed endovascular grafts for the treatment of complex vascular lesions. *Ann Surg* 1995;224:449-465.
- 133.Massière B, von Ristow A, Cury J, Gress M, Vescovi A, Marques M. Internal Iliac Artery Branch Stent Grafting for Aortoiliac Aneurysms Using the Apollo Branched Device. *Annals of Vascular Surgery* 2010;417:15-18.
- 134.Massière B, von Ristow A, Vescovi A, Pedron C, Fonseca LMB. Management of aortoiliac aneurysms by retrograde endovascular hypogastric artery preservation. *Vascular* 2014;22(2):116-120.
- 135.Maurel B, Bartoli MA, Jean-Baptiste E, Reix T, Cardon A, Goueffic Y, Martinez R, Cochenec F, Albertini JN, Chauffour X, Steinmetz E, Haulon S. Perioperative evaluation of iliac ZBIS branch devices: a French multicenter study. *Ann Vasc Surg* 2013;27(2):131-138.
- 136.May J, White G, Waugh R, Yu W, Harris J. Treatment of complex abdominal aortic aneurysms by a combination of endoluminal and extraluminal aortofemoral grafts. *J Vasc Surg* 1994;19:924-933.
- 137.Mehta M, Veith FJ, Darling RC, Roddy SP, Ohki T, Lipsitz EC, Paty PS, Kreienberg PB, Ozsvath KJ, Chang BB, Shah DM. Effects of bilateral hypogastric artery interruption during endovascular and open aortoiliac aneurysm repair. *J Vasc Surg* 2004;40:698-702.
- 138.Mehta M, Veith FJ, Ohki T, Cynamon J, Goldstein K, Suggs WD, Wain RA, Chang DW, Friedman SG, Scher LA, Lipsitz EC. Unilateral and bilateral hypogastric artery interruption during aortoiliac aneurysm repair in 154 patients: a relatively innocuous procedure. *J Vasc Surg* 2001;33:27-32.
- 139.Mehta M, Valdés FE, Nolte T, Mishkel GJ, Jordan WD, Gray B, et al; A Pivotal Clinical Study to Evaluate the Safety and Effectiveness of the Ovation Abdominal Stent Graft System Investigators. One-year

- outcomes from an international study of the Ovation Abdominal Stent Graft System for endovascular aneurysm repair. *J Vasc Surg* 2014;59:65-73.
140. Melas N, Saratzis A, Dixon H, Saratzis N, Lazaridis J, Perdikides T, Kiskinis D. Isolated iliac artery Aneurysms: a revised classification to assist endovascular repair. *J Endovasc Ther* 2011;18:697-715.
141. Mell M, Tefera G, Schwarze M, Carr S, Acher C, Hoch J, Turnipseed W. Absence of buttock claudication following stent-graft coverage of the hypogastric artery without coil embolization in endovascular aneurysm repair. *J Endovasc Ther* 2006;13:415-419.
142. Michaels JA, Drury D, Thomas SM. Cost-effectiveness of endovascular abdominal aortic aneurysm repair. *Br J Surg* 2005;92(8):960-967.
143. Millon A, Della Schiava N, Arsicot. Preliminary experience with the GORE® EXCLUDER® iliac branch endoprosthesis for common iliac aneurysm endovascular treatment. *Ann Vasc Surg* 2016;33:11-17.
144. Minion DJ, Xenos E, Sorial E, Saha S, Edean ED. The trifurcated endograft technique for hypogastric preservation during endovascular aneurysm repair. *J Vasc Surg* 2008;47(3):658-661.
145. Moll FL, Powell JT, Fraedrich G, Verzini F, Haulon S, Waltham M, van Herwaarden JA, Holt PJ, van Keulen JW, Rantner B, Schlösser FJ, Setacci F, Ricco JB. Management of abdominal aortic aneurysms clinical practice guidelines of the European Society for Vascular Surgery. *Eur J Vasc Endovasc Surg* 2011;41(1):1-58.
146. Mosquera Arochena N, Molina Herrero F, Carbalho Fernandez C, Rodriguez Feijoo G, Fernandez Lebrato R, Barrios Castro A, Garcia Fernandez I. Hybrid approach to AAA: Bilateral "banana" technique to preserve hypogastric artery in complex anatomy aorto-biiliac aneurysm. *Rev Port Cir Cardiorac Vasc* 2011;18(4):225-230.
147. Mosquera Arochena N, Rodríguez Feijoo G, Carballo Fernandez C, Molina Herrero F, Fernandez Lebrato R, Barrios Castro A, Garcia Fernandez I. Use of modified Sandwich graft technique to preserve hypogastric artery in EVAR treatment of complex aortic aneurysm anatomy. *J Cardiovasc Surg (Torino)* 2011;52(5):643-649.
148. Mosquera N. The hypogastric issue: how is the hypogastric patency? Why not a sandwich technique? SITE 2013. 8-11 May, Barcelona, Spain.
149. Mulder EJ, van Bockel JH, Maas J, van den Akker PJ, Hermans J. Morbidity and mortality of reconstructive surgery of noninfected false aneurysms detected long after aortic prosthetic reconstruction. *Arch Surg* 1998;133:45-49.
150. Mwipatayi BP, Thomas S, Luca K. A case in which synchronous fenestrated stent grafting and iliac branch devices are used for exclusion of an aortoiliac aneurysm. *Endovascular Today* 2010:35-38.
151. Mylonas SN, Rümenapf G, Schelzig H, Heckenkamp J, Youssef M, Schäfer JP, Ahmad W, Brunkwall JS; E-iliac Collaborative Group. A multicenter 12-month experience with a new iliac side-branched device for revascularization of hypogastric arteries. *J Vasc Surg*. 2016;64(6):1652-1659.
152. Nachbur BH, Inderbitzi RGC, Bär W. Isolated iliac aneurysms. *Eur J Vasc Surg* 1991;5:375.
153. Naik J, Hayes PD, Sadat U, See TC, Cousins C and Boyle JR. Internal Iliac Artery Branch Graft for Common Iliac Artery Aneurysm Following Previous Open Abdominal Aortic Aneurysm Repair. *Eur J Vasc Endovasc Surg* 2008;35:436-438.

154. Naughton PA, Park MS, Kheirelseid EAH, O'Neill SM, Rodriguez HE, Morasch MD, Madhavan P, Eskandari MK. A comparative study of the bell-bottom technique vs hypogastric exclusion for the treatment of aneurysmal extension to the iliac bifurcation. *J Vasc Surg* 2012;55(4):956-962.
155. Nice C, Bhattacharya V, Ashour HY. Modified Technique for Iliac Branched Stent-Graft Insertion. *EJVES Extra* 2008;16:33-35.
156. Noel-Lamy M, Jaskolka J, Lindsay TF, Oreopoulos GD, Tan KT. Internal Iliac Aneurysm Repair Outcomes Using a Modification of the Iliac Branch Graft. *Eur J Vasc Endovasc Surg* 2015;50:474-479.
157. Oberhuber A, Duran M, Ertaş N, Simon F, Schelzig H. Implantation of an Iliac Branch Device After EVAR via a Femoral Approach Using a Steerable Sheath. *J Endovasc Ther* 2015;22(4):610-612.
158. Oderich GS, Greenberg RK. Endovascular Iliac Branch Devices for Iliac Aneurysms. *Vascular Surgery and Endovascular Therapy* 2011;23(3):166-172.
159. Oderich GS, Ricotta JJ 2nd. Novel surgeon-modified hypogastric branch stent graft to preserve pelvic perfusion. *Ann Vasc Surg* 2010;24:278-286.
160. Papazoglou KO, Sfyroeras GS, Zambas N, Konstantinidis K, Kakkos SK, Mitka M. Outcomes of endovascular aneurysm repair with selective internal iliac artery coverage without coil embolization. *J Vasc Surg* 2012;56:298-303.
161. Park KM, Yang SS, Kim YW, Park KB, Park HS, Do YS, Kim DI. Clinical outcomes after internal iliac artery embolization prior to endovascular aortic aneurysm repair. *Surg Today* 2014;44:472-477.
162. Parlani G, Verzini F, De Rango P, Brambilla D, Coscarella C, Ferrer C, Cao P. Long-term results of iliac aneurysm repair with iliac branched endograft: a 5-year experience on 100 consecutive cases. *Eur J Vasc Endovasc Surg* 2012;43:287-292.
163. Parodi JC, Ferreira M. Relocation of the iliac bifurcation to facilitate endoluminal treatment of abdominal aortic aneurysm. *J Endovasc Surg* 1999;6:342-347.
164. Parodi JC, Palmaz JC, Barone HD. Transfemoral intraluminal graft implantation for abdominal aortic aneurysms. *Ann Vasc Surg* 1991;5:491-499.
165. Parodi JC. Endovascular repair of abdominal aortic aneurysms and other lesions. *J Vasc Surg* 1995;21:549-557.
166. Peacock JH, Brown GJ. Wiring in the treatment of aortic aneurysms. *Br J Surg* 1968;55:344-346.
167. Pearce BJ, Varu VN, Glocker R, et al. Anatomic suitability of aortoiliac aneurysms for next generation branched systems. *Ann Vasc Surg* 2015;29:69-75.
168. Peters AS, Bischoff MS, Meisenbacher K, Böckler D. Management isolierter Iliakalaneurysmen. *Gefäßchirurgie* 2013;18:307-316.
169. Petrik PV, Moore WS. Endoleaks following endovascular repair of abdominal aortic aneurysm: the predictive value preoperative anatomic factors – a review of 100 cases. *J Vasc Surg* 2001;33:739-744.
170. Pfabe FP, Hinc D, Sud D, Bach M. Das isolierte Iliakaaneurysma – eine morphologische Klassifikation unter endovaskulären Gesichtspunkten. *Gefäßchirurgie*, Springer-Verlag Berlin Heidelberg 2014;19:38-50.
171. Pratesi G, Fargion A, Pulli R, Barbante M, Dorigo W, Ippoliti A, Pratesi C. Endovascular Treatment of Aorto-iliac Aneurysms: Four-year Results of Iliac Branch Endograft. *European Journal of Vascular and Endovascular Surgery* 2013;45(6):607-609.

172. Prinssen M, Buskens E, de Jong SE, Buth J, Mackaay AJ, van Sambeek MR, Blankensteijn JD. Cost-effectiveness of conventional and endovascular repair of abdominal aortic aneurysms: results of a randomized trial. *J Vasc Surg* 2007;46:883-890.
173. Prinssen M, Verhoeven EL, Buth J, Cuypers PW, van Sambeek MR, Balm R, Buskens E, Grobbee DE, Blankensteijn JD; Dutch Randomized Endovascular Aneurysm Management (DREAM) Trial Group. A randomized trial comparing conventional and endovascular repair of abdominal aortic aneurysms. *N Engl J Med* 2004;351:1607-1618.
174. Pua U, Tan K, Rubin BB, Sniderman KW, Rajan DK, Oreopoulos GD, Lindsey TF. Iliac branch graft in the treatment of complex aortoiliac aneurysms: early results from a North American institution. *J Vasc Interv Radiol* 2011;22(4):542-549.
175. Pua U, Tan K. Radiology of advanced EVAR techniques in complex abdominal aortic aneurysms. *Eur Radiol* 2012;22:387-397.
176. Puech-Leao P. Banding of the common iliac artery: an expedient in endoluminal correction of aortoiliac aneurysms. *J Vasc Surg* 2000;32:1232-1234.
177. Pulli R, Fargion A, Pratesi G, Dorigo W, Angiletta D, Pratesi C. Aortic type B dissection with acute expansion of iliac artery aneurysm in previous endovascular repair with iliac branched graft. *J Vasc Surg* 2011;54:1788-1791.
178. Queiroz AB, Mulatti GC, Aun R, Valentim LA, Puech-Leão P. Endovascular repair of a traumatic arteriovenous fistula involving the iliac bifurcation using an iliac branch device. *J Vasc Surg* 2012;55,5:1474-1476.
179. Rajesparan K, Partridge W, Refson J, Abidia A, Aldin Z. The risk of endoleak following stent covering of the internal iliac artery during endovascular aneurysm repair. *Clinical Radiology* 2014;69(10):1011-1018.
180. Rayt HS, Bown MJ, Lambert KV, Fishwick NG, McCarthy MJ, London NJ, Sayers RD. Buttock claudication and erectile dysfunction after internal iliac artery embolization in patients prior to endovascular aortic aneurysm repair. *Cardiovasc Interv Radiol* 2008;31(4):728-734.
181. Razavi MK, DeGroot M, Olcott C III, Sze D, Kee Ssemba CP, Dake MD. Internal iliac artery embolization in the stent-graft treatment of aortoiliac aneurysms: analysis of outcomes and complications. *J Vasc Interv Radiol* 2000;11:561-566.
182. Reber PU, Hakki H, Stirnemann P, Kniemeyer HW. Häufigkeit, Klassifikation und Therapie der isolierten Beckenarterienaneurysmen. *Chirurg* 2001;72:419-424.
183. Reilly LM, Chuter TA. Endovascular repair of thoracoabdominal aneurysms: design options, device construct, patient selection and complications. *J Cardiovasc Surg* 2009;50:447-460.
184. Reyring TF, Brewster DC, Cambria RP, Kaufman JA, Geller SC, Fan CM, Gertler JP, Lamuraglia GM, Abbott WM. Utility and reliability of endovascular aortouniiliac with femorofemoral crossover graft for aortoiliac aneurysm disease. *J Vasc Surg* 2000;31:1135-1141.
185. Ricci C, Ceccherini C, Cini M, Francesco Vigni F, Leonini S, Tommasino G, Muzzi L, Tucci E, Benvenuti A, Neri E. Single-Center Experience and 1-Year Follow-up Results of “Sandwich Technique” in the Management of Common Iliac Artery Aneurysms During EVAR. *Cardiovasc Intervent Radiol* 2012; 35:1195-1200.
186. Richardson JW, Greenfield LJ. Natural history and management of iliac aneurysms. *J Vasc Surg* 1988;8:165-171.

187. Riesenman PJ, Ricotta JJ, Veeraswamy RK. Preservation of Hypogastric Artery Blood Flow During Endovascular Aneurysm Repair of an Abdominal Aortic Aneurysm With Bilateral Common and Internal Iliac Artery Involvement: Utilization of Off-the-Shelf Stent-Graft Components Case reports. *Annals of Vascular Surgery* 2012;26(1):109.e1-109.e5.
188. Sakamoto I, Sueyoshi E, Hazama S, Makino K, Nishida A, Yamaguchi T, Eishi K, Uetani M. Endovascular treatment of iliac artery aneurysms. *Radiographics* 2005;25:213-227.
189. Sakamoto I, Mori M, Nishida A, Fukushima A, Sueyoshi E, Hazama S, Eishi K, Hayashi K. Coil embolization of iliac artery aneurysms developing after abdominal aortic aneurysm repair with a conventional bifurcated graft. *J Endovasc Ther* 2003;10:1075-1081.
190. Sandhu RS, Pipinos II. Isolated iliac artery aneurysms. *Semin Vasc Surg* 2005;18:209-215.
191. Santilli SM, Wernsing SE, Lee ES. Expansion rates and outcomes for iliac artery aneurysms. *J Vasc Surg* 2000;31:114-121.
192. Sarac TP, Clair DG, Hertzner NR, Greenberg RK, Krajewski LP, O'Hara PJ, Ouriel K. Contemporary results of juxtarenal aneurysm repair. *J Vasc Surg* 2002;36:1104-11.
193. Schlösser FJ, Gusberg RJ, Dardik A, Lin PH, Verhagen HJM, Moll FL, Muhs BE. Aneurysm rupture after EVAR: can the ultimate failure be predicted? *Eur J Vasc Endovasc Surg* 2009;37:15-22.
194. Schoder M, Zaunbauer L, Holzenbein T, Fleischmann D, Cejna M, Kretschmer G, Thurnher S, Lammer J. Internal iliac artery embolization before endovascular repair of abdominal aortic aneurysms: frequency, efficacy, and clinical results. *AJR Am J Roentgenol* 2001;177:599-605.
195. Senekowitsch C, Assadian A, Assadian O, Hartleb H, Ptakovsky H, Hagmüller GW. Replanting the inferior mesentery artery during infrarenal aortic aneurysm repair: influence on postoperative colon ischemia. *J Vasc Surg* 2006;43(4):689-694.
196. Serracino-Inglott F, Bray AE, Myers P. Endovascular abdominal aortic aneurysm repair in patients with common iliac artery aneurysms - Initial experience with the Zenith bifurcated iliac side branch device. *J Vasc Surg* 2007;46:211-217.
197. Sfyroeras GS, Koutsias S, Karathanos C, Stamoulis K, Giannoukas AD. Colonic Ischemia After Endovascular Exclusion of an Aortoiliac Aneurysm Using an Iliac Branch Device. *Vascular and Endovascular Surgery* 2010;44(7):597-600.
198. Silberzweig JE, Marin ML, Hollier LH, Mitty HA, Connelly TL. Balloon-expandable CIA occluder device for endovascular aneurysm repair. *Vasc Surg* 2001;35:263-271.
199. Stokmans RA, Willigendael EM, Tejjink JA, Ten Bosch JA, van Sambeek MR, Cuypers PW. Challenging the Evidence for Pre-emptive Coil Embolisation of the Internal Iliac Artery during Endovascular Aneurysm Repair. *Eur J Vasc Endovasc Surg* 2013;45(3):220-226.
200. Stroumpouli E, Nassef A, Loosemore T, Thompson M, Morgan R, Belli AM. The endovascular management of iliac artery aneurysms. *Cardiovasc Intervent Radiol* 2007;30:1099-1104.
201. Su WT, Stone DH, Lamparello PJ, Rockman CB. Gluteal compartment syndrome following elective unilateral internal iliac artery embolization before endovascular abdominal aortic aneurysm repair. *J Vasc Surg* 2004;39:672-675.
202. Suy RM. Arterial aneurysms: a historical review. *J R Soc Med* 2005;98(6):290.
-

203. Svensson LG, Crawford ES, Hess KR, Coselli JS, Safi HJ. Experience with 1509 patients undergoing thoracoabdominal aortic operations. *J Vasc Surg* 1993;17:357-368.
204. Tarride JE, Blackhouse G, De Rose G, Novick T, Bowen JM, Hopkins R, O'Reilly D, Goeree R. Cost-effectiveness analysis of elective endovascular repair compared with open surgical repair of abdominal aortic aneurysms for patients at a high surgical risk: a 1-year patient-level analysis conducted in Ontario, Canada. *J Vasc Surg* 2008;48:779-787.
205. Tefera G, Turnipseed WD, Carr SC, Pulfer KA, Hoch JR, Acher CW. Is coil embolization of hypogastric artery necessary during endovascular treatment of aortoiliac aneurysms? *Ann Vasc Surg* 2004;18:143-146.
206. Tielliu I. Endovascular Repair of Peripheral Artery Aneurysms. University of Groningen 2010. ISBN 978-90-367-4374-7.
207. Tielliu IF, Bos WT, Zeebregts CJ, Prins TR, Van Den Dungen JJ, Verhoeven EL. The role of branched endografts in preserving internal iliac arteries. *J Cardiovasc Surg* 2009;50:213-218.
208. Tielliu IF, Zeebregts CJ, van den Dungen JJ, Verhoeven EL. A modified technique for iliac artery branched endografting using a "tromboned" sheath. *J Vasc Surg* 2008;48:1605-1608.
209. Torsello G, Schönefeld E, Osada N, Austermann M, Pennekamp C, Donas KP. Endovascular treatment of common iliac artery aneurysms using the bell-bottom technique: long-term results. *J Endovasc Ther* 2010;17:504-509.
210. Torsello J, Tessarek B, KasprzakKlenk E. Aortenaneurysmabehandlung mit komplett perkutaner Technik: Eine Zwischenbilanz nach Behandlung von 80 Patienten. *Dtsch Med Wochenschr* 2002;127:1453-1457.
211. Uberoi R Tsetis D, Shrivastava V, Morgan R, Belli AM. Standard of practice for the Interventional management of isolated Iliac artery aneurysms. *Cardiovasc Intervent Radiol* 2011;34:3-13.
212. Unno N, Inuzuka K, Mitsuoka H, Ishimaru K, Sagara D, Konno H. Automated bedside measurement of penile blood flow using pulse-volume plethysmography. *Surg Today* 2006;36:257-261.
213. Unno N, Inuzuka K, Yamamoto N, Sagara D, Suzuki M, Konno H. Preservation of pelvic circulation with hypogastric artery bypass in endovascular repair of abdominal aortic aneurysm with bilateral iliac artery aneurysms. *J Vasc Surg* 2006;44:1170-1175.
214. Unno N, Yamamoto N, Inuzuka K, Mano Y, Sano M, Saito T, Sugisawa R, Katahashi K, Konno H. Early outcomes of iliac branch grafts in the endovascular repair of abdominal aortic aneurysms with concomitant bilateral common iliac artery aneurysms at a Japanese institution. *Surg Today* 2015;45(6):688-694.
215. van Keulen JW, de Vries JP, Dekker H, Goncalves FB, Moll FL, Verhagen HJ, van Herwaarden JA. One-year multicenter results of 100 abdominal aortic aneurysm patients treated with the Endurant stent graft. *J Vasc Surg* 2011;54:609-615.
216. Vandy F, Criado E, Upchurch GR Jr, Williams DM, Rectenwald J, Eliason J. Transluminal hypogastric artery occlusion with an Amplatzer vascular plug during endovascular aortic aneurysm repair. *J Vasc Surg* 2008;48(5):1121-1124.
217. van Sterkenburg SMM, Heyligers JMM, van Bladel M, Verhagen HJ, Eefting D, van Sambeek MR, Zeebregts CJ, Reijnen MMPJ. Experience with the GORE EXCLUDER iliac branch endoprosthesis for common iliac artery aneurysms. *J Vasc Surg* 2016;63:1451-1457.
218. Veith FJ. Transluminally placed endovascular stented grafts and their impact on vascular surgery. *J Vasc Surg* 1994;20:855-860.

219. Verzini F, Parlani G, Romano L, De Rango P, Panuccio G, Cao P. Endovascular treatment of iliac aneurysm: Concurrent comparison of side branch endograft versus hypogastric exclusion. *J Vasc Surg* 2009;49(5):1154-1161.
220. Volodos NL, Karpovich IP, Shekhanin VE, Troian VI, Iakovenko LF. A case of distant transfemoral endoprosthesis of the thoracic artery using a self-fixing synthetic prosthesis in traumatic aneurysm [in Russian], *Grudn Khir* 1988;6:84-86.
221. Vourliotakis G, Bracale UM, Sondakh A, Tielliu IF, Prins T, Verhoeven EL. Iliac branched device implantation in tortuous iliac anatomy after previous open ruptured aortic aneurysm repair. *J Cardiovasc Surg* 2012;53:527-530.
222. White GH, May J, Waugh RC, Chaufour X, Yu W. Type III W. Type IV endoleak: toward a complete definition of blood flow in the sac after endoluminal AAA repair. *J Endovasc Surg* 1998;5:305-309.
223. Williams PL, Warwick R, Dyson M, Bannister LH, editors. *Gray's anatomy*. 37th ed. New York: Churchill Livingstone; 1989;777-780.
224. Wolpert LM, Dittrich KP, Hallisey MJ, Allmendinger PP, Gallagher JJ, Heydt K, Lowe R, Windels M, Drezner AD. Hypogastric artery embolization in endovascular abdominal aortic aneurysm repair. *J Vasc Surg* 2001;33:1193-1198.
225. Wong S, Greenberg RK, Brown CR, Mastracci TM, Bena J, Eagleton MJ. Endovascular repair of aortoiliac aneurysmal disease with the helical iliac bifurcation device and the bifurcated–bifurcated iliac bifurcation device. *J Vasc Surg*. 2013;58:861–869.
226. Wu IH, Chan CY, Chen YS, Huang SC, Wang SS, Chi NH. Crossover chimney technique to preserve the internal iliac artery in abdominal aortic aneurysm with common iliac artery aneurysms. *J Endovasc Ther* 2013;20(3):298-302.
227. Wu WW, Lin Ch, Liu B, Liu CW. Using a Surgeon-modified Iliac Branch Device to Preserve the Internal Iliac Artery during Endovascular Aneurysm Repair: Single-center Experiences and Early Results. *Chin Med J* 2015;128:674-679.
228. Wyers MC, Schermerhorn, ML, Fillinger MF, Powell RJ, Rzucidlo EM, Walsh DB, Zwolak RM, Cronenwett JL. Internal iliac occlusion without coil embolization during endovascular abdominal aortic aneurysm repair. *J Vasc Surg* 2002;36:1138-1145.
229. Yano OJ, Morrissey N, Eisen L, Faries PL, Soundararajan K, Wan S, Teodorescu V, Kerstein M, Hollier LH, Marin ML. Intentional internal iliac artery occlusion to facilitate endovascular repair of aortoiliac aneurysms. *J Vasc Surg* 2001;34:204-211.
230. Yoshida R, Yoshida WB, Kolvenbach R, Pinter L, Vieira PR. Retrograde endovascular treatment of internal iliac aneurysm in a patient with Marfan syndrome. *Vascular* 2010;18:235-241.
231. Yoshida Rde A, Yoshida WB, Kolvenbach R, Vieira PR. Modified “stent graft sandwich” technique for treatment of isolated common iliac artery aneurysm in patient with Marfan syndrome. *Ann Vasc Surg*. 2012;26(3):419.e7-9.
232. Zander T, Baldi S, Rabellino M, Rostagno R, Isaza B, Llorens R, Carreira JM, Maynar M. Bilateral hypogastric artery occlusion in endovascular repair of abdominal aortic aneurysms and its clinical significance. *J Vasc Interv Radiol* 2007;18:1481-1486.
233. Zhang T, Guo W, Ma X, Jia X, Liu X, Dong Y, Xiong J, Jia S. Novel-Designed Iliac Branch Stent Graft for Internal Iliac Artery Reconstruction during Aneurysm Repair. *Ann Vasc Surg* 2015; 29:189-196.

234. Zhang WW, Kulaylat MN, Anain PM, Dosluoglu HH, Harris LM, Cherr GS, Dayton MT, Dryjski ML. Embolization as cause of bowel ischemia after endovascular abdominal aortic aneurysm repair. *J Vasc Surg* 2004;40(5):867-872.
235. Ziegler P, Avgerinos ED, Umscheid T, Perdikides T, Erz K, Stelter WJ. Branched iliac bifurcation: 6 years experience with endovascular preservation of internal iliac artery flow. *J Vasc Surg* 2007;46:204-210.
-

Eidesstattliche Versicherung

„Ich, Fakhri Abdo, versichere an Eides statt durch meine eigenhändige Unterschrift, dass ich die vorgelegte Dissertation mit dem Thema: *Total endovascular therapy of aortoiliac aneurysms with preservation of internal iliac artery patency using Iliac Branch Device (Zenith® Branch, COOK MEDICAL INCORPORATED)* selbstständig und ohne nicht offengelegte Hilfe Dritter verfasst und keine anderen als die angegebenen Quellen und Hilfsmittel genutzt habe.

Alle Stellen, die wörtlich oder dem Sinne nach auf Publikationen oder Vorträgen anderer Autoren beruhen, sind als solche in korrekter Zitierung (siehe „Uniform Requirements for Manuscripts (URM)“ des ICMJE -www.icmje.org) kenntlich gemacht. Die Abschnitte zu Methodik (insbesondere praktische Arbeiten, Laborbestimmungen, statistische Aufarbeitung) und Resultaten (insbesondere Abbildungen, Graphiken und Tabellen) entsprechen den URM (s.o) und werden von mir verantwortet.

Meine Anteile an etwaigen Publikationen zu dieser Dissertation entsprechen denen, die in der untenstehenden gemeinsamen Erklärung mit dem/der Betreuer/in, angegeben sind. Sämtliche Publikationen, die aus dieser Dissertation hervorgegangen sind und bei denen ich Autor bin, entsprechen den URM (s.o) und werden von mir verantwortet.

Die Bedeutung dieser eidesstattlichen Versicherung und die strafrechtlichen Folgen einer unwahren eidesstattlichen Versicherung (§156,161 des Strafgesetzbuches) sind mir bekannt und bewusst.“

Datum

Unterschrift

LEBENS LAUF

Mein Lebenslauf wird aus datenschutzrechtlichen Gründen in der elektronischen Version meiner Arbeit nicht veröffentlicht.

Danksagung

Für ihre vielfältige Unterstützung im Entstehungsprozess der vorliegenden Arbeit bin ich einer Reihe von Menschen zu Dank verpflichtet. An erster Stelle danke ich meinem Doktorvater, Herrn PD Dr. Ralph-I. Rückert, für die Anregung und Ermutigung zum Abfassen der Arbeit und für seine beharrlichen Nachfragen während des Schreibprozesses, die mich motiviert haben, die Arbeit zum Abschluss zu bringen.

Meiner Ehefrau Katharina Lange und unseren Kindern bin ich sehr dankbar für ihr Verständnis und ihre Geduld während der Abfassung der Arbeit.

Schließlich danke ich meinen Eltern, Mohamad Abdo und Almas Khalil, für ihre fortwährende und bedingungslose Unterstützung während meiner gesamten Ausbildungs- und Studienzeit. Ihnen und den Menschen meiner Heimat Syrien, insbesondere der Region Afrin, die unter Krieg und Vertreibung leiden, widme ich diese Arbeit.