

Ventricular Tachycardia (VT) Storm After Cryoballoon-Based Pulmonary Vein Isolation

Authors' Contribution:
Study Design A
Data Collection B
Statistical Analysis C
Data Interpretation D
Manuscript Preparation E
Literature Search F
Funds Collection G

ABDEF 1,2 **Paula Münkler**
ABD 3 **Alexander Wutzler**
E 4 **Philipp Attanasio**
E 1 **Martin Huemer**
E 1 **Abdul Shokor Parwani**
ACD 1 **Wilhelm Haverkamp**
CDE 2 **Christian Meyer**
ABDE 1 **Leif-Hendrik Boldt**

1 Department of Cardiology, Charité – Universitaetsmedizin Berlin, Campus Virchow-Klinikum, Berlin, Germany
2 Department of Cardiology – Electrophysiology, University Heart Center Hamburg, University Hospital Hamburg-Eppendorf, Hamburg, Germany
3 Cardiovascular Center, St. Josef-Hospital, University Hospital of the Ruhr-University of Bochum, Bochum, Germany
4 Department of Internal Medicine and Cardiology, Charité – Universitaetsmedizin Berlin, Campus Benjamin Franklin, Berlin, Germany

Corresponding Author: Paula Münkler, e-mail: p.muenkler@uke.de
Conflict of interest: None declared

Patient: Male, 57
Final Diagnosis: Ventricular arrhythmia
Symptoms: Dyspnea
Medication: —
Clinical Procedure: Pulmonary vein isolation
Specialty: Cardiology

Objective: Unusual clinical course





Background: Following catheter ablation of atrial fibrillation, increased incidence of ventricular arrhythmia has been observed. We report a case of sustained ventricular arrhythmia in a patient who underwent cryoballoon-based pulmonary vein isolation for symptomatic persistent atrial fibrillation.

Case Report: A 57-year-old patient with dilated cardiomyopathy underwent CB-based pulmonary vein isolation for symptomatic persistent AF. On the day following an uneventful procedure, the patient for the first time experienced a sustained ventricular tachycardia that exacerbated into VT storm. Each arrhythmia was terminated by the ICD that had been implanted for primary prevention. Antiarrhythmic treatment with amiodarone was initiated immediately. The patient remained free from sustained ventricular arrhythmia during follow-up.

Conclusions: After pulmonary vein isolation, physicians should be vigilant for ventricular arrhythmia. The influence of atrial autonomic innervation on ventricular electrophysiology is largely unknown.

MeSH Keywords: Atrial Fibrillation • Catheter Ablation • Tachycardia, Ventricular

Full-text PDF: <https://www.amjcaserep.com/abstract/index/idArt/908999>

 877  —  3  12



Background

Pulmonary vein isolation (PVI) for atrial fibrillation (AF) has been associated with increased incidence of premature ventricular contractions (PVC) and non-sustained ventricular tachycardia (nsVT) [1–3]. We report a case of new-onset sustained ventricular arrhythmia (VA) in a patient after cryoballoon (CB)-based PVI.

Case Report

A 58-year-old patient was admitted to our hospital for PVI for symptomatic persistent AF. The patient presented with dyspnea stage III (NYHA classification) and an obese nutritional condition (height 182 cm, body weight 123 kg, BMI 37). A dilated cardiomyopathy with reduced left ventricular ejection

fraction (25%) was known. The patient had no history of smoking. Coronary artery disease had been excluded via angiography 2 years previously in a community hospital. Cardiac magnetic resonance imaging had not been performed. The patient was carrying a dual-coil implantable cardioverter-defibrillator (ICD) (Fortify Assura, St. Jude Medical), which had been implanted 2 years prior to the procedure and never recorded any episode of ventricular tachycardia (VT) or ventricular fibrillation (VF).

Weight loss had been attempted unsuccessfully and after careful evaluation of risks and recurrence rates, we decided, in agreement with the patient, to perform PVI using a second-generation CB device. Cryo-energy was delivered at each pulmonary vein ostium for 360 s (Figure 1A, 1B). There was no vagal reaction during the procedure and all basic ECG-intervals remained normal. At the beginning of the procedure, the patient was in atrial fibrillation with a ventricular rate of

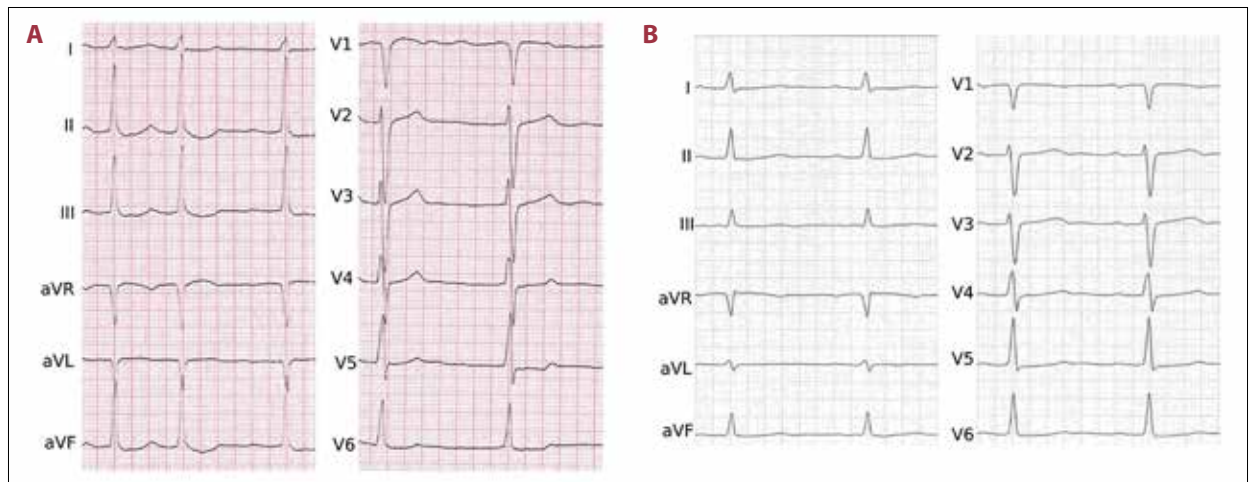


Figure 1. (A) 12-lead ECG (50 mm/s) pre-procedure showing atrial fibrillation with borderline rapid ventricular response, (B) 12-lead ECG (50 mm/s) post-procedure showing sinus rhythm with 76 bpm and normal QT-interval (PQ 180 ms, QRS 80 ms, QT 390 ms, QTc 440 ms).

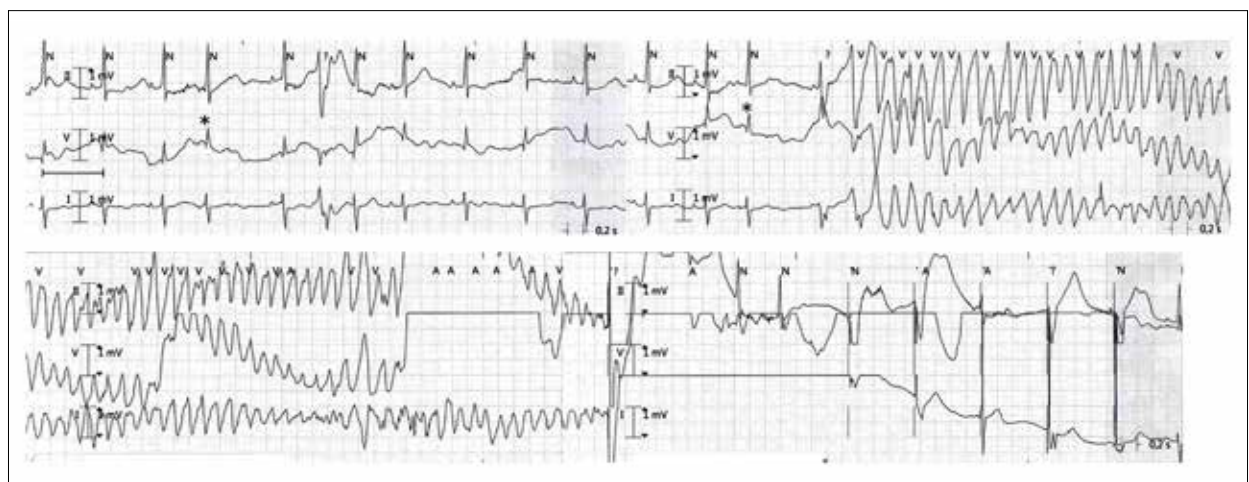


Figure 2. Onset of sustained VA and adequate ICD shock delivery registered in monitoring. Atrial extrasystoles are indicated by *.

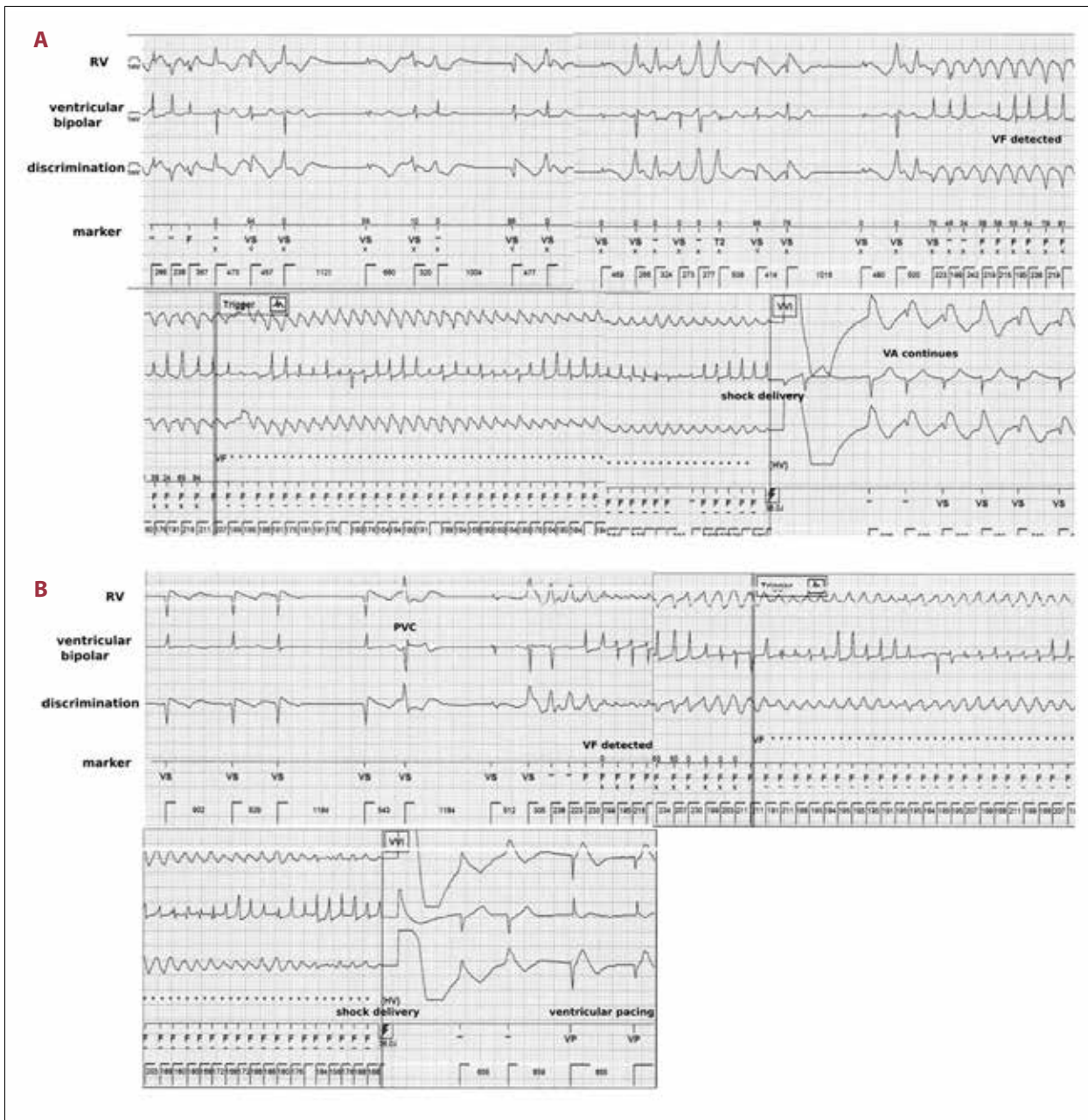


Figure 3. (A) ICD tracings of ventricular fibrillation, adequate shock delivery, sustained VA. (B) ICD tracings of repeated ventricular fibrillation, adequate shock delivery, and termination of VA.

110 bpm, which remained stable throughout the procedure. After PVI, electrical cardioversion established a stable sinus rhythm with a heart rate of 80 bpm. No relevant changes in blood pressure were registered before or after the procedure. The patient's regular intake of metoprolol had been continued. The anesthetic regimen consisted of midazolam, propofol, and piritramide according to the institutional standard. There were no drugs recently prescribed. Post-procedurally, the patient was in stable sinus rhythm and no antiarrhythmic therapy was initiated.

On the day following the intervention, the patient syncope twice and suffered a fracture of the fibula. ICD recordings showed sustained VA, each episode being terminated by ICD shock (Figure 2). Pericardial effusion was immediately excluded by echocardiography. Electrolyte disturbances (serum potassium was 3.8 mmol/l), QT-prolongation, and thyroidal dysfunction were ruled out. Hemoglobin and hematocrit remained stable. Coronary angiography excluded coronary artery occlusion. Antiarrhythmic treatment with amiodarone was initiated immediately, but ventricular arrhythmia exacerbated into an electrical

storm on the fourth postinterventional day, with 4 distinct episodes of sustained VA occurring within 24 hours; each was treated successfully by the ICD (Figure 3A, 3B). Antiarrhythmic treatment with amiodarone was continued under monitoring of the QT-interval and no further episodes of sustained VA occurred. In a follow-up exam 3 months after the intervention, no arrhythmic event had been recorded by the ICD.

Discussion

The case reported here gives an account of an electrical storm after CB-PVI. No incidence of sustained VA had been recorded by the ICD, which had been implanted for primary prevention of a known structural heart disease. The mechanism causing the VA post-procedurally is unknown. However, vagal denervation with concomitant sympathetic denervation on the atrial level has been found to increase VA in animal experiments [3,4].

Due to the anatomic proximity of atrial ganglionated plexus (GP) to the pulmonary veins [5], PVI does affect atrial GP [6]. Targeted ablation of atrial GP reduces ectopic activity of PV [7] and recurrence rates of AF following PVI [8,9]. While effects of neuromodulation on the atrial level after PVI are well known, evidence that modification of atrial GP also impacts ventricular electrophysiology is more recent: animal experiments found a predisposition to ventricular arrhythmia after ablation or mechanical disruption of atrial GP [3,4]. In clinical studies, an increased incidence of VA following PVI has been observed [1–3,10]. In patients with structural heart disease, sympathetic ventricular innervation is impaired [11,12], and additional modification of atrial GP may increase the risk of malignant VA. This case report cannot explain the pathomechanism of the VA and the causality of the PVI cannot be proved. Other causes of VA, such as electrolyte disturbances, pericardial effusion, thyroidal dysfunction, and QT-prolongation, had been ruled out. Based on experimental data, we hypothesize a modulation of atrial autonomic innervation during PVI as a possible pathomechanism.

References:

1. Patel PJ, Ahlemeyer L, Freas M et al: Outflow tract premature ventricular depolarizations after atrial fibrillation ablation may reflect autonomic influences. *J Interv Card Electrophysiol*, 2014; 41: 187–92
2. Wu L, Lu Y, Yao Y et al: New-onset ventricular arrhythmias post radiofrequency catheter ablation for atrial fibrillation. *Medicine (Baltimore)*, 2016; 95: e4648
3. Jungen C, Scherschel K, Eickholt C et al: Disruption of cardiac cholinergic neurons enhances susceptibility to ventricular arrhythmias. *Nat Commun*, 2017; 8: 14155
4. He B, Lu Z, He W et al: Effects of ganglionated plexi ablation on ventricular electrophysiological properties in normal hearts and after acute myocardial ischemia. *Int J Cardiol*, 2013; 168: 86–93
5. Armour JA, Murphy DA, Yuan BX et al: Gross and microscopic anatomy of the human intrinsic cardiac nervous system. *Anat Rec*, 1997; 247: 289–98
6. Yorgun H, Aytemir K, Canpolat U et al: Additional benefit of cryoballoon-based atrial fibrillation ablation beyond pulmonary vein isolation: Modification of ganglionated plexi. *Europace*, 2014; 16: 645–51
7. Nakagawa H, Scherlag BJ, Patterson E et al: Pathophysiologic basis of autonomic ganglionated plexus ablation in patients with atrial fibrillation. *Hear Rhythm*, 2009; 6: S26–34
8. Katritsis DG, Pokushalov E, Romanov A et al: Autonomic denervation added to pulmonary vein isolation for paroxysmal atrial fibrillation. *J Am Coll Cardiol*, 2013; 62: 2318–25
9. Pokushalov E, Romanov A, Katritsis DG et al: Ganglionated plexus ablation vs. linear ablation in patients undergoing pulmonary vein isolation for persistent/long-standing persistent atrial fibrillation: A randomized comparison. *Heart Rhythm*, 2013; 10: 1280–86

Interestingly, no vagal reaction occurred during the procedure. Because the patient was in persistent AF previous to the procedure, heart rate and heart rate variability before and after the PVI cannot be compared.

VT did not recur. As the cause of VA induction after PVI itself remains unclear, we can only speculate whether the regeneration of atrial cholinergic innervation was anti-arrhythmic.

This is the first published report of periprocedural sustained VA of unknown origin following PVI. Recent findings, however, hint at a role of atrial intrinsic nervous structures in ventricular electrophysiology. It should therefore be taken into consideration that left atrial ablation in PVI may affect electrophysiological properties of the ventricle.

Conclusions

This case report emphasizes that, in clinical routine, cardiologists must be aware of the risk of potentially life-threatening VA after PVI.

Acknowledgements

We acknowledge support from the German Research Foundation (DFG) and the Open Access Publication Fund of Charité – Universitätsmedizin Berlin.

Department and Institution where work was done

Department of Cardiology, Charité – Universitätsmedizin Berlin, Campus Virchow-Klinikum, Berlin, Germany.

Conflicts of interest

None.

10. Osman F, Kundu S, Tuan J et al: Ganglionic plexus ablation during pulmonary vein isolation – predisposing to ventricular arrhythmias? *Indian Pacing Electrophysiol J*, 2010; 10: 104–7
11. Nagao M, Baba S, Yonezawa M et al: Prediction of adverse cardiac events in dilated cardiomyopathy using cardiac T2* MRI and MIBG scintigraphy. *Int J Cardiovasc Imaging*, 2015; 31: 399–407
12. Jungen C, Von Gogh G, Schmitt C et al: Mismatch between cardiac perfusion, sympathetic innervation, and left ventricular electroanatomical map in a patient with recurrent ventricular tachycardia. *Am J Case Rep*, 2016; 17: 280–82