

Aus dem
CharitéCentrum für Neurologie, Neurochirurgie und Psychiatrie
Klinik für Psychiatrie und Psychotherapie
Direktor: Professor Dr. med. Andreas Heinz

Habilitationsschrift

Structural Neuroimaging Research in Elderly Depression: Findings and Possible Implications for Development and Progression of the Illness

zur Erlangung der Lehrbefähigung
für das Fach

Psychiatrie

vorgelegt dem Fakultätsrat der Medizinischen Fakultät
Charité –Universitätsmedizin Berlin

von
Frau Dr. Martina Ballmaier

eingereicht am: Oktober/2007
Dekan: Prof. Dr. med. M. Paul

1. Gutachter: Prof. Dr. med. H.J. Freyberger, Greifswald

2. Gutachter: Prof. Dr. med. S. Herpertz, Rostock

Contents

1.	Introduction	3
2.	Own previous work	
2.1	Ballmaier M , Toga AW, Blanton RE, Sowell ER, Lavretsky H, Peterson J, Pham D, Kumar A (2004a). Anterior cingulate, gyrus rectus, and orbitofrontal abnormalities in elderly depressed patients: an MRI-based parcellation of the prefrontal cortex. <i>Am J Psychiatry</i> 161:99-108.	6
2.2	Ballmaier M , Sowell ER, Thompson PM, Kumar A, Narr KL, Lavretsky H, Welcome SE, DeLuca H, Toga AW (2004b). Mapping brain size and cortical gray matter changes in elderly depression. <i>Biol Psychiatry</i> 55:382-389.	17
2.3	Ballmaier M , Kumar A, Thompson PM, Narr KL, Lavretsky H, Estanol L, DeLuca H, Toga AW (2004c). Localizing gray matter deficits in late-onset depression using computational cortical pattern matching methods. <i>Am J Psychiatry</i> 161:2091-2099.	26
2.4	Ballmaier M , Narr KL, Toga AW, Elderkin-Thompson V, Thompson PM, Hamilton L, Haroon E, Pham D, Heinz A, Kumar A. Hippocampal morphology and distinguishing late-onset from early-onset elderly depression. In press, <i>Am J Psychiatry</i> , 2007a.	36
2.5	Ballmaier M , Kumar A, Elderkin-Thompson V, Narr KL, Luders E, Thompson PM, Hojatkashani C, Pham D, Heinz A, Toga AW. Mapping callosal morphology in early- and late-onset elderly depression: an index of distinct changes in cortical connectivity. In press, <i>Neuropsychopharmacology</i> , 2007b.	46
2.6	Lavretsky H, Ballmaier M , Pham D, Toga A, Kumar A (2007). Neuroanatomical characteristics of geriatric apathy and depression: a magnetic resonance imaging study. <i>Am J Geriatr Psychiatry</i> 15:386-394.	56

2.7	Lavretsky H, Roybal DJ, Ballmaier M , Toga AW, Kumar A (2005). Antidepressant exposure may protect against decrement in frontal gray matter volumes in geriatric depression. J Clin Psychiatry 66:964-967.	66
2.8	Lavretsky H, Kurbanyan K, Ballmaier M , Mintz J, Toga A, Kumar A (2004). Sex differences in brain structure in geriatric depression. Am J Geriatr Psychiatry 12:653-657.	71
3.	Discussion	77
4.	Summary	82
5.	References	86

1. Introduction

The bulk of the literature on neuroimaging investigations into the pathophysiology of major depression have revealed a complex set of abnormalities in multiple limbic and prefrontal cortical structures. Only in recent years, research has also begun to intensively focus on the neurobiological correlates of major depression in older age. Indeed, major depression is a common disorder in the elderly associated with substantial morbidity and mortality.

1-4% of the general elderly population has major depression (Blazer 2003), equivalent to an incidence of 0-15% per year. Twice as many women are affected. Both the prevalence (Palsson et al. 2001) and incidence (Teresi et al. 2001) of major depression double after age 70-85 years. In old age, depressive syndromes often affect people with medical illnesses, cognitive impairment, or disability (Alexopoulos et al. 2002; Blazer 2003). Beyond personal suffering and family disruption, depression worsens the outcomes of many medical disorders and promote disability (Alexopoulos et al. 2002). Although progress has been made in characterizing the presentation of late-life depression and in improving treatment, it continues to have detrimental consequences with a high risk of suicide (Charney et al. 2003).

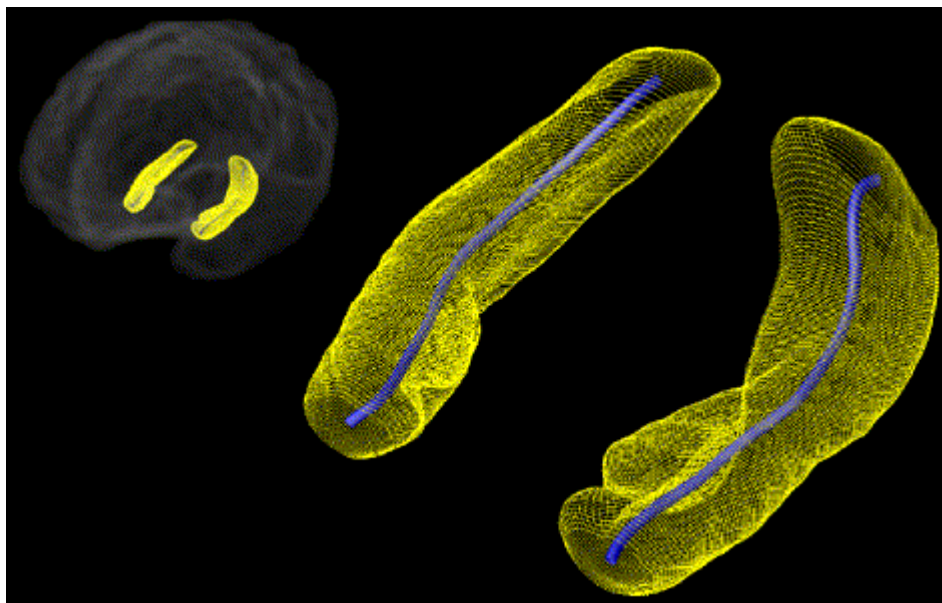
For a diagnosis of major depression to be made, ICD-10 or DSM-IV state that depressed mood, loss of interest or pleasure must be present. Although not part of the diagnostic criteria, elderly depression is often associated with peripheral body changes and cognitive impairment. Changes to the body include hypercortisolemia, increased abdominal fat, decreased bone density, and increased risk for type II diabetes and hypertension (Brown et al. 2004). Non-demented elderly people with major depression often have difficulties with concentration, speed of mental processing, and executive function (Lockwood et al. 2002; Elderkin-Thompson et al. 2003). These deficits improve but may not completely solve after remission of elderly depression (Butters et al. 2000; Nebes et al. 2002).

Importantly, major depression, especially in the elderly, may be considered a heterogeneous disorder. Elderly individuals with depression may have had multiple episodes of depression, starting earlier in life; alternatively, they may have had no psychiatric history, becoming depressed for the first time later in life. Several distinctions between these groups have been identified, such that subjects with early-onset depression are more likely to have a family history of psychiatric illness, while subjects with late-onset

depression are more likely to have greater subcortical ischemic disease. Some evidence links late-onset depression to increased risk of developing dementia. These findings have been interpreted to be signs of different causes or risk factors for depression based on age at depression onset.

Elderly depression is accompanied by clinical, neuropsychological and neuroimaging findings pointing to specific brain abnormalities. Several recent methodological developments and analytic methods have played a major role in examining brain structure abnormalities and their implications in older people with major depression. Volumetric region of interest analyses of specific brain regions still have an important impact on the evaluating of volumetric alterations. However, reductions of morphometric results into a single volume may overlook regional specificity that may add insight into the pathophysiological mechanisms underlying elderly depression. Highly sophisticated computational image methods, known as cortical pattern matching and surface-based mesh modeling, enable the measurement and visualization of subtle and anatomically selective brain changes most vulnerable to disease processes.

Highly sophisticated computational image methods



Cortical mapping methods allow data from each individual to be analyzed with a series of manual and automated procedures that carefully match cortical anatomy across subjects and measure local proportions of gray matter at each of the 65,536 anatomically matched points on the cortical surface.

In addition, surface-based mesh modeling techniques are able to identify changes of specific brain structures, such as the hippocampus, at a very local level. Shape abnormalities are identified by comparing distances, measured from homologous surface points to the central core of each individual's surface model, between groups that allow for changes in surface deformation/expansion to be examined at high spatial resolution in three dimensions. Importantly, damage to particular subregions may produce different functional and clinical consequences, because different cortical projections may be involved. Identifying regional local changes in a given brain structure may therefore point to disturbances in the neural network subserving functions that may be differentially affected based on age at illness onset. Moreover, these brain mapping techniques can identify how local changes correlate with cognitive function, which may yield novel observations of structural brain alterations and their relationship to course of illness. In addition, they may offer new perspectives for defining risk profiles and appropriate interventions.

In the work presented here, these sophisticated techniques were applied to shed light on the neuroanatomical correlates and neural network abnormalities of elderly depression. Specifically, differences in morphometry were assessed in the cortex, the hippocampus and the corpus callosum based on age at onset of depression, which have not been specifically addressed in the literature. Relations of these structural brain abnormalities to cognitive measures, treatment response and gender were also examined. These approaches allowed us to generate new hypotheses for a more comprehensive understanding of the complex nature of elderly depression.

2.1 **Ballmaier M**, Toga AW, Blanton RE, Sowell ER, Lavretsky H, Peterson J, Pham D, Kumar A (2004a). Anterior cingulate, gyrus rectus, and orbitofrontal abnormalities in elderly depressed patients: an MRI-based parcellation of the prefrontal cortex. *Am J Psychiatry* 161:99-108.

2.2 **Ballmaier M**, Sowell ER, Thompson PM, Kumar A, Narr KL, Lavretsky H, Welcome SE, DeLuca H, Toga AW (2004b). Mapping brain size and cortical gray matter changes in elderly depression. *Biol Psychiatry* 55:382-389.

2.3 **Ballmaier M**, Kumar A, Thompson PM, Narr KL, Lavretsky H, Estanol L, DeLuca H, Toga AW (2004c). Localizing gray matter deficits in late-onset depression using computational cortical pattern matching methods. *Am J Psychiatry* 161:2091-2099.

2.4 **Ballmaier M**, Narr KL, Toga AW, Elderkin-Thompson V, Thompson PM, Hamilton L, Haroon E, Pham D, Heinz A, Kumar A. Hippocampal morphology and distinguishing late-onset from early-onset elderly depression. In press, *Am J Psychiatry*, 2007a.

2.5 **Ballmaier M**, Kumar A, Elderkin-Thompson V, Narr KL, Luders E, Thompson PM, Hojatkashani C, Pham D, Heinz A, Toga AW. Mapping callosal morphology in early- and late-onset elderly depression: an index of distinct changes in cortical connectivity. In press, *Neuropsychopharmacology*, 2007b.

2.6 Lavretsky H, **Ballmaier M**, Pham D, Toga A, Kumar A (2007). Neuroanatomical characteristics of geriatric apathy and depression: a magnetic resonance imaging study. *Am J Geriatr Psychiatry* 15:386-394.

2.7 Lavretsky H, Roybal DJ, **Ballmaier M**, Toga AW, Kumar A (2005). Antidepressant exposure may protect against decrement in frontal gray matter volumes in geriatric depression. *J Clin Psychiatry* 66:964-967.

2.8 Lavretsky H, Kurbanyan K, **Ballmaier M**, Mintz J, Toga A, Kumar A (2004). Sex differences in brain structure in geriatric depression. *Am J Geriatr Psychiatry* 12:653-657.

3. Discussion

Brain structure abnormalities in elderly depression involve frontal and temporal/parietal cortices, as well the hippocampus and the corpus callosum, which may be differentially affected based on age at illness onset. Abnormalities in more than one region might predispose to depression. There are at least two reasons for this assumption. First, abnormalities in one brain region might influence other functionally connected regions. Second, elderly patients might have vulnerabilities in more than one brain region with complex interactions, leading to vulnerability to depression.

Prefrontal cortex: Structural imaging research in elderly depression has provided evidence for reduced gray matter (Kumar et al. 1997, 1998) and white matter abnormalities in the frontal lobe (Nobuhara et al 2006), including the dorsolateral prefrontal cortex (Thomas et al. 2002, Taylor and Krishnan, 2003, Taylor et al. 2004), the orbitofrontal cortex (Lai et al. 2000; Taylor et al. 2003) and the anterior cingulate (Alexopoulos et al. 2002, Kumar et al. 2002; Bae et al. 2006). Using a detailed volumetric MRI-based parcellation of the prefrontal cortex, we have shown for the first time significant differential patterns of abnormalities in gray matter, white matter and cerebrospinal fluid volumes of the orbitofrontal cortex, the gyrus rectus and anterior cingulate, implying that distinct etiopathological mechanisms may underlie the structural changes in these regions. Whether and to what extent length of depression history contributes to frontal abnormalities is yet to be clarified. In a further study on elderly depression with an early-onset, we mapped morphologic abnormalities to the entire cortical surface and showed highly significant decreased brain size along with complex cortical abnormalities in the orbitofrontal cortex, supporting previous post-mortem observations (Rajkowska et al. 2005) and the role of this region as a critical target of depressed mood (Drevets et al. 2000; Liotti et al. 2002). On the contrary, investigating elderly depression with a late onset by using computational cortical surface mapping, we could not detect any differences in frontal regions. Future longitudinal studies are needed to support this observation, and to examine how frontal lobe abnormalities are related to age of illness onset and to what extent they progress over time.

Temporal/parietal cortices: Whereas the prefrontal cortex has been a primary area of neuroimaging studies, the involvement of temporal/parietal cortices in elderly

depression is less well established. Prior findings from structural MRI research implied mixed evidence for whole temporal lobe involvement in elderly depression (O'Brien et al. 1994; Kumar et al. 1998; Nobuhara et al. 2006). Using computational methods that map morphologic abnormalities to the entire cortical surface, we detected apparent gray matter *increases* in temporal cortices in early-onset depression, whereas patients with a late-onset of illness exhibited pronounced *decreases* of temporal gray matter. Similar differences based on age at illness onset were seen in parietal cortices. Apparent gray matter *increase* might reflect axonal myelin reduction (that diminishes white matter signal values, thus increasing gray matter appearance), whereas gray matter *decrease* might occur when degeneration of neuronal cell bodies overtakes reduced myelin formation.

In my two studies using the sensitive computational cortical pattern matching methods, early- and late-onset depression groups were compared to controls. In these studies, disease groups were not directly compared between each other. Nevertheless, our findings suggest that late-onset depression may present with more advanced atrophic or neurodegenerative processes.

Hippocampus: Structural imaging studies have reported decreased volumes of the hippocampus in major depression, including elderly patients (Steffens et al. 2000; Bell-McGinty et al. 2002, Janssen et al. 2004; Frodl et al. 2004; O'Brien et al. 2004, Hickie et al. 2005). These changes may be more pronounced in key clinical subgroups (e.g. early- or late-onset groups) and in subjects with genetic risk factors (Kim et al. 2002; Taylor et al. 2005). Using novel surface-based mesh modeling methods, we identified the hippocampal subregions most vulnerable to disease processes in elderly patients with early- and late-onset depression. Regional atrophy patterns were significantly more pronounced in late-onset than early-onset depression, with concentrated volume reductions in anterior aspects of the subiculum and lateral-posterior aspects of the CA1 subfield. In addition, significant shape differences were observed bilaterally in anterior CA1-CA3 subfields and the subiculum in all depressed patients compared to controls, results that were similar when each disease group was compared to control subjects separately.

Since projections to and from the prefrontal cortices occur in a gradient concentrated in anterior hippocampal regions (Barbas and Blatt, 1995; Cavada et al. 2000), these findings are in line with our previous investigations in elderly depression showing bilateral gray matter abnormalities in distinct subregions of the prefrontal cortex. We also found that late-onset depression may be associated with greater cortical atrophy

than early-onset depression, especially in temporal and parietal regions. This may offer a potential explanation as to more pronounced local volume reductions in both hippocampal head and tail of late-onset compared to early-onset depressed subjects. In addition, greater CA1 involvement in late-onset depression may suggest that these patients might be at higher risk to develop dementia over time. Indeed, lateral edge atrophy in regions corresponding to CA1 has been found in patients with mild cognitive impairment who later developed Alzheimer's disease (Apostolova et al. 2006). Therefore, identifying regional abnormalities in hippocampal structure may help elucidate which neural systems are most vulnerable to the disorder and may prove useful for dissociating early-onset from late-onset depression.

Corpus callosum: The question of callosal abnormalities in elderly depression has not been specifically addressed in the literature. Our study was the first to examine regional alterations of callosal morphology in elderly depression and to shed light on the hypothesis that late-onset depression may present certain unique disease effects on callosal morphology that may differ from elderly patients with an early onset of illness.

Interestingly, subjects with late-onset depression showed callosal thinning in the splenium compared to subjects with early-onset depression. In addition, greater callosal thinning in the genu and the splenium were observed in all depressed patients compared to controls. Comparison between the early-onset depression group and controls revealed callosal thinning restricted to the genu, while the late-onset depression group exhibited reductions in both the genu and the splenium relative to controls.

The anterior part of the corpus callosum is composed by fibers connecting prefrontal, premotor and motor areas, whereas the caudal part is composed by fibers connecting temporal, parietal and occipital areas (de Lacoste et al. 1985; Pandya and Rosene 1985; Pandya and Seltzer 1986).

In light of these connectivity patterns, our observation of callosal thinning in the genu in the early-onset group could be an indicator of altered prefrontal connections, which is in accordance with our previous results of structural prefrontal alterations in depressed elders with an early onset of illness. On the other hand, callosal thinning in both the genu and the splenium in late-onset depression relative to controls may be suggestive of more diffuse changes in cortico-cortical connectivity. This may support our findings of cortical temporal and parietal gray matter reductions in late-onset depression.

Furthermore, greater splenium thinning in late-onset compared to early-onset depression might point to more prominent atrophic or neurodegenerative processes in temporal connections, in accordance with studies showing greater temporal lobe (Greenwald et al. 1997; Kumar et al. 1998) atrophy and hippocampal volume reductions (Steffens et al. 2000; Lloyd et al. 2004; Hickie et al. 2005) in late-onset than early-onset depression. In addition, splenium thinning supports our own findings of more pronounced local surface deformations in the hippocampus in late-onset depression, which may place these patients at higher risk for dementia.

Cognitive measures and brain correlates: Although a variety of studies found different clinical characteristics to be associated with impaired cognition, including depression severity (Boone et al. 1995; Barnes et al. 2006; Sheline et al. 2006), history of depression (Beats et al. 1996; Ownby et al. 2006), age (King et al. 1995; Lyness et al. 2002), late age of depression onset (van Ojen et al. 1995; Salloway et al. 1996; Geda et al. 2006), and vascular disease (O'Brien et al. 2003; Sheline et al. 2006), relatively little is known about the relationship between cognitive measures and structural abnormalities in specific brain regions.

We observed that apathy, a key component of executive dysfunction (Lockwood et al. 2002), is preferentially associated with structural abnormalities in distinct frontal regions, including the anterior cingulate. On the other hand, structural brain abnormalities can also correlate with neuropsychological measures when they are still in the normal range. This association may reflect an early indicator of cognitive impairment becoming clinically evident only with further illness progression. Indeed, our research on callosal abnormalities in elderly depression suggested a strong relationship between reduced genu and splenium volumes and normal learning and attention functioning, respectively, in late-onset depression, but not early-onset depression or controls. In addition, our study in the hippocampus found a strong correlation for the CA1 subfield and the subiculum and normal verbal as well as nonverbal memory performance in late-onset but not early-onset depression or controls.

Future longitudinal studies may be needed to clarify how the associations between local callosal and hippocampal abnormalities and neuropsychological functioning may predict later cognitive decline and whether late-onset depression is more vulnerable to dementia conversion.

Effects of antidepressant treatments: Research on treatment of elderly depression has yielded mixed results. This may be, at least partly, related to concomitant cognitive impairments (Alexopoulos et al. 2000; Butters et al. 2000; Nebes et al. 2003; O'Brien et al. 2004). Patients with poor response to antidepressant treatment appear at increased risk of developing dementia (Modrego and Ferrández 2004). On the other hand, antidepressant treatments, if effective, could contribute to counteract cognitive decline (Steffens et al. 2006).

We found that elderly depressed patients with prior history of antidepressant exposure had larger gray matter volumes of the orbitofrontal cortex than those without such an exposure. Interestingly, the drug-naïve group had the smallest orbitofrontal gray matter volumes, followed by the antidepressant-exposed group, and by normal controls. This effect warrants further investigation, also in light of a more recent study in elders by Geda et al. (2006) who found that prior history of depression rather than a late onset of illness may protect against mild cognitive impairment, relating this interaction to possible protective effects of antidepressant medications in subjects with recurrent depressive episodes during lifetime.

Influence of gender: Twice as many women as men are affected by major depression among elders. In all my studies, approximately two thirds of the subjects were women. We appropriately corrected for potential interindividual differences in brain size that might be associated with gender. However, the contribution of gender to structural abnormalities in elderly depression may deserve attention. We specifically addressed gender differences in brain structure in one study and found smaller frontal gray matter volumes in older men than women in both groups (patients and controls). In addition, the diagnosis x gender interaction became only significant after controlling for medical burden. This might imply that there are gender differences in the patterns of medical burden that may affect brain atrophy and may increase the risk of elderly depression. Frontal gray matter reductions might be one of the underlying mechanisms that may predispose older men to depression. Interestingly, our study on gender differences reported a greater proportion of men with late-onset depression than women, in line with earlier investigations (Krishnan et al. 1995). Therefore, exploring gender differences directly in future studies might add further valuable insight to the pathophysiology of elderly depression based on age at illness onset.

4. Summary

Findings from our MRI studies in elderly depression employing traditional volumetric region of interest analyses as well as sophisticated brain mapping methods have enabled us to identify complex morphological changes in frontal and temporoparietal cortical gray matter, as well as highly localized abnormalities in functionally relevant subregions of the hippocampus and the corpus callosum, which may reflect differential patterns of atrophic or neurodegenerative processes, possibly influenced by age at illness onset. We have also observed that apathy, a crucial component of executive dysfunction commonly observed in depressed elders, relates to structural changes in distinct frontal regions, such as the anterior cingulate.

Furthermore, we have shown that memory and attention performances correlate with regional hippocampal and callosal abnormalities among late-onset but not early-onset depression or controls. Since neuropsychological measures were in the normal range in this elderly depressed population, these results may suggest that regional hippocampal and callosal atrophy patterns and their associations with memory and/or attention could become apparent prior to clinical evidence of cognitive decline. Exploring abnormalities at a very local level may thus help identify risk profiles by dissociating possible neuroanatomic vulnerabilities to illness progression based on age at onset. Moreover, we have provided preliminary evidence for gender differences in critical brain regions involved in elderly depression. Finally, we have shown that antidepressant exposure may be neuroprotective against frontal gray matter loss in depressed elders.

Although cross-sectional studies are informative, prospective longitudinal designs may ultimately be necessary for answering questions about (1) the neurobiological differences in early-onset versus late-onset depression and the impact of repeated depressive episodes across the life span; (2) the neurobiology of treatment-responsive and treatment-resistant depression with focus on the domains of cognitive function that improve with antidepressant therapy compared to those that remain impaired after remission of mood symptoms; (3) neurobiological vulnerability markers and prevention strategies by studying such “at risk” subject samples, including patients with depression secondary to significant psychosocial stressors (bereavement, caregiver burden), medical illness (cardiovascular disease or stroke), or medical interventions (interferon-induced depressive symptoms, beta-blocker induced depressive symptoms). In addition, future investigations will integrate multimodal imaging approaches (diffusion tensor imaging,

functional neuroimaging including positron emission tomography) with genetic methods, thereby providing important information regarding for example the role of specific genetic polymorphisms with respect to altered neural circuitry and neurotransmitter pathways. The integration of genetic and neuroimaging data will ultimately foster a more comprehensive delineation of neurobiological subtypes of depression that might relate to different patterns of age at onset, disease course or treatment response.

4. Zusammenfassung

Die vorliegende Arbeit fasst meine Forschungstätigkeit zusammen, der die Untersuchungen von morphologischen Veränderungen im Gehirn und deren Bedeutung bei Major Depression im Alter gewidmet sind. In meinen Arbeiten mit struktureller Bildgebung, bei denen klassische Ansätze zur Volumetriebestimmung und hauptsächlich neu entwickelte computerisierte Methoden - auch „cortical pattern matching“ und „surface-based mesh modeling“ genannt - verwendet wurden, konnten komplexe Veränderungen in frontalen, parietalen und temporalen Kortexarealen und in limbischen Strukturen gezeigt werden, die auf unterschiedliche Formen von atrophischen oder neurodegenerativen Prozessen hinweisen, welche durch das Alter bei Beginn der Erkrankung beeinflusst werden. So ist in Gehirnen von Patienten mit spätem Krankheitsbeginn eine verbreitete Abnahme der kortikalen Dichte im temporalen und parietalen Kortex gefunden worden, die am ehesten neurodegenerativ bedingt sein kann. Diese Veränderungen unterschieden sich von denen bei Patienten mit frühem Krankheitsbeginn, wo zum Beispiel Areale von erhöhter wie auch verringerter kortikaler Dichte im orbitofrontalen Kortex beobachtet wurden, was weniger ausgeprägte degenerative Prozesse annehmen lässt.

Zudem hat die Anwendung von Techniken des drei-dimensionalen „surface-based mesh modeling“ ermöglicht, feinste regional spezifische Veränderungen im Hippocampus und im Corpus callosum zu identifizieren, wobei sich auch hier vermehrt ausgeprägte Veränderungen bei Individuen mit spätem Krankheitsbeginn ergaben. Schäden in bestimmten Subregionen einer Hirnstruktur können unterschiedliche funktionelle und klinische Auswirkungen haben, da verschiedene kortikale Projektionen beteiligt sind. Daher konnten wir spezifische Hypothesen zu neuronalen Konnektivitätsstörungen formulieren, die zu einem besseren Verständnis der Pathophysiologie von depressiven Syndromen unter Berücksichtigung des Alters bei Beginn der Erkrankung führen.

Des Weiteren wurde gefunden, dass Verhaltensstörungen wie Apathie, die zu den wichtigsten exekutiven Funktionseinschränkungen gehören, mit strukturellen Veränderungen in spezifischen frontalen Regionen, insbesondere im Gyrus cinguli anterior, einhergehen. Ferner haben wir gezeigt, dass Veränderungen in spezifischen Subregionen des Hippocampus und des Corpus callosum mit bestimmten Gedächtnis- und Aufmerksamkeitsfunktionen bei Menschen mit spätem Krankheitsbeginn, aber nicht bei Individuen mit frühem Krankheitsbeginn korrelieren. Da die in dieser Studie eingeschlossenen Patienten keine klinisch zu erkennenden kognitiven Defizite aufwiesen,

kann die Hypothese aufgestellt werden, dass unsere beobachteten Korrelationen bei Depressionen mit spätem Krankheitsbeginn der frühe neurobiologische Indikator einer fortschreitenden Erkrankung sind, die erst zu einem späteren Zeitpunkt klinisch manifest wird. In einer weiteren Studie ergaben sich zudem erste Hinweise für eine erhöhte Gesamthirnatrophie und Frontalatrophie bei älteren Männern im Vergleich zu Frauen, was den möglichen Einfluss von geschlechtsspezifischen Faktoren beim Auftreten von depressiven Syndromen im Alter nahe legt. Schließlich hat eine Studie auch gezeigt, dass Antidepressiva der Reduktion von kortikaler Substanz in frontalen Regionen – möglicherweise im Sinne einer Neuroprotektion - entgegenwirken können.

Unsere Daten unterstreichen die Wichtigkeit, reliable klinische und neurobiologische Korrelate zu identifizieren, die eine Einteilung von Patienten mit depressiven Episoden im Alter nach den zugrunde liegenden pathophysiologischen Veränderungen erlauben. Dies kann wesentlich dazu beitragen, die Pharmakotherapie und damit den Behandlungserfolg zu optimieren. Somit wird das Ziel zukünftiger Forschungsvorhaben sein, Patienten im Längsschnitt zu untersuchen und zu prüfen, ob sich die von uns beobachteten strukturellen Veränderungen unter angemessener Therapie zurückbilden und auch eine mögliche Entwicklung zur Demenz vorbeugt werden kann. Dabei könnten multimodale bildgebende Verfahren (Diffusion-Tensor Bildgebung, funktionelle Bildgebung einschliesslich Positron-Emissions-Tomographie) mit genetischen Untersuchungen kombiniert werden, um zum Beispiel Einblicke in die Bedeutung von bestimmten genetischen Polymorphismen bei der Veränderung von neuronalen Netzwerken und Neurotransmitterprofilen zu gewinnen. Diese zukünftigen Forschungsstrategien werden eine noch verfeinerte Charakterisierung von Depressionssubtypen in Bezug auf Alter bei Beginn der Erkrankung, Krankheitsverlauf und Behandlungserfolg ermöglichen.

5. References

- Alexopoulos GS, Meyers BS, Young RC, Kalayam B, Kakuma T, Gabrielle M, Sirey JA, Hull J (2000). Executive dysfunction and long-term outcomes of geriatric depression. *Arch Gen Psychiatry* 57:285-290.
- Alexopoulos GS, Kiosses DN, Choi SJ, Murphy CF, Lim KO (2002). Frontal white matter microstructure and treatment response of late-life depression: a preliminary study. *Am J Psychiatry* 159:1929-1932.
- Apostolova LG, Dutton RA, Dinov ID, Hayashi KM, Toga AW, Cummings JL, Thompson AW (2006). Conversion of mild cognitive impairment to Alzheimer disease predicted by hippocampal atrophy maps. *Arch Neurol* 63:693-699.
- Bae JN, MacFall JR, Krishnan KRR, Payne ME, Steffens DC, Taylor WD (2006). Dorsolateral prefrontal cortex and anterior cingulate cortex white matter alterations in late-life depression. *Biol Psychiatry* 60:1356-1363.
- Barbas H, Blatt GJ (1995). *Hippocampus* 3:511-533.
- Barnes DE, Alexopoulos GS, Lopez OL, Williamson JD, Yaffe K (2006). Depressive symptoms, vascular disease, and mild cognitive impairment. *Arch Gen Psychiatry* 63:273-280.
- Beats BC, Sahakian BJ, Levy R (1996). Cognitive performance in tests sensitive to frontal lobe dysfunction in the elderly depressed. *Psychol Med* 26:591-603.
- Bell-McGinty S, Butters MA, Meltzer CC, Greer PJ, Reynolds CF, Becker JT (2002). Brain morphometric abnormalities in geriatric depression: long-term neurobiological effects of illness duration. *Am J Psychiatry* 159:1424-1427.
- Blazer DG (2003). Depression in late life: review and commentary. *J Gerontol A Biol Sci Med Sci* 58:249-265.
- Boone KB, Lesser IM, Miller BL, Wohl M, Berman N, Lee A, Palmer B (1994). Cognitive functioning in a mildly to moderately depressed geriatric sample: relationship to chronological age. *J Neuropsychiatry Clin Neurosci* 6:267-272.
- Brown ES, Varghese FP, McEwen BS (2004). Association of depression with medical illness: does cortisol play a role? *Biol Psychiatry* 55:1-9.
- Butters MA, Becker JT, Nebes RD, Zmuda MD, Mulsant BH, Pollock BG, Reynolds CF (2000). Changes in cognitive functioning following treatment of late-life depression. *Am J Psychiatry* 157:1949-1954.

Cavada C, Company T, Tejedor J, Cruz-Rizzolo RJ, Reinoso-Suarez F (2000). The anatomical connections of the macaque monkey orbitofrontal cortex. A review. *Cereb Cortex* 10:220-242.

Charney DS, Reynolds CF, Lewis L, Lebowitz BD, Sunderland T, Alexopoulos GS, Balzer DG, Katz IR, Meyers BS, Arean PA, Borson C, Bruce ML, Callahan CM, Charlson ME, Conwell Y, Cuthbert BN, Devanand DP, Gibson MJ, Gottlieb GL, Krishnan KR, Laden SK, Lyketsos CG, Mulsant BH, Niederehe G, Olin JT, Oslin DW, Pearson J, Persky T, Pollock BG, Raetzman S, Reynolds M, Salzman C, Schulz R, Schwenk TL, Scolnick E, Unutzer J, Weissman MM, Young RC (2003). Depression and bipolar support alliance consensus statement on the unmet needs in diagnosis and treatment of mood disorders in late-life. *Arch Gen Psychiatry* 60:664-672.

De Lacoste MC, Kirkpatrick JB, Ross ED (1985). Topography of the human corpus callosum. *J Neuropathol Exp Neurol* 6:578-591.

Drevets WC (2000): Neuroimaging studies in mood disorders. *Biol Psychiatry* 48: 813-829.

Elderkin-Thompson V, Kumar A, Bilker WB, Dunkin JJ, Mintz J, Moberg PJ (2003). Neuropsychological deficits among patients with late-onset minor and major depression. *Arch Clin Neuropsychol* 18:529-549.

Frodl T, Meisenzahl EM, Zill P, Baghai T, Rujescu D, Leinsinger G, Bottlender R, Schüle C, Zwanger P, Engel RR, Rupprecht R, Bondy B, Reiser M, Möller H (2004). Reduced hippocampal volumes associated with the long variant of the serotonin transporter polymorphism in major depression. *Arch Gen Psychiatry* 61:177-183.

Geda YE, Knopman DS, Mrazek DA, Jicha GA, Smith GE, Negash S, Boeve BF, Ivnik RJ, Petersen RC, Shane Pankratz V, Rocca WA (2006). Depression, apolipoprotein E genotype, and the incidence of mild cognitive impairment. *Arch Gen Psychiatry* 63:435-440.

Greenwald BS, Kramer-Ginsberg E, Bogerts B, Ashtaru M, Aupperle PM, Wu H, Allen L, Zeman D, Patel M (1997). Qualitative magnetic resonance imaging findings in geriatric depression. Possible link between later-onset depression and Alzheimer's disease? *Psychol Med* 27: 421-431.

Hickie I, Naismith S, Ward PB, Turner K, Scott E, Mitchell P, Wilhelm K, Parker G (2005). Reduced hippocampal volumes and memory loss in patients with early- and late-onset depression. *Br J Psychiatry* 186:197-202.

Janssen J, Hulshoff Pol HE, Lampe IK, Schnack HG, de Leeuw F, Kahn RS, Heeren TJ (2004). Hippocampal changes and white matter lesions in early-onset depression. *Biol Psychiatry* 56:8325-831.

Kim DH, Payne ME, Levy RM, MacFall JR, Steffens DC (2002). APOE genotype and hippocampal volume change in geriatric depression. *Biol Psychiatry* 51:426-429.

King DA, Cox C, Lyness JM, Caine ED (1995). Neuropsychological effects of depression and age in an elderly sample: a confirmatory study. *Neuropsychology* 9:399-408.

Krishnan KR, Hays JC, Tupler LA, George LK, Blazer DG (1995). Clinical and phenomenological comparisons of late-onset and early-onset depression. *Am J Psychiatry* 152:785-788.

Kumar A, Schweizer E, Jin Z, Miller D, Bilker W, Swan LL, Gottlieb G (1997). Neuroanatomical substrates of late-life minor depression: a quantitative magnetic resonance imaging study. *Arch Neurology* 54:613-617.

Kumar A, Zin Z, Bilker W, Udupa J, Gottlieb G (1998). Late onset minor and major depression: early evidence for common neuroanatomical substrates detected by using MRI. *Proc Natl Acad Sci USA* 95:7654-7658.

Kumar A, Thomas A, Lavretsky H, Yue K, Curran J, Venkatraman T, Estanol L, Mintz J, Mega M, Toga A (2002). Frontal white matter biochemical abnormalities in late-life major depression detected with proton magnetic resonance spectroscopy. *Am J Psychiatry* 159:630-636.

Lai TJ, Payne ME, Byrum CE, Steffens DC, Krishnan KRR (2000). Reduction of orbital frontal cortex volume in geriatric depression. *Biol Psychiatry* 48:971-975.

Liotti M, Mayberg HS, McGinnis S, Brannan SL, Jerabek P (2002). Unmasking disease-specific cerebral blood flow abnormalities: mood challenge in patients with remitted unipolar depression. *Am J Psychiatry* 159:1830-1840.

Lloyd AJ, Ferrier IN, Barber R, Gholkar A, Young AH, O'Brien JT (2004). Hippocampal volume change in depression: late- and early-onset compared. *Br J Psychiatry* 184:488-495.

Lockwood KA, Alexopoulos GS, van Gorp WG (2002). Executive dysfunction in geriatric depression. *Am J Psychiatry* 159:1119-1126.

Lyness JM (2002). The cerebrovascular model of depression in late life. *CNS Spectrum* 7:712-715.

Modrego PJ, Ferrández J (2004). Depression in patients with mild cognitive impairment increases the risk of developing dementia of Alzheimer's type. *Arch Neurol* 61:1290-1293.

Nebes RD, Pollock BG, Houck PR, Butters MA, Mulsant BH, Zmuda MD, Reynolds CF 3rd (2003). Persistence of cognitive impairment in geriatric patients following antidepressant treatment: a randomized, double-blind clinical trial with nortriptyline and paroxetine. *J Psychiatr Res* 37:99-108.

Nobuhara K, Okugawa G, Sugimoto T, Minami T, Tamagaki C, Takase K, Saito Y, Sawada S, Kinoshita T (2006). Frontal white matter anisotropy and symptom severity of late-life depression: a magnetic resonance diffusion tensor imaging study. *J Neurol Neurosurg Psychiatry* 77:120-122.

O'Brien JT, Desmond P, Ames D, Schweitzer I, Tuckwell V, Tress B (1994). The differentiation of depression from dementia by temporal lobe magnetic resonance imaging. *Psychol Med* 24:633-640.

O'Brien JT, Erkinjuntti T, Reisberg B, Roman G, Sawada T, Pantoni L, Bowler JV, Ballard C, DeCarli C, Gorelick PB, Rockwood K, Burns A, Gauthier S, DeKosky ST (2003). Vascular cognitive impairment. *Lancet Neurology* 2:89-98.

O'Brien JT, Lloyd A, McKeith I, Gholkar A, Ferrier N (2004). A longitudinal study of hippocampal volume, cortisol levels, and cognition in older depressed subjects. *Am J Psychiatry* 161:2081-2090.

Ownby RL, Crocco E, Acevedo A, John V, Loewenstein D (2006). Depression and risk for Alzheimer disease. *Arch Gen Psychiatry* 63:530-538.

Palsson S, Ostling S, Skoog I (2001). The incidence of first onset depression in a population followed from the age of 70 to 85. *Psychol Med* 31:1159-1168.

Pandya DN, Rosene DL (1985). Some observations on trajectories and topography of commissural fibers. In: Reeves, AG (Ed.), *Epilepsy and the Corpus callosum*, Plenum, New York, pp 21-39.

Pandya DN, Seltzer B (1986). The topography of commissural fibers. In: Leporé P, Ptito M, Japser HH (Eds.). *Two hemispheres-one brain: functions of the corpus callosum*. Alan R. Liss, New York, pp 47-73.

Rajkowska G, Miguel-Hidalgo JJ, Dubey P, Stockmeier CA, Krishnan KRR (2005). Prominent reduction in pyramidal neurons density in the orbitofrontal cortex of elderly depressed patients. *Biol Psychiatry* 58:297-306.

Salloway S, Malloy P, Kohn R, Gillard E, Duffy J, Rogg J (1996). MRI and neuropsychological deficits in early- and late-life-onset geriatric depression. *Neurology* 46:1567-1574.

Sheline YI, Barch DM, Garcia K, Gersing K, Pieper C, Welsh-Bohmer K, Steffens DC, Doraiswamy PM (2006). Cognitive function in late life depression: relationships to depression severity, cerebrovascular risk factors and processing speed. *Biol Psychiatry* 60:58-65.

Steffens DC, Byrum CE, McQuoid DR, Greenberg DL, Payne ME, Blitchington TF (2000). Hippocampal volume in geriatric depression. *Biol Psychiatry* 48:301-309.

Steffens DC, Snowden M, Fan M, Hendrie H, Katon WI, Unützer J (2006). Cognitive impairment and depression outcomes in the IMPACT study. *Am J Geriatr Psychiatry* 14:401-409.

Taylor WD, Steffens DC, McQuoid DR, Payne ME, Lee SH, Lai TJ, Krishnan KR (2003). Smaller orbital frontal cortex volumes associated with functional disability in depressed elders. *Biol Psychiatry* 53:144-149.

Taylor WD, MacFall JR, Payne ME, McQuoid DR, Provenzale JM, Steffens DC, Krishnan KRR (2004). Late-life depression and microstructural abnormalities in dorsolateral prefrontal cortex white matter. *Am J Psychiatry* 161:1293-1296.

Taylor WD, Steffens DC, Payne ME, MacFall JR, Marchuk DA, Svenson IK, Krishnan RR (2005). Influence of serotonin transporter promoter region polymorphisms on hippocampal volumes in late-life depression. *Arch Gen Psychiatry* 62:537-544.

Teresi J, Abrams R, Holmes D, Ramirez M, Eimicke J (2001). Prevalence of depression and depression recognition in nursing homes. *Soc Psychiatry Psychiatr Epidemiol* 36:613-629.

Thomas AJ, O'Brien JT, Davis S, Ballard C, Barber R, Kalaria RN, Perry RH (2002). Ischemic basis for deep white matter hyperintensities in major depression: a neuropathological study. *Arch Gen Psychiatry* 59:785-792.

van Ojen R, Hooijer C, Bezemer D, Jonker C, Lindelboom J, van Tilburg W (1995). Late-life depressive disorder in the community, I: the relationship between MMSE score and depression in subjects with and without psychiatric history. *Br J Psychiatry* 156:311-315.

Danksagung

Ich möchte allen danken, die mich bei der Durchführung der Forschungsvorhaben unterstützt haben.

Ganz besonders möchte ich mich bei meinem Mentor, Herrn Professor Andreas Heinz, für die Unterstützung in meinem Habilitationsbestreben und die konstruktive Begleitung und Förderung meines wissenschaftlichen Werdegangs bedanken, sowie seinen Kollegen und Mitarbeitern, die mich in den letzten Monaten unterstützt und begleitet haben.

Weiterhin möchte ich Herrn Professor Anand Kumar und Herrn Professor Arthur W. Toga, wie auch allen Kollegen und Mitarbeitern der University of California at Los Angeles, USA, für die stets fundierte inhaltliche und praktische Unterstützung danken.

Ich danke ferner Herrn Professor PierFranco Spano von der Universität Brescia, Italien, für den langjährigen und fruchtbaren wissenschaftlichen Austausch.

ERKLÄRUNG

§ 4 Abs. 3 (k) der HabOMed der Charité

Hiermit erkläre ich, daß

- weder früher noch gleichzeitig ein Habilitationsverfahren durchgeführt oder angemeldet wird bzw. wurde,
- welchen Ausgang ein durchgeführtes Habilitationsverfahren hatte,
- die vorgelegte Habilitationsschrift ohne fremde Hilfe verfasst, die beschriebenen Ergebnisse selbst gewonnen sowie die verwendeten Hilfsmittel, die Zusammenarbeit mit anderen Wissenschaftlern/Wissenschaftlerinnen und mit technischen Hilfskräften sowie die verwendete Literatur vollständig in der Habilitationsschrift angegeben wurden.
- mir die geltende Habilitationsordnung bekannt ist.

.....
Datum

.....
Unterschrift