

Subclinical pulmonary pathogenic infection in camels slaughtered in Cairo, Egypt

Gamal Wareth^{1,2}, Jayaseelan Murugaiyan², Dalia F Khater³, Shawky A Moustafa¹

¹ Department of Pathology, Faculty of Veterinary Medicine, Benha University, Egypt

² Institute of Animal Hygiene and Environmental Health, Free University of Berlin, Germany

³ Food Hygiene Department, Animal Health Research Institute, Tanta branch, Egypt

Abstract

Introduction: Camels migrate between the open boundaries of Sudan and Egypt either for grazing or for slaughtering. Bad hygiene and stress is often related to pulmonary diseases in camels. This study investigated whether camels slaughtered in Cairo carried pulmonary infections.

Methodology: Five hundred lung tissues of slaughtered camels were examined and 100 samples suspected for pulmonary infection were subjected to microbial identification and histopathology.

Results: A total of 70 lung tissues revealed 97 bacterial isolates of 8 species, including *Staphylococcus aureus* (37.14%), *Escherichia coli* (27.14%), *Klebsiella pneumoniae* (26.71%), *Bacillus* spp. (25.72%), *Streptococcus pyogenes* (10%), *Corynebacterium* spp. (8.85%), *Pasteurella* spp. (2.85%), and *Arcanobacterium pyogenes* (1.4%). Some of these species were earlier reported to be associated with pulmonary infection. Histopathology revealed different types of pneumonia in 50% of the investigated lungs.

Conclusions: A considerable number of apparently healthy camels carry pathogenic agents in their lower respiratory tracts. Immunosuppression and stressful conditions might influence these pathogens to induce respiratory diseases in camels. Thus, the infected camels might act as reservoir of these infections agents. If adequate care is not taken, this might be a threat to abattoir workers and may spread infections to humans.

Key words: camel; lung; pulmonary infection; pathogens; histopathology.

J Infect Dev Ctries 2014; 8(7):909-913. doi:10.3855/jidc.4810

(Received 04 February 2014 – Accepted 25 June 2014)

Copyright © 2014 Wareth *et al.* This is an open-access article distributed under the Creative Commons Attribution License, which permits unrestricted use, distribution, and reproduction in any medium, provided the original work is properly cited.

Introduction

The one-humped camel (*Camelus dromedarius*), often referred as the Arabian camel, is one of two species within the genus *Camelus* [1]. Camels, compared to other livestock in the same locations, have been reported to be less susceptible to many diseases [2]. Detailed information on many aspects of the health status of camels is not well documented. However, it has been reported that camels are subjected to various types of bacterial and viral infections [3,4]. Many of these infectious diseases, as well as mycotic and parasitic agents, may affect the lungs [5]. Pulmonary diseases in camels are considered to be one of the main emerging problems that lead to productivity loss and death [6,7]. When insufficient protective procedures are followed, infected camels pose a risk of transmission of infections to other camels, livestock, abattoir workers, veterinarians, and animal traders who come into close contact.

Descriptions of the Middle East Respiratory Syndrome (MERS) posit that camels might be one of the reservoirs of human respiratory infections [8]. Bad sanitation, stressful conditions, and an immunosuppressed state are often related to camel respiratory infections. Nowadays, camel meat is a cheaper choice of meat in certain countries, such as Egypt. The increased meat demand in Egypt has drastically increased the importation of camels solely for slaughtering purposes from neighboring countries, especially Sudan and Somalia. These countries also share open borders that facilitate the movement of camels for grazing. Despite basic border control, it is not clear if these camels carry subclinical pulmonary infections. Therefore, the aim of this study was to investigate the presence of pathogenic agents that are associated with lung lesions in apparently healthy camels slaughtered in Cairo, Egypt.

Methodology

Animal selection and sample collection

A total of 500 apparently healthy camels were inspected at El-Warrak slaughterhouse, one of Cairo's main abattoirs, between April and October 2008. All camels used in this study were imported from Sudan and kept with livestock traders until slaughter. Details of sex, breed, or husbandry conditions of the camels were not available. During routine slaughter, a total 100 (20%) possessed gross pulmonary lesions, which were aseptically collected using sterile plates.

Isolation and identification of pathogens

The outer surfaces of the pneumonic lungs were first seared with a heated spatula, and the inner surface of the lungs was cultured in a nutrient broth at 37°C for 24 hours. The isolates were identified and classified according to Bergey's manual of systemic bacteriology [9]. Ten lungs that appeared healthy at gross inspection were examined for isolation of bacteria as a control group.

Histopathological examinations

For histopathological examination, specimens from abnormal lungs of slaughtered camels were

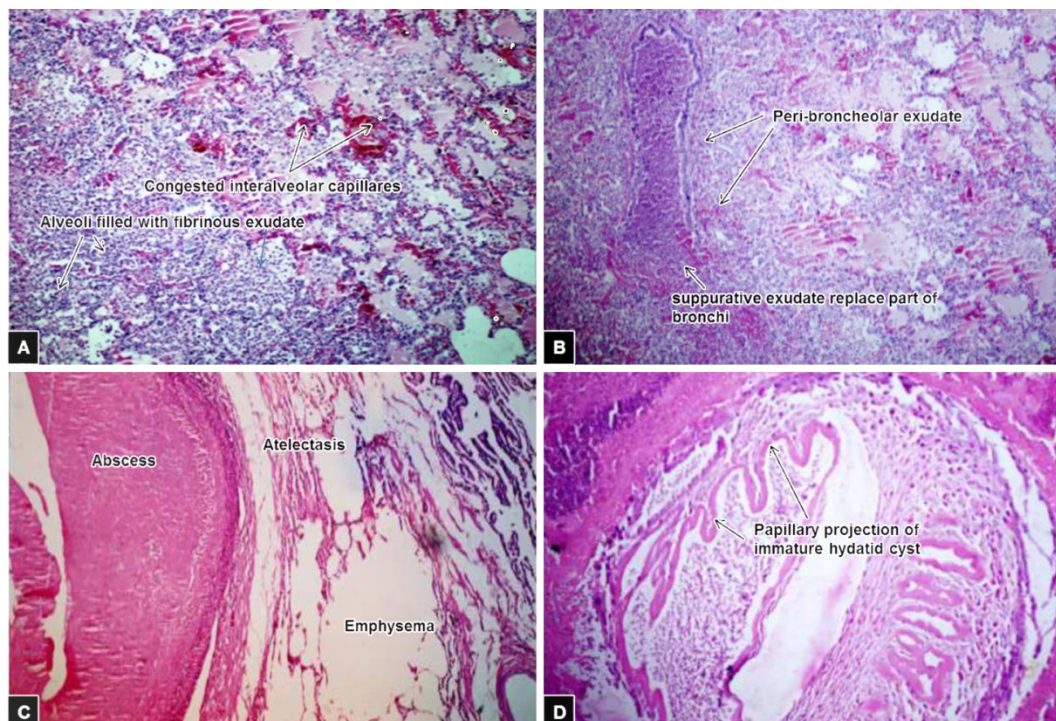
obtained and fixed in 10% formalin solution. After complete fixation, the specimens were washed with water, dehydrated in ascending series of ethanol up to absolute alcohol, cleared in xylene, and embedded in paraffin. Sections of 5 µm thickness were prepared and stained with hematoxylin and eosin.

Results

Among the 100 pneumonic lungs tested, 70% displayed detectable bacterial colonies, while the rest (30%) failed to yield any observable microbial growth. A total of 97 bacterial isolates were observed and 8 different microbes were identified: *Staphylococcus aureus* (37.14%), *E. coli* (27.14%), *Klebsiella pneumoniae* (26.71%), *Bacillus* spp. (25.72%), *Streptococcus pyogenes* (10%), *Corynebacterium* spp. (8.85%), *Pasteurella* spp. (2.85%), and *Arcanobacterium pyogenes* (1.4%). More than one species of microorganism were found in 36.71% of the affected lungs. All healthy control lungs were free from bacteria.

As shown in Figure 1, histological analysis revealed that about 50% of the examined lungs displayed different types of pneumonia and hydatidosis; 3% of examined lungs displayed signs of

Figure 1. Histopathological analysis of camel lungs with Hematoxylin and Eosin stain (magnification x200) showing **A**) fibrinous pneumonia: alveoli filled with fibrinous exudates with congestion of inter-alveolar capillaries; **B**) suppurative bronchopneumonia: suppurative exudates in peribronchiolar tissues partially replaced the bronchial wall; **C**) focal suppurative pneumonia (abscess) with necrosed center surrounded with capsule, adjacent alveoli revealed atelectasis and emphysema; and **D**) several minute papillary projections of immature hydatid cyst.



fibrinous pneumonia as gray and red hepatization with congestion of the inter-alveolar capillaries, and interlobular blood vessels were seen. Suppurative bronchopneumonia, characterized by the presence of suppurative exudates in the lumen of bronchioles and peribronchiolar tissues with partial replacement of the bronchiolar wall, was observed in 12% of the examined lungs. Pus appeared to be accumulated focally as multiple differently sized abscesses with necrosed centers surrounded by larger numbers of inflammatory cells. Furthermore, adjacent alveoli revealed areas of atelectasis and emphysema. Ten percent of the lungs showed the signs of acute interstitial pneumonia characterized by the presence of edema and leucocytic cellular infiltration with congestion in peri-alveolar capillaries resulting in thickening of the interalveolar septa. Thickening in the interstitial tissues due to fibrous tissue proliferation infiltrated with lymphocytes and macrophages indicates chronic interstitial pneumonia. Varying sizes of hydatid cysts with several minute papillary structures surrounded by thick connective tissue walls were observed in 15% of the tested lungs. These cysts appeared to contain different stages of immature parasitic developmental forms.

Discussion

Camel trade is ever increasing in North Africa and in the Middle East, where camels are used for meat and milk production, and occasionally for transportation and sport. Many apparently healthy camels slaughtered in abattoirs were reported to have one or more pulmonary lesions during postmortem examination [10,11]. Presence of pulmonary lesions in apparently healthy camels prompted us to identify pathogenic agents that are associated with pneumonia in this neglected animal species. Bacteria isolated from pneumonic camel lungs in this study produced clear pneumonic lesions in the pulmonary tissue. Under stressful conditions, bad sanitation, and immunosuppression, they could predispose camels to other infections. Middle East Respiratory Syndrome (MERS) is posited to be a zoonotic disease; dromedary camels are essential to the continuous transmission of infection to humans [12]. High prevalence of antibody titers to the recently described Middle East Respiratory Syndrome Coronavirus (MERS-CoV) or a highly related virus were detected in dromedary camels imported to Egypt for slaughter. No antibody reactivity was investigated in other species or in humans. MERS-CoV may be endemic in camels imported for slaughter to Egypt and could be a source

of occasional zoonotic infection [13]. According to our results, bacteria were isolated from 70 lung tissue samples, while 30 lung tissue samples with observable lesions failed to yield microorganisms on culture. The presence of lesions and the absence of visible microbial growth might be due to other pathogens such as mycoplasma, fungi, virus, parasites, or neoplastic growth [47].

Wide ranges of bacterial agents have been associated with pneumonia. *Corynebacterium* spp., *Staphylococcus aureus*, *Streptococcus* spp., *Pasteurella* spp., *Klebsiella pneumoniae*, and *Bacillus* spp. were commonly isolated from pulmonary lesions in dromedaries [6,7,14]; these findings are, to some extent, in agreement with our findings. Pneumonic pathogens identified in the present study showed that *Staphylococcus aureus* was the most common bacteria isolated from lung lesions at a rate of 37.14%, higher than rates reported in previous studies: 28.6% [15], 10.66% [1], and 2.2% [7]. In contrast, *Pasteurella* spp. and *Arcanobacterium pyogenes* were less prominent and isolated at rates of 2.85% and 1.4%, respectively. Isolation of different bacterial species from lung lesions of apparently healthy camels has been previously reported [4,7,16]. The variation in identified bacteria and isolation rates could be due to differences in sample sizes and causes of pneumonia in certain geographical areas [4]. *Arcanobacterium pyogenes*, *Klebsiella pneumoniae*, *Corynebacterium* spp., *Staphylococcus aureus*, and *Streptococcus pyogenes* were previously isolated from suppurative bronchopneumonia either in dromedaries [7] or in sheep [17], and this inconsistent with our results.

From a public health point of view, infected camels can also spread infections during meat processing and during migration [18]. Infection with pyogenic bacteria produces subsequent tissue injury in human and progresses to disease. For example, *Klebsiella pneumoniae* causes severe respiratory tract infections in humans due to destructive changes, inflammation, hemorrhage, and necrosis that occurs in pulmonary tissue [19]. Pneumonia, liver abscess, and meningitis have also been reported following infection with this bacteria [20]. *Corynebacterium* spp. is involved predominantly in urinary and respiratory tract infections [21]. *Staphylococcus aureus*, *Streptococcus pyogenes*, *E. coli*, and *Bacillus* spp. are the causes of many important human diseases, ranging from mild superficial skin infections to systemic diseases. Infection with *Echinococcus* is a major public health problem around the world, especially in livestock-raising regions. Humans may also develop the disease,

and hydatid cysts have been reported in several body organs, primarily the liver, lungs, and the retroperitoneal region [22]. Transmission of hydatid cysts in unlicensed abattoirs to neighboring people has been reported elsewhere [23]. Some dressing activities at slaughterhouses can reduce contamination of carcasses, but others still jeopardize carcass hygiene [24].

The results shown in Figure 1 reveal that types of pneumonia varied from mild to severe fibrinous pneumonia, acute and chronic interstitial pneumonia, and that diffuse and focal suppurative inflammation was observed in most of the examined lungs. These results are consistent with the previous observations of Awol *et al* [4] and Al-Tarazi [1], who demonstrated that acute and chronic suppurative, fibrinous, and interstitial bronchopneumonia were the predominant lesions in dromedary lungs.

The present study revealed that approximately one in five camels slaughtered in Cairo was infected with subclinical pneumonia. The apparently healthy camels carried potentially pathogenic agents in their lower pulmonary tracts. At some point, these camels might pose a serious threat to the abattoir workers and veterinarians who come in direct contact with the camels' infected lungs. It is recommended that the transborder movements of camels be controlled and that abattoir workers be educated so as to avoid infecting themselves or spreading the pathogens.

References

1. Al-Tarazi YH (2001) Bacteriological and pathological study on pneumonia in the one-humped camel (*Camelus dromedarius*) in Jordan. *Revue Élev Méd Vét Pays Trop* 54: 93-97.
2. Dirie MF, Abdurahman O (2003) Observations on little known diseases of camels (*Camelus dromedarius*) in the Horn of Africa. *Rev Sci Tech* 22: 1043-1049.
3. Intisar KS, Ali YH, Khalafalla AI, Rahman MEA, Amin AS (2010) Respiratory infection of camels associated with parainfluenza virus 3 in Sudan. *J Virol Methods* 163: 82-86.
4. Awol N, Ayelet G, Jenberie S, Gelaye E, Sisay T, Nigussie H (2011) Bacteriological studies on pulmonary lesions of camel (*Camelus dromedarius*) slaughtered at Addis Ababa abattoir, Ethiopia. *Afr J Microbiol Res* 5: 522-527.
5. Mohamed RA, Abdelsalam EB (2008) A review on pneumonic pasteurellosis (respiratory manheimiosis) with emphasis on pathogenesis virulence mechanisms and predisposing factors. *Bulgaria J Vet Med* 11: 139-160.
6. Zubair R, Khan AMZ, Sabri MA (2004) Pathology in camel lungs. *J Camel Science* 1: 103-106.
7. Abubakar MS, Fatihu MY, Ibrahim NDG, Oladele SB, Abubakar MB (2010) Camel pneumonia in Nigeria: Epidemiology and bacterial flora in normal and diseased lung. *Afr J Microbiol Res* 4: 2479-2483.
8. Coleman C, Frieman M (2013) Emergence of the Middle East respiratory syndrome Coronavirus. *PLoS Pathog* 9: e1003595.
9. Bergey S (1984) Manual of systematic bacteriology, volume 1, 4th edition. Baltimore: William & Wilkins. 964 p.
10. Jenberie S, Awol N, Ayelet G, Gelaye E, Negussie H, Abie G (2012) Gross and histopathological studies on pulmonary lesions of camel (*Camelus dromedarius*) slaughtered at Addis Ababa abattoir, Ethiopia. *Trop Anim Health Prod* 44: 849-854.
11. Bekele ST (2008) Gross and microscopic pulmonary lesions of camels from Eastern Ethiopia. *Trop Anim Health Prod* 40: 25-28.
12. Alagaili, A, Briese, T, Mishra, N, Kapoor, V, Sameroff, S, de Wit, E, Munster, V, Hensley, L, Zalmout, I, Kapoor, A, Epstein, J, Karesh, W, Daszak, P, Mohammed, O, WI, L (2014) Middle East respiratory syndrome coronavirus infection in dromedary camels in Saudi Arabia. *MBio* 5: e00884-00814. doi: 00810.01128/mBio.00884-00814.
13. Perera, R, Wang, P, Gomaa, M, El-Shesheny, R, Kandeil, A, Bagato, O, Siu, L, Shehata, M, Kayed, A, Moatasim, Y, Li, M, Poon, L, Guan, Y, Webby, R, Ali, M, Peiris, J, Kayali, G (2013) Seroepidemiology for MERS coronavirus using microneutralisation and pseudoparticle virus neutralisation assays reveal a high prevalence of antibody in dromedary camels in Egypt, June 2013. *Euro Surveill* 2013;18(36):pii=20574. Available online: <http://www.eurosurveillance.org/ViewArticle.aspx?ArticleId=20574>. Accessed April 2014.
14. Rana MZ, Ahmed A, Sindhu ST, Mohammad G (1993) Bacteriology of camel lungs. *Camel Newsletter* 10: 30-32.
15. Abo-Elnaga TR, Osman WA (2012) Detection of pathogens of condemned lungs of one humped camels (*Camelus dromedarius*) slaughtered in Matrouh abattoirs, Egypt. *Global Veterinaria* 9: 290-296.
16. Azizollah E, Bentol-hoda M, Raziheh K (2009) The aerobic bacterial population of the respiratory passageways of healthy dromedaries in Najaf-abbad abattoir, central Iran. *J Camel Sci* 2: 26-29.

17. Azizi S, Korani FS, Oryan A (2013) Pneumonia in slaughtered sheep in south-western Iran: pathological characteristics and aerobic bacterial aetiology. *Vet Ital* 49: 109-118.
18. Teshome H, Molla B, Tibbo M (2003) A seroprevalence study of camel brucellosis in three camel-rearing regions of Ethiopia. *Trop Anim Hlth Prod* 35: 381-390.
19. Hackstein H, Kranz S, Lippitsch A, Wachtendorf A, Kershaw O, Gruber AD, Michel G, Lohmeyer J, Bein G, Herold NB (2013) Modulation of respiratory dendritic cells during *Klebsiella pneumoniae* infection. *Respir Res* 14: 91 doi: 10.1186/1465-9921-1114-1191.
20. Shon AS, Bajwa RPS, Russo TA (2013) Hypervirulent (hypermucoviscous) *Klebsiella pneumoniae*: A new and dangerous breed. *Virulence* 4: 107-118.
21. Cazanave C, Greenwood-Quaintance KE, Hanssen AD, Patel R (2012) *Corynebacterium* prosthetic joint infection. *J Clin Microbiol* 50: 1518-1523.
22. Cullu N, Karakas O, Kiliçaslan N, Konukoglu O, Karakas E (2013) Primary retroperitoneal hydatid cyst. *Clin Ter* 164: e489-491. doi: 410.7417/CT.2013.1642.
23. Reyes MM, Taramona CP, Saire-Mendoza M, Gavidia CM, Barron E, Boufana B, Craig PS, Tello L, Garcia HH, Santivañez SJ (2012) Human and canine echinococcosis infection in informal, unlicensed abattoirs in Lima, Peru. *PLoS Negl Trop Dis* 6: e1462. doi: 1410.1371/journal.pntd.0001462. Epub 0002012 Apr 0001463.
24. Arguello H, Alvarez-Ordoñez A, Carvajal A, Rubio P, Prieto M (2013) Role of slaughtering in *Salmonella* spreading and control in pork production. *J Food Prot* 76: 899-911. doi: 810.4315/0362-4028X.JFP-4312-4404.

Corresponding author

Gamal Wareth
Friedrich-Loeffler-Institut, Federal Institute for Animal Health
Institute of Bacterial Infections and Zoonoses
Naumburger Str. 96 a, 07743 Jena, Germany
Phone: 0049-015779564050
Email: gamalwareth@hotmail.com

Conflict of interests: No conflict of interests is declared.