

Case Report

Followup of a Dog with an Intraocular Silicone Prosthesis Combined with an Extraocular Glass Prosthesis

Gwendolyna Romkes and Johanna Corinna Eule

Small Animal Clinic, Faculty of Veterinary Medicine, Freie Universität Berlin, Oertzenweg 19b, 14163 Berlin, Germany

Correspondence should be addressed to Gwendolyna Romkes, gwendolyna.romkes@gmail.com

Received 30 July 2012; Accepted 5 September 2012

Academic Editors: S. Hecht and C.-T. Lin

Copyright © 2012 G. Romkes and J. C. Eule. This is an open access article distributed under the Creative Commons Attribution License, which permits unrestricted use, distribution, and reproduction in any medium, provided the original work is properly cited.

Because of unpredictable corneal changes, evisceration and implantation of a silicone prosthesis does not always lead to a satisfying cosmetic result. This paper describes the use of an intraocular silicone prosthesis in combination with an extraocular glass prosthesis and shows a followup of two and a half years in a nonexperimental study. An intraocular silicone prosthesis was implanted after evisceration of the left eye in a five-month-old Bernese mountain dog. A glass prosthesis was fitted four weeks after evisceration. Two and a half years after the operation, the dog is in good health and free of medication. No short-term or long-term complications were seen. The owners do not have trouble with handling the glass prosthesis. The combination of both prostheses shows a perfect solution to retrieve a normal looking and moving eye after evisceration.

1. Introduction

In both human and veterinary ophthalmology several surgical options are described to treat an end-stage glaucomatous eye that does not respond to medical therapy.

The easiest and fastest procedure is enucleation of the eye. Evisceration and implantation of a silicone prosthesis is an alternative which gives a better cosmetic result [1–6].

A disadvantage of evisceration and silicone implantation in dogs is the neovascularization of the cornea immediately after evisceration. One to two months after the operation, the cornea will be completely vascularized [2, 4, 6, 7]. Parallel to this process, the cornea becomes fibrotic and sometimes also pigmented [6]. The extent of blood vessel regression and the degree of pigmentation and/or opacification varies between canine eyes. Opacification can lead to unsatisfying cosmetic results [4, 7]. In a questionnaire for dog owners of eviscerated patients, 62% of the owners were very content with the result. Less satisfaction was caused by dense fibrosis of the cornea [5]. Still, all owners were happy to have chosen evisceration instead of enucleation. To improve the cosmetic appearance, in human medicine evisceration is

always combined with an extraocular prosthesis (scleral shell or “artificial eye”) [8–10]. An extraocular prosthesis combined with an intraocular prosthesis shows a better motility than an extraocular prosthesis alone [9, 10]. Table 1 gives an overview of selected options to restore anatomical structure after exenteration, enucleation, or evisceration. Figure 1 shows the anatomic relationship of the two prostheses.

Transscleral cyclophotocoagulation with diode laser or cryotherapy in combination with an Ahmed gonioimplantation in dogs with primary glaucoma has a success rate of approximately 76%, and most of the patients still need long-term medication [12, 13]. Therefore, this method is reserved for acute glaucomatous eyes, which are still visible or are believed to have a change to regain vision.

Ciliary body ablation by intravitreal gentamicin injection for the treatment of end-stage glaucoma is thought to correlate with the development of malignant intraocular tumours [14].

This paper shows a followup of two and a half years of a dog with an intraocular silicone prosthesis combined with an extraocular glass prosthesis after evisceration.

TABLE 1: Overview of selected options to restore anatomical structure after exenteration, enucleation, or evisceration [8, 10, 11]. Depending on the procedure and the selected prosthesis, a second prosthesis or an “artificial eye” can be placed between the first prosthesis and the eyelids. Porous implants like hydroxyapatite can be combined with a coupling or peg system, to give the second implant better motility [8, 10].

Surgical procedure	Prosthesis material	Site of implantation	Coupling system	Second prosthesis	Eyelid movement	Globe movement	
Exenteration	Silicone	Intraorbital	No		—		
	Hydroxyapatite						
Enucleation	Silicone	Intraorbital	No	Acrylic	+	—	
				Glass	+	—	
	Hydroxyapatite	Intraorbital	No	Acrylic	+	—	
				Glass	+	—	
				Yes	Acrylic	+	++
				—	+	++++	
Evisceration	Silicone	Intraocular	No	Bandage lens	+	++++	
				Acrylic	+	+++	
					Glass	+	+++
					—	+	++++
	Hydroxyapatite	Intraocular	No	Bandage lens	+	++++	
				Acrylic	+	+++	
			Yes	Glass	+	+++	
				Acrylic	+	++++	

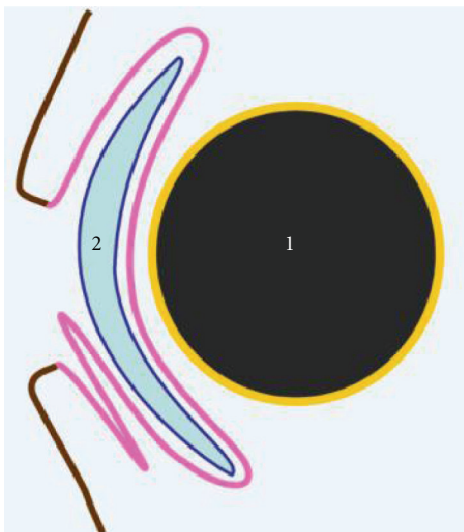


FIGURE 1: Anatomical position of different prostheses. 1: intraocular prosthesis introduced within the empty tunica fibrosa after evisceration. 2: second extraocular prosthesis or “artificial eye,” lying between the conjunctiva (third eyelid in animals) and eyelids. Brown: eyelid skin, pink: conjunctiva, and yellow: tunica fibrosa.

2. Case Report

A three-month-old, male Bernese mountain dog was presented to a private veterinarian after a cat claw injury in his left eye. Ophthalmic examination, including fluorescein staining, Seidel Test, slit lamp biomicroscopy and B-mode

ultrasound, led to the diagnosis of corneal perforation without injury of the lens. Under general anesthesia, the corneal wound was cleaned and afterwards closed with simple interrupted sutures (Vicryl 8/0, Ethicon, Johnson & Johnson, Norderstedt, Germany). An additional nictitating membrane flap was performed to protect the corneal wound. Postoperative treatment included topical treatment with neomycin, gramicidin, and polymyxin B eye drops TID (Polyspectran, Alcon, Freiburg, Germany) and atropine eye drops SID (Atropine-POS 1%, Ursapharm, Saarbrücken, Germany) and systemic treatment with amoxicillin-clavulanic acid 12.5 mg/kg BID (Clavaseptin, Vétoquinol, Ravensburg, Germany) for two weeks and carprofen 4 mg/kg SID (Rimadyl, Pfizer, Karlsruhe, Germany) for six weeks.

After six weeks, the eye became blind and the dog was referred. Ophthalmic examination of the blind eye revealed secondary glaucoma with an intraocular pressure of 29 mmHg measured by rebound tonometry (TonoVet, Acrivet-Veterinary Division, Hennigsdorf, Germany). Topical treatment including carbonic anhydrase-inhibitor and β -blocker eye drops QID (dorzolamide 2% and timolol 0.5%, Cosopt, Merck Sharp & Dohme-Chibret, Clermont-Ferrand, France) and prostaglandin-analog eye drops BID (Travoprost 40 μ g/mL, Travatan, Alcon, Hemel Hempstead, United Kingdom) was initiated, but the intraocular pressure could not be controlled below 20 mmHg to prevent further damage. Seven weeks after the injury, the blind eye became buphthalmic (Figure 2). The owners elected to eviscerate the eye and chose an extraocular prosthesis to be installed.

2.1. Surgery Part I: Intraocular Prosthesis. The dog underwent general anesthesia. The left eye was cleaned in a routine

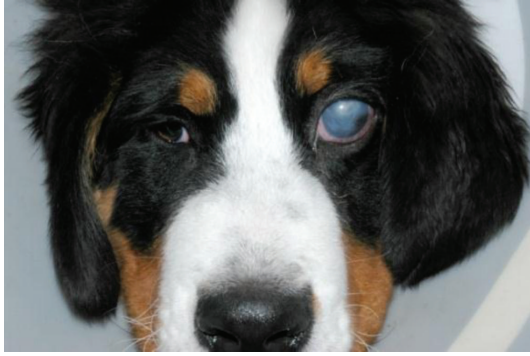

FIGURE 2: Four-and-a-half-month-old Bernese mountain dog with end-stage, glaucomatous left eye seven weeks after cat claw injury.

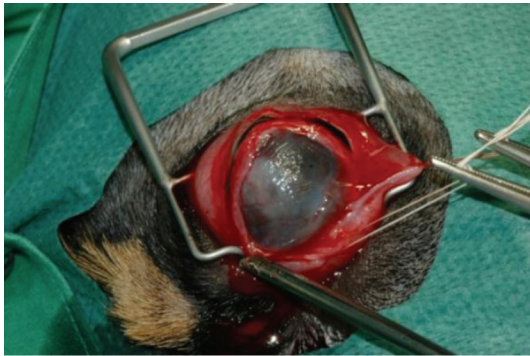

FIGURE 3: Perilimbal perforating scleral incision as preparation for implantation of intraocular silicone prosthesis.

manner for eye surgery. A Barraquer eyelid speculum was placed to open the eyelids. The conjunctiva was prepared for a 360° flap by a complete perilimbal incision with a Stevenson's scissor. The cornea was excised by a 360° scleral incision with a Beaver blade nr. 65 and Stevenson's scissor 1 mm behind the limbus (Figure 3).

The content of the globe was removed with a lens loop, leaving an empty scleral shell. An 18 mm silicone prosthesis (Acrivet-Veterinary Division, Hennigsdorf, Germany) (size of the healthy eye, measured as the distance between the posterior surface of the cornea and the anterior surface of the sclera with B-mode ultrasound) was placed into the scleral shell with a Carter sphere introducer (Acrivet-Veterinary Division, Hennigsdorf, Germany). The sclera was closed above the prosthesis with interrupted horizontal mattress sutures (Vicryl 6/0, Ethicon, Johnson & Johnson, Norderstedt, Germany) (Figure 4).

The 360° limbal-based conjunctival flap was closed above the sclera in a simple continuous pattern by the use of the Vicryl 6/0 (Figure 5).

A temporary tarsorrhaphy with the use of a monofilament suture material (Dafilon 4/0, Braun Aesculap, Tuttlingen, Germany) was performed to protect the empty fornix (Figure 6).

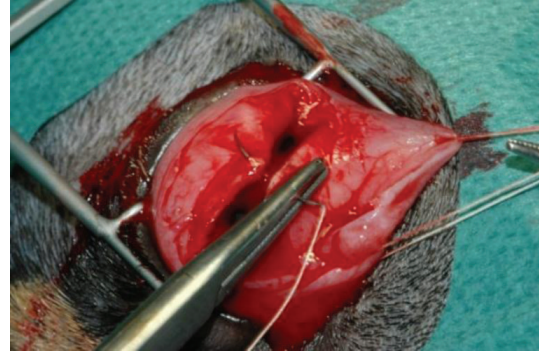


FIGURE 4: Closure of the sclera above the intraocular silicone prosthesis.

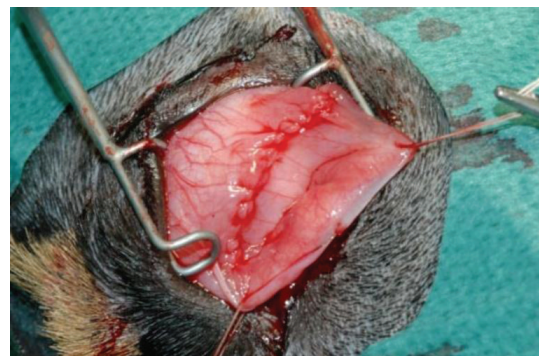


FIGURE 5: Closure of the conjunctiva above the sclera.

The sclera and conjunctiva healed within two weeks, and after which the tarsorrhaphy was released.

2.2. Surgery Part II: Extraocular Prosthesis. Three weeks after the surgery, an extraocular prosthesis of glass was prepared by an ocularist (Figure 7).

The prosthesis was placed into the fornix, above the conjunctiva, sclera, and intraocular prosthesis (Figure 1). The extraocular prosthesis was kept in place by its shape, the third eyelid and the eyelids resting over the border of the prosthesis.

2.3. Postoperative Care. Postoperative treatment included systemic treatment with amoxicillin-clavulanic acid 12.5 mg/kg BID (Clavaseptin, Vétoquinol, Ravensburg, Germany) and metamizol 20 mg/kg TID (Novaminsulfon, Ratiopharm, Ulm, Germany) for five days. No topical treatment was applied. The wound was examined one day, one week, and two weeks after surgery. No further systemic or local medication was indicated.

2.4. Prosthesis Handling. The glass prosthesis has to be taken out every evening. The prosthesis is placed overnight in a generally available lens cleaner (for example Boston Simplus all in one, Bausch & Lomb, Berlin, Germany). In the morning, the conjunctival sack is flushed with a generally

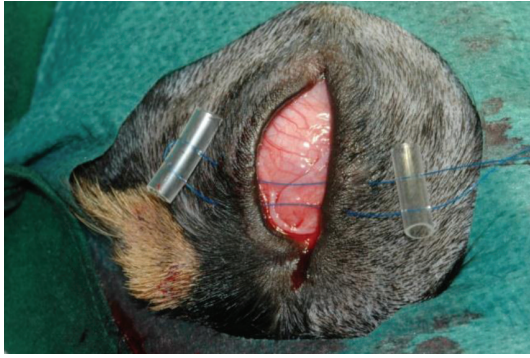

FIGURE 6: Temporary tarsorrhaphy to protect the empty fornix.

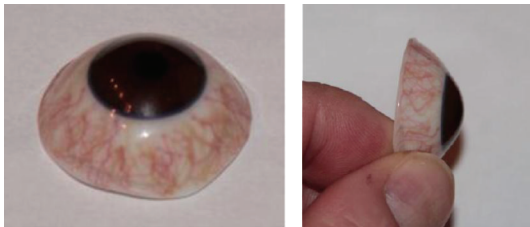


FIGURE 7: Artificial glass eye (extraocular prosthesis).

available eye cleaner (e.g., Albrecht, Aulendorf, Germany), and the prosthesis is placed back into the fornix.

2.5. Followup. Pictures were taken two months, one and a half year, and two and a half years after surgery (Figures 8, 9, and 10).

The extraocular prosthesis was replaced by the same ocularist for a new prosthesis after one year and after two and a half years. By experience, the ocularist was able to fit the last prosthesis in such a manner that less white of the prosthesis is seen. The only (long-term) complication is a little intermittent serous secretion. There is no history of a bacterial infection or insufficient tear production. Schirmer's tear test readings were always above 15 mm per minute. The dog is happy, does not need any medication and behaves and looks like a dog with two normal eyes. The dog does not show any discomfort with the intraocular and extraocular prosthesis.

The owners are very satisfied with the cosmetic result and do not feel inconvenienced by the handling of the extraocular prosthesis. Given the same circumstances, they would make the same decision again.

3. Discussion

3.1. Evisceration versus Enucleation. In human ophthalmology, the main advantage of evisceration over enucleation is that evisceration is described as the easier procedure with less orbital manipulation, hemorrhage, and reduced postoperative swelling, pain, and associated trauma [8]. In human ophthalmology eviscerations are also associated with fewer complications than enucleation due to less periocular



FIGURE 8: Six-and-a-half-month-old Bernese mountain dog with intraocular and extraocular prosthesis two months after surgery.




FIGURE 9: Two-year-old Bernese mountain dog one and a half year after surgery.

damage caused during evisceration [15, 16]. Postoperatively the globe still moves normally, because during evisceration extraocular muscles and their attachments are not disturbed [8]. Different studies in dogs have shown that evisceration and implantation of a silicone prosthesis is easy to learn, easy to practice and shows a very low complication rate in well-selected cases [5, 6]. In dogs, postoperative pain after evisceration is comparable with postoperative pain after enucleation [5]. Postoperative local therapy is needed for two to three weeks after evisceration, and therefore, the postoperative care is more intensive as after enucleation, but this was not inconvenient to owners and dogs [5].

3.2. Stimulating Appropriate Orbital Growth in Infants. Kennedy [17] describes that facial asymmetry and cosmetic deformity can occur following enucleation. Some studies in human ophthalmology describe that enucleation of one eye in infancy or childhood accompanied by insertion of an implant does not cause a cosmetically significant orbital variation [18, 19]. An experimental study in young cats



FIGURE 10: Three-year-old Bernese mountain dog two and a half years after surgery.

testing tissue expanders in the anophthalmic orbit after enucleation showed that insufficient tissue expanding led to asymmetric skull development [20]. In the presented case a tissue expander implant was not available at the time of surgery. The combination of an intraocular silicon prosthesis with an extraocular glass prosthesis did not lead to visible facial asymmetry. Additional radiographic studies to measure the volume of both orbitae are lacking due to clinical irrelevance in the presented patient.

3.3. Operation Technique. In this case the evisceration was combined with a full-thickness keratectomy, because the eye was so buphthalmic. Additionally, in human ophthalmology excision of the cornea is described for those patients who may still have corneal sensation or corneal pain. The removal of the cornea allows the sclera edges to be united, which provides a secure wound closure [8]. As the owners of the dog already decided preoperatively for a second extraorbital prosthesis, it was attempted to establish the best basis for this second prosthesis. Without the cornea, no cornea-related complications, such as a deep (nonhealing) ulcer, can develop.

Due to the preoperative buphthalmic eye, the silicone implant, which was the size of the other normal eye, could be introduced, and the sclera wound could be opposed without tension releasing incisions or posterior radial sclerotomies, which may be used in human ophthalmology [8, 9]. A buphthalmic globe contracts around the implant within one to two months to conform to the size of the implanted sphere [2].

3.4. Implant Material. In dogs, implantation of silicone prosthesis after evisceration has been used already for many years [1–6]. In more recent studies with well-selected cases, no extrusion of the prosthesis was seen and no secondary enucleation was needed [2, 5, 6].

The first extraocular prostheses for humans were made of glass, mainly produced in Germany. During World War II, an increased demand for glass eyes and limited export from Germany led to the development of acrylic prostheses [11]. Glass causes no allergic reactions [10]. The manufacturing of the prosthesis takes approximately one

hour. The measurement and placement in the patient can be done during one consultation [10]. Disadvantages of glass are the gradual break down of the smooth surface over time and the need to renew the prosthesis every one or two years [21]. Furthermore, glass can become very cold in windy or cold weather. This can cause pain to the eyelids in contact with the prosthesis [10]. Acrylic prostheses have a very large mechanical resistance and therefore last five to ten years. After manufacturing, the prosthesis can be molded several times. The measurement and placement in the patient takes normally two to three visits. Theoretically, acrylics can cause allergic reactions. To maintain the surface smooth and clean, the prosthesis has to be polished once a year [21]. In Germany, ophthalmologists prefer to use glass whereas, for example, in the Netherlands the ophthalmologists prefer to use acrylic prostheses [22]. In the presented case, the ophthalmologist preferred to use glass for the extraocular prosthesis.

In an eviscerated eye without keratectomy in which a fibrotic cornea develops a tinted bandage lens can be tried to camouflage the white appearance. Care must be taken with those eyes that develop a lower tear production.

3.5. Prosthesis Motility. The motility of an intraocular prosthesis together with the extraocular prosthesis can be further increased by addressing a motility coupling system, like a peg, between the two prostheses [10, 23]. This improvement is reported to be relatively small in effect and neutralized by the need of a second anesthesia or sedation and increased rate of complications like persistent discharge, pain, and peg extrusion [9, 10, 24, 25].

3.6. Postoperative Complications. Different studies show that 10% of the eviscerated canine eyes developed a keratoconjunctivitis sicca (KCS) [4, 5, 26], but within this presented case no signs of KCS were seen.

This paper shows that the combination of both prostheses offers a good treatment option with very good cosmetic results, with no discomfort for the dog and no need for additional medication.

References

- [1] A. H. Brightman, W. G. Magrane, R. W. Huff, and L. C. Helper, "Intraocular prosthesis in the dog," *Journal of the American Animal Hospital Association*, vol. 13, no. 4, pp. 481–485, 1977.
- [2] R. E. Hamor, R. D. Whitley, S. A. McLaughlin et al., "Intraocular silicone prostheses in dogs: a review of the literature and 50 new cases," in *Journal of the American Animal Hospital Association*, vol. 30, pp. 66–69, 1994.
- [3] S. A. Koch, "Intraocular prosthesis in the dog and cat: the failures," *Journal of the American Veterinary Medical Association*, vol. 179, no. 9, pp. 883–885, 1981.
- [4] C. T. Lin, C. K. Hu, C. H. Liu, and L. S. Yeh, "Surgical outcome and ocular complications of evisceration and intraocular prosthesis implantation in dogs with end stage glaucoma: a review of 20 cases," *Journal of Veterinary Medical Science*, vol. 69, no. 8, pp. 847–850, 2007.
- [5] E. Ruoss, B. M. Spiess, M. B. Rühli et al., "Intascleral silicone prosthesis in the dog: a retrospective study of 22 cases," *Tierärztliche Praxis*, vol. 25, no. 2, pp. 164–169, 1997.

- [6] D. A. Wilkie, B. C. Gilger, A. van der Woerd et al., "Implantation of intraocular silicone prostheses," *Der praktische Tierarzt*, vol. 12, pp. 1097–1100, 1994.
- [7] K. N. Gelatt and R. D. Whitley, "Surgery of the orbit," in *Veterinary Ophthalmic Surgery*, K. N. Gelatt and J. Peterson Gelatt, Eds., pp. 63–86, Elsevier Saunders, Philadelphia, Pa, USA, 2011.
- [8] W. P. Chen, "Evisceration," in *Oculoplastic Surgery, The Essentials*, W. P. Chen, Ed., pp. 347–353, Thieme, New York, NY, USA, 2001.
- [9] D. R. Jordan and L. Mawn, "Enucleation, evisceration, and exenteration," in *Basic Techniques of Ophthalmic Surgery*, J. P. Dunn and P. D. Langer, Eds., pp. 305–319, American Academy of Ophthalmology, San Francisco, Calif, USA, 2009.
- [10] M. L. R. Rasmussen, "The eye amputated—consequences of eye amputation with emphasis on clinical aspects, phantom eye syndrome and quality of life," *Acta Ophthalmologica*, vol. 88, no. 2, pp. 1–26, 2010.
- [11] D. Sami, S. Young, and R. Petersen, "Perspective on orbital enucleation implants," *Survey of Ophthalmology*, vol. 52, no. 3, pp. 244–265, 2007.
- [12] E. Bentley, P. E. Miller, C. J. Murphy, and J. V. Schoster, "Combined cycloablation and gonioimplantation for treatment of glaucoma in dogs: 18 cases (1992–1998)," *Journal of the American Veterinary Medical Association*, vol. 215, no. 10, pp. 1469–1472, 1999.
- [13] J. S. Sapienza and A. Van Der Woerd, "Combined transscleral diode laser cyclophotocoagulation and Ahmed gonioimplantation in dogs with primary glaucoma: 51 Cases (1996–2004)," *Veterinary Ophthalmology*, vol. 8, no. 2, pp. 121–127, 2005.
- [14] F. D. Duke, T. D. Strong, E. Bentley, and R. R. Dubielzig, "Canine ocular tumors following ciliary body ablation with intravitreal gentamicin," *Veterinary Ophthalmology*. In press.
- [15] R. K. Dortzbach and J. J. Woog, "Choice of procedure. Enucleation, evisceration, or prosthetic fitting over globes," *Ophthalmology*, vol. 92, no. 9, pp. 1249–1255, 1985.
- [16] T. Nakra, G. J. B. Simon, R. S. Douglas, R. M. Schwarcz, J. D. McCann, and R. A. Goldberg, "Comparing outcomes of enucleation and evisceration," *Ophthalmology*, vol. 113, no. 12, pp. 2270–2275, 2006.
- [17] R. E. Kennedy, "The effect of early enucleation on the orbit in animals and humans," *Advances in Ophthalmic Plastic and Reconstructive Surgery*, vol. 9, pp. 1–39, 1992.
- [18] C. Hintschich, F. Zonneveld, L. Baldeschi, C. Bunce, and L. Koornneef, "Bony orbital development after early enucleation in humans," *British Journal of Ophthalmology*, vol. 85, no. 2, pp. 205–208, 2001.
- [19] G. M. Howard, R. S. Kinder, and A. S. MacMillan Jr., "Orbital growth after unilateral enucleation in childhood," *Archives of ophthalmology*, vol. 73, no. 1, pp. 80–83, 1965.
- [20] M. A. Cepela, W. R. Nunery, and R. T. Martin, "Stimulation of orbital growth by the use of expandable implants in the anophthalmic cat orbit," *Ophthalmic Plastic and Reconstructive Surgery*, vol. 8, no. 3, pp. 157–169, 1992.
- [21] T. Lyberg and M. Grip, "Ocular prosthesis production in Norway," *Tidsskrift for den Norske laegeforening*, vol. 110, no. 20, pp. 2663–2664, 1990.
- [22] C. Hintschich and L. Baldeschi, "Rehabilitation of anophthalmic patients. Results of a survey," *Ophthalmologie*, vol. 98, no. 1, pp. 74–80, 2001.
- [23] N. Y. Yi, S. A. Park, M. B. Jeong et al., "Comparison of orbital prosthesis motility following enucleation or evisceration with sclerotomy with or without a motility coupling post in dogs," *Veterinary Ophthalmology*, vol. 12, no. 3, pp. 139–151, 2009.
- [24] D. R. Jordan, S. S. Chan, L. Mawn et al., "Complications associated with pegging hydroxyapatite orbital implants," *Ophthalmology*, vol. 106, no. 3, pp. 505–512, 1999.
- [25] A. Shoamanesh, N. K. Pang, and J. H. Oestreicher, "Complications of orbital implants: a review of 542 patients who have undergone orbital implantation and 275 subsequent peg placements," *Orbit*, vol. 26, no. 3, pp. 173–182, 2007.
- [26] T. Blocker, A. Hoffman, D. J. Schaeffer, and J. A. Wallin, "Corneal sensitivity and aqueous tear production in dogs undergoing evisceration with intraocular prosthesis placement," *Veterinary Ophthalmology*, vol. 10, no. 3, pp. 147–154, 2007.