

## Two Severe Cases of Tungiasis in Goat Kids in Uganda

Francis Mutebi,<sup>1,2</sup> Jürgen Krücken,<sup>3</sup> Norbert Mencke,<sup>4</sup> Hermann Feldmeier,<sup>5</sup>  
Georg von Samson-Himmelstjerna,<sup>3</sup> and Charles Waiswa<sup>1</sup>

<sup>1</sup>College of Veterinary Medicine, Animal Resources and Biosecurity, Makerere University, P.O. Box 7062, Kampala, Uganda (francmutebi10@gmail.com; cwaiswa@covab.mak.ac.ug), <sup>2</sup>Corresponding author, e-mail: francmutebi10@gmail.com, <sup>3</sup>Institute for Parasitology and Tropical Veterinary Medicine, Freie Universität Berlin, Robert-von-Ostertag Street 7-13, 14163 Berlin, Germany (juergen.kruecken@fu-berlin.de; samson.georg@fu-berlin.de), <sup>4</sup>Bayer Animal Health, 51368 Leverkusen, Germany (norbert.mencke@bayer.com), and <sup>5</sup>Institute of Microbiology and Hygiene, Charité University Medicine, Berlin, Campus Benjamin Franklin, Hindenburgdamm 30, 12203 Berlin, Germany (Feldmeier.FUBerlin@t-online.de)

Subject Editor: Phyllis Weintraub

Received 11 December 2015; Accepted 9 February 2016

### Abstract

Tungiasis ensues from the penetration and burrowing of female sand fleas (*Tunga* spp.; Siphonaptera: Tungidae) in the skin of mammals. There are few case reports of severe tungiasis in goats and in these cases the *Tunga* species were not in most cases clearly identified. Two cases of severe tungiasis caused by *Tunga penetrans* in goat kids from tungiasis-endemic rural Uganda are reported. These are the first severe cases of tungiasis in goats reported from outside South America.

**Key words:** clinical presentation, goat, *Tunga penetrans*, Uganda

Tungiasis is caused by female sand fleas (*Tunga* spp.) burrowing in the skin of mammals including humans. Although to date 14 species have been characterized in the genus *Tunga*, only three species, *Tunga penetrans*, *Tunga trimamillata*, and *Tunga hexalobulata*, are known to parasitize domestic animals (De Avelar et al. 2012, Linardi and Avelar 2014, Ezquiaga et al. 2015). Of the three species, only *T. penetrans* has been reported in Africa. In sub-Saharan Africa, the pathogen parasitizes humans and a wide range of animals (Ugbomoiko et al. 2008, Mutebi et al. 2015). *T. trimamillata* and *T. hexalobulata*, which have been reported only in South America, are the main sand flea species affecting domestic ruminants (Fioravanti et al. 2003, De Avelar et al. 2013, Linardi et al. 2013).

Principally, the life cycle of the *T. penetrans* consists of broadly two phases; off host development as well as the *in situ* development in the skin of homeothermic vertebrate hosts. In a suitable environment, off-host development progresses through eggs, larvae, pupae before adults emerge in about 17 d (Nagy et al. 2007, Pampiglione et al. 2009). A suitable environment has been characterized as one with dry and sandy soils containing some organic matter and away from direct sunlight with a temperature range of 20–31°C (Linardi et al. 2010). While both male and female adult fleas are hematophagous, only the females embed in the skin of a wide range of suitable homeothermic hosts, develop by neosomy, lay eggs, and eventually die *in situ* in about 30 d after penetration (Eisele et al. 2003, Feldmeier et al. 2007). Nevertheless, abnormal on-host metamorphosis has been reported (Thielecke and Feldmeier 2013). Normally, shortly after penetration, female sand fleas hypertrophy and increase in size by ~2000 times within 2 wk (Eisele et al. 2003).

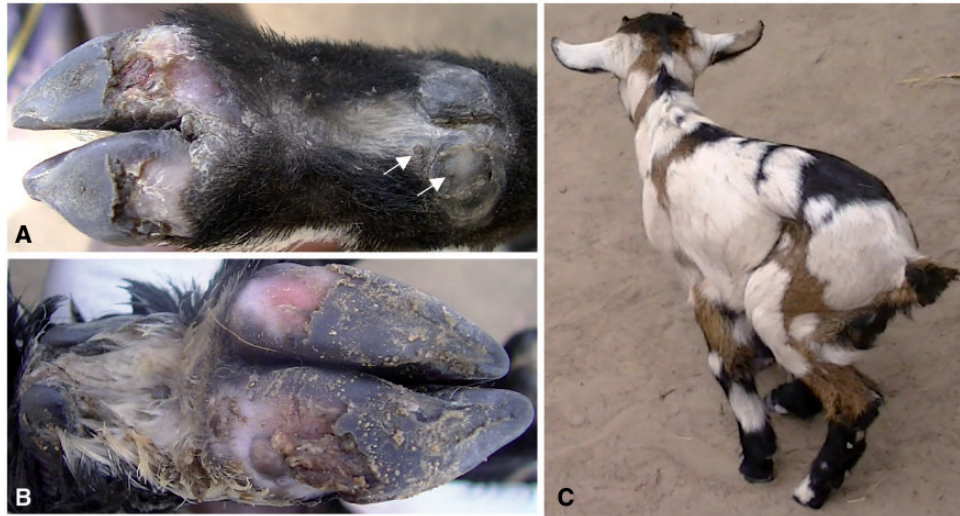During its development in host skin, *T. penetrans* evokes a severe inflammatory response which is often complicated by bacterial super infections which intensify the inflammation to cause severe morbidity.

There are few reported cases of goats infected by *T. penetrans*, of which, very few have presented with severe morbidity (Pampiglione et al. 2009) and all are exclusively from South America (Trentini et al. 2000, Gustinelli et al. 2006). This short communication presents two cases of severe manifestations of *T. penetrans* infection in goat kids detected during an epidemiological survey in rural impoverished communities in Busoga, Uganda (Mutebi et al. 2015).

### Case Reports

#### Case 1

A 3-wk-old female goat kid with a history of weakness and inappetence was detected in Masolya Village, Bugiri District, Busoga, Uganda, where tungiasis is highly prevalent among humans. It was under free range management and neither anthelmintic nor ectoparasitic treatment had ever been administered. The kid was clinically anemic (pale mucous membranes), had a starry hair coat, and was also infested with *Ctenocephalides canis*. A total of 34 sand flea lesions were detected on the four limbs. According to the Fortaleza staging system (Eisele et al. 2003), 21 were viable (Stages IIa to IIIb) and 13 were dead (Stage IV). On the limbs, sand fleas were localized mainly on the coronary band of the claws but some were embedded on the soles of the hooves (Fig. 1A and B). The affected hoof wall



**Fig. 1.** Tungiasis in Case 1. Stage III lesions on coronary band of the dew claw (arrows) and bilateral hoof wall loss of the front limb (A). Dead sand fleas, necrosis, and loss of hoof wall tissues of the hind leg (B). Infected goat kid with lameness (C).

was necrotic and had peeled off from the sole to expose the underlying soft tissue (Fig. 1B).

Sites with viable lesions were painful on palpation and the kid exhibited shifting limb lameness while moving (Fig. 1C). It spent most of the time lying down but its body temperature was within the normal range (38.9°C). The household also had a mature goat (dam to the affected kid), a sow, a dog, and a cat. The sow, the dog, and all four household members were infected by *T. penetrans* but the mature goat and the cat did not have any sand flea lesions. Goats were housed in a kitchen with earthen floor and the homestead was generally of poor sanitation with household waste being disposed off in the garden close to the compound.

### Case 2

A 3-wk-old male goat kid was detected from Busindha Village, Bugiri District in which human tungiasis is endemic. It was kept under free range management and had no history of ectoparasite or helminth control measures. It had six viable (Stages IIa to IIIb) embedded sand fleas which were exclusively on the right hind leg at the coronary band of both hooves and the accessory digits. The kid was neither anemic (as per the physical examination) nor was it pyrexia (body temperature 38.4°C). The area around the attachment sites of Stage III lesions on the coronary band of the dew claws was edematous (Fig. 2A, arrows) and very painful on touch as evidenced by limb retraction and bleating on touch.

The affected limb was raised off the ground when the kid was moving (swinging lameness; Fig. 2B). On the same compound, there were three adult goats ( $\geq 1$  yr), one sow, one cat, and eight chickens. The other goats, the four examined chickens, and a cat were not affected but 12 out of 13 household members had tungiasis. The affected goat kid was roaming on the compound during day time whereas other goats were tethered in bushes. However, it was housed during the night with other goats in a goat shade on the compound which had a dusty floor.

### Intervention

Affected kids were dewormed with Wormicid 150 (levamisole 150 mg; Cosmos Limited, Nairobi City, Kenya) and Supona aerosol (chlorfenvinphos 4.8%, dichlorophos 0.75%, and gentian violet

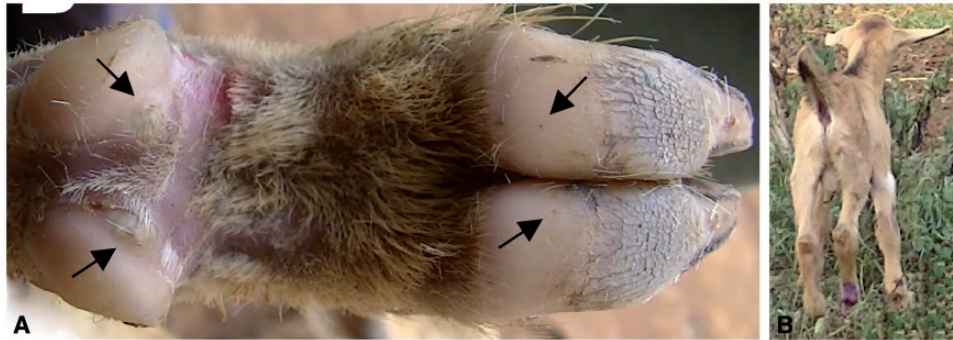
0.145%; Pfizer Laboratories (Pty) Limited, Sandton, 2196, South Africa) was applied on the affected sites to kill the embedded sand fleas and control secondary bacterial infections. One viable sand flea (Stage III) was extracted from each of the goats, fixed in 70% ethanol, and transported to the laboratory at the College of Veterinary Medicine, Animal Resources and Bio-security, Makerere University and the Freie Universität, Berlin, Germany, for morphological identification based on features described previously (De Avelar et al. 2012, Ezquiaga et al. 2015). The chitin of the anterior hypertrophic abdominal segment of the gravid fleas had an appearance reminiscent of a clover leaf on light and electron microscopy hence identified as *T. penetrans* (Mutebi et al. 2015).

In a follow-up 1 wk after the treatment, the kid in Case 1 was reported to have died 4 d after treatment following a short-clinical course of illness characterized by anorexia and a mucoid nasal discharge. No viable sand fleas were detected and healing by re-epithelialization had taken place when the kid in Case 2 was re-examined 1 wk post-treatment. The kid had also regained a normal gait.

### Discussion

Data on tungiasis-associated morbidity in animals is scarce. Regarding goats, only a few cases have been described in South America (Trentini et al. 2000, Gustinelli et al. 2006). Most of these were attributed to *T. trimamillata*, which was initially misidentified as *T. penetrans* (Linardi et al. 2013). An epidemiological study in Uganda during which these two cases were identified, detected tungiasis in only two goat kids from two villages out of 848 goats examined from 10 villages (Mutebi et al. 2015). In general, it appears that goats represent rather uncommon hosts of *T. penetrans* in sub-Saharan Africa. This may be attributed to the tough horny hoof wall and thick skin which increase as the goats mature and move on rough surfaces resulting into a considerable barrier for penetrating sand fleas. This may explain why mature goats on the same compound were not infected. However, goat kids still have soft hoof walls and thinner stratum corneum. In this case, the affected kids were the only young goats ( $\leq 5$  mo) on the compounds on which they were detected.

Necrosis of the hoof wall in one kid could be attributed to a dense cluster of sand fleas exerting pressure on tissues at the site of penetration. In addition, the goat kid may have rubbed the itchy



**Fig. 2.** Tungiasis in Case 2. Right hind leg of a goat kid with viable sand fleas (A) surrounded by edematous zones at the coronary band of claws (arrows). Goat kid with swinging lameness (B).

lesions against hard surfaces further aggravating the necrosis. The site of extensive necrosis (soles of the hooves, Fig. 1A and B) further supports this assertion since the sole of the hoof is the area that goats can easily rub against hard surfaces.

In humans and pigs, the degree of morbidity parallels the intensity of infection (Feldmeier et al. 2004). From the cases presented it appears that in young goats, even a few lesions can induce severe morbidity as indicated by severe inflammation, tissue necrosis, and lameness. Therefore, tungiasis should be included among the differential diagnoses whenever hoof necrosis and lameness are detected in goats in endemic areas. The cause of death of one of the kids was not ascertained. However, from the clinical history obtained, respiratory complications such as pneumonia are implicated.

As demonstrated in this article, animal tungiasis can cause severe morbidity. It is also an important epidemiological factor in human tungiasis in sub-Saharan Africa (Mutebi et al. 2015). Therefore, ectoparasite control should be encouraged among animal owners. However, an effective compound is yet to be identified. The chlorfeniphos and dichlorophos in the Supona wound spray appeared to be tungicidal at least in one kid and the antibacterial effects of gentian violet presumably helped to curb super infections thus facilitating healing. However, these effects need to be validated through controlled studies.

## Conclusion

Tungiasis can cause severe morbidity in goats especially kids manifesting with variable degrees of lameness. Therefore, tungiasis should be considered a differential diagnosis when lameness and hoof lesions are detected in goats in endemic areas.

## Acknowledgments

The Management of High Heights Initiatives and the goat owners are appreciated for their support. No specific funding was received for this study. The cases described were detected during an epidemiological survey of animal tungiasis which was supported by Bayer Animal Health, Leverkusen, German and the German Academic Exchange Service (DAAD). Data are part of Francis Mutebi's thesis.

## References Cited

De Avelar, D. M., A. X. Linhares, and P. M. Linardi. 2012. A new species of *Tunga* (Siphonaptera: Tungidae) from Brazil with a key to the adult species and neosomes. *J. Med. Entomol.* 49: 23–28.

De Avelar, D. M., E. J. F. Filho, and P. M. Linardi. 2013. A new species of *tunga* (siphonaptera: Tungidae) parasitizing cattle from Brazil. *J. Med. Entomol.* 50: 679–684.

Eisele, M., J. Heukelbach, E. V. Marck, H. Mehlhorn, O. Meckes, S. Franck, and H. Feldmeier. 2003. Investigations on the biology, epidemiology, pathology and control of *Tunga penetrans* in Brazil: I. Natural history of tungiasis in man. *Parasitol. Res.* 90: 87–99.

Ezquiaga, M. C., M. P. Linardi, D. M. De Avelar, and M. Lareschi. 2015. A new species of *Tunga* perforating the osteoderms of its armadillo host in Argentina and redescription of the male of *Tunga penetrans*. *Med. Vet. Entomol.* 29: 196–204.

Feldmeier, H., M. Eisele, E. V. Marck, H. Mehlhorn, R. Ribeiro, and J. Heukelbach. 2004. Investigations on the biology, epidemiology, pathology and control of *Tunga penetrans* in Brazil: IV. Clinical and histopathology. *Parasitol. Res.* 94: 275–282.

Feldmeier, H., L. Witt, S. Schwalfenberg, P. M. Linardi, R. A. Ribeiro, R. A. C. Capaz, E. V. Marck, O. Meckes, H. Mehlhorn, N. Mencke, and J. Heukelbach. 2007. Investigations on the biology, epidemiology, pathology and control of *Tunga penetrans* in Brazil. VI. Natural history of the infestation in laboratory-raised Wistar rats. *Parasitol. Res.* 102: 1–13.

Fioravanti, M. L., S. Pampiglione, and M. Trentini. 2003. A second species of *Tunga* (Insecta, Siphonaptera) infecting man; *Tunga trimamillata*. *Parasite* 10: 282–283.

Gustinelli, A., M. L. Fioravanti, V. Fabbri, M. Trentini, G. Onore, M. Caffara, and S. Pampiglione. 2006. Pathology of *Tunga trimamillata* (Siphonaptera, Tungidae) in animals, pp. 6–11. *In*, ICOPA XI, 2006, Glasgow.

Linardi, P. M., and D. M. D. Avelar. 2014. Neosomes of tungid fleas on wild and domestic animals. *Parasitol. Res.* 113: 3517–3533.

Linardi, P. M., D. M. De Avelar, and E. J. Facury Filho. 2013. Establishment of *Tunga trimamillata* (Siphonaptera: Tungidae) in Brazil. *Parasitol. Res.* 112: 3239–3242.

Linardi, P. M., C. M. L. Calheiros, E. B. Campelo-Junior, E. M. Duarte, J. Heukelbach, and H. Feldmeier. 2010. Occurrence of off-host stages of *Tunga penetrans* (Siphonaptera) in various environments in Brazil. *Ann. Trop. Med. Parasit.* 104: 337–345.

Mutebi, F., J. Krücken, H. Feldmeier, C. Waiswa, N. Mencke, E. Sentongo, and G. von-Samson-Himmelstjerna. 2015. Animal reservoirs of zoonotic tungiasis in endemic rural villages of Uganda. *PLoS Negl. Trop. Dis.* 9: e0004126.

Nagy, N., E. Abari, J. D'Haese, C. Calheiros, J. Heukelbach, N. Mencke, and H. Feldmeier. 2007. Investigations on the life cycle and morphology of *Tunga penetrans* in Brazil. *Parasitol. Res.* 101: S233–S242.

Pampiglione, S., M. L. Fioravanti, A. Gustinelli, G. Onore, B. Montovani, A. Luchetti, and M. Trentini. 2009. Sand flea (*Tunga* spp.) infections in man and domestic animals: state of the art. *Med. Vet. Entomol.* 23: 172–186.

Thielecke, M., and H. Feldmeier. 2013. The fate of the embedded virgin sand flea *Tunga penetrans*: hypothesis, self-experimentation and photographic sequence. *Travel. Med. Infect. Dis.* 11: 440–443.

Trentini, M., S. Pampiglione, S. Gianneto, and B. Finocchiaro. 2000. Observations about specimens of *Tunga* spp. (Siphonaptera: Tungidae) extracted from goats in Ecuador. *Parassitologia* 45: 65.

Ugbomoiko, U. S., L. Ariza, and J. Heukelbach. 2008. Pigs are the most important animal reservoirs for *Tunga penetrans* (jigger flea) in rural Nigeria. *Trop. Doct.* 38: 226–227.