

## **2. REVIEW OF LITERATURE**

### **2.1. General Review**

Minimal invasive joint surgery has been reported in humans since the early 1918s (Takagi 1933). Watanaba (1960) performed the first hock joint arthroscopy in equine.

Large animal arthroscopy was first presented in the German literature in 1973 (McIlwraith 1990a) and in the English European literature in 1975 and 1977 (Smith 1975; Knezevic and Wrshs 1977). The first description of arthroscopic surgery in the United States involved the carpus (Ommet 1981; Valdez et al. 1983).

Intraoperative fluoroscopy was first used by Coltman (1948) and since then has been used extensively in many areas of surgery. Advances in fluoroscopic technology have enabled high resolution images to be obtained using significantly lower doses of radiation (Gehrke et al. 1993).

Equine minimal invasive joint surgery with the aid of intraoperative fluoroscopy was first described in the German literature in 1992 and this involved the removal of isolated shadows from the region of the extensor process of the third phalanx (Hertsch 1992).

### **2.2. General overview of fluoroscopic imaging**

#### **2.2.1. Historical Development**

The first fluoroscopes consisted of an X- ray tube and fluorescent screen. The radiologist positioned the screen between the patient and himself or herself with the x-ray tube behind the patient. A lead glass layer was included to reduce exposure to the radiologist. Other early fluoroscope screens were held by the radiologist or worn in the head like goggles (Krohmer 1989; Eisenberg 1992).

The major problem with first generation fluoroscopy was production of an image with sufficient brightness and even with advances in the fluorescent material and screen design, it was not possible to improve the performance of early fluoroscopes because the deficiencies of

the human eye at low light levels. To overcome the deficiencies of viewing the dim fluorescent screen, image intensifier devices were developed and introduced in 1953 (Krohmer 1989; Schueler 2000). These devices provide sufficient brightness gain to allow use of photopic vision for improved spatial and contrast resolution. Early image intensifiers used a system of optical lenses and mirrors to magnify and view the output image. The major problem with the viewing system was that the viewing angle was narrow. As a result, the operator's position needed to be frequently adjusted as the image intensifier was moved. In addition, only one person at a time could observe the image, making it very difficult to communicate observations to others for teaching or discussion. These shortcomings were later removed by using a video camera to view the output image and display in a monitor.

Bushberg, et al. (1994) and Blume (1998) mentioned that, additional advancements in fluoroscopic imaging have occurred in recent years. Image intensifiers are now available in large sizes that allow visualization of the entire abdomen. Video camera and monitor performance improvements have resulted in greater spatial and contrast resolution. The introduction of video signal digitization has allowed application of digital image processing technique for improved fluoroscopic image quality and digital image recording.

Digital fluoroscopy is currently most commonly configured as a conventional fluoroscopy system ( Tube, table, image intensifier, video system) in which the analog video signal is converted to digital format with an analog-to-digital converter (ADC). A digital fluoroscopy system is composed of a conventional fluoroscopy system plus hardware for the digitization, processing, and storage of images. The digital data may be processed in real time or during later review by means of many image processing techniques. These techniques can be used to decrease radiation exposure to the patient and medical staff or enhance the visualization of anatomy (Pooley, et al. 2001).

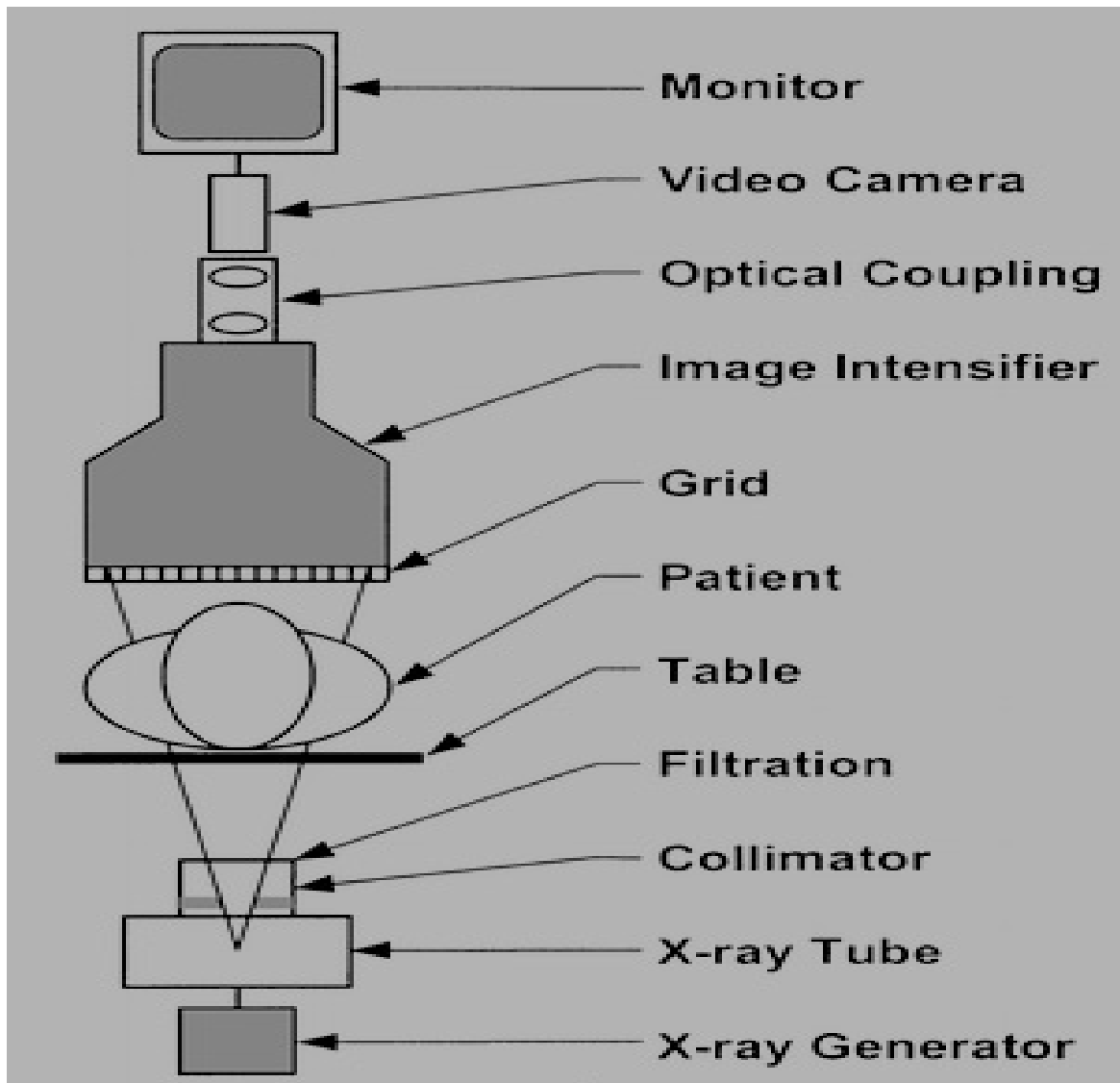
### **2.2.2. Fluoroscopic imaging chain**

Gehrke, et al. (1993) stated that, modern x-ray image intensification devices are essentially unchanged in design since its introduction by Coltman in 1940s. These devices rely upon an x-ray beam that excites an image tube screen with the production of photoelectrons. These electrons are electronically accelerated to impinge on a tungsten target producing x-rays which are focused onto a phosphorous screen, producing a visible image. This image is then

## *Review of Literature*

focused onto a television camera. It is this image that the television camera scans and converts into a composite signal. The signal is processed and converted into digital data and stored for retrieval by the surgeon.

Schueler (2000) described that, some components included in a modern fluoroscopic imaging system (Figure 1) are similar to those included in systems used exclusively for radiography, whereas others are unique to fluoroscopy. Typically, additional apparatus are attached to allow for image recording, such as a spot-film device, film changer photospot camera, cine camera, or ADC.



*Figure 1: Diagram shows the components of fluoroscopic imaging chain*

### **2.2.3. Uses and clinical applications of C-arm fluoroscopy**

The use of C-arm fluoroscopy systems has found increased application in a number of areas of both veterinary and human medicine, which included orthopedic, vascular, and cardiac procedures (NRPB 1990; Goldstone, et al. 1993; Loyer and Thomas 1995; Hanson, et al. 1997).

Hempfling (1982) examined the human knee joint with a combined arthroscopic-fluoroscopic technique, in which fluoroscopic examination has been performed during CO<sub>2</sub> filling of the joint. Sixty patients underwent examination by this method. He found that, pathological changes in 18 patients (12 Baker cysts and six ruptures of the knee-joint capsule). All the findings were confirmed at surgery.

Bian, et al. (1997) reviewed the use of a low radiation mobile fluoroscopy unite, that have a smaller C-arm in 100 human patients. The most common indication was closed reduction of distal radial fractures. Fluoroscopically guided joint injections and localisation of implants, foreign bodies and bone tumours were also performed.

They also found that, fluoroscopy is a useful adjunct to arthroscopic assisted fracture reduction and other arthroscopic procedure such as distal ulnar resection. These new generation units produce superior resolution images, are easy to manoeuvre and do not require a radiographer.

Bohanon (1998) mentioned that, fluoroscopy is preferred over radiography for intra-articular drilling procedures (arthrodesis) of the equine distal tarsal joint.

Krettek, et al. (1998) stated that, intraoperative fluoroscopic imaging is used routinely to provide the human surgeon's optical feedback during the percutaneous insertion of surgical instruments and implants and for intraoperative control of length, axial and rotational alignment during osteosynthesis.

Cook, et al. (1999) evaluated the fluoroscopically guided closed reduction and internal fixation of fractures of the lateral portion of the humeral condyle in ten dogs. After surgery the dogs were evaluated by means of lameness scores, elbow range of motions, radiographic

## *Review of Literature*

---

assessment, and owner evaluation function. The conclusions and clinical relevance were that, fluoroscopic guidance for closed reduction and internal fixation of the lateral portion of the humeral condyle in dogs is an effective technique.

Thomas, et al. (1999) stated that, the new hand held portable fluoroscopic unit has gained popularity for detection of orthopaedic injuries in horses. Use of this unit as a survey tool during prepurchase examination has also increased.

Schueler (2000) noted that, fluoroscopy is used to visualize the motion of internal fluids, structures, and devices. The primary function of fluoroscopy is real-time imaging to provide visualisation of dynamic processes as they occur. For some clinical applications, a fluoroscope is used to determine a diagnosis from live display of patient anatomy. For other applications, fluoroscopy is used to position the patient for subsequent image recording or devices for interventional procedures.

Suhm, et al. (2000) stated that, Fluoroscopy is used to guide surgical instruments during orthopedic procedures. Radiation exposure and lack of spatial information are drawbacks of this method. Improvements are expected when fluoroscopy-based surgical navigation is used for intra-operative guidance.

In addition they concluded that, Fluoroscopy-based surgical navigation provided precise intra-operative guidance for computer-assisted distal locking with minimal use of fluoroscopy. The complex system and related procedure times may be drawbacks in these applications

Bale, et al. (2001) declared that, Fluoroscopy is the imaging method of choice to perform a variety of surgical procedure such as fracture reduction, osteotomy, and bone tumor biopsy. The authors developed a minimally invasive method with computer assisted navigation for retrograde drilling of osteochondral lesions of the human talus.

Bhandari and Shaughnessy (2001) reported an efficient, minimally invasive technique of percutaneous retrograde insertion in a model of rat femoral fracture healing with the aid of fluoroscopy that eliminate the need for incisions sutures, and postoperative radiographs.

## *Review of Literature*

---

Moore (2001) reported that, fluoroscopic guided forceps retrieval appear to be an effective method of treatment of oesophageal foreign bodies in dogs. No complications specific to the method of retrieval were encountered.

Boening (2002) advised the use of fluoroscopy for useful anatomic orientation and positioning of either scope or instrument during arthroscopy of the palmar/plantar pouch of the coffin joint.

Keegan and Dyson (2003) mentioned that, image-intensified fluoroscopy is the only legal technology allowed in veterinary practice, is not recommended to use in routine veterinary practice, and should only be used after specialized training. Fluoroscopy is useful for monitor positioning of the needle for injection of the navicular bursa.

Image guided surgery is a fast developing field with a growing impact on orthopaedic surgery. Common synonyms are computer-aided surgery, computer integrated surgery, computer-assisted virtual fluoroscopy, navigation surgery and robotic surgery. They all describe the use of sophisticated computer technology for the optimization of surgical performance (Tylor, et al. 1996; Berleman, et al. 1997).

Auer, et al. (2003) described the first use of computer assisted orthopedic surgery (CAOS) in equine. The indications for application of CAOS included fractures of the distal, middle, and proximal phalanx, the navicular bone condylar and saucer fractures of MCIII/MTIII, as well as cystic lesions of the various bones. CAOS is very helpful technique to accurately implant screws at the desired location and at the correct angle relative to the fracture plane, which result in a better prognosis for the patient.

### **2.2.4. Radiation exposure**

Miller, et al. (1983) said that, similar to routine radiography, personnel involved in fluoroscopic procedure should be protected from the primary x-ray beam and stray radiations. Exposure to the scattered radiation is greatest to the fluoroscopist's head, neck, and hands.

Using thin-layer lithium fluoride chips for thermoluminescence dosimeter, the same authors directly measured the radiation exposure encountered by the primary surgeon during seven

## *Review of Literature*

---

operative procedures that were done utilizing fluoroscopic guidance technique. The data in these studies indicated that the standard lead apron that is used for radiation protection during the use of fluoroscopy provide adequate protection to most of the body; however, the surgeon is exposed to a significant levels of scatter radiation to the head, neck, and hands. All radiation exposures that were measured beneath the lead apron worn by the surgeon were in the range of zero to five milliroentgens.

Fluoroscopic equipment is presently responsible for a highly significant component of medical radiation dose. Physicians and staff members performing these procedures are exposed to relatively high levels of scattered radiation and are sometimes irradiated directly (NRPB 1990; Goldstone, et al. 1993).

Goldstone, et al. (1993) evaluated the radiation exposure to the hands of human orthopedic surgeon during fluoroscopically guided procedures. They directly measured the radiation exposure to the hands during fluoroscopic screening in a series of consecutive cases over a month. Extremity monitoring was carried out using thermoluminescent dosimeters. The dosimeter was secured to the operating surgeon's dominant index finger. 44 procedures were carried by 9 different surgeons. Each surgeon performed between 1 and 15 cases (mean 4.9 cases). The mean time per procedure was 1.2 minutes (range 0.1- 5.4). The total radiation dose received per surgeon ranged from 0.048-2.329 mSv. In 80% of procedures the dose of radiation to the surgeon's hand was less than 1 mSv. The extrapolated annual dose, even for the surgeon with the highest radiation exposure, was well below the annual dose limit for extremities of 500 mSv per year recommended by the international Commission of Radiological Protection (ICRP).

A similar study was conducted by Larson, et al. (1995) to evaluate the radiation exposure during 50 consecutive fluoroscopically assisted anterior cruciate ligament reconstructions. For the 50 procedures, total time using the fluoroscopy was 119.61 or 2.38 minutes per procedure. The average radiation exposure to the surgeon hand was 0.067 mSv per minute of fluoroscope use. It would take 7463.08 minutes of fluoroscope time, to exceed the recommended occupational exposure limit of 500 mSv per year.

Mehlman and DIPasquale (1997) recommended that, operating-room personnel remain a minimum of 46 to 70 cm from the X-ray beam. People working more than 90 cm from the

## *Review of Literature*

---

beam have been considered to be at low risk for radiation exposure. The surgeon may often be within this radius and can be subjected to a large amount of scattered radiation.

Fuchs, et al. (1998) performed a prospective study, in which 24 operative procedures with fluoroscopic guidance were undertaken to measure the radiation exposure of the primary surgeon. The dose received per procedure ranged from 0.6 to 259.3 mSv and was well within the government guidelines.

Van Staden, et al. (2000) and Tremains, et al. (2001) reported a decrease in radiation exposure to both the surgeon and the patient during surgical procedures on upper extremities with the C-arm setup in the inverted position, with the radiation source up and the image intensifier down as an operating table.

However, Matthews (2000) and Waseem and Kenny (2000) have advised against this practice (X-ray tube up), citing increased radiation exposure and possible equipment damage.

In order to determine the exposure of personnel towards X-ray radiation during veterinary radiographic examination with the C-bow X-ray units. Nölker and Ueltschi (2001) designed a study, in which the animals were divided into three groups by weight, 3, 10 and 30 kg, and the thorax, abdomen and extremities were X-rayed. The irradiation of the hands, neck and genitals of the examining veterinarian, protected and unprotected by a 0.35 mm lead apron, was determined using a portable dosimeter. Each measurement was repeated ten times and a total of 360 measurements were recorded. The actual exposure times of the C-bow X-ray examinations was also recorded. The estimated irradiation doses were compared with the legal limits permitted in Germany. In the case of exposure to hands, it was estimated that the legal limit of 500 mSv/ year will be exceeded when exposed to X-rays for about 16 hours per months provided that protection is used. For the neck and eye area, the legal limit of 150 mSv/ year is likely to be reached after 8 hours per month. For the genital area, protected by a 0.35 mm lead apron, there is no danger of exceeding the legal value. Without protection, the legal value of 50 mSv/ year would be exceeded after 4 hours per month.

Mahesh (2001) stated that, since the early 20<sup>th</sup> century, fluoroscopy has been integral to the practice of diagnostic radiology. However, over the past 15-20 years, fluoroscopic procedure mixes have included an increasing fraction that are primary therapeutic. Because these



procedures are often technically difficult, they can involve total exposure times exceeding an hour or more. The nature of these prolonged fluoroscopic procedures has led to an increase in reports of high skin doses causing a significant tissue injury. There are a variety of techniques to reduce the dose of radiation during protracted interventional procedures; some are methodical and some involve taking advantage of technical features present in modern equipment, these techniques include; Intermittent fluoroscopy, Pulsed fluoroscopy, Removal of grid from the x-ray system, Last image hold and electronic collimation, Dose spreading, Image magnification and Adjustment of beam quality.

King, et al. (2002) evaluated the effectiveness of new radiation protection method designed to decrease the amount of scatter radiation received by practitioners performing procedures under fluoroscopic guidance. A sterile, disposable, lead-free drape containing radiation protection material composed primarily of bismuth was used. They found that, scattered radiation to physicians, as measured by thermoluminescent dosimeters placed on each eye, the thyroid, and the wrist, was reduced by 12-fold for the eyes, 25- fold for the thyroid, and 29-fold for the hands when the radiation-attenuating drape is used and compared with control studies performed with a standard nonattenuating surgical drape alone. Monthly Thermoluminescent dosimeter measurements decreased 4-fold in one physician. Using the protective drape reduced exposure to the assistant in each case to negligible levels. Skin entrance dose was not increased unless the protective drape was placed directly in the X-ray beam.

## **2.3. Indications and methods for equine joint surgical treatment**

### **2.3.1. Isolated radiopaque opacities (isolated shadows)**

#### **2.3.1.1. Terminology**

For the X-ray finding isolated radiopaque opacity many synonyms, all of them describe only the finding without any consideration to the exact etiology and pathogenesis. The different synonyms in both the German and English literature are as follow:

Intra-articular avulsion fracture, intra-articular osteochondral fragment, intra-capsular fragment, fragment, avulsion fragment: (Numans and Winzer 1961&1964; Birkland and Haakenstand 1968; Dietz, et al. 1975; Dämmrich 1985; Dobberstein, et al.1985)

## *Review of Literature*

---

Loose fragment: (Baker 1963)

Osteocartilagenous bodies: (Baker 1963; Nixon 1990)

Free body, corpus liber: (Baker 1963; Adams 1964; Copelan 1964; Milne 1964; Baker, et al. 1966; Diethelm 1971; Schiebtz, et al. 1975; Stromberg 1979; Böhm and Nagel 1980; Sönnichsen, et al. 1982; Van Stuntum 1983; Dämmrich 1985; Dobberstein, et al. 1985; Dik and Gunss 1987; Hurtienne 1986; Hertsch 1991)

Joint mouse: (Baker 1963; Dietz, et al. 1975; Schebitz, et al. 1975; Sromberg 1979; Sönnichsen et al, 1982; Wintzer 1997; Edwards 1984; Breuer and becker 1985; Hurtienne 1986; Dik and Gunsser 1987)

Bony fragments: (Copelan 1964; Yovich, et al. 1985; Dik and Gunsser 1987; Sandgren 1988; Gröndhal 1992; Nixon und Pool 1995)

Chip: (Adams 1969; Rooney 1975; Raker 1973; O'Brien 1977; Ferraro 1978; Allan 1979; Fackelman 1983; Edwards 1984; Breuer and Becker 1985; McIlwraith 1986; Stashak 2002)

Sequester: (Diethelm 1971; Zeller, et al. 1978; Hertsch 1991)

Ossicles/ osseous islands: (Nilsson and Olsson 1973)

Osteochondral Pieces: (Dietz, et al. 1975; Schebitz, et al. 1975)

Chip Fractures: (Dietz, et al. 1975; Dämmrich 1985; Hurrтинne 1986; Butler, et al. 1993)

Discrete radiodensity: (O'Brien 1977)

Dissekate: (Samy 1977; Hertsch 1991)

Loose bodies: (Hoppe 1984; McILwraith, et al. 1991; Bramlage 1993)

Flakes: (Stromberg 1979)

## *Review of Literature*

---

Flaps: (Stromberg 1979; Pool 1993)

Intra-articular fracture: (Böhm and Nagel 1980; Schebitz, et al. 1975)

Fracture fragment: (Haynes 1980; Grant 1982; Copelan and Bramlage 1983)

Corpus Pendulance: (Fessler and Girtler 1983)

Joint bodies: (Fessler and Girtler 1983; Stöckli and Ultschi 1992; Morgan 1999)

Osteochondral fragments: (Yovich, et al. 1985; Yovich and McIlwraith 1986; Nixon 1990; McIlwraith, et al. 1991; Dalin, et al. 1993; Carlstein, et al. 1993; Sandgren, et al. 1993; Philipsson, et al. 1993; Nixon and Pool 1995)

Osseous densities: (Yovich, et al. 1985; Gröndahl 1992)

Arthrolith/ joint stone: (Hurtienne 1986; Hertsch and Höppner 1999)

Small mineralized fragments: (Honnas 1992)

Intra-articular body: (Stöckl and Ultschi 1992)

Palmar/plantar Osteochondral fragments (POF): (Dalin, et al. 1993; Carlsten, et al. 1993; Philipsson, et al. 1993; Sandgren, et al. 1993)

Dissecting lesions: (Nixon 1990)

Cartilage flap, flap lesion: (Nixon 1990; Pool 1993)

Detached fragments: (Dik 1998)

Isolated bone chips: (Hertsch and Höppner 1999)

### **2.3.1.2. Specific Sites in different joints and their treatment**

#### **2.3.1.2.1. Distal interphalangeal (coffin) joint:**

Radiopaque bodies were observed at different sites in the coffin joint;

##### *In the region of the extensor (pyramidal) process*

-Small mineralized fragments proximal to the extensor process as an incidental finding in horses that are clinically normal, which may be osteochondrosis lesion of the extensor process or separate centre of ossification (Pettersson 1976; Scott, et al. 1979; Yovich 1989; Honnas, et al. 1992)

-Ectopic (dystrophic) ossification (metaplasia) of the joint capsule or at the insertion of the common digital extensor tendon (CDET) (Hertsch 1992)

-Fractures of the basis or the apex of the extensor process which may be traumatic or avulsion fracture due to excessive tension on the CDET or overextension of the coffin joint resulting in contact of the extensor process with the middle phalanx and trauma to the dorsal aspect of the foot (Colles 1983; Yovich 1989; Honnas, et al. 1992; Stashack 2002)

- Fracture of a marginal osteophyte (spur) which developed due to degenerative joint disease (DJD) of the coffin joint. This fracture may be as a result of overextension (Hertsch 1992; Stashack 2002)

##### *In the region of the distal aspect of the middle phalanx*

-Osteochondral chip fractures of the distal dorsolateral aspect of the middle phalanx (Vail and McIlwraith 1992)

-Osteochondral chip fractures of the distal palmar/plantar articular border of the middle phalanx (Torre 1997)

## *Review of Literature*

In the literatures the researchers found that the frequency of extensor process radiopaque bodies ranged from 0-44, 1 % (table 1)

1,7%	Nilsson and olsson 1973	2 from 86 Standardbred horses
18,1%	Pettersson 1976	23 from 79 horses with pedal bone fractures
2,6%	Scott, et al. 1979	4 from 65 horses with pedal bone fractures
0%	Böhm and Nagel 1980	242 horses with lameness
5,7%	Müller 1982	43 from 754 horses lameness free
0,19%	Yovich, et al. 1982	1 from 19 horses with pedal bone fractures
10,7%	Harfst 1986	18 from 186 3 years old horses
44,1%	Hertsch and Haack 1987	48 from 92 horses with pedal bone fractures
5,8%	Terberger 1988	109 from 1874 horses
4,6%	Hertsch, et al. 1997	7 from 151 Holstein foals, yearling till 2 year-old.

Duncan and Dingwall (1971) stated that, avulsion fracture of the extensor process of the 3<sup>rd</sup> phalanx is not commonly encountered in the horse; consequently, the techniques for surgical removal of the fragments have been not widely published.

Pettersson (1976); Harfst (1986); Honnas, et al. (1988) and Miller and Bohanon (1994) found that, fractures of the extensor process of the distal phalanx occur most frequently in the forelimb, and, occasionally, are bilateral.

Although various breeds are affected, male horses tend to be overrepresented with large extensor process fractures (Pettersson 1976; Scott 1979; Dechant, et al. 2000)

Hertsch (1992) and Bertone (1996) noticed that, the fragment shape, contour, size, and location varies from round to triangular, sharp to diffuse contour, small (pepper seed-size) to large (Pea-size), and non displaced with direct location on the pedal bone to displaced with proximal dislocation.

## *Review of Literature*

---

Terberger (1986) observed that, fractures of the extensor process of the distal phalanx appear seldom in horses under 2 years; in contrast appear most frequency in horses over 2 years old.

Treatments for fractures of the extensor process have included stall confinement, surgical removal of the fragment, or internal fixation using lag screw technique (Adams 1974; Haynes and Adams 1974; Pettersson 1976; Rose, et al. 1979; Gabel and Bukowiecki 1983; Honnas, et al. 1988; Honnas 1992; Honnas, et al. 1992)

Pettersson (1976) and Honnas, et al. (1988) mentioned that surgery is indicated for all extensor process fracture with an articular component unless DJD is advanced. Stall rest is generally unsuccessful in returning horses with fracture of the extensor process to soundness because the fracture generally will not heal.

Adams (1964); Duncan and Dingwall (1971) and Scott, et al. (1979) described that, the avulsion fracture of the extensor process of the 3<sup>rd</sup> phalanx can be successfully removed through arthrotomy of the hoof joint, in which they approached these fractures through longitudinal incision of the CDET, Whereas Numan and Winzer (1961) approached these fractures lateral to the CDET.

Numan and Winzer (1961) and Boening (1980) declared that, removal of the extensor process fragment via arthrotomy has led to unfavourable results in some cases.

Haynes and Adams (1974); Rose, et al. (1979); Honnas 1992 and MacLellan, et al. (1997) reported that, large fractures of the extensor process can be successfully treated by lage-screw fixation of the fragment to the parent bone.

In order to evaluate the technique of arthrotomy of the hoof joint for removal of avulsion fractures of the extensor process of 3<sup>rd</sup> phalanx, Duncan and Dingwall (1971) performed this technique in 2 horses with small extensor process fractures. They found that, each horse has returned to its previous usefulness and has remained sound.

Dechant, et al. (2000) evaluated a series of large fragments of the extensor process treated by use of arthrotomy and reported that 8 of 14 horses had a successful outcome. Outcome was not associated with age, duration or severity of lameness or fragment size.

Brems, et al. (1986) described a technique in which a fibrin adhesive material was used for fixation of the extensor process fractures.

Boening, et al. (1989); McIlwraith (1990a) and Honnas, et al. (1992) mentioned that, removal of the small extensor process fragments by arthroscopic guidance through the dorsal pouch of the distal interphalangeal joint is the preferred surgical technique, because this technique reduces tissue damage, improves cosmetics, permits a more thorough evaluation of the joint, and minimize recovery time.

Boening, et al. (1989) evaluated a series of small fragments of the extensor process treated by use of arthroscopy and reported 14 of 16 horses returned to soundness.

Vail and McIlwraith (1992) removed an intra-articular osteochondral chip fracture of the distal dorsolateral aspect of the right hind middle phalanx in a 4-year-old Dutch Warmblood gelding arthroscopically. Accessibility and visibility of the fragment were excellent, and there was minimal soft tissue trauma.

Hertsch (1992) described a new technique to remove extensor process fragments from the coffin joint; with the aid of C-arm fluoroscopy the isolated shadows in the area of the extensor process were removed under continuous rinsing.

#### **2.3.1.2.2. Proximal interphalangeal joint (PIPJ)**

Radiopaque bodies were observed at different sites in the PIPJ joint;

-Joint capsule ossification as a manifestation of DJD (El-Guindy, et al. 1986).

-Synovial osteochondroma''Corpora libera'' (El-Guindy, et al. 1986).

-Small radiopaque body (less than approximately 2mm in diameter, smooth and uniformly opaque) may occasionally be present at the dorsal aspect of the proximal articular surface of the middle phalanx as incidental finding (Butler, et al. 1993).

## *Review of Literature*

---

-Small periarticular or marginal osteophytes are frequently seen on the dorsoproximal aspect or the palmar/plantaroproximal aspect of the middle phalanx in the early cases of DJD (Trotter, et al. 1982; El-Guindy, et al. 1986; Butler, et al. 1993).

-Dorsal or palmar/plantar osteochondral chip fracture of either the lateral or medial eminence of the middle phalanx (Welch and Watkin 1991; Schneider, et al. 1994; Watkins 1996; Torre 1997; Nixon 1999).

Stashak (1987) stated that, Osteochondral chip fractures of the PIPJ may be treated conservatively depending on the horse's intended purpose, amount of articular surface involved, fracture duration or degree of lameness present.

Osteochondral fractures associated with PIPJ that result in lameness are best treated by surgical removal with the use of arthrotomy (Modransky, et al. 1982; Torre 1997).

Welch and Watkins (1991) described the arthrotomy technique for surgical excision of an osteochondral fragment from the proximal palmar aspect of the second phalanx in a three-year-old Thoroughbred colt. The result suggested that surgical excision through the arthrotomy can produce favourable outcome.

While Schneider, et al. (1994) mentioned that, the use of arthroscopy is preferred. Dorsal and palmar/plantar fragments can be removed by arthroscopy, although the manoeuvrability of the instrumentation is somewhat limited in the dorsal approach because of the extensor tendon attachment immediately distal to the joint. The palmar or plantar recess of PIPJ is larger, which makes surgical manipulation easier.

The same author reported the usefulness of arthroscopy for removal of osteochondral fragments from the dorsoproximal margin of the middle phalanx in 4 PIPJs in 3 horses. After surgery all horses were able to race again and fibrous thickening of the joint capsule developed on the dorsal surface of the joints. A fibrous scar was palpable at the surgical site in all horses.

Torre (1997) described the use of arthrotomy for removal of osteochondral chip fractures of the middle phalanx in 5 horses (2 Standardbreds, 2 Show Jumpers, and one Thoroughbred): in



two cases, the fragment originated from the palmar/plantar proximal border of the middle phalanx in the PIPJ; in one case from the proximal lateral palmar eminence; in two cases from the distal lateral palmar/plantar articular border in the coffin joint. Of the 5 surgically treated cases, 4 returned successfully to the previous performance level, while one was lost for long term follow up.

### **2.3.1.2.3. Metacarpophalangeal and Metatarsophalangeal (Fetlock) Joint:**

Radiopaque bodies were observed at different sites in the fetlock joint;

*In the region of the dorsal aspect of the joint* (Edward 1984; Yovich, et al. 1985; Yovich and McIlwraith 1986; Schube, et al. 1991; Kawcack and McIlwraith 1994; Hertsch and Höppner 2000)

- Osteochondral fragments of the proximal dorsal aspect of the first phalanx.
- Osteochondral fragments of the distal end of the third metacarpal or metatarsal bone (less commonly).
- Osteochondritis dissecans of the sagittal ridge of the metacarpus or metatarsus.
- Ectopic mineralization (metaplasia) of the joint capsule synovial villi.
- Fracture of an arthritic marginal osteophyte.

*In the region of the palmar/plantar proximal aspect of the first phalanx* (Birkeland 1972; Sönnichsen, et al. 1982; Harfst and Hertsch 1988; Barclay, et al. 1987; Foerner 1987; Sandgren 1988; McIlwraith and Foerner 1990; Gröndahl 1992; Zöttl, et al. 1995)

There are four types of radiopaque bodies that are found between the base of the proximal sesamoid bones and the palmar/plantar eminence of the proximal aspect of the proximal phalanx.

- Type I fragments originate from the palmar/plantar eminence of the proximal phalanx just medial or lateral to the sagittal groove.
- Type II fragments originate from the medial or lateral wing of the proximal phalanx (also called ununited fractures of the proximopalmar/plantar tuberosity of the proximal phalanx).
- Type III fragments originate from the base of proximal sesamoid bone.
- Type IV fragments which are osseous bodies (ectopic mineralization) located within the distal sesamoid ligaments and are not contained within the joint space.

## *Review of Literature*

---

In the region of apex of the proximal sesamoid bone (Copelan and Bramlage 1983; Spurlock and Gabel 1983; Fretz, et al. 1984; Zöttl, et al. 1995; McIlwraith and Bramlage 1996; Southwood, et al. 1998)

-Apical and abaxial osteochondral fragments of the sesamoid bone.

-Ectopic mineralization (osseous bodies) located within the branches of the suspensory ligaments.

Adams (1969) and Edward (1984) mentioned that, chip fractures of the proximal end of the first phalanx are relatively common in the fore limb. Most fractures of this type involve the cranial surface, just medial or, less frequently, lateral to the common digital extensor tendon. Chip fractures also occur from the distal end of the third metacarpal bone, but less commonly.

Bony fragments located at the dorsoproximal end of the proximal phalanx have been considered to be traumatic in origin and to cause lameness (Adams 1969). While Edward (1984) have suggested that fragments at this location could be separate centres of ossification or a manifestation of osteochondrosis. It has also been suggested that these fragments are secondary complications affecting joint margins altered by DJD and that the fractures can arise by fragmentation of the original tissue of the joint margin or within the bony base of periarticular lip that forms in DJD (Pool and Meagher 1990)

Yovich and McIlwraith (1986) had noted that, the proximodorsal osteochondral fractures of the proximal phalanx were common in race horses. Fragments may occur on one medial or lateral eminence (most commonly in the former).

Birkland (1972) is the first who described the radiographic appearance and clinical signs of chip fractures involving the postero-proximal end of the first phalanx at the attachment of the oblique distal sesamoid ligament in 29 Trotter horses. All fractures involved the hindlimb, in one case bilaterally. Most of the horses were treated with prolonged rest. Some of these horses recovered while others went lame again when training was used.

## *Review of Literature*

---

Opinions differ as to whether these fragments are result of fractures (Birkeland 1972; Nilsson and Olsson 1973; Pettersson and Rydaen 1982; Bukowiecki, et al. 1985) or osteochondrosis (Barclay, et al. 1987; Sönnichsen, et al. 1982; Foerner 1987; Nixon 1990; Gröndahl 1992)

Petterson and Ryden (1982) have investigated the results of examination and treatment of 65 horses with chip fractures of the palmar/plantar-proximal end of the first phalanx, so called “Birkland fractures”. Only in 4 cases was the mouse found in the fore leg. Out of 57 horses that underwent surgery 64% (+13% not yet clarified) gained full performance ability.

Sandgren, et al. (1993) reported that, Palmar/plantar osteochondral fragments (POF) in the metacarpo/metatarso phalangeal joints most often occur in the hindlimbs and more frequently in the medial part of the joint.

Fractures of the proximal sesamoid bones are common injuries in both racing Standardbreds and Thoroughbreds. These fractures have most often classified as apical, abaxial, sagittal, midbody, or basal (Churchill 1956; Wheat and Rhode 1958; Wirstad 1963; Schneider, et al. 1979; Fretz et al. 1984; Palmar 1982; Bukowieck, et al. 1985; Palmar 1989; Gabel 1990)

Bramlage (1979) in a survey conducted in 1979, 100% of the veterinarian polled (n= 14) recommended surgical removal of apical sesamoid fractures fragments. There was no consensus on the best treatment or prognosis of basal sesamoiden fractures.

Various treatments have been described for proximal sesamoid bones fractures, including extended stall confinement (Peters 1949; Fretz, et al. 1984; Parente, et al. 1993), external coaptation (Peters 1994), cancellous bone grafting with cast immobilization (Medina, et al. 1980; Parenta, et al. 1993), therapeutic cautery (Dietz and Nagel 1960), suspensory ligament tenotomy (Sevelius and Tufvesson 1963), lag-screw fixation (McKibbin and Armstrong 1970; Fackelman 1978; Fackelman and Nunamaker 1988), hemicerclage wiring (Martin, et al. 1991), systemic nonsteroidal anti-inflammatory drugs and intra-articular corticosteroid injection (Superlock and Gabel 1983), and surgical removal via arthrotomy or arthroscopy (Churchill 1956; Wheat and Rhode 1958; Grant 1982; Superlock and Gabel 1983; Parente 1993; Southwood and McIlwraith 2000).

## *Review of Literature*

---

Fackelman (1978); Palm (1992); Copelan and Bramlage (1983); Fretz, et al. (1984); Gabel (1990); Parente, et al. (1993); Bassage and Richardson (1998) and Torre and Motta (1999) said that, fractures of the proximal sesamoid bones were common injuries in racing Thoroughbreds, Standardbreds, and Quarter horses. These fractures take a variety of forms, including apical, abaxial (articular and non articular), mid body, basilar (articular and non articular), sagittal and comminuted. The fore limbs are most frequently affected in the thoroughbred (right fore limb) and Quarter horses, whereas the hindlimbs are most frequently affected in the Standardbred (left hindlimb).

Haynes (1980); Medina (1980); Copelan and Bramlage (1983) and Bukowiecki, et al. (1985) concluded that, basilar fractures of the proximal sesamoid bones were often smaller than apical fractures but impart a worse prognosis because of their attachment to the distal sesamoidean ligaments. Basilar fractures were common in racing Thoroughbreds, usually contain an articular component, and frequently involved the distal third or less of the total mass of the bone. Distraction of the fragment caused a wedge shaped fractures gap.

Copelan and Bramlage (1983); Superlock and Gabel (1983); Fretz, et al. (1984); Bukowiecki, et al. (1985); Parente, et al. (1993); Bertone (1996); Southwood, et al. (1998); Boure, et al. (1999) and Southwood and McIlwraith (2000) advised that, the apical fragments of the proximal sesamoid bones should be removed when less than one-third of the total mass of the proximal sesamoid has fractured. Horses with fractures of less than one-fourth of the abaxial surface of the bone where the suspensory ligament attaches have a better prognosis. Best results achieved if surgery is performed within 30 days after fracture.

In another study Wheat and Rhode (1958) reported successful surgical removal via arthrotomy of apical sesamoid fragments from fractures of several months' duration. Of the 12 horses so treated, 3 raced, 3 did not, and sufficient time had not elapsed to evaluate the others.

Torre and Motta (1999) studied the incidence and distribution of fractures of 369 proximal sesamoid bones in 354 Standardbred horses. They found that fractures of the apical portion of the sesamoid bone were the most common, making up more than 88.1% of sesamoid fractures. Apical fractures were frequently articular, were singular, were rarely comminuted, and were usually involve less than one-third of the bone. In Standardbreds, apical fractures occurred more frequently on the lateral sesamoid bones of the left hindlimb (42.8%) than on

## *Review of Literature*

the right hindlimb (36.6%). Basilar fractures were less common than apical fractures (6%). The abaxial fractures were uncommon (3%).

Isolated shadows of the fetlock joint are relatively common in the horse. In the literatures the investigators found that the frequency of them range from 0%- 28.8% (table 2)

<b>Table (2): Frequency of isolated shadows in the fetlock joint</b>			
3.5%	-At the dorsal proximal end of P1.	Nilsson and Olsson 1973	3 horses (one foreleg and two hindlegs) from 86 Standardbreds
3.5%	-Between the distal part of the sesamoid bone and and the posterior part of p1.		3 horses (3 hindlegs) from 86 Standardbreds
3.5%	-Apical fracture at the proximal third of the sesamoid bone.		3 horses (2 forelegs and one hind-leg) from 86 Standardbreds
0%		O'Brien 1977	43 fetlock joints from Thoroughbreds
16%	Dorsal aspect of fetlock joint	Böhm and Nagel 1980	-76 Warmblooded foals (4 weeks-2 year-old) were examined.
22%			-166 Warmblooded horses (2-3.5 year-old) were examined.
10.5%	Dorsal aspect of fetlock joint	Fessl and Girtler 1983	76 from 721 horses with lameness and average 7 years-old (62 unilateral fore- legs; 12 bilateral fore- legs and 3 hindlegs).
6.5%	Dorsal aspect of fetlock joint	Harfst 1986	-11 from 168 horses (forelegs).
13.9%			-10 from 72 horses (hindlegs).
1.2%	Palmar/plantar proximal end of P1		-2 from 186 horses (forelegs)
8.3%			-6 from 72 horses (hindlegs)
1.8%	The area of the distal sesamoidean ligaments		-3 from 168 horses (fore legs)

## *Review of Literature*

**Table (2) (contd.)**

28.8%	Plantar proximal end of P1		-40 from 139 Standardbreds
2.9%	Dorsal aspect of metacarpophalangeal joint	Sandgren 1988	-3 from 103 horses.
2.2%	Dorsal aspect of metatarsophalangeal joint		-3 from 139 horses.
4.8%	Dorsal proximal end of P1	Gröndahl 1992	-36 from 753 yearling Standardbred Trotters (35 forelimbs, 14 hindlimbs; 90 fragment were medial to the extensor tendon and 28 were found laterally).
15.7%	Dorsal aspect of the sagittal ridge of the third metacarpus/metatarsus		-118 from 753 horses (61 fore limb and 147 hindlimbs).
11.8%	Palmar/plantar aspect of fetlock joint		-89 from 753 horses(7 fore limbs, 86 hindlimbs and 11 were bilateral)
7.4%	Dorsal aspect of metacarpophalangeal joint	Stöckli and Ueltschi 1992	-25 from 339 Warmblood horses with different breeds.
0.6%	Plantar aspect of metacarpophalangeal joint		-2 from the previous 339 horses.
4.4%	Dorsal aspect of fetlock joint	Sandgren, et al. 1993	-53 from 793 Standardbred Trotters.
22.4%	Palmar/plantar eminence of P1		-178 from the previous 793 horses.
4.2%	Medial or lateral wing of P1(ununited palmar/plantar eminence)		-33 from the previous 793 horses.
15.9%	Dorsal aspect of fetlock	Hertsch, et al. 1997	24 from 115 Holstein foals yearling till 2 years-old

Churchill (1956) described the first arthrotomy technique for extirpation of the proximal fragments of the proximal sesamoid bone fractures in 23 horses. Of them, 11 resumed racing; 6 of the 11 were completely sound.

Raker (1975) recommended conservative treatment for many chip fractures of the fetlock joint, because of the occurrence of the calcification within the joint capsule over the dorsal aspect of the equine fetlock joint after arthrotomy. Satisfactory repair and athletic activity can be resulted if the joint is kept at rest for 3 to 6 months.

Johnston (1975) described the arthrotomy technique in the standing position for removal of the osteochondral fracture from the anterior medial aspect of the proximal end of the first phalanx in a 6-year-old Thoroughbred gelding. He concluded that in selected cases, equine joint surgery can be successfully performed with the patient in the standing position.

## *Review of Literature*

---

In contrast Elce and Richardson (2002) reported a new successful technique for arthroscopic removal of P1 chip fractures using local anaesthesia in 104 standing horses. No major operative or postoperative complications occurred. 91% of race horses raced after surgery with 78% returning to race at the same or higher level.

Ferraro (1978) mentioned that, surgical removal of antero-medial and antero-lateral chips in the fetlock joint was unnecessary and, in fact, detrimental to racing performance in 90% of these cases. Conservative therapy consisting of rest for three to four months will yield much better results. Most fetlocks, following surgery, have a lessened degree of flexion and were distended by scar tissue at the surgical site. Chip fractures of the postero-medial or postero-lateral aspect of the first phalanx merit a poor prognosis, regardless of therapy. Surgical access to the area was limited and surgical correction was difficult. Conservative therapy did not always result in a good bony union of the apical fractures of the sesamoid bone. Surgical removal often increased the chance of recovery, but careful evaluation of the suspensory ligament damage was necessary.

Jann, et al. (1986) described the use of electrosurgery for fetlock arthrotomy in 12 horses. In six of them, osteochondral fragments from the dorsoproximal aspects of the P1 were successfully removed.

Yovich and McIlwraith (1986) reported the results of arthroscopic surgery for the treatment of the proximodorsal osteochondral fractures of the first phalanx (P1) in 74 fetlock joints of 63 horses (35 Thoroughbreds and 28 Quarter Horses) during a 2-year period. The medial dorsal proximal aspect of the P1 of the forelimbs was most commonly involved (59 fractures), followed by the lateral aspect (26 fractures), and 2 fractures occurred in the fetlock joint of the right hindlimb. At surgery, 82 fragments were removed and 5 fragments that had healed or were embedded in the joint capsule were not removed. Of the fragments removed, 15 were fixed firmly to the proximal phalanx, 63 were easily movable by arthroscopic instruments, and 4 were floating free within the joint. 38 of 46 horses (82.6%) with adequate postoperative follow-up returned to athletic performance at least equal to that before fetlock injury.

In a more recent and extensive study Kawcak and McIlwraith (1994) evaluated the results of arthroscopic surgery in the treatment of osteochondral fragmentation of the proximodorsal

## *Review of Literature*

---

aspect of the P1 in 320 horses. Some 311 of the horses were race horses. The 25 other horses included 12 used for show, 5 jumping, 2 dressage, 1 rodeo, 1 pleasure and 4 others whose uses were unrecorded. Surgery was performed on a single metacarpophalangeal in 220 horses, both metacarpophalangeal joints in 97 horses, a single metatarsophalangeal joints in 17 horses, both metatarsophalangeal joints in one horse, and all 4 joint in one horse. The proximomedial aspect of the P1 was the most common site of fragmentation with 498 of 572 fragments. Fragmentation of the proximodorsal P1 was the only lesion in the fetlock of 159 horses. Some 177 horses had fragmentation and additional fetlock lesions. Follow up was available for 286 horses (85.1%). Two hundred and eight (73.0%) returned to the previous use. Of these, 153 horses (73.6%) returned to the same level of performance and 55 (26.4%) returned to performance but at lower class. Eighteen horses (6.3%) developed another fragment, and 60 (21.0%) horses did not return to their previous use.

Colon, et al. (2000) reported the incidence and location of dorsoproximal P1 osteochondral chip fragments in 461 thoroughbred race horses. 659 dorsoproximal P1 chip fractures were removed arthroscopically from 574 joints. 89% of the horses (411/461) raced after surgery and 82% (377/461) did so at the same or higher class.

Barclay, et al. (1987) Diagnosed osteochondral fragmentation of the plantar aspect of the proximal phalanx as a cause of hindlimb lameness in 19 horses, 10 horses were treated with surgical removal by arthrotomy and all returned to full use, whereas of 7 treated intra-articularly with polysulphated glycosaminoglycans or corticosteroids, only one was able to return to full use. Two horses were not treated.

In another study Bukowiecki, et al (1985) described fifteen fractures of the palmar or plantar process of the proximal phalanx in 15 horses. Ten were articular and five were non articular. Two modes of therapy were used depending on the location of the fracture. Nonarticular fractures were treated with stall rest or reduction in exercise, and articular fractures were treated with either surgical removal or internal fixation of the fragment with arthrotomy. All horses that were operated on were sound within 6 months after surgery, and 14 returned to an equal or better level of performance.

Houttu (1991) presented the results of arthroscopic surgery for removal of osteochondral fragments of the palmar/plantar aspect of the the metacapo/metatarsophalangeal joints in 42



## *Review of Literature*

---

Standardbred trotters and 3 Finish horses. 44 horses had type I fragments and 1 horse had type III fragments were operated. Of the 45 horses operated on, 23 (51 %) returned to speed training in three months and 41 (91 %) returned to speed training in six months. 3 of 45 (6 %) were lame three months after the surgery when the trainer attempted to start speed training. One of those was sound. The remaining two (4%) stayed lame due to a lesion in the affected joint. Two of 45 (4%) discontinued training for other reasons. The horse with type III fragments returned to speed training in three months.

Foerner (1992) mentioned that, arthroscopic surgery is the treatment of choice for removal of type I and type III (that are less than half of the width or depth of the base of the proximal sesamoid bone) osteochondral fragments of the plantar aspect of the fetlock joint, while arthrotomy is required for removal of type II fragments.

Whitton and Kannegieter (1994) mentioned that, palmar/plantar osteochondral fragmentation of the proximal aspect of the first phalanx is a common cause of low -grade lameness in racing horses, and arthroscopic removal results in improvement in race performance.

The above authors reported the clinical presentation and outcome of the treatment of 26 cases of osteochondral fragmentation of the palmar/plantar proximal aspect of the P1. Twenty-three were racing Standardbreds and three were racing Thoroughbreds. The most common reason for presentation was an inability to run straight at high speed. Only eight horses presented for lameness, although on examination 19 were lame. A positive flexion test was recorded in 90% of affected fetlock joints and effusion in 48%. Arthroscopic fragment removal was performed on 23 occasions in 21 horses and arthrotomy in one horse. Of the 16 horses that had returned to racing, 12 had improved their performance, while three showed no improvement. One was retired for other reasons. In three horses refragmentation occurred after surgery, two of which had improved after initial arthroscopic removal. Degenerative changes within the fetlock joint were detected in eight horses. Of the four horses treated conservatively, one returned to its previous level of performance temporarily after intra-articular medication, one showed no improvement and two were still resting.

Fortier, et al. (1995) characterized the clinical findings and location of axial osteochondral fragments of the palmar/plantar proximal aspect of P1 in 119 horses that had undergone arthroscopic surgery for removal of these fragments. Standardbred race horses represented

## *Review of Literature*

---

109 (92%) of those affected. Ninety three (78%) of the horses were less than 3 years old. Fragments most commonly were observed in the hindlimbs (95%), specifically on the medial aspect of the left hindlimb (44%). Bilateral fragmentation occurred in 21 of 119 (18%) horses, and 15 of 119 (13%) horses had fragments in the medial and lateral aspect within the same joint. In 55 of 87 (63%) race horses and in 100% of the 9 non race horses, performance returned to preoperative level after surgery.

Superlock and Gabel (1983) diagnosed 109 cases with apical sesamoid fractures involving less than one-third the estimated mass of the sesamoid bone. 80 (73%) horse were treated with surgical removal of the fracture fragment via arthrotomy and 40 (50%) of these horses raced at least once after surgery. 29 horses treated nonsurgically, 10 (37%) had reduced postsurgery racing performance.

Zöttl, et al. (1995) reviewed the surgical arthroscopy of 20 proximal sesamoid fractures and 29 distal palmar/plantar fragments in the fetlock joint. Concerning the age distribution sesamoid fractures and distal fragments showed a predominance of young horses. Proximal sesamoid fractures occurred most frequently in the lateral sesamoid of the hindlimb, distal fragments in the medial side of the hindlimb. 12 of 17 horses with proximal sesamoid fractures and 19 of 24 horses with distal fragments returned to full work.

In a study dealing with 43 Standardbred race horses in which apical fractures of the proximal sesamoid bone (PSB) were removed by means of arthrotomy in 81 % (35/43) of cases and by arthroscopic technique in 19% (8/43) of cases. Woodie, et al. (1999) observed that, the median surgical time for arthrotomy was 49 minutes (range, 20 to 90 minutes), whereas median surgical for arthroscopy was 40 minutes (range, 30 to 85 minutes). Method of removal did not affect postinjury racing performance or outcome.

Bertone (2002) mentioned that, surgical removal of apical sesamoid fractures can be performed by arthroscopy or arthrotomy through the palmar/plantar recess of the fetlock joint. Arthroscopy offered the advantages of rapid return to performance for small articular fractures without suspensory involvement and ability to remove more than one fracture from the joint with minimal incisional morbidity. Whereas surgical removal of basilar fractures was difficult to remove with arthroscope because of the extent of ligamentous structures attached to the bone. If the fragment cannot be completely removed by arthroscopy owing to

haemorrhage or migration of the fragment, the arthroscopic instrument portal can be enlarged to allow direct removal by arthroscopy.

Saldern, et al. (2003) removed 470 osseous and osteochondral fragments in the region of the metacarpo/metatarsophalangeal joints from 381 horses. Four hundred and nineteen fragments were located intra-articularly of which 410 (98%) were removed arthroscopically and 9 (2%) by arthrotomy. The location of 418 osteochondral fragments in the joint was: Dorsoproximal P1 207 cases (49.5%); Proximopalmar/plantar P1 76 cases (18%); Apex of the proximal sesamoid bone 58 cases (14%); Dorsal synovial pad 45 cases (11%); Loose fragments in the dorsal pouch 19 cases (4.5%); Proximal dorsal sagittal ridge 8 cases (2%); Loose fragments proximal aspect of the palmar/plantar pouch of 5 cases (1%). 51 peri-articular osseous fragments were removed under fluoroscopic control using C-arch technique. These were located in the distal sesamoiden ligaments (18 cases), were avulsion fractures of the proximal palmar/plantar margin of P1 (9 cases), were on the lateral/medial aspect of dorsoproximal P1 (8cases), were avulsion fractures of the sesamoid bone (7 cases) or were found in other locations (e.g. the digital flexor tendon sheath, distal aspect of the suspensory ligaments, or the metacarpophalangeal collateral ligaments).

### **2.3. 2. Intra-articular Fractures**

#### **2.3.2.1. Noncomminuted fractures of the proximal phalanx**

##### **2.3.2.1.1. Sagittal fractures of the proximal phalanx**

Markel and Richardson (1985) and Markel (1990) classified sagittal fractures of P1 into incomplete (short or long) or complete fractures. Short incomplete fractures were less than 30 mm long and arose from the proximal phalanx at or just lateral to the sagittal groove of the P1. Long incomplete fractures were longer than 30 mm and arose from the proximal articular surface of the proximal phalanx or just lateral to the sagittal groove of the P1. Complete fractures began at the proximal articular surface of P1, at or just medial or lateral to the intermediate groove, and entered the PIP joint separating the P1 into two approximately equal halves.

Fackelman and Nunmaker (1982); Markel and Richardson (1985); Ellis, et al. (1987) and Holcombe, et al. (1995) mentioned that, horses with short incomplete sagittal fractures of P1 were typically treated with stall rest and support bandages on the affected limb for 6-10

weeks. They were gradually returned to normal exercise over the next 6 weeks. These fractures typically healed with a large periosteal response over the dorsal aspect of the fracture site, but the prognosis was good for return to athletic cadavers. Lag screw fixation may shorten the convalescence period and reduce the formation of periosteal new bone. Acute long incomplete fractures were treated by lag screw fixation through stab incisions. Fractures diagnosed 4 to 6 weeks after the onset of lameness were generally treated with stall confinement and support bandage. The prognosis was good for return to racing following either surgical or non surgical management. Treatment of complete fractures have included lag screw fixation, stall rest and support bandages, and external coaptation. The prognosis for return to athletic endeavours was poor when the condition was treated nonsurgically. Horses whose sagittal fractures were treated nonsurgically took about 4 months to become free from pain and lameness. With lag screw fixation, healing time was reduced by approximately 2 months, and less callus formation and DJD result. Less than 50% of horses sustaining complete mid sagittal fractures returned to racing, and of those horses more than 50% returned to a lower level of performance.

#### **2.3.2.1.2. Distal Articular Fractures of P1**

These fractures occur variably within the P1 and enter the distal articulation (PIP joint) only (Markel and Richardson 1985; Ellis, et al. 1987; Markel 1990).

Fractures of P1 into the PIP joint have been reported to occur only in hindlimbs. This type of fractures may be more common in foals (Markel and Richardson 1985).

The fracture courses from the PIP joint to either the medial or lateral cortex of the P1. Reduction and stabilisation are best accomplished with lag screw fixation. The prognosis for return to athletic service ability is good following lag screw fixation of acute fractures. Chronic fractures can be treated by lag screw fixation and arthrodesis of the PIP joint. Arthrodesis avoids lameness caused by secondary DJD of PIP joint (Honnas 1992)

#### **2.3.2.1.3. Dorsal Frontal fractures of P1**

Dorsal frontal fractures of the P1 enter the metcarpo or metatarsophalangeal joint in the frontal plane and course toward the dorsal cortex of the P1. They are generally incomplete but

can be complete, with or without displacement. Complete fractures extend from the proximal dorsal articular surface of the MCP joint to the dorsal cortical surface of the P1 (Markel and Richardson 1985; Markel 1990).

Markel and Richardson (1985) described dorsal frontal fractures of P1 in nine horses. All fractures were in hindlimbs, and two horses were affected bilaterally. Of the eleven fractures, seven were incomplete, and none displaced, and three were complete and displaced. Two horses with complete displaced fractures had their fractures repaired with lag screw fixation combined with open reduction, and the other seven horses were treated nonsurgically. Open reduction was used, as unsatisfactory articular reduction of the fracture was noted on image intensification.

In addition they stated that, complete, displaced dorsal frontal fractures should be stabilized with lag screws to reduce the articular defect and to help to prevent secondary joint changes. Complete, nondisplaced fractures and incomplete fractures should be treated with stall rest and support bandages. Bony healing of the fracture usually occurs within 4 to 6 months following surgical treatment, fracture healing and return to training can be suspected 1 to 3 months earlier than with nonsurgical treatment.

#### **2.3.2.2. Metacarpal or Metatarsal Condylar Fracture**

Condylar fractures of the third metacarpal bone (MC III) or the third metatarsal bone (MT III) occur most frequently in the racing horse, most commonly in the young racing Thoroughbred, less frequently in Standardbred, and occasionally in Quarter Horses and Polo Ponies. Such fractures most often involve the lateral condyle of MC-3 in young Thoroughbreds, but can also involve the medial condyle of MC-3 and either condyle of MT-3 (Heinze 1972; Rooney 1974; Turner 1977; Baker 1979; Haynes 1980; Rick, et al. 1983; Richardson 1984; Barclay, et al. 1985; Ferraro 1990; Bathe 1994; Ellis 1994; Johnson, et al. 1994).

The treatment of choice for horses with condylar fracture of MC-3 and MT-3, particularly horses that must return to athletic competition, is surgical repair using orthopaedic screw placed in lag fashion. External coaptation and stall confinement may also be successful in selected horses with incomplete or nondisplaced fracture (Meagher 1976; Rick, et al. 1983;

Richardson 1984; Barclay, et al. 1985; Ferraro 1990; Richardson 1990; Honnas 1992; Ellis 1994).

Richardson, et al. (1984) detailed fifteen longitudinal fractures involving the medial condyle of the third metatarsal bone in racing Thoroughbreds and Standardbreds. Twelve were repaired surgically with lag screws placed through stab incisions. The correct placement of screws was ensured by the use of plain radiography or fluoroscopy during the surgery.

Bowman, et al. (1987) stated that, the approach to the MC III or MC III condylar fractures was determined by the extent of the damage to the diaphysis. In the short fracture, simple lag screw for joint reconstruction may be sufficient; however, in some instances bone plating to prevent severe comminution may be necessary.

Bassage and Richardson (1998) reported 233 condylar fractures of the third metacarpal bone (MC-3) and third metatarsal bone (MT-3) in 224 horses. They found that horses with condylar fractures of MC-3 and MT-3 that had minimal pathologic changes in the involved joint had favourable prognosis for returning to races after surgical treatment.

Zekas, et al. (1999) reported a series of 145 condylar fractures in mostly Thoroughbreds. They found that the males were over presented (95%) and the distribution of fracture was approximately one third incomplete nondisplaced, one third complete nondisplaced, and one third complete –displaced. The right front was more likely to sustain a complete –displaced fracture, whereas the left front was more likely to sustain an incomplete- nondisplaced fracture. Forelimbs (81%) and lateral condyles (85%) were more likely to be involved.

### **2.3.3. Subchondral Bone Cysts (Osseous Cyst-like Lesions)**

#### **2.3.3.1. Definition and Historical Perspective**

Trotter and McIlwraith (1981); McIlwraith (1987); Bramlage (1993); and Butler, et al. (1993) mentioned that, subchondral cystic lesions are commonly recognized pathologic entities of bones and joints in horses. They are usually solitary, circular, lucent area in a bone, which may be surrounded by a narrow rim of sclerosis. They are usually unicameral but may be multicameral. They are often close to the articular surface of the bone and sometimes a neck

connecting the cyst –like lesion with the joint surface can be identified. They may or may not cause lameness. They may be articular or nonarticular. The most common age for diagnosis, or at least the time when clinical signs developed, is usually 3 years or less.

Periarticular subchondral bone cysts were first reported as a clinical entity in the horse in 1968 (Petterson and Sevelius 1968).

In that report, there were 12 cases of periarticular subchondral bone cysts in the phalanges and 1 case in the radial carpal bone. One more case in the phalanges was added to the series the following year (Petterson and Rieland 1968&1969).

Reid (1970) reported another series of 69 cases in 64 horses under a modified name, osseous cyst like lesions. In that series, there were 15 instances of cysts in the carpal bone, 10 instances in the third metacarpus, 3 in the radius, 5 in the proximal sesamoids, 6 in the first phalanx, 4 in the second phalanx, 5 in the third phalanx, 6 in the navicular disease, 12 in the femur, 2 in the tibia and 3 in the tarsal bone.

Trotter and McIlwraith (1981) reported a series of 36 cases, the sites of occurrence of subchondral lesions included the medial condyle of the distal femur (22), the lateral condyle of the femur (3), the proximal tibial condyle (2), the carpus (9), the fetlock (5) and the pastern (4).

Ramos (1987) presented the result of looking at x-rays of 4464 horses with limb diseases. 147 (3%) had cyst like lesions. They were most often seen in the navicular bone (28), followed by 25 in the coffin bone, 18 in the tibia, 11 in the middle phalanx, 16 in the first phalanx, 16 in the talus, 7 in the femur, 6 in the third metacarpus, 6 in the proximal sesamoids, 5 in the humerus, 4 in the scapula, 3 in the third metatarsus, 1 in the radius and 1 in the patella.

### **2.3.3.2. Terminology**

Subchondral bone cysts and in particular, their pathogenesis and treatment, still incite considerable controversy. Most authors have not been able to agree even on terminology (McIlwraith 1998).

## *Review of Literature*

---

Although the lesions were initially described as periarticular subchondral bone cysts (Pettersn and Sevelius 1968; Petterson and Rieland 1968 &1969; McIlwraith 1982), another authors described them as:

- Bone Cyst (Butler, et al. 1993)
- Cystic-like Bone Defect (Hertsch, et al. 1981; Ramos 1987; Baez 1989).
- Osteochondritis Dissecans (O'Brien 1973; Hornof, et al. 1981).
- Non marginal Osteochondrosis (Rooney 1975).
- Osseous Cyst-like Lesions (Reid 1970; Butler 1993).

### **2.3.3.3. Sites of Occurrence within the Phalangeal Joints**

Hogen, et al. (1977) mentioned that, fetlock subchondral bone cysts occur most commonly on the weight bearing surface of the metacarpal condyle and less commonly on the weight – bearing surface of the first phalanx. Cysts of the distal metacarpus that open into the fetlock joint occur in young horses and are considered a part of the developmental osteochondrosis syndrome.

Subchondral cystic lesions occur in specific locations within the phalangeal joints (table 3), and controversy existed as to whether these lesions were a manifestation of osteochondrosis, secondary to intra-articular trauma, or a combination of both (Trotter and McIlwraith 1981; Trotter, et al. 1982; McIlwraith1987&1990b; Nixon 1990; Wagner and Watrous 1990; Hoppen, et al. 1992; Bramlage 1993)

<b>Table (3): Sites of occurrence of subchondral cystic lesions within the phalangeal joints</b>	
<b>Joint</b>	<b>Specific location</b>
Coffin	-Third phalanax -Navicular bone
Pastern	-Distal first phalanx -Proximal second phalanx
Fetlock	-Distal metacarpus or metatarsus -Proximal first phalanx -Sesamoids



#### **2.3.3.4. Treatment**

Trotter, et al. (1982); Stewart and Reid (1982) Rose, et al. (1985); McIlwraith (1987&1990b) and Howard, et al. (1995) stated that, there are two basic approaches to treat most subchondral cystic lesions: (1) Conservative treatment (with or without intra-articular medication with hyaluronan and polysulphated glycosaminoglycans or anti-inflammatory drugs) and (2) Surgical débridement. The only exception to this generalization would be for subchondral cystic lesions of proximal interphalangeal joint, which usually are associated with severe secondary degenerative joint disease (DJD) and may require arthrodesis of the affected joint to achieve soundness.

Petterson and Sevelius (1968) found cysts in the distal extremities to heal occasionally by osseous resolution, although this was not generally believed to be essential for satisfactory clinical improvement following conservative management. Less than 50% of their case material (6/13) became sound after conservative management.

McIlwraith (1982) also found the prognosis to be poor with conservative management due to the risk of DJD.

As an alternative to conservative management of subchondral bone cysts, Evans and Jenny (1970); Kold and Hickman (1983&1984); McIlwraith (1982&1986); White, et al. (1988) and Kold (1990) have all described surgical technique involving intra-articular curettage via arthroscopy or arthrotomy, or curettage via an extra-articular contra-opening.

In some reports, the above mentioned surgical treatment has been complemented by installation of an autogenous cancellous bone graft (Evans and Jenny 1970; Kold and Hickman 1983; Kold 1990) or acrylic bone cement (Hickman, et al. 1984).

McIlwraith (1990b); Hopen, et al. (1992) and Baxter (1996) suggested that horses with subchondral cystic lesions not respond to conservative treatment within 3 or 4 months, or that worsened should probably be treated surgically.

Stanek and Edinger (1990) performed a surgical treatment of a subchondral bone cyst of the third phalanx in a standardbred gelding. Under fluoroscopic control the cyst was drilled and

## *Review of Literature*

---

implanted with autogenous bone graft collected from the tuber coxae. The treatment was successful, the horse returned to race track after six months.

Hogan, et al (1997) detailed the surgical treatment of subchondral cystic lesions in the condyle of the third metacarpal bone in 15 horses. The median age at presentation was 18 months with 10 of 15 horses less than age 2 years. The lesions were confined to the front limbs in all cases with 2 horses having bilateral lesions. Lesions were isolated to the medial condyle of MCIII in 13 of 15 horses; a cystic lesion occurred in the lateral condyle in one horse and in the sagittal ridge in one horse. Fourteen of the 15 horses had a history of lameness attributable to the fetlock joint; the lesion was an incidental finding in one horse. Cystic lesions were curetted arthroscopically in 12 horses, and through a dorsal pouch arthrotomy in 3 horses. Concurrent osteostixis of the cystic cavity was performed in 7 horses. Twelve of 15 horses (80%) were sound for intended use following surgical treatment. Two horses did not regain soundness and Follow-up information was unavailable for one horse.

Dowling, et al. (1998) described 2 cases of subchondral cystic lesions involving the distal aspect of the palmar/plantar aspect of the 2<sup>nd</sup> phalanx. They suggested that, an extra-articular approach to the cyst may have been possible using fluoroscopic guidance, as the palmar/plantar position of the cysts would have made surgical exposure difficult.

Kold and Killingbeck (1998) reported the satisfactory outcome of 3 surgical cases involving a subchondral bone cyst in communication with proximal and distal interphalangeal joints respectively. All cases treated by using a bone grafting technique via extra-articular approach.

Hertsch, et al. (2000) described a fluoroscopic guided minimal invasive surgical method for treatment of subchondral bone cysts involving extra-articular drilling of the cyst and installation of an autogenous cancellous bone graft from the tuber coxae via a modified Jamshidi-needle.