

Original Article

A non-inferiority comparative analysis of micro-ultrasonography and MRI-targeted biopsy in men at risk of prostate cancer

Sebastian L. Hofbauer¹ , Ferdinand Luger², Niklas Harland³, Henning Plage¹, Maximilian Reimann¹, Markus Hollenbach¹, Andreas Gusenleitner², Arnulf Stenzl³ , Thorsten Schlomm¹, Laura Wiemer^{1,*}  and Hannes Cash^{1,4,5,*} 

¹Department of Urology, Charité – Universitätsmedizin Berlin, Berlin, Germany, ²Department of Urology, Ordensklinikum Linz, Elisabethinen, Austria, ³Department of Urology, Eberhard-Karls-University, Tübingen, ⁴Prouro, Urology Berlin, Berlin, and ⁵Department of Urology, University of Magdeburg, Magdeburg, Germany

*These authors contributed equally.

Objective

To compare the efficacy of multiparametric magnetic resonance imaging (mpMRI)-directed and micro-ultrasonography (micro-US)-directed biopsy for detecting clinically significant (Grade Group >1) prostate cancer (csPCa).

Materials and Methods

A total of 203 patients were prospectively enrolled at three institutions across Germany and Austria in the period from January 2019 to December 2019. During each biopsy, the urologist was blinded to the mpMRI report until after the micro-US targets had been assessed. After unblinding, targets were then sampled using software-assisted fusion, followed by systematic samples. The primary outcome measure was non-inferiority of micro-US to detect csPCa, with a detection ratio of at least 80% that of mpMRI.

Results

A total of 79 csPCa cases were detected overall (39%). Micro-US-targeted biopsy detected 58/79 cases (73%), while mpMRI-targeted biopsy detected 60/79 (76%) and non-targeted (completion sampling) samples detected 45/79 cases (57%). mpMRI-targeted samples alone detected 7/79 (9%) csPCa cases which were missed by micro-US-targeted and non-targeted samples. Three of these seven were anterior lesions with 2/7 in the transition zone. Micro-US-targeted samples alone detected 5/79 (6%) and completion sampling alone detected 4/79 cases (5%). Micro-US was non-inferior to mpMRI and detected 97% of the csPCa cases detected by mpMRI-targeted biopsy (95% CI 80–116%; $P = 0.023$).

Conclusions

This is the first multicentre prospective study comparing micro-US-targeted biopsy with mpMRI-targeted biopsy. The study provides further evidence that micro-US can reliably detect cancer lesions and suggests that micro-US biopsy might be as effective as mpMRI for detection of csPCa. This result has significant implications for increasing accessibility, reducing costs and expediting diagnosis.

Keywords

prostate cancer, prostate biopsy, targeted biopsy, micro-ultrasonography, multiparametric magnetic resonance imaging, #uroonc, #PCSM, #ProstateCancer

Introduction

Until recently, prostate cancer (PCa) was diagnosed by systematic TRUS-guided biopsy. This method is limited because it frequently detects clinically insignificant PCa

while missing up to 30% of clinically significant (cs)PCa [1]. Multiparametric MRI (mpMRI)-targeted biopsy has produced a major paradigm shift in the way PCa biopsy is performed. Data from several large multicentre studies have provided compelling evidence that addition of mpMRI-

targeted biopsy provides a significantly higher detection rate over systematic biopsy alone [1–3]. Similarly, well-run randomized and non-randomized trials have demonstrated considerable risk stratification can be used to provide better justification for biopsy [4,5]. This has led to changes by all major guidelines groups to recommend the use of mpMRI prior to prostate biopsy. However, mpMRI is limited by availability, cost and urologist expertise [6]. Moreover, interpretation of mpMRI is subject to considerable variability [7].

Micro-ultrasonography (micro-US) is a novel imaging technique that provides a 300% improvement in resolution over conventional ultrasonography [8]. Micro-US-targeted biopsy is performed using the Prostate Risk Identification for Micro-Ultrasonography (PRI-MUS™) protocol, which was developed to provide a standardized risk stratification protocol in micro-US analogous to the Prostate Imaging Reporting and Data System (PI-RADS®) protocol for mpMRI [9]. It has been previously demonstrated that micro-US visualizes csPCa which is regularly in accordance with mpMRI results [10–12].

The present study provides prospective multicentre data for the first time comparing the efficacy of mpMRI- and micro-US-targeted biopsy in the same patients.

Materials and Methods

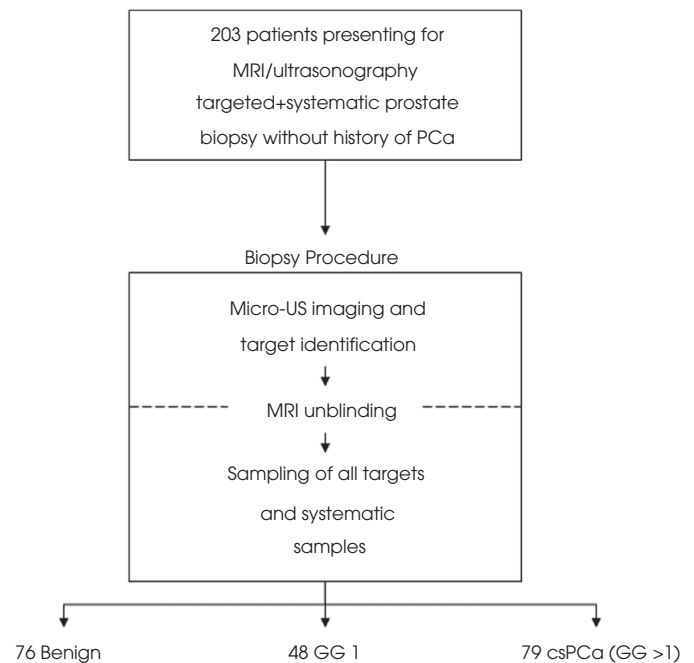
Patients

Men aged 40–75 years who were at clinical risk of PCa were enrolled at three institutions (Charité, Universitätsmedizin Berlin, Berlin, Germany; Eberhard-Karls-University, Tübingen, Germany; Ordensklinikum Linz, Elisabethinen, Austria) over the period from January to December 2019. Clinical risk of PCa in patients with a negative mpMRI was based on PSA value and/or suspicious DRE. All men had undergone mpMRI prior to study inclusion but were excluded if: PSA level was > 20 ng/mL; known prostate volume was > 100 mL; they had a history of cancer; or they were unfit for transrectal biopsy. The study was approved by the independent ethics committees of each institution. A patient flowchart is shown in Fig. 1.

Multiparametric MRI and Multiparametric MRI-targeted Biopsy

Multiparametric MRI was performed with a 3.0-Tesla scanner with a pelvic phased-array surface coil without an endorectal coil. T2-weighted-, diffusion-weighted- and dynamic contrast-enhanced sequences were acquired according to a PI-RADS-compliant protocol. All patients who underwent mpMRI were analysed with PI-RADS v2 or PI-RADS v2.1 [13].

Fig. 1 Study scheme.



The mpMRI-targeted biopsies were performed transrectally using the Exact Imaging™ FusionVu™ feature on the ExactVu™ system. The mpMRI targets were marked by an independent examiner the day before biopsy. The physician performing the biopsies was blinded to mpMRI results when performing the micro-US assessment, and targets (if any) were revealed only after entering biopsy mode in the software. Lesions that scored ≥ 3 in PRI-MUS or PI-RADS were defined as targets. A minimum of two cores were taken per target.

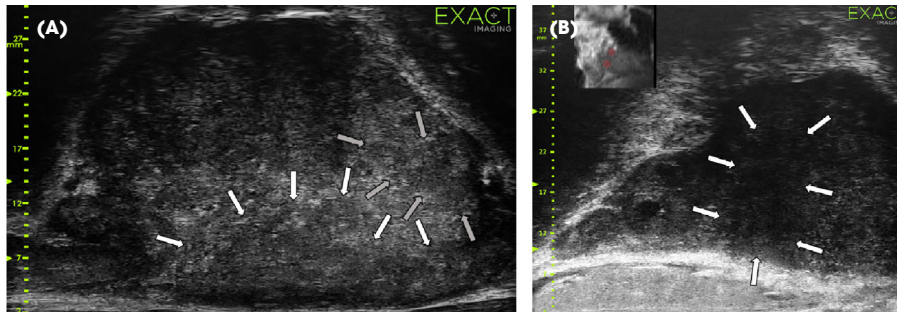
Micro-ultrasonography

The prostate was assessed and suspicious lesions documented in real-time using the PRI-MUS protocol [8] (Fig. 2) by a physician blinded to the mpMRI results and the patient's medical history. The physician was then unblinded to the mpMRI results. All identified suspicious PRI-MUS lesions were subsequently sampled as part of the 10–14-core 'systematic' biopsy using a transrectal approach. At least two cores were taken from every target. This systematic biopsy omitted samples from areas already well sampled by targeted biopsy and so will be termed 'completion sampling' in the present analysis.

Biopsy Procedure

Biopsies were performed transrectally by a total of seven urologists experienced in performing MRI-targeted biopsies and standard TRUS. All operators received a standardized training programme from Exact Imaging prior to performing

Fig. 2 Examples of suspicious lesions on micro-ultrasonography. **(A)** Study subject with extensive grade group 2 along left side. Multiparametric MRI (mpMRI) Prostate Imaging Reporting and Data System (PI-RADS) 5 and micro-ultrasonography Prostate Risk Identification for Micro-Ultrasonography (PRI-MUS) 4 targets (white and grey arrows) matched well in both apical horn and mid-base. **(B)** Study subject with small localized focus of Grade Group 2 in the left lateral base prostate. mpMRI targets are shown in the upper left white box live during procedure, however, these targets matched very well with the PRI-MUS 5 target (white arrows).



micro-US of the prostate and applying the PRI-MUS rating as previously reported [10]. A suspicious target was defined as PRI-MUS ≥ 3 . All micro-US examiners were blinded to mpMRI as part of our protocol. After documenting micro-US targets, the examiner was unblinded to the mpMRI, and targeted biopsies were taken (minimum two cores per target). In case of identical micro-US and MRI targets, no additional targeted samples were taken. Subsequently, all patients received a completion biopsy (systematic biopsy) in regions without suspicious micro-US and mpMRI lesions. MRI-targeted lesions were taken with the FusionVu device on the ExactVu system. Biopsy cores were submitted individually by prostate region. The cores were analysed by specialized uropathologists using the International Society of Urological Pathology (ISUP) Gleason system [14].

Statistical Analysis

The non-inferiority margin was based on considerations from the US Food and Drug Administration for selecting a clinical margin [15] and was defined as preserving 50% of the sensitivity improvement between TRUS systematic biopsy and MRI according to the PROMIS trial [5]. For the third definition of csPCa in PROMIS, which is equivalent to that used here, mpMRI demonstrated a sensitivity of 88% while TRUS demonstrated only 48% for a test ratio of 0.55. To preserve at least half of the benefit of mpMRI over TRUS, the lower bound of our 95% CI must be higher than $(1-0.55)/2 + 0.55 = 0.775$. For the purposes of this study, we rounded up to 0.8 indicating that, if successful, micro-US sensitivity is at least 80% as high as mpMRI sensitivity. The required sample size was calculated assuming mpMRI sensitivity of 0.76, a non-inferiority margin of 0.8 (20%), an actual ratio of 0.97, prevalence of 50%, and 80% agreement. A total of 198 participants would provide 80% power at a one-sided alpha value of 0.025, allowing for approximately 5% loss of data using the 'Non-Inferiority Tests for the Ratio of Two

Correlated Proportions' routine in the PASS 16 software. The resulting sample size was doubled to account for the 50% prevalence which is not factored directly in the software. csPCa was defined as an ISUP Grade Group of ≥ 2 (\geq Gleason 3 + 4). Group differences were evaluated using the Wilcoxon rank test. CIs and comparison *P*-values were calculated using the Jeffreys interval in MATLAB. Numbers are given as median and interquartile range (IQR).

Results

A total of 203 men were enrolled and biopsied, with no significant deviations from protocol, with 144, 48 and 11 patients in the respective institutions. The population exhibited a typical pre-biopsy risk level and had a median (IQR) age of 66 (59–70) years and median (IQR) PSA level of 6.5 (4.8–9.3) ng/mL (Table 1). A total of 15% of men had a positive DRE and 28% had at least one prior negative biopsy. Prostate volume determined by MRI was 48 (37–63) mL. The median (IQR) ultrasonography volume (37 [29–50] mL) was consistently lower than MRI volume (48 [37–63] mL).

Of the 203 patients, 127 (63%) were positive for PCa, with 79/203 (39%) showing csPCa. Micro-US-targeted biopsy detected 58/79 patients (73%) with csPCa, while mpMRI-targeted biopsy detected 60/79 (76%). Figure 3 and Table 2 show stratification of cancer detection rates and detected PCa according to different PRI-MUS and PI-RADS scores. Micro-US was non-inferior to mpMRI and detected 97% of csPCa detected by mpMRI-targeted biopsy (95% CI 80–116%; $P = 0.023$ [Fig. 4]). The total number of lesions detected by each method did not differ significantly (228 micro-US vs 246 mpMRI; $P = 0.14$). The distribution of risk scores was also similar for the two methods.

Completion samples were less effective, diagnosing only 45/79 (57%) of csPCa. However, combining targeted micro-US with non-targeted (completion sampling) micro-US-guided

Table 1 Demographics.

Demographics	
Patients, <i>n</i>	203
Any PCa, <i>n</i> (%)	127 (63)
csPCa (GG>1), <i>n</i> (%)	79 (39)
Age, years	66 (59–70)
PSA, ng/mL	6.5 (4.8–9.3)
US volume, mL	37 (29–50)
MRI volume, mL	48 (37–63)
DRE positive, <i>n</i> (%)	31 (15)
Previous biopsy, <i>n</i> (%)	56 (28)
MRI lesions, <i>n</i> ; median (range)	246; 1 (0–4)
Highest MRI PI-RADS per patient, <i>n</i> (%)	
1	1 (0.5)
2	14 (7)
3	37 (18)
4	109 (54)
5	41 (20)
Micro-US lesions, <i>n</i> ; median (range)	228; 1 (0–8)
Highest micro-US PRI-MUS per patient, <i>n</i> (%)	
1	9 (4)
2	7 (3)
3	56 (28)
4	96 (47)
5	35 (17)

GG, International Society of Urological Pathology Grade Group; IQR, interquartile range; PI-RADS, Prostate Imaging Reporting and Data System; PRI-MUS, Prostate Risk Identification for Micro-Ultrasonography; US, ultrasonography. Data are *n* (%), unless otherwise stated.

samples resulted in a larger benefit, detecting 72/79 (91%) of csPCa which was significantly greater than the targeted mpMRI detection rate (ratio 1.18, 95% CI 1.02–1.38; $P = 0.013$). When combining both targeting methods with completion sampling, there was no difference between micro-US- and mpMRI-targeted biopsy (ratio 0.99, 95% CI 0.89–1.09; $P < 0.001$ for non-inferiority). mpMRI-targeted samples alone detected 7/79 (9%) csPCa cases which were missed by micro-US targets and non-targeted samples. Two of the seven lesions were located in the transitional zone and 5/7 in the peripheral zone. Both missed lesions from the transitional zone and one from the peripheral zone were anteriorly located. Similarly, micro-US-targeted samples alone detected 5/79 (6%) csPCa cases, all located in the posterior peripheral zone, 3/5 at the apex, 1/5 at the base and 1/5 was unmarked. Completion sampling alone detected 4/79 csPCa cases (5%).

Discussion

Micro-US-targeted biopsy was non-inferior to mpMRI-targeted biopsy for detecting csPCa in a real-world biopsy population. This population and the overall detection rate of mpMRI-targeted biopsy corresponds well to other reports in the literature, both in risk factors as well as detection rate [1,3,4,16]. This confirms the high quality of the diagnostic pathway present at the participating centres.

With the expanding recommendation of mpMRI in the PCa diagnosis pathway, mpMRI has been increasingly limited by

availability, costs and radiological resources [17]. In addition, mpMRI is subject to variability due to differences in magnet strength, interpretation and patient movement [7].

Furthermore, numerous csPCa lesions are either too small, invisible or underestimated by mpMRI, leading to approximately 15% missed csPCa cases with this technique [18,19]. For some patients, mpMRI is contraindicated for various reasons including claustrophobia, pacemakers, prosthetic implants or renal impairment. Eventually with the mpMRI diagnostic pathway, patients need to undergo at least two diagnostic procedures, which generally implies two visits.

Micro-US offers a considerably higher resolution, with frequencies up to 29 MHz compared to conventional ultrasonography. Previous single-centre work on micro-US has demonstrated improved detection rates [20,21], validation of PRI-MUS risk stratification [22], sensitivity relative to mpMRI [11], and improved accuracy in sampling mpMRI targets [23]. Some csPCa was only diagnosed by one of the two methods, suggesting an added benefit of micro-US when combined with mpMRI [10,20]. A meta-analysis by Zhang et al. [24] also concluded that the technology provides significant diagnostic value. Recently, Lughezzani et al. [25] presented data from the first prospective single-centre study showing similar improvement in csPCa detection with either MRI-targeted or micro-US-targeted biopsy in combination with systematic biopsy.

The study design leveraged the unique opportunity for blinding in a sequential biopsy procedure to provide same-patient comparison data of findings between non-targeted, targeted micro-US, and targeted mpMRI. These data are critical to our understanding of which cancers are found and which are missed, as well as quantifying the added value of each technique. The present analysis shows that micro-US biopsy is non-inferior to MRI-targeted biopsy for detecting csPCa ($P = 0.023$), including both completion and targeted samples, and more effective than mpMRI-targeted only biopsy ($P = 0.013$). mpMRI-targeted biopsy added 7/203 (3%) additional csPCa lesions. Three of these seven were anterior lesions, with 2/7 in the transition zone. Micro-US interpretation of the anterior and transition zones has not yet been systematically described, as PRI-MUS was developed only based on examples of peripheral zone disease. Therefore, these missed lesions may be attributed to limitations of the current interpretation protocol which will require extension to describe the appearance of cancer outside of the peripheral zone. Prostate size can also be a factor in TRUS, which in part also applies to transrectal mpMRI-targeted biopsy. To address this issue, patients with a prostate volume of >100 cc were excluded from the study. Similarly, an inhomogeneous transitional zone with benign hyperplastic changes or prostatic calcifications with posterior acoustic shadowing limits the accuracy and increases the complexity of micro-US. Again, interpretation of the transitional zone on mpMRI is

Fig. 3 Stratification of cancer detection rates according to different Prostate Risk Identification for Micro-Ultrasonography (PRI-MUS) and Prostate Imaging Reporting and Data System (PI-RADS) scores and overall cancer detection rate including only targeted biopsies. GG, International Society of Urological Pathology Grade Group.

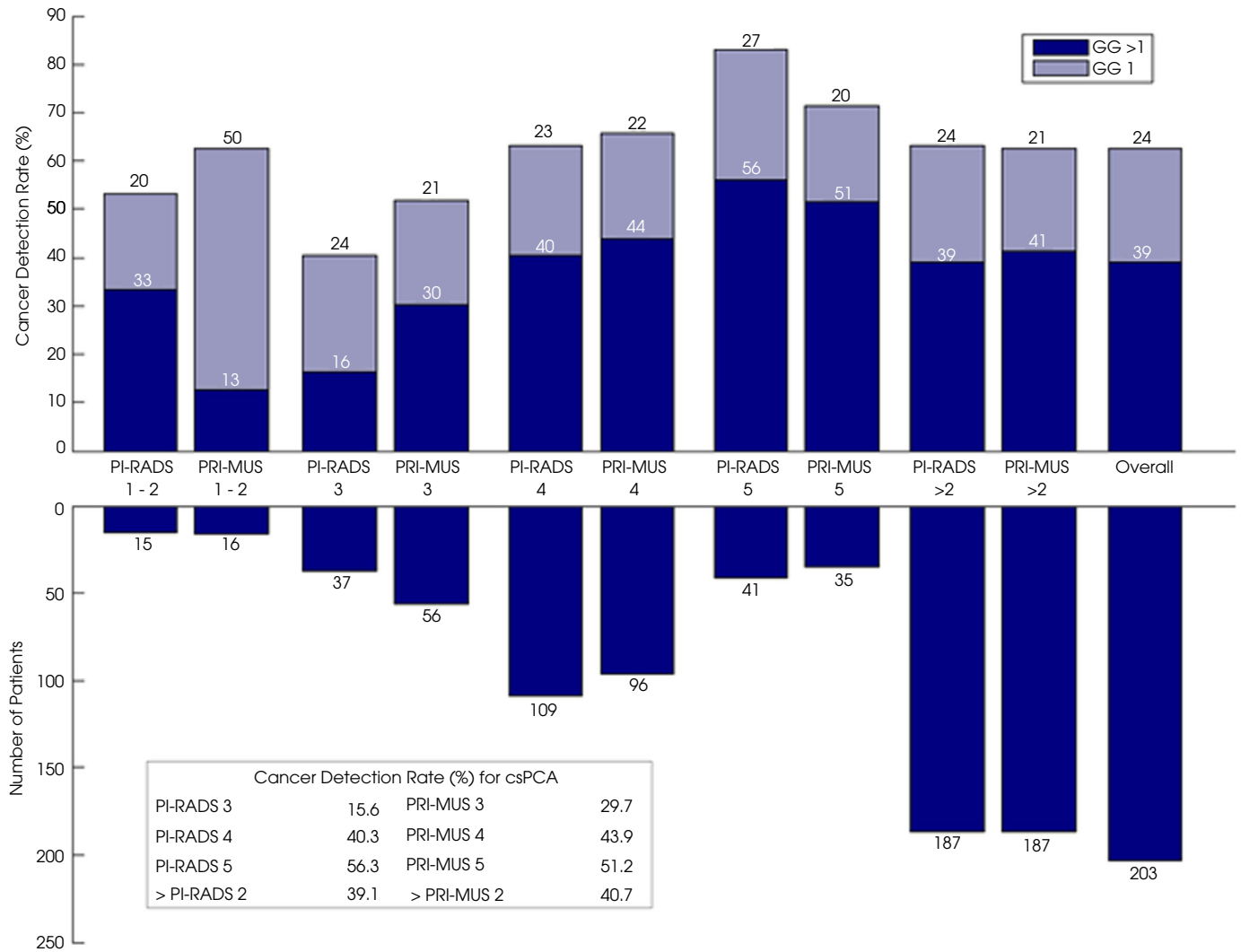


Table 2 Detected clinically significant prostate cancer (PCa) and PCa according to different Prostate Risk Identification for Micro-Ultrasonography and Prostate Imaging Reporting and Data System scores.

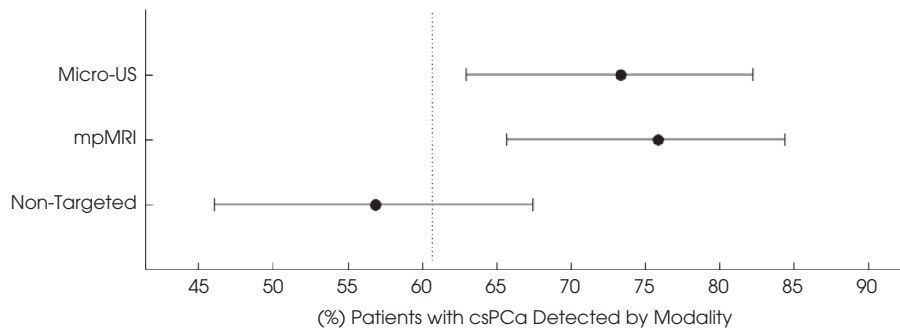
csPCa/PCa (ratio %)	PI-RADS 1 + 2 n/N (%)	PI-RADS 3	PI-RADS 4	PI-RADS 5	Total
PRI-MUS 1 + 2	0/0 (-)	0/4 (0.0)	2/9 (22.2)	0/3 (0.0)	2/16 (12.5)
PRI-MUS 3	2/6 (33.3)	3/17 (17.6)	10/28 (35.7)	2/5 (40.0)	17/56 (30.4)
PRI-MUS 4	2/7 (28.6)	3/16 (18.8)	29/60 (48.3)	7/12 (58.3)	41/95 (43.2)
PRI-MUS 5	1/2 (50.0)	0/0 (-)	3/12 (25.0)	14/21 (66.7)	18/35 (51.4)
Total	5/15 (33.3)	6/37 (16.2)	44/109 (40.4)	23/41 (56.1)	78/202 (38.6)

csPCa, clinically significant prostate cancer; PCa, prostate cancer; PI-RADS, Prostate Imaging Reporting and Data System; PRI-MUS, Prostate Risk Identification for Micro-Ultrasonography.

faced with similar problems resulting in higher false-positive rates within this region [26]. On the other hand, micro-US detected five csPCa lesions that were missed on mpMRI-

targeted biopsy. These lesions were all located in the posterior peripheral zone, 3/5 at the apex, 1/5 at the base and 1/5 lesion was unfortunately unmarked.

Fig. 4 Percentage of clinically significant prostate cancer (csPCa) cases detected by micro-ultrasonography (micro-US)-targeted, multiparametric MRI (mpMRI)-targeted, and non-targeted samples with 95% CI; 80% of the mpMRI value is shown as a dotted line representing the non-inferiority threshold. Micro-US-targeted biopsy was non-inferior to mpMRI-targeted biopsy ($P=0.023$), while non-targeted biopsy was inferior.



This study design also introduces certain limitations, including the lack of randomization. As mpMRI is recommended in biopsy-naïve patients we only compared micro-US-directed biopsy as add-on to the standard of care, while being blinded to mpMRI results, introducing a systematic bias in the search for suspicious lesions, which can only be clarified within a different trial design. The completion biopsy omitted samples from areas already sampled by targeted biopsy. As targeted biopsy error is a potential source of targeted biopsy failure, targeted tumour detection rates might be too optimistic [27]. The use of live ultrasonography vs post hoc mpMRI reporting introduces a bias because decision making during the procedure could be more pressured, potentially sacrificing accuracy. Tumour detection rates decrease with prostate size [28]. Thus, excluding these patients introduces a selection bias, possibly overestimating our results. However, prostate volume determined by mpMRI was 48 (IQR 37-63) cc, which is similar to other cohorts. Ultrasonography volume was consistently lower than MRI volume (79% of MRI value). This is in line with previous work and may be attributed to compression of the gland by the ultrasound transducer [29]. While all investigators performing micro-US imaging and biopsy were blinded to the mpMRI results, we cannot exclude the possibility that knowledge of the micro-US target locations influenced the sample locations for mpMRI. This bias may have been in the form of conscious adjustment of fusion biopsy location (as for deformation adjustment) or unconscious bias due to prostate swelling from previous samples. The fact that mpMRI positive predictive values were high suggest this effect may have been small. Although ineffective to serve as a reference in the present study design, systematic TRUS biopsy was the standard of care in the primary biopsy setting at the time of study initiation. Cancer detection rates for PI-RADS 1 and 2 lesions were relatively high. Patient recruitment in this cohort was rather difficult as these patients usually undergo outpatient systematic biopsy. With 15 and 16 patients in the mpMRI and micro-US

negative cohort, respectively, the significance of these results seems negligible. However, in case these results do resemble the true data, micro-US would have omitted less clinically insignificant and missed less csPCa. Compared to previously reported detection rates, our cancer detection rate for PI-RADS 5 lesions is rather low. Again, with no recent changes in mpMRI workflow at the participating centres and considering that the detection rates for PI-RADS 4 lesions here do match those previously reported [30], we assume this difference in detection rate for PI-RADS 5 is a result of statistical variability in this small subpopulation (41) rather than a limitation of the biopsy procedure. This is further supported by the fact that PI-RADS 4 and 5 differ only in size and therefore, if a targeting problem was present, we would expect the PI-RADS 4 rate to be lower as these should be harder to target. However, further trials within a different trial design are needed for clarification.

In conclusion, this is the first multicentre study comparing micro-US-targeted biopsy with mpMRI-targeted biopsy, suggesting that micro-US may provide a comparable benefit. There are clear implications here for reducing cost and complexity of the patient care pathway. Additional studies specific to the biopsy-naïve population are required, as well as data to compare micro-US to mpMRI as screening tests for triggering biopsy.

Conflict of Interest

The study was supported by Exact Imaging Inc., Toronto, Canada, with material support, data management and analysis. There was no additional funding. H. Cash received honoraria for lectures and is a member of the advisory board of Exact Imaging Inc. All other authors have nothing to declare.

Acknowledgment

Open access funding enabled and organized by ProjektDEAL.

References

- 1 Rouvière O, Puech P, Renard-Penna R et al. Use of prostate systematic and targeted biopsy on the basis of multiparametric MRI in biopsy-naïve patients (MRI-FIRST): a prospective, multicentre, paired diagnostic study. *Lancet Oncol* 2018; 20(4): 1–10
- 2 Elkhoury FF, Felker ER, Kwan L et al. Comparison of targeted vs systematic prostate biopsy in men who are biopsy naïve. *JAMA Surg* 2019; 154: 811
- 3 van der Leest M, Cornel E, Israël B et al. Head-to-head comparison of transrectal ultrasound-guided prostate biopsy versus multiparametric prostate resonance imaging with subsequent magnetic resonance-guided biopsy in biopsy-naïve men with elevated prostate-specific antigen: A large prospective study. *Eur Urol* 2019; 75: 570–8
- 4 Kasivisvanathan V, Rannikko AS, Borghi M et al. MRI-targeted or standard biopsy for prostate-cancer diagnosis. *N Engl J Med* 2018; 378: 1767–77
- 5 Ahmed HU, El-Shater Bosaily A, Brown LC et al. Diagnostic accuracy of multi-parametric MRI and TRUS biopsy in prostate cancer (PROMIS): a paired validating confirmatory study. *Lancet*. 2017; 6736: 1–8
- 6 Walz J. The “PROMIS” of magnetic resonance imaging cost effectiveness in prostate cancer diagnosis? *Eur Urol* 2018; 73: 31–2
- 7 Rosenkrantz AB, Ginocchio LA, Cornfeld D et al. Interobserver reproducibility of the PI-RADS version 2 lexicon: A multicenter study of six experienced prostate radiologists. *Radiology* 2016; 280: 793–804
- 8 Ghai S, Eure G, Fradet V et al. Assessing cancer risk on novel 29 MHz micro-ultrasound images of the prostate: Creation of the micro-ultrasound protocol for prostate risk identification. *J Urol* 2016; 196: 562–9
- 9 Turkbey B, Rosenkrantz AB, Haider MA et al. Prostate imaging reporting and data system version 2.1: 2019 Update of prostate imaging reporting and data system version 2. *Eur Urol* 2019; 76: 340–51
- 10 Wiemer L, Hollenbach M, Heckmann R et al. Evolution of targeted prostate biopsy by adding microultrasound to the magnetic resonance imaging pathway. *Eur Urol Focus* 2020; S2405-4569(20)30188-7
- 11 Lughezzani G, Saita A, Lazzeri M et al. Comparison of the diagnostic accuracy of micro-ultrasound and magnetic resonance imaging/ultrasound fusion targeted biopsies for the diagnosis of clinically significant prostate cancer. *Eur Urol Oncol* 2019; 2: 329–32
- 12 Harland N, Stenzl A. Microultrasound - A way to bring imaging for prostate cancer back to urology. *Prostate Int* 2021; 9: 61–5
- 13 Weinreb JC, Barentsz JO, Choyke PL et al. PI-RADS prostate imaging – Reporting and data system: 2015, version 2. *Eur Urol* 2016; 69: 16–40
- 14 Egevad L, Delahunt B, Srigley JR, Samarasinghe H. International Society of Urological Pathology (ISUP) grading of prostate cancer – An ISUP consensus on contemporary grading. *Apmis* 2016; 124: 433–5
- 15 FDA, CDER. Buckmans Non-Inferiority Clinical Trials to Establish Effectiveness Guidance for Industry. 2016
- 16 Mischinger J, Kaufmann S, Russo GI et al. Targeted vs systematic robot-assisted transperineal magnetic resonance imaging-transrectal ultrasonography fusion prostate biopsy. *BJU Int* 2018; 121: 791–8
- 17 Lughezzani G, Buffi NM, Lazzeri M. Diagnostic pathway of patients with a clinical suspicion of prostate cancer: Does one size fit all? *Eur Urol* 2018; 74: 400–1
- 18 Padhani AR, Haider MA, Villers A, Barentsz JO. Multiparametric magnetic resonance imaging for prostate cancer detection: What we see and what we miss. *Eur Urol* 2019; 75: 721–2
- 19 Otti VC, Miller C, Powell RJ, Thomas RM, McGrath JS. The diagnostic accuracy of multiparametric magnetic resonance imaging before biopsy in the detection of prostate cancer. *BJU Int*. 2019; 123: 82–90
- 20 Abouassaly R, Klein EA, El-Shefai A, Stephenson A. Impact of using 29 MHz high-resolution micro-ultrasound in real-time targeting of transrectal prostate biopsies: initial experience. *World J Urol* 2020; 38: 1201–6
- 21 Eure G, Fanney D, Lin J, Wodlinger B, Ghai S. Comparison of conventional transrectal ultrasound, magnetic resonance imaging, and micro-ultrasound for visualizing prostate cancer in an active surveillance population: A feasibility study. *Can Urol Assoc J* 2019; 13: E70–7
- 22 Luger F, Gusenleitner A, Kaar J, Mayr C, Loidl W. Does 29Mhz micro-ultrasound provide uniform diagnostic accuracy within and beyond the peripheral zone? *Ann Urol Nephrol* 2019; 1
- 23 Claros OR, Tourinho-Barbosa RR, Fregeville A et al. Comparison of initial experience with transrectal MRI cognitive guided micro-ultrasound biopsies versus established transperineal robotic ultrasound-magnetic resonance imaging fusion biopsies for prostate cancer. *J Urol* 2020; 203: 918–25
- 24 Zhang M, Wang R, Wu Y et al. Micro-ultrasound imaging for accuracy of diagnosis in clinically significant prostate cancer: A meta-analysis. *Front Oncol. Frontiers Media S.A* 2019; 9: 1368
- 25 Lughezzani G, Maffei D, Saita A et al. Diagnostic accuracy of microultrasound in patients with a suspicion of prostate cancer at magnetic resonance imaging: A single-institutional prospective study. *Eur Urol Focus* 2021; 7: 1019–26
- 26 Rosenkrantz AB, Kim S, Campbell N, Gaing B, Deng FM, Taneja SS. Transition zone prostate cancer: Revisiting the role of multiparametric MRI at 3 T. *Am J Roentgenol* 2015; 204: W266–72
- 27 Cash H, Günzel K, Maxeiner A et al. Prostate cancer detection on transrectal ultrasonography-guided random biopsy despite negative real-time magnetic resonance imaging/ultrasonography fusion-guided targeted biopsy: reasons for targeted biopsy failure. *BJU Int* 2016; 118: 35–43
- 28 Annerleim WD, Hoang HA, Baris T et al. Can magnetic resonance-ultrasound fusion biopsy improve cancer detection in enlarged prostates? *J Urol WoltersKluwer* 2013; 190: 2020–5
- 29 Christie DRH, Sharpley CF. How accurately can prostate gland imaging measure the prostate gland volume? Results of a systematic review. *Prostate Cancer* 2019; 2019: 1–12
- 30 Westphalen AC, McCulloch CE, Anaokar JM et al. Variability of the positive predictive value of PI-RADS for prostate MRI across 26 Centers: Experience of the society of abdominal radiology prostate cancer disease-focused panel. Radiological Society of North America. *Radiology* 2020; 296: 76–84

Correspondence: Sebastian L. Hofbauer, Department of Urology, Charité – Universitätsmedizin Berlin, Charitéplatz 1, 10117 Berlin, Germany.

e-mail: hofbauer.sebastian@gmail.com

Abbreviations: csPCa, clinically significant prostate cancer; IQR, interquartile range; micro-US, micro-ultrasonography; mpMRI, multiparametric MRI; PCa, prostate cancer; PI-RADS, Prostate Imaging Reporting and Data System; PRI-MUS, Prostate Risk Identification for Micro-Ultrasonography.

Supporting Information

Additional Supporting Information may be found in the online version of this article:

Table S1 Missed csPCa locations according to different PRI-MUS and PI-RADS scores csPCa = clinically significant prostate cancer; PRI-MUS = Prostate Risk Identification for Micro-Ultrasonography; PI-RADS = Prostate Imaging Reporting and Data System; PZ = peripheral zone; TZ = transitional zone.