


Early volumetric changes of hippocampus and medial prefrontal cortex following medial temporal lobe resection

Anna Pajkert¹ | Christoph J. Ploner¹ | Thomas-Nicolas Lehmann² | Veronica A. Witte³ | Frank Oltmanns⁴ | Werner Sommer⁵ | Martin Holtkamp^{1,4} | Hauke R. Heekeren^{6,7} | Carsten Finke^{1,8} 

¹Department of Neurology, Charité – Universitätsmedizin Berlin, Berlin, Germany

²Department of Neurosurgery, Helios Clinic, Bad Saarow, Germany

³Department of Neurology, Max Planck Institute for Human Cognitive and Brain Sciences, Leipzig, Germany

⁴Epilepsy-Center Berlin-Brandenburg, Berlin, Germany

⁵Institut für Psychologie, Humboldt-Universität zu Berlin, Berlin, Germany

⁶Department of Education and Psychology, Freie Universität Berlin, Berlin, Germany

⁷Center for Cognitive Neuroscience Berlin, Freie Universität Berlin, Berlin, Germany

⁸Berlin School of Mind & Brain, Humboldt-Universität zu Berlin, Berlin, Germany

Correspondence

Carsten Finke, Department of Neurology, Charité – Universitätsmedizin Berlin, Charitéplatz 1, 10117 Berlin, Germany. Email: carsten.finke@charite.de

Funding information

Deutsche Forschungsgemeinschaft, Grant/Award Number: 327654276

Abstract

Previous studies have shown that cognitive demands and physical exercise stimulate adult neurogenesis in the dentate gyrus and hippocampus. Recent observations in healthy humans and patients with mild cognitive impairment moreover suggest that training-induced increases in hippocampal volume may be associated with improved memory performance. The corresponding plasticity processes in hippocampal volume may occur on timescales of months to years. For patients with focal lesions in this region, previous functional imaging studies suggest that increased recruitment of the contralateral hippocampus and extratemporal regions may be an important part of the reorganization of episodic memory. However, it is currently unclear whether focal damage to the medial temporal lobe (MTL) induces gray matter (GM) volume changes in the intact contralateral hippocampus and in connected network regions on a shorter timescale. We therefore investigated whether unilateral resection of the MTL, including the hippocampus, induces measurable volumetric changes in the contralateral hippocampus and in the default mode network (DMN). We recruited 31 patients with unilateral left ($N = 19$) or right ($N = 12$) hippocampal sclerosis undergoing MTL resection for treatment of drug-resistant epilepsy. Structural MRI was acquired immediately before and 3 months after surgery. Longitudinal voxel-based morphometry (VBM) analysis revealed a significant increase of right hippocampal volume following resection of the left anterior MTL. Furthermore, this patient group showed GM volume increases in the DMN. These results demonstrate significant structural plasticity of the contralateral hippocampus, even in patients with a long-standing unilateral hippocampal dysfunction and structural reorganization processes extending to distant, but functionally connected brain regions.

Abbreviations: ANOVAs, Analyses of variance; DMN, Default mode network; GM, Gray matter; MTL, Medial temporal lobe; MWT, Mehrfachwahl-Wortschatz-Intelligenztest; NART, National Adult Reading Test; ROCF, Rey-Osterrieth Complex Figure Test; TFCE, Threshold-free cluster enhancement; TLE, Temporal lobe epilepsy; ToM, Theory of mind; VBM, Voxel-based morphometry; VLMT, Verbaler Lern- und Merkfähigkeitstest.

Edited by John Foxe.

The peer review history for this article is available at <https://publons.com/publon/10.1111/ejn.14784>

This is an open access article under the terms of the Creative Commons Attribution-NonCommercial-NoDerivs License, which permits use and distribution in any medium, provided the original work is properly cited, the use is non-commercial and no modifications or adaptations are made.

© 2020 The Authors. *European Journal of Neuroscience* published by Federation of European Neuroscience Societies and John Wiley & Sons Ltd

KEYWORDS

default mode network, hippocampus, medial prefrontal cortex, medial temporal lobe resection, plasticity

1 | INTRODUCTION

Due to its pivotal role for cognition, neuroplasticity of the hippocampus has received intense interest during the last few years. In healthy subjects, interventions such as cognitive training or physical exercise have been shown to induce hippocampal volume increases that correlate with improved cognitive performance (Fotuhi, Do, & Jack, 2012; Voss, Vivar, Kramer, & van Praag, 2013). Proposed mechanisms of these structural changes include neurogenesis, myelination, glial changes, and angiogenesis (Thomas et al., 2016; Voss et al., 2013; Zatorre, Fields, & Johansen-Berg, 2012). Recently, structural hippocampal plasticity has also been reported in patients with hippocampal disorders (Mufson et al., 2015). However, the temporal properties and extent of these structural changes in patients remain to be explored.

In healthy participants, the acquisition of navigational knowledge selectively increases GM volume in the posterior hippocampus, accompanied by improved visuospatial memory performance (Maguire et al., 2000; Woollett & Maguire, 2011). Similar increases of hippocampal volume were found following virtual navigation training (Kühn, Gleich, Lorenz, Lindenberger, & Gallinat, 2014) or following the acquisition of abstract information (Draganski et al., 2006). Furthermore, aerobic exercise has been shown to increase anterior hippocampal volume in healthy older adults, correlating with improved spatial memory (Düzel, Van Praag, & Sendtner, 2016; Erickson et al., 2011). Training-induced hippocampal plasticity has been observed at different timescales—ranging from several weeks (Thomas et al., 2016) to months (Draganski et al., 2006) and even years of regular exercise (Erickson et al., 2011; Woollett & Maguire, 2011), while others found microstructural changes of the hippocampus already two hours after visuospatial memory training (Sagi et al., 2012; Tavor, Hofstetter, & Assaf, 2013). Longitudinal analyses moreover revealed that structural hippocampal changes may be both transient (Thomas et al., 2016) and permanent, even after cessation of training (Draganski et al., 2006).

Hippocampal plasticity can also be observed in neurological and psychiatric disorders. In patients with schizophrenia, aerobic training was associated with increased hippocampal volume and improved memory performance (Pajonk et al., 2010). Compensatory hippocampal plasticity was also found in patients with mild cognitive impairment and in early stages of Alzheimer's disease (Rosen, Sugiura, Kramer, Whitfield-Gabrieli, & Gabrieli, 2011; ten Brinke et al., 2015). In patients with hippocampal sclerosis, efficient

functional network reorganization has been observed (Bettus et al., 2009; Bonelli et al., 2010; Finke, Bruehl, Düzel, Heekeren, & Ploner, 2013; Sidhu et al., 2013). Following unilateral resection of a sclerotic anterior hippocampus, memory performance depended on functional compensation by the posterior hippocampal remnant as well as by the intact contralateral hippocampus (Bonelli et al., 2013; Sidhu et al., 2016; Stretton et al., 2014).

The hippocampus is furthermore associated with the DMN, a large-scale functional brain network related to self-referential processing, including episodic memory and theory of mind supported by distinct DMN subnetworks (Buckner, Andrews-Hanna, & Schacter, 2008; Peer et al., 2015; Braga & Buckner, 2017; DiNicola, Braga, & Buckner, 2020). Previous studies in patients with hippocampal damage have shown relevant functional alterations of DMN core regions in association with impaired memory performance, including reduced functional connectivity between the hippocampus and the medial prefrontal cortex, reduced functional connectivity within the DMN, and decreased activation of the DMN regions during the performance of memory tasks (Addis, Moscovitch, & McAndrews, 2007; Finke, Kopp, et al., 2013; Heine et al., 2018; Voets et al., 2012).

Here, we investigated short-term structural plasticity following acute unilateral MTL damage. Patients undergoing MTL resection due to drug-resistant focal epilepsy were studied before and after surgery using VBM (3 months after surgery) and neuropsychological assessment (12 months after surgery). We aimed to study postsurgical volumetric changes in the contralesional hippocampus and to explore associated structural changes in the DMN.

2 | METHODS

2.1 | Patients

Thirty-one patients with histologically verified unilateral hippocampal sclerosis (left, 19 patients; right, 12 patients) and pharmacologically intractable temporal lobe epilepsy (TLE) were recruited from the Epilepsy-Center Berlin-Brandenburg (Table 1). All patients underwent combined temporal pole resection with amygdalohippocampectomy (TPR + resection (Helmstaedter et al., 2008)). Only patients without any further structural brain damage were included. The seizure focus was determined according to a standard clinical protocol using long-term video-EEG monitoring, structural MRI, and neuropsychological testing. Patients with left- and right-sided resections did not differ

TABLE 1 Patient data

	Left-sided resection (<i>N</i> = 19)	Right-sided resection (<i>N</i> = 12)	<i>p</i> value
Age (y, mean ± <i>SD</i>)	38.3 ± 10.4	38.4 ± 16.1	>.9 ^a
Sex (F/M)	12/ 7	7/ 5	>.8 ^b
Age at disease onset (y, mean ± <i>SD</i>)	14.1 ± 12.5	13.8 ± 12.7	>.9 ^a
Preoperative IQ (± <i>SD</i>)	103 ± 17	102 ± 14	>.8 ^a
Time between pre-op and post-op MRI (m, mean ± <i>SD</i>)	3.5 ± 1.1	3.7 ± 1.5	>.6 ^a
Hippocampal sclerosis			
Wyler grade 1	3 (16%)	1 (8%)	>.3 ^c
Wyler grade 2	2 (11%)	2 (17%)	
Wyler grade 3	10 (52%)	3 (25%)	
Wyler grade 4	4 (21%)	6 (50%)	
Lesion volume (mm ³ , mean ± <i>SD</i>)	5,095 ± 1,361	5,335 ± 1,491	>.6 ^a

^a*t*-test (2-tailed).^bchi-square test.^cMann–Whitney *U* test.

significantly with respect to age at resection, age at seizure onset, disease duration, and severity of hippocampal sclerosis (Table 1). Handedness was determined using a standard questionnaire (Oldfield, 1971). One patient from the right-resected group (8.3%) and two patients from the left-resected group (10.5%) were left-handed. All patients received antiepileptic medication (Table S1). All participants gave written informed consent. The study was approved by the Ethics Committee of Charité—Universitätsmedizin Berlin.

2.2 | Neuropsychological assessment

All patients underwent neuropsychological assessment as part of a standard pre- and postoperative evaluation procedure. Neuropsychological testing was conducted 5 ± 3.7 and 7 ± 3.6 months before surgery in the left- and right-resected groups, respectively (*t*-test, $t_{29} = -1.5$; $p = .14$). The postsurgical data were collected 12.2 ± 1.1 and 11.5 ± 0.7 months after resection in the left- and right-resected group, respectively (*t*-test, $t_{29} = 1.8$; $p = .08$). Verbal and visuospatial episodic memory were tested using a German adaptation of the Rey Auditory Verbal Learning Test (*Verbaler Lern- und Merkfähigkeitstest*, VLMT; Helmstaedter, Lendt, & Lux, 2000) and the Rey-Osterrieth Complex Figure Test (ROCF; Shin, Park, Park, Seol, & Kwon, 2006). Crystalline intelligence was assessed before surgery using the multiple-choice vocabulary intelligence test (*Mehrfachwahl-Wortschatz-Intelligenztest*, MWT),

a German equivalent to the National Adult Reading Test (NART; Lehrl, 2005).

2.3 | Statistical analysis of demographic and neuropsychological data

Statistical analyses were performed using PASW Statistics 18.0 (IBM). We used unpaired *t*-tests for comparisons of demographic and clinical data between patient groups. Group differences in memory performance between both patient groups were assessed using mixed design analyses of variance (ANOVAs) with “group” as between-subjects factor and repeated measures on “time point” of assessment. ANOVAs were conducted separately for verbal and visuospatial memory with Bonferroni correction for multiple comparisons. As a post hoc test, the Bonferroni test was used.

2.4 | MRI acquisition

MRI data were acquired on a 1.5T Philips Gyroscan NT Intera scanner using a T1-weighted 3D MPRAGE sequence (matrix = 256×256 ; voxel size $1 \times 1 \times 1$ mm; number of slices: 190; TR 15 ms; TE 5.4 ms). The first MRI session was conducted 3.4 ± 5.5 and 2.1 ± 3.8 days before surgery in the left- and right-resected group, respectively (*t*-test, $t_{29} = 0.71$; $p = .48$). The second MRI scan was acquired 101 ± 34 and 108.5 ± 45 days postoperatively in the left- and right-resected patients, respectively (*t*-test, $t_{29} = -0.53$; $p = .6$).

2.5 | Lesion analysis

Postsurgical lesions were manually outlined on each coronal slice of the individual MPRAGE images using MRIcron (www.mricron.com/mricron; Rorden, Karnath, & Bonilha, 2007). Individual lesion shapes and MPRAGE images were then spatially normalized to the MNI brain template using the unified segmentation and normalization approach provided with SPM8 (www.fil.ion.ucl.ac.uk/spm). Lesion overlap analysis revealed similar lesion extent for patients with left- and right-sided resection with lesions of the anterior hippocampus, amygdala, entorhinal cortex, parts of perirhinal cortex in all patients, and additional damage to parahippocampal and inferotemporal cortex in some patients (Figure 1). The lesion volume was not significantly different between the two patient groups (left, $5,095 \pm 1,361$; right, $5,335 \pm 1,491 \text{ mm}^3$, t -test, $t_{29} = -0.45$; $p = .66$).

2.6 | VBM analysis

Longitudinal VBM analysis followed the procedure described by Douaud et al. (2009), using FSL-VBM 5.0 (FMRIB's Software Library, <https://fsl.fmrib.ox.ac.uk/fsl/>). All outputs were carefully checked after each processing stage. First, T1-weighted images were preprocessed to remove all non-brain matter (BET; Smith, 2002) and segmented into GM probability maps using FSL FAST (Zhang, Brady, & Smith, 2001). Then, a halfway rigid-body transformation was determined

between the two anatomical brain images (pre- and postoperative), applied to register both images to that halfway space and averaged to build a subject-specific template. Next, the subject-specific templates were registered to a standard MNI152 brain image using affine and non-linear transformations and averaged to build a study-specific template (Andersson, Jenkinson, & Smith, 2007). Then, all subject-specific halfway templates were non-linearly registered using FSL FNIRT onto the study-specific template. The native GM images were co-registered to the subject- and study-specific templates using a combined transformation and modulated by the Jacobian determinant to correct for local expansion (or contraction) due to the non-linear component of the spatial transformation. To obtain a better distribution of GM probability values across voxels, images were smoothed with an isotropic Gaussian kernel with a sigma of 2 mm. Changes in contralateral temporal lobe GM density, measured using the modulated GM probability values voxel-by-voxel in that region, were assessed using difference maps. These maps were created by subtracting the preoperative scan from the postoperative scan separately for each subject. One-sample t -tests with permutation-based non-parametric significance testing (10,000 permutations) with the threshold-free cluster enhancement (TFCE) option (Winkler, Ridgway, Webster, Smith, & Nichols, 2014) were used to assess longitudinal changes. These analyses were conducted for the left- and right-resected patients separately. For both groups, the contralateral hippocampus was defined as region of interest based on the probabilistic Harvard-Oxford Structural Atlas (threshold at 50%). For the DMN analysis,

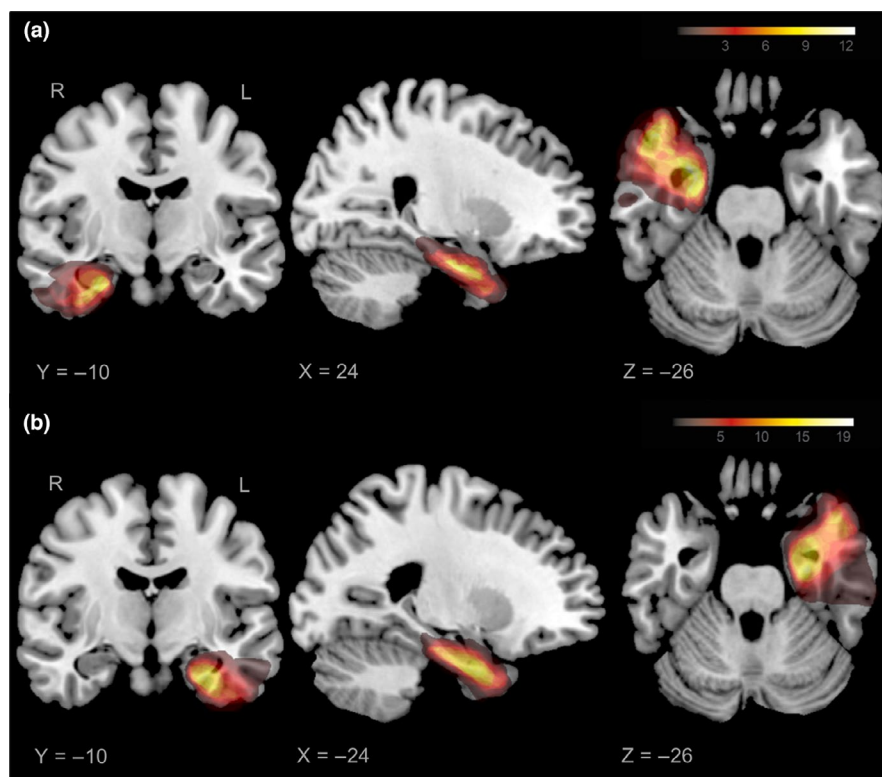


FIGURE 1 Lesion overlap analysis in patients with right (a) and left-sided (b) resection. The colour bar indicates the number of patients with a lesion in a particular voxel [Colour figure can be viewed at wileyonlinelibrary.com]

a mask by Shirer, Ryali, Rykhlevskaia, Menon, and Greicius (2012) was used. For correlation analyses, the difference between pre- and postoperative structural images was calculated and correlated with memory performance using a continuous covariate interaction.

3 | RESULTS

3.1 | Neuropsychological assessment

Patients with left- and right-sided resection did not differ in demographic and disease-related variables (Table 1). Patients with left-sided pathology showed significantly better visuospatial memory performance compared to patients with right-sided pathology (ROCF, main effect; $F_{1,29} = 10.22$, $p = .003$, $\eta^2 = 0.261$; Table 2). Conversely, patients with right-sided pathology performed significantly better in the verbal memory test compared to patients with left-sided pathology (VLMT, main effect; $F_{1,29} = 5.3$, $p = .03$, $\eta^2 = 0.154$). No interactions between patient group and time of testing were found for visuospatial and verbal memory performance (ROCF, $F_{1,29} = 1.05$, $p = .314$, $\eta^2 = 0.035$; VLMT, $F_{1,29} = 0.435$, $p = .515$, $\eta^2 = 0.015$).

3.2 | Longitudinal GM changes in the hippocampus and the DMN

Following left-sided resections, a region in the right hippocampus homologous to the resected area showed a significant increase in GM volume ($p < .05$; Figure 2). In addition, a GM volume increase was observed in the left medial prefrontal cortex in patients with left-sided resection (Figure 3). No significant volume change was observed in patients with right-sided resections. No correlations between the observed volume changes and memory performance were found.

TABLE 2 Memory performance

	Left-sided resection ($N = 19$)	Right-sided resection ($N = 12$)	p value
Verbal memory			
Delayed recall preoperative (Test score, mean \pm SD)	8.4 \pm 3.3	10.8 \pm 4	.029 ^a
Delayed recall postoperative (Test score, mean \pm SD)	8 \pm 3.6	11 \pm 3	.515 ^b
Visuospatial memory			
Delayed recall preoperative (Test score, mean \pm SD)	36.7 \pm 8.8	27.3 \pm 14.7	.003 ^a
Delayed recall postoperative (Test score, mean \pm SD)	38.9 \pm 11.5	24.8 \pm 12.9	.314 ^b

^aRepeated ANOVA: Between-subject.

^bRepeated ANOVA: Interaction: Testing time \times Lesion side.

4 | DISCUSSION

The present longitudinal study investigated early structural plasticity of the hippocampus following contralateral anterior temporal lobe resections. In patients with left-sided resections, a significant increase in the contralateral hippocampal volume was observed. Furthermore, we observed GM volume increases in the medial prefrontal cortex—a core region of the DMN—in patients with resection of the left temporal lobe.

Although lesion studies over the last decade have repeatedly investigated reorganization processes following temporal lobe resections, their temporal properties and behavioral significance are still a matter of debate (Bonelli et al., 2010; Figueiredo et al., 2008; Powell et al., 2007; Richardson, Strange, Duncan, & Dolan, 2003; Stretton et al., 2013). Nonetheless, previous findings have shown that adult patients with TLE suffer from memory decline for several months after surgery (Gleissner, Sassen, Schramm, Elger, & Helmstaedter, 2005; Sidhu et al., 2015, 2016) and that these deficits may be persistent (Gleissner, Helmstaedter, Schramm, & Elger, 2004; Rausch et al., 2003). In the present study, we observed similar patterns of longitudinal memory performance in both patient groups. Postoperatively, left-resected patients had declined in verbal memory but improved in visuospatial memory as compared to the preoperative test. A reverse pattern was found in the right-resected group. After surgery, these patients scored worse in the visuospatial but improved in the verbal memory assessment. These findings are in line with previous observations showing decline in verbal memory performance following left temporal lobe resection and decline in visual memory after right-sided resection (Gleissner et al., 2005; Sidhu et al., 2016).

Neuroplasticity of the hippocampus following cognitive training or aerobic exercise has been demonstrated in various studies in healthy participants (Draganski et al., 2006; Erickson et al., 2011; Kühn et al., 2014; Maguire et al., 2000;

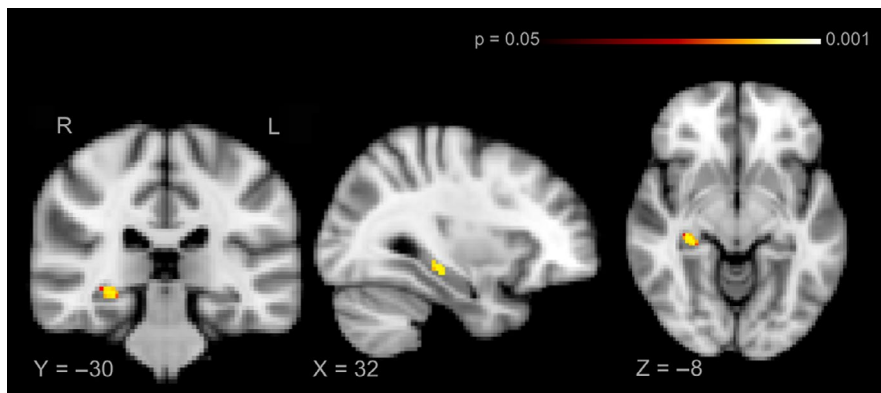


FIGURE 2 Increase of right hippocampal volume following left-sided anterior MTL resection [Colour figure can be viewed at wileyonlinelibrary.com]

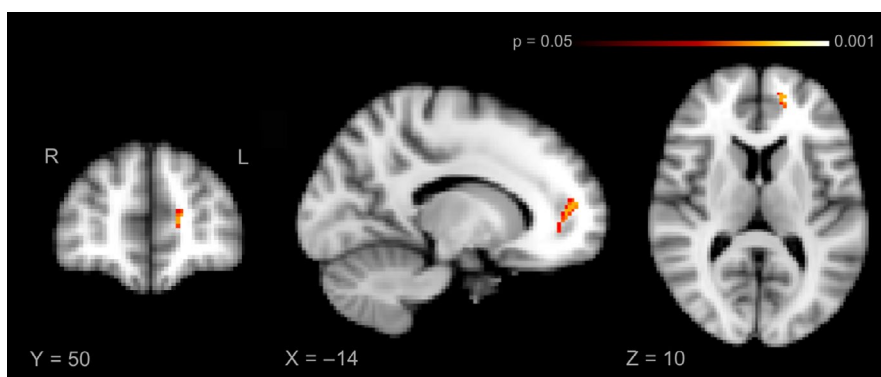


FIGURE 3 Gray volume increase in left medial prefrontal cortex following left-sided anterior MTL resection [Colour figure can be viewed at wileyonlinelibrary.com]

Sagi et al., 2012; Tavor et al., 2013; Thomas et al., 2016; Woollett & Maguire, 2011), but also in patients with hippocampal dysfunction (Bettus et al., 2009; Bonelli et al., 2010; Das et al., 2009; Mufson et al., 2015). For example, longitudinal studies have shown that memory performance in patients with hippocampal sclerosis and TLE undergoing anterior temporal lobe resection can be compensated by increased activation of the contralateral hippocampus as well as the ipsilateral hippocampal remnant (Bonelli et al., 2013; Finke, Bruehl, et al., 2013; Sidhu et al., 2016; Stretton et al., 2014). These functional changes were observed already three months after surgery, with further reorganization 12 months postoperatively (Sidhu et al., 2016; Stretton et al., 2014). Here, we show that postlesional adaptive processes extend beyond functional network reorganization and also include significant structural changes that operate on a short timescale. Interestingly, structural variations have been suggested to drive functional connectivity alterations in patients with TLE (Voets et al., 2012); therefore, the observed hippocampal volume increase might contribute to the postsurgical normalization of functional network alterations in these patients (Sidhu et al., 2016; Stretton et al., 2014).

The present findings highlight the relevance of pre- and postoperative temporal dynamics for hippocampal plasticity in patients with anterior temporal lobe resections. For example, Braun et al. (2008) compared two patient groups with similar surgical lesions to the right MTL, but different

preoperative disease courses. Patients suffering from hippocampal sclerosis, which develops early in life, performed on the same level as controls in a non-verbal associative memory task. By contrast, patients operated due to benign tumors had a significantly shorter preoperative disease duration and showed degraded memory performance. These findings indicate successful memory reorganization following long-standing hippocampal damage. Moreover, Finke, Bruehl, et al. (2013) reported that activity in the contralateral hippocampus after partial temporal lobe resection in patients with hippocampal sclerosis correlated positively with memory performance, whereas no such link between hippocampal activity and memory performance was observed in patients operated due to benign tumor with short preoperative disease duration. Patients with hippocampal sclerosis, compared to tumor patients, showed increased activity in neocortical areas in dorsolateral prefrontal cortex and posterior parietal cortex. In contrast, early onset of seizures and prolonged disease duration were associated with reduced ipsilateral temporal lobe network connectivity that was in turn associated with naming deficits in patients with temporal lobe epilepsy (Trimmel et al., 2018). In addition to such long-standing preoperative plasticity processes, our results and previous studies (Gleissner et al., 2005; Sidhu et al., 2016; Stretton et al., 2014) show that structural postoperative reorganization can occur on a much shorter timescale, that is, 3–12 months after anterior temporal lobe resection.

The hippocampus is associated with the DMN, a functional brain network involved in self-referential processing, including theory of mind (ToM) and episodic memory (Andrews-Hanna, Reidler, Sepulcre, Poulin, & Buckner, 2010; DiNicola et al., 2020). Consequently, a variety of structural and functional alterations have been observed in core regions of the DMN in patients with hippocampal dysfunction. Structural analyses in patients with unilateral hippocampal sclerosis found progressive atrophy that included core regions of the DMN, that is, medial prefrontal cortex, retrosplenial cortex, precuneus, posterior inferior parietal lobe, and lateral temporal cortex (Bernhardt, Bernasconi, Concha, & Bernasconi, 2010; Bernhardt, Hong, Bernasconi, & Bernasconi, 2013; Frings, Schulze-Bonhage, Spreer, & Wagner, 2009; Keller & Roberts, 2008). Functional connectivity analyses frequently observed reduced connectivity between the hippocampus and DMN regions in patients with hippocampal damage such as hippocampal sclerosis (Frings et al., 2009; Liao et al., 2011; Voets et al., 2012) and autoimmune encephalitis (Esfahani-Bayerl, Finke, Kopp, Moon, & Ploner, 2019; Finke, Kopp, et al., 2013). Further studies in these patient groups reported increased functional connectivity between the hippocampus and DMN regions that was associated with better memory performance, suggesting compensatory processes (Bettus et al., 2009; Heine et al., 2018). Here, we found a significant GM volume increase in the ipsilateral medial prefrontal cortex following left-sided resection. This finding indicates that structural reorganization processes can extend beyond contralateral homologous areas and include other functionally connected brain regions. Recent within-individual analyses have moreover shown that the DMN comprises two distinct subnetworks: network A coupled with the posterior parahippocampal cortex and preferentially recruited for episodic memory tasks and network B linked to the temporoparietal junction and recruited for tasks requiring ToM (Braga & Buckner, 2017; Braga, Van Dijk, Polimeni, Eldaief, & Buckner, 2019; DiNicola et al., 2020). Interestingly, the GM increase in medial prefrontal cortex observed in patients with left-sided resection overlaps well with medial prefrontal cortex parts of the proposed network A that is linked to episodic memory (Braga & Buckner, 2017; Braga et al., 2019). Moreover, a similar region within the medial prefrontal cortex was identified as part of the human memory circuit using lesion network analysis in a sample of patients with amnesia due to stroke-associated brain lesions (Ferguson et al., 2019). These latter findings further support the notion that the here observed medial prefrontal cortex GM increase is linked to episodic memory processing and could contribute to an improvement of memory performance.

Limitations of the current study include the relatively low overall sample size and the uneven distribution of patients with left-sided resection ($n = 19$) and right-sided resection

($n = 12$). Although demographic and clinical parameters did not differ between groups, structural changes in the hippocampus and the DMN were only observed in left-resected patients. It is conceivable that the absence of statistically significant volume increases in the left hippocampus or in DMN regions in patients with right-sided resection is due to the lower sample size of this group. Alternatively, these findings could indicate differences in the reorganization process between right- and left-sided TLE. This latter hypothesis would be in line with findings highlighting the differential neuroanatomy of the left and right MTL (Nobis et al., 2019), which might extend to structural reorganization processes (Bonelli et al., 2013; Gleissner, Helmstaedter, & Elger, 2002; Gleissner et al., 2004). To further address this question, studies with larger samples sizes and a balanced distribution of left- and right-resected patients are required.

Anterior temporal lobe resection is a successful treatment for patients with drug-resistant focal epilepsy (Engel, 2012; Wiebe, Blume, Girvin, & Eliasziw, 2001), leaving 50% of patients seizure-free for at least 10 years (De Tisi et al., 2011). Here, we show that temporal lobe resection triggers a cascade of postsurgical plasticity processes that add to preoperative brain reorganization. Importantly, these postsurgical plasticity processes can be observed despite the resection of an already dysfunctional hippocampus. Future studies that use repeated structural MRI studies—ideally combining different imaging modalities such as volumetric analyses and diffusion tensor imaging to study associated white matter changes—and neuropsychological assessments following temporal lobe resection are needed to reveal the critical time windows for reorganization. These time windows may contribute to a more individualized cognitive rehabilitation in patients following temporal lobe resection.

ACKNOWLEDGEMENTS

This work was funded by the Deutsche Forschungsgemeinschaft (DFG, German Research Foundation)—Project number 327654276 – SFB 1315. Anna Pajkert was supported by an Elsa-Neumann-Scholarship and by the Sonnenfeld-Stiftung.

CONFLICT OF INTEREST

The authors declare no conflict of interest.

AUTHOR CONTRIBUTIONS

Carsten Finke, Christoph J. Ploner, Hauke R. Heekeren, and Martin Holtkamp involved in conceptualization. Anna Pajkert, Carsten Finke, and Veronica Witte involved in data analysis. Anna Pajkert, Carsten Finke, and Christoph J. Ploner involved in writing the original draft. Anna Pajkert, Christoph J. Ploner, Thomas-Nicolas Lehmann, Veronica Witte, Frank Oltmanns, Werner Sommer, Martin Holtkamp, Hauke R. Heekeren, and Carsten Finke involved in reviewing and editing.

DATA AVAILABILITY STATEMENT

The data that support the findings of this study are available from the corresponding author upon reasonable request.

ORCID

Carsten Finke  <https://orcid.org/0000-0002-7665-1171>

REFERENCES

- Addis, D. R., Moscovitch, M., & McAndrews, M. P. (2007). Consequences of hippocampal damage across the autobiographical memory network in left temporal lobe epilepsy. *Brain*, *130*, 2327–2342. <https://doi.org/10.1093/brain/awm166>
- Andersson, J. L. R., Jenkinson, M., & Smith, S. (2007). *Non-linear registration, aka spatial normalisation. FMRIB Technical Report TR07JA2*. Oxford, UK: FMRIB Centre, 22. <https://www.fmrib.ox.ac.uk/datasets/techrep/tr07ja2/tr07ja2.pdf>.
- Andrews-Hanna, J. R., Reidler, J. S., Sepulcre, J., Poulin, R., & Buckner, R. L. (2010). Functional-anatomic fractionation of the brain's default network. *Neuron*, *65*, 550–562. <https://doi.org/10.1016/j.neuron.2010.02.005>
- Bernhardt, B. C., Bernasconi, N., Concha, L., & Bernasconi, A. (2010). Cortical thickness analysis in temporal lobe epilepsy: Reproducibility and relation to outcome. *Neurology*, *74*, 1776–1784. <https://doi.org/10.1212/WNL.0b013e3181e0f80a>
- Bernhardt, B. C., Hong, S., Bernasconi, A., & Bernasconi, N. (2013). Imaging structural and functional brain networks in temporal lobe epilepsy. *Frontiers in Human Neuroscience*, *7*, 624.
- Bettus, G., Guedj, E., Joyeux, F., Confort-Gouny, S., Soulier, E., Laguitton, V., ... Guye, M. (2009). Decreased basal fMRI functional connectivity in epileptogenic networks and contralateral compensatory mechanisms. *Human Brain Mapping*, *30*, 1580–1591.
- Bonelli, S. B., Powell, R. H. W., Yogarajah, M., Samson, R. S., Symms, M. R., Thompson, P. J., ... Duncan, J. S. (2010). Imaging memory in temporal lobe epilepsy: Predicting the effects of temporal lobe resection. *Brain*, *133*, 1186–1199. <https://doi.org/10.1093/brain/awq006>
- Bonelli, S. B., Thompson, P. J., Yogarajah, M., Powell, R. H. W., Samson, R. S., McEvoy, A. W., ... Duncan, J. S. (2013). Memory reorganization following anterior temporal lobe resection: A longitudinal functional MRI study. *Brain*, *136*, 1889–1900. <https://doi.org/10.1093/brain/awt105>
- Braga, R. M., & Buckner, R. L. (2017). Parallel interdigitated distributed networks within the individual estimated by intrinsic functional connectivity. *Neuron*, *95*, 457.e5–471.e5. <https://doi.org/10.1016/j.neuron.2017.06.038>
- Braga, R. M., Van Dijk, K. R. A., Polimeni, J. R., Eldaief, M. C., & Buckner, R. L. (2019). Parallel distributed networks resolved at high resolution reveal close juxtaposition of distinct regions. *Journal of Neurophysiology*, *121*, 1513–1534.
- Braun, M., Finke, C., Ostendorf, F., Lehmann, T.-N., Hoffmann, K.-T., & Ploner, C. J. (2008). Reorganization of associative memory in humans with long-standing hippocampal damage. *Brain*, *131*, 2742–2750. <https://doi.org/10.1093/brain/awn191>
- Buckner, R. L., Andrews-Hanna, J. R., & Schacter, D. L. (2008). The brain's default network: Anatomy, function, and relevance to disease. *Annals of the New York Academy of Sciences*, *1124*, 1–38.
- Das, S. R., Mechanic-Hamilton, D., Korczykowski, M., Pluta, J., Glynn, S., Avants, B. B., ... Yushkevich, P. A. (2009). Structure specific analysis of the hippocampus in temporal lobe epilepsy. *Hippocampus*, *19*, 517–525.
- De Tisi, J., Bell, G. S., Peacock, J. L., McEvoy, A. W., Harkness, W. F., Sander, J. W., & Duncan, J. S. (2011). The long-term outcome of adult epilepsy surgery, patterns of seizure remission, and relapse: A cohort study. *Lancet*, *378*, 1388–1395. [https://doi.org/10.1016/S0140-6736\(11\)60890-8](https://doi.org/10.1016/S0140-6736(11)60890-8)
- DiNicola, L. M., Braga, R. M., & Buckner, R. L. (2020). Parallel distributed networks dissociate episodic and social functions within the individual. *Journal of Neurophysiology*, *123*, 1144–1179.
- Douaud, G., MacKay, C., Andersson, J., James, S., Quedest, D., Ray, M. K., ... James, A. (2009). Schizophrenia delays and alters maturation of the brain in adolescence. *Brain*, *132*, 2437–2448. <https://doi.org/10.1093/brain/awp126>
- Draganski, B., Gaser, C., Kempermann, G., Kuhn, H. G., Winkler, J., Buchel, C., & May, A. (2006). Temporal and spatial dynamics of brain structure changes during extensive learning. *Journal of Neuroscience*, *26*, 6314–6317.
- Duzel, E., Van Praag, H., & Sendtner, M. (2016). Can physical exercise in old age improve memory and hippocampal function? *Brain*, *139*, 662–673. <https://doi.org/10.1093/brain/awv407>
- Engel, J. (2012). Early surgical therapy for drug-resistant temporal lobe epilepsy. *JAMA*, *307*, 922. <https://doi.org/10.1001/jama.2012.220>
- Erickson, K. I., Voss, M. W., Prakash, R. S., Basak, C., Szabo, A., Chaddock, L., ... Kramer, A. F. (2011). Exercise training increases size of hippocampus and improves memory. *Proceedings of the National Academy of Sciences of the United States of America*, *108*, 3017–3022.
- Esfahani-Bayerl, N., Finke, C., Kopp, U., Moon, D.-U., & Ploner, C. J. (2019). Musical memory and hippocampus revisited: Evidence from a musical layperson with highly selective hippocampal damage. *Cortex*, *119*, 519–527. <https://doi.org/10.1016/j.cortex.2018.12.023>
- Ferguson, M. A., Lim, C., Cooke, D., Darby, R. R., Wu, O., Rost, N. S., ... Fox, M. D. (2019). A human memory circuit derived from brain lesions causing amnesia. *Nature Communications*, *10*, 3497.
- Figueiredo, P., Santana, I., Teixeira, J., Cunha, C., Machado, E., Sales, F., ... Castelo-Branco, M. (2008). Adaptive visual memory reorganization in right medial temporal lobe epilepsy. *Epilepsia*, *49*, 1395–1408. <https://doi.org/10.1111/j.1528-1167.2008.01629.x>
- Finke, C., Bruehl, H., Düzel, E., Hecker, H. R., & Ploner, C. J. (2013). Neural correlates of short-term memory reorganization in humans with hippocampal damage. *Journal of Neuroscience*, *33*, 11061–11069.
- Finke, C., Kopp, U. A., Scheel, M., Pech, L.-M., Soemmer, C., & Schlichting, J., ... Paul, F. (2013). Functional and structural brain changes in anti-N-methyl-D-aspartate receptor encephalitis. *Annals of Neurology*, *74*, 284–296.
- Fotuhi, M., Do, D., & Jack, C. (2012). Modifiable factors that alter the size of the hippocampus with ageing. *Nature Reviews Neurology*, *8*, 189–202.
- Frings, L., Schulze-Bonhage, A., Spreer, J., & Wagner, K. (2009). Remote effects of hippocampal damage on default network connectivity in the human brain. *Journal of Neurology*, *256*, 2021–2029.
- Gleissner, U., Helmstaedter, C., & Elger, C. E. (2002). Memory reorganization in adult brain: Observations in three patients with

- temporal lobe epilepsy. *Epilepsy Research*, *48*, 229–234. [https://doi.org/10.1016/S0920-1211\(01\)00333-3](https://doi.org/10.1016/S0920-1211(01)00333-3)
- Gleissner, U., Helmstaedter, C., Schramm, J., & Elger, C. E. (2004). Memory outcome after selective amygdalohippocampectomy in patients with temporal lobe epilepsy: One-year follow-up. *Epilepsia*, *45*, 960–962. <https://doi.org/10.1111/j.0013-9580.2004.42203.x>
- Gleissner, U., Sassen, R., Schramm, J., Elger, C. E., & Helmstaedter, C. (2005). Greater functional recovery after temporal lobe epilepsy surgery in children. *Brain*, *128*, 2822–2829. <https://doi.org/10.1093/brain/awh597>
- Heine, J., Prüss, H., Kopp, U. A., Wegner, F., Then Bergh, F., Münte, T., ... Finke, C. (2018). Beyond the limbic system: Disruption and functional compensation of large-scale brain networks in patients with anti-LGII encephalitis. *Journal of Neurology, Neurosurgery and Psychiatry*, *89*, 1191–1199.
- Helmstaedter, C., Lendt, M., & Lux, S. (2000). *VLMT: Verbaler Lern- und Merkfähigkeitstest*.
- Helmstaedter, C., Richter, S., Röske, S., Oltmanns, F., Schramm, J., & Lehmann, T.-N. (2008). Differential effects of temporal pole resection with amygdalohippocampectomy versus selective amygdalohippocampectomy on material-specific memory in patients with mesial temporal lobe epilepsy. *Epilepsia*, *49*, 88–97. <https://doi.org/10.1111/j.1528-1167.2007.01386.x>
- Keller, S. S., & Roberts, N. (2008). Voxel-based morphometry of temporal lobe epilepsy: An introduction and review of the literature. *Epilepsia*, *49*, 741–757. <https://doi.org/10.1111/j.1528-1167.2007.01485.x>
- Kühn, S., Gleich, T., Lorenz, R. C., Lindenberger, U., & Gallinat, J. (2014). Playing Super Mario induces structural brain plasticity: Gray matter changes resulting from training with a commercial video game. *Molecular Psychiatry*, *19*, 265–271.
- Lehrl, S. (2005). *Mehrfachwahl-Wortschatz-Intelligenztest*. Göttingen, Germany: Hogrefe Verlag.
- Liao, W., Zhang, Z., Pan, Z., Mantini, D., Ding, J., Duan, X., ... Chen, H. (2011). Default mode network abnormalities in mesial temporal lobe epilepsy: A study combining fMRI and DTI. *Human Brain Mapping*, *32*, 883–895. <https://doi.org/10.1002/hbm.21076>
- Maguire, E. A., Gadian, D. G., Johnsrude, I. S., Good, C. D., Ashburner, J., Frackowiak, R. S., & Frith, C. D. (2000). Navigation-related structural change in the hippocampi of taxi drivers. *Proceedings of the National Academy of Sciences of the United States America*, *97*, 4398–4403.
- Mufson, E. J., Mahady, L., Waters, D., Counts, S. E., Perez, S. E., DeKosky, S. T., ... Binder, L. I. (2015). Hippocampal plasticity during the progression of Alzheimer's disease. *Neuroscience*, *309*, 51–67. <https://doi.org/10.1016/j.neuroscience.2015.03.006>
- Nobis, L., Manohar, S. G., Smith, S. M., Alfaro-Almagro, F., Jenkinson, M., Mackay, C. E., & Husain, M. (2019). Hippocampal volume across age: Nomograms derived from over 19,700 people in UK Biobank. *NeuroImage Clinical*, *23*, 101904. <https://doi.org/10.1016/j.nicl.2019.101904>
- Oldfield, R. C. (1971). The assessment and analysis of handedness: The Edinburgh inventory. *Neuropsychologia*, *9*, 97–113. [https://doi.org/10.1016/0028-3932\(71\)90067-4](https://doi.org/10.1016/0028-3932(71)90067-4)
- Pajonk, F.-G., Wobrock, T., Gruber, O., Scherk, H., Berner, D., Kaizl, I., ... Falkai, P. (2010). Hippocampal plasticity in response to exercise in schizophrenia. *Archives of General Psychiatry*, *67*, 133–143.
- Peer, M., Salomon, R., Goldberg, I., Blanke, O., & Arzy, S. (2015). Brain system for mental orientation in space, time, and person. *Proceedings of the National Academy of Sciences of the United States of America*, *112*, 11072–11077.
- Powell, H. W. R., Richardson, M. P., Symms, M. R., Boulby, P. A., Thompson, P. J., Duncan, J. S., & Koepp, M. J. (2007). Reorganization of verbal and nonverbal memory in temporal lobe epilepsy due to unilateral hippocampal sclerosis. *Epilepsia*, *48*, 1512–1525. <https://doi.org/10.1111/j.1528-1167.2007.01053.x>
- Rausch, R., Kraemer, S., Pietras, C. J., Le, M., Vickrey, B. G., & Passaro, E. A. (2003). Early and late cognitive changes following temporal lobe surgery for epilepsy. *Neurology*, *60*, 951–959. <https://doi.org/10.1212/01.WNL.0000048203.23766.A1>
- Richardson, M. P., Strange, B. A., Duncan, J. S., & Dolan, R. J. (2003). Preserved verbal memory function in left medial temporal pathology involves reorganisation of function to right medial temporal lobe. *NeuroImage*, *20*, 112–119. <https://doi.org/10.1016/j.neuroimage.2003.09.008>
- Rorden, C., Karnath, H.-O., & Bonilha, L. (2007). Improving Lesion-Symptom Mapping. *Journal of Cognitive Neuroscience*, *19*, 1081–1088.
- Rosen, A. C., Sugiura, L., Kramer, J. H., Whitfield-Gabrieli, S., & Gabrieli, J. D. (2011). Cognitive training changes hippocampal function in mild cognitive impairment: A pilot study. *Journal of Alzheimer's Disease*, *26*(Suppl 3), 349–357. <https://doi.org/10.3233/JAD-2011-0009>
- Sagi, Y., Tavor, I., Hofstetter, S., Tzur-Moryosef, S., Blumenfeld-Katzir, T., & Assaf, Y. (2012). Learning in the fast lane: New insights into neuroplasticity. *Neuron*, *73*, 1195–1203. <https://doi.org/10.1016/j.neuron.2012.01.025>
- Shin, M.-S., Park, S.-Y., Park, S.-R., Seol, S.-H., & Kwon, J. S. (2006). Clinical and empirical applications of the Rey-Osterrieth complex figure test. *Nature Protocols*, *1*, 892–899.
- Shirer, W. R., Ryali, S., Rykhlevskaia, E., Menon, V., & Greicius, M. D. (2012). Decoding subject-driven cognitive states with whole-brain connectivity patterns. *Cerebral Cortex*, *22*, 158–165. <https://doi.org/10.1093/cercor/bhr099>
- Sidhu, M. K., Stretton, J., Winston, G. P., Bonelli, S., Centeno, M., Vollmar, C., ... Duncan, J. S. (2013). A functional magnetic resonance imaging study mapping the episodic memory encoding network in temporal lobe epilepsy. *Brain*, *136*, 1868–1888. <https://doi.org/10.1093/brain/awt099>
- Sidhu, M. K., Stretton, J., Winston, G. P., McEvoy, A. W., Symms, M., Thompson, P. J., ... Duncan, J. S. (2016). Memory network plasticity after temporal lobe resection: A longitudinal functional imaging study. *Brain*, *139*, 415–430. <https://doi.org/10.1093/brain/awv365>
- Sidhu, M. K., Stretton, J., Winston, G. P., Symms, M., Thompson, P. J., Koepp, M. J., & Duncan, J. S. (2015). Factors affecting reorganisation of memory encoding networks in temporal lobe epilepsy. *Epilepsy Research*, *110*, 1–9.
- Smith, S. M. (2002). Fast robust automated brain extraction. *Human Brain Mapping*, *17*, 143–155.
- Stretton, J., Sidhu, M. K., Winston, G. P., Bartlett, P., McEvoy, A. W., Symms, M. R., ... Duncan, J. S. (2014). Working memory network plasticity after anterior temporal lobe resection: A longitudinal functional magnetic resonance imaging study. *Brain*, *137*, 1439–1453. <https://doi.org/10.1093/brain/awu061>
- Stretton, J., Winston, G. P., Sidhu, M., Bonelli, S., Centeno, M., Vollmar, C., ... Duncan, J. S. (2013). Disrupted segregation of working memory networks in temporal lobe epilepsy. *NeuroImage Clinical*, *2*, 273–281.
- Tavor, I., Hofstetter, S., & Assaf, Y. (2013). Micro-structural assessment of short term plasticity dynamics. *NeuroImage*, *81*, 1–7. <https://doi.org/10.1016/j.neuroimage.2013.05.050>

- ten Brinke, L. F., Bolandzadeh, N., Nagamatsu, L. S., Hsu, C. L., Davis, J. C., Miran-Khan, K., & Liu-Ambrose, T. (2015). Aerobic exercise increases hippocampal volume in older women with probable mild cognitive impairment: A 6-month randomised controlled trial. *British Journal of Sports Medicine*, *49*, 248–254. <https://doi.org/10.1136/bjsports-2013-093184>
- Thomas, A. G., Dennis, A., Rawlings, N. B., Stagg, C. J., Matthews, L., Morris, M., ... Johansen-Berg, H. (2016). Multi-modal characterization of rapid anterior hippocampal volume increase associated with aerobic exercise. *NeuroImage*, *131*, 162–170. <https://doi.org/10.1016/j.neuroimage.2015.10.090>
- Trimmel, K., van Graan, A. L., Caciagli, L., Haag, A., Koepp, M. J., Thompson, P. J., & Duncan, J. S. (2018). Left temporal lobe language network connectivity in temporal lobe epilepsy. *Brain*, *141*, 2406–2418. <https://doi.org/10.1093/brain/awy164>
- Voets, N. L., Beckmann, C. F., Cole, D. M., Hong, S., Bernasconi, A., & Bernasconi, N. (2012). Structural substrates for resting network disruption in temporal lobe epilepsy. *Brain*, *135*, 2350–2357. <https://doi.org/10.1093/brain/aws137>
- Voss, M. W., Vivar, C., Kramer, A. F., & van Praag, H. (2013). Bridging animal and human models of exercise-induced brain plasticity. *Trends in Cognitive Sciences*, *17*, 525–544.
- Wiebe, S., Blume, W. T., Girvin, J. P., & Eliasziw, M. (2001). A randomized, controlled trial of surgery for temporal-lobe epilepsy. *New England Journal of Medicine*, *345*, 311–318.
- Winkler, A. M., Ridgway, G. R., Webster, M. A., Smith, S. M., & Nichols, T. E. (2014). Permutation inference for the general linear model. *NeuroImage*, *92*, 381–397. <https://doi.org/10.1016/j.neuroimage.2014.01.060>
- Woollett, K., & Maguire, E. A. (2011). Acquiring “the knowledge” of London’s layout drives structural brain changes. *Current Biology*, *21*, 2109–2114.
- Zatorre, R. J., Fields, R. D., & Johansen-Berg, H. (2012). Plasticity in gray and white: Neuroimaging changes in brain structure during learning. *Nature Neuroscience*, *15*, 528–536. <https://doi.org/10.1038/nn.3045>
- Zhang, Y., Brady, M., & Smith, S. (2001). Segmentation of brain MR images through a hidden Markov random field model and the expectation-maximization algorithm. *IEEE Transactions on Medical Imaging*, *20*, 45–57. <https://doi.org/10.1109/42.906424>

SUPPORTING INFORMATION

Additional supporting information may be found online in the Supporting Information section.

How to cite this article: Pajkert A, Ploner CJ, Lehmann T-N, et al. Early volumetric changes of hippocampus and medial prefrontal cortex following medial temporal lobe resection. *Eur J Neurosci*. 2020;52:4375–4384. <https://doi.org/10.1111/ejn.14784>