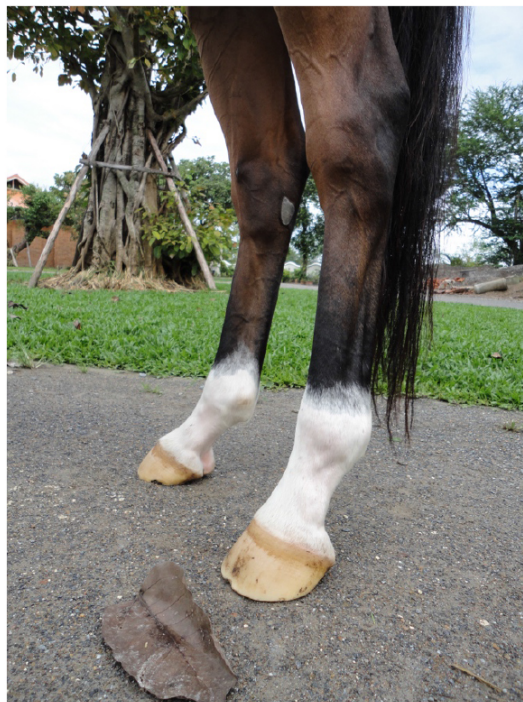

Aus der Klinik für Pferde, Allgemeine Chirurgie und Radiologie,  
des Fachbereichs Veterinärmedizin  
der Freien Universität Berlin

---

**Use of body-mounted inertial sensors to objectively  
evaluate hindlimb lameness and the response to diagnostic  
analgesia of distal tarsal pain in horses**



**Inaugural-Dissertation**  
zur Erlangung des Grades eines  
Doktors der Veterinärmedizin (Dr. med. vet.)  
an der  
Freien Universität Berlin

vorgelegt von  
**Pitiporn Leelamankong**  
Tierärztin aus Chiangmai, Thailand

Berlin 2020  
Journal-Nr.: 4173







**Aus der Klinik für Pferde, Allgemeine Chirurgie und Radiologie,  
des Fachbereichs Veterinärmedizin der Freien Universität Berlin**

**Use of body-mounted inertial sensors to objectively evaluate hindlimb lameness and  
the response to diagnostic analgesia of distal tarsal pain in horses**

**Inaugural-Dissertation  
zur Erlangung des Grades eines  
Doktors der Veterinärmedizin (Dr. med. vet.)  
an der  
Freien Universität Berlin**

**vorgelegt von  
Pitiporn Leelamankong  
Tierärztin aus Chiangmai, Thailand**

Berlin 2020  
Journal-Nr.: 4173

Gedruckt mit Genehmigung des Fachbereichs Veterinärmedizin der Freien Universität Berlin

Dekan: Univ.-Prof. Dr. Jürgen Zentek  
Erster Gutachter: Univ.-Prof. Dr. Christoph Lischer  
Zweiter Gutachter: Prof. Dr. Leo Brunberg  
Dritter Gutachter: Univ.-Prof. Dr. Mahtab Bahramsoltani

Deskriptoren (nach CAB- Thesaurus):

horse, lameness, clinical examination, sensors, evaluation, veterinary practice, analgesics,  
pain, senses, mepivacaine (MeSH), hindlimb (MeSH), lower extremity (MeSH)

Tag der Promotion: 03.02.2020

## Table of Contents

1. Introduction	1
Hindlimb lameness	1
Subjective and objective lameness evaluation	1
Body-mounted inertial system	1
First project of this research study, its aims and hypothesis	2
Second project of this research study, its aims and hypotheses	2
2. Research publications in journals	
2.1 Agreement among equine veterinarians and agreement between equine veterinarians and inertial sensors system during clinical examination of hind limb lameness in horses	5
2.2 Objective evaluation of the response to perineural analgesia of the deep branch of the lateral plantar nerve and intra-articular analgesia of the tarsometatarsal joint in horses with suspected proximal metatarsal pain using body-mounted inertial sensors	12
3. Discussion	18
4. Declaration of own portion of work in the research publications	22
5. Summary	23
6. Zusammenfassung	24
7. References	26
8. List of Abbreviations	30
9. Appendices	31
10. Oral presentation	33
11. List of publications	35
12. Acknowledgements	36
Selbstständigkeitserklärung	37

## 1. Introduction

Lameness is a clinical sign presented as an alteration of gait or “limping”, most commonly due to pain (Baxter, 2011). The essential elements of lameness diagnosis are to assess whether the horse is lame (1), to identify the affected limb(s) (2) and to localise the site of pain (3).

Hindlimb lameness is more challenging to be recognised compared to forelimb lameness (Ross, 2011). The traditional way of assessing hindlimb lameness is to observe the movement of specific anatomical structures of the hindlimb and the pelvis. These include the stride length, fetlock extension while weight bearing, limb abduction and adduction, and vertical movement of hip or pelvis (Buchner et al., 1996; Seeherman, 1999; Kramer et al., 2000; Kaneps, 2004; Baxter, 2011). Among these parameters, asymmetrical movement of tuber coxae and tuber sacrale have been described as the principal points of observation. Several terms have been used to explain the asymmetrical movement such as “hip hike”, “pelvic hike” or “hip drop” depending on the anatomical point and phase of stride being observed. As there is no universal agreement of which term or which description should best represent hindlimb lameness, two clinicians might observe the same thing but refer it differently (Baxter, 2011). Nevertheless, subjective lameness examination performed by equine clinicians are prone to inaccuracy. For hindlimb lameness, the agreement even among experience clinicians was limited in acceptable range (Keegan et al., 2010). Moreover, when a diagnostic analgesia has been performed clinicians would have the tendency of being biased towards the positive result (Arkeel et al., 2006).

Numerous objective methods have been developed in the past decades in order to aid lameness evaluations. Kinetic method measuring ground reaction forces is known to be gold standard for objective lameness evaluation (Dow et al., 1991; Schambardt et al., 1993; McLaughlin et al., 1996; Bertone, 2003; Baxter, 2011). In attempt to measure ground reaction forces, tools such as stationary force plate, treadmill integrated force plate or force measuring horse boot have been used (Weishaupt et al., 2002, Clayton et al., 2000; Dow et al., 1991; Barrey, 1990). However, the disadvantage of force plates, both the stationary and the treadmill instrumented ones, are the fact that they require dedicated setting and are expensive. Force measuring horse boot also put extra, unnatural weight to the horse’s limb. Moreover, kinetic measure outputs are difficult for general practitioners to understand. Alternatively, kinematic methods measuring movement such as high speed camera-based gait analysis or body-mounted inertial sensor system have been widely used (Peloso et al., 1993; Degueurce et al., 1996; Kramer et al., 2000; Keegan et al., 2004). The results from



kinematic measures are in general more intuitive and easier to understand. The advantages of the body-mounted inertial sensor systems over the camera-based gait analysis are their less requirement of equipment, the applicability to clinical setting, and more affordable price.

The body-mounted inertial sensor system (BMISS) used in this thesis has been tested to have adequate accuracy, sufficient repeatability and is capable of quantifying lameness in horses (Keegan et al., 2011; Keegan et al., 2012; McCracken et al., 2012; Maliye et al., 2013; Bell et al., 2016). This system comprises of 3 inertial sensors; one uni-axial accelerometer attached to the poll region, another uni-axial accelerometer placed at pelvis between tubera sacrale, and one gyroscope attached to the dorsal aspect of the right forelimb pastern. The data collected from a trotting horse by 3 inertial sensors is transmitted wirelessly to a portable computer and converted through sophisticated proprietary algorithms into head and pelvic height differences (in millimetres) between right and left halves of stride (Keegan et al., 2004).

This thesis is about the objective evaluation of hindlimb lameness and to measure the effect of different diagnostic analgesia techniques in the lower hock using the BMISS.

The first project investigates the *“Agreement among equine veterinarians and between equine veterinarians and inertial sensor system during clinical examination of hindlimb lameness in horses”*. There have been several studies comparing lameness quantified by the BMISS and equine veterinarians in the past years. These studies investigated different lameness assessment situations such as flexion test, improvement of lameness after diagnostic analgesia of equine foot or lameness identification in experimental situation (Marshall et al., 2012; McCracken et al., 2012; Maliye et al., 2013; Keegan et al., 2013; Rungsri et al.2014a). However, the agreement between the BMISS and equine clinicians from different experience background in identifying hindlimb lameness has not been estimated, nor the agreement between the BMISS and equine clinicians in assessing improvement of hindlimb lameness after diagnostic analgesia. This BMISS is becoming more popular and is supposed to be used as an aid for clinicians in lameness evaluation both in clinical and research situation. Therefore, this project attempted to add the knowledge to the aforementioned gaps. The aims of this first project are 1) to investigate the agreement between equine veterinarians from different experience background and the BMISS in assessing hindlimb lameness, and 2) to estimate the agreement between the BMISS and experienced veterinarians on the change in lameness after a diagnostic analgesia in hindlimbs.

The second project is about *“Objective evaluation of the response to perineural analgesia of the deep branch of the lateral plantar nerve and intra-articular analgesia of the*

*tarsometatarsal joint in horses with suspected proximal metatarsal pain using body-mounted inertial sensors”.*

Hindlimb lameness originating from the distal tarsal and the proximal metatarsal areas are common in horses. Historically osteoarthritis (OA) of the distal tarsal joints has been believed to be the source of pain in most of the hindlimb lame horses (Jackman, 2006; Ross, 2011; Sullins, 2011). Tarsometatarsal joint (TMT) and distal intertarsal joint (DIT) can be affected either individually or together (Dyson and Ross, 2011). In the past decades, proximal suspensory desmopathy (PSD) has also gained recognition as a common cause of hindlimb lameness and can affect sport horses of all disciplines and ages (Dyson, 1994; Brokken et al., 2007; Dyson, 2007). The causes of pain could be the lesion of the suspensory itself, the osseous injury to the third metatarsal bone at the origin of the suspensory ligament, or adhesions between the suspensory ligament and the second, third or fourth metatarsal bones (Labens et al., 2010; Dyson et al., 2017).

Diagnostic analgesia is usually performed in order to locate the site of pain. Perineural analgesia would be conducted starting from distal and working the way up proximal. In this fashion, the site of pain could be determined as the region proximal to where the last negative analgesia and distal to where the positive analgesia have been performed. Intra-articular analgesia is used to rule out localized pain originating from a joint.

To localize lameness caused by PSD the use of the analgesia of the deep branch of lateral plantar nerve (DBLPN block) has been described (Hughes et al., 2007). The DBLPN block is performed after the negative result of the low 6-point block. Whereas the pain caused by OA of TMT and DIT joints could be localized by the use of the intra-articular analgesia. The injection techniques for both joints have been well described (Bassage and Ross, 2011; Baxter, 2011). The precision of the DIT joint injection has been reported to be much lower than the TMT joint (Seabaugh et al., 2017). The intra-articular analgesia of the TMT joint alone is more often performed in clinical practice as; 1) the communication between these 2 joints is believed to be around 30% (Jackman, 2006) and, 2) the diffusion of the anesthetics between these 2 joints occurs nearly in 90% of the cases (Gough et al., 2002).

Nevertheless, the challenge of diagnostic analgesia is that the adjacent structures to the injecting sites could also be anesthetised. This could be due to the diffusion of the anaesthetic agent or the inadvertent placement of the needle. The results from previous studies show that anaesthetic agent and contrast media could be found in the tarsal sheath and the TMT joint after being deposited around the deep branch of lateral plantar nerve (Hughes et al., 2007; Claunch et al., 2014; Contino et al., 2015,). Similarly, in the study where contrast

media was injected in the TMT joint the potential distribution of contrast media out of the plantar outpouching was described (Dyson and Romero, 1993). This result suggested the ability of the TMT block to desensitize structures at the proximal plantar metatarsal region including proximal suspensory ligament.

After all, the effects of these 2 local analgesia techniques in terms of the lameness improvement has never been compared objectively. This project aims to utilize the BMISS as a bias-free, objective method to measure the lameness improvement after the deep branch of lateral plantar nerve analgesia and the tarsometatarsal joint analgesia in clinical cases.

## **2. Research publication in journals**

### **2.1 Agreement among equine veterinarians and between equine veterinarians and inertial sensor system during clinical examination of hindlimb lameness in horses**

Authors: Leelamankong Pitiporn, Estrada Roberto, Mählmann Kathrin, Rungsri Porrakote, Lischer Christoph

Journal: Equine Veterinary Journal, 52(2020), 326-331

**Please read this part online**

DOI: <https://doi.org/10.1111/evj.13144>

© 2019 EVJ Ltd

**2.2 Objective evaluation of the response to perineural analgesia of the deep branch of the lateral plantar nerve and intra-articular analgesia of the tarsometatarsal joint in horses with suspected proximal metatarsal pain using body-mounted inertial sensors**

Authors: Leelamankong Pitiporn, Stäcker Wolfgang, Rungsri Porrakote, Estrada Roberto, Carolin Müller, Lischer Christoph

Journal: Journal of Equine Veterinary Science, 70(2018), 91-95

**Please read this part online**

DOI: <https://doi.org/10.1016/j.jevs.2018.07.004>

### 3. Discussion

This dissertation aimed to assess hindlimb lameness evaluation especially improvement of lameness after diagnostic analgesia using an objective method. The body-mounted inertial sensor system (BMISS) used in this dissertation has been tested to be capable of quantifying lameness (Keegan et al., 2004; McCracken et al., 2012) in horses with sufficient repeatability (Keegan et al., 2011) as well as identifying change of lameness after manipulation such as flexion test and diagnostic analgesia (Marshall et al., 2012; Maliye et al., 2013).

In the first study, agreement was higher between the live clinicians than for those who evaluated videos for both interobserver agreement and the agreement between veterinarians and the BMISS. The agreement was calculated using Fleiss' Kappa statistics and the strength of agreement was estimated using the benchmark scale ranges from poor, slight, fair, moderate, substantial to almost perfect (Landis and Koch, 1977). For the veterinarians who evaluated the videos, the interobserver agreement were all just in "fair" strength for high experience, moderate experience, and inexperience group. For the agreement between the veterinarians and the BMISS, the agreement was highest in the high experience group and lowest in the inexperience group. Nevertheless, when looking at the agreement between the BMISS and each individual veterinarian, some experience veterinarians had lower agreement with the BMISS than the those with less experience. These results emphasised the challenge of lameness examination even for experienced equine veterinarians.

Assessing lameness from video records should be done carefully, since the study showed that the agreement from the clinicians in live situation were higher than those who viewed videos. Controversially, when evaluating the improvement of lameness after diagnostic analgesia also from video records, the experienced veterinarians had strong agreement with the BMISS. The similar findings were also yielded in the forelimb lameness study from Rungsri et al. (2014b) which had the same study protocol and condition. It could be said that the lameness evaluation from video record is not as reliable as in live situation. However, series of video records should be useful for assessing change of lameness over a period of time.

The advantages of the BMISS over human are the bias free assessment and the higher sampling frequency. In the first study, the agreement between the BMISS and the high experience group for determining hindlimb lameness was higher than those with lower experience. This result supports the statement about the reliability of the BMISS. Despite the potential difficulty of the video assessment, the agreement between high experience veterinarians and the BMISS in evaluating improvement of lameness after analgesia was strong. This also emphasises the ability of the BMISS in identifying change of lameness after

diagnostic analgesia. In the same time, these results should encourage the use of video in order to record the change of lameness in the same patient over a period of time.

Nevertheless, the use of BMISS also has some limitations. First, horses with bilateral lameness would be identified as sound when lameness of both limbs are in the same severity. Second, interpretation of clinical importance of hindlimb lameness improvement is not straight forward. This is due to the separate calculation of 2 lameness parameters. Third, the interpretation of lameness improvement in lunging trials is not fully understood.

In the second study, the response of hindlimb lameness to the DBLPN block and the TMT block in horses with suspected lower hock pain were compared. It was hypothesized that the improvement of lameness parameters after the DBLPN block would be significantly different than after the TMT block in the selected horses. From the results, 63% of the horses showed the significant difference between improvement of lameness after the DBLPN block and the TMT block. In this group of horses, lameness had improved only after the DBLPN block, but not after the TMT block. These results suggest that in this horse population, the source of pain arose from the proximal metatarsal area rather than distal tarsal joints and that the anesthetic agent injected after the DBLPN block apparently did not diffuse to the TMT joint. The precision of the DBLPN block to anaesthetize the DBLPN is a controversial topic. Even though Hughes et al. (2007) reported a high accuracy in a cadaveric study, other studies suggest that the local diffusion might anesthetize other nerves like the lateral plantar nerve and other structures like the distal tarsal joint and the tarsal sheath (Claunch et al., 2014; Contino et al., 2015). Even though this block is not as specific as expected, it seems to be able to localize pain in the subtarsal region. Theoretically, the effect of the DBLPN block in anaesthetizing pain from the more distal part of the limb could be ruled out by having previously performed the low 6-point block. Based on our results, blocking the TMT on a separate day from the DBLPN might also help to differentiate the origin of the pain. In this context, the clinician should also take into account that a blocking pattern presenting a positive DBLPN and a negative TMT is not specific for suspensory ligament pathologies and might also involve other soft tissue structures in the subtarsal region.

Contrastingly, in the other 37% of the horses, lameness had improved after both the DBLPN block and the TMT block. Several reasons could explain the aforementioned response, the distal tarsal joints could be penetrated while performing the DBLPN block (Claunch et al., 2014; Contino et al., 2015). Another possible cause could be the improvement of lameness resulted from the proximal diffusion of the anesthetic agent after the DBLPN block and the inadvertent desensitization of other structures. The study from Claunch et al. (2014) demonstrated that a greater volume of contrast medium could diffuse significantly further in both proximal and distal direction compare to a smaller volume (Claunch et al.,

2014). The volume of 5 ml mepivacaine ( Baxter, 2011; Meehan, 2016) is more than the volume recommended by the others (Bassage and Ross, 2011, Dyson, 2007). This is likely to lead to less specificity of the DBLPN block in our study. Labens et al. (2010) reported that anesthesia of the DBLPN is not specific either for lesions of the origin of the suspensory ligament (as other pathologies were diagnosed), or for conditions in the proximal metatarsal region since pathologies were diagnosed outside of this region. Diffusion of the anesthetic agent out of the distal outpouching of the TMT joint could be another possible explanation for what was observed in the second group. Proximal diffusion has been previously suggested by a study in which the distribution of contrast media was observed around the proximal plantar metatarsal area as soon as 5 minutes after injecting the TMT (Dyson and Romero, 1993). Lastly, concurrent pathologies of the proximal suspensory ligament and the distal tarsal joints including osteoarthritis are as previously reported (Labens et al., 2007).

The first limitation of the second study was the fact that the true distribution of the anesthetics could not be documented. In order to study the distribution, the anesthetics could have been mixed with contrast media and radiograph could have been performed. Since the horses had to be trotted, at the certain minutes after the analgesia, sedation was not the choice and radiography would therefore not be possible in every horse. The second limitation is the lack of the definitive diagnosis. The imaging modalities used in this study were restricted to sonography and radiography. The results from diagnostic imaging were inconsistent with the results from diagnostic analgesia as presented in Appendix, table 1. This is not unexpected since both aforementioned modalities are not as sensitive as advanced medical imaging in diagnosing proximal metatarsal and tarsal lesions. The third limitation was the fact that lunging trials on the soft ground could not be used. As previously mentioned, the interpretation of the lameness parameters for soft ground trials especially the change to these parameters in response to improvement of lameness is to-date not fully validated. It is possible that cases presenting subtle lameness, only observed during lunging, might have been excluded.

After all, the results from both studies emphasize that the BMISS is an excellent tool to aid lameness examination but this system cannot substitute the opinion of an experienced equine veterinarian.



#### 4. Declaration of own portion of work in the research publications

##### **Agreement among equine veterinarians and agreement between equine veterinarians and inertial sensors system during clinical examination of hind limb lameness in horses**

Authors: Leelamankong Pitiporn, Estrada Roberto, Mählmann Kathrin, Rungsri Porrakote, Lischer Christoph

Year: 2020

Journal: Equine Veterinary Journal, 52(2020), 326-331

	Leelamankong	Estrada	Mählmann	Rungsri	Lischer
Study design	40%	-	-	30%	30%
Data collection and study execution	50%	10%	-	30%	10%
Data analysis And interpretation	80%	-	-	10%	10%
Preparation of the manuscript	70%	10%	10%	-	10%

**Objective evaluation of the response to perineural analgesia of the deep branch of the lateral plantar nerve and intra-articular analgesia of the tarsometatarsal joint in horses with suspected proximal metatarsal pain using body-mounted inertial sensors**

Authors: Leelamankong Pitiporn, Stäcker Wolfgang, Rungsri Porrakote, Estrada Roberto, Carolin Müller, Lischer Christoph

Year: 2018

Journal: Journal of Equine Veterinary Science, 70(2018), 91-95

	Leelamankong	Stäcker	Rungsri	Estrada	Müller	Lischer
Study design	35%	15%	10%	5%	-	35%
Data collection	70%	10%	10%	10%	-	-
Study execution	50%	10%	20%	10%	-	10%
Data analysis And interpretation	60%	-	-	10%	10%	20%
Preparation of the manuscript	60%	5%	5%	10%	-	20%

## 5. Summary

The ability to recognize movement pattern of lame horses accurately, requires practice and experience from equine clinicians. Hindlimb lameness evaluation is known to be more difficult than the forelimb counterpart. Even among experienced veterinarians agreement in hind limb lameness evaluation was only reported to be in acceptable range. This leads to the potential inaccuracy of subjective assessment of diagnostic analgesia. Moreover, veterinarians as subjective individuals are prone to bias. Therefore, numeral objective lameness measuring methods have been developed in the past decades in order to aid veterinarians. The objective system used in this study is a body-mounted inertial sensor system (BMISS) which has been proved to have adequate accuracy and sufficient repeatability.

In the first study, the agreement among veterinarians (interobserver agreement) and the agreement between veterinarians and the BMISS have been investigated. The results emphasised that hindlimb lameness examination is challenging even for experienced equine veterinarians. The BMISS showed to have high agreement with clinicians in clinical live situation when evaluating hindlimb lameness, and with a group of highly experienced veterinarians when assessing the changes after diagnostic analgesia. These results should encourage the use of the BMISS as an aid in lameness examination.

The second study has taken the benefits of the BMISS as a bias-free objective method to evaluate improvement of lameness after the analgesia of the deep branch of lateral plantar nerve (DBPLN) and the analgesia of the tarsometatarsal joint (TMT)-in horses with suspected pain in the lower hock area. In 63% of the horses with suspected lower hock pain an improvement of lameness was observed after the analgesia of the DBPLN, but not after the analgesia of the TMT. Based on this result, the analgesia of the DBPLN did desensitise a different source of pain than the TMT analgesia. However, in the other 37% of the horses lameness improved after both analgesia. Therefore, it was not possible to differentiate source of lameness in this second group of horses. There are several possible explanations for the different pattern of lameness improvement in the 2 groups such as diffusion of anesthetic agent, inadvertent placement of the needle or concurrent pathologies. Nevertheless, since sonography and radiography were only the imaging modalities used in this study, it is still an open question what the exact cause of lameness was. In order to gain more understanding about the pathologies and improvement of lameness after these analgesia, similar studies using more advanced imaging modalities such as MRI or scintigraphy should be performed.

## 6. Zusammenfassung

### **Anwendung eines mittels Trägheitssensoren arbeitenden Lahmheitsuntersuchungssystems zur Evaluierung von Hinterhandlahmheit und zur Beurteilung der Ergebnisse der diagnostischen Anästhesie bei Pferden mit Schmerzen im Bereich des distalen Sprunggelenkes**

Bewegungsmuster lahmer Pferde genau zu erkennen, erfordert viel Übung und Erfahrung. Die Untersuchung von Lahmheiten der Hinterhand ist bekanntermaßen deutlich schwieriger als die von Lahmheiten der Vorderhand. Die Übereinstimmung der Untersuchung war bisher auch zwischen erfahrenen Tierärzten bestenfalls akzeptabel. Dies führt potentiell zu Ungenauigkeiten bei der Beurteilung von Effekten einer diagnostischen Analgesie. Tierärzte als subjektive Individuen neigen darüber hinaus zu Voreingenommenheit bei der Erkennung von Lahmheiten. Zur Unterstützung der Lahmheitsbeurteilung von Pferden wurden in den letzten Jahren numerische, objektive Messmethoden entwickelt. In dieser Studie wurde ein sensorgestütztes Untersuchungssystem (BMISS, body-mounted inertial sensor system) verwendet, bei welchem die Validierung eine ausreichende Genauigkeit und Wiederholbarkeit der Messungen ergab.

Die erste Studie untersuchte vergleichend die Übereinstimmung zwischen Tierärzten (interobserver agreement) sowie die Übereinstimmung zwischen Tierärzten und den Daten, die mittels BMISS erhoben wurden. Die Ergebnisse haben die Schwierigkeit einer Lahmheitsuntersuchung der Hinterhand selbst für Spezialisten erneut hervorgehoben. Das BMISS zeigte eine hohe Übereinstimmung sowohl mit Tierärzten bei der klinischen Lahmheitsuntersuchung als auch mit erfahrenen Spezialisten bei der Beurteilung von Videoaufnahmen die das Pferd vor und nach einer diagnostischen Anaesthetie zeigen. Die Resultate unterstützen die Anwendung des BMISS bei der Lahmheitsuntersuchung von Pferden.

In der zweiten Studie wurde die objektiven Messmethode (BMISS) verwendet, um zwei verschiedene diagnostische Anaesthetien zu vergleichen, die häufig bei Pferden mit Verdacht auf Schmerzen im Bereich des distalen Sprunggelenkes angewendet werden.

Bei 63 % der Pferde wurde eine Verbesserung der Lahmheit nach der Anästhetie des tiefen Astes des Nervus plantaris lateralis, jedoch nicht nach der Analgesie des Tarsometatarsalgelenkes festgestellt. Diese Resultate suggerieren, dass die Anaesthetie des tiefen Astes des Nervus plantaris lateralis und die Anaesthetie des Tarsometatarsalgelenkes unterschiedliche Gewebe im Bereich des distalen Sprunggelenkes anaesthetisieren. Bei 37 % der Pferde verbesserte sich die Lahmheit gleichermassen nach

beiden diagnostischen Anaesthesien. In dieser zweiten Gruppe war daher keine klare Differenzierung des Schmerzursprungs möglich. Ursachen für die unterschiedlichen Ausprägungen der Verbesserung der Lahmheit sind beispielsweise die Diffusion des Anästhetikums, eine fehlerhafte Platzierung der Injektionskanüle oder gleichzeitiges Auftreten verschiedener Pathologien. Da im Rahmen dieser Studie ausschließlich Sonographie und Radiologie zur bildgebenden Diagnostik genutzt wurden, blieb die exakte Ursache der Lahmheit offen. Für ein genaueres Verständnis der Pathologien und Verbesserungen der Lahmheit wären ähnliche Studien mit präziseren bildgebenden Verfahren, wie MRT oder Szintigraphie, erforderlich.

## 7. References

- ARKELL, M., ARCHER, R. M., GUITIAN, F. J. & MAY, S. A. 2006. Evidence of bias affecting the interpretation of the results of local anaesthetic nerve blocks when assessing lameness in horses. *Vet Rec*, 159, 346-9.
- BARREY, E. 1990. Investigation of the vertical hoof force distribution in the equine forelimb with an instrumented horseboot. *Equine Vet J Suppl*, 35-8.
- BASSAGE II, L. H. & ROSS, M. W. 2011. Chapter 10 - Diagnostic Analgesia. *Diagnosis and Management of Lameness in the Horse (Second Edition)*. Saint Louis: W.B. Saunders.
- BAXTER, G. M. 2011. Chapter 3 - Examination of lameness. *Adams and Stashak's lameness in horses (Sixth Edition)*. Wiley.
- BELL, R. P., REED, S. K., SCHOONOVER, M. J., WHITFIELD, C. T., YONEZAWA, Y., MAKI, H., PAI, P. F. & KEEGAN, K. G. 2016. Associations of force plate and body-mounted inertial sensor measurements for identification of hind limb lameness in horses. *Am J Vet Res*, 77, 337-45.
- BERTONE, A. L. 2003. Chapter 22 - Gait Analysis for the Quantification of Lameness. In: ROSS, M. W. & DYSON, S. J. (eds.) *Diagnosis and Management of Lameness in the Horse*. Saint Louis: W.B. Saunders.
- BROKKEN, M. T., SCHNEIDER, R. K., SAMPSON, S. N., TUCKER, R. L., GAVIN, P. R. & HO, C. P. 2007. Magnetic resonance imaging features of proximal metacarpal and metatarsal injuries in the horse. *Vet Radiol Ultrasound*, 48, 507-17.
- BUCHNER, H. H., SAVELBERG, H. H., SCHAMHARDT, H. C. & BARNEVELD, A. 1996. Limb movement adaptations in horses with experimentally induced fore- or hindlimb lameness. *Equine Vet J*, 28, 63-70.
- CLAUNCH, K. M., EGGLESTON, R. B. & BAXTER, G. M. 2014. Effects of approach and injection volume on diffusion of mepivacaine hydrochloride during local analgesia of the deep branch of the lateral plantar nerve in horses. *J Am Vet Med Assoc*, 245, 1153-9.
- CLAYTON, H. M., SCHAMHARDT, H. C., WILLEMEN, M. A., LANOVAZ, J. L. & COLBORNE, G. R. 2000. Kinematics and ground reaction forces in horses with superficial digital flexor tendinitis. *Am J Vet Res*, 61, 191-6.
- CONTINO, E. K., KING, M. R., VALDES-MARTINEZ, A. & MCILWRAITH, C. W. 2015. In vivo diffusion characteristics following perineural injection of the deep branch of the lateral plantar nerve with mepivacaine or iohexol in horses. *Equine Vet J*, 47, 230-4.
- DEGUEURCE, C., DIETRICH, G., POURCELOT, P., DENOIX, J. M. & GEIGER, D. 1996. Three-dimensional kinematic technique for evaluation of horse locomotion in outdoor conditions. *Med Biol Eng Comput*, 34, 249-52.
- DOW, S. M., LEENDERTZ, J. A., SILVER, I. A. & GOODSHIP, A. E. 1991. Identification of subclinical tendon injury from ground reaction force analysis. *Equine Vet J*, 23, 266-72.
- DYSON, S. J. & ROMERO, J. M. 1993. An investigation of injection techniques for local analgesia of the equine distal tarsus and proximal metatarsus. *Equine Vet J*, 25, 30-5.

- DYSON, S. 1994. Proximal suspensory desmitis in the hindlimb: 42 cases. *Br Vet J*, 150, 279-91.
- DYSON, S. 2007. Diagnosis and management of common suspensory lesions in the forelimbs and hindlimbs of sport horses. *Clinical techniques in equine practice*, 6, 179-188.
- DYSON, S. J. & ROSS, M. W. 2011. Chapter 44 - The Tarsus. *Diagnosis and Management of Lameness in the Horse (Second Edition)*. Saint Louis: W.B. Saunders.
- DYSON, S., MURRAY, R. & PINILLA, M. J. 2017. Proximal suspensory desmopathy in hindlimbs: A correlative clinical, ultrasonographic, gross post mortem and histological study. *Equine Vet J*, 49, 65-72.
- GOUGH, M. R., MUNROE, G. A. & MAYHEW, G. 2002. Diffusion of mepivacaine between adjacent synovial structures in the horse. Part 2: tarsus and stifle. *Equine Vet J*, 34, 85-90.
- HUGHES, T. K., ELIASHAR, E. & SMITH, R. K. 2007. In vitro evaluation of a single injection technique for diagnostic analgesia of the proximal suspensory ligament of the equine pelvic limb. *Vet Surg*, 36, 760-4.
- JACKMAN, B. R. Review of equine distal hock inflammation and arthritis. Proceedings of the 52th Annual American Association of Equine Practitioners Convention, 2006 Texas, USA. American Association of Equine Practitioners, 2006, 5-12.
- KANEPS, A. J. 2004. Chapter 14 - Diagnosis of lameness. *Equine sports medicine and surgery. Basic and clinical sciences of the equine athlete*. St.Louis, MO: Saunders.
- KEEGAN, K. G., YONEZAWA, Y., PAI, P. F., WILSON, D. A. & KRAMER, J. 2004. Evaluation of a sensor-based system of motion analysis for detection and quantification of forelimb and hind limb lameness in horses. *Am J Vet Res*, 65, 665-70.
- KEEGAN, K. G., DENT, E. V., WILSON, D. A., JANICEK, J., KRAMER, J., LACARRUBBA, A., WALSH, D. M., CASSELLS, M. W., ESTHER, T. M., SCHILTZ, P., FREES, K. E., WILHITE, C. L., CLARK, J. M., POLLITT, C. C., SHAW, R. & NORRIS, T. 2010. Repeatability of subjective evaluation of lameness in horses. *Equine Vet J*, 42, 92-7.
- KEEGAN, K. G., KRAMER, J., YONEZAWA, Y., MAKI, H., PAI, P. F., DENT, E. V., KELLERMAN, T. E., WILSON, D. A. & REED, S. K. 2011. Assessment of repeatability of a wireless, inertial sensor-based lameness evaluation system for horses. *Am J Vet Res*, 72, 1156-63.
- KEEGAN, K. G., MACALLISTER, C. G., WILSON, D. A., GEDON, C. A., KRAMER, J., YONEZAWA, Y., MAKI, H. & PAI, P. F. 2012. Comparison of an inertial sensor system with a stationary force plate for evaluation of horses with bilateral forelimb lameness. *Am J Vet Res*, 73, 368-74.
- KEEGAN, K. G., WILSON, D. A., KRAMER, J., REED, S. K., YONEZAWA, Y., MAKI, H., PAI, P. F. & LOPES, M. A. 2013. Comparison of a body-mounted inertial sensor system-based method with subjective evaluation for detection of lameness in horses. *Am J Vet Res*, 74, 17-24.
- KRAMER, J., KEEGAN, K. G., WILSON, D. A., SMITH, B. K. & WILSON, D. J. 2000. Kinematics of the hind limb in trotting horses after induced lameness of the distal intertarsal and tarsometatarsal joints and intra-articular administration of anesthetic. *Am J Vet Res*, 61, 1031-6.

- LABENS, R., INNOCENT, G. T. & VOUTE, L. C. 2007. Reliability of a quantitative rating scale for assessment of horses with distal tarsal osteoarthritis. *Vet Radiol Ultrasound*, 48, 204-11.
- LABENS, R., SCHRAMME, M. C., ROBERTSON, I. D., THRALL, D. E. & REDDING, W. R. 2010. Clinical, magnetic resonance, and sonographic imaging findings in horses with proximal plantar metatarsal pain. *Vet Radiol Ultrasound*, 51, 11-8.
- LANDIS, J. R. & KOCH, G. G. 1977. The measurement of observer agreement for categorical data. *Biometrics*, 33, 159-74.
- MALIYE, S., VOUTE, L., LUND, D. & MARSHALL, J. F. 2013. An inertial sensor-based system can objectively assess diagnostic anaesthesia of the equine foot. *Equine Vet J Suppl*, 26-30.
- MARSHALL, J. F., LUND, D. G. & VOUTE, L. C. 2012. Use of a wireless, inertial sensor-based system to objectively evaluate flexion tests in the horse. *Equine Vet J Suppl*, 8-11.
- MCCRACKEN, M. J., KRAMER, J., KEEGAN, K. G., LOPES, M., WILSON, D. A., REED, S. K., LACARRUBBA, A. & RASCH, M. 2012. Comparison of an inertial sensor system of lameness quantification with subjective lameness evaluation. *Equine Vet J*, 44, 652-6.
- MCLAUGHLIN, R. M., JR., GAUGHAN, E. M., ROUSH, J. K. & SKAGGS, C. L. 1996. Effects of subject velocity on ground reaction force measurements and stance times in clinically normal horses at the walk and trot. *Am J Vet Res*, 57, 7-11.
- MEEHAN, L. L., R. 2016. Diagnosing desmitis of the origin of the suspensory ligament. *Equine Veterinary Education*, 28, 335-343.
- PELOSO, J. G., STICK, J. A., SOUTAS-LITTLE, R. W., CARON, J. C., DECAMP, C. E. & LEACH, D. H. 1993. Computer-assisted three-dimensional gait analysis of amphotericin-induced carpal lameness in horses. *Am J Vet Res*, 54, 1535-43.
- ROSS, M. W. 2011. Chapter 2 - Lameness in Horses: Basic Facts Before Starting. *Diagnosis and Management of Lameness in the Horse (Second Edition)*. Saint Louis: W.B. Saunders.
- RUNGSRI, P. K., STAECKER, W., LEELAMANKONG, P., ESTRADA, R. J., SCHULZE, T. & LISCHER, C. J. 2014. Use of Body-Mounted Inertial Sensors to Objectively Evaluate the Response to Perineural Analgesia of the Distal Limb and Intra-articular Analgesia of the Distal Interphalangeal Joint in Horses With Forelimb Lameness. *Journal of Equine Veterinary Science*, 34, 972-977.
- RUNGSRI, P., STAECKER, W., LEELAMANKONG P., ESTRADA R, RETTIG M., KLAUS C. & LISCHER C. 2014. Agreement between a body-mounted inertial sensors system and subjective observational analysis when evaluating lameness degree and diagnostic analgesia response in horses with forelimb lameness. *Pferdeheilkunde*, 30, 633-650.
- SCHAMBARDT, H. C., MERKENS, H. W., VOGEL, V. & WILLEKENS, C. 1993. External loads on the limbs of jumping horses at take-off and landing. *Am J Vet Res*, 54, 675-80.
- SEABAUGH, K. A., SELBERG, K. T., MUELLER, P. O. E., EGGLESTON, R. B., PERONI, J. F., CLAUNCH, K. M., MARKWELL, H. J. & BAXTER, G. M. 2017. Clinical study evaluating the accuracy of injecting the distal tarsal joints in the horse. *Equine Vet J*, 49, 668-672.



SEEHERMAN, H. J. 1999. Chapter 64 - Lameness Evaluation *In: AUER, J. A. (ed.) Equine Surgery (Second Edition)*. Philadelphia: Saunders.

SULLINS, K. N. 2011. The Tarsus and Tibia. *Adams & Stashak's Lameness in Horses (Sixth Edition)*. Chichester: Wiley.

WEISHAUPT, M. A., HOGG, H. P., WIESTNER, T., DENOTH, J., STUSSI, E. & AUER, J. A. 2002. Instrumented treadmill for measuring vertical ground reaction forces in horses. *Am J Vet Res*, 63, 520-7.

## 8. List of abbreviations

AAEP	American Association of Equine Practitioners
BMISS	Body-Mounted Inertial Sensor System
DIT	Distal intertarsal joint
DBLPN	Deep branch of lateral plantar nerve
et al.	et alii (Latin for „and others“)
HE	high experience
IE	inexperience
K	Kappa
ME	moderate experience
mL	millilitre
NA	not available
OA	osteoarthritis
PSD	proximal suspensory desmopathy
Pmax	mean maximum pelvic height difference
Pmin	mean minimum pelvic height difference
SL	suspensory ligament
TMT	Tarsometatarsal joint

## 9. Appendices

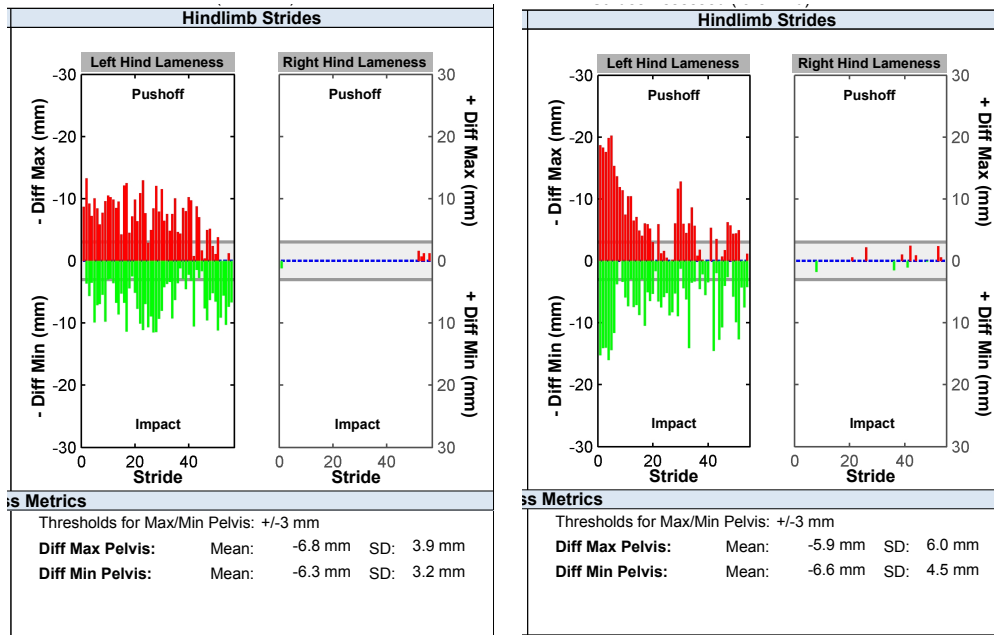
### Appendix 1



Figure 1: A horse instrumented with the 3 inertial sensors consisting of 1) accelerometer at the poll, 2) accelerometer at the pelvis and 3) gyroscope at the right fore pastern.

## Appendix 2

Figure 2: an output of the BMISS hindlimb parameters at baseline (a), and after a DBLPN analgesia (b).



(a)

(b)

## 10. Oral presentation

### Previously published abstract

Presented in scientific programme at the 2<sup>nd</sup>. International Congress of the German Equine Veterinary Association Specialist sub-division Equine Diseases of the German Veterinary Medical Society

Estrel Convention Center Berlin Germany, October 28-29, 2016

---

#### **USE OF BODY-MOUNTED INERTIAL SENSORS TO OBJECTIVELY EVALUATE THE RESPONSE TO PERINEURAL ANALGESIA OF THE DEEP BRANCH OF LATERAL PLANTAR NERVE AND INTRA-ARTICULAR ANALGESIA OF THE TARSOMETATARSAL JOINT IN HORSES WITH LOWER HOCK PAIN**

Leelamankong Pitiporn<sup>1</sup>, Stäcker Wolfgang<sup>1</sup>, Rungsri Porrakote<sup>1,2</sup>, Estrada Roberto<sup>1,3</sup>, Lischer Christoph<sup>1</sup>

Equine Clinic, Faculty of Veterinary Medicine, Free University of Berlin, Berlin, Germany<sup>1</sup>; Department of Companion Animal and Wildlife, Faculty of Veterinary Medicine, Chiang Mai University, Thailand<sup>2</sup>; Large Animal Hospital, School of Veterinary Medicine, National University, Heredia, Costa Rica<sup>3</sup>

#### Abstract

Diagnostic analgesia of the deep branch of lateral plantar nerve (DBLPN) and the tarsometatarsal joint (TMT) are commonly used for differentiating pain originating from lower hock in horses. However, recent studies suggest DBLPN block can cause inadvertent injection of the tarsometatarsal joint and tarsal sheath, where potential diffusion of anesthetic agent from TMT block might anesthetise proximal metatarsal region. The aim of the study was to objectively assess the effect of both diagnostic analgesia techniques on naturally occurring hindlimb lameness using a body-mounted inertial sensor system.

Two pelvic parameters indicating hindlimb lameness (mean pelvic height maximum and minimum differences between right and left hindlimb strides) were used for objective analysis. Horses which had improvement of hindlimb lameness after DBLPN were selected for the study to undergo TMT on the following day.

Thirty-six horses were included in the study. Eighteen (18/36) horses had improvement after DBLPN block but not after TMT block. The other 18 horses had improvement of lameness after both DBLPN and TMT block. In this second group, lameness in 7 horses was abolished after DBLPN and was either improved or abolished after TMT block. In 3 horses the Low 6 –

point and DBLPN abolished lameness, while TMT also almost abolished lameness in 2, and partially alleviated lameness in 1 horse.

DBLPN and TMT desensitized different structures in at least half of the horses in our study. However, possibility of both analgesia in desensitizing same structures due to either diffusion of anesthetic agent or inadvertent injection still remains.

## 11. List of publications

- I. Leelamankong, P., Estrada, R., Mählmann, K., Rungsri., Lischer, C. 2019. Agreement among equine veterinarians and between equine veterinarians and inertial sensor system during clinical examination of hindlimb lameness in horses. *Equine Vet Journal*, 52, 326-331.
- II. LEELAMANKONG, P., ESTRADA, R. J., RUNGSRI, P., WOLFGANG, S., MÜLLER, C. D. V. S. & LISCHER, C. J. 2018. Objective Evaluation of the Response to Perineural Analgesia of the Deep Branch of the Lateral Plantar Nerve and Intraarticular Analgesia of the Tarsometatarsal Joint in Horses With Suspected Proximal Metatarsal Pain Using Body-Mounted Inertial Sensors. *Journal of Equine Veterinary Science*, 70, 91-95.

## 12. Acknowledgements

This dissertation would not have been completed without these following people who have contributed to it in some way.

First of all, I would to express my gratitude to Professor Christoph Lischer, my supervisor, for the given opportunity, great advice and patience.

For the great part of data collection, I do owe a big a thank to the orthopedic team of the clinic for horses, Freie Universität Berlin; Dr. Christoph Klaus, Dr. Wolfgang Stäcker, Dr. Matthias Rettig, Dr. Bettina Rheiner, Dr. Wiebke Schröder, Dr. Sarah Jones, Dr. Carolin Müller, Dr. Svenja Rheinfeld, Dr. Meike Rapp, Natalia Dziubinsky, and Stephan Ostrowski. This particularly refers to the dedication of their free time to evaluate numerous videos used in this study. Many thanks also to the grooms who helped in handling horses and the owners for their consents.

I would also like to thank Dr. Porrakote Rungsri and Dr. Roberto Estrada, my coauthors, who have given advice and encouragement, and occasionally have poked, pushed, and pulled me towards the end of the study.

Thanks to Vasiliki Kathrinaki and Suphannika Phutthachalee for part of data collection through the operation of the Lameness Locator<sup>®</sup> and above all their friendship.

Deep appreciation to Dr. Chumnan Trinarong, former head of the Equine Clinic, Chiangmai University Thailand, who has taught me a great deal about horses and their spirits, as well as to Mr. Kenneth Cullen, my childhood English teacher, who not only gave me suggestion about English writing and but also lots of encouragements.

Many thanks to Maneenooch Khiao-in for always listening to my complaints and for her best friendship.

All the same to Fabian Riedel, my boyfriend, who is always there in the times of desperation and reveals his joys to every small step of my progression.

Last but not least, I would like to thank my family, especially my father, Dr. Prateep, and my mother, Pohnpen Leelamankong for their great love, endless supports, and understanding. It was from them that I have learned to be gentle towards this world and its creatures in the first place.



### **13. Selbstständigkeitserklärung**

Hiermit bestätige ich, dass ich die vorliegende Arbeit selbstständig angefertigt habe. Ich versichere, dass ich ausschließlich die angegebenen Quellen und Hilfen in Anspruch genommen habe.

Berlin, den 03.02.2020

Pitiporn Leelamankong









