

Functional Implications of LH/hCG Receptors in Pregnancy-Induced Cushing Syndrome

Ursula Plöckinger,¹ Marcin Chrusciel,² Milena Doroszko,² Wolfgang Saeger,³
 Oliver Blankenstein,⁴ Katharina Weizsäcker,⁵ Matthias Kroiss,⁷
 Kathrin Hauptmann,⁶ Cornelia Radke,⁸ Alexander Pöllinger,¹⁰ Nikolaus Tiling,¹
 Thomas Steinmüller,⁹ Ipo Huhtaniemi,^{2,11} Marcus Quinkler,¹²
 Jerome Bertherat,¹³ André Lacroix,¹⁴ and Nafis Rahman^{2,15}

¹Interdisciplinary Center of Metabolism: Endocrinology, Diabetes and Metabolism, Charité University Medicine Berlin, 13353 Berlin, Germany;

²Department of Physiology, Institute of Biomedicine, 20520 Turku, Finland;

³Institute of Pathology, University of Hamburg, 2000 Hamburg, Germany;

⁴Labor Berlin-Charité Vivantes GmbH, 13353 Berlin, Germany;

⁵Department of Obstetrics and ⁶Institute of Pathology, Charité University Medicine Berlin, 10117 Berlin, Germany;

⁷Endocrine and Diabetes Unit, Department of Internal Medicine I, University of Würzburg, 97080 Würzburg, Germany;

⁸Institute of Pathology and ⁹Department of Surgery, DRK Kliniken Berlin, 12559 Berlin, Germany;

¹⁰Department of Radiology, Inselspital, Bern University Hospital, 3010 Bern, Switzerland;

¹¹Faculty of Medicine, Department of Surgery and Cancer, Imperial College London, London W12 0NN, United Kingdom;

¹²Endocrinology in Charlottenburg, 10627 Berlin, Germany;

¹³Service d'Endocrinologie, Hôpital Cochin, 75014 Paris, France;

¹⁴Division of Endocrinology, Department of Medicine, Centre Hospitalier de l'Université de Montréal, Montreal, Quebec H2W 1T8 Canada; and

¹⁵Medical University of Białystok, 15001 Białystok, Poland

Context: Elevated human choriogonadotropin (hCG) may stimulate aberrantly expressed luteinizing hormone (LH)/hCG receptor (LHCGR) in adrenal glands, resulting in pregnancy-induced bilateral macronodular adrenal hyperplasia and transient Cushing syndrome (CS).

Objective: To determine the role of LHCGR in transient, pregnancy-induced CS.

Design, Setting, Patient, and Intervention: We investigated the functional implications of LHCGRs in a patient presenting, at a tertiary referral center, with repeated pregnancy-induced CS with bilateral adrenal hyperplasia, resolving after parturition.

Main Outcome Measures and Results: Acute testing for aberrant hormone receptors was negative except for arginine vasopressin (AVP)-increased cortisol secretion. Long-term hCG stimulation induced hypercortisolism, which was unsuppressed by dexamethasone. Postadrenalectomy histopathology demonstrated steroidogenically active adrenocortical hyperplasia and ectopic cortical cell clusters in the medulla. Quantitative polymerase chain reaction showed upregulated expression of *LHCGR*, transcription factors *GATA4*, *ZFPM2*, and proopiomelanocortin (*POMC*), AVP receptors (AVPRs) *AVPR1A* and *AVPR2*, and downregulated melanocortin 2 receptor (*MC2R*) vs control adrenals. LHCGR was localized in subcapsular, zona glomerulosa, and hyperplastic cells. Single adrenocorticotrophic hormone-positive medullary cells were demonstrated in the zona reticularis. The role of adrenal adrenocorticotrophic hormone was considered negligible due to downregulated *MC2R*. Coexpression of *CYP11B1/CYP11B2* and *AVPR1A/AVPR2* was

Abbreviations: ACTH, adrenocorticotrophic hormone; APA, aldosterone-producing adenoma; AVP, arginine vasopressin; AVPR, arginine vasopressin receptor; BMAH, bilateral macronodular adrenal hyperplasia; cAMP, cyclic adenosine monophosphate; CRH, corticotropin-releasing hormone; CS, Cushing syndrome; GA, gestational age; GATA4, GATA binding protein 4; GnRH, gonadotropin-releasing hormone; hCG, human choriogonadotropin; LH, luteinizing hormone; LHCGR, luteinizing hormone/human choriogonadotropin receptor; MC2R, melanocortin 2 receptor; mRNA, messenger RNA; POMC, proopiomelanocortin; qPCR, quantitative polymerase chain reaction.

observed in ectopic cortical cells in the medulla. hCG stimulation of the patient's adrenal cell cultures significantly increased cyclic adenosine monophosphate, corticosterone, 11-deoxycortisol, cortisol, and androstenedione production. *CTNNB1*, *PRKAR1A*, *ARMC5*, and *PRKACA* gene mutational analyses were negative.

Conclusion: Nongenetic, transient, somatic mutation-independent, pregnancy-induced CS was due to hCG-stimulated transformation of LHCGR-positive undifferentiated subcapsular cells (presumably adrenocortical progenitors) into LHCGR-positive hyperplastic cortical cells. These cells respond to hCG stimulation with cortisol secretion. Without the ligand, they persist with aberrant LHCGR expression and the ability to respond to the same stimulus.

Copyright © 2017 by the Endocrine Society

This article has been published under the terms of the Creative Commons Attribution License (CC BY-NC-ND; <https://creativecommons.org/licenses/by-nc-nd/4.0/>).

Freeform/Key Words: Cushing's syndrome, BMAH, adrenal hyperplasia, LHCGR, pregnancy, GATA-4

Primary bilateral macronodular adrenal hyperplasia (BMAH) causes <1% of endogenous Cushing syndrome (CS), although subclinical cortisol production occurs more frequently [1]. In BMAH several G protein-coupled receptors have been shown to be aberrantly expressed in the adrenal cortex and to induce adrenal steroid synthesis, cellular proliferation, and/or adrenal hyperplasia [2–4]. These include receptors for gastric inhibitory polypeptide, arginine vasopressin (AVP), serotonin, catecholamines, and luteinizing hormone (LH)/human chorionic gonadotropin (hCG). Ligand-induced receptor activation results in cortisol excess and suppression of pituitary adrenocorticotrophic hormone (ACTH) secretion; however, stimulated secretion of ACTH locally produced in clusters of BMAH cells has been described as well [5–9].

In pregnancy-induced CS, ectopic adrenal LH/hCG receptor (LHCGR) expression has been related to hypercortisolism, hyperandrogenism, and hyperaldosteronism [10, 11]. Physiologically increased hCG secretion during pregnancy may affect the expression of LHCGR, adrenal cell differentiation, and zonal distribution [9, 12]. It has been suggested that LHCGR activation upregulates the expression of the transcription factor GATA binding protein 4 (GATA4), which as modulated by zinc finger protein ZFP281 is essential for adrenocortical cell neoplastic differentiation and proliferation [12–14]. GATA4 is upregulated in murine and human adrenocortical tumors [12–14].

Somatic mutations in the *CTNNB1*, *PRKAR1A*, *ARMC5*, and *PRKACA* genes have been found in pregnancy/menopause-induced aldosterone-producing adenomas (APAs) [11], primary pigmented nodular adrenocortical disease [15], familial BMAH [16], and cortisol-producing adrenocortical adenomas [17], respectively.

In this study, we describe novel features of gene expression in LHCGR-mediated, pregnancy-induced, mutation-independent (or nongenetic), transient CS, which elucidate the molecular pathogenesis of this rare condition of adrenocortical hyperplasia.

1. Materials and Methods

A. Diagnostic Procedures

CS was diagnosed by determinations of ACTH, steroid hormones, 24-h urinary cortisol, dexamethasone suppression, aberrant hormone receptor testing, and long-term stimulation with hCG (see details in the Supplemental Appendix).

B. Morphological, Histopathological, Molecular, and Biochemical Investigations

Following bilateral adrenalectomy, the patient's adrenal tissues were investigated by histopathology, RNAscope *in situ* hybridization, gene expression profiling by quantitative polymerase chain reaction (qPCR) (Supplemental Table 1), immunohistochemical localization analysis (Supplemental Table 2A and 2B), and gene mutation analysis for *CTNNB1*, *PRKAR1A*, and *ARMC5*. Primary

adrenal cells were stimulated with ACTH and recombinant hCG. Tandem mass spectroscopy and radioimmunoassay were used for steroid hormone and extracellular cyclic adenosine monophosphate (cAMP) determination, respectively (see details in the Supplemental Appendix).

2. Results

A. Case Report

A 22-year-old primigravid woman at 21 weeks gestational age (GA) presented with signs and symptoms of CS (Fig. 1). The increased 24-hour urinary free cortisol excretion,

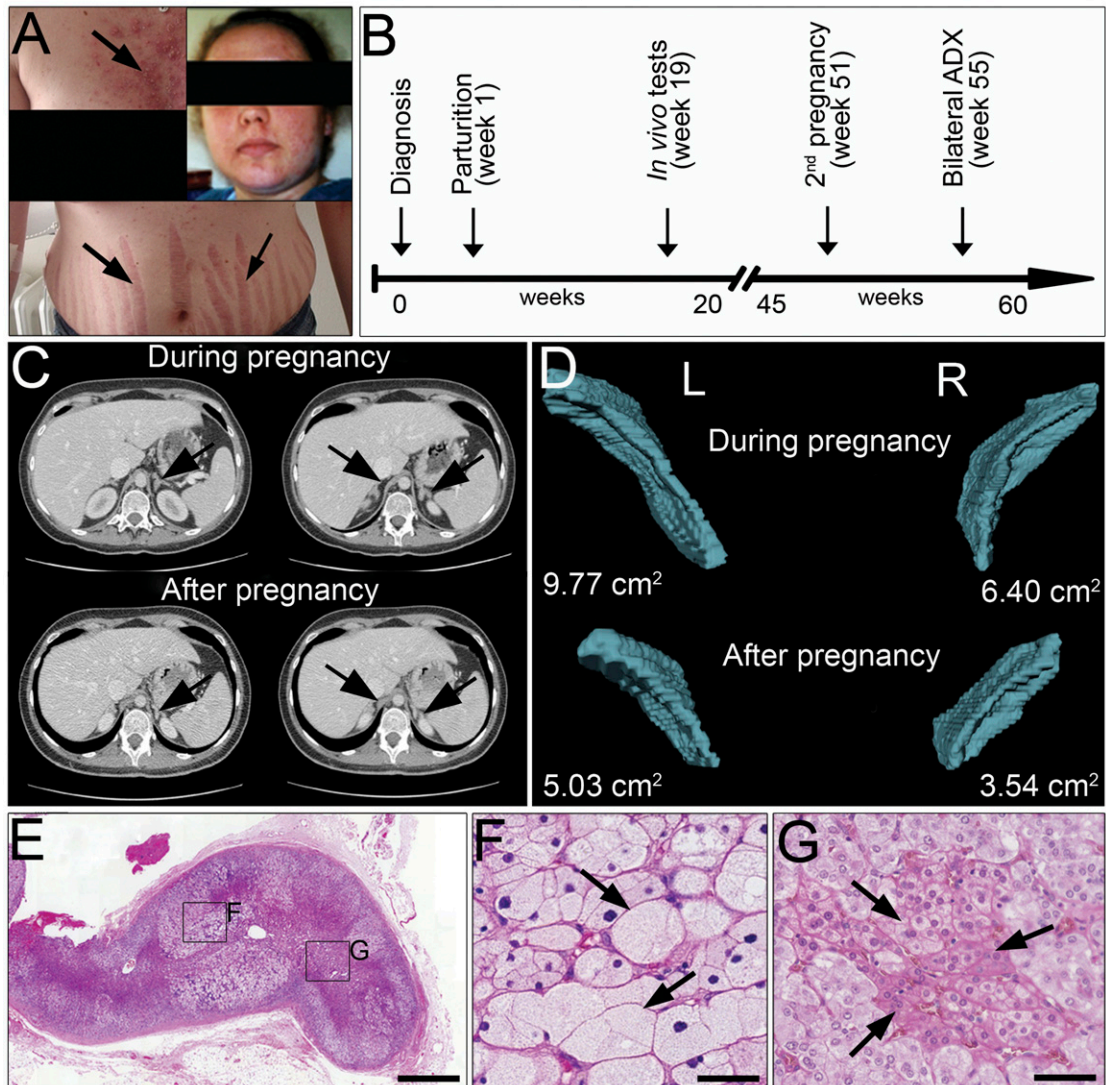


Figure 1. Pregnancy induced CS: clinical symptoms, timeline, computed tomography, and histology. Pregnancy-induced CS (A). A 22-year-old pregnant woman (gravida 1, 21 weeks GA) presented with arterial hypertension, diabetes mellitus, acne (A; black arrow), hirsutism, edema, purple striae distensae (stretch marks) (A; black arrows), and moon face. (B) Schematic timeline view from diagnosis to bilateral adrenalectomy (ADX). (C and D) Abdominal computed tomography and adrenal volumetry showed bilateral enlarged adrenals that normalized after parturition. (E–G) Histopathology with hematoxylin and eosin staining of right adrenal (E) showed hyperplasia with large spongiocytic lipid-loaded cells of the adrenal cortex (F) and clusters of small compact ectopic cortical cells infiltrating the medulla (G). Scale bars, 1000 μm (E) and 50 μm (F and G).

nonsuppressability of cortisol by dexamethasone, low plasma ACTH concentration [<5 pg/mL (<1.1 nmol/L)] (Tables 1–3), and unresponsiveness to corticotropin-releasing hormone (CRH) suggested ACTH-independent CS. The family history was negative for endogenous hypercortisolism. Computed tomography showed bilaterally enlarged adrenals, but no nodular structures [Fig. 1(C) and 1(D)]. Acne suggesting hyperandrogenism (Fig. 1(A); Supplemental Table 3), insulin-dependent diabetes mellitus, and hypokalemic hypertension were prominent. At 25 weeks GA, preterm labor resulted in the vaginal delivery of a male child (sex chromosomes XY) [Fig. 1(B)]. The child died on day 3 due to septicemia and pulmonary hemorrhage. Within a week after delivery, the signs and symptoms of CS receded. Two weeks postpartum, peripheral and adrenal vein aldosterone concentrations were still suppressed [aldosterone <2.3 ng/mL (<63.8 pmol/L); normal range supine, 2.3 to 16 ng/mL (63.8 to 440.0 pmol/L)] and did not increase after ACTH stimulation. Biochemical changes and adrenal volume had normalized 49 days after parturition (Table 3; Fig. 1(C) and 1(D)). During aberrant hormone receptor testing, 19 weeks postpartum ACTH-stimulated cortisol secretion was normal (Table 2; Supplemental Table 4). Orthostasis, a standard meal, thyrotropin-releasing hormone injections, gonadotropin-releasing hormone (GnRH) injections, glucagon injections, or oral metoclopramide failed to evoke a positive cortisol response. However, AVP injection induced a 30-fold increase in cortisol, albeit at a low basal plasma cortisol concentration due to the preceding dexamethasone administration (Table 2; Supplemental Table 4). Long-term hCG stimulation resulted in a peak plasma hCG concentration of 809 IU/L (day 6, hCG 10,000 IU/d), representing 3.2% of the hCG concentration at 26 weeks GA. The peak plasma cortisol concentration increased to 144% [15.1 to 21.7 μ g/dL (386.4 to 555.2 nmol/L)] at day 2 on hCG 5000 IU/d and 133% [16.0 to 21.3 μ g/day (409.4 to 545.0 nmol/L)] at day 2 on hCG 10,000 IU/d, whereas ACTH was suppressed from 11.0 pg/mL to <5 pg/mL (2.4 to <1.2 nmol/L) at day 2 on hCG 5000 IU/d. hCG stimulation elicited a significant increase in androgen concentration (Table 3). During hCG stimulation (10,000 IU/d), both cortisol and

Table 1. Differential Diagnosis of CS

Diagnosis of CS	Week 22 of Pregnancy			49 Days After Parturition		
	Plasma Cortisol (μ g/dL)	24-h Urinary Free Cortisol (nmol/d)	ACTH (pg/mL)	Plasma Cortisol (μ g/dL)	24-h Urinary Free Cortisol (nmol/d)	ACTH (pg/mL)
Normal range ^a	9.2–23.7	11.8–485.6	<46.0	9.2–23.7	11.8–485.6	<46.0
Day 0	—	13,799.0	<5.0	—	91.0	11.0
Day 1	44.9	—	<5.0	23.2	—	—
CRH test						
10:00 AM	38.7	—	<5.0	10.0	—	—
10:15 AM	43.8	—	<5.0	15.1	—	—
10:30 AM	44.2	—	<5.0	18.0	—	—
10:45 AM	40.6	—	<5.0	17.7	—	—
11:00 AM	41.0	—	<5.0	18.1	—	—
DEXA, 1 mg, 12:00 PM						
Day 2: 8:00 AM	43.3	—	<5.0	2.8	—	<5.0
DEXA, 8 mg, 12:00 PM						
Day 3: 8:00 AM	48.9	13,089.0	<5.0	1.2	9.8	<5.0
DEXA, 3 \times 8 mg ^b						
Day 4: 8:00 AM	47.2	11,715.0	6.0	1.1	10.0	<5.0

A dexamethasone suppression test, CRH test, and 24-hour urinary free cortisol determination at week 22 of the first pregnancy and 49 days after spontaneous parturition were used for the diagnosis of Cushing Syndrome. Plasma cortisol concentration after 1 mg dexamethasone >1.8 μ g/L confirms endogenous, autonomous cortisol secretion. Twenty-four-hour urinary free cortisol excretion is 28-fold of the upper limit of normal and 4.7-fold of the concentration reported in pregnancy with CS. Abbreviation: DEXA, dexamethasone.

^aAll normal values refer to basal concentrations in nonpregnant females, as normal values for pregnant females are not available.

^bDexamethasone (8 mg) was given 3 times at 8:00 AM, 4:00 PM, and 12:00 PM.

Table 2. Acute *In Vivo* Tests for Aberrant Receptors

Acute <i>In Vivo</i> Tests for Aberrant Receptors	Plasma Cortisol Basal ($\mu\text{g/dL}$)	Plasma Cortisol Maximum ($\mu\text{g/dL}$)	% Increase
Orthostasis	10.8	13.9	28.7
Test meal	5.8	8.6	48.3
ACTH, 0.25 mg intramuscularly	9.2	22.4	143.5
GnRH, 200 μg intravenously	18.2	16.3	-10.4
Thyrotropin-releasing hormone, 200 μg intravenously	5.0	7.2	44.0
Glucagon, 1 mg intramuscularly	5.6	7.0	25.0
DEXA, 0.5 mg orally/AVP, 10 IE intramuscularly	0.1	3.1	3000.0
Metoclopramide, 10 mg orally	1.1	1.2	9.1

Results of standardized *in vivo* screening tests for the presence of ectopic or overexpressed eutopic adrenal hormone receptors in the patient with CS are shown. Responses to the various stimuli were considered “positive” if there was a cortisol increase >50% of basal, “partial” with a response between > 25% and < 50%, and “negative” when <25%. Abbreviation: DEXA, dexamethasone.

androgen secretions were unresponsive to dexamethasone suppression (Table 3), indicating hCG-induced CS and hyperandrogenism.

At week 51 [Fig. 1(B)] the patient presented with renewed signs and symptoms of CS, including an increased 24-hour urinary free cortisol excretion [999.4 $\mu\text{g}/24\text{ h}$ (2757 nmol/d); upper limit of normal, 176 $\mu\text{g}/24\text{ h}$ (485.6 nmol/d)] and a concurrent plasma hCG concentration of 2634 IU/L. An ectopic pregnancy was diagnosed and terminated. Thereafter, both urinary free cortisol excretion and hCG normalized. Four weeks later [Fig. 1(B)] the patient underwent bilateral adrenalectomy at her request to achieve a normal pregnancy. Thirty months after the initial diagnosis the patient delivered, after an uneventful pregnancy with physiologically substituted glucocorticoid and mineralocorticoid replacement therapy, a healthy female baby.

Table 3. Long-Term βhCG Stimulation

Long-Term βhCG Stimulation (49 d After Parturition)	Plasma Cortisol ($\mu\text{g/dL}$)	24-h Urinary Free Cortisol (nmol/d)	ACTH (pg/mL)	hCG (IU/L)	LH (IU/L) ^a	T (ng/mL)
Normal range ^b	9.2–23.7	11.8–485.6	<46.0	<5	2.4–12.6	0.012–0.099
βhCG , 5000 IU/d	Day 1	15.1	—	11.0	5.9	0.01
(day 1 to day 5)	Day 5	21.5	—	<5.0	399.5	0.07
βhCG , 10,000 IU/d	Day 1	16.0	—	<5.0	123.2	0.08
(day 1 to day 11)	Day 8	19.8	—	<5.0	809.1	0.13
After DEXA, 1 mg, 12:00 PM	Day 9	21.4	—	<5.0	661.7	0.12
After DEXA, 1 mg, 12:00 PM	Day 10	20.5	—	<5.0	706.0	0.11
After DEXA, 3 \times 8 mg ^c	Day 11	20.1	750.0	<5.0	536.0	0.11

Long-term stimulation with hCG (Predalon®) after parturition (week 19): plasma cortisol, ACTH, and hCG concentration, as well as results of the dexamethasone suppression test during hCG stimulation, are shown. Daily injections included 5000 IU of hCG for 5 days and 10,000 IU of hCG for 13 days. Plasma cortisol concentration (8:00 AM) is indicated before the first injection of 5000 IU of hCG, on the last day on 5000 IU of hCG, on the first day of 10,000 IU of hCG, after 8 days of 10,000 IU of hCG, and for 3 days on 10,000 IU of hCG during the dexamethasone suppression test.

Abbreviation: DEXA, dexamethasone.

^aNormal range for the follicular phase of the menstrual cycle.

^bAll normal values refer to basal concentrations in nonpregnant females, as normal values for pregnant females are not available.

^cDexamethasone (8 mg) was given 3 times at 8:00 AM, 4:00 PM, and 12:00 PM.

B. Analysis of Functional Mechanism

Histopathology demonstrated adrenocortical hyperplasia with large lipid-loaded spongiocytic cells [Fig. 1(E) and 1(F)] and few clusters of small compact cells in the center of the medulla [Fig. 1(E) and 1(G)] resembling zona reticularis cells.

The *LHCGR* messenger RNA (mRNA) expression was fourfold upregulated compared with normal healthy female adrenal tissue [Fig. 2(A)]. LHCGR mRNA and protein were colocalized in the undifferentiated subcapsular cells of the cortex [Fig. 2(B) and (E)], in zona glomerulosa cells [Fig. 2(C) and (E)], and in hyperplastic cells [Fig. 2(E) and 2(F); Supplemental Fig. 1]. ACTH or rhCG stimulation of isolated adrenal cells increased cAMP production by 158.6% ($P=0.048$) or 25.4% ($P=0.011$), respectively, *vs* nonstimulated cells [Fig. 2(G)], confirming the suggested transduction pathway for LHCGR. ACTH and rhCG stimulation of dispersed and cultured adrenal cells induced a significant increase in corticosterone, 11-deoxycortisol, cortisol, and androstenedione production in accordance with the positive *in vivo* response of cortisol and testosterone to long-term hCG stimulation [Fig. 2(H); Table 3].

In parallel to the upregulation of the *LHCGR* expression, *GATA4* and the modulator of its transcriptional activity *ZFPM2* were upregulated at the mRNA level *vs* control [Fig. 3(A); eightfold and 2.8-fold, respectively]. However, although immunohistochemistry demonstrated LHCGR in undifferentiated subcapsular cells of the cortex and zona glomerulosa and in hyperplastic cells (see above), only GATA4 was observed within the undifferentiated subcapsular cells [Fig. 3(B)], whereas both GATA4- and ZFMP2-positive cells were positive in the zona glomerulosa cells [Fig. 3(C) and 3(F)]. In contrast, the hyperplastic cells of the cortex were negative for both GATA4 and ZFPM2 expression [Fig. 3(D) and 3(G)].

The steroidogenic profiles of the hyperplastic cortical cells and the ectopic cortical cells in the medulla were defined by immunofluorescence localization of CYP11A1, 3 β -HSD, CYP21A1, CYP17, CYP11B1, and CYP11B2 (Fig. 4). The hyperplastic cells expressed all steroidogenic enzymes except CYP11B2 [Fig. 4(A–F)], whereas the ectopic cortical cells in the medulla coexpressed both CYP11B1 and CYP11B2 [Fig. 4(L)]. The cortical phenotype of the cell clusters in the medulla was demonstrated by positive staining for all cortical cell markers analyzed and by negative staining for the medullary cell marker chromogranin A [CgA; Fig. 4(G)].

mRNA expression of the ACTH precursor *POMC* and the two AVP receptors (AVPRs) *AVPR1A* and *AVPR2* was highly upregulated in both adrenals *vs* the healthy female controls [Fig. 5(A)]. Immunohistochemistry demonstrated ACTH-positive cells only in CgA-positive adrenal medullary cells, located adjacent to the zona reticularis [Fig. 5(B); Supplemental Figs. 2 and 3]. ACTH receptor [melanocortin 2 receptor (*MC2R*)] expression was downregulated [Fig. 5(A)]. As expected, immunohistochemistry localized the MC2R mainly in the cells of the zona fasciculata and reticularis (Fig. 5C; Supplemental Fig. 4). Quite unexpectedly, AVPR1A and AVPR2 were found in the ectopic cortical cell clusters in the medulla (Fig. 5(D) and 5(E); Supplemental Figs. 5 and 6). Vasopressin was not expressed in the patient's adrenals (Supplemental Fig. 7). All findings are summarized in Supplemental Table 5. *CTNNB1*, *PRKAR1A*, *ARMC5*, and *PRKACA* gene mutational analyses were negative.

3. Discussion

Diagnosing excess cortisol secretion in pregnancy is challenging due to the physiological modification of the ACTH/cortisol axis by the placental production of CRH and ACTH [18]. However, in our patient the diagnostic confidence was high, due to the convincing signs and symptoms of CS and the clearly elevated urinary free cortisol concentrations. The suppressed plasma ACTH concentration indicated primary adrenal hypercortisolism [18]. The clinical course of the pregnancy followed the established risk of maternal morbidity and adverse fetal outcome in untreated CS [19–23]. The postpartum remission of CS after the first normal and the second extrauterine pregnancy suggested transient pregnancy-induced hypercortisolism

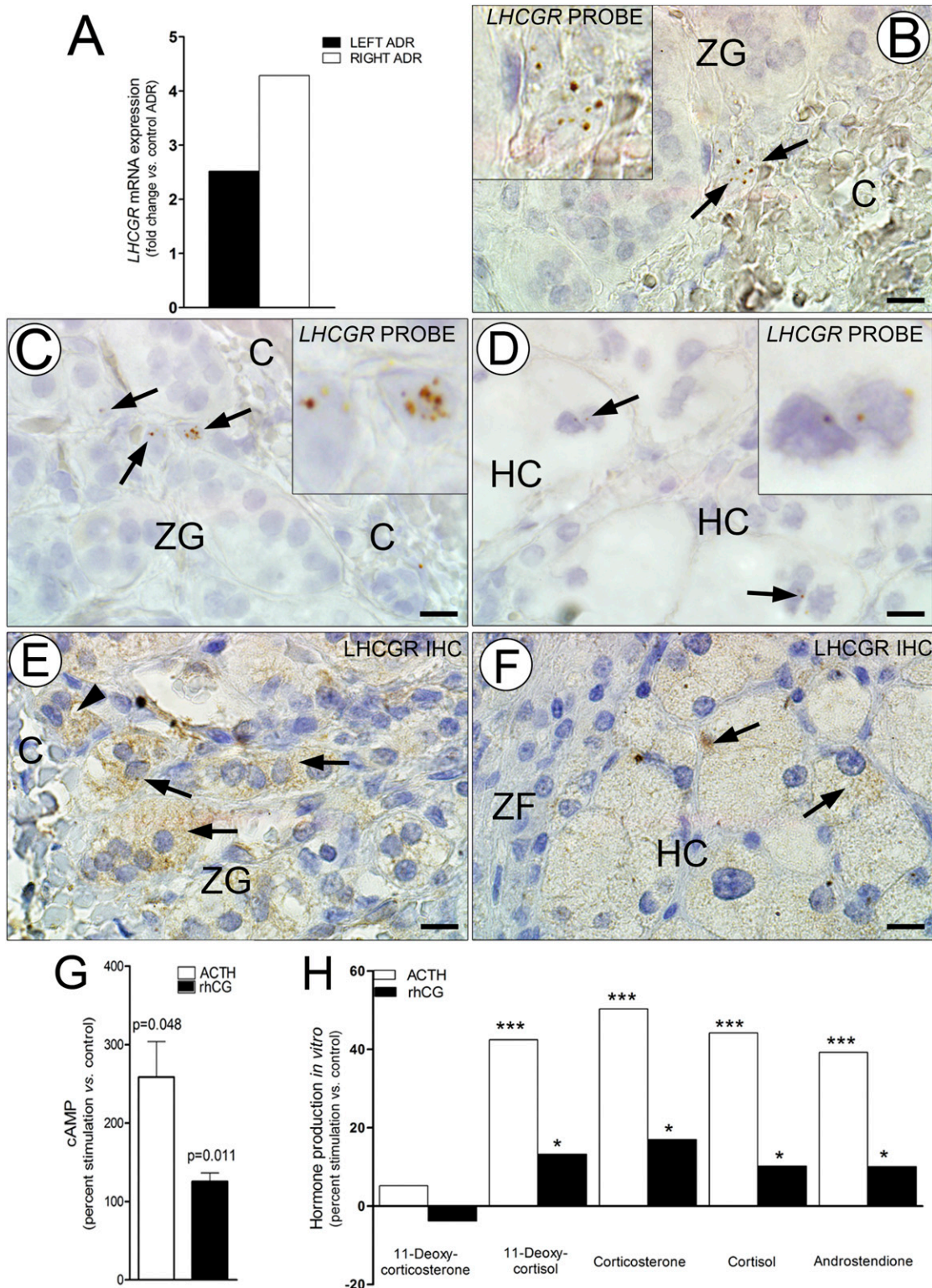


Figure 2. Expression, cellular localization, and functionality of adrenal LHCGR. (A) Quantification of *LHCGR* mRNA expression in the patient's left and right adrenal (ADR) and in an adrenal of a female healthy control subject by qPCR. Data are normalized to four housekeeping genes: cyclophilin A (*PPIA*), β -actin (*ACTB*), β -glucuronidase (*GUSB*), and 18S ribosomal RNA (*18S rRNA*) and presented as fold change where expression of control group is equal to 1.0 (bar not shown on the graph); controls, n = 3. (B–D) *LHCGR* RNA *in situ*

hybridization (RNAscope®) in subcapsular cells (B), zona glomerulosa (C), and hyperplastic cells (D). (E and F) Immunohistochemical localization of LHCGR in subcapsular (arrowhead), zona glomerulosa (E, arrows), and hyperplastic cells (F, arrows). Sections were counterstained with hematoxylin. Scale bars, 10 μ m. (G) Recombinant hCG-stimulated cAMP production and (H) 11-deoxycorticosterone, 11-deoxycortisol, corticosterone, cortisol, and androstenedione secretion in the primary adrenal cells isolated after adrenalectomy. * $P < 0.05$, *** $P < 0.001$. C, adrenal capsule; HC, hyperplastic cell; rhCG, recombinant hCG; ZF, zona fasciculata; ZG, zona glomerulosa.

related to hCG secretion and was subsequently confirmed to be due to the increased expression of eutopic adrenal LHCGR [21] and hCG-stimulated steroidogenesis [4, 8]. To identify the receptors responsible for aberrant cortisol secretion, a standardized acute *in vivo* screening procedure [24] was performed after parturition [Fig. 1(B)]. At the time of testing, the 8:00 AM ACTH concentration was rather low, suggesting a still incomplete recovery of the ACTH/cortisol axis from hypercortisolism after parturition. Alternatively, the corresponding basal and ACTH-stimulated cortisol concentrations were normal, indicating normal adrenal function.

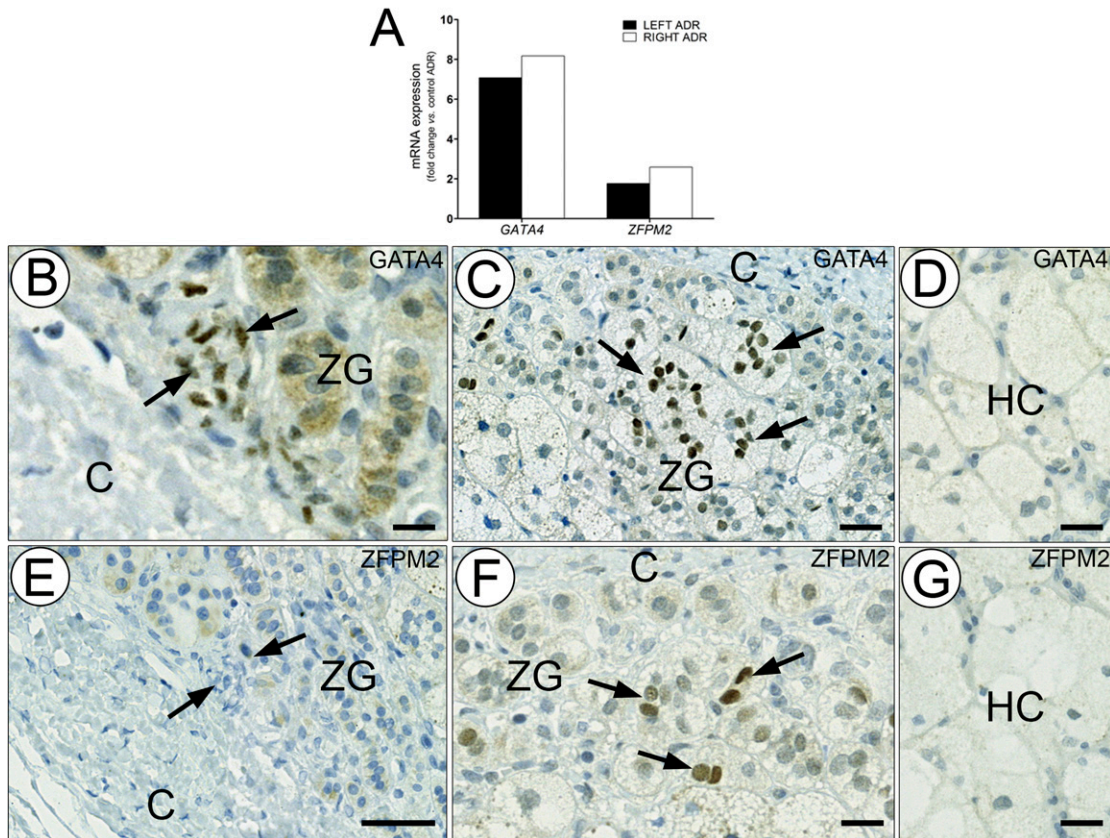
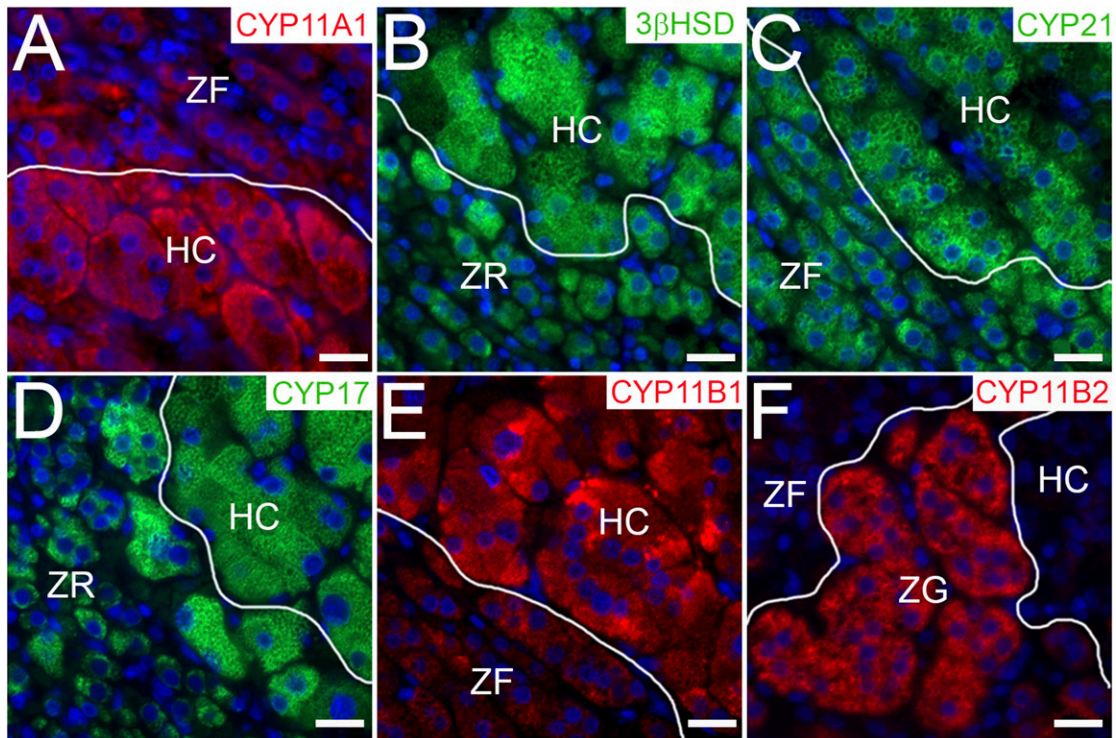


Figure 3. Expression and cellular localization of adrenal GATA4 and ZFMP2. (A) Quantification of *GATA4* and *ZFMP2* mRNA expression in the patient's left and right adrenal (ADR) and in an adrenal of a female healthy control subject by qPCR. Data are normalized to four housekeeping genes: cyclophilin A (*PPIA*), β -actin (*ACTB*), β -glucuronidase (*GUSB*), and 18S ribosomal RNA (*18S rRNA*). Results are presented as fold change where expression of control group is equal to 1.0 (bar not shown on the graph); controls, n = 3. (B–G) Immunohistochemical localization of GATA4 (B–D) and ZFMP2 (E–G) in the adrenal gland of the patient. GATA4 was localized in subcapsular (B) and zona glomerulosa cells (C) (black arrows), whereas ZFMP2 was detected only in zona glomerulosa cells (F) (black arrows). Subcapsular cells (black arrows) were negative for ZFMP2 (E). Hyperplastic cells of the adrenal gland were negative for both GATA4 (D) and ZFMP2 (G). Sections were counterstained with hematoxylin. Scale bars, 10 μ m. C, adrenal capsule; HC, hyperplastic cell; ZG, zona glomerulosa.

Adrenal hyperplasia



Cortical cells in the medulla

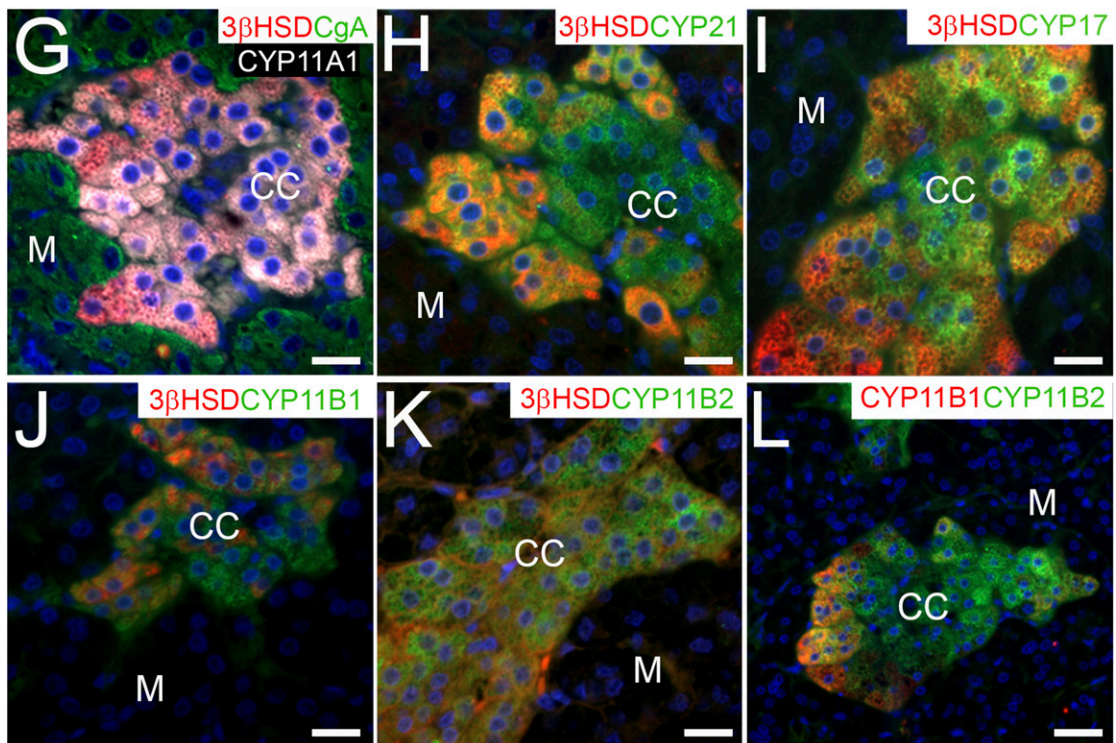


Figure 4. Origin and steroidogenic profile of hyperplastic cells and ectopic cortical cells in the medulla by immunofluorescence staining. (A–F) Immunofluorescence localization of CYP11A1 (red, A); 3βHSD (green, B); CYP21 (green, C); CYP17 (green, D), CYP11B1 (red, E), and CYP11B2 (red, F) in the cells of adrenal hyperplasia and normal cortical cells of zona

glomerulosa, zona fasciculata, or zona reticularis. (G–L) Steroidogenic characterization of ectopic cortical cells infiltrating the medulla by immunofluorescence colocalization (pink or orange) of 3β HSD (red) used as an adrenocortical cell marker, with CYP11A1 (white, G) and CgA (green, G), CYP21 (green, H), CYP17 (green, I), CYP11B1 (green, J), and CYP11B2 (green, K). In contrast to normal or hyperplastic cells, cortical cells in the medulla coexpressed (orange) CYP11B1 (red) and CYP11B2 (green) (L). DAPI was used as counterstaining to detect cell nuclei (blue). Scale bars, 20 μ m. CYP11A1 is a C27 side-chain cleavage enzyme; CYP11B1, steroid 11-hydroxylase; CYP11B2, steroid 11- β -hydroxylase (aldosterone synthase); CYP17A1, steroid 17- α -hydroxylase; CYP21, steroid 21-hydroxylase; and 3β HSD is a 3- β -hydroxysteroid dehydrogenase. CC, ectopic cortical cell in the medulla, HC, hyperplastic cell; M, adrenal medulla; ZF, zona fasciculata; ZG, zona glomerulosa; ZR, zona reticularis.

The acute GnRH stimulation during initial *in vivo* testing failed to elicit a cortisol increase, possibly in part due to the postpartum still-unresponsive endogenous LH secretion. However, after long-term hCG stimulation, even though hCG plasma concentration was significantly lower than during the first trimesters of both pregnancies, symptomatic and dexamethasone nonsuppressible hypercortisolism and hyperandrogenism were observed. Thus, outside pregnancy, long-term stimulation is probably a prerequisite for this positive response, and the monthly preovulatory LH surge is obviously too short to induce the syndrome. Post-adrenalectomy (4 weeks after termination of the second, ectopic pregnancy) gene expression studies on the removed adrenal tissue demonstrated persistently upregulated *LHCGR*, localized in sparsely distributed undifferentiated subcapsular cells, in glomerulosa cells, and in hyperplastic zona fasciculata-type BMAH cells. The *LHCGR*-positive subcapsular cells may belong to a pool of progenitor cells with a capacity to develop into gonadal-like and/or adrenocortical cells. It is known that both the adrenal cortex and the gonads originate from a common stem/progenitor cell population in the adrenogenital ridge. Owing to mistrafficking, some of the stem/progenitor cells, directed into gonadal differentiation, migrate to the adrenal compartment. There, under specific conditions, they may differentiate into mixed gonadotropin/steroid-responsive gonadal-like cells with adrenocortical phenotype [25, 26]. We suggest that under persistently high LH/hCG stimulation these cells may transform into LH/hCG-responsive glomerulosa-type cells and further give rise to the hyperplastic zona fasciculata-type BMAH cells.

hCG stimulation of cultured primary adrenal cells obtained after adrenalectomy activated the adenylyl cyclase pathway and significantly increased the production of glucocorticoids, androgens, and corticosterone, yet failed to increase aldosterone. Thus, the expression of the *LHCGR* in zona glomerulosa cells and hyperplastic cells together with the *in vitro* data substantiate the role of the LH/hCG–*LHCGR* complex in the pathophysiology of pregnancy-induced CS with hypertension [13], signs and symptoms of glucocorticoid excess, and severe hyperandrogenism and acne.

Mouse strains and domestic ferrets susceptible to gonadectomy-induced adrenocortical tumorigenesis develop, under the influence of high LH concentrations, sex steroid-producing adrenocortical tumors composed of large lipid-loaded *LHCGR*-positive cells. This phenomenon is thought to reflect a gonadotropin-induced neoplastic transformation of stem/progenitor cells in the subcapsular region of the adrenal gland [27–29]. This transformation is regulated by *GATA4*, which, together with cofactors *ZFMP2* and *SF1*, is involved in sex determination, gonadal development, and function [28]. Although *GATA4* is not normally expressed in adult adrenals, it has been reported to play a role in adrenal tumorigenesis [14, 30]. Upregulated *GATA4* and *ZFMP2*, as well as *GATA4*, *LHCGR*-matching localizations in the periphery, and zona glomerulosa cells, may contribute to the neoplastic development of the LH/hCG-responsive cells. We therefore suggest that increased hCG secretion during pregnancy upregulated *LHCGR*, *GATA4*, and *ZFMP2* expression and induced the hCG-responsive subcapsular cells to differentiate into adrenal steroid-producing hyperplastic cells. The transformed hyperplastic cells no longer express *GATA4* and *ZFMP2*, as

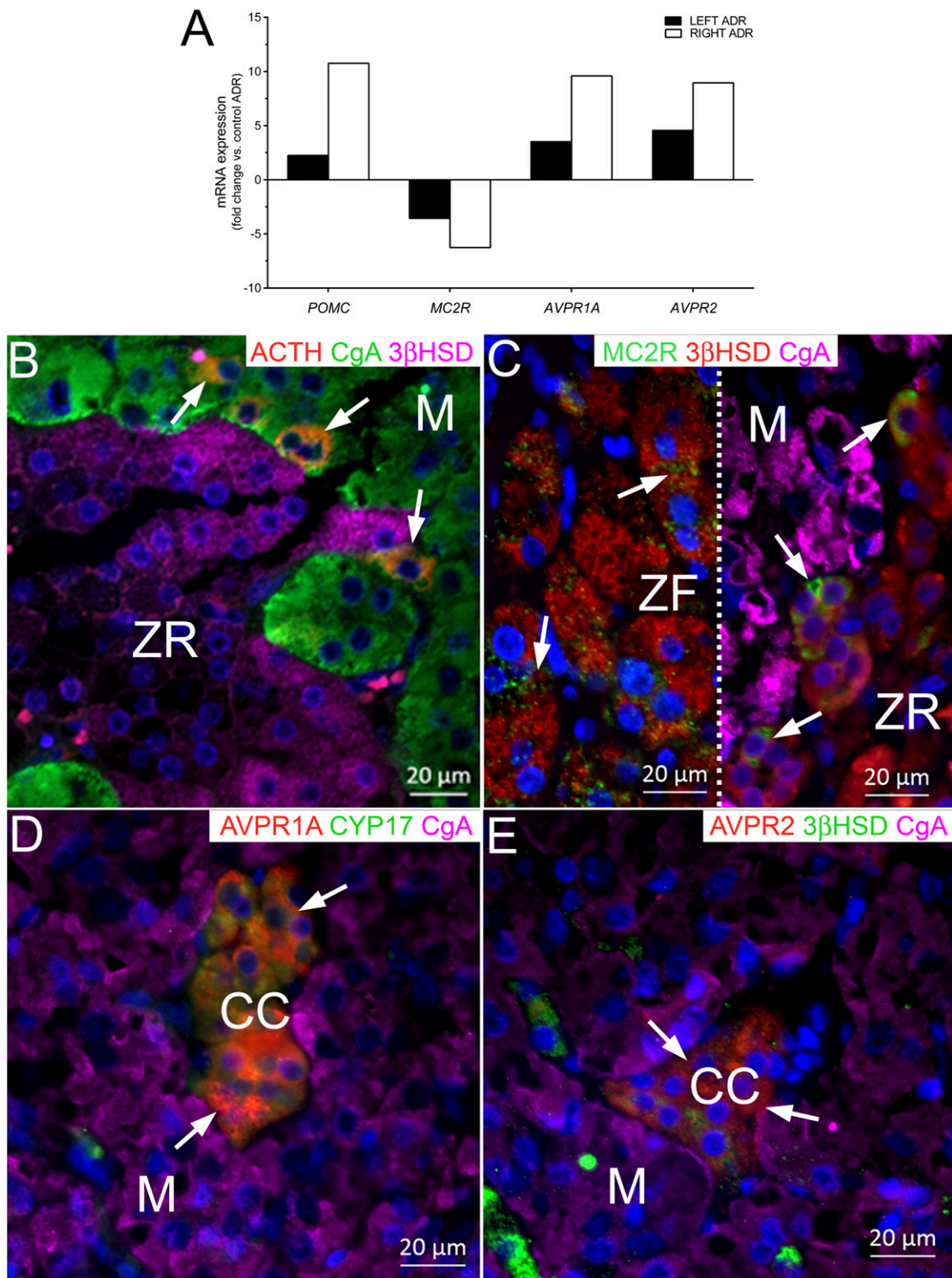


Figure 5. Adrenal expression and cellular localization of POMC/ACTH, MC2R, AVPR1A, and AVPR2. (A) Quantification of *POMC*, *MC2R*, *AVPR1A*, and *AVPR2* mRNA expression in the patient's left and right adrenal (ADR) and in the adrenal of a female healthy control subject by qPCR. Data are normalized to four housekeeping genes: cyclophilin A (*PPIA*), β -actin (*ACTB*), β -glucuronidase (*GUSB*), and 18S ribosomal RNA (*18S rRNA*) and presented as fold change where expression of control group is equal to 1.0 (bar not shown on the graph); controls, n = 3. (B–E) Immunofluorescence colocalization (orange, white arrows) of (B) ACTH (red) with CgA (green) in adrenal medulla on the border with zona reticularis specified by

3 β HSD staining (purple); (C) MC2R (green) with 3 β HSD-positive cells (red) of zona fasciculata and zona reticularis (white arrows), but not with CgA (purple) in the adrenal medulla; (D) AVPR1A (red) with CYP17 (green); and (E) AVPR2 (red) with 3 β HSD (green) in the cortical cells (white arrows) infiltrating medulla (CgA, purple). DAPI was used as counterstaining to detect cell nuclei (blue). Scale bars, 20 μ m. AVPR1A, vasopressin receptor 1A; AVPR2, vasopressin receptor 2; CC, cortical cell in the medulla; M, medulla; ZF, zona fasciculata; ZR, zona reticularis.

they developed an adrenocortical phenotype with a pattern of steroidogenic profile akin to the zona fasciculata.

Negative results of familial and somatic *CTNNB1*, *PRKACA*, *ARMC5*, and *PRKACA* gene mutation analyses excluded a genetic background of CS in our patient [11, 16, 17]. Nevertheless, our patient displayed some similarities with patients who presented with pregnancy/menopause-induced primary hyperaldosteronism due to a somatic mutation in *CTNNB1* and β -catenin activation [11]. In both cases there were increased hCH/LH levels, overexpression of LHCGR, and GATA4 positivity in the zona glomerulosa cells. In the *CTNNB1* mutation case, the authors postulated hyperaldosteronism as a consequence of aberrant gonadal differentiation caused by β -catenin activation through a mutation in *CTNNB1* [11]. Very recently, two independent groups have criticized association between activated mutation in *CTNNB1*, pregnancy/menopause, overexpression of *LHCGR*, and primary hyperaldosteronism [31, 32]. In their opinion, based on recently published results, pregnancy/menopause-induced primary hyperaldosteronism cannot be directly linked with somatic mutation in *CTNNB1* and β -catenin activation [32, 33].

Interestingly, the ectopic cortical cell clusters found in the adrenal medulla coexpressed CYP11B1 and CYP11B2 and thus demonstrated a mixed steroidogenic pattern characteristic for normal zona glomerulosa and fasciculata cells. The location in the adrenal medulla may indicate an abnormal cell differentiation and/or migration pattern. CYP11B1, expressed in the zona fasciculata and reticularis, generates corticosterone from 11-deoxycorticosterone and cortisol from 11-deoxycortisol. CYP11B2, in physiological conditions, is limited to the zona glomerulosa catalyzing aldosterone biosynthesis. CYP11B1 and CYP11B2 colocalization adjacent to glomerulosa cells is very rare and has as yet only been observed in idiopathic hyperaldosteronism and adrenal cells in the vicinity of an APA [34]. The expression pattern of steroidogenic enzymes enables these cells to produce both glucocorticoids and mineralocorticoids.

AVP-stimulated cortisol synthesis via eutopic AVPR1A and ectopic AVPR2 activation in normal adrenal glands and BMAH tissues has been described [35]. Both AVPR1A and AVPR2 have also been detected in APAs [36]. In our patient, a mild stimulatory response to AVP *in vivo* was in accordance with the increased expression of AVP receptors at the mRNA level, immunohistochemically localized in ectopic cortical cells in the medulla. We excluded intra-adrenal AVP production and thus any autocrine or paracrine AVP effects. Additionally, no symptoms of exaggerated stimulation of cortisol secretion due to physiological AVPR stimuli, such as upright posture, were observed in the patient. Thus, the clinical relevance of AVP-stimulated cortisol secretion appears minimal.

The expression of *POMC* mRNA as well as the presence of sporadic ACTH and prohormone convertase 1/3 (a marker of neuroendocrine cells) double-positive cells in the adrenal medulla may suggest intra-adrenal ACTH secretion, although in such a low amount that it did not increase the circulating ACTH concentration. Furthermore, paracrine ACTH-stimulated cortisol secretion is highly unlikely due to normally distributed, yet, typically for BMAH [16, 24], downregulated *MC2R*. Additionally, the complete remission of CS after pregnancy excludes a substantial pathogenic role of the paracrine mechanism of cortisol production due to ACTH-positive medullary cells. In contrast to Louiset *et al.* [9], we did not identify ectopic or paracrine ACTH production in the zona fasciculata-like cells of the BMAH tissues of our patient.

In the literature, we found 6 cases of pregnancy-induced, transient hypercortisolism (Supplemental Table 6) [22, 23, 37–40]. Interestingly, severe hirsutism and/or acne were observed in all patients, and significant hypokalemia was found in 5 of 7 published patients. *In vivo* hCG-stimulated cortisol secretion was positive in four of five patients [23, 38, 40]. In the nonresponding patient, only short-time stimulation with hCG was performed [23], emphasizing the time-dependency of the stimulatory effect. Imaging procedures were negative for adrenal adenomas in all patients, but macronodular hyperplasia was observed in 2 patients, both after chronic adrenal stimulation (menopause in 1 patient and 8 pregnancies within 6 years in the other patient) [38, 40]. Data from the patient with BMAH and subclinical CS after 8 pregnancies [40], all complicated by pregnancy-induced CS, suggest the possibility of a transition from reversible, pregnancy-induced hypercortisolism to LH/hCG-independent BMAH. This could well be due to the repeated, pregnancy-related, LHCGR-induced, GATA4-modulated transformation and proliferation into LHCGR-negative, hyperplastic zona fasciculata-type cells, with an LH/hCG-independent capacity for proliferation and cortisol secretion resulting in BMAH and subclinical CS.

In conclusion, we present a patient with reversible, somatic mutation-independent pregnancy-induced CS due to hCG-activated LHCGR-associated mechanism. The sequence of events resulting in severe CS are primarily the LH/hCG-stimulated trans-differentiation of LHCGR-positive subcapsular cells (most likely adrenal progenitors) into glomerulosa cells and/or hyperplastic cells responding to LH/hCG stimulation with ACTH-independent glucocorticoid, mineralocorticoid, and androgen production. Additionally, the presence of steroidogenic ectopic cortical cells in the medulla, capable of producing all adrenal steroids, may add to the severe clinical CS observed in these patients. Finally AVP-stimulated cortisol secretion, acting via AVPR1A and AVPR2 receptors in the steroidogenically active, ectopic cortical cells in the medulla, may play a role in the increased cortisol secretion. In contrast, the presence of ACTH-positive cells in the medulla failed to increase systemic ACTH secretion. Although paracrine stimulation of androgens in normal MC2R-positive zona reticularis cells in the vicinity of these ACTH-positive medullary cells cannot be excluded, a paracrine effect on cortisol secretion is highly unlikely due to the down-regulated *MC2R*.

Acknowledgments

We thank M. Rochel and I. Eichhorn, Charité University Medicine Berlin, for expert technical work with the primary adrenal cell cultures. We thankfully acknowledge the contributions of Prof. B. Allolio, University Hospital Würzburg, Germany, who died during the time we were working on the project and whose advice and early contributions have been very helpful. Finally, we thank the patient for her excellent cooperation during the clinical investigations.

Address all correspondence to: Ursula Plöckinger, MD, Interdisziplinäres Stoffwechsel-Centrum, Charité-Universitätsmedizin Berlin, Campus Virchow-Klinikum, Augustenburger Platz 1, D-13353 Berlin, Germany. E-mail: ursula.ploeckinger@charite.de

This work was supported by grants from the Charité Research Fund (to U.P.) and by Academy of Finland Grant 254366 (to N.R.).

Author contributions: U.P. cared for the patient. U.P., M.C., and N.R. designed the research. M.C., M.D., U.P., M.K., and M.Q. performed the experiments. W.S. and C.R. were responsible for pathological results. O.B. performed the tandem mass spectroscopy determination of the steroids. K.W. was responsible for the clinical care of the patient's pregnancies. K.H. analyzed the chromosomal sex of the first child. A.P. analyzed the radiological data. N.T. compiled the clinical data. T.S. performed the bilateral adrenalectomy. J.B. and M.D. performed the genetic testing. U.P., M.C., and N.R. analyzed and interpreted the results. A.L. provided advice on conduct and interpretation of experiments. All the authors took part in the interpretation of the experimental results. U.P., M.C., I.H., and N.R. drafted and wrote the manuscript, which was critically reviewed by all authors.

Disclosure Summary: The authors have nothing to disclose.

References and Notes

1. Fragoso MC, Alencar GA, Lerario AM, Bourdeau I, Almeida MQ, Mendonca BB, Lacroix A. Genetics of primary macronodular adrenal hyperplasia. *J Endocrinol*. 2015;**224**(1):R31–R43.
2. Matsukura S, Kakita T, Sueoka S, Yoshimi H, Hirata Y, Yokota M, Fujita T. Multiple hormone receptors in the adenylate cyclase of human adrenocortical tumors. *Cancer Res*. 1980;**40**(10):3768–3771.
3. Schorr I, Rathnam P, Saxena BB, Ney RL. Multiple specific hormone receptors in the adenylate cyclase of an adrenocortical carcinoma. *J Biol Chem*. 1971;**246**(18):5806–5811.
4. Lefebvre H, Prevost G, Louiset E. Autocrine/paracrine regulatory mechanisms in adrenocortical neoplasms responsible for primary adrenal hypercorticism. *Eur J Endocrinol*. 2013;**169**(5):R115–R138.
5. Suda T, Tomori N, Yajima F, Odagiri E, Demura H, Shizume K. Characterization of immunoreactive corticotropin and corticotropin-releasing factor in human adrenal and ovarian tumours. *Acta Endocrinol (Copenh)*. 1986;**111**(4):546–552.
6. Lacroix A, Bolté E, Tremblay J, Dupré J, Poitras P, Fournier H, Garon J, Garrel D, Bayard F, Taillefer R, Flanagan RJ, Hamet P. Gastric inhibitory polypeptide-dependent cortisol hypersecretion—a new cause of Cushing’s syndrome. *N Engl J Med*. 1992;**327**(14):974–980.
7. Reznik Y, Allali-Zerah V, Chayvialle JA, Leroyer R, Leymarie P, Travert G, Lebrethon MC, Budi I, Balliere AM, Mahoudeau J. Food-dependent Cushing’s syndrome mediated by aberrant adrenal sensitivity to gastric inhibitory polypeptide. *N Engl J Med*. 1992;**327**(14):981–986.
8. Lacroix A, Bourdeau I, Lampron A, Mazzuco TL, Tremblay J, Hamet P. Aberrant G-protein coupled receptor expression in relation to adrenocortical overfunction. *Clin Endocrinol (Oxf)*. 2010;**73**(1):1–15.
9. Louiset E, Duparc C, Young J, Renouf S, Tetsi Nomigni M, Boutelet I, Libé R, Bram Z, Groussin L, Caron P, Tabarin A, Grunenberger F, Christin-Maitre S, Bertagna X, Kuhn JM, Anouar Y, Bertherat J, Lefebvre H. Intraadrenal corticotropin in bilateral macronodular adrenal hyperplasia. *N Engl J Med*. 2013;**369**(22):2115–2125.
10. Carlson HE. Human adrenal cortex hyperfunction due to LH/hCG. *Mol Cell Endocrinol*. 2007;**269**(1-2):46–50.
11. Teo AE, Brown MJ. Pregnancy, primary aldosteronism, and somatic *CTNNB1* mutations. *N Engl J Med*. 2016;**374**(15):1494.
12. Kero J, Poutanen M, Zhang FP, Rahman N, McNicol AM, Nilson JH, Keri RA, Huhtaniemi IT. Elevated luteinizing hormone induces expression of its receptor and promotes steroidogenesis in the adrenal cortex. *J Clin Invest*. 2000;**105**(5):633–641.
13. Vuorenoja S, Rivero-Muller A, Kiiveri S, Bielinska M, Heikinheimo M, Wilson DB, Huhtaniemi IT, Rahman NA. Adrenocortical tumorigenesis, luteinizing hormone receptor and transcription factors GATA-4 and GATA-6. *Mol Cell Endocrinol*. 2007;**269**(1-2):38–45.
14. Barbosa AS, Giacaglia LR, Martin RM, Mendonca BB, Lin CJ. Assessment of the role of transcript for GATA-4 as a marker of unfavorable outcome in human adrenocortical neoplasms. *BMC Endocr Disord*. 2004;**4**(1):3.
15. Groussin L, Horvath A, Jullian E, Boikos S, Rene-Corail F, Lefebvre H, Cephise-Velayoudom FL, Vantyghem MC, Chanson P, Conte-Devolx B, Lucas M, Gentil A, Malchoff CD, Tissier F, Carney JA, Bertagna X, Stratakis CA, Bertherat J. A *PRKARIA* mutation associated with primary pigmented nodular adrenocortical disease in 12 kindreds. *J Clin Endocrinol Metab*. 2006;**91**(5):1943–1949.
16. Assié G, Libé R, Espiard S, Rizk-Rabin M, Guimier A, Luscap W, Barreau O, Lefèvre L, Sibony M, Guignat L, Rodriguez S, Perlemoine K, René-Corail F, Letourneur F, Trabulsi B, Poussier A, Chabbert-Buffet N, Borson-Chazot F, Groussin L, Bertagna X, Stratakis CA, Ragazzon B, Bertherat J. *ARMC5* mutations in macronodular adrenal hyperplasia with Cushing’s syndrome. *N Engl J Med*. 2013;**369**(22):2105–2114.
17. Beuschlein F, Fassnacht M, Assié G, Calebiro D, Stratakis CA, Osswald A, Ronchi CL, Wieland T, Sbiera S, Faucz FR, Schaak K, Schmittfull A, Schwarzmayr T, Barreau O, Vezzosi D, Rizk-Rabin M, Zabel U, Szarek E, Salpea P, Forlino A, Vetro A, Zuffardi O, Kisker C, Diener S, Meitinger T, Lohse MJ, Reincke M, Bertherat J, Strom TM, Allolio B. Constitutive activation of PKA catalytic subunit in adrenal Cushing’s syndrome. *N Engl J Med*. 2014;**370**(11):1019–1028.
18. Lindsay JR, Nieman LK. The hypothalamic-pituitary-adrenal axis in pregnancy: challenges in disease detection and treatment. *Endocr Rev*. 2005;**26**(6):775–799.
19. Lo KW, Lau TK. Cushing’s syndrome in pregnancy secondary to adrenal adenoma. A case report and literature review. *Gynecol Obstet Invest*. 1998;**45**(3):209–212.
20. Murakami S, Saitoh M, Kubo T, Kawakami Y, Yamashita K. A case of mid-trimester intrauterine fetal death with Cushing’s syndrome. *J Obstet Gynaecol Res*. 1998;**24**(2):153–156.

21. Lindsay JR, Jonklaas J, Oldfield EH, Nieman LK. Cushing's syndrome during pregnancy: personal experience and review of the literature. *J Clin Endocrinol Metab.* 2005;**90**(5):3077–3083.
22. Kasperlik-Zaluska AA, Szczupacka I, Leszczynska-Bystrzanowska J, Drus-Przybyszewska G. Pregnancy-dependent Cushing's syndrome in three pregnancies. *BJOG.* 2000;**107**(6):810–812.
23. Achong N, D'Emden M, Fagermo N, Mortimer R. Pregnancy-induced Cushing's syndrome in recurrent pregnancies: case report and literature review. *Aust N Z J Obstet Gynaecol.* 2012;**52**(1):96–100.
24. Lacroix A. ACTH-independent macronodular adrenal hyperplasia. *Best Pract Res Clin Endocrinol Metab.* 2009;**23**(2):245–259.
25. Raff H. Cushing syndrome: update on testing. *Endocrinol Metab Clin North Am.* 2015;**44**(1):43–50.
26. Hatano O, Takakusu A, Nomura M, Morohashi K. Identical origin of adrenal cortex and gonad revealed by expression profiles of Ad4BP/SF-1. *Genes Cells.* 1996;**1**(7):663–671.
27. Röhrig T, Pihlajoki M, Ziegler R, Cochran RS, Schrade A, Schillebeeckx M, Mitra RD, Heikinheimo M, Wilson DB. Toying with fate: redirecting the differentiation of adrenocortical progenitor cells into gonadal-like tissue. *Mol Cell Endocrinol.* 2015;**408**:165–177.
28. Chrusciel M, Vuorenoja S, Mohanty B, Rivero-Müller A, Li X, Toppari J, Huhtaniemi I, Rahman NA. Transgenic GATA-4 expression induces adrenocortical tumorigenesis in C57Bl/6 mice. *J Cell Sci.* 2013;**126**(8):1845–1857.
29. Bielinska M, Kiiveri S, Parviainen H, Mannisto S, Heikinheimo M, Wilson DB. Gonadectomy-induced adrenocortical neoplasia in the domestic ferret (*Mustela putorius furo*) and laboratory mouse. *Vet Pathol.* 2006;**43**(2):97–117.
30. Kiiveri S, Siltanen S, Rahman N, Bielinska M, Lehto VP, Huhtaniemi IT, Muglia LJ, Wilson DB, Heikinheimo M. Reciprocal changes in the expression of transcription factors GATA-4 and GATA-6 accompany adrenocortical tumorigenesis in mice and humans. *Mol Med.* 1999;**5**(7):490–501.
31. Berthon A, Drelon C, Val P. Pregnancy, primary aldosteronism, and somatic *CTNNB1* mutations. *N Engl J Med.* 2016;**374**(15):1493–1494.
32. Murtha TD, Carling T, Scholl UI. Pregnancy, primary aldosteronism, and somatic *CTNNB1* mutations. *N Engl J Med.* 2016;**374**(15):1492–1493.
33. Berthon A, Drelon C, Ragazzon B, Boulkroun S, Tissier F, Amar L, Samson-Couterie B, Zennaro MC, Plouin PF, Skah S, Plateroti M, Lefèbvre H, Sahut-Barnola I, Batisse-Lignier M, Assié G, Lefrançois-Martinez AM, Bertherat J, Martinez A, Val P. WNT/ β -catenin signalling is activated in aldosterone-producing adenomas and controls aldosterone production. *Hum Mol Genet.* 2014;**23**(4):889–905.
34. Nakamura Y, Maekawa T, Felizola SJ, Satoh F, Qi X, Velarde-Miranda C, Plonczynski MW, Ise K, Kikuchi K, Rainey WE, Gomez-Sanchez EP, Gomez-Sanchez CE, Sasano H. Adrenal CYP11B1/2 expression in primary aldosteronism: immunohistochemical analysis using novel monoclonal antibodies. *Mol Cell Endocrinol.* 2014;**392**(1–2):73–79.
35. Louiset E, Contesse V, Groussin L, Cartier D, Duparc C, Perraudin V, Bertherat J, Lefebvre H. Expression of vasopressin receptors in ACTH-independent macronodular bilateral adrenal hyperplasia causing Cushing's syndrome: molecular, immunohistochemical and pharmacological correlates. *J Endocrinol.* 2008;**196**(1):1–9.
36. Suzuki S, Uchida D, Koide H, Suyama K, Shibata T, Yoshida T, Tanaka T, Noguchi Y, Saito Y, Tatsuno I. A possible association between aldosterone response to vasopressin and circadian change of aldosterone in the patients with aldosterone-producing adenoma. *Peptides.* 2008;**29**(12):2225–2231.
37. Wallace C, Toth EL, Lewanczuk RZ, Siminoski K. Pregnancy-induced Cushing's syndrome in multiple pregnancies. *J Clin Endocrinol Metab.* 1996;**81**(1):15–21.
38. Lacroix A, Hamet P, Boutin JM. Leuprolide acetate therapy in luteinizing hormone-dependent Cushing's syndrome. *N Engl J Med.* 1999;**341**(21):1577–1581.
39. Hána V, Dokoupilová M, Marek J, Plavka R. Recurrent ACTH-independent Cushing's syndrome in multiple pregnancies and its treatment with metyrapone. *Clin Endocrinol (Oxf).* 2001;**54**(2):277–281.
40. Chui MH, Ozbey NC, Ezzat S, Kapran Y, Erbil Y, Asa SL. Case report: Adrenal LH/hCG receptor overexpression and gene amplification causing pregnancy-induced Cushing's syndrome. *Endocr Pathol.* 2009;**20**(4):256–261.